Scholarly Research Exchange

Volume 2009 • Article ID 478468 • doi:10.3814/2009/478468

Research Article

Histologic Effects of Bilateral Adrenalectomy under the Light Microscopy on Rat Mandibular Condyle

Sabiha Zelal Ülkü,[1] Ali Ihsan Zengingul,[1] and Aydın Ketani[1, 2]

[1] *Department of Prosthodontics, Faculty of Dentistry, Dicle University, 21280 Diyarbakır, Turkey*
[2] *Department of Histology-Embriology, Faculty of Medical Veterinary, Dicle University, 21280 Diyarbakır, Turkey*

Correspondence should be addressed to Sabiha Zelal Ülkü, zelal_baskan@hotmail.com

Received 25 July 2008; Accepted 13 April 2009

The aim of this study was to compare the histologic findings from the condyles of rats with the general system findings. 30 Sprague-Dawley adult rats were used. The rats were sacrified and their condyles and femurs were examined histologically. The rats' weight were observed weekly, their femoral height and weight, femoral mineral elements, and their daily food and water consumes were recorded. The results were analysed statistically by using SPSS (10.0). During the histologic examination of femur, the osteogenesis and calcification of the femur layers of the male/female rats in the experimental group were found to be lower than those of the ones in the control group. In addition to that, during the histological examination of condyle the level of thickness of condyle layers, the number of cellular elements, the osteogenesis and calcification seemed to be decreased for the male/female rats in the experimental group than for those in the control group. The decrease was found to be more significant for the female rats than the male rats in experimental group and it is thought that this is related to the gonad hormones. These findings emphasize that a reduction of sex hormone levels, induced by adrenalectomy, significantly influences condylar histogenesis.

1. Introduction

Although adrenal gland has been known as the vital organ until the mid of the 19 century, its role in metabolism was not clear. However, within the light of the experiments with the animals which had adrenalectomy, it was found there was a strong relationship between adrenal gland and metabolism [1]. It is known that the development of the bones in the skeleton system is related to hormones. During the Addison's disease which occured by the bilateral adrenalectomy, there are some hormonal changes which result in the development of the bones [2, 3]. Glucocorticoids and mineralocorticoids play an important role in the biochemical differentiation of various organs during development. Adrenocortical hormones are known to have potent effects on bone cells [4–6].

The growth of the skull is governed and influenced by a number of factors [7–10]. The morphology of the temporomandibular joint reflects the complex development of the entire skull. The morphology of the temporomandibular joint (TMJ) should be studied from many different points of view because the TMJ, as a secondary and appositional joint, is one of the phylogenetically new acquisitions of mammals [7, 8]. The mandibular condyle is a major growth site and plays a significant role during mandibular development. Cartilage of the mandibular condyle provides regional adaptive growth, endochondral bone growth and a movable articulation [8, 9]. Thus information on skull morphogenesis as a whole is a prerequisite for understanding growth process in the TMJ. All studies known, so far have been restricted to the examination of the perichondral and chondral articular covering of the temporomandibular joint [7].

Within the light of these results, in the present study we investigated the possible role of adrenocortical hormones on the effects of condylar bone formation in rats.

2. Material and Methods

The experimental procedure was authorized and reviewed by the Dicle University Animal Research Ethics Committee. The study included 30 Sprague-Dawley, male/female, adult rats weighing between 260 and 350 g. 10 unoperated rats served as controls. 20 of them were consisted in the experimental

group. The rats of both groups were fed pellet-food (formula VTD-I) and water ad libitum. Body weight were observed weekly, food intake and water consumes were monitored daily. The rats were maintained for 21 days in laboratory after experiment in a controlled environment with a 12 hour light-dark cycle and a constant temperature of 22°C.

All rats in the adrenalectomy group were given water supplemented with 0.9% NaCl+1.1% Calcidine Ca+Glucose in order to compensate for the elimination of mineralocorticoids after adrenalectomy and ensure the best possible survival rate for operated animals.

All surgical procedures were accomplished under general anesthesia with an intramuscular injection of Ketamin HCl (Ketalar,) 25 mg/kg and xylazine (Rampun,) 0.1 mL, ten female and ten male rats underwent bilateral adrenalectomy. The two female rats died after operation. This two rats was excluded in our study. Each of the experimental and control rats were killed for histologic examinations under general anesthesia 3 weeks after surgery.

The heads of rats were chosen for histology of the condyle. Both TMJs and femurs were removed from each rat after fixation and decalcification. The mandibular condyles and femurs were fixed in 10% neutral formalin and decalcified in 5% formic acid. Temporomandibular joints and femurs were embedded in paraffin and 4.5 μm thick sagittal sections were stained with haematoxylin and eosin, toluidine blue and van Gieson's stain.

The haematoxylin and eosin stained sections were used to measure the thickness of the condylar cartilage layer. The articular cartilage layer was divided into fibrous (articular), proliferative (chondrogenic), and maturative/hypertrophic (cartilaginous) zones.

Measurements of condyles and femurs were made using an ocular scale (0.01 mm gradations) adapted to a Nikon-E400 light microscope under ×10 and ×20 objective magnification.

The dried femurs were ashed for 20 hours at 800°C; ash weight was measured and mineral content was determined by routine laboratory tests on a spectrometry (Unicam 929 AA Spectrometer).

The rats' weights were observed weekly, their femoral height and weight, femoral mineral element contents, and their daily food and water consumes were recorded.

The data were analyzed using SPSS software (SPSS 10.0 edition for Windows). Two-way analysis of variance was used to compare the control and experimental groups. Finally levene statistical test was used to analyse the homogenic test of group scores.

3. Results

3.1. Changes in the Body Weight. No remarkable differences in the body weight were found between the adrenalectomy male/female rats and the corresponding control rats (Figure 1). Thus, the experimental rats exhibited an almost equivalent growth to the controls, indicating negligible influences of the surgery on general growth in terms of the changes in body weight.

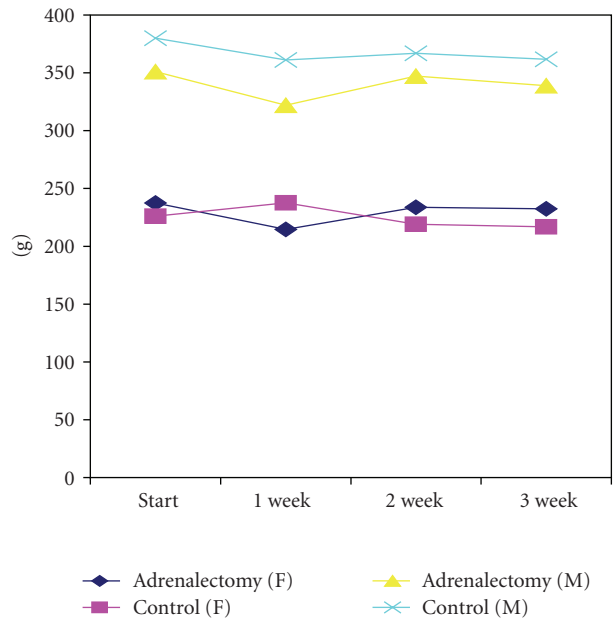

Figure 1: Variations in the body weights in the experimental and control groups.

3.2. Femoral Height and Weight. In femoral bone, we found that dry and ash weights normalized by body weight were lower in the adrenalectomy group than in the corresponding control group.

No significant differences were found in femoral height between the experimental and control groups of animals ($P > .05$).

3.3. Femur Mineral Contents. Femur was analyzed for calcium, copper, iron and phosphate content using routine laboratory tests on a spectrometry. The effects of adrenalectomy were far more important for calcium and copper than for iron and phosphate. Compared with controls, only calcium and copper contents were reduced, in the adrenalectomized (Adx) rats ($P > .05$). Despite this decrease in femoral bone weight in adrenalectomized rats, only calcium and copper contents were found fallen.

3.4. Food and Water Consumes. The water consumption increased in two experimental groups from 1 day to 21 days. The water consumption was balanced in the control groups (female and male) between 1 day and 21 days. The increased water consumption (from 1 day to 21 days) explain a cronic appetite for sodium in rats with bilateral adrenalectomy [3].

While there were balanced results in the experimental and control groups, only the water consumption showed evident falling in 13th days in two groups. We think that the cause of falling can be Addison crisis.

3.5. Histologic Findings. Light microscopy examination revealed great histological differences between the adrenalectomy and control groups.

During the histologic examination of femoral bone, the osteogenesis and calcification of the femur layers in the

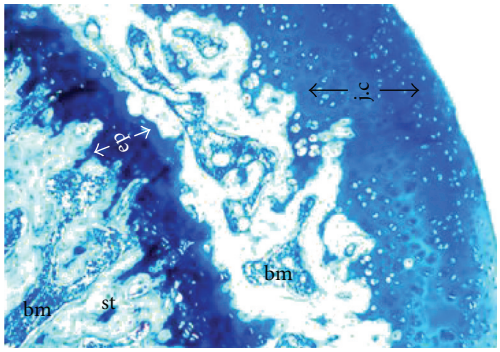

(a)

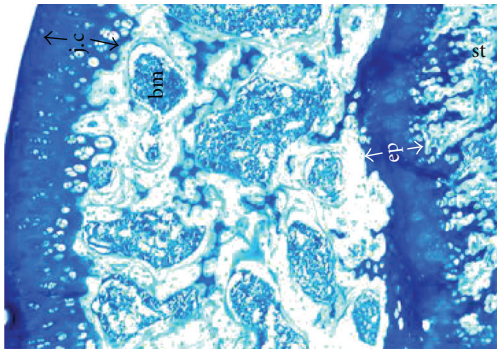

(b)

Figure 2: Light micrographs of toluidine-blue-stained of the femoral shaft in the adrenalectomy and control male rats (a) control male (b) adrenalectomy male. (magnification ×10).

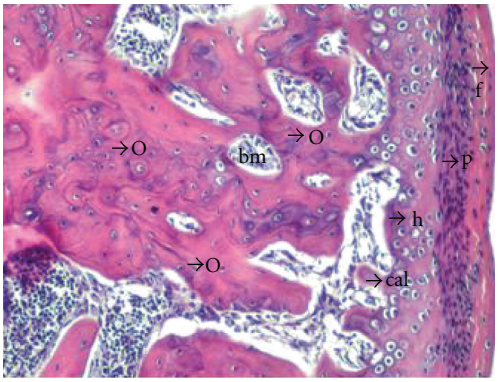

(a)

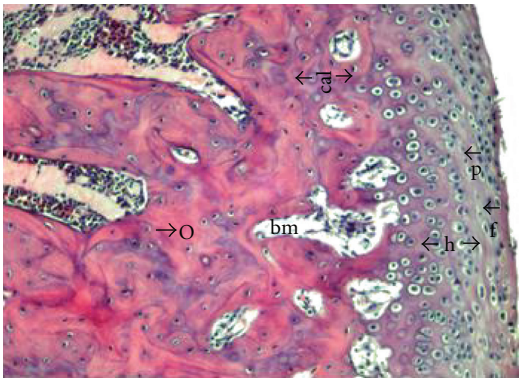

(b)

Figure 3: Photomicrographs of the condyle in the adrenalectomy and control female rats (a) control female (b) adrenalectomy female. (H-E stain; magnification ×20).

experimental group were found to be lower than those of the ones in the control group (Figure 2).

The histological observations show that; condyle have seven different regions during the enchondral ossification, only upper and lower hypertrophied cell zones were chondrogenic cells, central and posterior region were wider than anterior region.

The control group showed a distinct and marginally located fibrous layer, whereas this layer was recognizable but very thin in the adrenalectomy group. The adrenalectomy rats exhibited a decrease in trabecular bone volume, significantly different from the controls. The intercellular matrix of the mesenchymal cells under fibrous layer is increase and staining faintly metachromatically in experimental group rats (Figure 3).

The proliferative layer staining faintly metachromatically in experimental group. The metachromasia of the intermediate cell is totally absent and around of chondrocell are staining orthochromatically. This situation prove delay of ossification. Further posteriorly, the metachromasia of the intercellular matrix in proliferative layer is heavily in control group rats.

The number of cartilage cell and cell diagnosis increased in hypertrophied layer. Metachromasia of the intercellular matrix in hypertrophied layer was absent, However, there was metachromasia arround of cartilage cells. This situation proves the delay of ossification too.

In addition, the transition is irregular in ossification space (Figure 4).

4. Discussion

Experimental studies on the stomatognathic system can supply information on the effects of single factors in craniogenesis [7, 10]. In our study, we measured the morphological changes which had taken place in the mandibular condylar cartilage and in specific parameters of the skull after the bilateral adrenalectomy. To our knowledge, only a few recent similar articles have alluded to the effect of adrenalectomy on the temporomandibular condyle.

Reports have indicated that adrenocortical hormones have aindica range of effects on different body systems [6]. Our findings revealed histological evidence of mandibular condyle changes due to adrenalectomy. The aim of the present investigation was to study the relationships between condylar variations of layer dimensions, hormonal activities, and structural composition.

We use the van Gieson stain to show collagen and toluidine blue to show glycosaminoglycans [9, 11].

Aufdemorte et al. reported that the temporomandibular joint components of baboon contain numerous cells with receptors for estrogen, particularly on the surface of

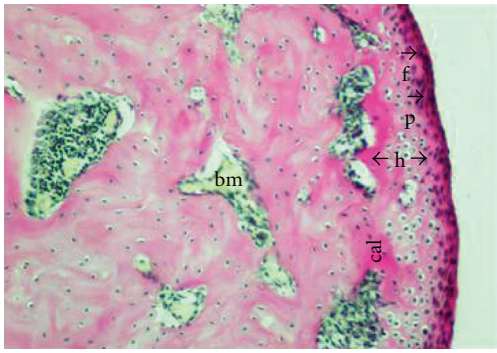

(a)

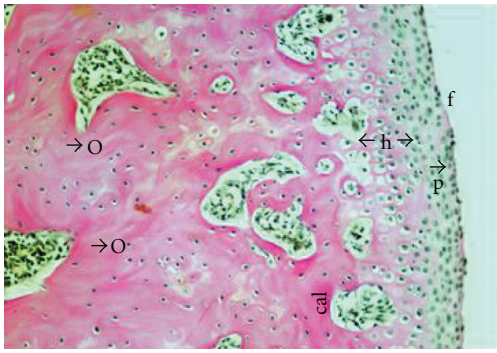

(b)

Figure 4: Photomicrographs of the condyle in the adrenalectomy and control male rats (a) control male (b) adrenalectomy male. (H-V-G stain; magnification ×20).

condyle, articular disk, and capsule. Meanwhile, estrogen receptors are rarely found in the masticatory muscles. As a result, one may postulate a role of the sex steroid hormones in the maintenance, repair, and/or pathogenesis of the temporomandibular joint structures [11]. Similar conclusions were drawn by Milam et al. They reported an absence of estrogen receptors in the temporomandibular joint complex of male baboon, further suggesting that estrogen may modulate, both directly and indirectly, cetrain metabolic events in the temporomandibular joint complex of the female baboon. These events include alteration of the immune response, changes in collagen synthesis [12].

The present results may clearly indicate the association between the condylar changes and sex hormones. It is considered that an decrease in the calcification in the experimental group may have resulted from the hormonal changes.

These results also indicate that estrogen may alter condylar remodelling, leading to degenerative changes in the temporomandibular joint. Similar conclusions were drawn by Fujita et al. [8].

5. Conclusion

The calcification and osteogenesis of condyle and femur in the adrenalectomize rats was lower than in the control rats.

In addition to that, during the histological examination of condyle the level of thickness of condyle layers, the number of cellular elements, the osteogenesis and calcification seemed to be decreased for the male/female rats in the experimental group than for those in the control group. The decrease was found to be more significant for the female rats than the male rats in experimental group and it is thought that this is related to the gonad hormones. It is highly emphasized that the sex hormones influence the morphogenesis of condyle in terms of the calcification and the influences of hormonal disturbances exerted by adrenalectomy in condylar histology are different between male and female.

In conclusion, adrenalectomy modifies differentiation process of the mandibular condyle in rats, demonstrating the important role of adrenals and adrenal hormones.

References

[1] M. Cotterrell, R. Balaazs, and A. L. Johnson, "Effects of corticosteroids on the biochemical maturation of rat brain: postnatal cell formation," *Journal of Neurochemistry*, vol. 19, no. 9, pp. 2151–2167, 1972.

[2] A. Montoli, G. Colussi, and L. Minetti, "Hypercalcaemia in Addison's disease: calciotropic hormone profile and bone histology," *Journal of Internal Medicine*, vol. 232, no. 6, pp. 535–540, 1992.

[3] S. Ten, M. New, and N. Maclaren, "Clinical review 130: Addison's disease 2001," *The Journal of Clinical Endocrinology & Metabolism*, vol. 86, no. 7, pp. 2909–2922, 2001.

[4] N. Demir and R. Demir, "Effects of maternal bilateral adrenalectomy on fetal rat cerebral cortex," *International Journal of Neuroscience*, vol. 111, no. 1-2, pp. 21–38, 2001.

[5] R. H. Williams, *Textbook of Endocrinology*, W. B. Saunders, Philadelphia, Pa, USA, 1968.

[6] E. Zerath, X. Holy, S. G. Roberts, et al., "Spaceflight inhibits bone formation independent of corticosteroid status in growing rats," *Journal of Bone and Mineral Research*, vol. 15, no. 7, pp. 1310–1320, 2000.

[7] J. Fanghanel and B. Miehe, "The influence of altered occlusion on the condylar cartilage of the mandible and on the growth of the entire skull," *Annals of Anatomy*, vol. 176, no. 1, pp. 61–65, 1994.

[8] T. Fujita, T. Kawata, C. Tokimasa, S. Kohno, M. Kaku, and K. Tanne, "Breadth of the mandibular condyle affected by disturbances of the sex hormones in ovariectomized and orchiectomized mice," *Clinical Orthodontics and Research*, vol. 4, no. 3, pp. 172–176, 2001.

[9] M. Delatte, J. W. Von den Hoff, R. E. M. van Rheden, and A. M. Kuijpers-Jagtman, "Primary and secondary cartilages of the neonatal rat: the femoral head and the mandibular condyle," *European Journal of Oral Sciences*, vol. 112, no. 2, pp. 156–162, 2004.

[10] H. U. Luder, "Structure and growth activities of the mandibular condyle in monkeys (*Macaca fascicularis*)—I. Intracondylar variations," *American Journal of Anatomy*, vol. 166, no. 2, pp. 223–235, 1983.

[11] T. Kantomaa, "New aspects of the histology of the mandibular condyle in the rat," *Acta Anatomica*, vol. 126, no. 4, pp. 218–222, 1986.

[12] S. B. Milam, T. B. Aufdemorte, P. J. Sheridan, R. G. Triplett, J. E. Van Sickels, and G. R. Holt, "Sexual dimorphism in the distribution of estrogen receptors in the temporomandibular joint complex of the baboon," *Oral Surgery, Oral Medicine, Oral Pathology*, vol. 64, no. 5, pp. 527–532, 1987.