Scholarly Research Exchange

SRX Neuroscience • Volume 2010 • Article ID 219261 • doi:10.3814/2010/219261

Case Report

Ganser Syndrome in a Patient with Dementia: A Case Report

Bernardo Ng[1,2,3] and Elma D. García[1,3]

[1] *Sun Valley Research Center, Imperial, CA 92251, USA*
[2] *Department of Psychiatry, University of California, San Diego, CA 92093, USA*
[3] *Nuevo Atardecer, Geriatric Center, Mexicali 21100, Mexico*

Correspondence should be addressed to Bernardo Ng, bng@sunvalleyb.com

Received 4 February 2010; Revised 14 March 2010; Accepted 17 March 2010

We present a case of a demented patient who experienced a reversible period of superimposed symptoms typical of Ganser syndrome. This is a poorly understood condition characterized by paralogia, clouding of consciousness and dissociative/conversion symptoms. Etiological factors include personal conflicts, organic brain syndromes, and child abuse. Even though more common in young adults, cases of conversion disorder in the elderly have been described as a form of pseudodementia, with functional impairment yet no evidence of organic deterioration. This was a 78 year old married male who came to our geriatric center after a hospitalization for a urinary tract infection, bronchitis and dehydration. The initial psychiatric evaluation offered evidence to rule out delirium, and errors in calculation compatible with paralogia (near right answers), disorientation, and errors in reality testing. Family also gave a history of an insidious and progressive deterioration of his cognition prior to his hospitalization that was not compatible with our initial findings. As well as a conflicting relationship with his ill and dependent wife. The treatment course during the following 12 months showed improvement in his mental status, compatible with the resolution of a superimposed and transient state compatible with Ganser syndrome, in a patient with underlying dementia of the Alzheimer type.

1. Introduction

Ganser syndrome is a poorly understood condition characterized by the giving of approximate answers (paralogia) together with a clouding of consciousness (i.e., disorientation, amnesia, loss of personal information, or impairment in reality testing), accompanied in about half of cases by auditory and/or visual hallucinations and other dissociative, somatoform or conversion symptoms. Etiological factors include personal and financial conflicts, organic brain syndromes, seizures, head injuries, and histories of child abuse [1].

Most cases have been described in young adults, in fact, conversion disorders in the elderly are rare and have been described as a form of pseudodementia. However, different to depressive pseudodementia that has been recognized to convert to dementia in up to 70% of cases, conversive pseudodementia courses with a syndrome that includes cognitive impairment, functional regression, and increasing physical dependency without evidence of organic deterioration [2, 3].

Unlike previous reports, we present a case of a demented patient followed up for 12 months who experienced a superimposed reversible period of the characteristic symptoms of Ganser syndrome, chronologically related to an overwhelming personal/family conflict.

2. Case Presentation

Mr. M is a 78-year-old Latino retired physician that became a patient at our Geriatric Center in June 2007. This was after an acute hospitalization for an episode of urinary tract infection, bronchitis, and dehydration. His geriatrician insisted that he did not return directly home until he was stronger and received appropriate medical and psychiatric rehabilitation treatment. He was discharged on levofloxacyn, escitalopram, clonazepam, olanzapine, and respiratory treatments with ipratropium/salbutamol. Upon admission, a physical exam ancillary tests included normal blood count and metabolic panel, and a brain MRI showed generalized atrophy without evidence of mass or prominent vascular-related changes (Figure 1).

Prior to his hospitalization Mr. M had taken it upon himself to take care of his disabled wife, at home, without

anyone else's assistance. His children had for weeks tried to either help or hire help to ease the burden, but he responded with refusal and increased isolation. On retrospect they were able to identify for about 6 months, some manifestations of cognitive deterioration, including getting lost at a department store, at least 2 episodes of not finding his car in a parking lot, and having trouble organizing his wife's medication. The final events prior to hospitalization included his trying to use a syringe on his wife for "drawing" blood instead of giving insulin and his plan to operate on her with a kitchen knife.

On our first psychiatric encounter, he was disorientated in place and time and exhibited peculiar errors in calculation and praxis. When asked how many $50 dollar bills were needed to complete $450, his answer was 8; when asked to spell "world", he spelled "worldly". He was then asked to draw a clock showing 2 : 30, he drew the hands of the clock showing 7 : 25 and 3 extra circles on the face of the clock instead of the clock numbers. Two more designs were given in which he copied "almost" correctly and in reverse order (Figure 2). He was also given an addition of 2 figures of 3 digits and he missed by ±2 or 3 points. His minimental status exam (MMSE) was 10/30, yet it appeared as if he did not exert enough effort. During the first 2 weeks at our center he remained disoriented without fluctuation in his level of consciousness. His sleep/wake cycle was inverted, and he was paranoid about having his belongings stolen, so he would put them away during the night in different drawers and under his bed or pillow. He needed help dressing up, taking a shower, tying up his shoes, and toileting, as he was unable to organize the steps to do it properly. He would no longer talk about his wife spontaneously, when inquired, he answered he missed her but did not mention her illnesses and/or care requirements. He was taken off escitalopram, the clonazepam was tapered off, olanzapine was titrated to 10 mg at bed time, and he was started on donepezil. The latter was started to the family's request as they saw the rapid deterioration of the patient's cognitive functions and the possibility of Alzheimer's dementia being entertained.

He continued with similar errors the first 4 weeks, until he was able to draw the hands of a clock correctly at 2 : 30, but he claimed it was wrong and when asked to complete the clock with numbers, he instead drew a second clock where you could appreciate hands indicating 2 : 35 in themidst of a total of 8 hands (Figure 3). He also solved a 3-digit subtraction correctly, but when he realized it, wrote 3 other different results all ending in the same digit (Figure 4). Within 6 weeks he had a remarkable improvement in his MMSE score going up to 21/30, with no more evidence of paralogia or cloudiness of consciousness.

At this point the patient and family were informed that Mr. M had probable Alzheimer's dementia, based on the history of at first insidious but eventually progressive deterioration of cortical functions (i.e., memory, judgment and orientation), a negative history of vascular disease (supported by a negative MRI of the brain to vascular events), and a negative work -up for other metabolic or toxic etiological factors. Donepezil was therefore continued

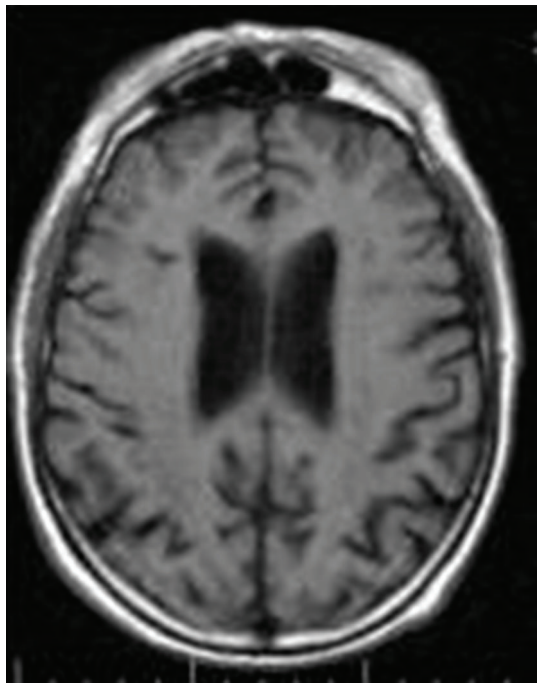

Figure 1

Figure 2

and the family educated of the superimposed and resolving symptoms being of a different nature.

The psychotherapeutic approach with Mr. M included working in cooperation with the family, to whom he kept inquiring about his wife's condition and his desire to care for her. We planned a home pass with the intention that he spent the night, with the message that he was also ill, such that if he wanted to do something for his wife, he could do it with the assistance of a home nurse. In other words, both of them were ill, and both would be under the care of a home nurse. The plan failed as he requested to be brought back to

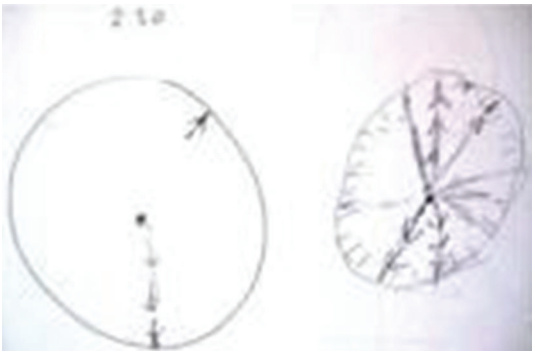

Figure 3

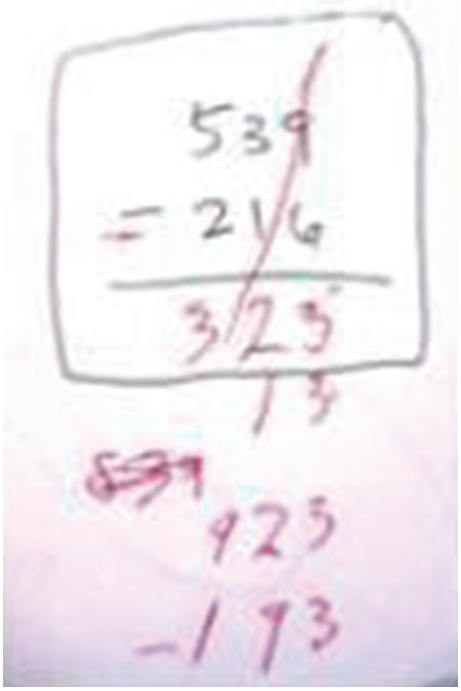

Figure 4

the center after spending only one hour at home. Since then passes were successful if they were to the movies or to eat at a restaurant without his wife included. Any attempts to go home resulted in bouts of anxiety and fear and request to return to the center with statements such as "they need me there. . ."

Four months after admission, his MMSE was 22/30 and went up to 24/30 by twelve months after admission. Mr. M exhibited intermittent agitation with occasional verbal aggression and verbal sexual advances to female staff but no longer paranoid. He was successfully switched from olanzapine to divalproex, which has been continued until the time of this report without major side effects. He has become able to independently dress up, self-feed, toilet, and shower. He has occasionally asked to return home to care for his wife and has been offered to try the overnight pass first, which has continued to fail.

3. Discussion

Mr. M's report illustrates a case with symptoms compatible with Ganser syndrome, in an elderly and demented patient. He presented with the classic features of paralogia and clouding of consciousness. It can be clinically argued that the rapid and sustained recovery in his MMSE [4] score was secondary to the resolution of a delirium as he had gone through acute respiratory and urinary condition. However, at the time of the first psychiatric consultation, his metabolic markers were normal and his level of consciousness remained without fluctuations throughout the day, supporting the conclusion that the symptoms were not due to an organic condition. But even in the possible scenario of an organic etiology, it does not rule out the possibility of Ganser Syndrome, in fact the available literature insists that the clinician must not obviate an organic work-up in individuals with this clinical presentation especially if they are middle age or older [1].

Given the history obtained, Mr. M was already exhibiting cognitive deficits, but it was hard for the children to inquire about it because of the patriarchal structure of their family. He is a retired yet prominent and authoritative physician in his community and home, so they were hesitant to bring up to him the changes they had observed. In Mr. M's particular case, establishing the clinical diagnosis of Alzheimer's dementia empowered the family to take the necessary steps to look after his health and his estate.

We believe the Ganser symptoms served as a way to save face and not have to return to an overwhelming situation at home. In fact the only way he was able to first "allow" himself to "quit" caring for his wife was when he got medically and acutely ill. It seems as if his being a physician made him feel obligated to be the one directly caring for his wife and at the same time too proud to ask for help, yet the concurrent and evolving cognitive deficits ended up in his inability to care even for himself.

Ganser syndrome has been classified both as a conversion disorder and as dissociative disorder. The onset of conversion disorders is generally late childhood to young adulthood. It is rare before age 10 and after age 35, but onset has been described as late as age 90. It is more common among rural population, persons with little education, those with low intelligence quotient, those in low socioeconomic groups, and military personnel who have been exposed to combat situations [1]. Interestingly enough, Mr. M does not meet most of the features mentioned above. He is a retired middle-upper class physician with a specialty in epidemiology in a mid-size city.

Unfortunately no systematic treatment studies have been conducted given the rarity of the condition as most available information is derived from case reports [1, 5]. Some guidance can be derived from general measures recommended for management of other conversion and "functional" syndromes, which include an honest and open approach, including the idea that as a physician one believes in the patient's symptoms, as well as educating the patient about the diagnosis and the possibility of psychopharmacologic agents and especially psychotherapy to explore underlying psychological issues [6].

We decided to report this case as we believe it is of clinical importance for various reasons. First, the clinician should keep in mind that these disorders can happen at any age, including the elderly that represent a rapidly expanding patient population. Second, it is important to identify conversion symptoms even in demented patients to elaborate a customized psychotherapeutic plan to prevent disability and improve function. Last but not least family members are usually very interested in having the correct diagnosis, in order to make plans since the prognosis and course of the disorder may vary from that of Alzheimer's dementia.

Our clinical conclusion is that the diagnoses of Alzheimer's dementia and Ganser Syndrome are not mutually exclusive.

Acknowledgment

The authors thank family members for the necessary information to better understand this case, and Dr. Guillermo Diaz-Chavez for the care provided to this patient.

References

[1] B. J. Sadock and V. A. Sadock, *Kaplan & Sadock's Synopsis of Psychiatry: Behavioral Sciences/Clinical Psychiatry*, Lippincott Williams & Wilkins, Philadelphia, Pa, USA, 2007.

[2] J. Hepple, "Conversion pseudodementia in older people: a descriptive case series," *International Journal of Geriatric Psychiatry*, vol. 19, no. 10, pp. 961–967, 2004.

[3] J. A. Sáez-Fonseca, L. Lee, and Z. Walker, "Long-term outcome of depressive pseudodementia in the elderly," *Journal of Affective Disorders*, vol. 101, no. 1–3, pp. 123–129, 2007.

[4] M. F. Folstein, S. E. Folstein, and P. R. McHugh, ""Mini mental state": a practical method for grading the cognitive state of patients for the clinician," *Journal of Psychiatric Research*, vol. 12, no. 3, pp. 189–198, 1975.

[5] R. Latcham, A. White, and A. Sims, "Ganser syndrome: the aetiological argument," *Journal of Neurology Neurosurgery and Psychiatry*, vol. 41, no. 9, pp. 851–854, 1978.

[6] J. Stone, A. Carson, and M. Sharpe, "Functional symptoms in neurology: management," *Neurology in Practice*, vol. 76, no. 1, pp. 13–21, 2005.