International Scholarly Research Network
ISRN Anesthesiology
Volume 2011, Article ID 421505, 10 pages
doi:10.5402/2011/421505

Review Article

The Loss of Resistance Nerve Blocks

Shiv Kumar Singh[1] and S. M. Gulyam Kuruba[1, 2]

[1] *Department of Anaesthesia, Royal Liverpool University Hospitals, 11th Floor Prescot street, Liverpool L7 8XP, UK*
[2] *Mersey Deanery, Summers Road, Liverpool L3 4BL, UK*

Correspondence should be addressed to Shiv Kumar Singh, shvkmrsngh@aol.com

Received 10 August 2011; Accepted 15 September 2011

Academic Editor: A. Mizutani

Presently ultrasound guided nerve blocks are very fashionable but vast majority of people around the world cannot practice these techniques mostly due to lack of resources but even in the developed countries there is lack of training which precludes people from using it. Lack of resources does not mean that patient cannot be provided with appropriate pain relief using nerve blocks. There are some nerve blocks that can be done using the loss of resistance (LOR) techniques. These blocks like, tranversus abdominis plane (TAP), rectus sheath, ilio-inguinal and fascia iliaca blocks can be effectively utilized to provide pain relief in the peri-operative period. For these blocks to be effectively delivered it is essential to understand the anatomical basis. It is also important to understand the reasons for failure, which is mostly due to delivery of the local anaesthetic in the wrong plane. The technique for LOR is not only simple and effective but also it can be delivered with minimal resources. This article deals with the techniques used for LOR blocks, the relevant anatomy and the methods used to administer the blocks. The article also describes the various indications where these blocks can be utilized, especially in the post-operative period where the pain management is sub-optimal.

1. Introduction

The latest trend in regional anaesthesia is to perform nerve blocks under ultrasound guidance [1, 2]. Even in the developed countries, not all hospitals have facilities for performing ultrasound-guided nerve blocks and even if ultrasound machines are available, not many people are trained to use them. The recent publications also suggest that using ultrasound may improve the safety of performing nerve blocks, which dissuades many who are not proficient in performing ultrasound-guided nerve blocks from using other simple techniques. There are probably many small hospitals in this world where, leave alone ultrasound machines for nerve blocks, the theatres may not even have nerve stimulators or stimulating needles to perform blocks using peripheral nerve stimulation. This does not mean that nerve blocks cannot be performed safely and effectively on patients for acute pain relief. There are some simple blocks that can be done with just a needle and some local anaesthetics. These blocks, if done properly, provide good analgesia for most common procedures on the abdomen and for fracture neck of femurs. These blocks include rectus sheath, transversus abdominis plane (TAP), ilio-inguinal, and fascia iliaca blocks. In this paper, we describe the relevant anatomy, indications, and techniques to do these blocks.

2. Loss of Resistance Technique

Before dwelling into the individual blocks, it is important to understand the loss-of-resistance (LOR) technique and how it can be used to achieve maximum effect and the reasons why it sometimes fails. The LOR technique relies on using blunt or short-bevelled needles, which provide a good feedback (pops or clicks) when they pass through fascial planes. Short-bevelled needles are commercially available (Figure 1) but it is not necessary to always use them, or for that matter, they may not be available. For thinner patients and in situations where the fascial planes are not very deep, a 1.5″ 21 G (green) hypodermic needle is all that is required. Before using it, it needs to be modified for the LOR technique. After attaching a green needle to a syringe and with the bevel facing inwards, scrape it against the inner wall of a sterile glass ampoule till the tip bends towards

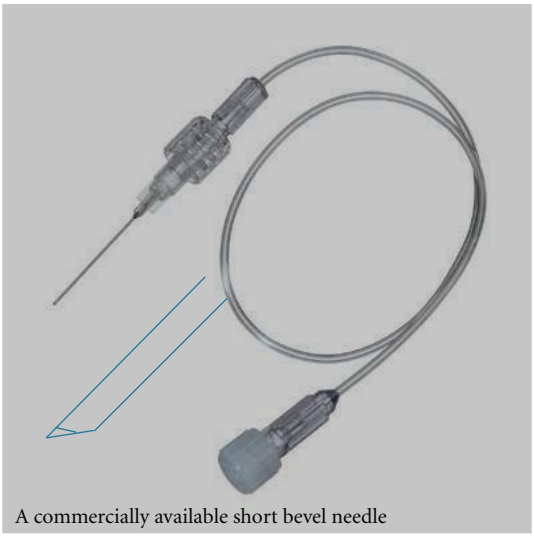

Figure 1: Commercially available short-bevel needle for LOR block.

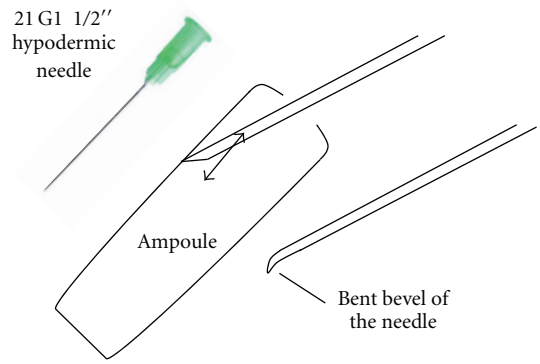

Figure 2: Modifying 21 G hypodermic needle for LOR Block.

the bevel (Figure 2). While using this needle for a LOR block, use the sharp end to enter the skin to reduce the damage (Figure 3).

For deep structures or for big and obese patients either Tuhoy needle or a 22 G pencil point spinal needle can be used. Despite the simplicity of these blocks, they still fail. The reason for this is inability to feel the "clicks/pops" especially in obese patients, where the fascial layers are weak and thinned out, or deposition of the local anaesthetic in the wrong plane. Depositing the local anaesthetic in a wrong plane probably is the commonest reason for failure of these blocks and this can be attributed to something we call the "cushion effect". What exactly is a cushion effect and why is it important?

3. The "Cushion Effect"

The needles used for the LOR are blunt or short bevelled and therefore a considerable amount of force is needed for the tip of the needle to pierce the skin. This large amount of force tends to obliterate the cushion of subcutaneous fat lying under the skin, the "cushion effect", and as the skin barrier is breached, the needle passes not only though the skin but also through the subcutaneous tissues and the fascia (Figure 4) [3]. This may lead to feeling "pops" in a wrong/deeper planes and deposition of local anaesthetic in the wrong place with failure and sometime complications (like femoral nerve block while performing hernia blocks), something which is not expected.

How do we prevent this from happening? The trick to preventing this is to pierce the skin and withdraw the needle back till the tip of the needle is just under the skin and then start feeling the loss of resistance. Before feeling the loss of resistance, it is always nice to feel the bounce on the fascia. Some people like to "scratch" the fascia before feeling the "pop". A small nick in the skin can also be made with a sharper bigger needle, before introducing the LOR needle through the skin. Another technique that has been described by the author is to use "needle-through-needle" technique (Figure 5) [3]. In this technique ("Singh technique"), a thin long blunt/short bevel needle (pencil or bullet point spinal needles can be used) is passed through a larger sharp needle (introducer). The sharp needle is initially introduced just through the skin and then the short bevel or blunt needle is used to seek the LOR.

4. Anatomy of the Transversus Abdominis Plane (TAP), Rectus Sheath, and Ilio-Inguinal Nerves

4.1. Anatomy of the Transversus Abdominis Plane. In the human body, on each side of the midline, there are four principle muscles. Three of these are flat muscles, arranged in layers in the lateral part of the abdominal wall. External oblique is the most superficial, internal oblique lies deep to it, and the deepest layer is transversus abdominis [4]. The intercostal nerves (T_{7-11}), subcostal nerves (T_{12}), ilio-inguinal and ilio-hypogastric nerves (L_1) that contribute to the innervation of the anterior abdominal wall run with their accompanying blood vessels in a neurovascular plane, known as the transversus abdominis plane (TAP) which lies between the internal oblique muscle and the transversus abdominis muscle (Figure 6). These nerves also supply the costal parts of diaphragm, related parietal pleura, and the parietal peritoneum. Most of these nerves, that course through the transversus abdominis plane, give rise to the muscular and lateral cutaneous branches (Ilioinguinal nerve has no lateral cutaneous branch) and after providing motor innervation to the rectus muscle and to pyramidalis, these nerves pierce the rectus sheath and end as anterior cutaneous nerves.

A recent review "refining the course of the thoracolumbar nerves; a new understanding of the innervation of the anterior abdominal wall" found that the fascial layer between the internal oblique and transversus abdominis muscles was more extensive than previously described [5]. This layer was not adherent to the internal oblique muscle layer and bound down the nerves on its deep surface to the transversus abdominis layer. The layer was present throughout the TAP

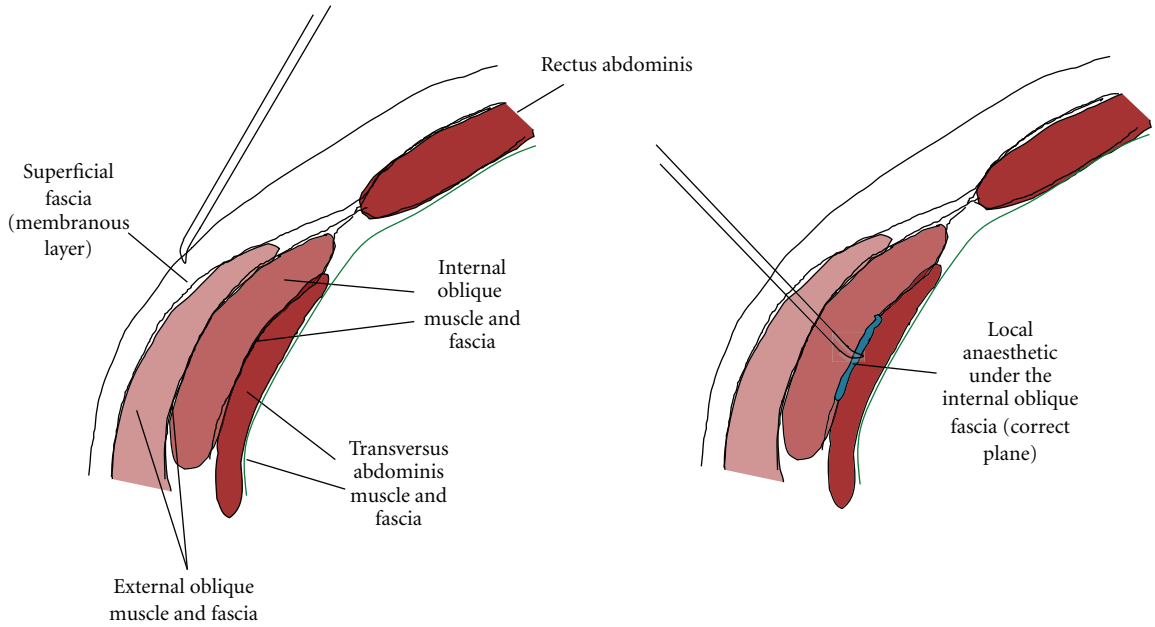

Using a blunt tip needle for LOR technique

Figure 3: Using the modified blunt-tip needle for LOR block; change the angle to almost 90° once the sharp end of the tip has pierced the skin.

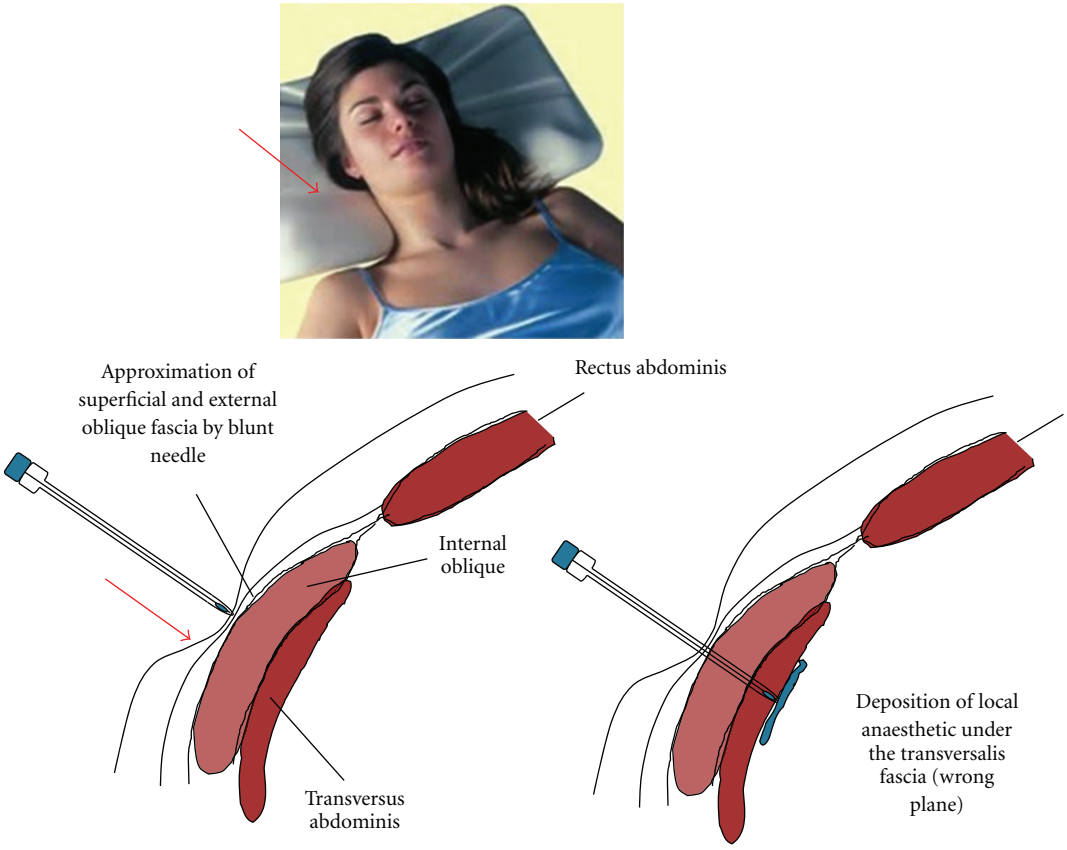

Figure 4: The "Cushion effect" caused by short bevel or blunt needles.

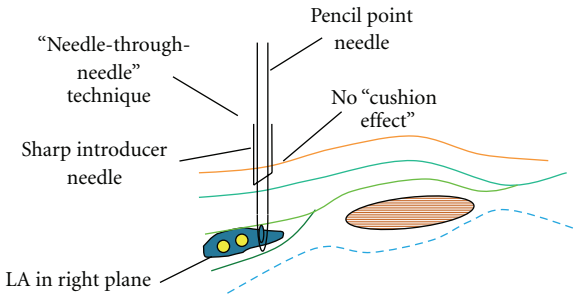

Figure 5: "Singh Technique" using needle through needle to prevent "cushion effect".

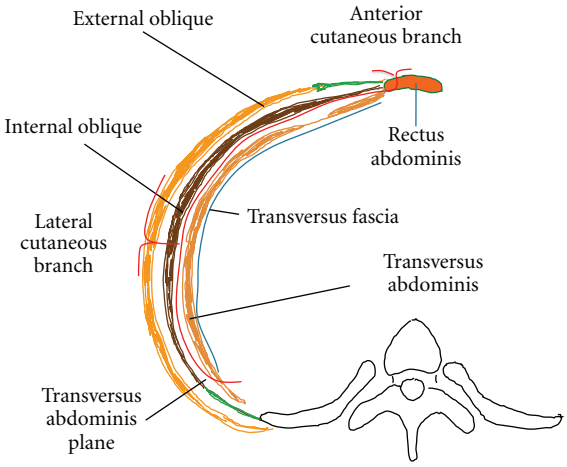

Figure 6: The abdominal wall muscles and the neurovascular plane.

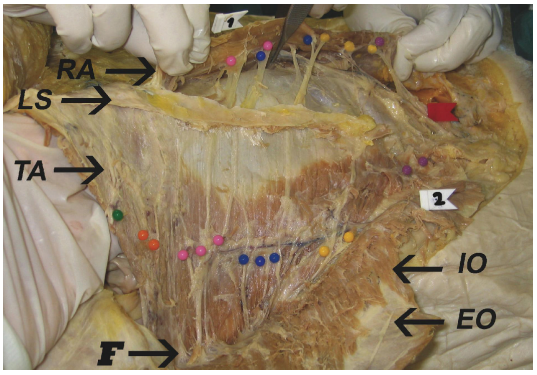

Figure 7: Dissection of the right anterolateral abdominal wall revealing the nerves of the transversus abdominis plane (TAP) and rectus sheath. White flag (1): level of umbilicus. White flag (2): anterior superior iliac spine. Red flag: pubic symphysis. Pins: purple L_1, yellow T_{12}, blue T_{11}, pink T_{10}, orange T_9, green T_8. RA: rectus abdominis muscle. LS: linea semilunaris. TA: transversus abdominis muscle. IO: internal oblique muscle. EO: external oblique muscle. F: fascial layer deep to internal oblique. (Courtesy Dr. Warren Rozen).

and extended medially to the linea semilunaris. It was also found that the T_6 enters the TAP just lateral to the linea alba and $T_{7–9}$ at progressively increasing distances from the linea alba. Nerves running in the TAP lateral to the anterior axillary line, on the other hand, originate from segmental nerves T_9–L_1. This may explain the observation of some authors that the TAP block is only suitable for lower abdominal surgery. There is extensive branching and communication of the segmental nerves in the TAP. In particular the T_9–L_1 branches form a so-called "TAP plexus" that runs with the deep circumflex iliac artery. This may partly account for the ability of a single injection to cover several segmental levels (Figure 7).

4.2. Anatomy of the Rectus Sheath and Rectus Abdominis Muscle. The rectus sheath is the strong, incomplete fibrous compartment of the rectus abdominis and pyramidalis muscles. Also found in the rectus sheath are the superior and inferior epigastric arteries and veins, lymphatic vessels, and distal portions of the thoracoabdominal nerves (abdominal portions of the anterior rami of spinal nerves $T_{7–12}$) [4]. The sheath is formed by the decussation and interweaving of the aponeuroses of the flat abdominal muscles. The external oblique aponeurosis contributes to the anterior wall of the sheath throughout its length. The superior two-thirds of the internal oblique aponeurosis splits into two layers, or laminae, at the lateral border of the rectus abdominis; one lamina passing anterior to the muscle and the other passing posterior to it. The anterior lamina joins the aponeurosis of the external oblique to form the anterior layer of the rectus sheath. The posterior lamina joins the aponeurosis of the transverse abdominal muscle to form the posterior layer of the rectus sheath (Figures 7 and 8).

Beginning at approximately one-third of the distance from the umbilicus to the pubic crest, the aponeuroses of the three flat muscles pass anterior to the rectus abdominis to form the anterior layer of the rectus sheath, leaving only the relatively thin transversalis fascia to cover the rectus abdominis posteriorly. A crescentic line, called the arcuate line, demarcates the transition between the aponeurotic posterior wall of the sheath covering the superior three quarters of the rectus and the transversalis fascia covering the inferior quarter. Throughout the length of the sheath, the fibers of the anterior and posterior layers of the sheath interlace in the anterior median line to form the complex linea alba [4].

The posterior layer of the rectus sheath is also deficient superior to the costal margin because the transverse abdominal muscle passes internal to the costal cartilages and the internal oblique attaches to the costal margin. Hence, superior to the costal margin, the rectus abdominis lies directly on the thoracic wall.

4.3. Anatomy of the Ilioinguinal and Iliohypogastric Nerves. The first lumbar nerve divides into upper and lower branches, the iliohypogastric and ilioinguinal nerves. The iliohypogastric nerve travels in the transversus abdominis plane and divides into two terminal branches just above the iliac crest; the lateral cutaneous branch supplies the upper lateral part of the gluteal region and the anterior cutaneous branch supplies the suprapubic region.

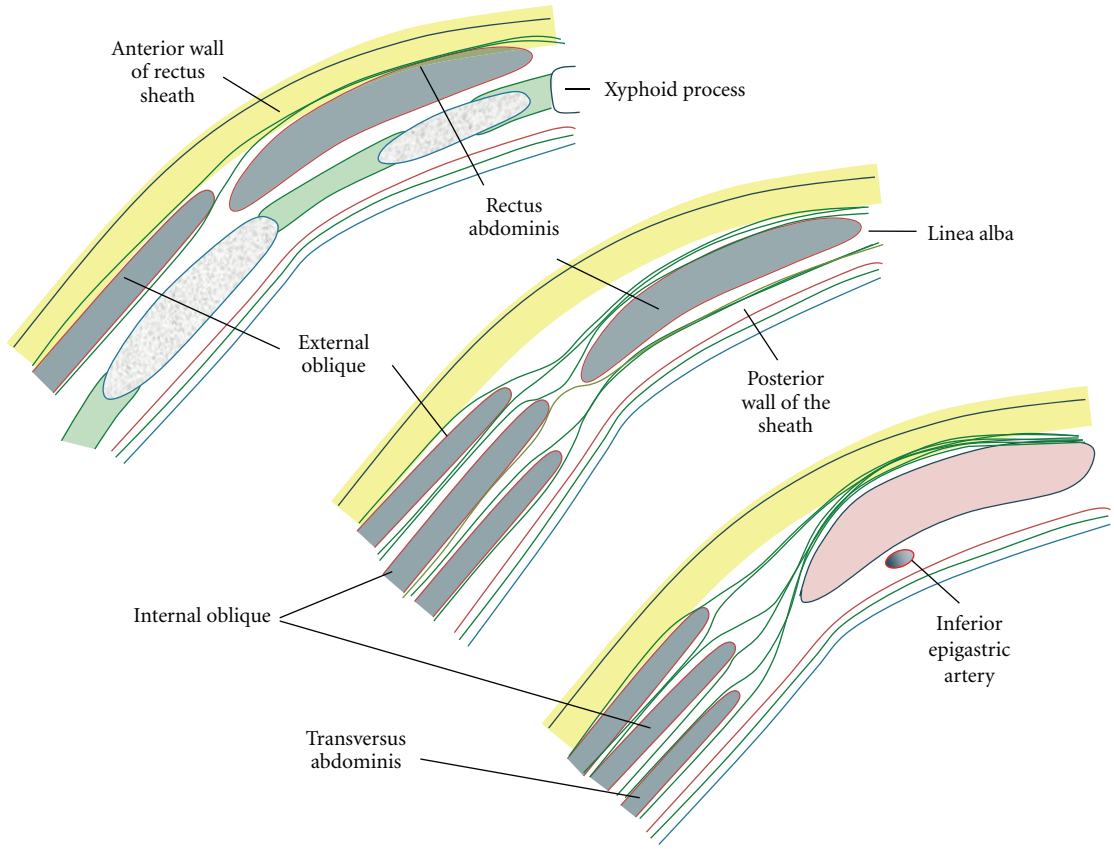

Figure 8: Formation of the rectus sheath at 3 different levels of the abdomen.

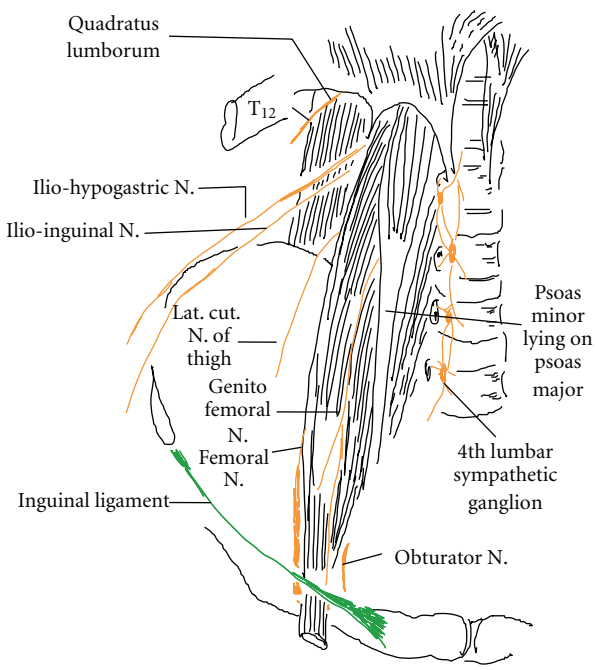

Figure 9: Iliohypogastric and Ilioinguinal nerves origin from the lumbar plexus.

The ilioinguinal nerve emerges from the lateral border of the psoas major just inferior to the iliohypogastric, passes obliquely across the quadratus lumborum and iliacus, and travels in the transversus abdominis plane (Figure 9).

It then leaves the neurovascular plane by piercing internal oblique above the iliac crest. It continues between the two obliques muscles and accompanies the spermatic cord (or round ligament of the uterus) in the inguinal canal [4, 6]. As it emerges from the superficial inguinal ring, it gives cutaneous branches to the skin on the medial side of the thigh, the proximal part of the penis, and front of the scrotum in males or the mons pubis and the anterior part of the labium majus in females (Figure 10).

5. Anatomy of the Fascia Iliaca Compartment

The fascia iliaca compartment is a potential space with the following limits: anteriorly it is covered by the posterior surface of the fascia iliaca, and posteriorly it is limited by the anterior surface of the iliacus muscle and the psoas major muscle. Medially the compartment is continuous with the space between the quadratus lumborum muscle and its fascia. The compartment spans from the lower thoracic vertebrae to the anterior thigh (Figure 11). The fascia iliaca lines the posterior abdomen and pelvis, covering psoas major and iliacus muscle, and it forms the posterior wall of femoral sheath, containing the femoral vessels. In

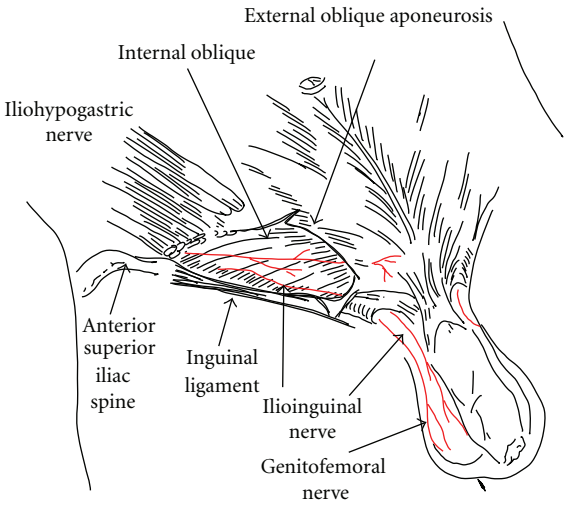

Figure 10: Iliohypogastric and Ilioinguinal nerves in the inguinal area.

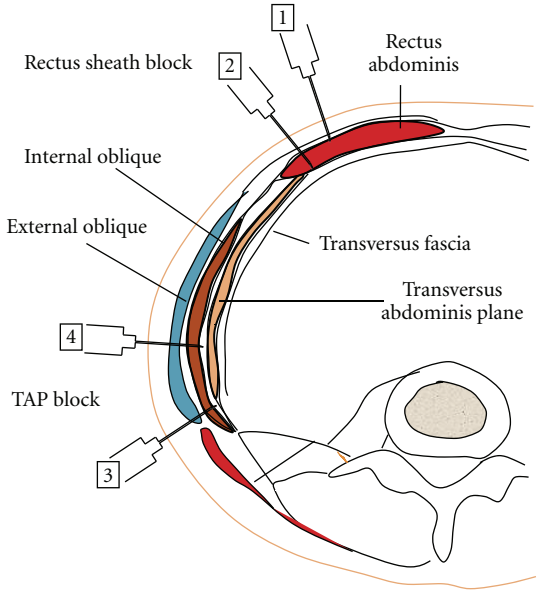

Figure 12: Approaches to Rectus sheath (1 & 2) and TAP block (3 & 4).

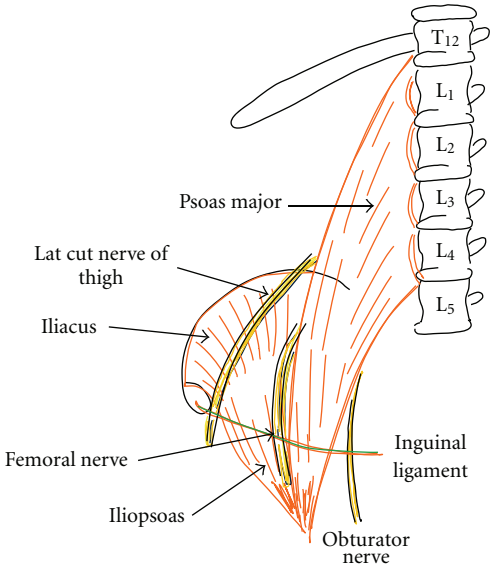

Figure 11: Iliacus and Iliopsoas muscles and the femoral and lateral cutaneous nerve of thigh.

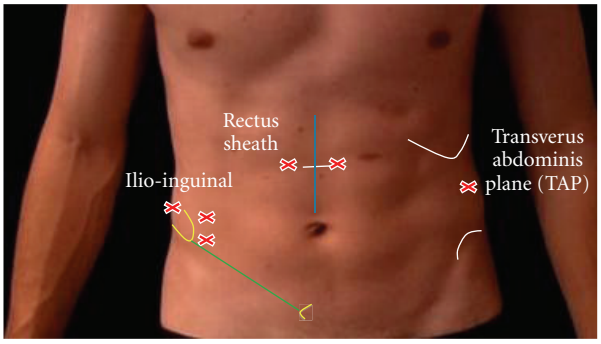

Figure 13: Landmarks for the Ilio-inguinal, Rectus sheath, and TAP blocks.

the femoral triangle, it is covered by fascia lata, blending with it further distally. The fascial covering of the iliopsoas is thin superiorly, becoming significantly thicker as it reaches the level of the inguinal ligament [6]. This thickness provides a great deal of resistance and a large "pop" as a needle tip is passed through the fascia. The femoral nerve enters the thigh beneath the inguinal ligament lying, within the fascia iliaca compartment, on iliopsoas lateral to the femoral sheath [6, 7].

6. Clinical Applications and Block Techniques

Regional analgesia techniques by blocking the nerves of the abdominal wall should be used as part of a multimodal analgesia technique. Blocks on their own are insufficient as they provide analgesia of the abdominal wall (somatic) and not the abdominal viscera [8]. These blocks have an important role in decreasing analgesic requirements and can often be used even in major abdominal surgery where epidural anaesthesia may be contraindicated [9]. The use of these blocks reduces the need for strong analgesics and the associated complications like respiratory depression, itching, nausea, and vomiting. These blocks can also be employed in the critical care settings to help in weaning patients from ventilatory support [10]. The blocks described here are so simple that they can be repeated in the postoperative period either to extend the analgesia or be used as rescue for failed epidurals. In our experience, we have used them as rescue techniques in patients who had open abdominal aneurysm repairs and had failed epidurals. The pain was uncontrollable despite PCA morphine and maximal boluses. The patient had bilateral TAP blocks and was successfully weaned off the PCA. We have also used them

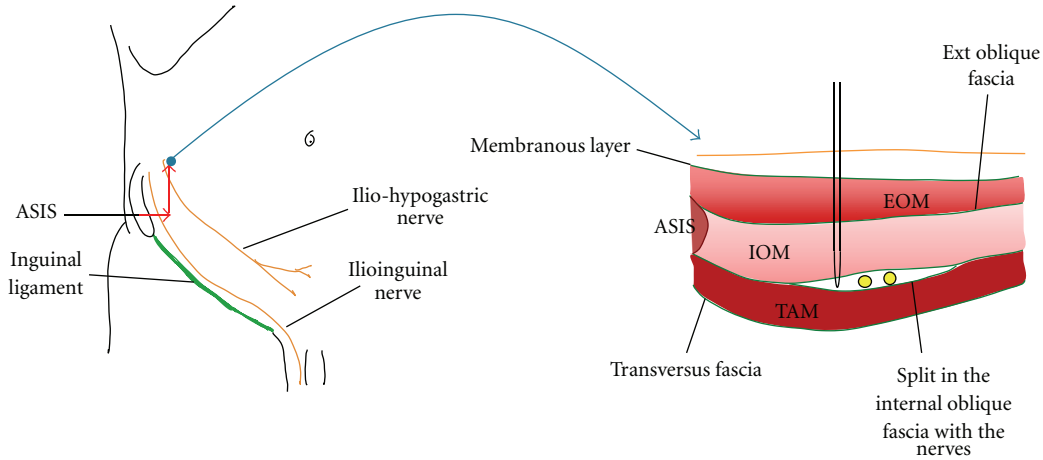

Figure 14: Ilioinguinal and iliohypogastric nerves in relation to the landmark. EOM: external oblique muscle, IOM: internal oblique muscle, and TAM: transversus abdominis muscle.

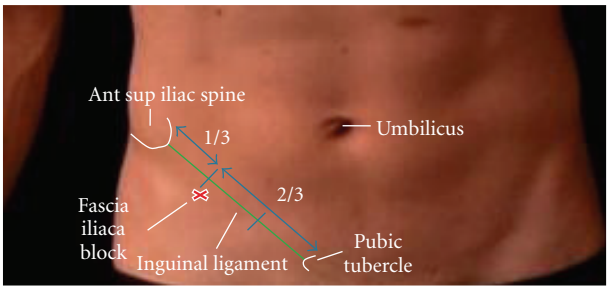

Figure 15: Landmarks for fascia iliaca compartment block.

for uncontrolled pain in renal transplant patients who were on PCA morphine. The simplicity of the LOR technique allows them to be used with minimal resources and the outcomes are excellent. The acute pain teams underutilise these blocks, as they are mostly lead by nurses who have no experience in this field but they can be easily taught to perform these blocks and the quality of pain management and patient satisfaction can be markedly improved.

6.1. TAP Block. TAP block can be used for any surgery involving the lower abdominal wall. This includes bowel surgery, caesarean section, appendicectomy, hernia repair, umbilical surgery, and gynaecological surgery [9, 11–14]. A single injection can achieve sensory block over a wide area of the abdominal wall. The block has been shown to be useful in upper abdominal surgery, but the upper extent of the block and its use in upper abdominal surgery are controversial. TAP block is particularly useful for cases when an epidural is contraindicated or refused. The block can be performed unilaterally (e.g., appendicectomy, renal transplant, and hernia repairs), or bilaterally when the incision crosses the midline (e.g., Pfannenstiel incision, and laparoscopic surgeries). A single injection can be used or a catheter inserted for several days of analgesic benefit. TAP block also has a role as rescue analgesia on awake postoperative patients who did not receive blocks prior to abdominal surgery or the analgesia technique used intraoperatively failed. TAP block can be combined with rectus sheath block above the umbilicus to complete analgesia for midline laparotomies.

The aim of TAP block is to deposit large amount of local anaesthetic in the transversus abdominis plane that lies below the internal oblique muscle and above the transversus abdominis muscle. Even though the literature describes the block to be performed in the so-called lumbar triangle "Petit's triangle", we prefer to use the midaxillary line and a point midway between the costal margin and the iliac crest (Figures 12 and 13).

Once the skin is cleaned and draped, a short bevel or blunt needle is connected to a syringe with 20 mLs of local anaesthetic. The needle is introduced in the midaxillary line, absolutely perpendicular to the skin. Once the skin barrier is breached (requires a large force), the needle is withdrawn back so that the tip lies just under the skin. The needle is then advanced through the external oblique and a first "pop" sensation is felt when the needle enters the plane between the external oblique and internal oblique. We tend to actively look for a "bounce" of the needle on the fascia before feeling the "pop". Further advancement of the needle results in a second "pop" after it passes through the internal oblique fascia into the TAP (Figures 12 and 13). At this point, after careful aspiration, 20–30 mLs of long-acting local anaesthetic (0.25% levobupivacaine, max 2 mg/kg) is injected in 5 mL aliquots. It is important that the "pops" are distinctly felt, to the extent that people watching you should be able to see the sudden movement of the needle through the plane. Sometimes it is important to change the angle of the needle slightly, in the caudad direction to feel these clicks/pops. While using bilateral blocks, it is important to keep in mind the toxic limits of the local anaesthetic as recommended by the manufactures are not exceeded.

6.2. Rectus Sheath Block. The rectus sheath block is mostly used for analgesia after umbilical or incisional hernia repairs and supraumbilical surgical incisions. It is also used to

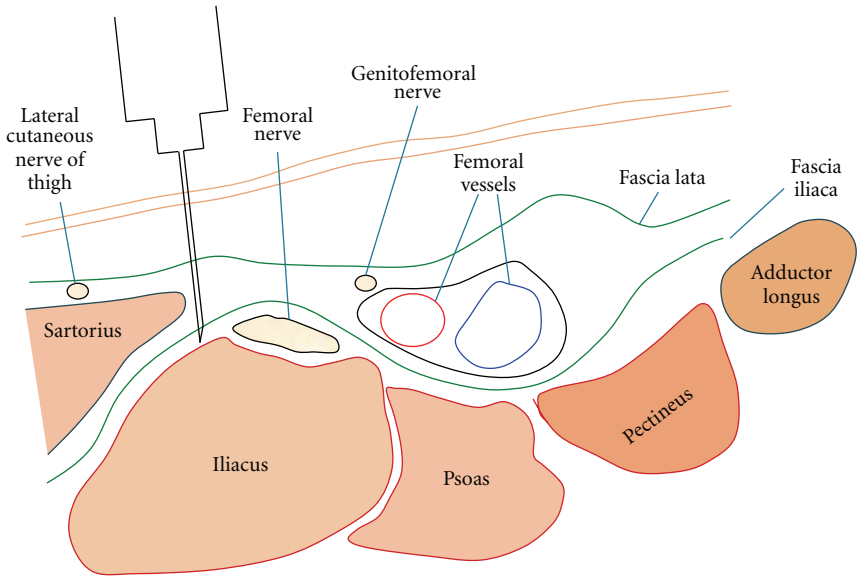

Figure 16: Anatomy of the fascia iliaca compartment block.

supplement TAP block for complete analgesia following large laparotomy incision that extents from the xiphisternum to the symphysis pubis [15–17].

The aim of this technique is to block the terminal branches of the upper intercostal nerves (often missed by TAP block) which run in between the internal oblique and transversus abdominis muscles to penetrate the posterior wall of the rectus abdominis muscle and end in an anterior cutaneous branch supplying the skin of the umbilical area. For this block, large amount of local anaesthetic is often required as it is mostly performed bilaterally. The technique is similar to the TAP block. The point of insertion is 2-3 cm lateral to linea alba, midway between the xiphisternum and the umbilicus (Figures 12 and 13). Using a short bevel or a blunt needle, once the skin barrier is breached, the needle is withdrawn and readvanced. The needle first passes through anterior rectus sheath and then through the rectus abdominis muscle till resistance is felt over the post wall of the rectus sheath, bouncing the needle on the fascia will confirm the correct location. Once the position is confirmed, injection of 15–20 mL local anaesthetic (levobupivacaine 0.25 or 0.5%, max dose of 2 mg/kg) is made in 5 mL aliquots. The procedure is repeated on the opposite side of the midline.

6.3. Ilioinguinal and Iliohypogastric Nerve Blocks. Inguinal herniorrhaphy and orchidopexy remain the most common indications for this block. Bilateral blocks have also been used for obstetrics and gynaecological procedures that utilise lower abdominal incisions (e.g., Pfannenstiel incision) [17–22]. In our practice, we also use bilateral blocks for endovascular abdominal aneurysm repairs (EVAR).

There are many approaches to this block; classical approach uses a landmark technique, which blocks the nerves once they have separated into the different fascial layers. Using a short beveled or a blunt needle, an injection is made at a point 2 cm medial and 2 cm cephalad (some go 2 cm caudad) to the anterior superior iliac spine (ASIS). Once the needle is through the skin, as the needle is advance an initial "pop" sensation is felt as it penetrates the external oblique aponeurosis, around 5–10 mL of local anaesthetic is injected. The needle is then inserted deeper until a second "pop" is felt penetrating the internal oblique, and a further 5–10 mL of local anaesthetic is injected to block the iliohypogastric nerve.

A subcutaneous injection of 3–5 mL can also be made at the point of entry, to block any remaining sensory supply from the intercostals and subcostal nerve. The approach we follow is based on a study by Eichenberger, our injection point is about 5 cm cranial and posterior to the ASIS; at this point both the iliohypogastric and the ilioinguinal nerves lie between the internal oblique and transverse abdominal muscle (Figures 13 and 14) [23]. This has been confirmed by cadaveric studies done as far back as 1952 and more recently by Rozen and colleagues in 2008 [5].

In younger paediatric patients, the landmarks are different from that used in adults. A line joining the ASIS and the umbilicus is drawn and then trisected. The point joining the lateral 1/3rd and medial 2/3rd is used for the nerve block. Even though in most paediatric patients both the nerves tend to lie below the internal oblique, in practice it is better to inject the LA under both external and internal oblique muscles. The optimal volume for the block is 0.1-0.2 mL/kg of 0.25% levobupivacaine [24, 25].

6.4. Fascia Iliaca Compartment Block. The fascia iliaca compartment block (FICB) is a simple and inexpensive method to provide perioperative analgesia in patients with painful conditions affecting the thigh, the hip joint, and/or the femur. The commonest indication for this block is analgesia for fracture neck of femurs [26, 27].

The landmarks for this block are ASIS, the pubic tubercle, and the inguinal ligament. Once the inguinal ligament is marked, it is trisected and then a point-one fingerbreadth (1 cm) below the junction of the medial 2/3rd and the lateral 1/3rd is marked (Figure 15). This is the point of the needle insertion. A short bevel/blunt needle is introduced at this point and once it has pierced the skin the tip would be lying on the fascia lata, passing through this layer providing the first "pop". Once the needle passes through the fascia lata, it is advanced further till resistance can be felt over the fascia iliaca, once the second "pop" is felt, 30–40 mLs of LA (0.25% levobupivacaine, max dose 2 mg/kg) is deposited to fill the potential space (Figure 16). The fluid travels cephalad (applying distal pressure generally helps) beneath the fascia and contacts the nerves of the lumbar plexus, which are located in the psoas compartment. The nerves that are mainly blocked are the femoral nerve and the lateral femoral cutaneous nerve but occasionally the obturator nerves may also be blocked.

7. Conclusion

Understanding the anatomy and avoiding the "cushion effect" helps to perform the TAP, Rectus sheath, ilioinguinal, and fascia iliaca blocks with greater confidence and excellent results. Simplicity of these blocks allows them to be performed in the theatres but also be used as "rescue analgesics" in situations where pain can be difficult to control in the postoperative period. Loss-of-resistance techniques are not only easy to learn (and teach) but, due to minimal resources required, they are highly cost effective.

References

[1] P. Marhofer, M. Greher, and S. Kapral, "Ultrasound guidance in regional anaesthesia," *British Journal of Anaesthesia*, vol. 94, no. 1, pp. 7–17, 2005.

[2] M. K. Peterson, F. A. Millar, and D. G. Sheppard, "Ultrasound-guided nerve blocks," *British Journal of Anaesthesia*, vol. 88, no. 5, pp. 621–624, 2002.

[3] R. G. Craig and S. K. Singh, "A new technique for ilio-inguinal and iliohypogastric nerve block," *Anaesthesia*, vol. 62, no. 1, pp. 96–97, 2007.

[4] J. A. Gosling, P. F. Harris, I. Whitmore, and P. L.T. Willan, "Anterior abdominal wall," in *Human Anatomy: Color Atlas and Text*, pp. 127–135, Elsevier Science, 4th edition, 2002.

[5] W. M. Rozen, T. M. N. Tran, M. W. Ashton, M. J. Barrington, J. J. Ivanusic, and G. I. Taylor, "Refining the course of the thoracolumbar nerves: a new understanding of the innervation of the anterior abdominal wall," *Clinical Anatomy*, vol. 21, no. 4, pp. 325–333, 2008.

[6] G. J. Romanes, "The abdomen," in *Cunningham's Manual of Practical Anatomy*, pp. 93–184, Oxford University Press, 15th edition, 1994.

[7] J. A. Gosling, P. F. Harris, I. Whitmore, and P. L. T. Willan, "Anterior compartment of thigh," in *Human Anatomy: Color Atlas and Text*, p. 234, Elsevier Science, 4th edition, 2002.

[8] O. Finnerty, J. Carney, and J. G. McDonnell, "Trunk blocks for abdominal surgery," *Anaesthesia*, vol. 65, pp. 76–83, 2010.

[9] J. G. McDonnell, B. O'Donnell, G. Curley, A. Heffernan, C. Power, and J. G. Laffey, "The analgesic efficacy of transversus abdominis plane block after abdominal surgery: a prospective randomized controlled trial," *Anesthesia and Analgesia*, vol. 104, no. 1, pp. 193–197, 2007.

[10] M. Singh, K. J. Chin, and V. Chan, "Ultrasound-guided transversus abdominis plane (TAP) block: a useful adjunct in the management of postoperative respiratory failure," *Journal of Clinical Anesthesia*, vol. 23, no. 4, pp. 303–306, 2011.

[11] F. Bonnet, J. Berger, and C. Aveline, "Transversus abdominis plane block: what is its role in postoperative analgesia?" *British Journal of Anaesthesia*, vol. 103, no. 4, pp. 468–470, 2009.

[12] P. L. Petersen, O. Mathiesen, H. Torup, and J. B. Dahl, "The transversus abdominis plane block: a valuable option for postoperative analgesia? A topical review," *Acta Anaesthesiologica Scandinavica*, vol. 54, no. 5, pp. 529–535, 2010.

[13] J. Carney, J. G. McDonnell, A. Ochana, R. Bhinder, and J. G. Laffey, "The transversus abdominis plane block provides effective postoperative analgesia in patients undergoing total abdominal hysterectomy," *Anesthesia and Analgesia*, vol. 107, no. 6, pp. 2056–2060, 2008.

[14] J. G. McDonnell, G. Curley, J. Carney et al., "The analgesic efficacy of transversus abdominis plane block after cesarean delivery: a randomized controlled trial," *Anesthesia and Analgesia*, vol. 106, no. 1, pp. 186–191, 2008.

[15] B. E. Smith, M. Suchak, D. Siggins, and J. Challands, "Rectus sheath block for diagnostic laparoscopy," *Anaesthesia*, vol. 43, no. 11, pp. 947–948, 1988.

[16] J. Muir and S. Ferguson, "The rectus sheath block—well worth remembering," *Anaesthesia*, vol. 51, no. 9, pp. 893–894, 1996.

[17] S. M. Yentis, P. Hills-Wright, and O. Potparic, "Development and evaluation of combined rectus sheath and ilioinguinal blocks for abdominal gynaecological surgery," *Anaesthesia*, vol. 54, no. 5, pp. 475–479, 1999.

[18] R. S. Hannallah, L. M. Broadman, and A. B. Belman, "Comparison of caudal and ilioinguinal/iliohypogastric nerve blocks for control of post-orchiopexy pain in pediatric ambulatory surgery," *Anesthesiology*, vol. 66, no. 6, pp. 832–834, 1987.

[19] A. Yilmazlar, H. Bilgel, C. Donmez, A. Guney, T. Yilmazlar, and O. Tokat, "Comparison of ilioinguinal-iliohypogastric nerve block versus spinal anesthesia for inguinal herniorrhaphy," *Southern Medical Journal*, vol. 99, no. 1, pp. 48–51, 2006.

[20] D. Nehra, L. Gemmell, and J. K. Pye, "Pain relief after inguinal hernia repair: a randomized double-blind study," *British Journal of Surgery*, vol. 82, no. 9, pp. 1245–1247, 1995.

[21] E. A. Bell, B. P. Jones, A. J. Olufolabi et al., "Iliohypogastric-ilioinguinal peripheral nerve block for post-Cesarean delivery analgesia decreases morphine use but not opioid-related side effects," *Canadian Journal of Anesthesia*, vol. 49, no. 7, pp. 694–700, 2002.

[22] M. C. Kelly, H. T. Beers, B. K. Huss, and H. M. E. Gilliland, "Bilateral ilioinguinal nerve blocks for analgesia after total abdominal hysterectomy," *Anaesthesia*, vol. 51, no. 4, p. 406, 1996.

[23] U. Eichenberger, M. Greher, L. Kirchmair, M. Curatolo, and B. Moriggl, "Ultrasound-guided blocks of the ilioinguinal and iliohypogastric nerve: accuracy of a selective new technique confirmed by anatomical dissection," *British Journal of Anaesthesia*, vol. 97, no. 2, pp. 238–243, 2006.

[24] H. Willschke, P. Marhofer, A. Bösenberg et al., "Ultrasonography for ilioinguinal/iliohypogastric nerve blocks in children," *British Journal of Anaesthesia*, vol. 95, no. 2, pp. 226–230, 2005.

[25] H. Willschke, A. Bösenberg, P. Marhofer et al., "Ultrasonographic-guided ilioinguinal/iliohypogastric nerve block in rediatric anesthesia: what is the optimal volume?" *Anesthesia and Analgesia*, vol. 102, no. 6, pp. 1680–1684, 2006.

[26] N. B. Foss, B. B. Kristensen, M. Bundgaard et al., "Fascia iliaca compartment blockade for acute pain control in hip fracture patients: a randomized, placebo-controlled trial," *Anesthesiology*, vol. 106, no. 4, pp. 773–778, 2007.

[27] D. G. Monzon, K. V. Iserson, and J. A. Vazquez, "Single fascia iliaca block for post-hip fracture pain relief," *Journal of Emergency Medicine*, vol. 32, no. 3, pp. 257–262, 2007.