International Scholarly Research Network
ISRN Pulmonology
Volume 2012, Article ID 840489, 7 pages
doi:10.5402/2012/840489

Research Article

Matrix Metalloproteinases-9 (MMPs-9) and -12 Are Upregulated in the Airways of Mice with Chronic Airway Inflammation and Remodeling

Yingyan Yu,[1] Hiroyasu Sakai,[1] Miwa Misawa,[1] and Yoshihiko Chiba[1, 2]

[1] *Department of Pharmacology, School of Pharmacy, Hoshi University, 2-4-41 Ebara, Shinagawa-ku, Tokyo 142-8501, Japan*
[2] *Department of Biology, School of Pharmacy, Hoshi University, 2-4-41 Ebara, Shinagawa-ku, Tokyo 142-8501, Japan*

Correspondence should be addressed to Yoshihiko Chiba, chiba@hoshi.ac.jp

Received 3 September 2011; Accepted 8 October 2011

Academic Editors: P. Bartsch and M. Tatar

In the present study, we tried to develop a mouse model of chronic airway inflammation and remodeling induced by chronic exposure to antigen. Furthermore, the expressions of MMPs-9 and -12 were also investigated. BALB/c mice were sensitized and then repeatedly challenged with OVA every 3 days for 54 days. At the following day after the last challenge, of days 24, 39, and 54, histological changes of the airways were studied by hematoxylin-eosin and Masson's trichrome stains. The expressions of MMPs-9 and -12 were also measured by western blot. Persistent inflammatory cells infiltration and collagen deposition in the lung tissue were observed in repeatedly challenged mice. Furthermore, the expressions of MMPs-9 and -12 were increased in the airways after repeated antigen challenges. The severest inflammation was observed in the day-54 challenged group. These results suggest that MMPs-9 and -12 might be involved in the pathogenesis of chronic airway inflammation and remodeling induced by antigen exposure in mice.

1. Introduction

Airway inflammation and remodeling are important features of chronic allergic airway diseases such as asthma [1]. Severe inflammatory cell infiltration into the lung tissue, airway structure changes including epithelium desquamation and abnormal, extracellular matrix (ECM) degradation are observed in the patients with chronic allergic airway diseases [2, 3]. These structure changes of the airways are thought to be the result from chronic repetitive injury to the airway wall caused by airway inflammation; however, the relationship between airway remodeling and inflammation is poorly understood.

Matrix metalloproteinases (MMPs) are a family of proteinases with zinc-dependent proteolysis, which play important roles in matrix turnover [3]. MMPs, most of which are expressed in the airways, cleave a number of ECM constituents and can be broadly divided into collagenases, gelatinases, stromelysins, elastinases, and membrane-bound forms [4–6].

In particular, MMP-9 (gelatinase B) and MMP-12 (macrophage elastase), both of which are reportedly increased in the airways of asthmatic patients [7, 8], are thought to be associated with the pathogenesis of airway inflammatory diseases [9, 10]. The expressions and involvements of MMPs-9 and -12 in the pathogenesis of allergic airway disease were tried to be studied in some animal models with acute allergic airway disease [11–15]. However, the detailed involvements of MMPs-9 and -12 in the process of chronic allergic airway inflammation and airway remodeling are still to be revealed. Therefore, a chronic airway inflammation and remodeling model, which approximates the chronic nature of allergic airway diseases, is necessary to study the detailed functional importance of MMPs-9 and -12 in the pathogenesis of chronic allergic airway diseases.

In the present study, a mouse model of chronic airway inflammation and remodeling was developed by repeated antigen exposure. By using this animal model of chronic airway inflammation and remodeling, the changes in the expressions of MMPs-9 and -12 were also investigated.

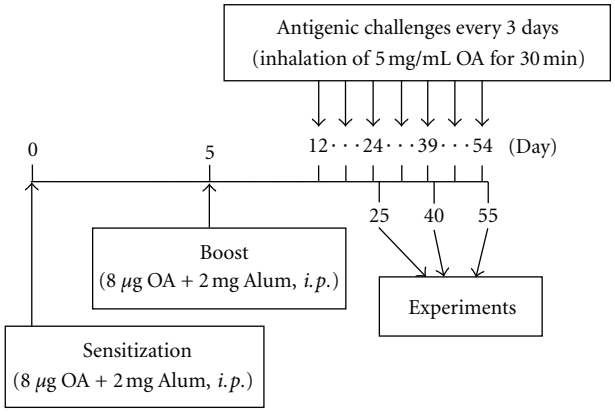

Figure 1: Schematic representation of the sensitization and challenge protocol. BALB/c mice (7-week old) were sensitized at days 0 and 5 and received repeated aerosol ovalbumin (OVA) challenge every 3 days from day 12 to day 54.

2. Methods

2.1. Animals and Antigen Challenge. Male BALB/c mice (7-week old, specific-pathogen-free) were used. All experiments were approved by the Animal Care Committee at the Hoshi University (Tokyo, Japan). Mice were sensitized by intraperitoneal injection of 8 μg ovalbumin (OVA) (Sigma-Aldrich, St. Louis, MO, USA) with 2 mg aluminum hydroxide (Pierce Biotechnology, Inc., Rockfold, IL, USA) on days 0 and 5. The sensitized mice were challenged with aerosolized OA-saline solution (5 mg/mL in saline) for 30 min every 3 days from day 12 to day 54 (Figure 1). A control group of mice received the same immunization schedule but were exposed to saline aerosol instead of OA challenge.

2.2. Bronchoalveolar Lavage (BAL). Twenty-four hr after the last antigen challenge, mice were anesthetized with urethane (1.6 g/kg, i.p.). One mL of phosphate-buffered saline (PBS) was instilled into the lungs and lavaged 3 times. The BAL fluid (BALF) was collected and then centrifuged (1,000 g, 10 min at room temperature). Then the supernatants were collected and stored at -80°C for the following experiments.

2.3. Histological Studies. Lungs were fixed in 10% formaldehyde and embedded in Paraplast X-TRATM paraffin (Fisher Healthcare, Houston, TX). Four μm sections were obtained from blocks and mounted on silane-coated glass slides. After deparaffinized with xylene and graded ethanol, the sections were stained with hematoxylin-eosin (HE) or Masson's trichrome (MT) stains by a standard technique as previously reported [16]. The extents of inflammatory infiltration in peripheral bronchial and subepithelium were evaluated by inflammation scores as previously reported [17]. For each lung specimen, the extent of inflammatory infiltration was graded on a scale of 0–3 by two blinded observers. A value of 0 was adjudged when no inflammation was detectable, a value of 1 for occasional cuffing with inflammatory cells, a value of 2 for most bronchi or vessels surrounded by thin layer (one to five cells) of inflammatory cells and a value of 3 when most bronchi or vessels were surrounded by a thick layer (more than five cells) of inflammatory cells. As 10–15 tissue sections per mouse were scored, inflammation scores could be expressed as a mean value and could be compared between groups.

2.4. Western Blot. Twenty-five μL of BALF obtained from antigen-challenged or sensitized animals was mixed with 3 $\times$ SDS sample buffer and heated at 100°C for 4 min. The mixtures were subjected to 10% SDS-PAGE. Proteins were then electrophoretically transferred for 2 hr onto polyvinylidene difluoride (PVDF) membranes (Hybond-P, Amersham, UK) in transfer buffer (20% methanol containing 25 mM Tris and 192 mM glycine). After repeatedly washing with Tris buffer (20 mM Tris, 500 mM NaCl, pH7.5) containing 0.1% Tween-20 (TTBS), the membranes were incubated with blocking buffer (5% skim milk in TTBS) for 3 hr at room temperature. Then the membranes were incubated with primary rabbit anti-MMP-12 antibody (1 : 1,000 dilution; C-terminal, Sigma-Aldrich, St. Louis, MO, USA) or mouse anti-MMP-9 (1 : 1,000 dilution; AnaSpec, San Jose, CA, USA) in antibody buffer (2% bovine serum albumin in TTBS) for 12 hr at room temperature. After washing with TTBS for 10 min 6 times, the membranes were then incubated with horseradish-peroxidase-(HRP-) conjugated goat anti-rabbit IgG (1 : 5,000 dilution; Amersham, UK) or goat anti-mouse IgG (1 : 5,000 dilution; Amersham, UK) for 1.5 hr at room temperature and were washed with TTBS for 10 min 6 times. The blots were detected with an enhanced chemiluminescent method (ECL System; Amersham, UK) and quantitated by densitometry system (Atto Densitograph; Atto Co., Tokyo, Japan).

3. Results

3.1. Inflammatory Cells Infiltration in Lung Tissue after Repeated Antigen Challenges. Inflammatory cells infiltration into the lung tissue was investigated with HE staining. Inflammatory cells infiltration in the peripheral bronchial and subepithelium was observed from day 24 (Figure 2(b)) and most seriously at day 54 (Figure 2(f)) when mice were repeatedly challenged with OVA. The inflammation score in peripheral bronchial and subepithelium was increased from day 24 and significantly increased at day 54 in challenged groups (Figure 2(g)).

3.2. Collagen Deposition in the Lung Tissue after Repeated Antigen Challenges. The distribution of collagen fiber in lung tissue was studied with Masson's trichrome staining. Collagen fibers were found in the endothelium of vessel, the subepithelium and smooth muscle layer in the lung tissues of sensitized and challenged mice (Figures 3(a) and 3(b)). Obviously, increased deposition of collagen in the airway subepithelium and smooth muscle layer was found in repeatedly challenged mice at day 54 (Figure 3(f)), whereas this was not observed in sensitized mice (Figure 3(e)).

3.3. Upregulations of MMPs-9 and -12 after Repeated Antigen Challenges. The bands corresponding to the proenzyme of

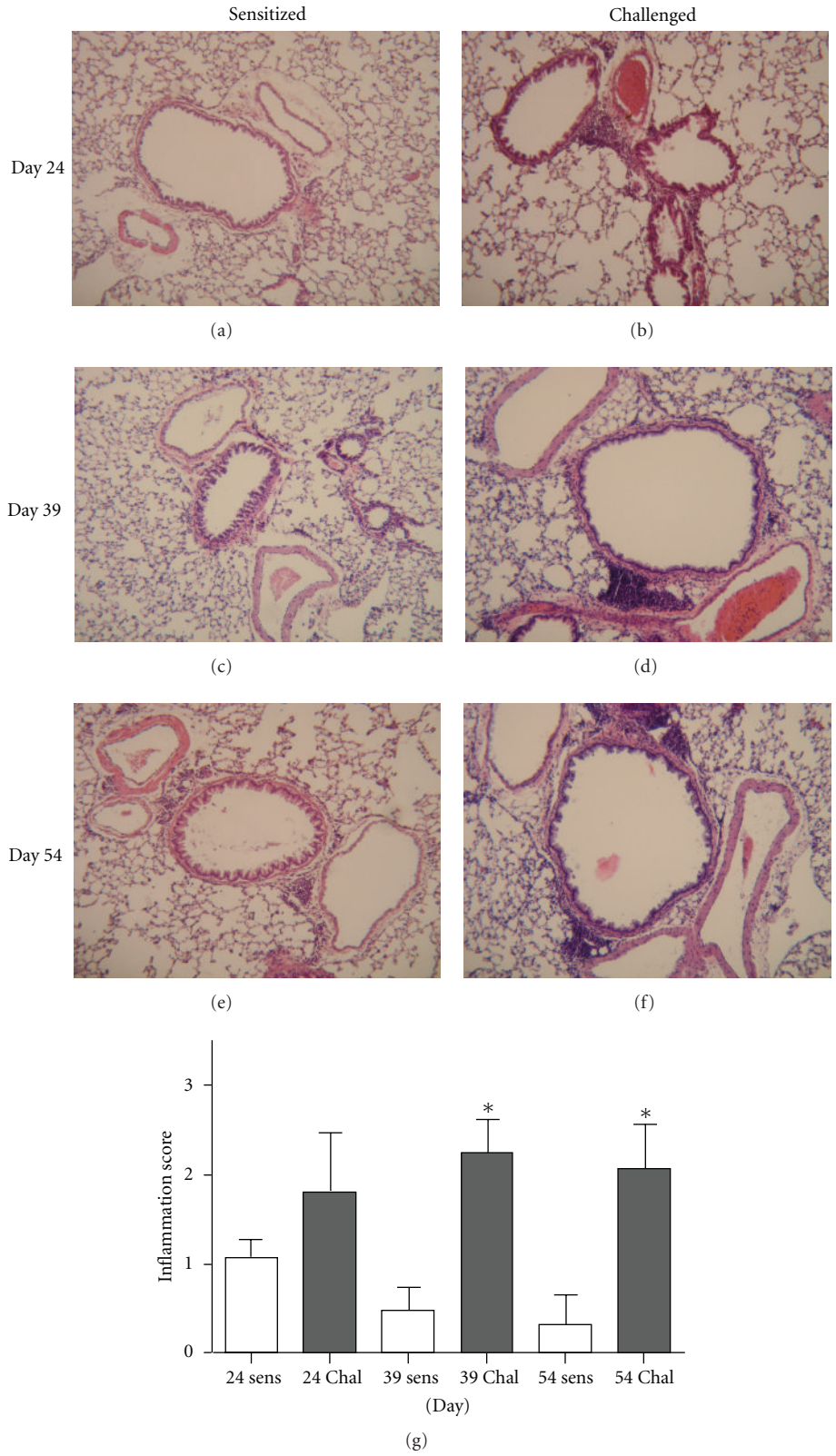

Figure 2: Inflammatory cells infiltration into the lungs of the repeatedly antigen challenged mice. Lung tissue sections from mice at days 24 ((a) and (b)), 39 ((c) and (d)), and 54 ((e) and (f)) were studied by HE stain (×40). Inflammatory cells infiltration in the peripheral bronchial and subepithelium was observed from day 24 (b) and most seriously at day 54 (f) when mice were repeatedly challenged with OVA. The inflammation scores in peripheral bronchial and subepithelium were graded as mentioned in Section 2. The inflammation scores were significantly increased at day 39 and 54 in challenged mice when compared with sensitized mice (g). Each column represents the mean with SEM from 3 independent experiments. $^{*}P < 0.05$ versus sensitized by Bonferroni/Dunn.

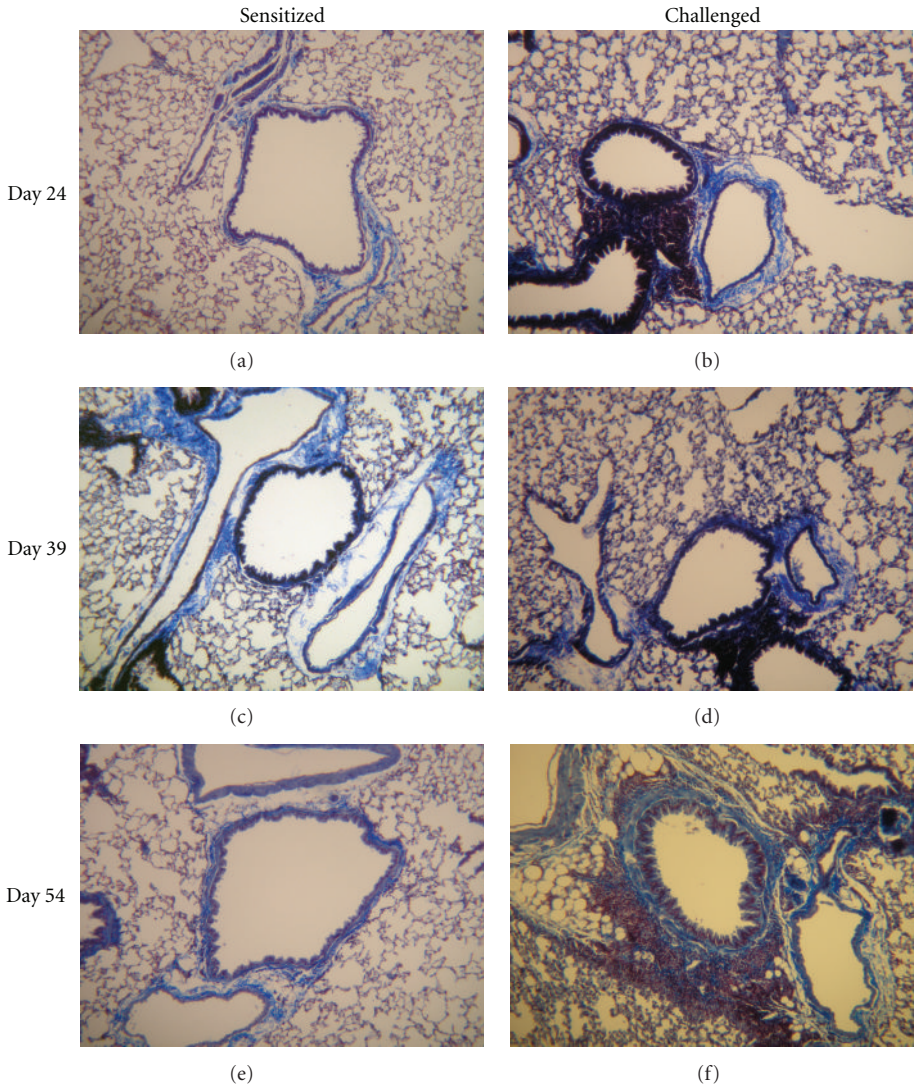

Figure 3: Distribution of collagen fiber in lungs of the repeatedly antigen challenged mice. Lung tissue sections from mice at days 24 ((a) and (b)), 39 ((c) and (d)), and 54 ((e) and (f)) were studied by Masson's trichrome staining (×40). Collagen fibers were found in the endothelium of vessel, the airway subepithelium and smooth muscle layer both in sensitized and challenged mice ((a) and (b)). Increased deposition of collagen in the airway subepithelium and smooth muscle layer was found in repeatedly challenged mice at day 54 (f), which was not observed in the airways of sensitized mice (e).

MMP-9 (98 kD) (Figure 4(a)), the proenzyme (54 kD) and intermediate form (45 kD) of MMP-12 (Figure 4(b)) were detected in BALFs by western blot. The expressions of MMPs-9 and -12 were persistently increased after repeated antigen challenges from day 24 to day 54 and significantly increased at day 54.

4. Discussion

Allergic airway diseases are characterized by chronic airway inflammation and remodeling. A number of animal models that imitate much of the pathophysiology have been developed [18–20], in which the animals are exposed to antigen multiple times for several weeks to attempt to approximate the chronic nature of allergic airway diseases with inflammation and remodeling. Therefore, we designed a mouse chronic OVA exposure model in the current study.

In the current mouse model, inflammation in lung tissue was observed at day 24 after antigen exposure till day 54 (Figures 2(b), 2(d), and 2(f)). On the other hand, the deposition of collagen was also found from day 24 to day 54 in challenged animals (Figures 3(b), 3(d), and 3(f)). Interestingly, most serious inflammation and remodeling in the lung tissue were both found in day 54, which suggested that the airway inflammation and remodeling were developed and assessed together. Indeed, it was previously reported that the airway inflammation and remodeling were developed and processed together in a mouse model to chronic antigen exposure [21]. On the other hand, it has been also reported that the process of inflammation was not

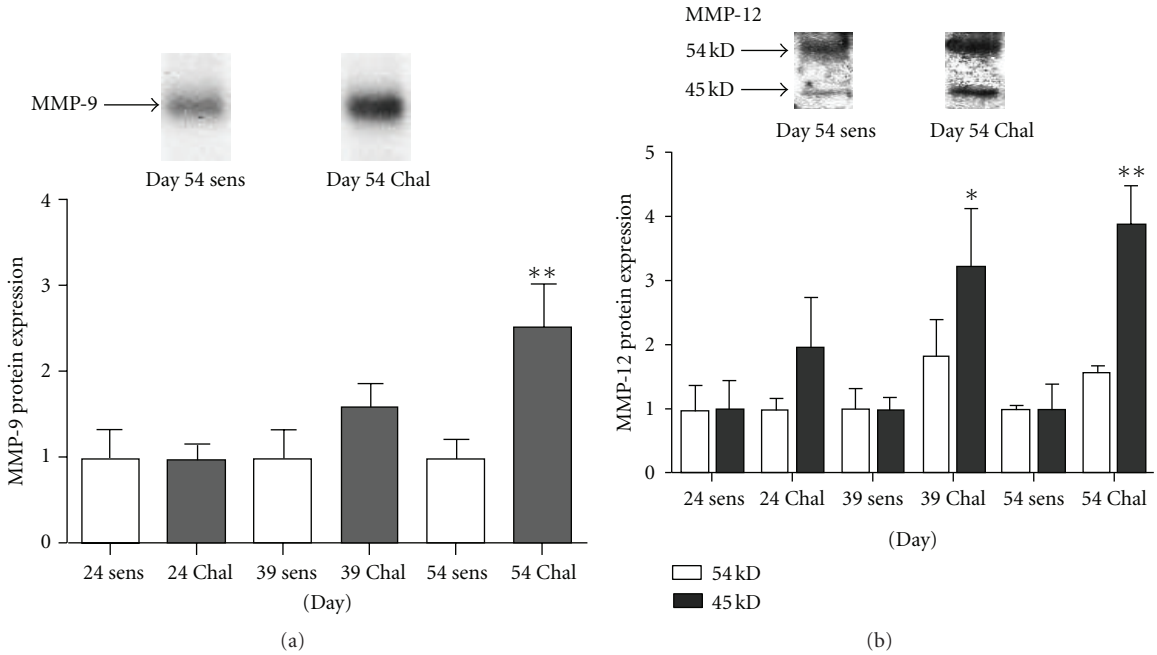

Figure 4: Upregulations of MMPs-9 and -12 in BALFs of the repeatedly antigen challenged mice. The bands corresponding to the proenzyme of MMP-9 (98 kD) (a), the proenzyme (54 kD) and intermediate form (45 kD) of MMP-12 (b) were detected by western blot. The expressions of MMPs-9 and -12 were persistently increased after repeated antigen challenges from day 24 to day 54, and significantly upregulated at day 54. Each column represents the mean with SEM from 3 to 4 independent experiments. $^{*}P < 0.05$, $^{**}P < 0.01$ versus sensitized by Bonferroni/Dunn.

changed parallelly to the structure change in the airways of mice repeatedly exposed to antigen [22]. It might be due to the different schedules of antigen exposure. In the present study, airway inflammation and collagen deposition were developed parallelly, which indicated that the airway remodeling results from the infiltration of inflammatory cells into the lung tissue in the mouse model currently used.

MMPs-9 and -12, which degrade ECM components such as collagen, are thought to be deeply involved in the pathogenesis of chronic airway diseases [6]. Upregulations of MMPs-9 and -12 have been previously reported in the airways with chronic inflammation and remodeling such as chronic obstructive pulmonary disease (COPD) including emphysema, pulmonary fibrosis [23–26]. Immunohistochemical examinations have demonstrated that MMPs-9 and -12 are expressed mainly in airway epithelia and alveolar macrophages in the murine model of allergic bronchial asthma [13, 19]. In the present study, expressions of MMPs-9 and -12 were found to be increased parallelly to the airway inflammation and remodeling induced by chronic antigen exposure, and both significantly increased at day 54 (Figure 4), when the most serious airway inflammation and remodeling were observed.

Upregulated expressions of MMPs are thought to mainly contribute to the abnormal degradation of ECM in the airways, which leads to the physiological structural changes of the airways and is also thought to be one of the main reasons of airway hyperresponsiveness [27]. It has been previously reported that the expressions of MMP-9 increased persistently in the bronchial epithelium where airway remodeling occurred in a mouse model [28]. Depletion of MMP-9 also attenuated the peribronchial fibrosis and airway hyperresponsiveness induced by chronic antigen exposure [29]. Currently, expressions of MMPs-9 and -12 were increased parallelly to the deposition of collagen in the subepithelium after antigen exposure. These findings suggested that MMPs-9 and -12 are involved in the process of airway remodeling in the pathogenesis of allergic airway disease.

Besides ECM, MMPs are known for their proteolysis on nonmatrix such as cell surface receptors [30]. Previously, MMPs such as MMPs-9 and -12 have been reported to be involved in inflammatory cells migration through the matrix membranes in vitro [31–33]. Furthermore, instillation of MMP-12 induced the inflammatory cells recruitment into lung tissue in mice [34]. These results indicated that MMPs-9 and 12 are important for the infiltration of inflammatory cells in the pathogenesis of allergic airway diseases. Currently, the parallel changes of the expressions of MMPs-9 and -12 and the inflammation scores indicated that MMPs-9 and -12 are cooperative in the pathogenesis of airway inflammation induced by chronic antigen exposure. Further studies, such as using inhibitors specific to respective MMPs, are needed to make clear the exact roles of MMPs-9 and -12 on the pathogenesis of allergic airway inflammation.

In summary, our results suggested that the processes of airway inflammation and remodeling are coordinated, and MMPs-9 and -12 are cooperative in these pathophysiological changes of chronic allergic airway diseases. These findings

might provide a better understanding of the regulation of airway inflammation and remodeling in allergic airway disease.

References

[1] S. M. Warner and D. A. Knight, "Airway modeling and remodeling in the pathogenesis of asthma," *Current Opinion in Allergy and Clinical Immunology*, vol. 8, no. 1, pp. 44–48, 2008.

[2] D. Broide, "New perspectives on mechanisms underlying chronic allergic inflammation and asthma in 2007," *Journal of Allergy and Clinical Immunology*, vol. 122, no. 3, pp. 475–480, 2008.

[3] P. K. Jeffery, A. Laitinen, and P. Venge, "Biopsy markers of airway inflammation and remodelling," *Respiratory Medicine*, vol. 94, pp. S9–S15, 2000.

[4] H. Nagaset and J. F. Woessner, "Matrix metalloproteinases," *Journal of Biological Chemistry*, vol. 274, no. 31, pp. 21491–21494, 1999.

[5] K. J. Greenlee, Z. Werb, and F. Kheradmand, "Matrix metalloproteinases in lung: multiple, multifarious, and multifaceted," *Physiological Reviews*, vol. 87, no. 1, pp. 69–98, 2007.

[6] V. Lagente, B. Manoury, S. Nénan, C. Le Quément, C. Martin-Chouly, and E. Boichot, "Role of matrix metalloproteinases in the development of airway inflammation and remodeling," *Brazilian Journal of Medical and Biological Research*, vol. 38, no. 10, pp. 1521–1530, 2005.

[7] F. W. S. Ko, C. Diba, M. Roth et al., "A comparison of airway and serum matrix metalloproteinase-9 activity among normal subjects, asthmatic patients, and patients with asthmatic mucus hypersecretion," *Chest*, vol. 127, no. 6, pp. 1919–1927, 2005.

[8] S. Xie, R. Issa, M. B. Sukkar et al., "Induction and regulation of matrix metalloproteinase-12 in human airway smooth muscle cells," *Respiratory Research*, vol. 6, article 148, 2005.

[9] H. Ohbayashi and K. Shimokata, "Matrix metalloproteinase-9 and airway remodeling in asthma," *Current Drug Targets*, vol. 4, no. 2, pp. 177–181, 2005.

[10] V. Lagente, C. Le Quement, and E. Boichot, "Macrophage metalloelastase (MMP-12) as a target for inflammatory respiratory diseases," *Expert Opinion on Therapeutic Targets*, vol. 13, no. 3, pp. 287–295, 2009.

[11] D. D. Cataldo, K. G. Tournoy, K. Vermaelen et al., "Matrix metalloproteinase-9 deficiency impairs cellular infiltration and bronchial hyperresponsiveness during allergen-induced airway inflammation," *American Journal of Pathology*, vol. 161, no. 2, pp. 491–498, 2002.

[12] S. J. McMillan, J. Kearley, J. D. Campbell et al., "Matrix metalloproteinase-9 deficiency results in enhanced allergen-induced airway inflammation," *Journal of Immunology*, vol. 172, no. 4, pp. 2586–2594, 2004.

[13] Y. Chiba, Y. Yu, H. Sakai, and M. Misawa, "Increase in the expression of matrix metalloproteinase-12 in the airways of rats with allergic bronchial asthma," *Biological and Pharmaceutical Bulletin*, vol. 30, no. 2, pp. 318–323, 2007.

[14] R. L. Warner, N. W. Lukacs, S. D. Shapiro et al., "Role of metalloelastase in a model of allergic lung responses induced by cockroach allergen," *American Journal of Pathology*, vol. 165, no. 6, pp. 1921–1930, 2004.

[15] Y. Yu, Y. Chiba, H. Sakai, and M. Misawa, "Effect of a matrix metalloproteinase-12 inhibitor, S-1, on allergic airway disease phenotypes in mice," *Inflammation Research*, vol. 59, no. 6, pp. 419–428, 2010.

[16] E. López, V. Del Pozo, T. Miguel et al., "Inhibition of chronic airway inflammation and remodeling by Galectin-3 gene therapy in a murine model," *Journal of Immunology*, vol. 176, no. 3, pp. 1943–1950, 2006.

[17] K. S. Lee, K. H. Min, S. R. Kim et al., "Vascular endothelial growth factor modulates matrix metalloproteinase-9 expression in asthma," *American Journal of Respiratory and Critical Care Medicine*, vol. 174, no. 2, pp. 161–170, 2006.

[18] D. G. Xisto, L. L. Farias, H. C. Ferreira et al., "Lung parenchyma remodeling in a murine model of chronic allergic inflammation," *American Journal of Respiratory and Critical Care Medicine*, vol. 171, no. 8, pp. 829–837, 2005.

[19] N. R. Locke, S. G. Royce, J. S. Wainewright, C. S. Samuel, and M. L. Tang, "Comparison of airway remodeling in acute, subacute, and chronic models of allergic airways disease," *American Journal of Respiratory Cell and Molecular Biology*, vol. 36, no. 5, pp. 625–632, 2007.

[20] J. H. Ahn, C. H. Kim, Y. H. Kim et al., "Inflammatory and remodeling events in asthma with chronic exposure to house dust mites: a murine model," *Journal of Korean Medical Science*, vol. 22, no. 6, pp. 1026–1033, 2007.

[21] R. Fraga-Iriso, L. Núñez-Naveira, N. S. Brienza et al., "Development of a murine model of airway inflammation and remodeling in experimental asthma," *Archivos de Bronconeumologia*, vol. 45, no. 9, pp. 422–428, 2009.

[22] T. Tsuchiya, Y. Nishimura, T. Nishiuma et al., "Airway remodeling of murine chronic antigen exposure model," *Journal of Asthma*, vol. 40, no. 8, pp. 935–944, 2003.

[23] T. Hayashi, W. G. Stetler-Stevenson, M. V. Fleming et al., "Immunohistochemical study of metalloproteinases and their tissue inhibitors in the lungs of patients with diffuse alveolar damage and idiopathic pulmonary fibrosis," *American Journal of Pathology*, vol. 149, no. 4, pp. 1241–1256, 1996.

[24] D. Cataldo, C. Munaut, A. Noël et al., "MMP-2- and MMP-9-linked gelatinolytic activity in the sputum from patients with asthma and chronic obstructive pulmonary disease," *International Archives of Allergy and Immunology*, vol. 123, no. 3, pp. 259–267, 2000.

[25] R. D. Hautamaki, D. K. Kobayashi, R. M. Senior, and S. D. Shapiro, "Requirement for macrophage elastase for cigarette smoke-induced emphysema in mice," *Science*, vol. 277, no. 5334, pp. 2002–2004, 1997.

[26] S. Molet, C. Belleguic, H. Lena et al., "Increase in macrophage elastase (MMP-12) in lungs from patients with chronic obstructive pulmonary disease," *Inflammation Research*, vol. 54, no. 1, pp. 31–36, 2005.

[27] D. W. Cockcroft and B. E. Davis, "Mechanisms of airway hyperresponsiveness," *Journal of Allergy and Clinical Immunology*, vol. 118, no. 3, pp. 551–559, 2006.

[28] N. R. Locke, S. G. Royce, J. S. Wainewright, C. S. Samuel, and M. L. Tang, "Comparison of airway remodeling in acute, subacute, and chronic models of allergic airways disease," *American Journal of Respiratory Cell and Molecular Biology*, vol. 36, no. 5, pp. 625–632, 2007.

[29] D. H. Lim, Y. C. Jae, M. Miller, K. McElwain, S. McElwain, and D. H. Broide, "Reduced peribronchial fibrosis in allergen-challenged MMP-9-deficient mice," *American Journal of Physiology*, vol. 291, no. 2, pp. L265–L271, 2006.

[30] L. J. McCawley and L. M. Matrisian, "Matrix metalloproteinases: they're not just for matrix anymore!," *Current Opinion in Cell Biology*, vol. 13, no. 5, pp. 534–540, 2001.

[31] M. Xia, D. Leppert, S. L. Hauser et al., "Stimulus specificity of matrix metalloproteinase dependence of human T cell

migration through a model basement membrane," *Journal of Immunology*, vol. 156, no. 1, pp. 160–167, 1996.

[32] S. Okada, H. Kita, T. J. George, G. J. Gleich, and K. M. Leiferman, "Migration of eosinophils through basement membrane components in vitro: role of matrix metalloproteinase-9," *American Journal of Respiratory Cell and Molecular Biology*, vol. 17, no. 4, pp. 519–528, 1997.

[33] M. Vaalamo, A. L. Kariniemi, S. D. Shapiro, and U. Saarialho-Kere, "Enhanced expression of human metalloelastase (MMP-12) in cutaneous granulomas and macrophage migration," *Journal of Investigative Dermatology*, vol. 112, no. 4, pp. 499–505, 1999.

[34] S. Nénan, J. M. Planquois, P. Berna et al., "Analysis of the inflammatory response induced by rhMMP-12 catalytic domain instilled in mouse airways," *International Immunopharmacology*, vol. 5, no. 3, pp. 511–524, 2005.