International Scholarly Research Network
ISRN Vascular Medicine
Volume 2012, Article ID 984178, 7 pages
doi:10.5402/2012/984178

Clinical Study

Periprocedural Thromboembolic Events Associated with Angioplasty and Stenting of the Extra- and Intracranial Carotid Artery Assessed by Neurological Status and Diffusion-Weighted Magnetic Resonance Imaging (DWI)

Frank Ahlhelm,[1,2] Johanna Lieb,[2] Stefan Ulmer,[2] Dirk Ahlhelm,[1] and Wolfgang Reith[1]

[1] *Clinic for Diagnostic and Interventional Neuroradiology Saarland, University Hospital, 66421 Homburg, Germany*
[2] *Department of Diagnostic and Interventional Neuroradiology, University Hospital Basel, 4031 Basle, Switzerland*

Correspondence should be addressed to Frank Ahlhelm, ahlhelmf@uhbs.ch

Received 27 July 2012; Accepted 24 August 2012

Academic Editors: F. C. Barone, A. Shaish, and A. Suzuki

Objective. The purpose of this study was to determine the frequency of thromboembolic events associated with angioplasty and stenting of the carotid artery with special regard to extra- or intracranial localization of stenosis. *Methods*. Twenty patients with symptomatic intracranial or extracranial internal carotid artery stenosis were treated with stenting and/or angioplasty. In 4 patients stenting was technically not feasible (all in the group with intracranial stenosis). All patients underwent diffusion-weighted imaging (DWI) and neurological examination within 48 hours before and after the procedure to detect periprocedural thrombembolic events. *Results*. Extracranial carotid angioplasty and stenting (eCAS) was technically feasible and successfull without procedure-related neurological complications in all cases. Intracranial stenting (iCAS) was not feasible in four cases including one patient with a fateful course. Concerning the restoration of the vessel diameter intracranial stenting was not as successful as eCAS, but more effective than balloon angioplasty alone. Incidence of thrombembolic events assessed by DWI was low. The detected periprocedural thrombembolic events were small and clinically silent. *Conclusion*. The risk of thromboembolic events during the endovascular treatment of symptomatic carotid artery stenosis was rather low for intra- and extracranial stenosis of the ICA in our patient sample, but one fatal course was observed.

1. Introduction

Intra- and extracranial high grade stenosis of carotid artery are major causes of recurrent ischemic stroke in patients with recent transient ischemic attacks or recent cerebral infarction. In case of symptomatic extracranial carotid artery stenosis, angioplasty and stenting of the carotid artery (eCAS) has shown its efficiency [1–3], especially in high-risk patients with high grade (>70%) stenosis [4].

The annual risk of recurrent ipsilateral ischemic stroke in patients with symptomatic intracranial atherosclerotic stenosis varies in the existing literature within 10%–24% despite optimal medical therapy [5–7]. Especially significant hemodynamic stenosis (>70%) is associated with near-term stroke recurrence. Since stroke is one of the most common reasons for death, long-term disability, and dementia, there is a rising demand on alternative therapeutic strategies.

Recently published short-term results of the SAMMPRIS (Stenting and Aggressive Medical Management for Preventing Recurrent Stroke in Intracranial Stenosis) trial showed that medical treatment alone for symptomatic intracranial artery stenosis in high-risk patients is superior to endovascular stenting and medical treatment together [8]. Patient enrollment was stopped by the Data Safety Monitoring Board, which found that 14% of patients treated with angioplasty combined with stenting and medical treatment experienced a stroke or died within 30 days after enrollment, while the stroke rate in the group only treated with oral pharmaceuticals without endovascular treatment was much lower as expected (5.2% strokes within 30 days). Long-term

follow-up results are still missing. This trial again shows that intracranial revascularization is still challenging, despite rising experience and new devices.

Depending on the vasculature and especially in case of inadequate collateral circulation, angioplasty with or without stent placement may be a promising treatment option for symptomatic intracranial stenosis [9, 10]. In case of sufficient collateral circulation, patients with intracranial artery stenosis respond well to medical treatment only.

Compared to the proximal ICA segment, the intracranial sections consist of a thinner muscular layer. Due to a "weaker" vessel wall, balloon angioplasty of intracranial stenosis carries the risk of elastic recoil and dissection. This risk can be diminished by additional stenting, but stenting itselfs carries the limitation that a rigid stent device may also lead to vessel wall injuries while positioning. However procedural risks such as dissection, perforation, and thereby intracranial hemorrhage, as well as intraluminal thrombus and perforator strokes, remain major concerns [11–13]. Currently, reports of cerebrovascular complications in stent placement for intracranial stenosis remain relatively limited because of the small number of patients included in such trials or the lack of analysis of factors that might be associated with these complications [11, 14, 15].

The purpose of this study was to investigate the effectiveness, safety, and short-term outcome of stent placement for the treatment of symptomatic extra- and intracranial artery disease with special regard to clinically silent infarctions depicted by diffusion weighted magnetic resonance imaging (DWI).

2. Materials and Methods

2.1. Patient Sample. This study included 20 patients (Tables 2 and 3) suffering from symptomatic internal carotid artery stenosis. 10 patients underwent extracranial internal carotid angioplasty and stenting (eCAS) for a high-grade ICA stenosis loco typico (mean degree of stenosis: about 90% as determined by the NASCET (North American Symptomatic Carotid Endarterectomy Trial) method). All of these 10 patients suffered from major cardiopulmonary comorbidities and received angioplasty/stenting because of their high risk for surgery.

Another 10 patients with symptomatic brain infarctions and high-grade intracranial stenosis at different carotid artery levels were treated either with angioplasty and stenting (6/10) or with balloon angioplasty alone (4/10).

All patients have given their written informed consent.

Patients were neurologically examined immediately before and after the procedure as well as 30 days after treatment. Cerebrovascular complications within 30 days of the procedure were considered periprocedural and procedure related [16].

Among those we distinguished between TIA's and ischemic strokes. TIA was defined as acute onset of a focal neurologic deficit that lasted 24 hours or less. Stroke was defined as acute onset of a focal neurologic deficit that lasted longer than 24 hours and that was specifically attributable to a cerebrovascular distribution.

Table 1: MR imaging protocol.

	T2W-TSE	DWI-EPI
TR (ms)	7000	7800
TE (ms)	91	104
Acquisition time (min:sec)	01:18	00:21
FOV (mm)	230	230
Diffusion gradient (b) (s/mm^2)		1000
Matrix (mm^2)	256 × 256	128 × 128
Slice thickness (mm)	3,0	3,0

2.2. MR Imaging. All patients received an MRI examination within 48 hours before and after the endovascular procedure consisting of diffusion weighted imaging (DWI) and T2-weighted turbo spin-echo sequences (Table 1; DWI: TR 3800 ms, TE 121 ms, acquisition time 11 sec, FOV 230 mm, *b*-value 1000, Matrix 128°—128 mm^2, slice thickness 6 mm. T2w: TR 4010 ms, TE 108 ms, acquisition time 78 sec, FOV 230 mm, matrix 256°—256 mm^2, slice thickness 6 mm). MRI data were consensually evaluated by two neuroradiologists (F. Ahlhelm and W. Reith) experienced with DWI. With high sensitivity to brain ischemia and high insensitivity for patient movement, diffusion weighted imaging is highly capable to detect acute/subacute ischemia.

2.3. Anticoagulation. All patients received a standard anticoagulation medication consisting of two antiplatelet agents (100 mg acetylsalicylacid/d and 75 mg clopidogrel/d) at least 3 days before stenting and over a six-week period after the procedure, continuing with a single antiplatelet agent. At the beginning of endovascular treatment 5000 IE heparin were applied, continued by a 20 UI/kg/h heparin infusion for 12 hours if no stent occlusion was detected on duplex sonography. Low-molecular-weight heparin was administered for 3–5 days afterwards.

2.4. Interventional Procedure. All endovascular procedures were performed by a single interventional neuroradiologist who had more than ten years of experience with endovascular therapy. Unlike eCAS, intracranial procedures were performed in general anesthesia to exclude any incidental head movement.

Embolic protection devices were not used in our study.

2.5. Extracranial ICA Stenosis. First of all a systematically selective angiography of the stenosed artery was performed using a 4-French catheter with angled tip and a 0.35 guide wire. Two series of images including two orthogonal views were acquired. A 6-French long sheath was positioned in the distal common carotid artery then replaced the diagnostic catheter. The stenosis was then carefully traversed under road map using a 0.18 guide wire followed by angioplasty and stenting. Traditionally the stent diameter was oversized about 10% and stent length was selected to completely cover

Table 2: Pre- and postprocedural (outcome on day 30) angiographic findings, diffusion-weighted (DWI) MR imaging findings, and symptoms of the patient sample who underwent CAS of the carotid bifurcation and/or ascending cervical segment of the extracranial internal carotid artery (ICA). (Sex: m: male; f: female).

Patient no./age/sex	Localisation/site	Stenosis (%)		Pre-procedural symptoms	Acute lesions on DWI before stenting (DWI −: no acute lesions)	New post-procedural symptoms	DWI after stenting (DWI −: no new lesions)
		before	after				
1/67/f	ICA left	90	0	Recurrent TIA	DWI −	None	DWI +; acute point-shaped lesions in the right MCA territory
2/75/f	ICA right	90	0	Recurrent TIA	DWI −	None	DWI −
3/47/m	ICA right	80	0	Recurrent TIA	DWI −; chronic infarct in the right frontal lobe	None	DWI +; acute point-shaped lesions in the right MCA territory
4/81/m	ICA right	95	0	Recurrent TIA	DWI −; chronic lesions in right semioval center and pons	None	DWI −
5/72/m	ICA right	90	0	Recurrent TIA	DWI +; borderzone cerebral infarction right ACA/MCA territory	None	DWI −
6/48/m	ICA right	95	0	Recurrent TIA	DWI +; acute point-shaped lesions in both hemispheres; (chronic lesion in the right cerebellum)	None	DWI −
7/61/m	ICA left	65	0	Recurrent TIA	DWI +; lesion in right central region, point-shaped lesion of the left frontal lobe	None	DWI −
8/64/m	ICA left	70	0	Recurrent TIA	DWI −	None	DWI −
9/68/m	ICA left	95	0	TIA	DWI −	None	DWI −
10/58/m	ICA left	90	0	TIA	DWI −; chronic lesion in the left MCA territory, chronic lacunar lesions in the basal ganglia	None	DWI −

Table 3: Pre- and postprocedural (outcome on day 30) angiographic findings, diffusion-weighted (DWI) MR imaging findings, and symptoms of the patient sample who underwent intracranial stenting or balloon angioplasty without additional stenting. (Sex: m: male; f: female).

Patient no./age (years)/sex	Segment/site	Stenosis before procedure (%)	Stenosis after procedure (%)	Pre-procedural symptoms	Acute lesions on DWI before treatment (DWI −: no acute lesions)	Periprocedural complications	New post-procedural symptoms	DWI after treatment (DWI −: no new lesions)
1/76/m	Cavernous segment; right	95	0	Recurrent TIA	DWI +, point-shaped lesion in the right MCA territory	None	None	DWI −
2/77/m	Cavernous segment; right	80	0	Recurrent TIA	DWI −	None	None	DWI −
3/65/m	Petrous segment; right	95	10	Recurrent TIA	DWI +, two point-shaped lesions in the right MCA territory	None	None	DWI −
4/58/f	Cavernous segment; right	80	20	HP right leg	DWI +; MCA territory of both hemispheres	Stenting technically not feasible, balloon angioplasty	None	DWI −
5/75/m	Cavernous segment; left	75	75	HP right hand	DWI +, point-shaped lesion in the left MCA territory	Stenting technically not feasible, balloon angioplasty	None	DWI −
6/63/m	Cavernous segment; left	85	60	TIA, Global amnesia	DWI −	Stenting technically not feasible, balloon angioplasty	None	DWI +, two point-shaped lesions in the right MCA territory
7/79/f	Cavernous segment; right	95	100 (rupture leading to occlusion)	Ataxia, vertigo	DWI −	Rupture during stent deployment exitus letalis	Dead	DWI −
8/75/m	Cavernous segment; right	85	0	TIA	DWI +	None	None	DWI −
9/64/m	Cavernous segment; right	80	0	Recurrent TIA	Borderzone cerebral infarction (ACA/MCA)	None	None	DWI −
10/64/f	Cavernous segment; right	85	30	HP left, neglect left	DWI +, right MCA territory	None	Slight disturbance in motor skill	DWI −

HP: Hemiparesis.
ACA: Anterior cerebral artery.
MCA: Middle cerebral artery.

the stenosis with an overhang of at least 1 mm on both sides (Zilver-Stent, Cook, Bjaeverskov, Denmark). After correct positioning of the system along the stenosis, the stent device was deployed followed by slow balloon angioplasty to 6–8 atm (after stent angioplasty).

2.6. Intracranial ICA Stenosis. First of all a systematically selective angiography of the stenosed artery was performed as described above. The stenosis was traversed carefully with a 0.10 guide wire followed by angioplasty and stenting if technically feasible. In four cases stenting was not feasible because of tortuous vessel anatomy, therefore balloon angioplasty was performed without stenting. The stent diameter of the stent was the same or about 10% smaller as the diameter of a normal adjacent vessel on either side of the stenosis and stent length was selected to completely cover the stenosis with an overhang of at least 1 mm on both sides. For intracranial procedures balloon expandable coronory stents (TsunamiT, Terumo Medical Corporation, Tokyo, Japan) were used. After correct positioning of the system along the stenosis, the stent was deployed by slow balloon inflation up to 6–8 atm.

After endovascular procedures all patients were admitted to our local stroke unit to warrant optimal monitoring.

3. Results

Angioplasty and stenting was technically feasible with no major procedure-related complications in all cases with extracranial ICA stenosis. In 4 of 10 patients suffering from intracranial atherosclerotic ICA stenosis stenting using coronary stents was not possible because of a distinct tortuosity of the vasculature, which did not allow positioning of the stent device and led to a fateful course in one patient (Table 2; no. 7) with advanced arteriosclerosis. Balloon angioplasty was performed in the latter patients yielding only minimal decrease of stenosis.

All inserted stents were patent after the procedure, as shown on MRI and Doppler sonograms. During the first 30 postprocedural days the neurological status remained unchanged except for the patient who died due to perforation of the treated artery.

Clinical findings and angiographic evaluation of procedures are summarized in Table 2 for patients who underwent eCAS and in Table 3 for patients who underwent angioplasty with or without stenting of the intracranial segments of ICA. Internal carotid artery stenosis of patients after extracranial CAS was definitely more reduced than intracranial artery stenosis.

3.1. MR Imaging. Diffusion weighted imaging using echo planar technique is quite insensitive for movement artifacts and can be performed within a few minutes due to a low acquisition time. All DW images were of diagnostic quality.

After stent implantation, new ipsilateral diffusion weighted lesions were observed in 2 patients with extracranial treatment (Table 2) and in one patient with intracranial treatment (Table 3, Figure 1).

During our periprocedural observation time of 30 days after intervention there was no case of relevant hemodynamic depression or other adverse effects.

4. Discussion

The benefits of revascularization of stenotic segments in preventing stroke have been demonstrated in patients with extracranial internal carotid artery disease [3, 17, 18]. Compared with extracranial ICA stenosis we do not know much about the annual risk of stroke in patients with intracranial ICA stenosis. Retrospective studies have suggested that a subset of patients with severe intracranial stenosis (80%) or ischemic events while receiving antithrombotic therapy may be at highest risk of stroke [19, 20]. Treatment of patients with intracranial arterial stenosis has traditionally consisted of antithrombotic therapy (antiplatelet agents or anticoagulation) and management of vascular risk factors [21]. Best antithrombotic therapy has yet to be defined since there are no data from randomized clinical trials comparing different antithrombotic agents for intracranial artery stenosis.

Concerning invasive treatment of intracranial stenosis of the ICA, the surgical approach using an extraintracranial arterial bypass is controversial and is only indicated in case of hemodynamic strokes [22–24]. However, due to improvement of microsurgical techniques and implant technology, the anticipated studies about surgical treatment are yet to be published, but until now this treatment option is considered inferior to the endovascular procedures.

Concerning endovascular approach for invasive treatment of symptomatic intracranial stenosis there is rapid improvement and refinement of stent technology yielding development of new balloon-expandable as well as self-expanding intracranial stents that now allow access even to tortuous and atherosclerotic vessel anatomy [25]. Balloon angioplasty alone is generally performed when individual anatomy does not allow reaching the stenosis with the stent device. As Lylyk et al. have described previously, compared with balloon angioplasty, stent placement had better results concerning residual stenosis [10]. In our study the mean postoperative residual intracranial stenosis was less than 10% after stent placement, whereas that of balloon angioplasty was about 50% in the mean which was also consistent with previous studies [26, 27]. A disadvantage of the balloon technique is that plaque material is not stabilized by the stent meshes and in case of floating plaques balloon angioplasty may even cause thromboembolism, which could not be observed in our patient sample.

Considering the high restroke rate of up to 24% per year under conservative therapy [5–7], the treatment of intracranial stenosis with stent and/or angioplasty should be accomplished as soon as possible. Since no large studies concerning long-term results of intracranial stenosis treated with stent and/or angioplasty exist there is little knowledge regarding restroke rate due to restenosis of these vessels. These studies are necessary to assess the real benefit of this treatment option.

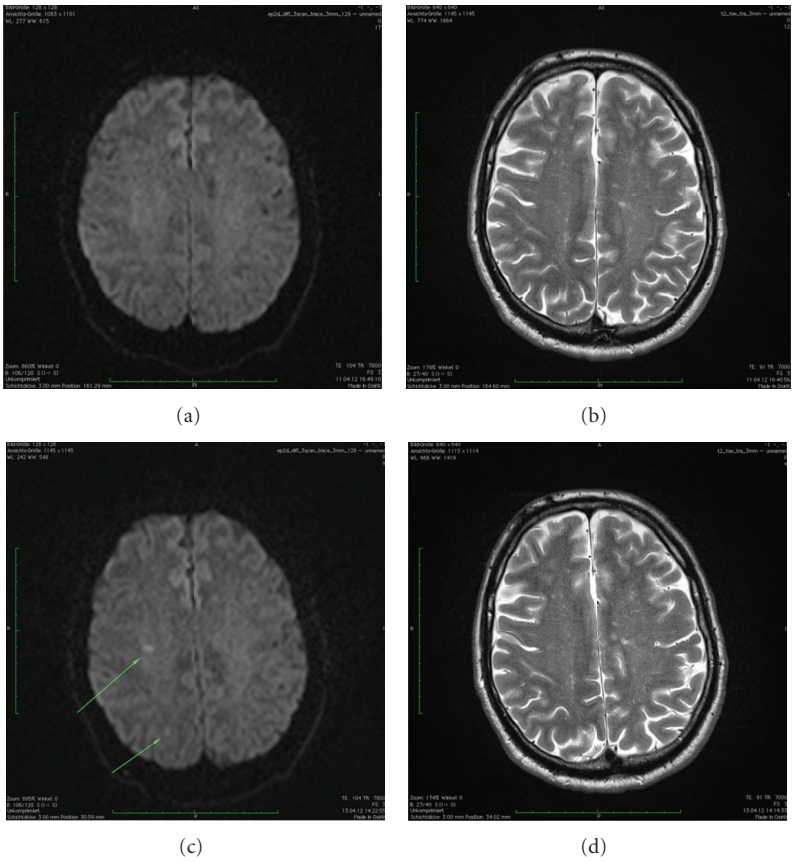

Figure 1: MR imaging findings before (a, b) and after (c, d) angioplasty and stenting of the right intracranial cavernous carotid artery segment. DW imaging (a, c) reveals two procedure-related embolic lesions (arrows) in the ipsilateral MCA territory of the treated right carotid artery. T2-W TSE image (d) of the same slice position does not allow depiction of the lesions.

The results of endovascular treatment of intracranial stenosis with balloon angioplasty have been tempered by the increased risk of stroke, which may result from distal embolization, vessel dissection, and acute vessel occlusion secondary to dissection or platelet aggregation [26].

Concerning the point of stent-related restenosis, a pre- and postprocedural, antiaggregatory treatment, dual antiplatelet therapy, with ASA and Clopidogrel is considered to be mandatory to prevent thromboembolic complications and stent thrombosis. This is a dilemma since periprocedural antithrombotic medications and anticoagulation are generally a problem in case of procedure-related vessel injuries such as perforation with subsequent bleeding. In our series there was also one 79-year-old female patient with a fateful course of vessel rupture. Recently, the advent of a new generation of more flexible stents has prompted consideration of stent-assisted angioplasty as an alternative approach for treatment of intracranial stenosis [25, 28].

Improved periprocedural medication with use of dual antiplatelet agents and advancements concerning stent technologies lead to remarkable decrease of complications especially preventing early in-stent restenosis or procedural-related brain infarction. Our series shows that even clinically silent infarctions assessed by diffusion weighted imaging, which is generally considered to be the diagnostic procedure of primary choice for detection of acute brain infarctions, are quite rare, a skilled operator and experienced postprocedural surveillance provided.

One limitation of this study is the low number of patients which does not allow any statistical analysis. Moreover due to refinements of catheter materials, today especially designed intracranial stents are available which should also contribute to improve the technical success rate and maybe the outcome of patients with intracranial stenosis.

5. Conclusion

To our best knowledge, this is the first study that directly compares periprocedural complications assessed by clinical findings and diffusion weighted imaging after intracranial carotid angioplasty (with or without stenting) with extracranial carotid artery angioplasty and stenting performed by a single operator. Since this endovascular approach has a relatively low clinical complication rate, thrombembolic events with no clinical impact but ischemic lesions assessed by diffusion weighted imaging could be revealed in three extracranial CAS patients, but only in one case of intracranial treatment. Diffusion weighted imaging has shown its potency for detection of clinically silent ischemic brain

lesions and thereby is a powerful tool for quality control in case of endovascular treatment of brain supplying arteries and therefore should be used as a marker of quality control for further studies.

References

[1] N. Al-Mubarak, G. S. Roubin, C. R. Gomez et al., "Carotid artery stenting in patients with high neurologic risks," *American Journal of Cardiology*, vol. 83, no. 9, pp. 1411–1413, 1999.

[2] L. J. Coward, R. L. Featherstone, and M. M. Brown, "Safety and efficacy of endovascular treatment of carotid artery stenosis compared with carotid endarterectomy: a cochrane systematic review of the randomized evidence," *Stroke*, vol. 36, no. 4, pp. 905–911, 2005.

[3] P. A. Ringleb, J. Allenberg, H. Brückmann et al., "30 day results from the SPACE trial of stent-protected angioplasty versus carotid endarterectomy in symptomatic patients: a randomised non-inferiority trial," *Lancet*, vol. 7368, no. 9543, pp. 1239–1247, 2006.

[4] A. M. Malek, R. T. Higashida, C. C. Phatouros et al., "Stent angioplasty for cervical carotid artery stenosis in high-risk symptomatic NASCET-ineligible patients," *Stroke*, vol. 31, no. 12, pp. 3029–3033, 2000.

[5] V. N. Thijs and G. W. Albers, "Symptomatic intracranial atherosclerosis: outcome of patients who fail antithrombotic therapy," *Neurology*, vol. 55, no. 4, pp. 490–497, 2000.

[6] K. S. Wong, H. Li, W. W. M. Lam, Y. L. Chan, and R. Kay, "Progression of middle cerebral artery occlusive disease and its relationship with further vascular events after stroke," *Stroke*, vol. 33, no. 2, pp. 532–536, 2002.

[7] M. I. Chimowitz, M. J. Lynn, H. Howlett-Smith et al., "Comparison of warfarin and aspirin for symptomatic intracranial arterial stenosis," *The New England Journal of Medicine*, vol. 352, no. 13, pp. 1305–1397, 2005.

[8] M. I. Chimowitz, M. J. Lynn, C. P. Derdeyn et al., "Stenting versus aggressive medical therapy for intracranial arterial stenosis," *The New England Journal of Medicine*, vol. 365, no. 11, pp. 993–1003, 2011.

[9] R. T. Higashida, F. Y. Tsai, V. V. Halbach et al., "Transluminal angioplasty for atherosclerotic disease of the vertebral and basilar arteries," *Journal of Neurosurgery*, vol. 78, no. 2, pp. 192–198, 1993.

[10] P. Lylyk, J. E. Cohen, R. Ceratto, A. Ferrario, and C. Miranda, "Angioplasty and stent placement in intracranial atherosclerotic stenoses and dissections," *American Journal of Neuroradiology*, vol. 23, no. 3, pp. 430–436, 2002.

[11] R. Gupta, H. C. Schumacher, S. Mangla et al., "Urgent endovascular revascularization for symptomatic intracranial atherosclerotic stenosis," *Neurology*, vol. 61, no. 12, pp. 1729–1735, 2003.

[12] H. C. Schumacher, A. V. Khaw, P. M. Meyers, R. Gupta, and R. T. Higashida, "Intracranial angioplasty and stent placement for cerebral atherosclerosis," *Journal of Vascular and Interventional Radiology*, vol. 15, no. 1, pp. S123–S132, 2004.

[13] R. D. M. De Rochemont, B. Turowski, M. Buchkremer, M. Sitzer, F. E. Zanella, and J. Berkefeld, "Recurrent symptomatic high-grade intracranial stenoses: safety and efficacy of undersized stents—initial experience," *Radiology*, vol. 231, no. 1, pp. 45–49, 2004.

[14] H. Henkes, E. Miloslavski, S. Lowens, J. Reinartz, T. Liebig, and D. Kühne, "Treatment of intracranial atherosclerotic stenoses with balloon dilatation and self-expanding stent deployment (WingSpan)," *Neuroradiology*, vol. 47, no. 3, pp. 222–228, 2005.

[15] W. J. Jiang, B. Du, T. W. Leung, X. T. Xu, M. Jin, and K. H. Dong, "Symptomatic intracranial stenosis: cerebrovascular complications from elective stent placement," *Radiology*, vol. 243, no. 1, pp. 188–197, 2007.

[16] R. T. Higashida, P. M. Meyers, C. C. Phatouros, J. J. Connors, J. D. Barr, and D. Sacks, "Reporting standards for carotid artery angioplasty and stent placement," *Stroke*, vol. 35, no. 5, pp. e112–e134, 2004.

[17] G. G. Ferguson, M. Eliasziw, H. W. K. Barr et al., "The North American Symptomatic Carotid Endarterectomy Trial: surgical results in 1415 patients," *Stroke*, vol. 30, no. 9, pp. 1751–1758, 1999.

[18] European Carotid Surgery Trialists Collaborative Group, "MRC European Carotid Surgery Trial: interim results for asymptomatic patients with severe or with mid carotid stenosis," *The Lancet*, vol. 337, pp. 1235–1241, 1995.

[19] M. Mazighi, R. Tanasescu, X. Ducrocq et al., "Prospective study of symptomatic atherothrombotic intracranial stenoses: the GESICA Study," *Neurology*, vol. 66, no. 8, pp. 1187–1191, 2006.

[20] S. E. Kasner, M. I. Chimowitz, M. J. Lynn et al., "Predictors of ischemic stroke in the territory of a symptomatic intracranial arterial stenosis," *Circulation*, vol. 113, no. 4, pp. 555–563, 2006.

[21] M. I. Chimowitz, J. Kokkinos, J. Strong et al., "The warfarin-aspirin symptomatic intracranial disease study," *Neurology*, vol. 45, no. 8, pp. 1488–1493, 1995.

[22] "Failure of extracranial-intracranial arterial bypass to reduce the risk of ischemic stroke: results of an international randomized trial," *The New England Journal of Medicine*, vol. 313, no. 19, pp. 1191–1200, 1985.

[23] G. J. Przybylski, H. Yonas, and H. A. Smith, "Reduced stroke risk in patients with compromised cerebral blood flow reactivity treated with superficial temporal artery to distal middle cerebral artery bypass surgery," *Journal of Stroke and Cerebrovascular Diseases*, vol. 7, no. 5, pp. 302–309, 1998.

[24] N. Futrell, "EC-IC bypass: the failure of a clinical trial? Applicability to PFO closure trials," *Current Treatment Options in Cardiovascular Medicine*, vol. 9, no. 3, pp. 173–179, 2007.

[25] W. J. Jiang, X. T. Xu, M. Jin, B. Du, K. H. Dong, and J. P. Dai, "Apollo stent for symptomatic atherosclerotic intracranial stenosis: study results," *American Journal of Neuroradiology*, vol. 28, no. 5, pp. 830–834, 2007.

[26] W. M. Clark, S. L. Barnwell, G. Nesbit, O. R. O'Neill, M. L. Wynn, and B. M. Coull, "Safety and efficacy of percutaneous transluminal angioplasty for intracranial atherosclerotic stenosis," *Stroke*, vol. 26, no. 7, pp. 1200–1204, 1995.

[27] M. P. Marks, M. Marcellus, A. M. Norbash, G. K. Steinberg, D. Tong, and G. W. Albers, "Outcome of angioplasty for atherosclerotic intracranial stenosis," *Stroke*, vol. 30, no. 5, pp. 1065–1069, 1999.

[28] P. Lylyk, J. F. Vila, C. Miranda et al., "Endovascular reconstruction by means of stent placement in symptomatic intracranial atherosclerotic stenosis," *Neurological Research*, vol. 27, supplement 1, pp. S84–S88, 2005.