Hindawi Publishing Corporation
ISRN Plastic Surgery
Volume 2013, Article ID 735406, 4 pages
http://dx.doi.org/10.5402/2013/735406

Clinical Study

The "Power" Brow Lift: Efficient Correction of the Paralyzed Brow

Marc H. Hohman,[1] Amanda L. Silver,[1] Douglas K. Henstrom,[2] Mack L. Cheney,[1] and Tessa A. Hadlock[1]

[1] *Division of Facial Plastic and Reconstructive Surgery, Massachusetts Eye and Ear Infirmary, 243 Charles Street, Boston, MA 02114, USA*
[2] *Department of Otolaryngology-Head and Neck Surgery, University of Iowa, 200 Hawkins Drive, Iowa City, IA 52242, USA*

Correspondence should be addressed to Marc H. Hohman; marc_hohman@meei.harvard.edu

Received 11 October 2012; Accepted 4 November 2012

Academic Editors: C. Maldonado and D. D. Park

Purpose. To describe a novel approach to brow ptosis correction and evaluate its long-term efficacy in patients with facial-paralysis-associated brow ptosis. *Methods*. Twenty-two patients aged from 50 to 90 years underwent "power" brow lifting, involving 3 intrabrow stab incisions and suture suspension of the brow to the frontal calvarium via titanium miniplate. Long-term results of the operation were assessed retrospectively. Pre- and postoperative photographs were measured with FACE-gram software to evaluate efficacy of the procedure. *Results*. Seventeen patients who underwent "power" brow lift were available for postoperative evaluation. Among them, follow-up length ranged from 12 to 448 days. The average post-operative change in brow height was 5.7 mm, which was statistically significant ($P < 0.01$). There were no complications. *Conclusions*. The "power" brow procedure can help to restore upper facial symmetry and visual fields and improve periocular hygiene. The operation is easily performed in an office setting, under local anesthesia, and appears to provide reliable long-term results. The time required to perform the procedure is far less than that required for a standard direct brow lift; there is no risk of postoperative forehead hypesthesia, and there is no superciliary scar.

1. Introduction

Recognition and correction of brow ptosis are critical to satisfactory functional and aesthetic treatment of the upper face in facial paralysis. Indications for unilateral brow ptosis correction include visual-field deficits, hygiene issues caused by overhanging skin, ocular fatigue due to compensatory hyperactivity of the frontalis muscle, and desire for improved cosmesis through the reestablishment of symmetry. For patients desiring upper facial rejuvenation, brow ptosis evaluation is recommended prior to the performance of upper lid blepharoplasty [1, 2]. Caution should be exercised in patients with dry eyes, lagophthalmos, or decreased corneal sensitivity.

In 1926, Hunt first described a coronal incision to elevate the brow [1, 3]. Limitations of this approach include difficulty in precise brow shaping and positioning through the distant incision, localized alopecia, unsatisfactory widening of the scar over time, paresthesias posterior to the incision line, and recurrent brow ptosis [4]. Other approaches to address some of these shortcomings have been developed, including pretrichial, midforehead, direct, and endoscopic brow lift techniques; each has particular advantages and drawbacks. Specific disadvantages of direct brow lift include occasionally unsatisfactory superciliary scar, recurrent brow ptosis, and paresthesias or hypesthesia of the forehead.

In patients with significant brow ptosis secondary to facial paralysis, we recognized that certain unfavorable anatomic conditions predisposed to a poor outcome following standard brow lifting methods. Among these, recessed eyes, prominent brow ridges, and aged or thick skin were leading factors in unsatisfactory outcomes. In response to this, we developed a novel miniplate assisted technique for brow ptosis correction that is easily performed in the office setting. In patients with predictors of unsatisfactory outcomes using traditional methods, we have performed 22 "power" brow lifts in the

Massachusetts Eye and Ear Infirmary Facial Nerve Clinic, since February 2009. Herein, we describe our technique and long-term results.

2. Materials and Methods

The procedure is performed in the office setting, using a local anesthetic (1% lidocaine with 1 : 100,000 epinephrine). The forehead and eyebrow on the affected side are infiltrated, and ice is applied to the forehead region to maximize vasoconstriction. A 2 cm incision is placed just posterior to the hairline on the frontal scalp, centered on a vertical mid-pupillary line. Dissection is carried down sharply through the subcutaneous tissue, and the calvarium is exposed. A subperiosteal pocket is created, large enough to place a 5-hole straight 1.4 mm titanium miniplate (Synthes, West Chester, PA,USA). A number 11 blade is then used to make three 2 mm stab incisions evenly spaced within the hair-bearing eyebrow (Figure 1). A 2-0 silk tie loaded onto an 11 cm Keith needle (Dermatologic Lab and Supply, Inc., Council Bluffs, IA,USA) is inserted into the lateral aspect of the lateral incision and directed out of the scalp incision (Figure 1). The needle courses superficially, in the subcutaneous plane, until approximately 2 cm above the brow, at which point it is guided into a deeper plane, gradually reaching the subperiosteal plane before emerging from the scalp incision. Thus, one end of the suture is brought through the superior incision, as the other end is kept at the lateral stab incision and reloaded onto the needle. The Keith needle is then directed in to a superficial plane from the lateral stab incision to the middle stab incision (Figure 1, inset). The loaded needle is finally directed superiorly as described above. In this manner, a "U" is created with a single suture such that both ends emerge from the scalp incision. The base of the "U" creates a broad front for the superior vector of elevation. A second 2-0 silk is used to create another "U" from the middle stab incision to the medial stab incision in the same way. The emerging sutures are threaded through the holes of the miniplate (Figure 1), which is then secured to the calvarium using 4 mm self-tapping screws. Care is taken not to tighten the screws at this step, as pinching the sutures tightly between the plate and the underlying bone would prevent final adjustment of the brow height. The patient is raised into a seated position to allow assessment of brow height as the sutures are tied down sequentially. Once adequate brow height is achieved and the sutures are secured, the screws are tightened to pinch the sutures against the underlying calvarium, thereby further stabilizing the final brow position. The scalp incision is closed using a 4-0 prolene suture (Ethicon, Inc., Somerville, NJ, USA) in a simple interrupted fashion, and the stab incisions within the brow are treated with antibiotic ointment. A pressure dressing is applied and kept in place for 24 hours. Figure 2 shows key procedure steps, and Figure 3 shows preprocedure and postprocedure results.

Brow position was quantified using our previously described FACE-gram program, which is used to measure both static and dynamic positions of the face [5]. Briefly, the program scales the photograph according to the premise that the average iris diameter in humans is roughly 12 mm. The program then calculates the distance between the pupil and the upper border of the brow in the midpupillary line (Figure 4). Statistical significance was assessed using the Student's paired two-tailed test.

3. Results

Since February 2009, we have performed 22 "power" brow lifts, in 17 men and 5 women. Age at the time of the procedure ranged from 50 to 90 years (median age 66 years). The most common cause of facial paralysis was tumor (19 patients); the second most common was iatrogenic injury during mandible or temporomandibular joint surgery (2 patients). One patient developed facial paralysis from Ramsay-Hunt syndrome. Median followup was 75 days (range 12–549 days). All pre- and postoperative images were taken at rest, after 15 seconds of relaxation with eyes closed. Patients were then asked to open their eyes gently, without inducing any forehead or brow tension. A representative patient is shown in Figure 3.

Four patients have not yet been seen in postoperative followup, and 1 patient expired due to his primary disease; these 5 patients were not included when results were calculated. For the remaining 17 patients (13 males and 4 females), quantitative measurements of brow position were made using a vertically oriented line from the superior-most point of the brow to a horizontal midpupillary line. The average preoperative pupil to top-of-brow distance was 18.0 +/− 3.55 mm, and the average postoperative distance was 23.7 +/− 3.46 mm. The average increase of 5.7 mm was statistically significant ($P < 0.01$).

4. Discussion

The brow ptosis correction technique described herein is designed to address unilateral or bilateral brow ptosis reliably in the office setting. Significant advantages include the ability to set the brow position with the patient awake and seated, simplicity, and brief operative time. The procedure requires no significant subperiosteal dissection, resulting in very limited edema. No endoscope is required, and there is no division of the arcus marginalis nor is there manipulation of the supraorbital or supratrochlear neurovascular bundles, minimizing the likelihood of bleeding and hypesthesia. Large superciliary incisions are avoided, thereby improving cosmesis and reducing closure time. The "power" brow lift is very well tolerated under local anesthesia and requires minimal postoperative care. In addition, the procedure appears to be effective over time. Should revision be required, the second procedure would be even simpler than the primary one: loosening of the screws on the miniplate, followed by tightening of the sutures, and retightening of the screws.

Unlike other techniques which describe a singlepoint vector of upward pull from a suspension suture [2, 6], in our technique we incorporate a broader plane, or "front," of subdermal tissue into the suspension vector. There is a mechanical advantage inherent in a subdermal lift because

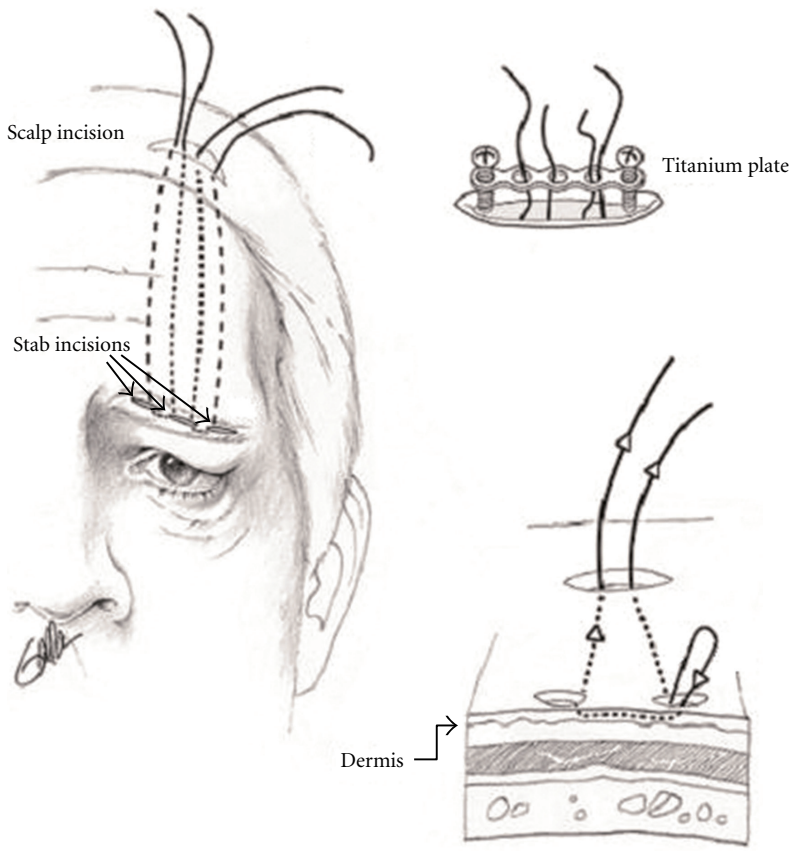

Figure 1: Artist's rendering of the procedure.

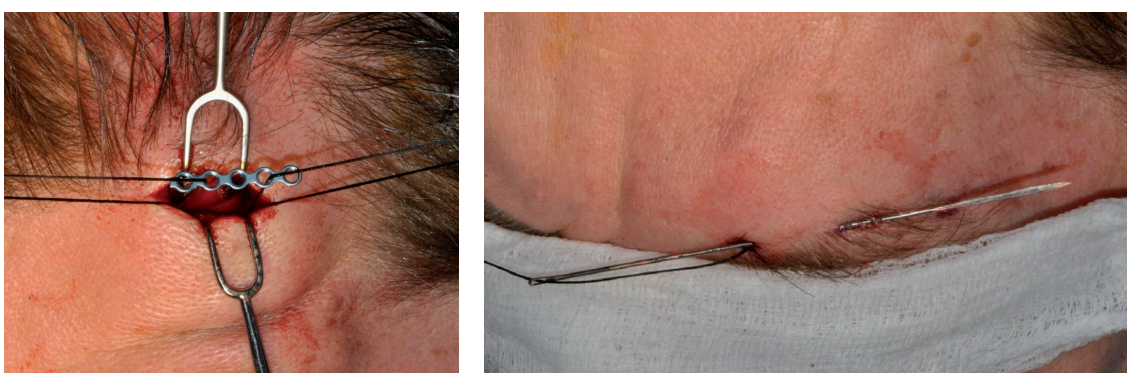

(a) (b)

Figure 2: Key procedure steps: (a) 2-0 silk sutures placed through a 5-hole straight 1.4 mm miniplate that will be secured into the calvarium. (b) Passage of an 11 cm Keith needle through the deep dermis from one brow stab incision to another.

there is less soft tissue to stretch and sag between the lifted eyebrow and the suspension sutures than there would be in a subperiosteal plane lift; this leads us to expect longterm persistence of the results we have seen to date. In 2003, Costantino et al. [7] described a brow elevation technique in which 3 nylon sutures are used to suspend the brow to the frontal periosteum, achieving results similar to those reported in this study, with the exception of a single postoperative hematoma in their series. The primary difference between their technique and that reported in this paper is that they suspend the brow to the pericranium, which has the potential to stretch and allow some degree of brow depression over time, whereas the titanium plate employed in our approach should provide a long term rigid suspension point. Less dissection is required in our technique as well, as we do not advocate a subperiosteal elevation of the forehead before suspension of the brow, which may decrease the risk of postoperative edema or hematoma.

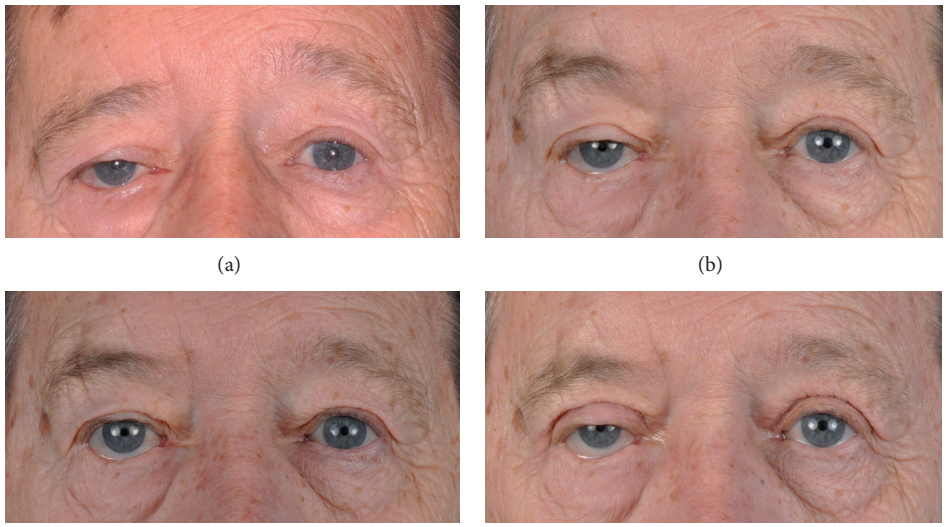

Figure 3: Clinical example of right brow lift. (a) Before procedure, frontal view. (b) 2 weeks after procedure. (c) 4 months post-procedure. (d) 18 months after procedure.

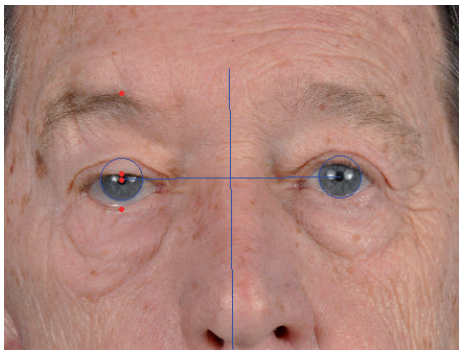

Figure 4: FACE-gram program. The lower lid, iris, upper lid, and upper boarder of the brow are marked in the midpupillary line. The program then calculates the distance between the pupil and the upper border of the brow in the midpupillary line.

Disadvantages of our technique include transient brow dimpling or puckering at the 3 brow incision points, an issue which the Costantino technique [7] addresses at the time of surgery via limited undermining. Over time, we have modified the angle of the Keith needle in the subperiosteal plane by making it less acute and more graded. This has decreased the degree of brow dimpling seen in the early postoperative period. Nevertheless, the ideal patient must be tolerant of an office procedure performed under local anesthesia and must accept the risk of potential transient brow dimpling, which may last for up to 3 months. Reassurance, as well as gentle massage of the upper brow starting 2 weeks after procedure, appears to help to expedite resolution. Another potential disadvantage of the technique is the possibility of extrusion of the silk sutures. This occurred with a single suture in 1 patient and was managed successfully with topical and oral antibiotics.

5. Conclusion

Given the procedure's advantages and limitations, we have performed this technique primarily on patients seen in our Facial Nerve Center who were experiencing symptomatic brow ptosis resulting from facial paralysis. To date, our results appear to be durable, functional, and aesthetically pleasing for patients; however, longer-term followup is required.

References

[1] R. P. Yeatts, "Current concepts in brow lift surgery," *Current Opinion in Ophthalmology*, vol. 8, no. 5, pp. 46–50, 1997.

[2] D. Georgescu, R. L. Anderson, and J. D. McCann, "Brow ptosis correction: a comparison of five techniques," *Facial Plastic Surgery*, vol. 26, no. 3, pp. 186–192, 2010.

[3] O. M. Ramirez and P. McKinney, "The anchor subperiosteal forehead lift," *Plastic and Reconstructive Surgery*, vol. 95, no. 6, pp. 993–1006, 1995.

[4] O. M. Ramirez, "Anchor subperiosteal forehead lift: from open to endoscopic," *Plastic and Reconstructive Surgery*, vol. 107, no. 3, pp. 868–871, 2001.

[5] D. Bray, D. K. Henstrom, M. L. Cheney, and T. A. Hadlock, "Assessing outcomes in facial reanimation: evaluation and validation of the smile system for measuring lip excursion during smiling," *Archives of Facial Plastic Surgery*, vol. 12, no. 5, pp. 352–354, 2010.

[6] A. R. Namazie and G. S. Keller, "Current practices in endoscopic brow and temporal lifting," *Facial Plastic Surgery Clinics*, vol. 9, no. 3, pp. 439–451, 2001.

[7] P. D. Costantino, D. H. Hiltzik, J. Moche, and A. Preminger, "Minimally invasive brow suspension for facial paralysis," *Archives of Facial Plastic Surgery*, vol. 5, no. 2, pp. 171–174, 2003.