Hindawi Publishing Corporation
ISRN Stroke
Volume 2013, Article ID 838292, 7 pages
http://dx.doi.org/10.1155/2013/838292

Clinical Study

Morphology of Middle Cerebral Artery Aneurysms: Impact on Surgical Strategy and on Postoperative Outcome

Karl-Michael Schebesch,[1] Martin Proescholdt,[1] Kathrin Steib,[1] Odo-Winfried Ullrich,[1] Andreas Herbst,[1] Janine Rennert,[2] and Alexander Brawanski[1]

[1] *Department of Neurosurgery, University Medical Center, Franz-Josef-Strauss Allee 11, 93053 Regensburg, Germany*
[2] *Neuroradiology Branch, Radiological Institute, University Medical Center, Franz-Josef-Strauss Allee 11, 93053 Regensburg, Germany*

Correspondence should be addressed to Karl-Michael Schebesch; karl-michael.schebesch@klinik.uni-regensburg.de

Received 15 February 2013; Accepted 7 March 2013

Academic Editors: A. Ducruet, T. Platz, R. Ptak, J. Van Der Grond, and J. Wambaugh

The outcome of middle cerebral artery (MCA) aneurysm clipping depends on the presence of subarachnoid hemorrhage (SAH). Moreover, it is influenced by anatomical features of the aneurysm and its parent artery. We hypothesized that morphological characteristics of the aneurysm may be predictive for postoperative outcome. Therefore, we identified radiographic assessable details that predicted the surgical difficulty and the risk for new ischemia. The angiograms of 151 consecutive patients (82 presenting with SAH) were analyzed in a standardized fashion focusing on 12 defined morphological aspects. The results were correlated to intraoperative rupture and to postoperative ischemia. Aneurysms presenting with SAH were associated with irregular shape, larger maximum diameter, and larger dome-to-base distance (DBD) and were located more frequently on the M2 segment. Multivariate analysis revealed 6 independent predictors for intraoperative rupture: SAH, location on M2 segment, DBD, maximum diameter, diameter of the parent MCA, and the presence of branching vessel. Independent predictors of surgery-related ischemia were identified: SAH, irregular shape, location on M2 segment, DBD, and the neck-to-vessel ratio (NVR). In MCA aneurysms, independent predictors for the risk of rupture intraoperatively and for the postsurgical outcome were the presence of SAH, location on the M2-segment, size (DBD), and the broadness of the neck.

1. Introduction

Publication of the ISAT data in 2002 [1] led to a drastic change in the treatment strategy of intracranial aneurysms [2, 3]. Today, endovascular occlusion of cerebral aneurysms is a widespread and well-evaluated option, although the long-term data evaluation of the ISAT collective failed to demonstrate a sustained beneficial impact of endovascular treatment [4]. Recent publications and reviews, assessing the feasibility and clinical value of interventional treatment, particularly of middle cerebral artery (MCA) aneurysms, consistently conclude that the complex anatomy and elevated long-term recurrence rate of MCA aneurysms gives preference to the surgical option [3, 5–12].

The localization, size, and morphology of MCA aneurysms have been recognized as crucial for the risk of sudden rupture, but, moreover, these anatomical aspects may serve as valuable parameters for preoperative estimation of the complexity of the surgical procedure, demanding experienced surgical skills, accordingly. This "surgical difficulty level" may affect the postoperative outcome in a significant manner [13]. We hypothesized that a standardized quantitative assessment of the pathoanatomical aneurysm characteristics may allow predicting the incidence of surgical complication and morbidity rates.

Nowadays, the size and shape of the aneurysm, of the aneurismal dome and neck, and the diameter of the parent artery, adjacent or branching vessels, are usually depicted by preoperative contrast enhanced computed tomography (CT) and by three-dimensional (3D) rotational digital subtraction angiography (3D-DSA) [14, 15]. In this study, we extracted parameters representative for the anatomy of the aneurysm and the direct environment. These features were correlated to the "surgical difficulty level," represented by the rate of intraoperative rupture, and were correlated to the neurological outcome immediately postoperatively, represented by

Table 1: Preoperative Hunt and Hess (HH) and WFNS scores of the 82 pts with SAH.

HH	n (n%)	WFNS	n (n%)
1	18 (22%)	1	2 (2.4%)
2	25 (30.5%)	2	11 (13.5%)
3	14 (17.1%)	3	26 (31.7%)
4	13 (15.9%)	4	43 (52.4%)
5	12 (14.5%)		

any new ischemia directly postoperatively in MCA aneurysm patients with and without subarachnoid hemorrhage (SAH).

2. Patients and Method

Retrospectively, we analyzed the preoperative angiography and the pre- and postoperative CT-scans, as well as patient records, of 151 consecutive patients that underwent surgical treatment of at least one MCA aneurysm (ruptured or unruptured) in our Neurosurgical Department. The mean followup was 1.5 months (range 1–5 months).

Exclusion criteria were distal MCA aneurysms (M3- or M4 segment), giant aneurysms (>24.9 mm), and mycotic aneurysms. Furthermore, we excluded all patients that experienced treatment other than craniotomy and surgical aneurysm repair.

In all patients, aneurysm clipping was performed via the pterional approach and opening of the Sylvian fissure in microsurgical technique. The complete occlusion of the aneurysm and the perfusion of the proximal and distal branches were assessed by intraoperative Doppler Sonography and Indocyanine Green (ICG) angiography. All patients were transferred to the neurosurgical intensive care unit (ICU) where treatment was given according to our standard protocol [16].

Besides demographical data, we analyzed the preoperative World Federation of Neurosurgical Societies score (WFNS) and Hunt and Hess score (HH). Important accompanying diseases, iatrogenic anticoagulation, and relevant comorbidities were recorded. The radiographic data obtained by DSA, contrast enhanced CT, and noncontrast CT were analyzed for information concerning aneurysm morphology; see Figure 1: shape (saccular, multilobulated), diameters (maximum diameter, dome-to-base distance = DBD), Neck broadness (neck-to-vessel ratio = NVR), parent vessel diameter, location of the aneurysm (M1 or M2 segment), and the presence of branching vessels. Intraoperative events and the surgical strategy (temporary clipping time, surgery time, and intraoperative rupture) were extracted from the surgery report. The immediate postoperative CTs (<24 hrs postop.) were screened for any new, surgery-related ischemia.

The crucial event "intraoperative rupture" defined the "surgical difficulty level," and the postoperative outcome was registered as "new ischemia postoperatively" (CT scan < 24 hrs) by the neuroradiologists.

The study was approved by the local ethics committee (11-101-0271).

2.1. Statistical Analysis. Comparative statistical analysis for two different groups was performed using a Mann-Whitney Rank Sum test and for rates and proportions using Chi square analysis or a two-tailed Fisher Exact test. Associations between different parameters were investigated by Spearman's rank correlation analysis. Multivariate analysis of factors influencing either the intraoperative difficulty level or postoperative ischemia was performed by multiple logistic regression analysis (SigmaStat Version 3.5, Systat Inc., Chicago, IL, USA). Significance was defined as $P < 0.05$.

3. Results

3.1. Demographics and Preoperative Condition. We included 48 males and 103 females (151 patients). The mean age was 52.3 years (range 17.1 years to 78.0 years). Eighty two patients presented with SAH; see Table 1. No statistically significant difference in age ($P = 0.11$) and gender distribution ($P = 0.21$) was detected between the SAH and non-SAH groups.

From all patients, 103 (68.2%) suffered from a relevant accompanying disease or had a major risk factor; arterial hypertension was present in 74 patients (71.8%), nicotine dependence in 25 patients (24.3%), and diabetes mellitus in 13 patients (12.6%). There was no statistically significant difference between aneurismal rupture and comorbidity ($P = 0.88$, $P = 0.69$, and $P = 0.80$, resp.). Initial iatrogenic anticoagulation ($n = 17$, 11.3%) was not predictive for aneurismal rupture ($P = 0.89$).

Moreover, 136 aneurysms were clipped (90.1%), 3 aneurysms were wrapped (2.0%), and both clipping and wrapping were performed in 8 cases (5.3%). A definitive surgical treatment was not possible in 4 patients (2.6%). No statistically significant difference was detected between the SAH and non-SAH group regarding the surgical treatment strategy ($P = 0.10$).

The mortality in the SAH group ($n = 82$) was 9.7%. The overall mortality (non-SAH group included) was 5.3% during the followup. No death occurred within 24 hrs after surgery.

The univariate statistical analysis of the morphological aspects that were associated with initial aneurysm rupture is presented in Table 2.

3.2. Aneurysm Morphology

3.2.1. Shape (Configuration, NVR). In the complete population, 87 (57.6%) were saccular aneurysms with a single berry while 39 aneurysms (25.8%) had a multilobulated configuration. The frequency of saccular versus multilobulated aneurysm was not significantly different in the SAH versus the non-SAH group ($P = 0.81$). One aneurysm was fusiform (0.7%). Twenty four aneurysms were disregarded as the shape could not be classified exactly. The mean neck-vessel ratio (NVR) was 1.8 (range 0.1 to 7.1) and stratified by SAH 1.95 ± 1.0 in the SAH and 1.70 ± 1.0 in the non SAH group ($P = 0.17$).

3.2.2. Related Vasculature (M1/M2, Branching Vessels, Diameter Parent Artery). A total of 118 aneurysms (78.1%) were originating from the M1-segment while 24 aneurysms (15.9%)

Table 2: Analysis of morphological aspects associated with aneurysm rupture (SAH group).

	SAH (n = 82)	Non-SAH (n = 69)	P value
DBD	7.9 mm	5.3 mm	0.001*
Max diameter	7.9 mm	6.3 mm	0.04*
Multilobated shape	32.9%	18.8%	0.01*
NVR	1.95	1.7	>0.05
Branching vessels	3.6%	4.3%	>0.05
Diameter parent vessel	1.9	2.0	>0.05
M1	12.2%	29%	>0.05
M2	87.8%	71%	0.007*

(*) Level of significance.

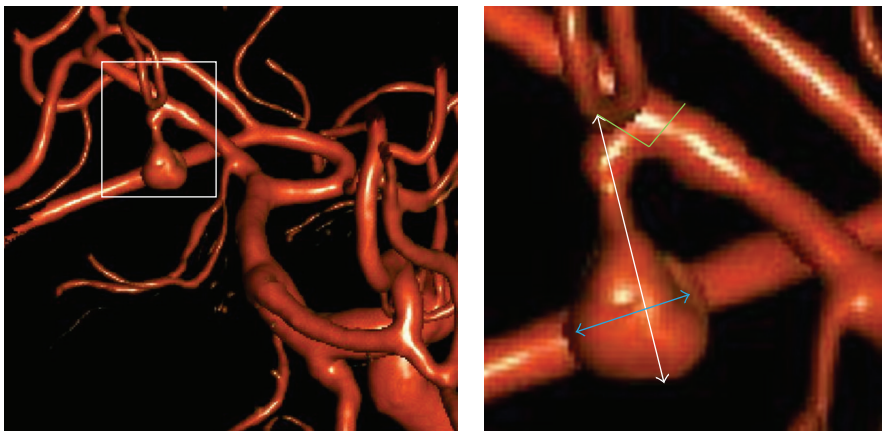

(a) (b)

Figure 1: (a,b) Demonstration of radiographic assessment of morphological features (here: saccular M2 aneurysm). (Green angle: neck-vessel ratio (NVR); white arrow: dome-to-base distance (DBD); blue arrow: maximum diameter).

were found in the M2-segment. Three aneurysms (2.0%) involved both the M1 and M2 segments. While the frequency of M1 aneurysms was equally distributed in the patients presenting with or without SAH, significantly more patients presented with an M2 segment aneurysm in the SAH group compared to the non-SAH group (P = 0.018). Six aneurysms were disregarded as the surrounding vasculature could not be evaluated exactly. In 6 pts (4.0%), branching vessels out of the aneurismal neck were registered. The mean diameter of the parent MCA was 2.0 mm (range 0.5 to 5.0 mm).

3.2.3. Size. Of all aneurysms, the mean diameter was 7.2 mm (median 6.0 mm, range 1.5 to 24.5 mm). The mean dome-to-base distance (DBD) was 6.1 mm (median 5.0 mm, range 1.5 to 32.0 mm). Both the mean diameter (mean 7.9 versus 6.3 mm; P = 0.04) and the DBD (7.9 versus 5.3 mm; P = 0.001) were significantly larger in the SAH group.

3.3. Operative Strategy and Intraoperative Events

3.3.1. Surgery Time and Temporary Clipping. The mean surgery time was 216.1 min in the complete population (median 208.0 min, range 110.0 to 400.0 min). The surgery time was significantly longer in pts with SAH (P = 0.04). When unruptured aneurysms were treated, the surgery time was 207.0 min (±56.0 min). In pts with ruptured aneurysms, the mean surgery time was 223.2 min (±57.1 min).

The mean time of temporary clipping of the parent vessel was 2.8 min (median 1.3 min). When SAH was present, the mean temporary clipping time of the MCA was 3.9 min (±5.0 min) compared to 1.5 min (±2.0 min) in patients without SAH. This difference was statistically different (P = 0.002). However, multiple logistic regression analysis revealed no statistically significant difference between both groups concerning the time of temporary clipping for the development of new ischemic deficits; see Table 3(b).

3.3.2. Intraoperative Rupture. Intraoperative rupture of the aneurysm occurred in 15 patients (9.9%). Aneurysms ruptured significantly more often intraoperatively in patients with SAH (n = 14) than in patients with incidental aneurysms (n = 1). This difference was statistically significant (P = 0.003).

3.4. Outcome

3.4.1. New Ischemia Directly Postoperatively. According to Adams, the plain postoperative CT scan was accurately screened for any new ischemia [17]. A new, surgery-related ischemia was detected in 44 patients (29.1%). The discrimination between ischemia and edema was obtained by the neuroradiologists, capturing not only large and territorial infarctions, but small and rather diffuse ischemic "holes." Presumably, these small ischemic areas were due to perforator damage, as proposed by Ulm et al. [18].

Table 3: (a) Surgical difficulty: factors assessed to prognosticate intraoperative rupture in patients with ACM aneurysm ($n = 151$). Statistically significant influence of the factors was evaluated using multiple logistic regression analysis. (b) Outcome: factors assessed to prognosticate new postoperative ischemia in patients with MCA aneurysm ($n = 151$). Statistically significant influence of the factors was evaluated using multiple logistic regression analysis.

(a)

Factor	*P* value	Odds ratio	Confidence interval	
			5% Lower	95% Upper
SAH	0.001*	18.91	3.249	110.075
M2	0.008*	0.15	0.041	0.613
DBD	0.007*	1.92	1.195	3.108
Aneurysm diameter	0.022*	0.56	0.345	0.920
Vessel diameter	0.043*	0.35	0.128	0.968
Neck vessel ratio	0.907	1.03	0.615	1.729
Multi-lobated shape	0.442	0.51	0.527	4.338
Branching vessels	0.023*	23.88	1.563	364.840

(b)

Factor	*P* value	Odds ratio	Confidence interval	
			5% Lower	95% Upper
SAH	0.001*	0.184	0.094	0.360
M2	0.004*	3.48	3.484	1.483
DBD	0.031*	1.29	1.023	1.615
Aneurysm diameter	0.340	0.90	0.728	1.116
Vessel diameter	0.083	0.62	0.365	1.064
Neck diameter	0.041*	1.26	1.009	1.568
Multi-lobated shape	0.009*	2.33	1.230	4.407
Branching vessels	0.997	0.99	0.182	5.450
Temporary clipping	0.308	1.06	0.944	1.200

The neurological outcome was classified due to the Glasgow Outcome Scale (GOS); 6–8 weeks after aneurysm clipping, the GOS was assessed as follows: GOS 5 = 70 patients, GOS 4 = 26 patients, GOS 3 = 7 patients, GOS 2 = 5 patients, and GOS 1 = 8 patients. Thirty-five patients were lost to followup.

Immediately postoperatively, 10 patients developed a new transient hemiparalysis, but fully recovered during the in-hospital interval.

3.5. Multivariate Analysis: Intraoperative Rupture. Accordingly, we performed multivariate analysis for assessing independent morphological features that promoted the intraoperative rupture of the aneurysm.

The presence of subarachnoid hemorrhage, the DBD, aneurismal location on the M2 segment, presence of branching vessels, the maximum diameter of the aneurysm and the diameter of the parent vessel were independently and significantly influencing an intraoperative rupture.

However, the NVR and a multilobulated configuration of the aneurysm had no effect on the risk of intraoperative rupture.

These results are summarized in Table 3(b).

3.6. Multivariate Analysis: New Ischemia Directly Postoperatively. Multivariate analysis was employed in order to identify independent features that potentially predicted the risk for a new ischemia postoperatively (CT scan < 24 hrs).

Factors, significantly influencing the development of a surgery-related ischemia, were the presence of subarachnoid hemorrhage, aneurismal location on the M2 segment, the DBD, the NVR, and a multilobulated configuration.

The maximum diameter of the aneurysm, presence of branching vessels, and the diameter of the parent artery did not significantly influence the development of a new ischemia directly postoperatively. These findings are summarized in Table 3(a).

4. Discussion

The majority of MCA aneurysms are nongiant and localized in the M1 and/or M2 segment [3]. In selected cases, more sophisticated occlusion techniques are needed due to most complex aneurismal morphology and in consideration of the anatomical environment. Among these are interlocking tandem clipping techniques [19], in situ bypass, surgical trapping, direct suture repair [8], circulatory arrest [20], and combined surgical and endovascular occlusion [21]. However, these techniques do not represent standard procedures. Nevertheless, certain MCA aneurysms bear specific morphological features that may complicate successful simple clip ligation and may imply prolonged temporary occlusion

of the parent vessel, aiming to avoid intraoperative rupture and to allow complete aneurysm clipping [22]. Hence, the risk of postoperative neurological deterioration, as Morgan et al. appropriately denoted "surgical downgrading" [8], is significantly increased in some patients, even when incidental aneurysms are targeted.

The presence of subarachnoid hemorrhage is the most obvious characteristic that not only urges in treating the aneurysm but also impedes safe preparation and seriously affects the postoperative neurological performance [6]. Accordingly, we found an increased rate of intraoperative aneurysm rupture in patients with SAH and a statistically significantly higher rate of a new ischemia immediately postoperatively in patients with SAH compared to the non-SAH group.

Additional key features defining the complexity and challenge of MCA aneurysm repair are size, shape, location, and the related vasculature [7, 19, 21, 23].

4.1. Size. Several authors described a significantly larger size in ruptured MCA aneurysms compared to asymptomatic ones. Van Dijk et al. retrospectively reviewed 151 patients with MCA aneurysms, 77 of them with SAH. In two thirds of these patients, the aneurysm size was larger than 6 mm [3]. Güresir et al. compared some characteristics of ruptured and unruptured MCA aneurysms and found a mean diameter of 8.8 mm in the SAH group, while the group of innocent aneurysms had a significantly smaller mean size of 6.5 mm [7].

In our study, the mean size of aneurysm in the SAH group was 7.9 mm and 6.3 mm in the non-SAH group, diverging statistically significant. Moreover, when evaluating the DBD, this difference was even more obvious with 7.9 mm and 5.3 mm, respectively. Thus, it may be assumed that finger-shaped aneurysms with a larger DBD tend to be at higher risk for initial rupture compared to ballooned aneurysms.

Moreover, a finger-shaped configuration of the aneurysm demands experienced surgical skills as the flow-related pressure on the distal aneurysm wall may be dramatically higher than in ballooned aneurysms in which the blood flow is more turbulent, hence, not concentrating on a localized impingement point [24]. Some authors suggested that aneurysm formation and rupture is due to small impingement regions and narrow jets [25, 26]. Our data support this theory as the DBD was significantly associated with an increased rate of intraoperative rupture and independently promoted the development of a surgery-related ischemia.

4.2. Shape. Many authors emphasized that aneurysm rupture is frequently associated with an irregularly multilobulated shape [3, 7] and our data support these findings. In our population, we significantly more frequently detected a multilobulated shape of aneurysms in the SAH group. However, a multilobulated configuration was not associated with an increased rate of intraoperative rupture but was significantly correlated with the development of a new ischemia immediately postoperatively.

Generally, intraoperative rupture is avoided by application of a temporary clip on the proximal MCA in almost every case of an initially ruptured, multilobulated aneurysm [21, 22, 27].

Nevertheless, a multilobulated configuration independently predicted the surgical outcome. However, the subgroup analysis has not enough statistical power to reliably figure out the supposed hypothesis that a prolonged temporary clipping in case of any initially ruptured, multilobulated aneurysm, results in a new, procedure-related ischemia [22, 28].

In our series, just one patient had a fusiform aneurysm, reflecting the rareness of this feature. A fusiform shape of MCA aneurysms is described occasionally when the aneurysm is localized distally [23] or in giant-sized aneurysms [20, 21].

A broad aneurismal neck is said to be a parameter of complexity [7] and generally renders complete endovascular occlusion impossible. However, the broadness of the aneurismal neck is hard to determine. Many authors refrain from clearly defining a "broad neck" [7, 12, 13]. In our series, we quantitatively determined the neck diameter and the diameter of the parent vessel, hereby calculating the NVR (neck diameter: vessel diameter); see Figure 1, in other words, the broader the neck the larger the NVR. Effectively, a larger NVR was associated with a new, surgery-related ischemia. This may attribute to a relevant decrease of the vessel's diameter, potentially resulting in an impaired perfusion, what sometimes may not be reliably detected by Indocyanine Green angiography or by intraoperative Doppler Sonography.

4.3. Related Vasculature. The relationship to the parent and to branching vessels was repeatedly found to be predictive for the risk of rupture and for the difficulty in preparation and clipping. In their anatomical review, Ulm et al. nicely described the relevance of early frontal and temporal vessels arising from the M1 segment, adjacent to or incorporated by the aneurysm [18], and Güresir et al. found in addition to a significantly larger size of the aneurismal corpus that an incorporation of both the M1 and M2 segments is significantly more often present in ruptured MCA aneurysms [7].

In our study, aneurismal localization on the M2 segment and the presence of branching vessels were independently associated to a higher the risk of intraoperative rupture and to an increased risk for a new ischemia postoperatively.

Presumably, the preparation of the aneurysm and its environment is much more complicated, and the probability for an accidental occlusion of small branching vessels increased when both M1 and M2 have to be dissected [18].

Treatment of MCA aneurysms remains the domain of operative vascular neurosurgery. However, besides the presence of subarachnoid hemorrhage, the identification of significant morphological features of the aneurysm itself and of its direct anatomical environment is strongly influencing the surgical strategy. Our results show that the detailed angiographic evaluation preoperatively is mandatory as it provides valuable information about the complexity of the aneurysm and the difficulty level of the clipping procedure.

The key features size, dome-to-base distance, shape, and branching vessels should always be considered. Thus, "surgical downgrading" can be kept to a minimum.

5. Conclusion

In MCA aneurysms, independent predictors for the risk of rupture intraoperatively and for the postsurgical outcome are presence of SAH, location on the M2-segment, size (dome-to-base distance), and the broadness of the neck. These important morphological features are easily amenable by CT angiography and rotational angiography. Thus, preoperative standardized assessment of these morphological features is recommended.

Conflict of Interests

The authors have no conflict of interests.

References

[1] A. Molyneux, R. Kerr, I. Stratton et al., "International Subarachnoid Aneurysm Trial (ISAT) of neurosurgical clipping versus endovascular coiling in 2143 patients with ruptured intracranial aneurysms: a randomised trial," *The Lancet*, vol. 360, no. 9342, pp. 1267–1274, 2002.

[2] Y. Kato, H. Sano, P. T. Dong et al., "The effect of clipping and coiling in acute severe subarachnoid hemorrhage after international subarachnoid aneurysmal trial (ISAT) results," *Minimally Invasive Neurosurgery*, vol. 48, no. 4, pp. 224–227, 2005.

[3] J. M. van Dijk, R. J. Groen, M. ter Laan, J. R. Jeltema, J. J. Mooij, and J. D. Metzemaekers, "Surgical clipping as the preferred treatment for aneurysms of the middle cerebral artery," *Acta Neurochirurgica*, vol. 153, pp. 2111–2117, 2011.

[4] A. J. Molyneux, R. S. Kerr, J. Birks et al., "Risk of recurrent subarachnoid haemorrhage, death, or dependence and standardised mortality ratios after clipping or coiling of an intracranial aneurysm in the International Subarachnoid Aneurysm Trial (ISAT): long-term follow-up," *The Lancet Neurology*, vol. 8, no. 5, pp. 427–433, 2009.

[5] W. Brinjikji, G. Lanzino, H. J. Cloft, A. Rabinstein, and D. F. Kallmes, "Endovascular treatment of middle cerebral artery aneurysms: a systematic review and single-center series," *Neurosurgery*, vol. 68, no. 2, pp. 397–402, 2011.

[6] D. O. Bulters, T. Santarius, H. L. Chia et al., "Causes of neurological deficits following clipping of 200 consecutive ruptured aneurysms in patients with good-grade aneurysmal subarachnoid haemorrhage," *Acta Neurochirurgica*, vol. 153, no. 2, pp. 295–303, 2011.

[7] E. Güresir, P. Schuss, J. Berkefeld, H. Vatter, and V. Seifert, "Treatment results for complex middle cerebral artery aneurysms. A prospective single-center series," *Acta Neurochirurgica*, vol. 153, no. 6, pp. 1247–1252, 2011.

[8] M. K. Morgan, W. Mahattanakul, A. Davidson, and J. Reid, "Outcome for middle cerebral artery aneurysm surgery," *Neurosurgery*, vol. 67, no. 3, pp. 755–761, 2010.

[9] A. Nanda and P. S. S. V. Vannemreddy, "Surgical management of unruptured aneurysms: prognostic indicators," *Surgical Neurology*, vol. 58, no. 1, pp. 13–20, 2002.

[10] D. H. Park, S. H. Kang, J. B. Lee et al., "Angiographic features, surgical management and outcomes of proximal middle cerebral artery aneurysms," *Clinical Neurology and Neurosurgery*, vol. 110, no. 6, pp. 544–551, 2008.

[11] J. F. Vendrell, N. Menjot, V. Costalat et al., "Endovascular treatment of 174 middle cerebral artery aneurysms: clinical outcome and radiologic results at long-term follow-up," *Radiology*, vol. 253, no. 1, pp. 191–198, 2009.

[12] P. Yang, J. Liu, Q. Huang et al., "Endovascular treatment of wide-neck middle cerebral artery aneurysms with stents: a review of 16 cases," *American Journal of Neuroradiology*, vol. 31, no. 5, pp. 940–946, 2010.

[13] W. Taki, N. Sakai, and H. Suzuki, "Determinants of poor outcome after aneurysmal subarachnoid hemorrhage when both clipping and coiling are available: Prospective Registry of Subarachnoid Aneurysms Treatment (PRESAT) in Japan," *World Neurosurgery*, vol. 76, pp. 437–445, 2011.

[14] M. N. Diringer, "Management of aneurysmal subarachnoid hemorrhage," *Critical Care Medicine*, vol. 37, no. 2, pp. 432–440, 2009.

[15] J. I. Suarez, R. W. Tarr, and W. R. Selman, "Aneurysmal subarachnoid hemorrhage," *The New England Journal of Medicine*, vol. 354, no. 4, pp. 387–396, 2006.

[16] S. M. Kagerbauer, D. M. Kemptner, C. P. Schepp et al., "Elevated premorbid body mass index is not associated with poor neurological outcome in the subacute state after aneurysmal subarachnoid hemorrhage," *Zentralblatt fur Neurochirurgie*, vol. 71, no. 4, pp. 163–166, 2010.

[17] H. P. Adams Jr., N. F. Kassell, J. C. Torner, and E. C. Haley Jr., "Predicting cerebral ischemia after aneurysmal subarachnoid hemorrhage: influences of clinical condition, CT results, and antifibrinolytic therapy. A report of the cooperative aneurysm study," *Neurology*, vol. 37, no. 10, pp. 1586–1591, 1987.

[18] A. J. Ulm, G. L. Fautheree, N. Tanriover et al., "Microsurgical and angiographic anatomy of middle cerebral artery aneurysms: prevalence and significance of early branch aneurysms," *Neurosurgery*, vol. 62, no. 5, pp. ONS344–ONS352, 2008.

[19] R. E. Clatterbuck, R. M. Galler, R. J. Tamargo, and D. J. Chalif, "Orthogonal interlocking tandem clipping technique for the reconstruction of complex middle cerebral artery aneurysms," *Neurosurgery*, vol. 59, no. 4, pp. ONS-347–ONS-352, 2006.

[20] K. M. Schebesch, M. Proescholdt, O. W. Ullrich et al., "Circulatory arrest and deep hypothermia for the treatment of complex intracranial aneurysms—results from a single European center," *Acta Neurochirurgica*, vol. 152, no. 5, pp. 783–792, 2010.

[21] Z. S. Shi, J. Ziegler, G. R. Duckwiler et al., "Management of giant middle cerebral artery aneurysms with incorporated branches: partial endovascular coiling or combined extracranial-intracranial bypass—a team approach," *Neurosurgery*, vol. 65, no. 6, pp. 121–131, 2009.

[22] C. Woertgen, R. D. Rothoerl, R. Albert, K. M. Schebesch, and O. W. Ullrich, "Effects of temporary clipping during aneurysm surgery," *Neurological Research*, vol. 30, no. 5, pp. 542–546, 2008.

[23] S. P. Joo, T. S. Kim, J. W. Choi et al., "Characteristics and management of ruptured distal middle cerebral artery aneurysms," *Acta Neurochirurgica*, vol. 149, no. 7, pp. 661–667, 2007.

[24] Y. Hoi, H. Meng, S. H. Woodward et al., "Effects of arterial geometry on aneurysm growth: three-dimensional computational fluid dynamics study," *Journal of Neurosurgery*, vol. 101, no. 4, pp. 676–681, 2004.

[25] J. R. Cebral, M. A. Castro, J. E. Burgess, R. S. Pergolizzi, M. J. Sheridan, and C. M. Putman, "Characterization of cerebral

aneurysms for assessing risk of rupture by using patient-specific computational hemodynamics models," *American Journal of Neuroradiology*, vol. 26, no. 10, pp. 2550–2559, 2005.

[26] J. R. Cebral, S. Hendrickson, and C. M. Putman, "Hemodynamics in a lethal basilar artery aneurysm just before its rupture," *American Journal of Neuroradiology*, vol. 30, no. 1, pp. 95–98, 2009.

[27] T. Haug, A. Sorteberg, W. Sorteberg, K. F. Lindegaard, T. Lundar, and A. Finset, "Surgical repair of unruptured and ruptured middle cerebral artery aneurysms: impact on cognitive functioning and health-related quality of life," *Neurosurgery*, vol. 64, no. 3, pp. 412–422, 2009.

[28] A. Cerejo, P. A. Silva, C. Dias, and R. Vaz, "Monitoring of brain oxygenation in surgery of ruptured middle cerebral artery aneurysms," *Surgical Neurology International*, vol. 2, article 70, 2011.