Hindawi Publishing Corporation
ISRN Pulmonology
Volume 2014, Article ID 692590, 3 pages
http://dx.doi.org/10.1155/2014/692590

Clinical Study

Carinal Resection and Reconstruction for Locally Advanced Primary Lung Cancer: Institutional Report

Yuji Matsumura,[1] Muneo Minowa,[1] Osamu Araki,[2] Yoko Karube,[2] and Masayuki Chida[2]

[1] *Department of Chest Surgery, Ohta-Nishinouchi Hospital, 2-5-20 Nishinouchi, Koriyama, Fukushima 963-8558, Japan*
[2] *Department of General Thoracic Surgery, Dokkyo Medical University, 880 Kitakobayashi, Mibu, Tochigi 321-0293, Japan*

Correspondence should be addressed to Yuji Matsumura; y-matsu@ohta-hp.or.jp

Received 17 December 2013; Accepted 6 February 2014; Published 6 March 2014

Academic Editors: C. Brambilla and M. Nosotti

Carinal resection and reconstruction for lung cancer, termed carinaplasty, is a rare operation, and the procedure remains challenging and few reports have been presented. We analyzed complications, local control, and manner of recurrence in patients who underwent a carinaplasty and compared the results to those who underwent an ordinary bronchoplasty. Among 766 patients who underwent surgery for primary lung cancer at our institutions, 82 bronchoplasty procedures were performed, while 6 of those who received a bronchoplasty underwent a carinaplasty. Three of 6 patients who received a carinaplasty underwent the montage method, and other 3 patients underwent the one-stoma method. There were no operative deaths in patients who underwent a carinaplasty, while there was 1 operative death in the group of patients who underwent an ordinary bronchoplasty. Complications in the anastomotic site were observed in 33% in the carinaplasty group and 5.3% in the ordinary bronchoplasty group ($P = 0.011$). There was no significant difference in regard to local recurrence between the groups ($P = 0.620$). In conclusion, our results show that a carinaplasty is a technically demanding but useful procedure to avoid a pneumonectomy in patients with locally advanced lung cancer.

1. Introduction

Carinal resection and reconstruction for lung cancer, termed carinaplasty, is a rare operation in the field of thoracic surgery. In Japan, only about 10 carinaplasty procedures are performed each year, while over 30,000 surgeries have been done annually for lung cancer in the past decade [1, 2]. The first carinaplasty procedure was reported by Barclay et al. [3] in 1957 for a lung tumor using an end-to-side anastomosis technique, the so-called montage method. Thereafter in 1966, Mathey et al. [4] reported the double-barrel technique. Presently, carinaplasty procedures are performed using 3 different techniques, the montage, double-barrel, and one-stoma methods. However, the procedure remains challenging and few reports have been presented. In this study, we analyzed complications, local control, and manner of recurrence in patients who underwent a carinaplasty and compared the results to those who underwent an ordinary bronchoplasty.

2. Subjects and Methods

Patients with primary lung cancer who underwent a carinaplasty or ordinary bronchoplasty at our institutions from June 2002 to December 2012 were retrospectively investigated. Each one provided the consent to undergo the respective procedure. An affiliated ethics committee approved this retrospective study and waived the need for patient consent for analysis of the results.

All patients who met the indications provided by cardiopulmonary function tests underwent surgery. In this series, patient selection for a carinaplasty was dependent on the balance between the extent of cancer and technical difficulty. Patients considered able to tolerate a sleeve pneumonectomy were also considered to be candidates for a carinaplasty.

An end-to-end anastomosis was performed in both the carinaplasty and ordinary bronchoplasty cases with a telescope technique using interrupted sutures with full-thickness

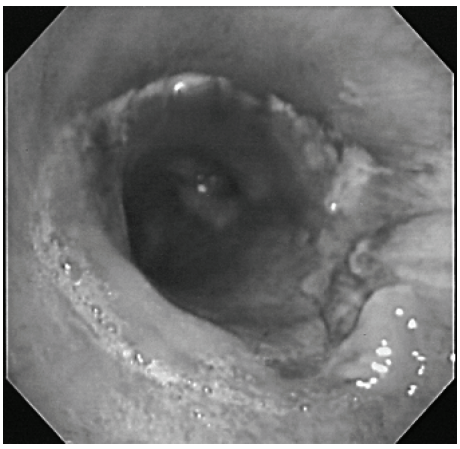

Figure 1: Representative bronchofiberscope view of a new bifurcation end-to-end anastomosis between trachea and left main bronchus and end-to-side anastomosis between left main bronchus and right basal bronchus.

bites and 3-0 or 4-0 monofilament absorbable materials. In addition, an appropriately sized ostium for the anastomosis was created on the right sidewall of the trachea or left main bronchus by a scalpel. When necessary, an angioplasty was performed using continuous sutures with 4-0 or 5-0 monofilament materials. We used an interposition of vascularized soft tissue to separate and protect the suture line between the bronchoplasty and angioplasty in some cases. One week after the operation, a bronchoscopic examination was conducted to observe the status of the anastomosis. When ischemic change at the site was observed, 120 μg of prostaglandin E1 was intravenously infused daily for 2 weeks to induce angiogenesis in the ischemic tissue [5].

Complications, local control, and recurrence were retrospectively analyzed. Statistical analysis was performed using a chi-square test for comparison of variables and differences were considered significant at $P < 0.05$.

3. Results

Among 766 patients who underwent surgery for primary lung cancer at our institutions, 82 bronchoplasty procedures were performed, while 6 of those who received a bronchoplasty underwent a carinal resection and reconstruction (Table 1). Two of 3 patients who underwent the montage method had the right upper bronchus anastomosed to the trachea, while the other underwent an anastomosis of the right basal bronchus to the left main bronchus (Figure 1). All 3 of those patients underwent a pulmonary arterioplasty, and 2 needed a pulmonary venoplasty and/or left atrial resection. Three patients who underwent the one-stoma method received a right upper sleeve lobectomy and carina resection, with the bronchus intermedius anastomosed to the carina. One of those patients who underwent an angioplasty and all 3 received a U-shaped incision in the pericardium to release the inferior pulmonary vein for distension of the anastomosis.

Table 1: Characteristics of patients in carinaplasty group.

Case number	Age/sex	Cell type	Lung resection	Induction therapy	Operation time
			Montage method		
1	63/F	AC	RMLL	(−)	6:01
2	56/M	AC	RUMS6	(−)	6:32
3	61/F	SCC	RMLL	CT	6:52
			One-stoma method		
4	72/M	SCC	RUL	CT	4:47
5	72/M	SCC	RUL	(−)	4:49
6	74/M	SCC	RUL	(−)	5:24

AC: adenocarcinoma; SCC: squamous cell carcinoma; RMLL: right middle lower lobectomy; RUMS6: right upper middle lobectomy and S6 segmentectomy; RUL: right upper lobectomy; CT: chemotherapy.

Table 2: Incidence of anastomotic complications.

	Number of complications		Total
	+	−	
Carinaplasty	2	4	6
Ordinary bronchoplasty	4	72	76

There were no operative deaths within 30 days or any hospital deaths in patients who underwent a carinaplasty, while there was 1 operative death within 30 days in the group of patients who underwent an ordinary bronchoplasty. Complications in the anastomotic site were observed in 33% in the carinaplasty group and 5.3% in the ordinary bronchoplasty group (Table 2), which was significantly different ($P = 0.011$). In 1 patient (case number 3), who underwent a montage carinaplasty after 2 courses of induction chemotherapy with carboplatin + paclitaxel, a bronchial stricture occurred as a result of anastomotic dehiscence because of excessive tension between the right upper bronchus and trachea. However, bronchoscopic ballooning and stent prosthesis achieved patency of the bronchus at the stenotic site. In another patient (case number 6), who underwent a one-stoma carinaplasty, dehiscence of the anastomotic site resulted in hemoptysis and an emergency operation was undertaken to perform a completion pneumonectomy. Of the anastomotic complications in the ordinary bronchoplasty group ($n = 4$), 2 were dehiscence and 2 hemoptysis.

Two of the 6 who underwent a carinaplasty had recurrence, which was neck lymph node metastasis in both, while no local recurrence was noted at the site of the anastomosis. These patients died at 13 and 21 months after the operation, respectively. One patient who underwent a completion pneumonectomy died without recurrence at 35 months after the operation due to chronic respiratory failure. Three of 76 patients who underwent an ordinary bronchoscopy had local recurrence at the anastomotic site. There was no significant difference in regard to local recurrence between the groups ($P = 0.620$).

4. Discussion

When considering surgery for selected patients with locally advanced lung cancer, it is important to note that the choice of procedure must take into account an appropriate balance between mortality risk and local control. Although the risk of operative mortality for a pneumonectomy is considered to be much greater than that for a sleeve lobectomy [6–12], long-term survival for both is similar at each stage. Thus, a pneumonectomy may not always be the best choice and, when technically possible, a carinaplasty is a viable alternate procedure for locally advanced lung cancer to avoid a pneumonectomy. In the present series of patients, we found that a carinaplasty was useful for locally advanced lung cancer, though more technically demanding than an ordinary sleeve lobectomy.

Some authors [6, 7, 9, 11–13] have reported rates of complications in the anastomotic site ranging from 3.3 to 16.3% after an ordinary sleeve lobectomy. In this investigation, complications in the anastomotic site occurred in 33% (2/6) of patients who underwent a carinaplasty. In case number 3, in which the montage method was performed, a bronchial stricture occurred due to anastomotic dehiscence, because of excessive tension between the right upper bronchus and trachea. In case number 6 with the one-stoma method, anastomotic dehiscence occurred due to ischemia of the distal bronchus. The technique used for this procedure is more demanding than that for an ordinary sleeve lobectomy, since tension between the stumps for an anastomosis is strong. Case number 3 required a metallic stent prosthesis and the resident lung has remained in good condition for more than 4 years, while case number 6 underwent a completion pneumonectomy. We found that 66% of our patients who underwent a carinaplasty required an accompanying pulmonary angioplasty procedure. However, there were no operative deaths in the carinaplasty group despite the higher rate of complications. Thus, we concluded that a carinaplasty is a reasonable choice for locally advanced lung cancer.

Three (3.9%) of the 76 patients in the ordinary sleeve lobectomy group and 0 of the 6 in the carinaplasty group had local control failure. In other reports that compared between a sleeve lobectomy and pneumonectomy, the rates of local relapse were 11.0% and 6.6%, respectively [8, 10, 11]. Thus, local control in patients who undergo a carinaplasty does not seem to be inferior to that in those who undergo an ordinary sleeve lobectomy or pneumonectomy.

5. Conclusion

Our results show that a carinaplasty is a technically demanding but useful procedure to avoid a pneumonectomy in patients with locally advanced lung cancer.

Conflict of Interests

The authors declare that there is no conflict of interests regarding the publication of this paper.

References

[1] H. Kuwano, J. Amano, and H. Yokomise, "Thoracic and cardiovascular surgery in Japan during 2010," *General Thoracic and Cardiovascular Surgery*, vol. 60, no. 10, pp. 680–708, 2012.

[2] J. Amano, H. Kuwano, and H. Yokomise, "Thoracic and cardiovascular surgery in Japan during 2011," *General Thoracic and Cardiovascular Surgery*, vol. 61, no. 10, pp. 578–607, 2013.

[3] R. S. Barclay, N. McSwan, and T. M. Welsh, "Tracheal reconstruction without the use of grafts," *Thorax*, vol. 12, no. 3, pp. 177–180, 1957.

[4] J. Mathey, J. P. Binet, J. J. Galey, C. Evrard, G. Lemoine, and B. Denis, "Tracheal and tracheobronchial resections; technique and results in 20 cases," *The Journal of Thoracic and Cardiovascular Surgery*, vol. 51, no. 1, pp. 1–13, 1966.

[5] D. Moreschi Jr., D. J. Fagundes, L. Hernandes, and E. F. Haapalainen, "Effects of prostaglandin E_1 in the genesis of blood capillaries in the ischemic skeletal muscle of rats: ultrastructural analysis," *Annals of Vascular Surgery*, vol. 22, no. 1, pp. 121–126, 2008.

[6] H. A. Gaissert, D. J. Mathisen, A. C. Moncure, A. D. Hilgenberg, H. C. Grillo, and J. C. Wain, "Survival and function after sleeve lobectomy for lung cancer," *The Journal of Thoracic and Cardiovascular Surgery*, vol. 111, no. 5, pp. 948–953, 1996.

[7] H.-C. Suen, B. F. Meyers, T. Guthrie et al., "Favorable results after sleeve lobectomy or bronchoplasty for bronchial malignancies," *The Annals of Thoracic Surgery*, vol. 67, no. 6, pp. 1557–1562, 1999.

[8] M. Okada, H. Yamagishi, S. Satake et al., "Survival related to lymph node involvement in lung cancer after sleeve lobectomy compared with pneumonectomy," *The Journal of Thoracic and Cardiovascular Surgery*, vol. 119, no. 4, part 1, pp. 814–819, 2000.

[9] J. Deslauriers, J. Grégoire, L. F. Jacques, M. Piraux, L. Guojin, and Y. Lacasse, "Sleeve lobectomy versus pneumonectomy for lung cancer: a comparative analysis of survival and sites or recurrences," *The Annals of Thoracic Surgery*, vol. 77, no. 4, pp. 1152–1156, 2004.

[10] P. Bagan, P. Berna, J. C. D. N. Pereira et al., "Sleeve lobectomy versus pneumonectomy: tumor characteristics and comparative analysis of feasibility and results," *The Annals of Thoracic Surgery*, vol. 80, no. 6, pp. 2046–2050, 2005.

[11] Y. T. Kim, C. H. Kang, S. W. Sung et al., "Local control of disease related to lymph node involvement in non-small cell lung cancer after sleeve lobectomy compared with pneumonectomy," *The Annals of Thoracic Surgery*, vol. 79, no. 4, pp. 1153–1161, 2005.

[12] C. Ludwig, E. Stoelben, M. Olschewski, and J. Hasse, "Comparison of morbidity, 30-day mortality, and long-term survival after pneumonectomy and sleeve lobectomy for non-small cell lung carcinoma," *The Annals of Thoracic Surgery*, vol. 79, no. 3, pp. 968–973, 2005.

[13] M. Krüger, K. Uschinsky, K. Hässler, and C. Engelmann, "Postoperative complications after bronchoplastic procedures in the treatment of bronchial malignancies," *European Journal of Cardio-Thoracic Surgery*, vol. 14, no. 1, pp. 46–53, 1998.