Hindawi Publishing Corporation
Advances in Orthopedic Surgery
Volume 2014, Article ID 814156, 7 pages
http://dx.doi.org/10.1155/2014/814156

Clinical Study

Clinical and Radiographic Evaluation of a Commercially Pure Cancellous-Structured Titanium Press Fit Total Hip Prosthetic Stem: Ten-Year Followup of the "Natural Hip" Femoral Stem

Thomas B. Pace,[1,2] James C. Karegeannes,[3] M. Jason Palmer,[1] Stephanie L. Tanner,[1] and Rebecca G. Snider[1]

[1] *Greenville Health System Department of Orthopaedics, 701 Grove Road, Greenville, SC 29605, USA*
[2] *University of South Carolina SOM, Greenville Health System, P.O. Box 27114, Greenville, SC 29616, USA*
[3] *Blue Ridge Bone and Joint, 129 McDowell Street, Asheville, NC 28801, USA*

Correspondence should be addressed to Thomas B. Pace; tpacemd@aol.com

Received 8 October 2013; Revised 20 November 2013; Accepted 21 November 2013; Published 27 January 2014

Academic Editor: Neal L. Millar

This study evaluates the outcomes of 92 hip arthroplasties using a press fit, tapered, split tip, proximally porous ingrowth (CSTi) femoral stem (Zimmer Natural Hip) in consecutive hip arthroplasty patients followed for an average of ten years postoperatively (range 5–16 years). Patients were functionally and radiographically evaluated using Harris Hip Scores and plain radiographs assessing postarthroplasty groin or thigh pain and radiographic signs of stem subsidence, proximal femoral fixation, stress shielding, and related calcar resorption. At followup of 5–10 years, the incidence of groin pain and thigh pain was 9.1% and 3.6%, respectively. This incidence improved over time. Beyond 10 years of followup, groin pain was 2.7% and thigh pain zero. In 89% of cases, there was solid contact between the calcar and the undersurface of the stem collar. Five cases were revised for instability (5.4%). The Harris Hip Scores and the incidence of thigh or groin pain were very favorable compared to other reported press fit total hip arthroplasty stems and not significantly different across a broad age range. There were no cases of stem loosening of failure of bony ingrowth into the stem.

1. Introduction

Femoral component fixation in total hip arthroplasty by bone ingrowth evolved in response to loosening observed from cemented stems [1]. The goal of press fit femoral stem fixation is to obtain biologic fixation of the implant, and thereby a more durable implant to bone interlocking interface less likely to succumb to stress over time and osteoporotic geriatric femoral canal enlargement. Porous-coated acetabular components have performed well [2] and have become the standard implant for the majority of hip arthroplasty procedures in North America. Reports of early femoral stem designs raised concerns of proximal bone resorption, thigh pain from cylindrical cobalt chrome stems, and difficult revision surgery secondary to proximal femoral stress shielding associated with extensive ingrowth at the diaphyseal bone interface with the stem. A slightly roughened finish may not allow sufficient fixation for stem stability [3]. Noncircumferentially applied ingrowth surface allows particulate debris to enter the femoral canal leading to significant osteolysis of the femoral shaft [4]. Circumferentially applied ingrowth surface seals the canal from wear debris and decreases osteolysis within the canal [1, 5, 6]. Insufficient proximal ingrowth surface, even if applied circumferentially, also leads to early failure from inadequate fixation [7]. Proximal cortical atrophy may occur in response to stress shielding proximal to the region of bone ingrowth. Greater bone loss has been observed with implants that obtain fixation within the diaphysis [8, 9] compared with proximal fixation implants [10–12]. A medial collar further decreased the incidence of proximal medial cortex resorption [12]. Thigh pain, caused by the sharp elastic modulus transition from the rigid stem to the more flexible cortical bone [13], has been reported in up to 12–27 percent of patients after cementless arthroplasty

[6, 9, 14]. The rate of thigh pain has been reported as less than 10 percent in designs with a tapered [11, 15, 16] or slotted [17] distal stem.

The use of press fit total hip stems in various age groups has been reported to offer more benefits in younger patients [18] with increased incidence of thigh pain and or groin pain as well as aseptic loosening in patients over 75 years old.

The Natural Hip femoral stem (Zimmer, Warsaw, IN, USA) has been in clinical use since 1993. The midterm 4–8-year clinical results of this stem have reportedly been very successful [19]. This stem is a tapered, split tip, proximal ingrowth collared monolithic, titanium alloy component with an inset circumferential flush finish of commercially pure cancellous-structured titanium (CSTi) proximal to and under the collar. It has a 12-degree anteverted neck and tapered threaded 12/14 trunnion that accepts a modular head of either cobalt chrome or ceramic (see Figures 2, 3, and 4). The proximal metaphyseal region of the stem has a 4 mm anterior wedge shape built up to maximize proximal fit and fill for improved postsurgical rotational stability. The body is a straight stem tapered proximally and distally with a distal stem split in the coronal plane with 2 mm fins to lower the elastic modulus while allowing some distal canal rotational control. The spilt tip and fins are designed to expand to engage in osteoporotic Type C diaphyseal bone and press together in more dense Type A diaphyseal bone, thus allowing for sufficient fixation in both young and geriatric femurs. The distal two-thirds of the straight stem is grit blasted to provide a roughened metallic surface for bony "ongrowth" but not porous enough to allow bony ingrowth and thus potentially minimize the risk of proximal femur stress shielding, implant loosening, and subsequent clinical failure reported with some full stem ingrowth implant designs.

The goal of this retrospective case series is to evaluate both the intermediate clinical outcomes and the effectiveness of bony ingrowth stem fixation following implantation of the cementless Natural Hip stem in a consecutive THA series of older and younger osteoarthritic patients (age range 30–83) over a 5–16-year experience with a mean followup of 10 years.

2. Materials and Methods

Institutional Review Board approval was obtained for this study.

Serial office radiographs and clinical notes were retrospectively reviewed for 92 primary total hip and bipolar arthroplasties in 84 patients. All surgeries were performed from 1993 to 2000 using the Natural Hip uncemented femoral stem. Preoperative and postoperative clinical hip scores and radiographs were reviewed for all 84 patients.

The indication for hip arthroplasty was osteoarthritis in all patients. There were 48 female cases and 44 male cases with an average age at surgery of 61 years (24–86 years). Figure 1 shows patient's age distribution and percentages of males and females within each age range.

Surgery was performed by the senior author (TBP) using a posterolateral approach. The decision to use a cementless stem was based on intraoperative trial stem stability.

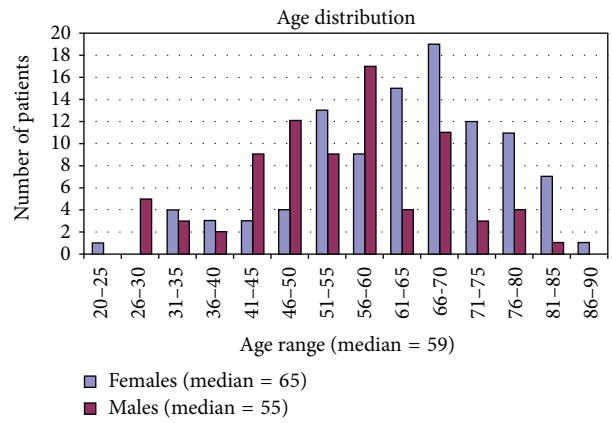

Figure 1

Figure 2: Natural Hip femoral stem.

Once the final broach was seated, torsional stability was assessed by applying a manual force to the broach handle. Lack of motion of the broach with enough torque force to rotate of the surgery extremity was interpreted as evidence for adequate bone quality and stem fixation to receive an uncemented stem.

The Sulzermedica (Zimmer) APR press fit acetabular component was used in 29 hips early in the series and the Sulzermedica (Zimmer) Intra-Op press fit cup was used in 63 hips later in the series. Of the total hip arthroplasties, cobalt chrome 28 mm heads were used in 41 hips, cobalt chrome 32 mm heads were used in 2 hips, and cobalt chrome 38 mm heads in 2 hips, Metasul (metal on metal) 28 mm heads were used in 12 hips, ceramic 28 mm heads in 34 hips, and one hip had a 32 mm ceramic head. Ceramic heads were used in younger patients, or those deemed by the senior author to be more physically active. Ten hips had a ceramic-zirconium 28 mm head. The duration of followup for each type of femoral head is described in Table 1.

Postoperative rehabilitation included weight bearing as tolerated with walker support for 3–6 weeks. Venous thrombosis event (VTE) prophylaxis was based on individualized

Figure 3: Natural Hip femoral stem, tapered split tip design.

Figure 4: Natural Hip femoral stem circumferentially CSTi.

Table 1: Femoral head type and clinical follow-up time.

	≤10 years	>10 years	Total
Ceramic heads	14	21	35
	25.5%	56.8%	38%
Cobalt chrome heads	29	16	45
	53%	43%	48.9%
Metal on metal heads	12	0	12
	21.8%	0.0%	13%

patient risk assessment. For the standard at risk patient, this included oral warfarin 5 mg daily starting from the night of surgery until the prothrombin time was 15 seconds or until the INR (international normalized ratio) was 1.2 or greater, at which time the warfarin dosage was reduced to 2 mg daily. This was continued as has previously been reported for 4 weeks as a 2 mg per day mini fixed dose oral warfarin regimen [20]. For the patient without a higher VTE or bleeding risk assessment, once the hospital prothrombin time reached 15 seconds or INR levels reached 1.2–2.0, postdischarge monitoring was not done unless signs or symptoms of bleeding occurred [21]. For higher-risk VTE patients, higher-dose monitored oral warfarin was used (prothrombin time of 18–20 seconds or INR range 2.0–2.5). Early in the series, the hospital used a prothrombin time-based laboratory system (based on patients bleeding to clotting time in seconds verses a control) and later in the series the hospital converted to an INR-based bleeding time reporting system. All patients were counseled to avoid dislocation-prone lower extremity positioning of surgical leg internal rotation, adduction and maintain <90 hip flexion for 12 weeks following surgery.

Outcome data was collected at follow-up office visits by the senior author using the Harris Hip Scores (HHS) [22]. The score was recorded before surgery for all patients and at standard follow-up intervals after surgery of three, six, and twelve months, and then annually. The presence or absence of thigh or groin pain was determined from the Harris Hip Score functional assessment record.

Anteroposterior radiographs of the hip and pelvis and a Lowenstein lateral radiograph of the hip were obtained at each follow-up visit and compared with the immediate postoperative radiographs. Acetabular components were evaluated for radiolucent lines and osteolytic areas in the regions described by DeLee and Charnley [23]. The femoral components were evaluated for radiolucent lines and osteolytic areas described by Gruen et al. [24] and Johnston et al. [25]. Calcar round-off (defined as resorption of calcar bone back to the junction of collar and stem in zone VII) was also recorded. Erosion under the collar was defined as radiographic bone loss between 2 and 10 mm extending distally from the junction of the collar and stem. Calcar bone loss greater than 10 mm was considered structurally significant osteolysis. Stem subsidence was determined by measuring the distance from the proximal tip of the greater trochanter to the lateral shoulder of the prosthesis on successive radiographs [26]. This measurement was corrected for magnification using the known diameter of the prosthetic head to its measured diameter on the radiograph [27]. A change of 2 mm or more was considered evidence of subsidence. Heterotopic bone formation was evaluated at the second year following surgery and classified by the method of Brooker et al. [28].

The results were analyzed for the group as a whole based on longevity of followup (5–10 years and >10 years) and also evaluated based on patient's age at the time of arthroplasty (<55 years, 55–75 years, and >75 years).

3. Clinical Results

3.1. Harris Hip Scores (HHS). The average preoperative HHS score was 68 (range 58–87). At an average of 10-year followup (range 5–16 years), the HHS score average was 99 (range 70–100) (Table 2).

3.2. Groin/Thigh Pain. Six patients (6.5%) reported groin pain at final followup (average 9.2 years, range 6–11 years). Two patients (2.2%) reported thigh pain at final followup (average 8.4 years, range 7–10 years) (Table 2).

Complications including dislocations and revisions are shown in Table 3. Nine cases sustained a dislocation (9.8%). Four hips had isolated dislocations that remained stable after closed reduction and one was the only anterior dislocation in the series. Five hips (5.4%) had persistent instability that required cup revision surgery. Stability was restored in each of these cases using constrained liners and without any stem exchanges.

Table 2: Natural Hip clinical data compared by time of followup.

	5–10 years	>10 years	Total
Total cases	55	37	92
Average age	63	58	61
Range	31–83	30–82	30–83
Average Pre-op HHS	68	69	68
Range	58–87	58–87	58–87
Average HHS at last f/up	99	99	99
Range	93–100	70–100	70–100
Groin pain	5	1	6
	9.1%	2.7%	6.5%
Thigh pain	2	0	2
	3.6%	0%	2.2%

Table 3: Complications.

	5–10 years	>10 years	Total
Total cases	55	37	92
Infections	0	1	1
	0.0%	2.7%	1.1%
Dislocations	5	4	9
	9.1%	10.8%	9.8%
Revisions	3	2	5
	5.5%	5.4%	5.4%
Major bleeding	3	0	3
Symptomatic DVT	0	0	0
Symptomatic PE	0	0	0

3.3. Infection. Infection occurred in 1 case. The patient elected not to have additional surgery for personal/religious reasons and is currently being treated with suppressive therapy 12 years postoperatively with retained implants and oral antibiotic therapy successfully without cup or stem loosening.

3.4. Major Bleeding. Three cases had postsurgical wound hematomas that required surgical evacuation within 3 weeks of arthroplasty surgery. One resulted in the single infection report in this series. Each of these three cases was on chronic warfarin daily therapy prior to hip arthroplasty for stroke or heart valve related conditions and their postdischarge INR times were kept in the 2.0–2.5 range.

3.5. Intraoperative Complications. One (1%) intraoperative calcar fractures occurred while seating the press fit stem in a male patient 30 years of age. It was appreciated at the time of femoral stem insertion and treated with immediate femoral neck cerclage wiring at the time of primary hip arthroplasty. The patient was restricted to touch down weight bearing for 6 weeks and healed uneventfully. There were no postoperative periprosthetic fractures.

4. Radiographic Results

There were no cases of stem subsidence and one case of acetabular osteolysis. The incidence of proximal calcar resorption, osteolysis, and polyethylene wear as occurred over time is shown in Table 4.

Table 4: Natural Hip radiographic data points compared by time of followup.

	5–10 years	>10 years	Total
Total	55	37	92
Calcar contact	52	30	82
	94.5%	81.2%	89.2%
Calcar round-off	0	3	3
	0.0%	8%	3.3%
Calcar erosion	3	4	7
(>5 mm)	5.5%	10.8%	7.6%
Polywear			
1-2 mm	1	13	14
	1.8%	35.1%	15.2%
2-3 mm	0	4	4
	0.0%	10.8%	4.3%
3-4 mm	1	1	2
	2%	2.7%	2.2%
Osteolysis	0	1	1
	0.0%	2.7%	1.1%

Figure 5: Radiograph of solid contact between the calcar and the cancellous-structured titanium under surface of the collar.

Eighty-two cases (89%) appeared to have solid contact between the calcar and the cancellous-structured titanium under surface of the collar. Of the 37 cases with beyond 10 years of followup, 30 (81%) had apparent calcar-collar bone contact (see Figure 5). Three of the hips (3.3%) had calcar bone "round-off" to the junction of the collar and stem (see Figure 6). Seven hips (7.6%) had 5–10 mm of focal subcollar calcar erosion of the Gruen zone VII (see Figure 7). Slowly progressive periprosthetic femoral radiolucent lines in Gruen zones I and VII were present in the one infected hip treated with suppressive antibiotic therapy. One case which also has 3-4 mm of polyethylene linear wear had focal osteolysis of the acetabular cup 16 years postoperatively.

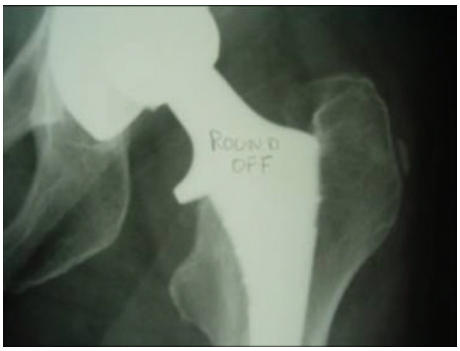

Figure 6: Radiograph showing calcar bone round-off to the junction of the collar and stem.

Table 5: Patient's age at time of surgery.

	<55 years $N = 27$	55–75 years $N = 56$	>75 years $N = 9$
Groin pain	3	5	1
Thigh pain	4	0	0
Avg. pre-op HHS (range)	68 (58–76)	68 (58–87)	68 (58–87)
Avg. pos-top HHS (range)	97.6 (95–100)	96 (95–100)	96 (76–100)

Heterotopic bone was found in 2 patients. The average followup for these patients was 10 years (range 8–12 years). One was Grade II, and 1 was Grade III as defined by Brooker et al. [28] and remained stable and asymptomatic at subsequent follow-up visits.

When the clinical results of this hip stem design were assessed relative to the age of patients at the time of arthroplasty, the pre-op and post-op follow-up HHS did not differ significantly (Table 5).

5. Discussion

This tapered, titanium, collared, split tip, proximally porous ingrowth, uncemented femoral stem design appears to address many of the historic concerns of cementless femoral stems in THA, namely, thigh pain in the early years, proximal femoral bone atrophy, and revision difficulty associated with diaphyseal press fit stem removal. The stem design worked equally well in both older and younger patients.

The presence of thigh pain in only two patients is consistent with literature reports of tapered, press fit, titanium stems. The lower modulus of titanium and slotted tip design that improve the transition from stem to host bone are thought to be the cause for the lower incidence of thigh pain.

One interesting feature of this stem design is the cancellous-structured titanium recessed ingrowth surface underneath the collar that contacts the calcar with full seating of the implant at the time of surgery. The finding that 89% of the patients in this series had apparent direct bone contact with the porous ingrowth surface under the collar suggests that a functional physiologic load is being applied

Figure 7: Radiograph of subcollar calcar erosion of Gruen zone VII.

through the collar and maintaining sufficient stress forces to avoid calcar bone regression. Furthermore, the finding that this pattern continued in 82% of the cases with beyond 10 years of followup suggests the physiological load sharing does not diminish over time. This coupled with the lack of any stem subsidence may indicate a favorable biomechanical load sharing construct of this stem design that minimizes proximal femur stress shielding. The 3% incidence of calcar round-off is significantly lower than other reports of up to 30% calcar round-off seen in other well functioning collarless press fit stem designs [29, 30].

The 10.8% incidence of nonstructural osteolysis referred to as erosion under the stem collar in the hips with 10 years or greater followup is lower than the rates reported with other bone ingrowth femoral stem designs [10, 12]. The limited osteolysis was felt to represent remote site osteolytic reaction secondary to polyethylene wear from the cup articulating surface. The fact that at 10 years 10.8% of the cases had subcalcar erosion suggests that the collar has some protective effect to seal of the medial calcar to polyethylene wear debris related osteolysis. The absence of femoral canal osteolysis and endosteal cavitation may indicate that the circumferential proximal bony ingrowth effectively seals the canal from wear debris as side from the focal subcalcar area.

One surgeon performed all arthroplasties utilizing the same stem insertion technique, which minimized intraoperative variables and is a potential strength of this study. The operating surgeon also performed all followups, including radiographic and Harris Hip Score assessment at the time of followup. This is a study weakness due to potential bias of the surgeon as some follow-up data is subjective. The stem function in this series is compared to the same stem results reported in another series [19] and functioned very similar to some cup impingement issues but otherwise low rates of failure related to stem loosening or thigh pain. What this paper contributes to the orthopaedic literature is the results of this press fit tapered stem not only in longitudinal followup but also across a wide spectrum of patient ages. While asymptomatic VTE was not reported here, the low incidence

of symptomatic VTE is consistent with previous reports of good results utilizing a low or fixed 2 mg dose of oral warfarin program and consistent with current AAOS Clinical Guidelines for the Prevention of Symptomatic Pulmonary Embolism in Patients Undergoing Total Hip or Knee [29–31].

The overall dislocation rate of 9.8% and recurrent dislocation incidence of 5.4% are higher than those reported for primary hip arthroplasty. The significance of this is not clear from this study data. Possibilities include variations in acetabular cup positioning. All of the recurrent dislocations had 28 mm heads with some degree of linear polyethylene wear. Of the five dislocation cases that required revision surgery with subsequent stability, none of the cases exceeded 55 degrees of lateral inclination as measured on AP radiographs. The femoral neck geometry (12/14 taper) with 12 degrees of ante-version may predispose to impingement related instability. Hofmann reported midterm results of this femoral stem design with a 2.4% incidence of cup problems with two cases of polyethylene liner dislodgement [19]. This raises the question of a possible neck-cup-impingement-prone design issue. In the present series, the subsequent stability following closed reduction in the four hips with single instability episodes would suggest that isolated leg and body positioning was the primary factor leading to instability.

6. Conclusion

This hip stem design appears to function well with a variety of different femoral head types and was well tolerated across a broad age range of patients. This current 5–16-year report confirms the successful 4–8-year mid-term fixation results of the same stem design previously published. The clinical results of the stem fixation as reflected in HHS at the last clinical assessment showed equal results in all three age groups, all with excellent results. The clinical results did not deteriorate over time. The presence of the low profile collar appears to have some physiological effect on both loading the calcar and sealing the canal from debris related osteolysis. The findings from the current study show a rate of instability higher than expected and the reason for this is not clear. The minimal incidence of thigh and groin pain as well as the structural integrity of the proximal femoral bony ingrowth with limited calcar resorption suggests functional load sharing implant biomechanics with this tapered titanium split tip collared proximal (CSTi) press fit design at midterm followup.

Conflict of Interests

The authors declare that there is no conflict of interests regarding the publication of this paper.

Acknowledgments

The authors wish to thank Ms. Sandy Fowler and Mrs. Katharine A. Pace for their valuable contributions to the paper and data preparation.

References

[1] D. S. Hungerford and L. C. Jones, "The rationale for cementless total hip replacement," *Orthopedic Clinics of North America*, vol. 24, no. 4, pp. 617–626, 1993.

[2] J. C. Clohisy and W. H. Harris, "The Harris-Galante porous-coated acetabular component with screw fixation. An average ten-year follow-up study," *Journal of Bone and Joint Surgery A*, vol. 81, no. 1, pp. 66–73, 1999.

[3] W. J. Donnelly, A. Kobayashi, M. A. R. Freeman et al., "Radiological and survival comparison of four methods of fixation of a proximal femoral stem," *Journal of Bone and Joint Surgery B*, vol. 79, no. 3, pp. 351–360, 1997.

[4] W. J. Maloney and S. T. Woolson, "Increasing incidence of femoral osteolysis in association with uncemented Harris-Galante total hip arthroplasty: a follow-up report," *Journal of Arthroplasty*, vol. 11, no. 2, pp. 130–134, 1996.

[5] M. A. Mont and D. S. Hungerford, "Proximally coated ingrowth prostheses: a review," *Clinical Orthopaedics and Related Research*, no. 344, pp. 139–149, 1997.

[6] J. S. Xenos, J. J. Callaghan, R. D. Heekin, W. J. Hopkinson, C. G. Savory, and M. S. Moore, "The porous-coated anatomic total hip prosthesis, inserted without cement. A prospective study with a minimum of ten years of follow-up," *Journal of Bone and Joint Surgery A*, vol. 81, no. 1, pp. 74–82, 1999.

[7] C. Khalily and L. A. Whiteside, "Predictive value of early radiographic findings in cementless total hip arthroplasty femoral components: an 8- to 12-year follow-up," *Journal of Arthroplasty*, vol. 13, no. 7, pp. 768–773, 1998.

[8] J. D. Bobyn, A. H. Glassman, H. Goto, J. J. Krygier, J. E. Miller, and C. E. Brooks, "The effect of stem stiffness on femoral bone resorption after canine porous-coated total hip arthroplasty," *Clinical Orthopaedics and Related Research*, no. 261, pp. 196–213, 1990.

[9] J. L. Kronick, M. L. Barba, and W. G. Paprosky, "Extensively coated femoral components in young patients," *Clinical Orthopaedics and Related Research*, no. 344, pp. 263–274, 1997.

[10] C. F. Burt, K. L. Garvin, E. T. Otterberg, and O. M. Jardon, "A femoral component inserted without cement in total hip arthroplasty: a study of the Tri-Lock component with an average ten-year duration of follow-up," *Journal of Bone and Joint Surgery A*, vol. 80, no. 7, pp. 952–960, 1998.

[11] T. H. Mallory, W. C. Head, and A. V. Lombardi Jr., "Tapered design for the cementless total hip arthroplasty femoral component," *Clinical Orthopaedics and Related Research*, no. 344, pp. 172–178, 1997.

[12] J. B. Meding, M. A. Ritter, E. M. Keating, P. M. Faris, and K. Edmondson, "A comparison of collared and collarless femoral components in primary cemented total hip arthroplasty: a randomized clinical trial," *Journal of Arthroplasty*, vol. 14, no. 2, pp. 123–130, 1999.

[13] B. M. Dodge, R. Fitzrandolph, and D. N. Collins, "Noncemented porous-coated anatomic total hip arthroplasty," *Clinical Orthopaedics and Related Research*, no. 269, pp. 16–24, 1991.

[14] R. B. Bourne, C. H. Rorabeck, M. E. Ghazal, and M. H. Lee, "Pain in the thigh following total hip replacement with a porous-coated anatomic prosthesis for osteoarthrosis. A five-year follow-up study," *Journal of Bone and Joint Surgery A*, vol. 76, no. 10, pp. 1464–1470, 1994.

[15] S. M. Madey, J. J. Callaghan, J. P. Olejniczak, D. D. Goetz, and R. C. Johnston, "Charnley total hip arthroplasty with use of improved techniques of cementing. The results after a minimum

of fifteen years of follow-up," *Journal of Bone and Joint Surgery A*, vol. 79, no. 1, pp. 53–64, 1997.

[16] J. R. Mclaughlin and K. R. Lee, "Total hip arthroplasty with an uncemented femoral component. Excellent results at ten-year follow-up," *Journal of Bone and Joint Surgery B*, vol. 79, no. 6, pp. 900–907, 1997.

[17] H. U. Cameron, "The 3-6-year results of a modular noncemented low-bending stiffness hip implant: a preliminary study," *Journal of Arthroplasty*, vol. 8, no. 3, pp. 239–243, 1993.

[18] K. T. Mäkelä, A. Eskelinen, P. Pulkkinen, P. Paavolainen, and V. Remes, "Total hip arthroplasty for primary osteoarthritis in patients fifty-five years of age or older: an analysis of the Finnish Arthroplasty Registry," *Journal of Bone and Joint Surgery A*, vol. 90, no. 10, pp. 2160–2170, 2008.

[19] A. A. Hofmann, M. E. Feign, W. Klauser, C. C. VanGorp, and M. P. Camargo, "Cementless primary total hip arthroplasty with a tapered, proximally porous-coated titanium prosthesis: a 4- to 8-year retrospective review," *Journal of Arthroplasty*, vol. 15, no. 7, pp. 833–839, 2000.

[20] M. J. Vives, W. J. Hozack, P. F. Sharkey, L. Moriarty, B. Sokoloff, and R. H. Rothman, "Fixed minidose versus-adjusted low-dose warfarin after total joint arthroplasty: a randomized prospective study," *Journal of Arthroplasty*, vol. 16, no. 8, pp. 1030–1037, 2001.

[21] J. R. Lieberman, J. Wollaeger, F. Dorey et al., "The efficacy of prophylaxis with low-dose warfarin for prevention of pulmonary embolism following total hip arthroplasty," *Journal of Bone and Joint Surgery A*, vol. 79, no. 3, pp. 319–325, 1997.

[22] W. H. Harris, "Traumatic arthritis of the hip after dislocation and acetabular fractures: treatment by mold arthroplasty. An end-result study using a new method of result evaluation," *Journal of Bone and Joint Surgery A*, vol. 51, no. 4, pp. 737–755, 1969.

[23] J. G. DeLee and J. Charnley, "Radiological demarcation of cemented sockets in total hip replacement," *Clinical Orthopaedics and Related Research*, vol. 121, pp. 20–32, 1976.

[24] T. A. Gruen, G. M. McNeice, and H. C. Amstutz, "'Modes of failure' of cemented stem-type femoral components. A radiographic analysis of loosening," *Clinical Orthopaedics and Related Research*, no. 141, pp. 17–27, 1979.

[25] R. C. Johnston, R. H. Fitzgerald Jr., W. H. Harris, R. Poss, M. E. Muller, and C. B. Sledge, "Clinical and radiographic evaluation of total hip replacement. A standard system of terminology for reporting results," *Journal of Bone and Joint Surgery A*, vol. 72, no. 2, pp. 161–168, 1990.

[26] C. A. Engh, P. Massin, and K. E. Suthers, "Roentgenographic assessment of the biologic fixation of porous-surfaced femoral components," *Clinical Orthopaedics and Related Research*, no. 257, pp. 107–128, 1990.

[27] M. J. Griffith, M. K. Seidenstein, D. Williams, and J. Charnley, "Socket wear in Charnley low friction arthroplasty of the hip," *Clinical Orthopaedics and Related Research*, vol. 137, pp. 37–47, 1978.

[28] A. F. Brooker, J. W. Bowerman, R. A. Robinson, and L. H. Riley Jr., "Ectopic ossification following total hip replacement. Incidence and a method of classification," *Journal of Bone and Joint Surgery A*, vol. 55, no. 8, pp. 1629–1632, 1973.

[29] J. R. McLaughlin and K. R. Lee, "Total hip arthroplasty with an uncemented tapered femoral component," *Journal of Bone and Joint Surgery A*, vol. 90, no. 6, pp. 1290–1296, 2008.

[30] J. B. Meding, E. M. Keating, M. A. Ritter, P. M. Faris, and M. E. Berend, "Minimum ten-year follow-up of a straight-stemmed, plasma-sprayed, titanium-alloy, uncemented femoral component in primary total hip arthroplasty," *Journal of Bone and Joint Surgery A*, vol. 86, no. 1, pp. 92–97, 2004.

[31] N. A. Johanson, P. F. Lachiewicz, J. R. Lieberman et al., "AAOS clinical practice guideline summary prevention of symptomatic pulmonary embolism in patients undergoing total hip or knee arthroplasty," *Journal of the American Academy of Orthopaedic Surgeons*, vol. 17, pp. 183–196, 2009.