Hindawi Publishing Corporation
Advances in Orthopedic Surgery
Volume 2014, Article ID 863748, 6 pages
http://dx.doi.org/10.1155/2014/863748

Clinical Study

Clinical and Radiological Outcome of the Newest Generation of Ceramic-on-Ceramic Hip Arthroplasty in Young Patients

Avishai Reuven,[1] Grigorios N. Manoudis,[1] Ahmed Aoude,[2] Olga L. Huk,[1] David Zukor,[1] and John Antoniou[1]

[1] *Department of Orthopaedics, McGill University, Jewish General Hospital, 3755 Cote-St.-Catherine Road, Room E-003, Montreal, QC, Canada H3T 1E2*
[2] *Medical School, University of Montreal, P.O. Box 6128, Station Centre-Ville, Montreal, QC, Canada H3C 3J7*

Correspondence should be addressed to Grigorios N. Manoudis; gregmanou@yahoo.com

Received 11 September 2013; Accepted 29 December 2013; Published 12 February 2014

Academic Editor: Mel S. Lee

Ceramic-on-ceramic articulations have become an attractive option for total hip arthroplasty in young patients. In this study, we retrospectively evaluated the short- to midterm clinical and radiographic results in 51 consecutive patients (61 hips) using the newest generation of ceramic implants. Results obtained in our study showed positive clinical and radiological outcomes. Both HHS and UCLA activity scores doubled after surgery and tended to increase over time. There was one infection requiring a two-stage revision and a case of squeaking that began 2 years postoperatively after a mechanical fall. The overall survival rate of the implants was 98.4% at six years with revision for any reason as the end point. Based on these results, fourth generation ceramics offer a viable option for young and active patients.

1. Introduction

One of the most challenging problems that orthopaedic surgeons are facing today is the increasing number of young and active patients requiring long lasting and reliable primary total hip arthroplasty (THA) [1]. It is well known that bearing surface wear and particle-driven osteolysis remain the major factors threatening the longevity and limiting the performance of the implant [2, 3]. Ceramic-on-ceramic (CC) hip articulations made form alumina have become an attractive option for young and active patients who require THA. This is partially due to the excellent wear characteristics and outstanding tribological properties of alumina over metal-on-polyethylene (MP) bearings [4, 5]. In addition, the inert nature of alumina gives the CC surfaces a great advantage over metal-on-metal (MM) surfaces [6].

Alumina CC bearings have a long history of use [7]. Initial attempts of ceramic-on-ceramic THA had high failure rates that were mainly related to bad design and flaws in the material [8, 9]. Further advancements in alumina manufacturing technology such as hot isostatic pressing led to the fabrication of a highly purified alumina (BIOLOX forte; CeramTec AG, Plochingen, Germany) with increased material density, decreased grain structure, and less impurities [10, 11]. All these material improvements yielded a noticeable decrease in the rate of implant components fracture and chipping [12, 13]. Despite the advancements made in the quality of alumina ceramic, substantial concerns remain regarding CC bearings including stripe wear, limited sizing option, squeaking, and ceramic implant fracture. Limitations of pure alumina characteristics required the development of an advanced ceramic material.

Ceramic composites were the next step in the development of CC bearings. The newest generation of BIOLOX delta ceramic bearings was introduced in 2000 by CeramTec AG (Plochingen, Germany). BIOLOX delta is an alumina-matrix composite (AMC) consisting of 81.6% aluminium oxide, 17% yttria-stabilized tetragonal zirconia particles, and traces (1.4%) of chromium dioxide and strontium crystals engineered to increase material density and reduce grain size (less than 0.8 μm compared with the grain size of alumina 1–5 μm) [14–16]. With these improvements, the risk for crack

propagation and component fracture was minimized. Laboratory mechanical and hip simulator wear tests have shown that these manufacturing advances have indeed resulted in a high-strength material with increased fracture toughness and lower wear rates over pure alumina [15, 17].

These enhanced mechanical properties should decrease the ceramic fracture rate, allowing the manufacturing of thinner acetabular liner inserts and therefore the use of larger femoral head options. This increased head size should improve joint stability and reduce dislocation rates [18, 19]. One study also suggests that material properties of the AMC may lead to a different wear response and may decrease or eliminate squeaking [17]. These favorable material characteristics make AMC a very promising material and particularly desirable for long lasting bearing surfaces. However, AMC has a relatively short clinical history and further monitoring is necessary.

The aim of this study was to retrospectively evaluate the short- to midterm clinical and radiographic outcome after primary total hip replacements using the fourth generation ceramic BIOLOX delta implants.

2. Material and Methods

Prior to the onset of the study, institutional review board approval was obtained. We conducted a retrospective evaluation of all patients who received a cementless CC BIOLOX delta THA between December 2004 and December 2009. Our exclusion criteria were a previous total hip replacement, previous hemiarthroplasty, or fusion on the ipsilateral side. In all, we evaluated 60 hips in 50 patients. Among these patients, 10 underwent staged bilateral THAs. There were 10 males (11 hips) and 40 females (49 hips) (Table 1). The mean age at the time of the surgery was 41.8 years (range 21–56 years). All patients underwent primary hip arthroplasty for both noninflammatory and inflammatory degenerative joint diseases. Preoperative diagnoses were osteoarthritis (40%), developmental dysplasia of the hip (22%), rheumatoid arthritis (13%), avascular necrosis (7%), juvenile rheumatoid arthritis (5%), and other causes (11%). Three arthroplasty surgeons performed all procedures through a direct lateral (77%) or posterior approach (23%). Bilateral cases were conducted on separate dates with a mean interval of 10.3 months (3–42 months) between the two procedures.

Twenty-five hips (42%) received 28 mm ceramic heads and 35 hips (58%) received 36 mm ceramic heads, depending on patient anatomy and implant stability. Head size was determined by the inner diameter of the ceramic liner for the corresponding cup size. All patients received one of four cementless Pinnacle acetabular cups (Pinnacle 100, Pinnacle 300, Pinnacle Bantam, Pinnacle Multihole II; DePuy Warsaw, IN) and one of five cementless femoral stems (Summit, Prodigy, Trilock, Corail, or S-ROM; DePuy, Warsaw, IN) (Table 1). Acetabular fixation with screws was used based on the patient's bone quality.

All patients were evaluated clinically and radiographically at 6 weeks, 3 months, and one year postoperatively, followed by subsequent annual examinations. Minimum followup for this study was 2 years, and average followup was 4.6 years (range 2–6.8 years). Preoperative and postoperative Harris hip score (HHS) [20] was recorded. HHS score of 90 points or more was defined as an excellent outcome; 80 to 89 points, a good outcome; 70 to 79 points, a fair outcome; and less than 70 points, a poor outcome. Activity score was assessed preoperatively and postoperatively using the University of California, Los Angeles (UCLA) activity level rating scale from 1 to 10 [21]. Presence of hip squeaking and all postoperative complications were documented. In each visit, serial anteroposterior (AP) radiographs of the pelvis and AP and lateral radiographs of the operated side were obtained. Radiographic analysis was performed using Einzel-Bild-Roentgen-Analyse (EBRA) by two of the authors (AR and AA).

Survival analysis was performed with use of the Kaplan-Meier method [22]. The patient demographics were calculated with arithmetic mean and all errors are reported as standard deviation. A nonparametric Mann-Whitney U test was conducted to determine the significance between preoperative and the last postoperative HHS and UCLA activity scores. All other comparisons between different time

Table 1: Demographic data.

Characteristic	Finding
Number of hips	60
Number of patients	50
Age (range)*	41.8 (21–56)
Gender	10 males/40 females
Side of surgery	31 right/29 left
Etiology	
Osteoarthritis	24 (40%)
Congenital dislocation	13 (22%)
Rheumatoid arthritis	8 (13%)
Avascular necrosis	4 (7%)
Juvenile rheumatoid arthritis	3 (5%)
Developmental dysplasia	1 (2%)
Multiple causes	7 (11%)
Femoral head	
BIOLOX delta 28 mm	25 hips (42%)
BIOLOX delta 36 mm	35 hips (58%)
Femoral stem	
S-ROM	41 (69%)
Prodigy	11 (18%)
Summit	3 (5%)
Corail	3 (5%)
Trilock	2 (3%)
Acetabular cup	
Pinnacle 100	37 (62%)
Pinnacle 300	19 (31%)
Pinnacle Bantam	3 (5%)
Pinnacle Multihole II	1 (2%)

*This value is reported as the mean in years.

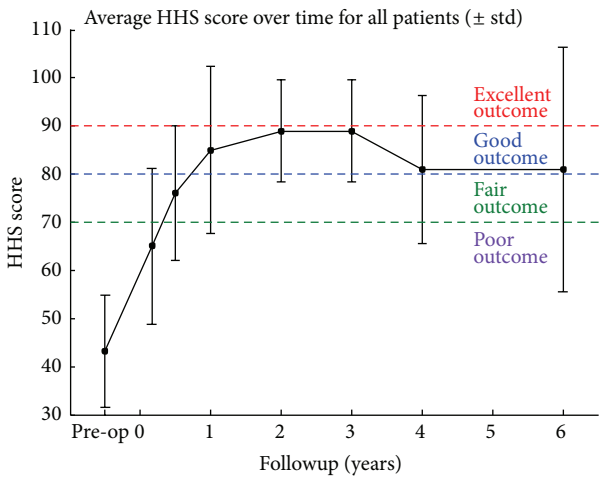

Figure 1: Average and standard deviation (SD) values of HHS scores for all patients over time.

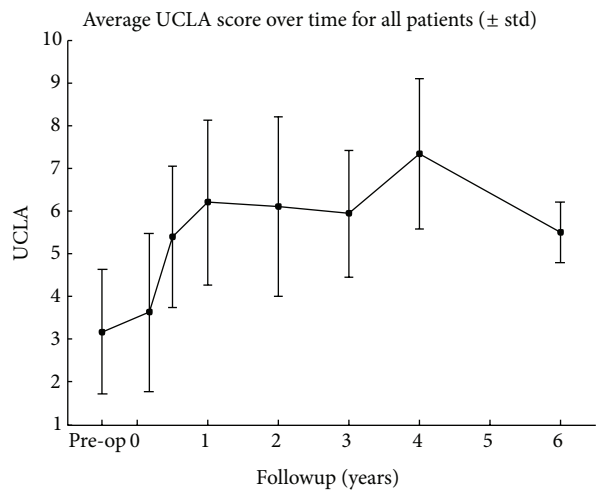

Figure 2: Average and standard deviation (SD) values of UCLA activity scores for all patients over time.

points of followup groups were performed using a nonparametric Kruskal-Wallis test followed by a Dunn's multiple comparisons. GraphPad Prism software (GraphPad Software, La Jolla, CA, USA) was used for all data analyses. A P value of less than 0.05 was considered to be statistically significant.

3. Results

All 50 patients had complete clinical and radiographic data at 2 years of followup.

The mean HHS and UCLA scores at last followup significantly improved ($P = 0.00087$) from their preoperative values. The mean HHS score for all patients at their last followup was 88 points (range, 40–99). The mean UCLA activity score was 6 (range, 2–10). Table 3 shows the number of hips showing excellent (HHS > 90), good (90 > HHS > 80), fair (80 > HHS > 70), or poor (HHS < 70) outcomes based on HHS score for all patients as well as those who received 36 mm and 28 mm femoral heads. In all cases, excellent outcomes were observed in 67% of hips, while poor results were only observed in minority of 5% of hips. There were no outcome differences between the two head diameters.

We also looked at the evolution of HHS and UCLA activity score over time. Both scores significantly increased until 4 years postoperatively reaching a plateau thereafter (Figures 1 and 2).

At the time of the final followup, there was no radiographic evidence of component loosening and no evidence of implant subsidence, liner fracture or dislocation. All components were stable and osseous-integrated. The mean acetabular inclination and anteversion were 46 degrees (range, 28 to 58 degrees) and 7 degrees (range, 2 to 22 degrees), respectively (Table 2).

There was a case of deep infection requiring a two-stage revision. One female patient presented with audible repetitive "squeaking" noise that began after a fall 2 years postoperatively. She had a 36 mm head and she was able to reproduce the squeaking in the office with walking. The cup was found to be in a nonoptimal position, measuring 58° of inclination and 19° of anteversion (Figures 3(a) and 3(b)). The patient was completely pain-free and she refused a revision surgery. The third patient presenting with poor result was a female patient with juvenile rheumatoid arthritis and reduced mobility.

The Kaplan-Meier survival with revision for any reason as the end point was 98.4% at 6 years. In summary, no patients showed osteolysis, one patient had audible squeaking, and only one patient required revision surgery for infection. Both HHS and UCLA activity scores significantly improved after surgery and tended to increase over time. Of all procedures, 72% of 28 mm heads and 63% of 36 mm heads had excellent HHS outcomes. No statistically significant difference was noted between 28 mm and 36 mm heads in both HHS

Table 2: Clinical and radiographic results at the last followup.

	Preoperative	Final followup
Clinical parameters*		
Harris hip score	45	88 (40–90)
UCLA activity score	3	6 (2–10)
Radiographic parameters*		
Acetabular anteversion	n/a	7° (2°–22°)
Acetabular inclination	n/a	46° (28°–56°)

*The values are reported as the mean.
n/a = not applicable.

Table 3: The number of hips showing the clinical outcome based on HHS score.

Total	Excellent	Good	Fair	Poor	
60	40 (67%)	9 (15%)	8 (13%)	3 (5%)	All THAs
25	18 (72%)	4 (16%)	3 (12%)	0 (0%)	28 mm THRs
35	22 (63%)	5 (14%)	5 (14%)	3 (9%)	36 mm THRs

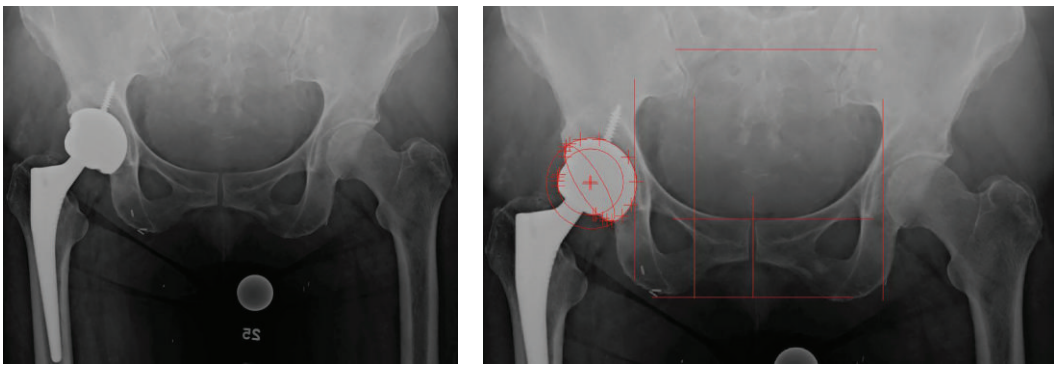

(a) (b)

Figure 3: (a) AP radiograph of the patient presenting with audible hip squeaking. (b) Analysis with the EBRA software revealed cup inclination of 58 degrees and anteversion of 19 degrees.

($P = 0.277$) and UCLA activity score ($P = 0.1029$) at the last followup or at any time point of followup.

4. Discussion

Wear debris-induced osteolysis and subsequent implant loosening are major factors limiting the survivorship and performance of THA. This problem may be overcome with the use of CC bearings known to produce the lowest volumetric wear rate and reduced incidence of periprosthetic osteolysis [23, 24]. Despite their elevated hardness and toughness, the CC surfaces are not immune to wear or surface damage and concerns arising about ceramic implants are chipping and component fracture, stripe wear, and the poorly understood phenomenon of squeaking [12]. Moreover, the lack of large modular options continues to exist [10, 13, 19]. The BIOLOX delta AMC was developed to address some of the drawbacks of currently available alumina designs. Its increased fracture toughness combined with the wider range of head sizes make this implant an attractive selection. In this study our aim was to evaluate the short- and midterm outcome of this new material.

One of the major disadvantages of the alumina ceramic bearing is the risk of fracture. Although sporadic, these component fractures can be catastrophic and continue to be a clinical concern for both surgeon and patient [12]. The CC fracture failure is principally related to the crack propagation and is favoured by stress concentration zones caused by microstructural flaws either at the surface or within the material [25]. Incremental advances in the manufacturing process, design, and quality control of alumina components have addressed these issues improving significantly the structural characteristics and fracture toughness of pure alumina [26].

Currently, component fractures with modern CC bearings are rare (0.004%) [26, 27]. Both D'Antonio et al. [23] and Lusty et al. [5] showed no ceramic bearing fractures in 213 and 301 primary alumina-on-alumina THAs, respectively, at an average of five years. The estimated risk of fracture of these implants is from 0.03% to 0.05% for femoral heads and from 0.017% to 0.013% for the alumina ceramic acetabular insert and is more likely to occur within the first three years following implantation [27]. Furthermore, fractures of 28 mm heads occur more frequent than 32 mm and 36 mm heads [28]. Because of the BIOLOX delta's increased fracture toughness and burst strength, the expectation is that fracture would occur with far less frequency than the estimated fracture rate of alumina ceramic heads (0.02%) [27, 29]. In our study, there was no incidence of head or liner fracture. Moreover, there was no difference between 28 mm and 32 mm heads in terms of clinical and radiological outcome.

In their prospective randomized study, D'Antonio et al. showed that liners that were not fully seated were prone to peripheral chipping during impaction [30]. They observed a peripheral chip in 1.2% of cases; however, none of these resulted in a fracture or in revision surgery. A subsequent design encased the ceramic acetabular component in a titanium sleeve, which eliminates the risk of insertional chips [28, 30].

Recognition of squeaking in ceramic articulations as a clinical problem has increased recently [16, 17, 31] with its incidence ranging from 0.48% to 7% [11, 18, 32]. Squeaking has been shown to be due to ceramic or metal wear, component factors, implant design, impingement, implant positioning [11, 18], and patient characteristics [27]. Squeaking often occurs in younger, heavier, and taller patients [33]. Edge loading appears to be the predominant causative factor for squeaking [33]. Ki et al. showed that increased BMI and certain cup designs were more prone to squeaking [34]. Swanson et al. reviewed 233 patients comparing 4 implant combinations representing 4 manufacturers and found that Trident acetabular cups paired with Stryker Accolade femoral stems showed a dramatically higher incidence of squeaking. They concluded that prosthetic design plays a key role in squeaking occurrence [35]. Another significant cause of squeaking is cup design that results in premature femoral neck-acetabular component rim impingement such as the presence of modular ceramic liner designs that are placed within a titanium encasement with extended rims [29, 34]. Most studies report that squeaking is rare with no clinical consequences [17], but in some studies, squeaking has led to

revision [32, 36]. Yang et al. also suggested that squeaking can be reduced due to material properties, such as the wear response of BIOLOX delta [17]. In our study squeaking was noted in only one patient with increased inclination of the acetabular component.

Our study has certain limitations. The number of patients is relatively small, three surgeons were involved using two different approaches, and four acetabular cups matched with five femoral stems were implanted. We also recognize that our study is of relatively short duration with a minimum followup of two years and a mean followup of just over four years. To the best of our knowledge, this is the first study reporting the survival and functional outcome of solely fourth generation ceramic delta implants.

5. Conclusion

Alumina-based ceramic composite materials, with its superior mechanical properties and excellent wear behavior, have been successfully implanted and have offered outstanding performance in the last 11 years. This retrospective study demonstrates that BIOLOX delta bearings provided good to excellent overall functioning outcomes with no implant related complications or osteolysis. An increase in head size did not lead to significantly different HHS and UCLA activity score results. However, the duration of followup is relatively short. Therefore, we cannot conclude whether this new ceramic material will outperform other bearing couplings over time. Long-term follow-up studies are needed to determine the stability and reliability of fourth generation ceramic articulation in THA. However, based on the results we observed and those already present in the literature, fourth generation ceramic bearing couplings appear to be very promising and should be considered for young and active patients.

Conflict of Interests

The authors declare that there is no conflict of interests regarding the publication of this paper.

Acknowledgment

This research was done in the Jewish General Hospital, Department of Orthopaedic Surgery.

References

[1] S. Kurtz, K. Ong, E. Lau, F. Mowat, and M. Halpern, "Projections of primary and revision hip and knee arthroplasty in the United States from 2005 to 2030," *Journal of Bone and Joint Surgery A*, vol. 89, no. 4, pp. 780–785, 2007.

[2] W. H. Harris, "Wear and periprosthetic osteolysis the problem," *Clinical Orthopaedics and Related Research*, no. 393, pp. 66–70, 2001.

[3] J. H. Dumbleton, M. T. Manley, and A. A. Edidin, "A literature review of the association between wear rate and osteolysis in total hip arthroplasty," *Journal of Arthroplasty*, vol. 17, no. 5, pp. 649–661, 2002.

[4] J. Y. Jeong, Y.-M. Kim, S. Y. Kang, K.-H. Koo, S. S. Won, and J. K. Hee, "Alumina-on-alumina total hip arthroplasty: a five-year minimum follow-up study," *Journal of Bone and Joint Surgery A*, vol. 87, no. 3, pp. 530–535, 2005.

[5] P. J. Lusty, C. C. Tai, R. P. Sew-Hoy, W. L. Walter, W. K. Walter, and B. A. Zicat, "Third-generation alumina-on-alumina ceramic bearings in cementless total hip arthroplasty," *Journal of Bone and Joint Surgery A*, vol. 89, no. 12, pp. 2676–2683, 2007.

[6] P. S. Christel, "Biocompatibility of surgical-grade dense polycrystalline alumina," *Clinical Orthopaedics and Related Research*, no. 282, pp. 10–18, 1992.

[7] P. Boutin, "Total hip arthroplasty using a ceramic prosthesis. Pierre Boutin (1924–1989)," *Clinical Orthopaedics and Related Research*, vol. 379, pp. 3–11, 2000.

[8] R. S. Nizard, L. Sedel, P. Christel, A. Meunier, M. Soudry, and J. Witvoet, "Ten-year survivorship of cemented ceramic-ceramic total hip prosthesis," *Clinical Orthopaedics and Related Research*, no. 282, pp. 53–63, 1992.

[9] L. Sedel, R. S. Nizard, L. Kerboull, and J. Witvoet, "Alumina-alumina hip replacement in patients younger than 50 years old," *Clinical Orthopaedics and Related Research*, no. 298, pp. 175–183, 1994.

[10] R. J. Heros and G. Willmann, "Ceramics in total hip arthroplasty: history, mechanical properties, clinical results, and current manufacturing state of the art," *Seminars in Arthroplasty*, vol. 9, pp. 114–122, 1998.

[11] Y.-Z. Cai and S.-G. Yan, "Development of ceramic-on-ceramic implants for total hip arthroplasty," *Orthopaedic Surgery*, vol. 2, no. 3, pp. 175–181, 2010.

[12] G. Willmann, "Cerami femoral head retrieval data," *Clinical Orthopaedics and Related Research*, no. 379, pp. 22–28, 2000.

[13] K. Kawanabe, K. Tanaka, J. Tamura et al., "Effect of alumina femoral head on clinical results in cemented total hip arthroplasty: old versus current alumina," *Journal of Orthopaedic Science*, vol. 10, no. 4, pp. 378–384, 2005.

[14] M. Kuntz, N. Schneider, and R. Heros, "Controlled zirconia phase transformation in biolox delta—a feature of safety," *Ceramics in Orthopeadics*, pp. 79–83, 2006.

[15] J. Y. Jeong, Y.-M. Kim, S. Y. Kang, K.-H. Koo, S. S. Won, and J. K. Hee, "Alumina-on-alumina total hip arthroplasty: a five-year minimum follow-up study," *Journal of Bone and Joint Surgery A*, vol. 87, no. 3, pp. 530–535, 2005.

[16] S. A. Sexton, W. L. Walter, M. P. Jackson, R. De Steiger, and T. Stanford, "Ceramic-on-ceramic bearing surface and risk of revision due to dislocation after primary total hip replacement," *Journal of Bone and Joint Surgery B*, vol. 91, no. 11, pp. 1448–1453, 2009.

[17] C. C. Yang, R. H. Kim, and D. A. Dennis, "The squeaking hip: a cause for concern-disagrees," *Orthopedics*, vol. 30, no. 9, pp. 739–742, 2007.

[18] K. Mai, M. E. Hardwick, R. H. Walker, S. N. Copp, K. A. Ezzet, and C. W. Colwell Jr., "Early dislocation rate in ceramic-on-ceramic total hip arthroplasty," *HSS Journal*, vol. 4, no. 1, pp. 10–13, 2008.

[19] D. J. Berry, M. Von Knoch, C. D. Schleck, and W. S. Harmsen, "Effect of femoral head diameter and operative approach on risk of dislocation after primary total hip arthroplasty," *Journal of Bone and Joint Surgery A*, vol. 87, no. 11, pp. 2456–2463, 2005.

[20] W. H. Harris, "Traumatic arthritis of the hip after dislocation and acetabular fractures: treatment by mold arthroplasty. An end-result study using a new method of result evaluation," *Journal of Bone and Joint Surgery A*, vol. 51, no. 4, pp. 737–755, 1969.

[21] S. Lerouge, O. Huk, L. H. Yahia, and L. Sedel, "Characterization of in vivo wear debris from ceramic-ceramic total hip arthroplasties," *Journal of Biomedical Materials Research A*, vol. 32, no. 4, pp. 627–633, 1996.

[22] E. L. Kaplan and P. Meier, "Nonparametric estimation from incomplete observations," *Journal of the American Statistical Association*, vol. 53, no. 282, pp. 457–481, 1958.

[23] J. D'Antonio, W. Capello, M. Manley, M. Naughton, and K. Sutton, "Alumina ceramic bearings for total hip arthroplasty: five-year results of a prospective randomized study," *Clinical Orthopaedics and Related Research*, no. 436, pp. 164–171, 2005.

[24] R. L. Barrack, C. Burak, and H. B. Skinner, "Concerns about ceramics in THA," *Clinical Orthopaedics and Related Research*, no. 429, pp. 73–79, 2004.

[25] D. Hannouche, C. Nich, P. Bizot, A. Meunier, R. Nizard, and L. Sedel, "Fractures of ceramic bearings: history and present status," *Clinical Orthopaedics and Related Research*, no. 417, pp. 19–26, 2003.

[26] J. A. D'Antonio and K. Sutton, "Ceramic materials as bearing surfaces for total hip arthroplasty," *Journal of the American Academy of Orthopaedic Surgeons*, vol. 17, no. 2, pp. 63–68, 2009.

[27] M. Hamadouche, P. Boutin, J. Daussange, M. E. Bolander, and L. Sedel, "Alumina-on-alumina total hip arthroplasty: a minimum 18.5-year follow-up study," *Journal of Bone and Joint Surgery A*, vol. 84, no. 1, pp. 69–77, 2002.

[28] J. A. D'Antonio, W. N. Capello, M. T. Manley, M. Naughton, and K. Sutton, "A titanium-encased alumina ceramic bearing for total hip arthroplasty: 3- to 5-year results," *Clinical Orthopaedics and Related Research*, no. 441, pp. 151–158, 2005.

[29] Y.-C. Ha, S.-Y. Kim, H. J. Kim, J. J. Yoo, and K.-H. Koo, "Ceramic liner fracture after cementless alumina-on-alumina total hip arthroplasty," *Clinical Orthopaedics and Related Research*, no. 458, pp. 106–110, 2007.

[30] J. A. D'Antonio, W. N. Capello, B. Bierbaum, M. Manley, and M. Naughton, "Ceramic-on-ceramic bearings for total hip arthroplasty: 5-9 year follow-up," *Seminars in Arthroplasty*, vol. 17, no. 3-4, pp. 146–152, 2006.

[31] C. A. Jarrett, A. S. Ranawat, M. Bruzzone, Y. C. Blum, J. A. Rodriguez, and C. S. Ranawat, "The squeaking hip: a phenomenon of ceramic-on-ceramic total hip arthroplasty," *Journal of Bone and Joint Surgery A*, vol. 91, no. 6, pp. 1344–1349, 2009.

[32] C. Restrepo, J. Parvizi, J. Purtill, P. Sharkey, W. Hozack, and R. Rothman, "The noisy ceramic hip: is component malposition the problem?" in *Proceedings of the 16th Annual Meeting of the American Association of Hip and Knee Surgeons*, American Association of Hip and Knee Surgeons, Rosemont, Ill, USA, 2006.

[33] S. J. C. Stanat and J. D. Capozzi, "Squeaking in third- and fourth-generation ceramic-on-ceramic total hip arthroplasty: meta-analysis and systematic review," *Journal of Arthroplasty*, vol. 27, no. 3, pp. 445–453, 2012.

[34] S.-C. Ki, B.-H. Kim, J.-H. Ryu, D.-H. Yoon, and Y.-Y. Chung, "Squeaking sound in total hip arthroplasty using ceramic-on-ceramic bearing surfaces," *Journal of Orthopaedic Science*, vol. 16, no. 1, pp. 21–25, 2011.

[35] T. V. Swanson, D. J. Peterson, R. Seethala, R. L. Bliss, and C. A. Spellmon, "Influence of prosthetic design on squeaking after ceramic-on-ceramic total hip arthroplasty," *The Journal of arthroplasty*, vol. 25, no. 6, pp. 36–42, 2010.

[36] W. L. Walter, G. C. O'Toole, W. K. Walter, A. Ellis, and B. A. Zicat, "Squeaking in ceramic-on-ceramic hips: the importance of acetabular component orientation," *Journal of Arthroplasty*, vol. 22, no. 4, pp. 496–503, 2007.