Hindawi Publishing Corporation
Advances in Orthopedic Surgery
Volume 2016, Article ID 6168923, 5 pages
http://dx.doi.org/10.1155/2016/6168923

Clinical Study

Experiences of a Peripheral Unit in Using a Tripolar Constrained Acetabular Component for Recurrent Dislocations following Total Hip Joint Replacements

Mohammed S. Arshad, Shashi Godey, Arun Kumar, and Martyn Lovell

University Hospital of South Manchester, Southmoor Road, Manchester M23 9LT, UK

Correspondence should be addressed to Mohammed S. Arshad; shebi@doctors.org.uk

Received 16 August 2015; Revised 14 December 2015; Accepted 29 December 2015

Academic Editor: Shyu-Jye Wang

Primary total hip arthroplasty is a successful procedure, although complications such as dislocation can occur. In certain patient populations if this is recurrent, it can be difficult to manage effectively. We present a retrospective analysis of our experience of using a capture/captive cup over an 8-year period for frail elderly patients who presented with recurrent hip dislocations. Our findings show no redislocations in our cohort and a survival analysis demonstrates just less than half surviving at 2 years after surgery. Furthermore, Harris Hip Scores were generally calculated to be good. A constrained acetabular component provides durable protection against additional dislocations without substantial deleterious effects on component fixation. Such components should be considered especially in a group of patients with comorbidities or those who are fragile, elderly, and low-demand in nature.

1. Introduction

Primary total hip arthroplasty (THA) is a renowned and successful procedure. Complications such as dislocation can occur and variable rates are reported but there is a cumulative increase which may approach 5% [1–7]. Recurrence is seen in up to two-thirds of cases with the problem persisting after revision surgery in about half [1, 8, 9]. Numerous risk factors have been documented which include increasing age, reduced cerebral capabilities, neuromuscular disorders, abductor deficiency, and mal-positioning of components at time of surgery [10–12]. Surgical solutions to correct, reverse, or manage such factors have on the whole produced mixed and inconclusive results, whether it is altering a mal-positioned component, using cup augments, increasing femoral head size, converting to a bipolar hemiarthroplasty, or reconstructing adjacent tissues [13–20].

Studies have advocated the use of a "capture/captive cup" (CC) (Figure 1) or constrained acetabular component to effectively manage dislocations [21–25]. By capturing the head and locking it within the acetabular component, forces causing dislocation are redistributed to the locking mechanism and liner-shell and shell-bone interfaces [24]. Thus such devices provide immediate stability and are a welcome solution to a debilitating complication, although the procedure has been associated with some setbacks, mainly a reduced range of motion, possible loosening, or dissociation of the component from the pelvis which requires either open reduction or revision [25, 26]. We present our experience of using a constrained cup in managing recurrent dislocations in low-demand patients.

2. Materials and Methods

A retrospective case-note review of all patients who underwent revision of their acetabular component using a tripolar Trident acetabular cup (Stryker-Howmedica-Osteonics, Rutherford, New Jersey) between 2005 and 2013 (identified through a local database) was undertaken by two orthopaedic surgeons. It was recognised that a constrained liner was offered to patients who had undergone recurrent dislocations ($n \geq 2$). A small number of our cohort had undergone further

Figure 1: Photograph demonstrating a capture/captive cup (tripolar Trident acetabular cup: Stryker-Howmedica-Osteonics, Rutherford, New Jersey).

procedures following on from their primary THA: THA revision ($n = 3$); posterior lip augmentation device (PLAD) ($n = 3$).

In total 43 patients who received a constrained acetabular component were identified. The mean age of our cohort was 76.5 years (range 53–93 years). Our male to female ratio was 19 : 24. A majority of our patients (93%) had undergone their primary surgery due to osteoarthritis. The remaining patients ($n = 3$) required a THA for a fractured neck of femur, nonunion of a fractured neck of femur, and a previous septic arthritis. Analysis of documentation revealed that 84% of patients had undergone either a trochanteric osteotomy ($n = 14$) or Hardinge (anterolateral) approach ($n = 29$) during primary surgery.

All 43 patients were followed up after their procedure; however, at the time of data analysis, 23 patients had died due to their comorbidities, 5 patients were lost to follow-up, and 2 patients were excluded for further analysis due to dementia and ongoing investigation for a psychiatric illness. Following initial analysis of all patients, the 13 remaining patients were reviewed further, specifically observing their postoperative pain scores and mobility status along with any recent radiographic abnormalities. Additionally, relevant questions were asked in order to calculate a Harris Hip Score [27] which was then graded [28].

For our cohort of remaining patients, pain levels were also documented according to a visual analogue score (VAS). Radiographs were reviewed by an orthopaedic surgeon to assess acetabular component failure in terms of stability by identifying features of loosening. Our cemented cups were analysed using DeLee and Charnley's criteria [29] and Tompkin et al.'s criteria were applied to uncemented cups [30].

3. Results

The mean time from previous surgery (whether primary or revision) to receiving a capture cup was 74 months (range 6 months–252 months). In 9% of cases ($n = 4$), the capture cup was uncemented; the remainder were cemented (Figure 2). Additionally, 6 of our patients had also undergone revision of their femoral component during the same session of surgery. These findings are summarised in Table 1. Many of our patients (>50%) had a monoblock Charnley femoral stem and thus the capture cup avoided a femoral component revision.

Table 1: Summary of data analysis of the 43 patients identified in our study. All patients underwent a capture/captive cup procedure for recurrent dislocations ($n \geq 2$). CC = capture/captive cup, PLAD = posterior lip augmentation device, and THA = total hip arthroplasty.

43 patients	
Alive	13
Dead	23
Lost to follow-up	5
Psychiatric illness	2
Cause of primary surgery	
Osteoarthritis	40
Neck of femur fracture	1
Neck of femur fracture nonunion	1
Secondary to septic arthritis	1
Further surgery after primary total hip arthroplasty (THA)	
THA revision (prior to CC)	3
PLAD (prior to CC)	3
Femoral component revision (at time of CC)	6
Capture/captive cup (CC)	
Uncemented	4
Cemented	39
Surgical approach	
Trochanteric osteotomy	14
Hardinge	29

Figure 2: Radiograph demonstrating the use of a cemented capture/captive cup for the right hip*.

Overall, our follow-up mean time was 26 months (range 1 month–68 months). A Kaplan-Meier plot of survival based on follow-up times (Figure 3) demonstrates that, one year after surgery, the survival was 62% and, at 2 years, was 48%. Of those patients who are currently alive, a VAS was recorded during their last follow-up. A mean score of 2.8 (range 0–8) was noted. The median Harris Hip Score [27] was 80.2 points (range 43.2–96.6) resulting in "good" grade on average (Table 2). In terms of mobility only, during their last follow-up, 5 patients were mobilising independently, 4 patients were

Table 2: Harris Hip Scores (and grading) of surviving patients (n = 13) after undergoing a capture/captive cup.

	Harris Hip Score		
		Grade	
Median	80.2	Poor	2
		Fair	3
Range	43.2–96.6	Good	3
		Excellent	5

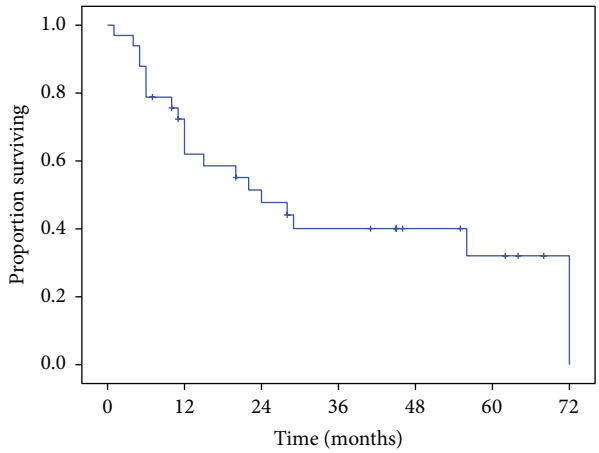

Figure 3: Graph demonstrating a Kaplan-Meier plot of survival (based on follow-up times) for patients undergoing a capture/captive cup.

mobilising with support, and 4 patients were unable to do so or were struggling and required more than a stick or crutch.

Radiographic analysis of these patients revealed that all cemented cups were satisfactory in that no loosening was evident as per DeLee and Charnley zones [29]. As per Tompkin et al.'s criteria [30], 75% of our uncemented cups were stable (n = 3) with the other cup being deemed unstable due to the presence of radiolucent lines in all zones and evidence of migration 15 mm (although the constrained mechanism itself was intact) which required further surgery (Figure 4).

A Summary Highlighting the Complications Seen in 3 Patients in Our Study. Complications were seen in 7% of all cases (n = 3) as follows.

Postoperative infection and Girdlestone's procedure.

Loosening and migration of uncemented cup.

Pelvic detachment of cemented cup.

The first patient had delayed postoperative wound healing and a staphylococcus aureus infection was diagnosed from serial microbiological swabs. She subsequently underwent a debridement and Girdlestone's procedure and required input from the plastic surgeons to assist in closing her wound. She recovered well and was keen to pursue another total hip arthroplasty in order to improve her mobility and was then referred to a tertiary centre for further revision surgery.

The second case involved a patient who underwent a primary total hip arthroplasty following a native hip joint

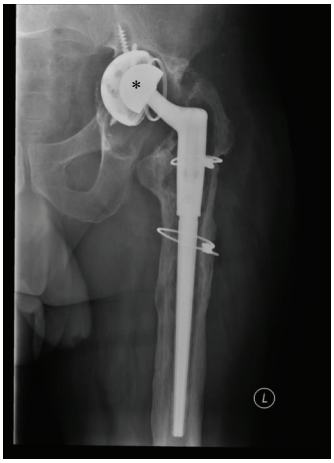

Figure 4: Radiograph demonstrating the failure of an uncemented acetabular shell for the left hip*.

septic arthritis 10 years before. He developed aseptic loosening (negative microbiology of aspirates and tissue samples) and thus a revision arthroplasty was done. This too failed due to aseptic loosening and thus a cementless constrained tripolar device was fitted. After 6 months, a similar picture was seen with the cup having migrated by approximately and no conclusive evidence to suggest infection. He was referred to a tertiary centre for further evaluation and treatment.

Our final case was a cemented cup done for a frail 86-year-old lady following recurrent dislocations. Unfortunately, the device became detached from the pelvis and revised capture/captive cup was done. However, given her frailty and comorbidities, the patient did not survive more than 6 months and thus for the purpose of this study further assessment was not possible. Most importantly, no redislocations have been evident from our series.

4. Discussion

Recurrent instability is often multifactorial and is frequently not associated with a clearly identifiable cause. For those affected, they are often old and frail undergoing rapid deterioration of their systems and as such the loss of skeletal muscle mass coupled with polyethylene wear and dementia may be some of the contributory factors leading to dislocation.

By locking or capturing the femoral head within the acetabular component, the constrained device can be a short to medium term solution when deployed by the revision hip surgeon in treating a particular group of patients who have significant comorbidities and recurrent dislocations. The constrained design is successful in reducing dislocations in such patient groups though it can lead to increasing levels of loosening. The variety in designs allows different head sizes, offset, and rim elevation which manifests in different ranges of motion. Impingement is seen once the limit is reached and thus forces are dissipated between the bone-shell and shell liner boundaries [24]. In a revision series, the devices have shown to reduce the dislocation rate to 6% but after a decade the loosening risk was noted to be at 9% [21].

On the other hand, the dual mobility device (tripolar unconstrained acetabular cup) aims to not only reduce dislocation risk but also lower loosening by increasing the functional diameter of the head and thus reducing impingement, wear, and dissociation. Since their development (Novae-1®, Serf, Décines, France) in the 1970s, they have provided a reliable solution in the revision setting for older low-demand patients as supported by midterm data with rates of dislocation at 1.1% and loosening at 2.2%, although there is a lack of significant evidence to support their use in the younger high demand patient [31–34]. The aim is to allow a greater range of motion through the use of a large diameter head before it impinges against the polyethylene liner hence preventing intraprosthetic dislocation [34]. Apart from their use in revision surgery, dual mobility cups have been implanted in primary surgery as well as in treating neck of femur fractures, tumour resection, and spastic disorders with dislocation rates varying between 0 and 14% and survivorship rates between 80 and 98% ranging from a period of 5 to 15 years [35–37].

Despite a survival rate of 30% in our cohort (representing the mixed nature of the population of a peripheral unit over a period of 8 years) which is unlikely to lead to any concrete conclusions, we believe the use of a capture/captive cup is an effective short to medium term tool in dealing with recurrent dislocation. With our monoblock femoral components, not using the dual mobility method but instead a capture/captive cup saved performing a femoral revision. The use of a constrained cup rather than a dual mobility device is likely to be of greater benefit also in patients with neuromuscular disorders, dementia, and low demand or patients without functional abductors. From our experience, it is clinically significant in reducing pain and over two-thirds of patients return to some form of mobility which, in a group of people of a certain demographic and medical status, of whom only less than 50% will survive at 2 years, may be considered as a significant result in terms of improving quality of life.

From our series, the use of cemented components was favourable and less likely to lead to complications although the numbers of uncemented cups were small, thus negating any significant conclusion. Previous studies on constrained acetabular components have quoted loosening/complication rates requiring revision to be between 4% and 11.8% [22, 24, 25]. Our experiences are well within such parameters. Furthermore, in our cohort, no redislocations were evident as supported by Shrader et al. [23]; however, rates of redislocation between 2.4% and 29% have been reported [22, 38]. Failure due to pull-off from the acetabular side wall or separation can occur (5% in total cohort and 8% in alive patients), thus highlighting a potential problem with the use of this technique; therefore all our patients are counselled regarding this complication.

A constrained acetabular component provides durable protection against additional dislocations without substantial deleterious effects on component fixation. Such components should be considered when a correctable cause of instability cannot be identified. Although we acknowledge that there are limitations to our data in terms of the follow-up period being short and the sample numbers being small, from our experience, the use of such a device should be considered to treat recurrent dislocation in comparison with other modalities which may be less effective especially in a group of patients with comorbidities or those who are fragile, elderly, and low-demand in nature.

Conflict of Interests

The authors declare that there is no conflict of interests regarding the publication of this paper.

References

[1] R. Y. G. Woo and B. F. Morrey, "Dislocations after total hip arthroplasty," *The Journal of Bone & Joint Surgery—American Volume*, vol. 64, no. 9, pp. 1295–1306, 1982.

[2] C. D. Fackler and R. Poss, "Dislocation in total hip arthroplasties," *Clinical Orthopaedics and Related Research*, vol. 151, pp. 169–178, 1980.

[3] S. A. Paterno, P. F. Lachiewicz, and S. S. Kelley, "The influence of patient-related factors and the position of the acetabular component on the rate of dislocation after total hip replacement," *The Journal of Bone & Joint Surgery—American Volume*, vol. 79, no. 8, pp. 1202–1210, 1997.

[4] A. Ekelund, N. Rydell, and O. S. Nilsson, "Total hip arthroplasty in patients 80 years of age and older," *Clinical Orthopaedics and Related Research*, vol. 281, pp. 101–106, 1992.

[5] R. S. Turner, "Postoperative total hip prosthetic femoral head dislocations. Incidence, etiologic factors, and management," *Clinical Orthopaedics and Related Research*, no. 301, pp. 196–204, 1994.

[6] D. Fender, W. M. Harper, and P. J. Gregg, "Outcome of Charnley total hip replacement across a single health region in England: the results at five years from a regional hip register," *The Journal of Bone and Joint Surgery—British Volume*, vol. 81, no. 4, pp. 577–581, 1999.

[7] J. Charnley, "The long-term results of low-friction arthroplasty of the hip performed as a primary intervention," *The Journal of Bone & Joint Surgery—British Volume*, vol. 54, no. 1, pp. 61–76, 1972.

[8] D. P. Newington, G. C. Bannister, and M. Fordyce, "Primary total hip replacement in patients over 80 years of age," *The Journal of Bone & Joint Surgery—British Volume*, vol. 72, no. 3, pp. 450–452, 1990.

[9] M. D. Earll, T. K. Fehring, W. L. Griffin, J. B. Mason, T. McCoy, and S. Odum, "Success rate of modular component exchange for the treatment of an unstable total hip arthroplasty," *Journal of Arthroplasty*, vol. 17, no. 7, pp. 864–869, 2002.

[10] S. T. Woolson and Z. O. Rahimtoola, "Risk factors for dislocation during the first 3 months after primary total hip replacement," *The Journal of Arthroplasty*, vol. 14, no. 6, pp. 662–668, 1999.

[11] G. M. Alberton, W. A. High, and B. F. Morrey, "Dislocation after revision total hip arthroplasty: an analysis of risk factors and treatment options," *The Journal of Bone & Joint Surgery—American Volume*, vol. 84, no. 10, pp. 1788–1792, 2002.

[12] L. D. Dorr, A. W. Wolf, R. Chandler, and J. P. Conaty, "Classification and treatment of dislocations of total hip arthroplasty," *Clinical Orthopaedics and Related Research*, vol. 173, pp. 151–158, 1983.

[13] P. J. Daly and B. F. Morrey, "Operative correction of an unstable total hip arthroplasty," *The Journal of Bone & Joint Surgery—American Volume*, vol. 74, no. 9, pp. 1334–1343, 1992.

[14] A. P. Charlwood, N. W. Thompson, N. S. Thompson, D. E. Beverland, and J. R. Nixon, "Recurrent hip arthroplasty dislocation: good outcome after cup augmentation in 20 patients followed for 2 years," *Acta Orthopaedica Scandinavica*, vol. 73, no. 5, pp. 502–505, 2002.

[15] P. E. Beaulé, T. P. Schmalzried, P. Udomkiat, and H. C. Amstutz, "Jumbo femoral head for the treatment of recurrent dislocation following total hip replacement," *The Journal of Bone & Joint Surgery—American Volume*, vol. 84, no. 2, pp. 256–263, 2002.

[16] S. Byström, B. Espehaug, O. Furnes, and L. I. Havelin, "Femoral head size is a risk factor for total hip luxation: a study of 42,987 primary hip arthroplasties from the Norwegian Arthroplasty Register," *Acta Orthopaedica Scandinavica*, vol. 74, no. 5, pp. 514–524, 2003.

[17] J. Parvizi and B. F. Morrey, "Bipolar hip arthroplasty as a salvage treatment for instability of the hip," *The Journal of Bone & Joint Surgery—American Volume*, vol. 82, no. 8, pp. 1132–1139, 2000.

[18] S. J. Kaplan, W. H. Thomas, and R. Poss, "Trochanteric advancement for recurrent dislocation after total hip arthroplasty," *The Journal of Arthroplasty*, vol. 2, no. 2, pp. 119–124, 1987.

[19] K. Strømsøe and K. Eikvar, "Fascia lata plasty in recurrent posterior dislocation after total hip arthroplasty," *Archives of Orthopaedic and Trauma Surgery*, vol. 114, no. 5, pp. 292–294, 1995.

[20] T. Fujishiro, T. Nishikawa, S. Takikawa, Y. Saegusa, S. Yoshiya, and M. Kurosaka, "Reconstruction of the iliofemoral ligament with an artificial ligament for recurrent anterior dislocation of total hip arthroplasty," *Journal of Arthroplasty*, vol. 18, no. 4, pp. 524–527, 2003.

[21] B. R. B. Bremner, D. D. Goetz, J. J. Callaghan, W. N. Capello, and R. C. Johnston, "Use of constrained acetabular components for hip instability: an average 10-year follow-up study," *Journal of Arthroplasty*, vol. 18, no. 7, pp. 131–137, 2003.

[22] G. S. Shapiro, D. E. Weiland, D. C. Markel, D. E. Padgett, T. P. Sculco, and P. M. Pellicci, "The use of a constrained acetabular component for recurrent dislocation," *The Journal of Arthroplasty*, vol. 18, no. 3, pp. 250–258, 2003.

[23] M. W. Shrader, J. Parvizi, and D. G. Lewallen, "The use of a constrained acetabular component to treat instability after total hip arthroplasty," *The Journal of Bone & Joint Surgery—American Volume*, vol. 85, no. 11, pp. 2179–2183, 2003.

[24] R. J. K. Khan, D. Fick, R. Alakeson et al., "A constrained acetabular component for recurrent dislocation," *The Journal of Bone and Joint Surgery—British Volume*, vol. 88, no. 7, pp. 870–876, 2006.

[25] E. Bigsby, M. R. Whitehouse, G. C. Bannister, and A. W. Blom, "The medium term outcome of the Omnifit constrained acetabular cup," *HIP International*, vol. 22, no. 5, pp. 505–510, 2012.

[26] K. R. Berend, A. V. Lombardi Jr., T. H. Mallory, J. B. Adams, J. H. Russell, and K. L. Groseth, "The long-term outcome of 755 consecutive constrained acetabular components in total hip arthroplasty: examining the successes and failures," *Journal of Arthroplasty*, vol. 20, supplement 3, no. 3, pp. 93–102, 2005.

[27] W. H. Harris, "Traumatic arthritis of the hip after dislocation and acetabular fractures: treatment by mold arthroplasty. An end-result study using a new method of result evaluation," *The Journal of Bone and Joint Surgery—American Volume*, vol. 51, no. 4, pp. 737–755, 1969.

[28] P. Marchetti, R. Binazzi, V. Vaccari et al., "Long-term results with cementless Fitek (or Fitmore) cups," *Journal of Arthroplasty*, vol. 20, no. 6, pp. 730–737, 2005.

[29] J. G. DeLee and J. Charnley, "Radiological demarcation of cemented sockets in total hip replacement," *Clinical Orthopaedics and Related Research*, vol. 121, pp. 20–32, 1976.

[30] G. S. Tompkins, J. J. Jacobs, L. R. Kull, A. G. Rosenberg, and J. O. Galante, "Primary total hip arthroplasty with a porous-coated acetabular component: seven-to-ten-year results," *The Journal of Bone & Joint Surgery—American Volume*, vol. 79, no. 2, pp. 169–176, 1997.

[31] F. Leiber-Wackenheim, B. Brunschweiler, M. Ehlinger, A. Gabrion, and P. Mertl, "Treatment of recurrent THR dislocation using of a cementless dual-mobility cup: a 59 cases series with a mean 8 years' follow-up," *Orthopaedics and Traumatology: Surgery and Research*, vol. 97, no. 1, pp. 8–13, 2011.

[32] M. Hamadouche, D. J. Biau, D. Huten, T. Musset, and F. Gaucher, "The use of a cemented dual mobility socket to treat recurrent dislocation," *Clinical Orthopaedics and Related Research*, vol. 468, no. 12, pp. 3248–3254, 2010.

[33] F. L. Langlais, M. Ropars, F. Gaucher, T. Musset, and O. Chaix, "Dual mobility cemented cups have low dislocation rates in THA revisions," *Clinical Orthopaedics and Related Research*, vol. 466, no. 2, pp. 389–395, 2008.

[34] O. Guyen, V. Pibarot, G. Vaz, C. Chevillotte, and J. Béjui-Hugues, "Use of a dual mobility socket to manage total hip arthroplasty instability," *Clinical Orthopaedics and Related Research*, vol. 467, no. 2, pp. 465–472, 2009.

[35] S. Tarasevicius, M. Busevicius, O. Robertsson, and H. Wingstrand, "Dual mobility cup reduces dislocation rate after arthroplasty for femoral neck fracture," *BMC Musculoskeletal Disorders*, vol. 11, article 175, 2010.

[36] J.-M. Philippeau, J.-M. Durand, J.-P. Carret, S. Leclercq, D. Waast, and F. Gouin, "Dual mobility design use in preventing total hip replacement dislocation following tumor resection," *Orthopaedics & Traumatology, Surgery & Research*, vol. 96, no. 1, pp. 2–8, 2010.

[37] R. J. M. Sanders, B. A. Swierstra, and J. H. M. Goosen, "The use of a dual-mobility concept in total hip arthroplasty patients with spastic disorders: no dislocations in a series of ten cases at midterm follow-up," *Archives of Orthopaedic and Trauma Surgery*, vol. 133, no. 7, pp. 1011–1016, 2013.

[38] M. J. Anderson, W. R. Murray, and H. B. Skinner, "Constrained acetabular components," *Journal of Arthroplasty*, vol. 9, no. 1, pp. 17–23, 1994.