Hindawi
Advances in Orthopedic Surgery
Volume 2017, Article ID 6514654, 7 pages
https://doi.org/10.1155/2017/6514654

Clinical Study

Transosseous Repair of Root Tears of the Lateral Meniscus: Operative Technique and Short-Term Clinical Follow-Up of 28 Patients

Arne Driessen,[1] Maurice Balke,[2] William James White,[3] Markus Fink,[2] Marcel Betsch,[1] Matthias Fröhlich,[4] Paola Koenen,[4] and Jürgen Höher[2]

[1] *Department of Orthopaedic Surgery, RWTH Aachen University, Pauwelsstrasse 30, 52074 Aachen, Germany*
[2] *Sportsclinic Cologne, Cologne-Merheim Medical Centre (CMMC), Witten/Herdecke University, Campus Cologne-Merheim, Ostmerheimerstr. 200, 51109 Köln, Germany*
[3] *Department of Trauma and Orthopaedic Surgery, Chelsea and Westminster Hospital, NHS Foundation Trust, 369 Fulham Road, London SW10 9NH, UK*
[4] *Department of Orthopaedic Surgery, Traumatology and Sports Traumatology, Cologne-Merheim Medical Centre (CMMC), Witten/Herdecke University, Campus Cologne-Merheim, Ostmerheimerstr. 200, 51109 Cologne, Germany*

Correspondence should be addressed to Jürgen Höher; jhoeher@t-online.de

Received 16 October 2016; Revised 11 February 2017; Accepted 1 March 2017; Published 31 May 2017

Academic Editor: Christoph Castellani

An avulsion of the posterior tibial insertion of the lateral meniscus occurs during rotational distortion of the knee and can be associated with a tear of the anterior cruciate ligament (ACL). We performed a follow-up of 28 patients who, following anatomical ACL reconstruction using the ipsilateral semitendinosus graft, underwent either transosseous repair of the posterior lateral meniscus root ($n = 14$) or no intervention ($n = 14$). The meniscus root tears were classified as Forkel I lesions. All patients were examined 6 months after surgery and undertook scoring using International Knee Documentation Committee Score (IKDC). Comparing the repair group with the no repair group the subjective IKDC 6 months after surgery was 75,72% (±1,019) and 75,56 (±1,058). Regarding the objective IKDC 8 × A (57,1%) and 6 × B (42,9%) could be ascertained in the repair group whereas 6 × A (42,9%), 6 × B (42,9%), and 2 × C (14,3%) scoring could be ascertained in the no repair group. It remains unclear if surgery on type Forkel I PLMRT provides benefits compared to the nonsurgical procedures as in both groups stability might occur. The purpose of this article was to report the outcome of surgical repair of lateral meniscus root tears.

1. Introduction

An avulsion of the posterior tibial insertion of either the medial or lateral meniscus is thought to be a relatively rare clinical diagnosis.

Unlike posterior root tears of the medial meniscus which generally occur as a consequence of meniscal tissue degeneration and increased compartmental load, posterior lateral meniscus root tears (PLMRTs) usually occur following traumatic rotational distortion of the knee and are commonly associated with an anterior cruciate ligament (ACL) tear [1–5].

Several studies have shown that approximately 1 out of 10 patients with ACL injury also sustain a PLMRT [2–4, 6–8].

Three different classification systems have been published to describe the pattern of the posterior lateral meniscal root tear (PLMRT) and adjacent structures [2, 9, 10] such as the meniscofemoral ligaments (MFLs).

By definition meniscal root tears are specified as a radial tear of the meniscus tissue in close proximity (1 cm) to the insertion or an avulsion of the meniscotibial ligament (root ligament) [11].

But the diagnosis can easily be missed in initial radiological and arthroscopic assessment and can often be diagnosed during arthroscopic ACL reconstruction.

Clinically a PLMRT shows similar symptoms as other meniscal injuries such as tenderness in the joint line and

positive meniscus tests and therefore cannot be distinguished clinically from other meniscal pathologies [2, 12–14].

MRI findings, such as the meniscal ghost sign (sagittal plane), extrusion (coronal plane), and vertical or linear defect, have been shown to be more sensitive [15–17].

Arthroscopic assessment of an avulsion of the posterior horn of the lateral meniscus is technically challenging; however, it has been shown to be the most accurate tool for diagnosis [11, 13, 18]. Assessment should include inspection and examination of the posterior lateral (and medial) meniscus with a probe in order to proof the integrity of the meniscus and adjacent structures.

The importance of an intact lateral meniscus as a secondary stabilizer of the knee under pivot-shift loading has been described [19] explaining an increase in instability in an ACL deficient knee.

Furthermore, a higher rate of cartilage degradation associated with PLMRT has been reported [8] and increased contact pressures and decreased contact areas correlating with the existence of PLMRT have been demonstrated [20–23].

Only recently biomechanical studies have been published underlining the importance of the meniscofemoral ligament (MFL) in stabilizing the meniscus root [21].

Therefore, repair of the ACL and effective stabilization of the meniscus root seem to be important to first prevent increased pressure on the lateral and medial compartment [24] and to secondary prevent cartilage degradation [8].

If this stability can be achieved by autologous healing or if surgical fixation is necessary is currently discussed in literature and seems to depend on the type and location of the tear as well as concomitant injured structures such as the MFL [11, 21].

With this study a clinical follow-up of 28 patients with presence of a PLMRT who underwent ACL reconstruction was performed and of which 14 patients received a transosseous repair (pull-out technique) of the posterior horn of the lateral meniscus.

The purpose of this study was to compare and report the technique and the outcome of surgical repair of lateral meniscus root tears.

2. Methods

The patients who took part in this study presented to the department between February 2013 and November 2014 with an acute traumatic knee injury diagnosed as ACL rupture. Patients with radiographically evident arthritic changes, other concomitant injuries (e.g., medial collateral ligament rupture, medial meniscus tear), and old ACL tear and laxity (absence of acute injury) were excluded. All patients received preoperative scoring and standard clinical examination such as Lachman test, anterior and posterior drawer, Rolimeter test, stability of collateral ligaments, standard meniscus tests (McMurray, Apley), patella test (Zohlen sign), and MRI imaging. A minimum time between injury and surgery of 40 days but no longer than 12 weeks was obtained. All patients received physiotherapy before surgery and the standard rehabilitation protocol after surgery, knee brace treatment for 6 weeks postoperatively including 4-week limitation of flexion 90° and for further 2 weeks with no limitation of flexion.

Performing surgery included a complete diagnostic arthroscopic examination of the knee joint including medial and lateral intra-articular structures of the knee. In all 28 patients the diagnosis of an ACL rupture and the PLMRT (Type I according to Forkel and Petersen) [9] was confirmed.

All patients were reexamined 6 months after surgery with International Knee Documentation Committee Score (IKDC) also obtained.

2.1. Operation Technique. All patients were operated on using a standard ACL reconstruction technique using the quadrupled semitendinosus tendon of the ipsilateral leg with hybrid fixation on the femur (interference screw (MegaFix®) and FlippTack® (Storz, Germany)) and on the tibia (interference screw (MegaFix) and standard cortical screw).

Furthermore, in all 28 patients the PLMRT was diagnosed during arthroscopy (Type I according to Forkel avulsion of the root at the plateau of the tibia with intact MFL) and decision for transosseous pull-out repair with the technique described was made for 14 by flipping a coin.

Prior commencing reconstructive surgery an arthroscopic diagnostic examination of the knee should be performed including a careful examination of the medial and lateral meniscal root with a probe. The "lift-up test" is described to be positive if the posterior meniscus root can be lifted and displaced anteriorly.

After drilling the tibial and femoral tunnel for the tendon transplant, the ACL reconstruction was extended by the PLMRT repair.

The posterior lateral meniscal root was reinserted using a transtibial repair technique by using a suture punch to shuttle the FiberWire® (Arthrex, USA) through the meniscal tissue twice lancing from the inferior to the superior part of the meniscus.

A standard PCL drill guide with an ACL tip aimer was used to place a K-wire in the anatomical footprint (anterior of the PCL, anterolateral of the medial posterior root attachment, and posteromedial of the lateral tibial eminence) [25] of the posterior lateral meniscus horn in order to create a separate tibial tunnel.

The suture was shuttled through the newly drilled tibial tunnel and knotted on the anterior tibial cortex using a FlippTack, whilst the tension of the suture was arthroscopically monitored.

Figures 1–7 show the fixation procedure of the PLMRT and provide step-by-step explanations.

2.2. Clinical Follow-Up. We evaluated 28 patients (14 without and 14 with repair of the PLMRT) who underwent ACL reconstruction using clinical evaluation and the International Knee Documentation Committee (IKDC). We managed to examine all patients 6 months after surgery. All patients received physiotherapy before surgery and the standard rehabilitation protocol after surgery, knee brace treatment for 6 weeks postoperatively including 4-week limitation of

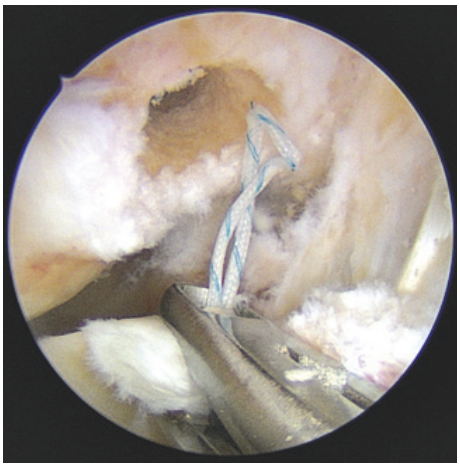

Figure 1: After drilling the femoral tunnel (ACL) a FiberWire was passed through the posterior horn of the lateral meniscus with a suture punch (ArthroPass™ II). The meniscus is perforated twice with suture punch in order to shuttle the FiberWire in two different locations (anterior and posterior part of the lateral meniscus root) through the meniscus.

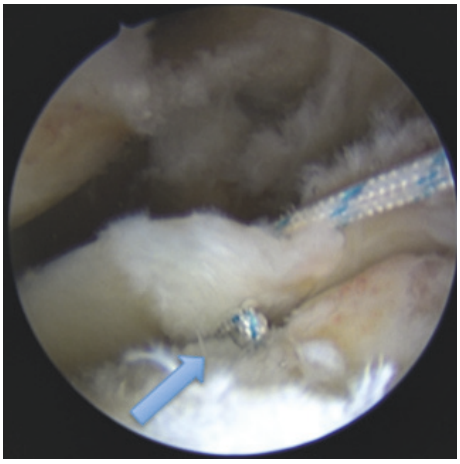

Figure 2: Both suture ends exit the meniscus on the superior part of the posterior horn and were carefully tightened to shorten the inferior suture loop (arrow) entering the meniscal tissue.

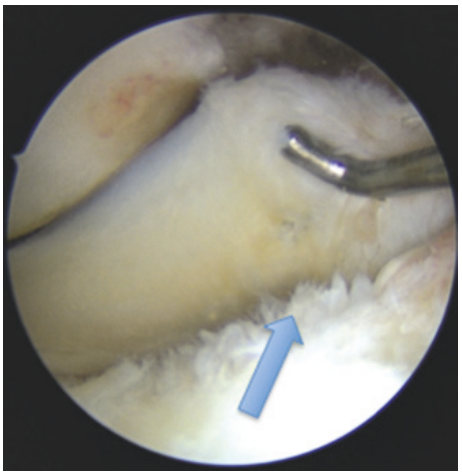

Figure 3: The inferior part should be checked for correct position of the suture and a sufficient meniscus tissue bridge in order to prevent further tearing of the meniscal tissue. The arrow refers to the tissue bridge.

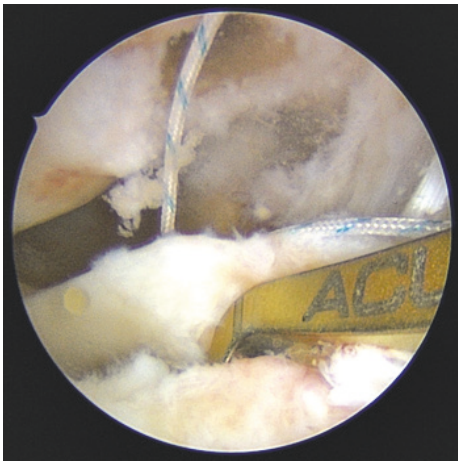

Figure 4: A standard PCL drill guide with an ACL tip aimer was used to place a K-wire in the anatomical footprint in order to create a separate tibial tunnel. The tunnel is drilled with a 4,5-diameter standard drill.

flexion 90° and for further 2 weeks with no limitation of flexion.

This retrospective analysis of 28 patients was approved by the ethics committee of the University of Witten/Herdecke under number 148/2016.

2.3. Statistical Analysis. Collected data were analyzed by the unpaired t-test to assess the differences between groups using GraphPad Prism Version 6.0. p values were considered statistically significant at $p < 0.05$.

3. Results

Arthroscopically there were no further ligamentous or meniscal pathologies in any of the patients included in this study. Six patients were found to have minor chondral defects of different stages (grades I and II medial femoral condyle, medial tibial plateau, and trochlear groove).

The intervention group consists of 8 males, 7 females, and 7 right and 7 left knees. The no intervention group consists of 9 males, 5 females, and 6 right and 6 left knees.

Comparing the repair group with the no intervention group the subjective IKDC 6 months after surgery was 75,72 ± 1,019 and 75,56 ± 1,058, respectively (p value 0,9118 ($p < 0.05$) revealed no significant differences). Regarding the objective IKDC 8 × A (57,1%) and 6 × B (42,9%) could be ascertained in the repair group and 6 × A (42,9%), 6 × B (42,9%), and 2 × C (14,3%) scoring in the no repair group.

The results of the scores are summarized in Table 1.

Table 1: Demographics of the IKDC score for both groups. Mean value from 14 patients 6 months after surgery (p value to compare variances was not significant).

	Intervention for PLMRT repair		No intervention despite having PLMRT		p value
	Subjective IKDC	Objective IKDC	Subjective IKDC	Objective IKDC	
IKDC 6 months after surgery	75,72 ± 1,019, $n = 14$	8 × A (57,1%) 6 × B (42,9%)	75,56 ± 1,058, $n = 14$	6 × A (42,9%), 6 × B (42,9%) 2 × C (14,3%)	0,9118 ($p < 0.05$) ns
Male/female (n)	8/6		9/5		
Right/left (n)	7/7		8/6		
PLMRT	14		14		

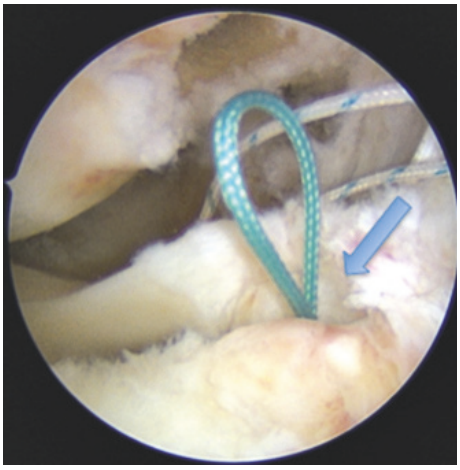

Figure 5: A suture loop (green colour) is passed through the tunnel (arrow) using a loop end wire. A probe might be used to enlarge the intra-articular loop.

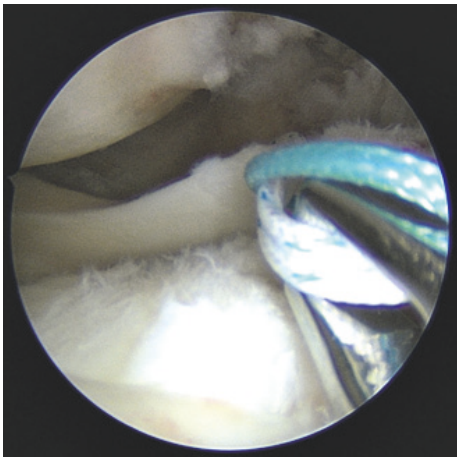

Figure 6: Suture forceps are used to shuttle the FiberWire through the suture loop (green colour) located in the tibial tunnel.

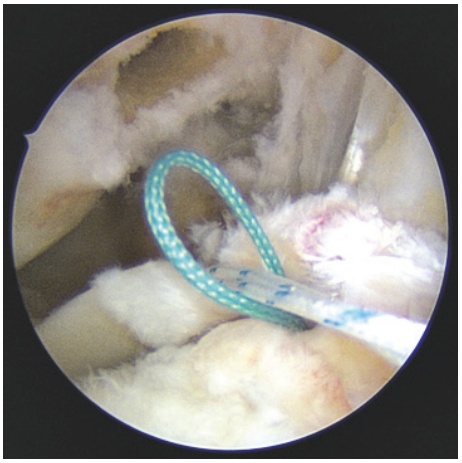

Figure 7: The suture loop is retracted through the tunnel pulling both ends of the FiberWire onto the anterior tibial cortex. The suture is knotted on the anterior tibial cortex using a FlippTack while monitoring arthroscopically the tension of the suture.

Six months after surgery none of the patients in each group had a pivot-shift or a side-to-side difference of more than 3 mm anterior translation on performing the Rolimeter test. None of the patients complained a feeling of instability 6 months after surgery.

The results of the scores are summarized in Table 1.

4. Discussion

The term "meniscal root tear" is used to name the insertion of the posterior horn (and the root ligaments) of either the medial or lateral meniscus on the tibial plateau [7, 26] suggesting an avulsion of the meniscus insertion at the tibia plateau.

According to the classification published by Forkel and Petersen, Type I is an avulsion of the root at the plateau of the tibia with intact MFL, Type II is a radial tear of the posterior

horn of the lateral meniscus with an intact MFL, and Type III is a complete injury of the posterior horn of the lateral meniscus with rupture of the MFL [9].

The biomechanical consequences of a lateral meniscus root tear in the compartment as described earlier show that the presence of the meniscofemoral ligament is crucial [27, 28]. It could be shown that for different angles in knee flexion an avulsion of the posterior lateral meniscal root attachment with a deficient MFL resulted in significantly decreased lateral contact area and increased pressure compared to the intact state. Otherwise, a root avulsion with intact MFL did not significantly affect contact mechanics [21].

We therefore chose those patients with Type I PLMRT and intact MFL to find out if a difference in clinical outcome can be carved out between groups, repair and no repair. Special interest was paid to this group as current literature reports undoubtedly about meniscal instability in the absence of an MFL whereas it might be questioned if surgical intervention in the presence of an MFL is beneficial for the patient. After intraoperative arthroscopically confirmed PLMRT patients were selected by tossing a coin into the repair or no repair group. Despite the extended operation time and therefore longer tourniquet time no disadvantage in short-term outcome for rehabilitation was found for the intervention group.

As different surgical techniques such as side-to-side suture, suture anchors, and transtibial pull-out suture have been described in literature, the most common for PLMRT with avulsion of the tibial insertion (the transtibial repair with a pull-out suture transosseous technique) was recommended [6, 29, 30]. Therefore, this technique was used in our patients. To prevent elongation of the suture FibreWire was used in a two-suture technique to fix the PLMRT onto the tibial plateau [31].

The importance of an adequate stabilization of the PLMRT is justified with several studies showing increased pressure in the compartment and therefore could determine onset and progression of osteoarthritis [21, 24, 27, 28, 32].

The contact pressure in the lateral compartment increases in radial tears and root avulsions and decreases after transosseous pull-out refixation as shown in a cadaveric knee setup by Forkel et al. [28, 33].

A recent review published by Feucht et al. found evidence for a prevention of progress of osteoarthritis during short-term follow-up in patients who have undergone an arthroscopic transtibial pull-out repair [22].

But whether repair can prevent or delay osteoarthritis has not been currently proven. Furthermore, it has not been shown if those PLMRTs with an intact MFL and therefore remaining moderate stability need surgical intervention or not.

Without any doubt damaged structures leading to instability and therefore promoting cartilage damage should be repaired. But the importance of the right selection of patients and pattern of injury seems to play a role as there might be evidence that in the presence of PLMRT but intact MFL no repair might be needed.

Hence, even spontaneous healing without surgical refixation of the posterior root tear might occur as the vascular blood supply of the anterior and posterior horn has been reported to be adequate [34, 35]. In addition, due to the surgical trauma of the ACL reconstruction and therefore the presence of growth factors, healing of the meniscus and its insertion (if avulsed) might be induced and result in "fixation by healing" [36–38]. Also the MFL which prevents dislocation to a certain extend was present in all patients. Furthermore, the postoperative treatment with bracing, limitation of flexion, and partial weight bearing might enhance the healing of the tendon graft and of the meniscus.

The most important issue regarding a PLMRT seems to be the adequate stability on the tibial plateau achieved either by surgery or by healing. Several (other) biomechanical studies have been published showing that both the repair of the PLMRT and the adequate operative technique are important to prevent further damage by meniscal instability and therefore decrease contact forces especially in the lateral compartment of the knee.

Regarding the short-term results of this study we can declare that in both groups physiotherapy and rehabilitation are not delayed by conservative nor meniscal repair but long-term results and bigger numbers are needed to carve out specific differences.

On follow-up two patients went on to have further surgery: one for suture granuloma in the area of the tibial tunnel from the ACL reconstruction at 24 months and one went on to have arthroscopically partial resection of the posterior horn of the lateral meniscus for persistent pain (most likely caused by a radial tear) at 13 months.

According to results from postsurgical MRI imaging significantly less extrusion of the lateral meniscus could be observed after repair [2, 5] whereas generally more frequent meniscus extrusion can be observed in medial meniscus root tears and repair due to its degenerative origin.

In accordance with these results the MRI results of the patient who underwent another knee arthroscopy 13 months after surgery show no dislocation or extrusion of the repaired meniscus.

According to the functional outcome literature, combined PLMRT repair and ACL reconstruction have been shown to lead to an increase in clinical scores postoperatively [2, 6]. But at the same time studies having compared the surgical with nonsurgical procedure for PLMRT report no significant differences in clinical outcome [39].

However, patients evaluate the whole knee and not the ACL reconstruction or the PLMRT, which is why these results are not distinguishable. But most important is that all patients restored a good functional level comparable to other studies [39].

Despite the fact that the results presented are short-term follow-up results within the phase of intense rehabilitation no significant differences were revealed. As usually 6 months after surgery patients start to return slowly to sports raising their level of activity, surely following these patients for 12 months and 24 months for evaluation is desirable. Further

limitations of this investigation are the small number of patients in both groups, the short follow-up period, no standard MRI follow-up, concomitant injuries such as the ACL tear following surgical procedures, and the clinical evaluation with only one score analyzed.

5. Conclusion

This study demonstrates safe and good short-term functional and patient outcome results from a limited case series following ACL reconstruction and transosseous repair of Forkel Type I PLMRTs using a pull-out technique. Despite the fact that the ACL reconstruction and the transosseous meniscal repair or no repair were not distinguishable from patient evaluation, patients in both groups restored a good and satisfying level of activity without significant complication in this short-term evaluation.

However, further studies to assess the long-term clinical outcomes and subsequent reduction in the development of osteoarthritis compared to nonsurgical treatment risk of osteoarthritis need to be carried out.

Abbreviations

ACL: Anterior cruciate ligament
IKDC: International Knee Documentation Committee
MFL: Meniscofemoral ligament
MRI: Magnetic resonance imaging
PCL: Posterior cruciate ligament
PLMRT: Posterior lateral meniscus root tear.

Ethical Approval

This study was carried out in accordance with the declaration of Helsinki and within appropriate ethical framework.

Disclosure

Parts of the results in this article were presented at the ESSKA Congress 2014 in Amsterdam, NL.

Conflicts of Interest

The authors declare that they have no conflicts of interest.

Authors' Contributions

Jürgen Höher and Arne Driessen diagnosed the ACL tear and the PLMRT and operated on all patients. Markus Fink, Paola Koenen, and Matthias Fröhlich were examining the patients and evaluating them clinically. Maurice Balke, William James White, Markus Fink, Matthias Fröhlich, Marcel Betsch, and Arne Driessen were providing scientific support and valuable advice working on the manuscript. Jürgen Höher and Maurice Balke furthermore helped analyzing and interpreting literature and data. Arne Driessen, Maurice Balke, and Jürgen Höher did perform the literature review and wrote the manuscript. William James White, Paola Koenen, Maurice Balke, and Marcel Betsch helped to proofread the manuscript, revising it critically and providing generous technical support with figures and tables. All authors have read and approved the final manuscript.

Acknowledgments

The authors thank Tim Poersch and his team for crucial support in organizing and executing advanced training courses and scientific meetings.

References

[1] J. M. Brody, H. M. Lin, M. J. Hulstyn, and G. A. Tung, "Lateral meniscus root tear and meniscus extrusion with anterior cruciate ligament tear," *Radiology*, vol. 239, no. 3, pp. 805–810, 2006.

[2] J. H. Ahn, Y. S. Lee, J. C. Yoo, M. J. Chang, S. J. Park, and Y. R. Pae, "Results of Arthroscopic All-Inside Repair for Lateral Meniscus Root Tear in Patients Undergoing Concomitant Anterior Cruciate Ligament Reconstruction," *Arthroscopy*, vol. 26, no. 1, pp. 67–75, 2010.

[3] M. J. Feucht, S. Bigdon, G. Bode et al., "Associated tears of the lateral meniscus in anterior cruciate ligament injuries: risk factors for different tear patterns," *Journal of Orthopaedic Surgery and Research*, vol. 10, no. 1, article 34, 2015.

[4] P. Forkel, S. Reuter, F. Sprenker et al., "Different patterns of lateral meniscus root tears in ACL injuries: application of a differentiated classification system," *Knee Surgery, Sports Traumatology, Arthroscopy*, vol. 23, no. 1, pp. 112–118, 2014.

[5] J. H. Koo, S.-H. Choi, S. A. Lee, and J. H. Wang, "Comparison of medial and lateral meniscus root tears," *PLoS ONE*, vol. 10, no. 10, Article ID e0141021, 2015.

[6] L. Anderson, M. Watts, O. Shapter et al., "Repair of radial tears and posterior horn detachments of the lateral meniscus: minimum 2-year follow-up," *Arthroscopy*, vol. 26, no. 12, pp. 1625–1632, 2010.

[7] J. M. Brody, M. J. Hulstyn, B. C. Fleming, and G. A. Tung, "The meniscal roots: gross anatomic correlation with 3-T MRI findings," *American Journal of Roentgenology*, vol. 188, no. 5, pp. W446–450, 2007.

[8] A. Kan, M. Oshida, S. Oshida, M. Imada, T. Nakagawa, and S. Okinaga, "Anatomical significance of a posterior horn of medial meniscus: the relationship between its radial tear and cartilage degradation of joint surface," *Sports Medicine, Arthroscopy, Rehabilitation, Therapy and Technology*, vol. 2, no. 1, article 1, 2010.

[9] P. Forkel and W. Petersen, "Posterior root tear fixation of the lateral meniscus combined with arthroscopic ACL double-bundle reconstruction: technical note of a transosseous fixation using the tibial PL tunnel," *Archives of Orthopaedic and Trauma Surgery*, vol. 132, no. 3, pp. 387–391, 2012.

[10] R. V. West, J. G. Kim, D. Armfield, and C. D. Harner, "Lateral meniscal root tears associated with anterior cruciate ligament injury: classification and management (SS-70)," *Arthroscopy: The Journal of Arthroscopic & Related Surgery*, vol. 20, pp. e32–e33, 2004.

[11] J. H. Ahn, Y. S. Lee, J.-Y. Chang, M. J. Chang, S. S. Eun, and S. M. Kim, "Arthroscopic all inside repair of the lateral meniscus root tear," *Knee*, vol. 16, no. 1, pp. 77–80, 2009.

[12] R. Rossi, F. Dettoni, M. Bruzzone, U. Cottino, D. G. D'Elicio, and D. E. Bonasia, "Clinical examination of the knee: know your tools for diagnosis of knee injuries," *Sports Medicine,*

Arthroscopy, Rehabilitation, Therapy and Technology, vol. 3, no. 1, article 25, 2011.

[13] D. Vyas and C. D. Harner, "Meniscus root repair," *Sports Medicine and Arthroscopy Review*, vol. 20, no. 2, pp. 86–94, 2012.

[14] A. Driessen, M. Balke, C. Offerhaus et al., "The fabella syndrome—a rare cause of posterolateral knee pain: a review of the literature and two case reports," *BMC Musculoskeletal Disorders*, vol. 15, no. 1, article 100, 2014.

[15] S.-H. Choi, S. Bae, S. K. Ji, and M. J. Chang, "The MRI findings of meniscal root tear of the medial meniscus: emphasis on coronal, sagittal and axial images," *Knee Surgery, Sports Traumatology, Arthroscopy*, vol. 20, no. 10, pp. 2098–2103, 2012.

[16] H.-J. Park, S. S. Kim, S.-Y. Lee et al., "Medial meniscal root tears and meniscal extrusion transverse length ratios on MRI," *British Journal of Radiology*, vol. 85, no. 1019, pp. e1032–e1037, 2012.

[17] C. R. Costa, W. B. Morrison, and J. A. Carrino, "Medial meniscus extrusion on knee MRI: is extent associated with severity of degeneration or type of tear?" *American Journal of Roentgenology*, vol. 183, no. 1, pp. 17–23, 2004.

[18] W. Petersen and T. Zantop, "Avulsion injury to the posterior horn of the lateral meniscus. Technique for arthroscopic refixation," *Unfallchirurg*, vol. 109, no. 11, pp. 984–987, 2006.

[19] T. B. Shybut, C. E. Vega, J. Haddad et al., "Effect of lateral meniscal root tear on the stability of the anterior cruciate ligament-deficient knee," *American Journal of Sports Medicine*, vol. 43, no. 4, pp. 905–911, 2015.

[20] G. E. Ode, G. S. Van Thiel, S. A. McArthur et al., "Effects of serial sectioning and repair of radial tears in the lateral meniscus," *American Journal of Sports Medicine*, vol. 40, no. 8, pp. 1863–1870, 2012.

[21] A. G. Geeslin, D. Civitarese, T. L. Turnbull, G. J. Dornan, F. A. Fuso, and R. F. LaPrade, "Influence of lateral meniscal posterior root avulsions and the meniscofemoral ligaments on tibiofemoral contact mechanics," *Knee Surgery, Sports Traumatology, Arthroscopy*, vol. 24, no. 5, pp. 1469–1477, 2016.

[22] M. J. Feucht, J. Kühle, G. Bode et al., "Arthroscopic transtibial pullout repair for posterior medial meniscus root tears: a systematic review of clinical, radiographic, and second-look arthroscopic results," *Arthroscopy*, vol. 31, no. 9, pp. 1808–1816, 2015.

[23] D. E. Bonasia, P. Pellegrino, A. D'Amelio, U. Cottino, and R. Rossi, "Meniscal root tear repair: why, when and how?" *Orthopedic Reviews*, vol. 7, no. 2, 2015.

[24] H. R. C. Bao, D. Zhu, H. Gong, and G. S. Gu, "The effect of complete radial lateral meniscus posterior root tear on the knee contact mechanics: a finite element analysis," *Journal of Orthopaedic Science*, vol. 18, no. 2, pp. 256–263, 2013.

[25] R. F. LaPrade, S. G. Moulton, M. Nitri, W. Mueller, and L. Engebretsen, "Clinically relevant anatomy and what anatomic reconstruction means," *Knee Surgery, Sports Traumatology, Arthroscopy*, vol. 23, no. 10, pp. 2950–2959, 2015.

[26] A. M. Johannsen, D. M. Civitarese, J. R. Padalecki, M. T. Goldsmith, C. A. Wijdicks, and R. F. Laprade, "Qualitative and quantitative anatomic analysis of the posterior root attachments of the medial and lateral menisci," *American Journal of Sports Medicine*, vol. 40, no. 10, pp. 2342–2347, 2012.

[27] P. Forkel, M. Herbort, M. Schulze et al., "Biomechanical consequences of a posterior root tear of the lateral meniscus: stabilizing effect of the meniscofemoral ligament," *Archives of Orthopaedic and Trauma Surgery*, vol. 133, no. 5, pp. 621–626, 2013.

[28] P. Forkel, M. Herbort, F. Sprenker, S. Metzlaff, M. Raschke, and W. Petersen, "The biomechanical effect of a lateral meniscus posterior root tear with and without damage to the meniscofemoral ligament: efficacy of different repair techniques," *Arthroscopy—Journal of Arthroscopic and Related Surgery*, vol. 30, no. 7, pp. 833–840, 2014.

[29] R. Papalia, S. Vasta, F. Franceschi, S. D'Adamio, N. Maffulli, and V. Denaro, "Meniscal root tears: from basic science to ultimate surgery," *British Medical Bulletin*, vol. 106, no. 1, pp. 91–115, 2013.

[30] Y.-M. Kim and Y.-B. Joo, "Pullout failure strength of the posterior horn of the medial meniscus with root ligament tear," *Knee Surgery, Sports Traumatology, Arthroscopy*, vol. 21, no. 7, pp. 1546–1552, 2013.

[31] S. B. Rosslenbroich, J. Borgmann, M. Herbort, M. J. Raschke, W. Petersen, and T. Zantop, "Root tear of the meniscus: biomechanical evaluation of an arthroscopic refixation technique," *Archives of Orthopaedic and Trauma Surgery*, vol. 133, no. 1, pp. 111–115, 2013.

[32] K. D. Shelbourne, T. A. Roberson, and T. Gray, "Long-term evaluation of posterior lateral meniscus root tears left in situ at the time of anterior cruciate ligament reconstruction," *American Journal of Sports Medicine*, vol. 39, no. 7, pp. 1439–1443, 2011.

[33] C. M. LaPrade, K. S. Jansson, G. Dornan, S. D. Smith, C. A. Wijdicks, and R. F. LaPrade, "Altered tibiofemoral contact mechanics due to lateral meniscus posterior horn root avulsions and radial tears can be restored with in situ pull-out suture repairs," *The Journal of Bone & Joint Surgery—American Volume*, vol. 96, no. 6, pp. 471–479, 2014.

[34] S. P. Arnoczky and R. F. Warren, "Microvasculature of the human meniscus," *The American Journal of Sports Medicine*, vol. 10, no. 2, pp. 90–95, 1982.

[35] W. Petersen and B. Tillmann, "Structure and vascularization of the knee joint menisci," *Zeitschrift für Orthopädie und ihre Grenzgebiete*, vol. 137, no. 1, pp. 31–37, 1999 (German).

[36] S. A. Müller, A. Todorov, P. E. Heisterbach, I. Martin, and M. Majewski, "Tendon healing: an overview of physiology, biology, and pathology of tendon healing and systematic review of state of the art in tendon bioengineering," *Knee Surgery, Sports Traumatology, Arthroscopy*, vol. 23, no. 7, pp. 2097–2105, 2015.

[37] L. de Girolamo, E. Galliera, P. Volpi et al., "Why menisci show higher healing rate when repaired during ACL reconstruction? Growth factors release can be the explanation," *Knee Surgery, Sports Traumatology, Arthroscopy*, vol. 23, no. 1, pp. 90–96, 2015.

[38] J. Jorjani, D. Altmann, R. Auen, C. Koopmann, B. Lyutenski, and D. C. Wirtz, "Medium- to long-term follow-up after anterior cruciate ligament rupture and repair in healing response technique," *Zeitschrift für Orthopädie und Unfallchirurgie*, vol. 151, no. 6, pp. 570–579, 2013.

[39] F. Pan, S. Hua, and Z. Ma, "Surgical treatment of combined posterior root tears of the lateral meniscus and ACL tears," *Medical Science Monitor*, vol. 21, pp. 1345–1349, 2015.