Bifurcation tumours: Is endoscopic drainage sufficient?

MICHEL CREMER, JACQUES DEVIERE

HILAR TUMOURS INCLUDE CARCINOMAS of the hepatic duct (Klatskin's tumour) (1), gallbladder carcinoma and metastases located in the confluence. A tumour is type I when stricture is limited to the common hepatic duct, type II when both left and right hepatic ducts are involved, and type III when one or more sectorial ducts are involved (Figure 1).

The anatomical variations of the bile ducts around the confluence have been described by Couinaud (2) (Figure 2). They are important for precise diagnosis of the sectors or segments involved, but also for management. These variations are more difficult to recognize when the ducts are enlarged above the confluence.

Bifurcation tumours are extremely difficult to manage surgically. Extensive resection to cure the disease is certainly the best treatment when possible (3), as is liver transplantation, which can only be proposed for carefully selected young patients with invasive carcinoma of the bifurcation without extrahepatic spread.

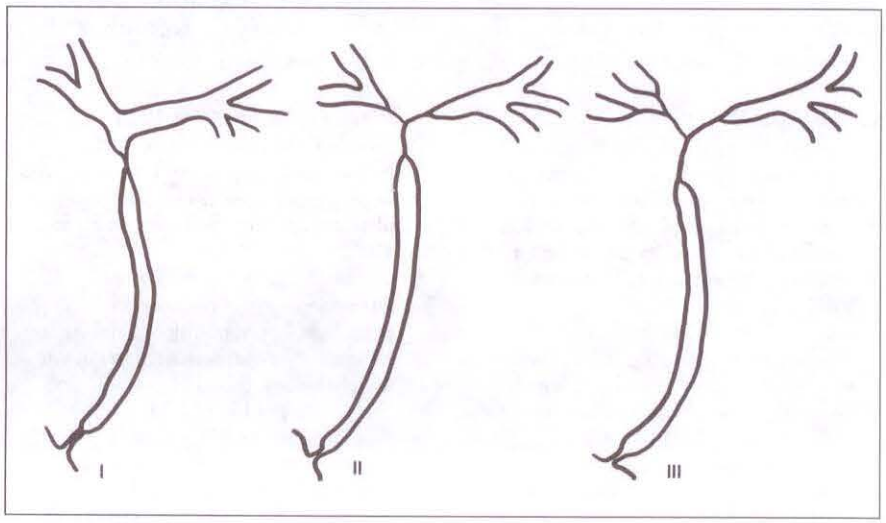

Figure 1) *Types of hilar strictures (bismuth)*

Palliative surgery, which is the usual outcome of laparotomy (4) and which is not easy nor completely successful, has a mortality rate between 10 and 15%. Moreover, when the patient survives after operation, the mean survival time is very short: between six and 16 months (5,6).

Finally, only a small minority of patients having a tumour of the confluence are candidates for surgery because of associated diseases often related to ageing, but also to extension of the tumour and the presence of lymph nodes.

The percutaneous-transhepatic approach to bifurcation tumours carries a high rate of severe complications, eg, peritoneal bile leakage, hemobilia and cholangitis, and failure to drain these leaves the patient even worse (7,8).

Although endoscopic stenting has

Hôpital Erasme – Université Libre de Bruxelles, Brussels, Belgium
Correspondence and reprints: Dr M Cremer, Hôpital Erasme – Université Libre de Bruxelles, Brussels, Belgium

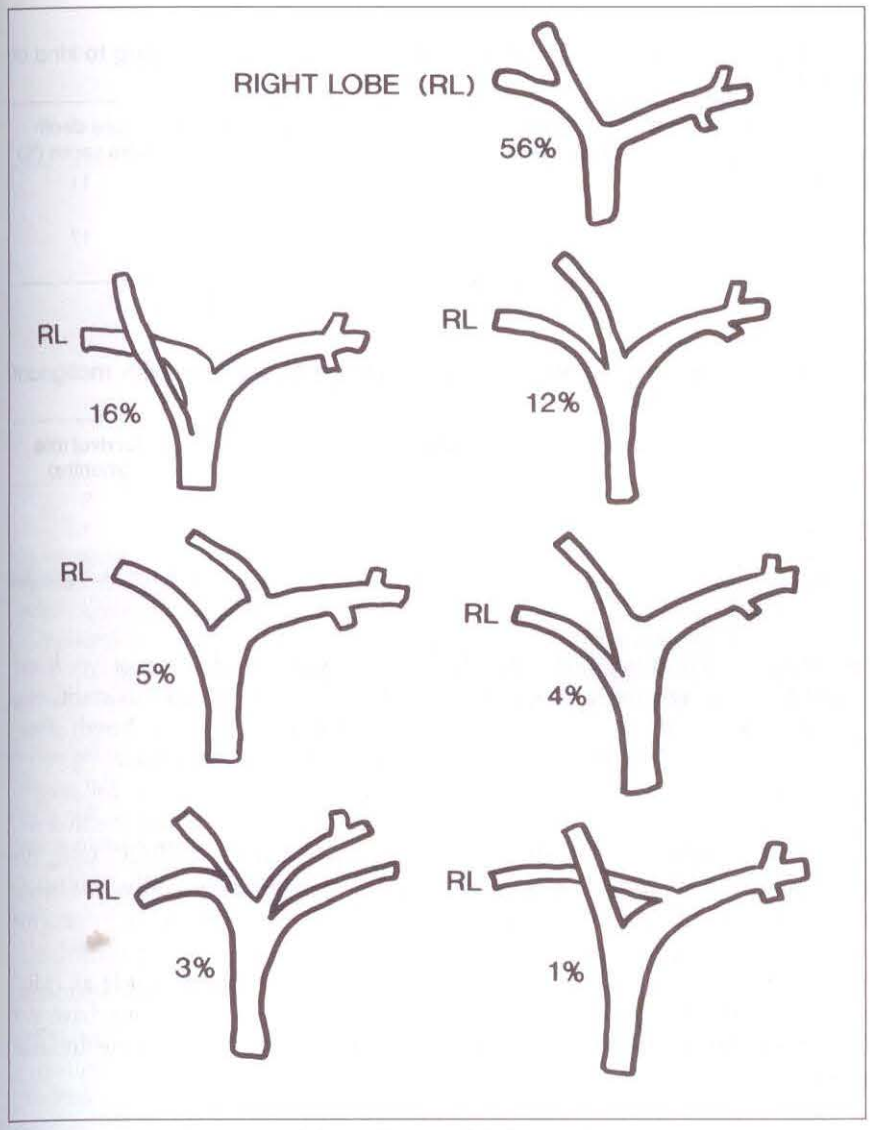

Figure 2) *Anatomical variations of the confluence of bile ducts (reference 2)*

TABLE 1
Cholangitis, 30 day mortality, median survival rate and rate of death from sepsis according to type of stricture and kind of treatment

	n	Early cholangitis (%)	30 day mortality (%)	Survival rate (months)	Late death from sepsis (%)
Type I					
1 stent	20	10%	0%	5.1	20%
Type II and III	50	30%	22%	5.9	38%
1 stent	24	38%	29%	5.3	46%
2 stents	24	17%	8%	6.5	13%

n Number of patients

become the method of choice for incurable malignant obstruction of the biliary tree, little enthusiasm has been elicited since the first endoscopic series. The high rate of cholangitis was related to incomplete drainage of both lobes of the liver for type II and III tumours, and most fatalities were caused by further septic shock (9).

In consideration of these poor results, the authors decided after 1984 to attempt aggressive management, ie, to drain both lobes immediately in patients with type II and III strictures, no longer waiting for cholangitis to occur in the undrained lobe.

The most frequently used stent for the hilar tumours in the authors' series is still the black 'sigmoid C shaped' polyamide endoprosthesis (Guerbet-Biotrol, Paris, France) with an internal diameter of 2.6 mm, an effective length of 11 cm, and a proximal bend adapted to the anatomy of the intrahepatic ducts. Unlike the straight Amsterdam stent which does not conform to the anatomical angulation of the left hepatic duct at the confluence, the hilar Biotrol stent has an angulation at the proximal end designed specifically for use in hilar strictures, preventing dislocation from the left hepatic duct. The distal C shaped end prevents duodenal perforation, reported in rare instances with the straight stent. The left hepatic duct must be stented first for patients with type II or III strictures as access to the right is nearly always easier for anatomical reasons.

In one patient of four with type II and III strictures it is necessary to follow the percutaneous route to thread a guidewire through a stricture that cannot be reached by a transpapillary approach. An external-internal Ring catheter is left in place beside the first endoscopic stent. Two days later, a second stent is inserted using the 'rendezvous' transpapillary technique, alongside the percutaneous guidewire. This approach has reduced sepsis and 30 day mortality, resulting in longer survival rates (Table 1).

Furthermore, the authors observed that the lowest rate of late death from sepsis or jaundice occurred in the group of patients with the most invasive tumours (type II and III) that were completely treated. The rate of late death was paradoxically lower than in the group with type I strictures. Higher rates were seen in patients with incomplete drainage (Table 2).

Late complications of endoscopic internal biliary drainage for the 59 patients who survived more than one month were mostly related to clogging of the stent (27%), with a mean stent survival time of 4.8 months. Dislocation (8%) and breakage of the stent (2%) were observed initially with

straight Amsterdam stents but not with the bend-type stent, which better fits the left hepatic duct. Cholecystitis was observed in 34 patients.

The results using this type of active management of hilar tumours are as good as those obtained for palliative treatment of pancreatic cancer (Table 3).

The present and the future are concerned with the self-expanding metallic stents (18, 24 and 30 French), for which little endoscopic experience has been obtained since the work of the European Multicentric Study Group in May 1989 (104 patients). Technical problems for type II and III hilar strictures remain, for which stents must be inserted simultaneously on both sides of the confluence.

Percutaneous transhepatic management with these 'wallstents' has shown secondary involvement of the stent by the tumour, but up to now few patients have been treated with two wallstents, and only by the preventative percutaneous approach.

TABLE 2
Cholangitis, 30 day mortality and median survival rate according to kind of treatment

Type II and III 2 stents	n	Early cholangitis (%)	30 day mortality (%)	Survival rate (months)	Late death from sepsis (%)
Endoscopic route only	18	11	11	7.4	11
Endoscopic and percutaneous	6	34	0	3.7	17

TABLE 3
Results of endoscopic internal biliary drainage in patients with malignant strictures of the bile ducts

	Success rate (%)	Cholangitis (%)	30 day mortality (%)	Survival rate (months)
Pancreas	95	10	2	8
Hilar type I	92	12	3	7
Hilar type II and III	89	17	8	6

CONCLUSION

Endoscopic and combined percutaneous-endoscopic transpapillary stenting with multiple large endoprostheses has a high technical success rate (97%), and is a palliative method of treatment for hilar tumours for which results are poor but strictly comparable to surgical palliation.

As long as endoscopic retrograde cholangiopancreatography (ERCP) is mandatory for every patient with obstructive jaundice and suspicion of hilar tumour, immediate drainage must be performed to avoid iatrogenic cholangitis. Biliary drainage is in fact 'preoperative' for only a minority of patients for whom curative resection or liver transplantation could be considered.

Percutaneous drainage of type II and III tumours has a higher mortality rate (30%) and a lower mean length of survival (two to four months).

The main rule to be followed is drainage of both lobes of the liver immediately following ERCP, using the rendezvous technique only after failure to thread a guidewire through one of the strictures.

Additional therapy such as radiotherapy and chemotherapy have not proved as useful following internal biliary drainage.

REFERENCES

1. Klatskin G. Adenocarcinoma of the hepatic duct at its bifurcation within the porta hepatis: An unusual tumour with destructive clinical and pathological features. Am J Med 1965;38:241-56.
2. Couinaud C. Le Foie. Etudes Anatomiques et Chirurgicales. Paris: Masson, 1957:464-79.
3. Launois B, Campion JP, Brissot P. Carcinoma of the hepatic hilus. Surgical management and the case for resection. Am Surg 1979;190:151-3.
4. Bismuth M, Dunham F, Oulsis A, et al. Complications tardives de l'endoscopie diagnostique et opératoire des voies bilio-pancréatiques. Acta Gastroenterol Belg 1981;44:396-403.
5. Perissat J, Diard F, Gouffrant JM, Bobois JP, Doutre LP. Cancer de la voie biliaire principale. Intérêt de la cholangiographie transpariétohépatique pré-opératoire. A propos de 31 cas. Ann Chir 1975;29:281-8.
6. Huguet C, Nordlinger B, Ibanez L, Halcami F, Parc R, Loygue J. Traitement palliatif des cancers du confluent biliaire supérieur. Choix entre dérivation intrahépatique et intubation transtumorale. Nouv Rev Med 1982;11:1467-70.
7. Ferrucci JT, Mueller PR, Harbin WP. Percutaneous transhepatic biliary drainage: Technique, results and applications. Radiology 1980;135:1-13.
8. Hatfield ARW, Tobras R, Teislauche J, et al. Preoperative external biliary drainage in obstructive jaundice: A prospective controlled trial. Lancet 1982;ii:896-8.
9. Deviere J, Baize M, de Toeuf J, Cremer M. Long term follow-up of patients with hilar malignant stricture treated by endoscopic internal biliary drainage. Gastrointest Endosc 1988;34:95-101.