Simplifying sphincterotomy

RICHARD A KOZAREK, MD

RA KOZAREK. Simplifying sphincterotomy. Can J Gastroenterol 1993;7(6): 471-476. Simplifying sphincterotomy requires access to current technology. The latter includes both videoduodenoscopes and a full range of accessories. By far, the two technical advances most important in improving the success rate of sphincterotomy for the general endoscopist have been the development and use of hydrophilic polymer-coated wires to gain access to the biliary tree and the use of guidewires, in general, to maintain position and facilitate sphincterotome placement and proper position. Additional factors that define procedural success or failure include an adequately sedated patient, support staff and endoscopist experience, and presence of variant anatomy such as Billroth II or roux-en-y anastomoses.

Key Words: *Endoscopic retrograde cholangiopancreatography, Papillotomy, Sphincterotomy*

Simplification de la sphinctérotomie

RÉSUMÉ: Pour simplifier la sphinctérotomie, il faut avoir accès aux technologies modernes. Cela inclut les vidéoduodénoscopes et toute une gamme d'accessoires. Les deux percées technologiques qui ont de loin eu le plus favorable retentissement sur le taux de réussite de la sphinctérotomie ont été la mise au point et le recours à des fils enduits de polymère hydrophile pour accéder à l'arbre biliaire et l'utilisation de guides pour maintenir la position et faciliter la mise en place du sphinctérotome. Les autres facteurs déterminants dans la réussite ou l'échec de l'intervention sont, entre autres, la sédation administrée au patient, le personnel de soutien, le degré d'expérience de l'endoscopiste, et la présence de variantes anatomiques associées à une opération de Billroth II ou à une dérivation de Roux en Y.

ENDOSCOPIC SPHINCTEROTOMY, simultaneously developed in Germany and Japan in 1974 (1,2), has undergone widespread application in the past 19 years. As such, the technique is used less commonly in many centres to facilitate common bile duct stone extraction than it is to treat the ampullary spasm/papillary stenosis symptom complex or to facilitate other therapeutic manoeuvres in the pancreaticobiliary tree (3). These include endoprosthesis placement for benign and malignant biliary strictures, balloon dilation of intrinsic stenoses and treatment of biliary fistulas.

Concomitant with this increased application of sphincterotomy has been widespread use by endotherapists with variable training, basic skill levels, and the clinical exposure needed to gain and maintain their therapeutic skills. Aside from limiting this procedure to a few clinical centres with high volumes (one alternative), what can be done to 'simplify' sphincterotomy, permitting wider application by additional endoscopists but without exposing patients to higher risks? These risks have been well-defined over the past decade. In the 1985 survey by Vennes and Silvis (personal communication), 75 respondents reported successful procedures in 88% of 5000 attempted sphincterotomies. Total complication rate was 7.7%, most commonly bleeding (3.1%) or pancreatitis (3.1%). Perforation, cholangitis, acute cholecystitis and basket entrapment occurred in less than 1% of patients, and procedure-related mortality was 0.4%. There were significantly more complications in patients undergoing sphincterotomy for papillary stenosis than for common bile duct stones. Cotton et al (4), in turn, have expanded these data, demonstrating an 8.2% complication rate and a 1.3% mortality in 7729 sphincterotomy patients compiled in survey form. Complications fell by 30 to 50% with additional endoscopist experience over

Virginia Mason Clinic, Seattle, Washington, United States
Correspondence and reprints: Dr RA Kozarek, Section of Gastroenterology, Virginia Mason Clinic, PO Box 900, Seattle, WA 98111, USA. Telephone (206) 223-6934, Fax (206) 223-6816



Figure 1) *Z, J, C, 0.021", nitinol and glide wires (left to right) used for biliary access, sphincterotomy and endoprosthesis placement*

time. Finally, Sherman et al (5) prospectively studied 423 patients undergoing sphincterotomy for stone disease, sphincter of Oddi dysfunction and miscellaneous indications. The overall complication rate was 6.9%, but was significantly higher in patients with sphincter dysfunction (10.8% versus 4.3%, P=0.009). The risk of complication was significantly higher for a small bile duct (5 mm or less), particularly if sphincterotomy was performed for biliary dyskinesia. The complication rate in these patients was 37.5%. Overall 30-day mortality was 1.7%.

With the foregoing as a background, how can we improve our technical success rate with the procedure and simultaneously minimize our complications? Four major interrelated areas deserve attention. These factors include access to technology (videoendoscopy, ancillary equipment, adequate fluoroscopy), patient selection, endoscopist and support staff experience, and endoscopic technique.

ACCESS TO TECHNOLOGY

Whereas endoscopists have used fibroptic duodenoscopes diagnostically for years, the video display of the periampullary area not only enhances visualization of the papilla and local duodenal anatomy, but has also dramatically enhanced coordination among the endoscopist, gastrointestinal assistant and radiologist. Moreover, use of 4.2 mm channel 'therapeutic' video duodenoscopes allow both enhanced coordination between endoscopist and support staff, and simultaneous passage of two instruments through the biopsy channel. This capability (eg, passage of two cannulas, cannula and guidewire) can be used in lieu of, or in addition to, over-the-wire technology in the patient in whom initial cannulation proves difficult or in whom simultaneous cannulation of the right and left ductal systems may be required post-sphincterotomy.

In addition to videoendoscopy, a plethora of ancillary equipment has evolved over the years to facilitate both free ductal cannulation and endoscopic sphincter section. Examples include various sphincterotomes (long/short nosed, precut, needle-knife, push, retractable, etc) and guidewires (0.018", 0.021", 0.025", 0.032", 0.035", 0.038", 0.052", along with 'J', 'C' and 'Z' distal types, torque-responsive, nonconductive and slick) (Figure 1). By far, the two foremost technical advances in therapeutic biliary accessories have been the development of hydrophilic polymer-coated wires (Tracer wire [nitinol], Wilson Cook, Inc, North Carolina and Glidewire, Terumo/Microvasive, Inc, Massachusetts) that allow ready proximal access to an obstructed biliary tree, and the use of guidewires in general to maintain position and facilitate sphincterotome passage. Most commonly this is done using an over-the-wire sphincterotome, but can also be accomplished by passing a conventional sphincterotome alongside a guidewire seated in the proximal biliary tree. Two varieties of wire guided sphincterotomes are available; one has the wire internalized only through the distal 3 cm of the sphincterotome tip and the second possesses two channels throughout its length (Figures 2,3). Both require wire retrieval after the sphincterotome is seated unless a nonconducting wire is used. The latter sphincterotome is particularly useful in difficult ductal cannulations as variable bowing of the tip changes the angle of approach to the papilla, thereby allowing contrast injection or guidewire placement.

In addition to the evolution of videoendoscopy and ancillary equipment, proper performance of sphincter section requires an electrosurgical generator which allows at least 40 to 60 W of blended current output because sphincterotomy requires considerably higher power outputs than for polypectomy. It is imperative that the endoscopist know (and have biomedical engineering check on a regular basis) the output of the cautery unit. Finally, advances in fluoroscopy have paralleled those in endoscopy proper. Just as it is inadequate to undertake endoscopic retrograde cholangiopancreatography (ERCP) sphincterotomy with most C-arms, the advent of digital fluoroscopy has been associated with considerably less radiation exposure to patient and personnel, as well as the ability to delete, enhance or duplicate hard copy images.

PATIENT SELECTION

Patient selection influences sphincterotomy outcome on two fronts. On the one hand, a frightened, ill-prepared or inadequately sedated patient may lose the ability to cooperate, either



Figure 2) *5 French distal wire* (**left**) *and double channel* (**right**) *sphincterotomes*

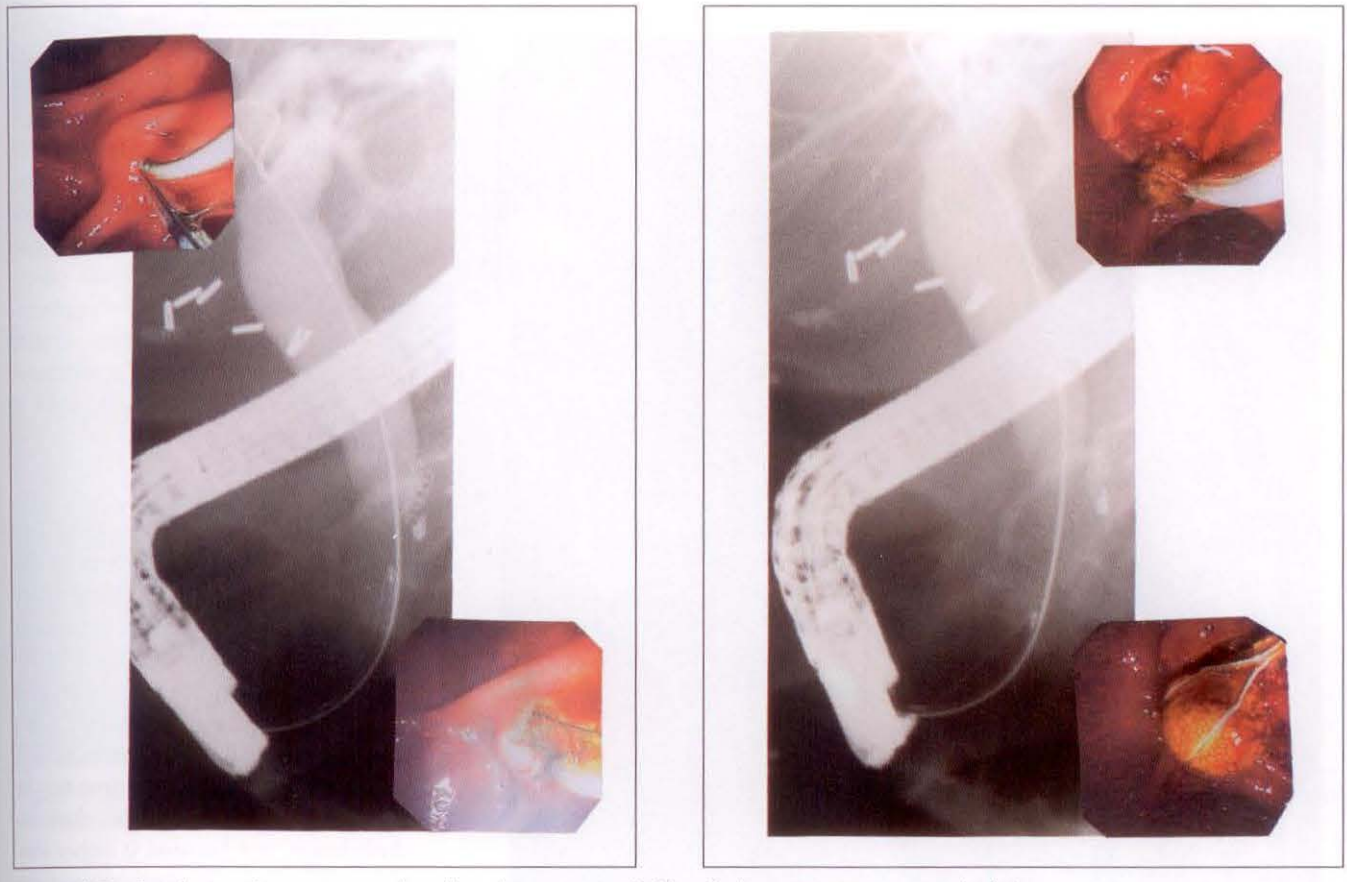

Figure 3) *Distal guidewire sphincterotome used to effect sphincter section* (**left**) *and subsequent stone extraction* (**right**)

dooming the procedure from the onset or making it a struggle for both the patient and medical personnel. On the other hand are patients who, either by virtue of underlying medical condition or local anatomy, make the procedure more difficult. The former include severe cardiopulmonary disease or coagulopathy and may require not only supplemental oxygenation in conjunction with bronchodilators, pressor agents or antihypertensives, but also close attention to monitoring (pulse, blood pressure, oxygen saturation, electrocardiogram). The latter may include discontinuation of nonsteroidal anti-inflammatory drugs, initiation of vitamin K therapy and even platelet or plasma transfusions. From the anatomical standpoint, limitations include not only gastric outlet obstructions secondary to acid-peptic and malignant disease, but also variant anatomy to include Billroth II gastric resections and roux-en-y jejunal loops. Variant anatomy may also include the occasional patient with papillae deep within large juxta-ampullary diverticula or papillae in unusual locations.

Just as one can choose a spouse but not one's children, the endoscopist may have limited ability to select the patient sent for ERCP and sphincterotomy. Several caveats are operative, however. In areas in which considerable endoscopic expertise exists, the individual who has limited sphincterotomy experience does not need to tackle 'all comers'. Data are clear that sphincterotomy success rates are lower and the complication rates higher in patients with B-II anastomoses and roux-en-y loops (3,6-9). Data are equally clear that patients with small ducts and presumptive sphincter dysfunction often have a prohibitive risk of sphincterotomy, approaching a 38% complication rate in ducts less than 5 mm, even in expert hands (5); these patients should probably be referred to centres with extensive pancreaticobiliary experience including pancreaticobiliary manometry capability. Equally important is an assurance that in those patients in whom the physician elects diagnostic and therapeutic ERCP, the necessary tools to complete the procedure are available. These may include mechanical or laser lithotriptors for large common bile duct stones (10,11), balloon dilators for gastric outlet obstruction (12) and forward viewing endoscopes or pediatric colonoscopes for patients with variant anatomy (8).

ENDOSCOPIST AND STAFF EXPERTISE

While there are published criteria regarding the number of diagnostic ERCPs recommended prior to attempting therapeutic procedures, a better criterion is the success rate of free biliary cannulation at diagnostic ERCP and the background of the endoscopist. Therefore, just as it seems reasonable to suggest that two-thirds to three-quarters of biliary cannulations should be 'free' prior to attempting sphincterotomy, it seems equally reasonable to assume that endoscopists with extensive exposure to sphincterotomy in

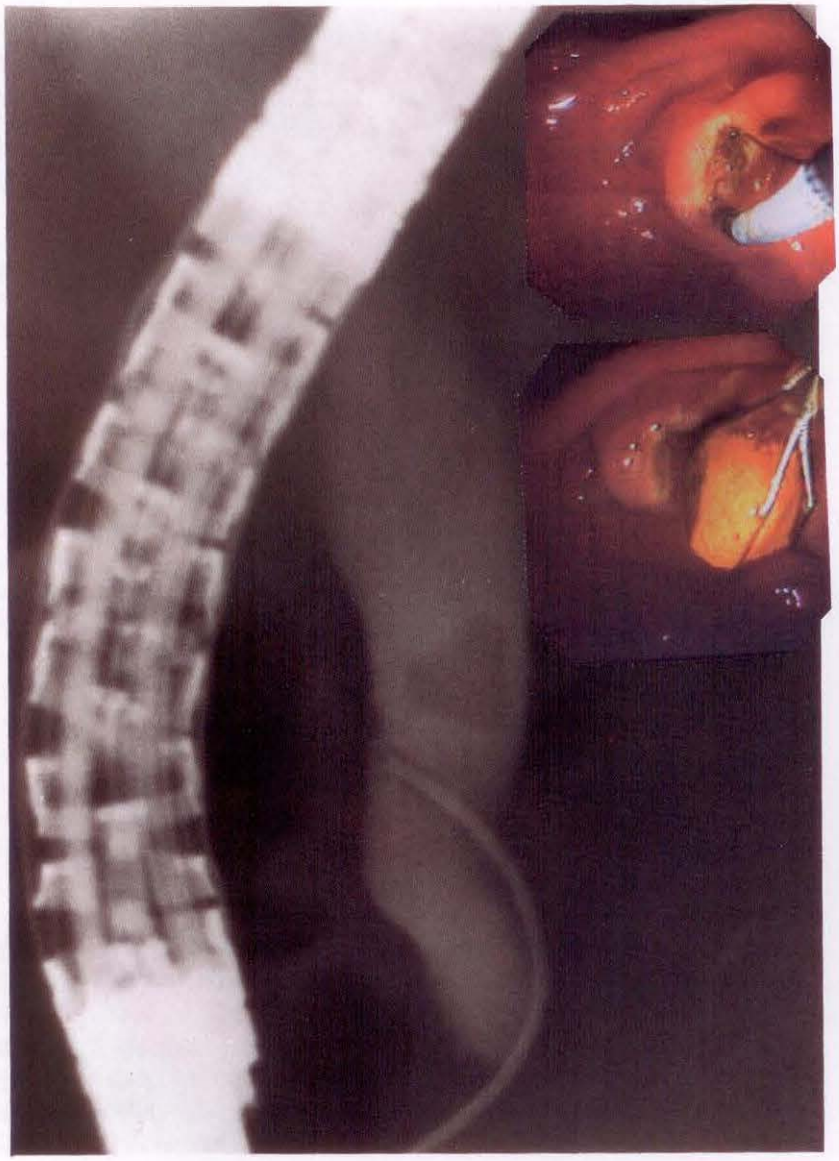

Figure 4) *Radiograph demonstrates excessive wire in biliary tree. Inserts demonstrate wire retrieval prior to sphincter section and calculus retrieval*

training or practice setting may be more apt to apply the technique than an individual with limited experience.

Because sphincterotomy is not done in a vacuum, the importance of well-trained and experienced gastrointestinal endoscopy nurses is a given. Not only do the nurses monitor the patient directly regarding discomfort, intravenous drugs, vital signs, oxygen saturation, positioning and the suctioning of oropharyngeal secretions, they also are responsible for instrument set-up and patient turnaround. Moreover, many endoscopists use the gastrointestinal nurse to inject contrast, handle the sphincterotome, manipulate balloon catheters and stone baskets, and assist in the placement of endoprostheses. In short, the gastrointestinal assistant, in conjunction with the radiologist or x-ray technician, has the ability to facilitate or prevent procedural success, and their role should not be either underestimated or minimized.

Finally under staff expertise, one should include the interventional radiologist. There is a myriad of publications regarding use of a combined percutaneous/radiologic and endoscopic approach in facilitating diagnostic and therapeutic ERCP (13,14). As percutaneous transhepatic cholangiography and biliary drainage are associated with a definable incidence of bleeding and bile leak, the application of these procedures in lieu of appropriate skill or poor endoscopic technique is to be discouraged. Whereas percutaneous transhepatic cholangiography/percutaneous transhepatic biliary drainage may not 'simplify' sphincterotomy, they may occasionally make it technically possible.

TECHNIQUE

Sphincterotomy depends upon free cannulation of the biliary tree in the vast majority of cases, whereas free cannulation usually implies an en face and readily approachable papilla. It makes no sense to lose access to the biliary tree after a difficult cannulation and I place guidewires in all such instances (3). Moreover, guidewire placement may be used in routine cases of choledocholithiasis, not because it either simplifies the procedure or improves the success rate, but rather because it may shorten it or decrease the risk of pancreatitis by minimizing additional manipulation and injections of the pancreatic duct.

As previously mentioned, the sphincterotome can be used to facilitate cannulation by adjusting the papillotome wire tension, often in conjunction with endoscope withdrawal along the lesser curvature of the stomach. If standard cannulation attempt and use of a double channel sphincterotome fail to allow free cannulation, the endoscopist is faced with using precut or needle-knife sphincterotomes in an attempt to unroof the papilla and freely enter the common bile duct (15); use a combined procedure with the aid of an interventional radiologist (13,16), refer to a more experienced endoscopist or send the patient to surgery. Depending upon the underlying patient condition, the latter two choices are often preferable. Specifically, considerable therapeutic pancreaticobiliary experience is recommended before blindly incising a papilla (17).

Once a guidewire has been placed, a

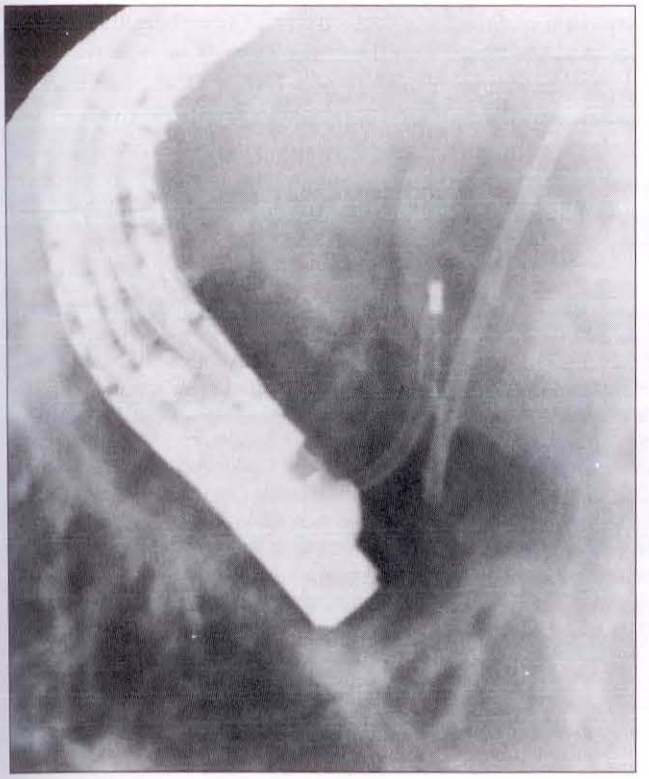

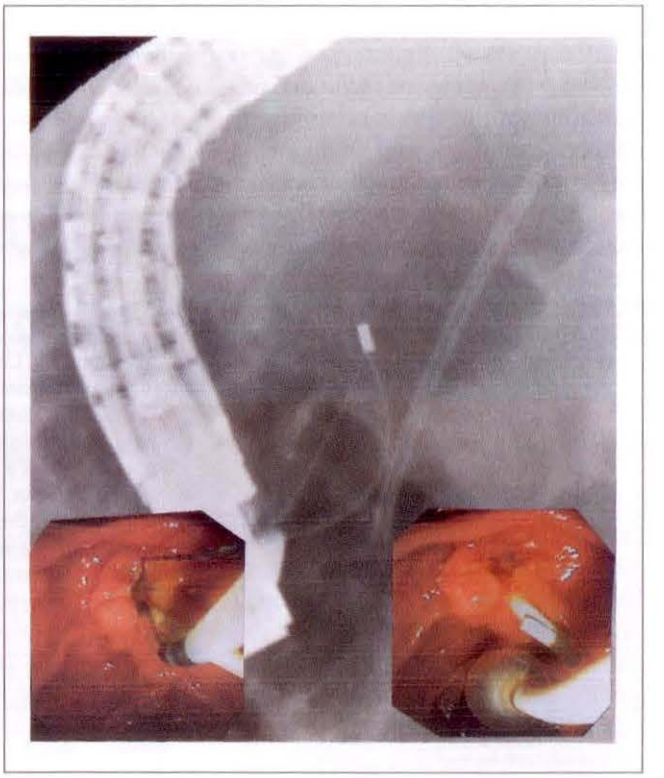

Figure 5) *Stent in pancreatic duct to preclude recurrent cannulation of the pancreatic duct at biliary sphincterotomy* (**left**). *Note sphincterotomy* (**right**) *and sizing with balloon (inserts)*

variety of methods are available to complete sphincterotomy. If a therapeutic scope is used, it often is quite simple to pass a conventional sphincterotome alongside the wire and into the biliary tree. More commonly, however, a variety of over-the-wire instruments are used, including the 5 French distal lumen sphincterotome by Wilson-Cook or the 5 French double lumen papillotome by Microvasive (Figures 2,3). Whereas the former requires wire removal prior to sphincter incision, the latter can be left in place if a nonconducting wire is used. Because this wire is two to three times more expensive than a conventional 0.035" wire, its use is limited to selected cases.

Simplifying sphincterotomy requires not only proper orientation of the sphincterotome between 11:00 and 1:00 at the papillary level, it also requires estimation of the length of cut needed (Figure 4). As previously noted, small ducts generally have a much higher complication rate with sphincterotomy than patients with large ducts; periampullary diverticulae, while generally not precluding diagnostic or therapeutic ERCP, can occasionally be troubling, and a short intramural segment of bile duct often limits the extent of incision that can safely be undertaken. Moreover, if sphincterotomy is being done to facilitate balloon dilation, brush cystology or endoprosthesis placement, there may be little reason to fully ablate the sphincter mechanism as a 5 to 10 mm incision often is adequate and less risky.

Sphincterotomy is a controlled procedure (3). I leave less than 5 mm of wire in the papilla, whatever length of sphincterotome wire used (Figures 3-5). Excess wire length and tension should be avoided as both may be associated with the 'zipper effect', in which a rapid and uncontrolled cut may be associated with inadequate tissue coagulation. I handle and use a largely unbowed wire, using tension at the level of the elevator to lift the sphincterotome against the superior margin of the papilla. If cutting does not occur, additional wire should be withdrawn from the papilla or the angle of the sphincterotome's contact with the mucosa changed in lieu of increasing the power setting on the cautery generator. Most endoscopists use 40 to 60 W of blended current, and some (myself excluded) tend to switch to a coagulative current at the upper margin of the incision. Stopping the incision may be as important as initiating one, however, and may be difficult to define. Typically one is safe in cutting up to (and often through) the proximal transverse fold above the papilla. Sudden air in the biliary tree, a gush of contrast material into the duodenum and the ability to pull a 5 to 10 mm balloon or open sphincterotome through the incision are reasonable estimates of successful papillotomy. Obviously, such success is a relative term, as it will prove impossible to retrieve a 20 mm^2 common bile duct stone through a 10 mm sphincterotomy incision without initial stone fragmentation of some sort. Moreover, the occasional 10 mm sphincterotomy may result in catastrophic complications despite proper instrument orientation and appropriate electrocautery precautions.

CONCLUSIONS

In summary, sphincterotomy – whether done primarily to treat choledocholithiasis or papillary dysfunction,

or to facilitate other therapeutic pancreaticobiliary procedures – has evolved into a guidewire facilitated undertaking in the 1990s. Simplifying sphincterotomy, however, includes not only attention to technical detail, but the availability of equipment, proper patient selection and preparation, and the support of ancillary nursing and radiologic personnel. Forward-viewing endoscopes, Billroth II, needle-knife, and precut sphincterotomes, and combined endoscopic-radiologic procedures allow higher success rates but certainly do not simplify the procedure. Contingent upon endoscopist experience, the acuteness and severity of the clinical situation, and the availability of a higher level of endoscopic or surgical expertise within a geographic area, patients requiring use of these instruments and techniques may best be handled at a biliary referral centre.

REFERENCES

1. Kawai K, Akasalia Y, Murakawi K, et al. Endoscopic sphincterotomy of the ampulla of Vater. Gastrointest Endosc 1974;20:148-51.
2. Classen M, Demling L. Endoscopic papillotomy and removal of gallstones. Br Med J 1975;4:371-4.
3. Brandabur JJ, Kozarek RA. Endoscopic sphincterotomy and combined endoscopic and radiographic procedures. In: Silvis SE, ed. Atlas of ERCP and Sphincterotomy. Philadelphia: Lippincott Co, 1993. (In press)
4. Cotton PB, Lehman G, Vennes J, et al. Endoscopic sphincterotomy complications and their management: An attempt at consensus. Gastrointest Endosc 1991;37:383-93.
5. Sherman S, Ruffolo TA, Hawes RH, Lehman GA. Complications of endoscopic sphincterotomy. A prospective series with emphasis on the increased risk with sphincter of Oddi dysfunction and nondilated bile ducts. Gastroenterology 1991;101:1068-75.
6. Forbes D, Cotton P. ERCP and sphincterotomy after Billroth II gastrectomy. Gut 1984;25:471-4.
7. Osnes M, Rosseland AR, Aabakkon L. Endoscopic retrograde cholangiography and endoscopic papillotomy in patients with a previous Billroth II resection. Gut 1986;27:1193-8.
8. Gostout CJ, Bender CE. Cholangiopancreatography, sphincterotomy, and common duct stone removal via roux-en-y limb enteroscopy. Gastroenterology 1988;95:156-63.
9. Ricci E, Bertoni G, Conigliaro R, et al. Endoscopic sphincterotomy in Billroth II patients: An improved method using a diathermic needle as sphincterotome and a nasobiliary drain as a guide. Gastrointest Endosc 1989;35:47-50.
10. Shaw MJ, Dersher PJ, Vennes JA. A new mechanical lithotripter for the treatment of large common bile duct stones. Am J Gastroenterol 1990;85:796-8.
11. Cotton PB, Kozarek RA, Schapiro RH, et al. Endoscopic laser lithotripsy of large bile duct stones. Gastroenterology 1990;99:1128-33.
12. Kozarek RA, Botoman VA, Patterson DJ. Long-term follow up in patients who have undergone balloon dilation for gastric outlet obstruction. Gastrointest Endosc 1990;36:558-61.
13. Tanaka M, Matsumoto S, Ikeda S, et al. Endoscopic sphincterotomy in patients with difficult cannulation: Use of an antegrade guide. Endoscopy 1986;18:87-9.
14. Bogost GA, Freeny PF, Kozarek RA, et al. Combined endoscopic and radiologic procedures for biliary intervention. Gastrointest Endosc 1992;38:247A.
15. Leung JWC, Banez VP, Chung SCS. Precut (needle knife) papillotomy for impacted common bile duct stone at the ampulla. Am J Gastroenterol 1990;85:991-3.
16. Simon DM, Brooks WS Jr, Hersh T. Endoscopic sphincterotomy: A reappraisal. Am J Gastroenterol 1989;84:213-9.
17. Booth FV, Doerr RJ, Khalafi RS, et al. Surgical management of complications of endoscopic sphincterotomy with precut papillotomy. Am J Surg 1990;159:132-6.