Ultrasound-guided extracorporeal shock wave lithotripsy of pancreatic ductal stones: Six years' experience

WERNER JOHANNS MD, CHRISTIAN JAKOBEIT MD, LUCAS GREINER MD, JAN JANSSEN MD

W JOHANNS, C JAKOBEIT, L GREINER, J JANSSEN. Ultrasound-guided extracorporeal shock wave lithotripsy of pancreatic ductal stones: Six years' experience. Can J Gastroenterol 1996;10(7):471-475. Extracorporeal shock wave lithotripsy (ESWL) and endoscopic sphincterotomy (EST) was performed in 35 patients suffering from pancreatic duct stones. Calculi disintegration and resolution of obstruction were achieved in all cases. Completely stone-free ducts were achieved in 16 patients (46%) while some peripheral asymptomatic stone material remained in 19 (54%). Dilation of the main pancreatic duct was reduced in 29 patients (83%). Twelve patients (34%) became completely asymptomatic and 17 (49%) reported a marked reduction of pain. Pancreatogenic steatorrhea ceased and 18 patients (51%) gained weight. Pathological glucose tolerance returned to normal in one patient. No major complications were observed. The combination of ESWL and EST is a successful, nonoperative, new treatment in pancreatic stone disease.

Key Words: *Chronic pancreatitis, Extracorporeal shock wave lithotripsy, Pancreatic duct stones*

Lithotripsie extracorporelle par ondes de choc contre des calculs du canal pancréatique : six années d'expérience

RÉSUMÉ : La lithotripsie extracorporelle par ondes de choc et la sphinctérectomie endoscopique ont été utilisées chez 35 patients souffrant de calculs du canal pancréatique. La désintégration des calculs et la désoblitération ont pu être obtenues dans tous les cas. Le canal pancréatique est redevenu tout à fait perméable chez 16 patients (46 %), alors que des résidus de calculs ne provoquant pas de symptomes persistaient chez 19 (54 %). Le recours à la dilatation du canal pancréatique principal a diminué chez 29 patients (83 %). Douze patients (34 %) sont devenus complètement asymptomatiques et 17 (49 %) se sont dits grandement soulagés. La stéatorrhée d'origine pancréatique a cessé et 18 patients (51 %) ont pris du poids. Les anomalies de la tolérance au glucose sont rentrées dans l'ordre chez un patient. Aucune complication majeure n'a été observée. Employées conjointement, la lithotripsie et la sphinctérectomie constituent un nouveau traitement non effractif et efficace de la lithiase pancréatique.

Pancreatic calcification is found in 50% to 90% of patients with advanced chronic pancreatitis (1,2). Two patterns of distribution can be distinguished: calcification of the secondary branches and acini; and calculi in the main pancreatic duct (3). Combinations of the two forms are common. The postulated pathophysiological mechanism is precipitation of proteins, which become calcified by calcium carbonate crystals (4). Reduced levels of pancreatic stone protein, which acts as calcium stabilizer in the pancreatic juice, are thought to play a role (5-7).

Pancreaticolithiasis with duct obstruction is a serious complication of chronic pancreatitis (Figure 1). Experience with anastomotic surgery and endoscopic drainage has shown that removal of the obstruction in the main pancreatic duct can produce immediate pain relief and prevent further inflammatory episodes (8-11).

Endoscopic-operative measures (papillotomy, stone extraction) are of limited use for large or impacted stones or ductal strictures. We used pancreatic extracorporeal shock wave lithotripsy (ESWL) as an alternative to surgical intervention to treat patients with symptomatic pancreaticolithiasis and ultrasonographically identifiable duct dilation (Fig-

Medical Clinic A – Gastroenterology, Municipal Hospital Wuppertal, University of Witten-Herdecke, Wuppertal, Germany
Correspondence and reprints: Prof Dr L Greiner, Medical Clinic A – Gastroenterology, Municipal Hospital Wuppertal, University of Witten-Herdecke Heusnerstraße 40, D-42283 Wuppertal, Germany. Telephone 0202 896 2288, fax 0202 896 2740
Received for publication June 13, 1995. Accepted February 6, 1996

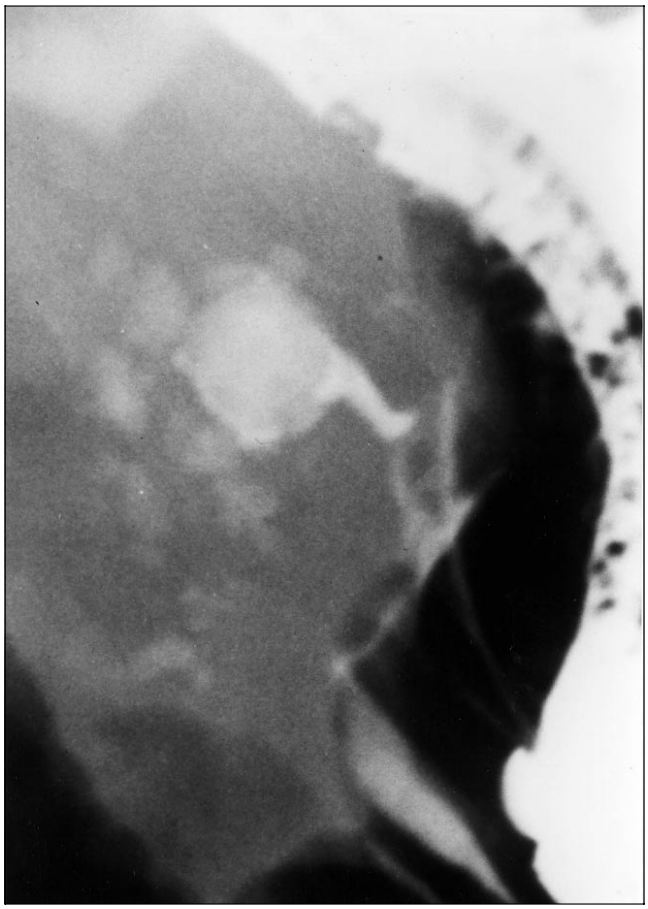

Figure 1) *Chronic calcifying pancreatitis with obstructing juxtapapillary calculus*

Figure 2) *Impacted concrement causing cystic dilation of the pancreatic duct*

ure 2). Our aims were clearance of ductal stones and consecutive reduction of patient complaints.

PATIENTS

Thirty-five patients (17 men, 18 women) suffering from chronic pancreatitis complicated by an obstruction of the pancreatic duct system resulting from pancreaticolithiasis who were treated by ESWL were included in this six-year

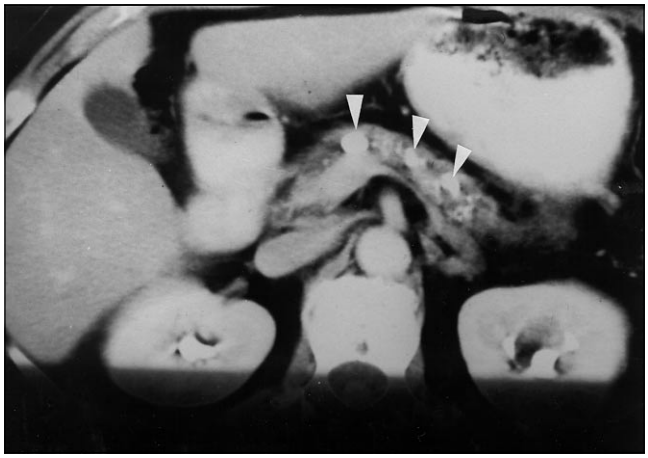

Figure 3) *Computed tomographic scan showing multiple ductal stones up to 12 mm in diameter (arrows)*

study. Average age of patients was 48 years (range 14 to 61). Nineteen patients (54%) suffered from chronic alcoholic pancreatitis; in 15 patients (43%) the etiology of the pancreatitis was not evident and in the case of a 13-year-old, idiopathic juvenile pancreatitis was assumed. All patients complained of upper abdominal pain, mostly with radiation to the back, which was classified as recurrent pain attacks in 24 (69%) and as continued pain in 11 (31%). Average history of symptoms was five years (range three to 12). Nine patients (26%) had solitary stones, 16 (46%) had one to five stones and 10 (29%) had multiple stones, in some cases completely filling Wirsung's duct (Figures 3,4a). Mean average diameter of the largest stone was 11 mm (range 5 to 25). In conventional abdominal ultrasound the mean average diameter of the dilated pancreatic duct was 9 mm (range 5 to 28).

Each patient underwent endoscopic retrograde pancreatography (ERP), which showed moderate to marked chronic inflammatory ductal changes. Significant strictures at the main pancreatic duct were found in 15 patients (43%). In 30 patients (86%) ERP confirmed pancreatic duct system dilation as observed by ultrasound; in five patients (14%) stone impaction prevented contrasting of the distal part of the duct. Two cases of pancreatic pseudocysts (4 and 5 cm in diameter) showed communication with the pancreatic ductal system.

Shock wave treatment was administered because the stones were not extractable by applied endoscopic measures. A total of 29 patients (83%) presented with exocrine pancreatic dysfunction (reduced fecal chymotrypsin, steatorrhea) and weight loss; 28 of them had enzyme replacement. Five patients had overt diabetes mellitus and two presented with impaired glucose tolerance.

METHODS

Pancreatic ductal stones were fragmented using an electrohydraulic lithotripter (MPL 9000, Dornier Medizintechnik, Germany) (12,13) after exact sonographic targeting. All patients were treated in a prone position. Up to 2000 electrocardiogram-triggered shock waves were delivered per session under continuous ultrasound monitoring. If fragmentation

Figure 4a) *Ultrasound scans showing ductal stones before (arrows) extracorporeal shock wave lithotripsy*

Figure 4c) *Diminished dilation of the duct after spontaneous passage and additional endoscopic removal of fragments. Residual fragments in caudal portion of the duct are seen (arrow)*

Figure 4b) *Ultrasound scans showing fine fragments after (arrows) extracorporeal shock wave lithotripsy*

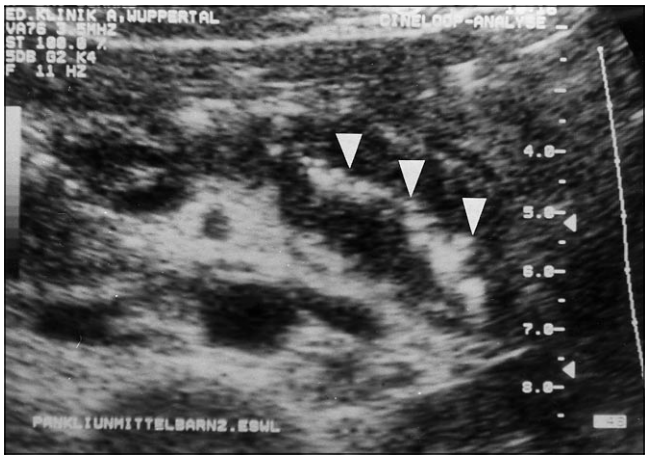

Figure 5) *"Steinstraße" – line of fragments (arrows) in the collapsed duct after extracorporeal shock wave lithotripsy. Same patient as in Figure 2*

was not successful, ie, insufficient disintegration of the stone(s) visible in the ultrasound examination, shock wave lithotripsy was repeated. The average shockwave energy was 18 kV (range 14 to 22). Patients were given piritramide (available only in Europe through Janssen Pharmaceutica Inc) and midazolam for analgesia and sedation. Endoscopic sphincterotomy (EST) of the pancreatic portion of the sphincter was done during ERP in 34 patients. In the 13-year-old, presumably presenting with idiopathic juvenile pancreatitis, EST was not done. Pancreatic duct diameters and stone fragmentation were controlled ultrasonographically. Fragments not passed spontaneously after ESWL were extracted as completely as possible using Dormia baskets (Schadlowsky; Voerde, Germany).

Average follow-up was 23 months (range three to 70). Patients were asked about their conditions and examined clinically and by ultrasonography every three months in the first year of follow-up, and thereafter at intervals of up to 12 months. If there was any doubt about fragment migration or impaction, or stone recurrence, an ERP was performed.

RESULTS

Targetting of pancreatic stones within the shock wave focus and complete therapeutic monitoring were possible in all treatment sessions under ultrasonographic control.

Stone disintegration was achieved in all patients; 13 (37%) required one treatment session, nine (26%) required two, eight (23%) required three, and five (14%), with multiple stones completely filling the duct of Wirsung, required between four and seven. A total of 5000 (range 500 to 13,500) shock waves were used per patient. Under analgesia and sedation with piritramide and midazolam ESWL was well tolerated. There were no cardiopulmonary complications.

After sufficient stone fragmentation, controlled by ultrasound examination (Figure 4b), follow-up ERP was performed. Based on ultrasound and ERP, 16 patients (46%) were shown to be completely stone-free. Nineteen patients (54%) had small residual fragments in the main ductal system, mostly located in the tail portion of the pancreatic duct (Table 1). Complete endoscopic extraction of these fragments was not possible because of strictures, kinking of the

TABLE 1
Results of extracorporeal shock wave lithotripsy (ESWL) and endoscopic stone extraction for pancreatic ductal stones

		After ESWL	
		Stone-free	Obstruction cleared
Before ESWL	Solitary stone (n=9)	6	9
	2 to 5 stones (n=16)	6	16
	≥6 stones (n=10)	4	10
	Total	16	35

TABLE 2
Clinical course as a function of duct morphology and stone clearance

	Pain-free	Pain-reduced	No change
Stone-free (n=16)			
With stricture	2	3	1
Without stricture	6	3	1
Residual stones (n=19)			
With stricture	1	6	2
Without stricture	3	5	2
Total	12	17	6

TABLE 3
Number of stones and clearance of stones in patients with strictures of the pancreatic duct

		After ESWL	
		Stone-free	Obstruction cleared
Before ESWL	Solitary stone (n=4)	2	4
	2 to 5 stones (n=3)	1	3
	≥6 stones (n=8)	3	8
	Total	6	15

ESWL Extracorporeal shock wave lithotripsy

pancreatic duct or both. The 13-year-old with idiopathic chronic pancreatitis (without sphincterotomy) and three other patients showed complete stone clearance spontaneously.

In 29 cases (83%) the diameter of Wirsung's duct was reduced to more than 50% of the baseline value (Figures 4c,5). After treatment, mean diameter of the main pancreatic duct was 2.8 mm (range 0 to 6). In patients with pancreatic pseudocysts the diameter of pseudocysts decreased within two to three days after removal of the stone obstruction. After three months they were no longer detectable ultrasonographically.

After treatment 12 patients (34%) were completely free from complaints and a further 17 (49%) reported significantly less pain (Table 2). Eighteen patients (51%) gained an average of 5.5 kg (range 2 to 15). Pathological glucose tolerance returned to normal in one patient. Five of six patients (17%) who reported no improvement despite successful ESWL had a filiform stenosis of the pancreatic duct and underwent pancreatic surgery. Six of nine patients with solitary stones, 10 of 26 patients with several stones and six of 15 patients with significant strictures of the pancreatic duct became stone-free (Tables 1,3). Eight of 12 patients who became pain-free were also stone-free and only three of the 12 had a stricture of the pancreatic duct (Table 2).

ESWL had to be repeated in four patients (11%) because of pain recurrence due to the migration of residual fragments or stones from the tail section of the pancreas. Three patients were successfully retreated for recurrence of symptomatic stones 18 to 28 months after successful primary therapy; they remained free from stones and complaints for up to 26 months. Diagnosis of fragment migration and recurrent concrements was made ultrasonographically and confirmed by ERP.

There were no serious complications associated with shock wave therapy. In five patients (14%) serum amylase and lipase were slightly elevated immediately after ESWL, without evidence of acute pancreatitis. Clinically overt pancreatitis occurred in three patients and subsided within two days under symptomatic therapy. Repeated ultrasound examinations revealed no additional morphological changes in the pancreatic parenchyma or the peripancreatic region. As a complication of EST, a localized retroduodenal perforation was found in one patient (managed conservatively). Two patients had acute pancreatitis.

DISCUSSION

Because of high perioperative mortality and generally poor long term results of surgical resection or drainage procedures in patients with chronic calcific pancreatitis (1,14-16), alternative forms of treatment are needed. Endoscopic procedures involving division of the pancreatic sphincter and extraction of ductal stones are often unsuccessful due to the incongruity between the size of the stone and the anatomy of the pancreatic duct. Stone fragmentation by ESWL permits clearance of the duct by spontaneous passage or endoscopic extraction of stone fragments (11,12,17-24).

Fragmentation of the occluding pancreatic ductal stones, with reduction of the stone volume and clearance of the obstruction, was achieved in all patients. In 16 patients (46%) treatment resulted in complete stone clearance. Twelve patients (34%) were free from complaints after treatment and pain diminished considerably in 17 (49%). The diameter of Wirsung's duct was reduced by more than 50% of the baseline value, indicating the clearance of obstruction with a decrease of pressure in the pancreatic duct system, in 29 patients (83%) (25) (Figures 4b,4c,5).

Importantly, five of six patients who complained of unchanged symptoms after ESWL and who subsequently required pancreatic surgery had a filiform stenosis in the distal portion of the main pancreatic duct. In patients with fragments not endoscopically extractable, these fragments were primarily located behind strictures or in especially narrow segments of the duct. However, there were some patients with a large stone volume, a stricture of the pancreatic duct or both, who became stone-free and asymptomatic (Tables 1-3). Thus, neither stone characteristics nor pancreatic duct morphology seems to be of predictive value regarding the therapeutic outcome.

We found that complete stone clearance was not necessary for complete abolition of symptoms. Remaining residual fragments were small, caused no obstruction and were usually situated in the tail portion of the gland. Four patients who suffered a further episode of pain due to fragment migration after initial success of ESWL were pain-free after repeated ESWL. Stone recurrence was observed in three patients after 18 to 28 months, and they were again treated successfully with ESWL.

Results equivalent to or better than those discussed have been reported by others (18,19,21,22,26,27) using electrohydraulic or electromagnetic lithotripters with radiographic stone location. Three groups used ultrasonography alone (28,29) or in combination with radiography (24) for targetting pancreatic ductal concrements; freedom from stones and complete freedom from pain were achieved in up to 70% of patients.

The success of ultrasonography in indication, therapeutic monitoring and follow-up examination renders it the method of choice in our opinion in pancreatic ESWL. By using ultrasound to locate stones, patients avoid exposure to radiation (12,20). With continuous treatment monitoring by real-time ultrasound, we can also spare patients the nasopancreatic tube necessary for administration of contrast medium during x-ray-guided ESWL.

Our complication rate was low, which is similar to results from other groups (18,19,21-24,26-29). In close temporal association with ESWL we observed mainly mild episodes of pancreatitis.

In our experience, ESWL is not contraindicated in the presence of pancreatic pseudocysts; in fact, removal of duct obstruction can improve drainage of the pseudocysts if they communicate with the duct system. Further controlled prospective studies are needed to determine whether the weight gain observed in 18 patients in our study was due simply to adequate intestinal enzyme replacement and improved appetite after pain relief, or whether it also reflects a significant reduction in pancreatic exocrine dysfunction. Improved endocrine function may occur in individual cases. However, in view of the highly variable spontaneous course of chronic pancreatitis our results have to be interpreted with caution.

CONCLUSIONS

The combination of ultrasound-guided ESWL, EST and fragment extraction is a new nonoperative approach – with a low rate of complications – for the treatment of pancreatic ductal stones. Although most patients showed improvement in their general condition and especially their pain, controlled prospective studies comparing the spontaneous course of the disease with the results of interventional endoscopy and surgical methods are needed.

ACKNOWLEDGEMENTS: The authors are grateful to Dr P Bertschinger (Gastroenterology Unit, Department of Internal Medicine, University Hospital Zurich, Zurich, Switzerland) for his advice and review of this manuscript.

REFERENCES

1. Ammann RW, Akovbiantz A, Largiader F, Schueler G. Course and outcome of chronic pancreatitis. Longitudinal study of a mixed medical-surgical series of 245 patients. Gastroenterology 1984;86:820-8.
2. Grimm H, Meyer WH, Nam VC, Soehendra N. New modalities for treating chronic pancreatitis. Endoscopy 1989;21:70-4.
3. Edmondson HA, Bullock WK, Mehl JW. Chronic pancreatitis and lithiasis. Am J Pathol 1949;25:1227-47.
4. Guy O, Robles-Diaz G, Adrich Z, Sahel J, Sarles H. Protein content of precipitates present in pancreatic juice of alcoholic subjects and patients with chronic calcifying pancreatitis. Gastroenterology 1983;84:102-7.
5. Multinger J, Sarles H, Lombardo D, De Caro A. Pancreatic stone protein II. Implication in stone formation during the course of chronic calcifying pancreatitis. Gastroenterology 1985;89:387-91.
6. Sarles H. Chronic calcifying pancreatitis. Scand J Gastroenterol 1985;20:651-9.
7. Sarles H, Bernard JP, Johnson C. Pathogenesis and epidemiology of chronic pancreatitis. Ann Rev Med 1989;40:453-68.
8. Devière J, Baize M, Matos C, et al. Pancreatic endoscopic sphincterotomy in chronic pancreatitis: indications and results. Digestion 1988;40:76-7.
9. Fuji T, Amano H, Harima K, et al. Pancreatic sphincterotomy and pancreatic endoprosthesis. Endoscopy 1985;17:69-72.
10. Huibregtse K, Schneider B, Vrij AA, Tytgat GNJ. Endoscopic pancreatic drainage in chronic pancreatitis. Gastrointest Endosc 1988;34:9-15.
11. Schneider MU, Lux G. Floating pancreatic duct concrements in chronic pancreatitis. Pain relief by endoscopic removal. Endoscopy 1985;17:8-10.
12. Greiner L, Jakobeit C. ESWL bei Pankreasgangsteinen. Dtsch Med Wochenschr 1989;114:1940.
13. Greiner L, Jakobeit C, Johanns W. Extrakorporale Stoßwellenlithotripsie (ESWL) in der Gastroenterologie. Fortschritte in der Therapie von Gallen und Pankreassteinen. Krankenpfl J 1994;32:117-20.
14. Cuilleret J, Guillemin G. Surgical management of chronic pancreatitis on the continent of Europe. World J Surg 1990;14:11-8.
15. Greenlee HB, Prinz RA, Aranha GV. Long-term results of side-to-side pancreaticojejunostomy. World J Surg 1990;14:70-6.
16. Ihse I, Borch K, Larsson J. Chronic pancreatitis: results of operations for relief of pain. World J Surg 1990;14:53-8.
17. Johanns W, Jakobeit C, Deinert K, Greiner L. ESWL-Therapie von Pankreasgangsteinen. Leber Magen Darm 1994;24:210-3.
18. Delhaye M, Vandermeeren A, Gabrielli A, Cremer M. Lithotripsy and endoscopy for pancreatic calculi – the first 104 patients. Gastroenterology 1990;98:A216.
19. Delhaye M, Vandermeeren A, Baize M, Cremer M. Extracorporeal shock-wave lithotripsy of pancreatic calculi. Gastroenterology 1992;102:610-20.
20. Greiner L, Wenzel H, Jakobeit C. Biliäre Stoßwellen-Lithotripsie. Erfahrungen der ersten drei Jahre bei 612 Patienten. Therapiewoche 1990;40:1770-82.
21. Sauerbruch T, Holl J, Sackmann M, Paumgartner G. Extracorporeal shock wave lithotripsy of pancreatic stones. Gut 1989;30:1406-11.
22. Sauerbruch T, Holl J, Sackmann M, Paumgartner G. Extracorporeal lithotripsy of pancreatic stones in patients with chronic pancreatitis and pain: a prospective follow up study. Gut 1992;33:969-72.
23. Van der Hul R, Plaisier P, Jeekel J, Terpstra O, den Toom R, Bruining H. Extracorporeal shock-wave lithotripsy of pancreatic duct stones: immediate and long-term results. Endoscopy 1994;26:573-8.
24. Schneider HT, May A, Benninger J, et al. Piezoelectric shock wave lithotripsy of pancreatic duct stones. Am J Gastroenterol 1994;89:2042-8.
25. Karanjia ND, Widdison AL, Leung F, Alvarez C, Lutrin FJ, Reber HA. Compartment syndrome in experimental chronic obstructive pancreatitis: effect of decompressing the main pancreatic duct. Br J Surg 1994;81:259-64.
26. Cremer M, Vandermeeren A, Delhaye M. Extracorporeal shock wave lithotripsy (ESWL) for pancreatic stones. Gastroenterology 1988;94:A80.
27. Soehendra N, Grimm H, Meyer HW, Schreiber HW. Extrakorporale Stoßwellenlithotripsie bei chronischer Pankreatitis. Dtsch Med Wochenschr 1989;114:1402-6.
28. Schreiber F, Gurakuqi G, Trauner M, Krejs GJ. Ultraschallgezielte extrakorporale Stoßwellenlithotripsie von Pankreasgangsteinen bei Patienten mit chronisch rezidivierender Pankreatitis. Bildgebung 1994;61:182-6.
29. Adamek HE, Buttmann A, Jakobs R, Offner B, Riemann JF. Extrakorporale piezoelektrische lithotripsie (EPL) bei der chronischen Pankreatitis: Indikationen, Fragmentationsraten und erste klinische Ergebnisse. Endoskopie heute 1994;1:43. (Abst)