Pneumatic dilation in achalasia

Maximilian Bittinger MD, Martin Wienbeck MD

M Bittinger, M Wienbeck. Pneumatic dilation in achalasia. Can J Gastroenterol 2001;15(3):195-199. Pneumatic dilation is the most common first-line therapy for the treatment of achalasia. The aim of dilation is a controlled disruption of circular muscle fibres of the lower esophageal sphincter to reduce the functional obstruction. Several types of dilators and different dilation techniques are used, but the achieved results are similar. The mean success rate is about 80% in the short term, but some patients need redilation in the further course (particularly young patients). Best long term results are obtained if the lower esophageal sphincter pressure can be reduced below 10 mmHg. Major complications are rare after pneumatic dilation; the most serious complication is esophageal perforation, which occurs at a mean rate of about 2.5%. Considering the pros and cons of other effective forms of treatment of achalasia (esophagomyotomy and intrasphincteric injection of botulinum toxin), pneumatic dilation is still the treatment of choice in the majority of patients with achalasia.

Key Words: *Achalasia; Pneumatic dilation*

Achalasie et dilatation pneumatique

RÉSUMÉ : La dilatation pneumatique constitue le traitement de première intention le plus courant de l'achalasie. La dilatation vise à provoquer une rupture ménagée des fibres musculaires circulaires du sphincter inférieur de l'œsophage pour diminuer l'obstruction fonctionnelle. Il existe différentes techniques de dilatation et différents types de dilateurs, mais ils donnent tous à peu près les mêmes résultats. Le taux moyen de réussite à court terme atteint environ 80 % mais, dans certains cas, il est nécessaire de reprendre l'intervention, surtout chez les jeunes patients. On obtient de meilleurs résultats à long terme si la pression du sphincter inférieur de l'œsophage peut être abaissée à moins de 10 mm Hg. La dilatation pneumatique donne rarement lieu à des complications graves; la plus sérieuse est la perforation de l'œsophage, qui se produit dans environ 2,5 % des cas. Compte tenu des avantages et des inconvénients d'autres traitements efficaces de l'achalasie (myotomie de Heller, injection intra-sphinctérienne de toxine botulique), la dilatation pneumatique demeure encore le traitement de première intention chez la plupart des patients.

The hallmarks of achalasia, a primary esophageal motility disorder, are incomplete relaxation of the lower esophageal sphincter (LES), elevated LES pressure in the majority of patients and aperistalsis in the esophageal body (1). The aim of treatment for achalasia is to weaken or eliminate the functional obstruction caused by the incomplete relaxation of the LES. This may be achieved pharmacologically (2), by intrasphincteric injection of botulinum toxin (3), by surgical myotomy (4) or by pneumatic dilation of the LES. The latter form of treatment, which is still the most common first-line therapy for the treatment of achalasia, is reviewed in this paper.

TECHNIQUE

The aim of dilation in achalasia is a controlled disruption of circular muscle fibres of the LES to reduce the functional obstruction. To achieve this goal, a forceful overstretching using a mechanical or pneumatic dilator is necessary. Simple bougienage is inadequate because of the smooth muscle properties of the circular muscle fibres, which adapt to stretch; it produces only transient improvement of symptoms for several days at best (5).

The patient should be prepared adequately for the dilation procedure. Because many patients with achalasia have a dilated esophagus that retains food debris, it is advisable to

This mini-review was prepared from a presentation made at the World Congress of Gastroenterology, Vienna, Austria, September 6 to 11, 1998
Department of Internal Medicine III, Zentralklinikum Augsburg, Augsburg, Germany
Correspondence: Drs Maximilian Bittinger and Martin Wienbeck, Department of Internal Medicine III, Zentralklinikum Augsburg, PO Box 101920, D-86009 Augsburg, Germany. Telephone +49-821-400-3331, fax +49-821-486-2915, e-mail max.bittinger@t-online.de
Received for publication July 21, 1999. Accepted July 30, 1999

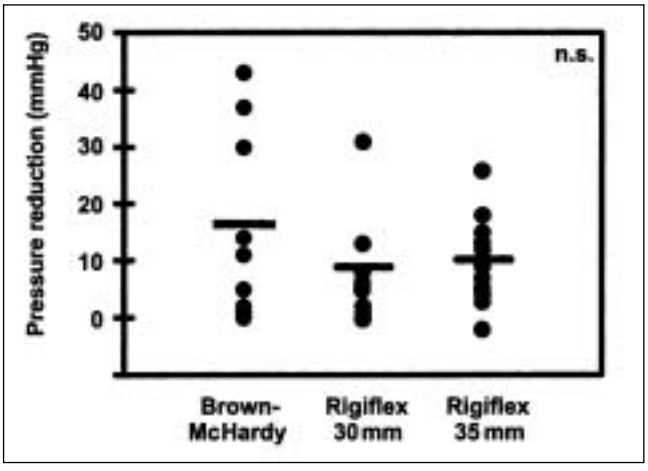

Figure 1) *Influence of the type of dilator on the achieved reduction of the lower esophageal sphincter pressure in 30 patients with achalasia (first dilation). There is no significant difference among the three dilators (Brown-McHardy [Narco Scientific, USA], Rigiflex 30 mm and Rigiflex 35 mm [Microvasive, USA]). n.s. Not significant. Data from reference 18*

give them only liquid food for two to three days before the dilation. In some patients, it is necessary to clean the esophagus before the dilation (6). Administration of a sedative and/or an analgesic drug is advisable because the dilation is usually painful (6). The correct placement of the dilator in the narrow zone of the LES has to be confirmed by fluoroscopic or endoscopic control. The dilation of the LES is performed by inflation of the dilator; the size of the dilation balloon, the dilation pressure and the dilation time depend on the preference and experience of the dilating physician and the type of prior dilation procedures. In adults, the maximum balloon diameter varies between 3.0 and 4.0 cm, the dilation pressure between 300 mmHg (6 PSI) and 750 mmHg (15 PSI) and the dilation time between 6 s and several minutes, respectively (7). Many physicians order an esophagogram after the procedure to rule out esophageal perforation, but this procedure remains controversial (8). Many centres perform pneumatic dilation on an outpatient basis, as suggested by Barkin et al (9), but hospitalization for observation is also appropriate.

Dilators: Several types of dilators are used in the treatment of achalasia. The Starck dilator, a mechanical dilator, was the first widely available dilator and has been used since 1924 (10). Although this dilator produces good clinical results, even in the long term (success rate 84% in a mean follow-up period of 11.5 years) (11), that are comparable with results from newer pneumatic dilation systems (12), its use has been abandoned in most centres because of some disadvantages; the correct placement of this dilator is difficult and an exact dosage of the dilation pressure is not possible (7,13). If this type of dilator is used by an experienced physician, however, the complication rates are not different from those seen after pneumatic dilation (12).

The pneumatic dilators may be classified into high compliance (HC) balloons (eg, Brown-McHardy dilator [Narco Scientific, USA], Witzel dilator [ABS, Par d'Activité Saint Michel, France]) and low compliance (LC) systems (eg, Rigiflex dilator [Microvasive, USA]). LC balloons are inflated up to a designated maximum diameter; further inflation only results in an incremental increase in the pressure but not in a further incremental increase in diameter. Because of these characteristics, the balloon attaches to the esophageal wall only in the stenotic zone; therefore, wall tension is increased maximally in this zone. In contrast, HC balloons adapt their form more closely to the esophagus. This leads to an increase in the esophageal wall tension proximal to the stenotic zone, and, according to Laplace's law, the wall tension is higher in the proximally widened esophagus than in the stenotic zone (14). Indeed, the typical location for esophageal perforation during pneumatic dilation is proximal to the cardia on the left lateral side of the esophagus (15). Theoretically, the use of LC systems should, therefore, reduce the rate of perforations. In addition, positioning of the older HC dilators (eg, Brown-McHardy dilator) can be difficult in patients with tortuous esophagus (16), while the Rigiflex dilator can be easily positioned over a guidewire under fluoroscopic control. However, until now, only two prospective, randomized studies have compared HC and LC dilators in achalasia. Stark et al (16) studied 20 patients and found a 100% success rate for the HC dilator (Brown-McHardy) and a 70% success rate for the LC dilator (Rigiflex), but 13 additional patients could not be randomly assigned because of difficulties in placing the Brown-McHardy dilator due to a tortuous esophagus. Therefore, selection bias cannot be excluded in this study. Mühldorfer et al (17) studied 25 patients – 13 were treated with an HC dilator (Pentax FG-29X [Pentax Precision Instrument Corporation, USA]) and 12 with an LC system (Rigiflex). There was no difference in the long term success rate nor in the complication rate. In addition, a retrospective study, including 30 patients with achalasia, found no significant difference in the reduction of the LES pressure between an HC dilator (Brown-McHardy) and two LC dilators (Rigiflex 30 and 35 mm) (Figure 1) (18). HC and LC systems, therefore, seem to have equal efficacies.

Efficacy: Many studies show that pneumatic dilation is an effective therapy for the majority of patients with achalasia (Figure 2); the mean success rate is about 80% in the short term (7,19). A substantial number of dilated patients (about 18% [Figure 2]), however, need a redilation in the further course of their disease (7). In the long term, the effect of the first dilation seems to decline with time (Figure 3); Eckardt et al (20) saw a decline in the remission rate, from 78% immediately after dilation to 26% after five years, and Ponce et al (21) observed a decline from 80% after dilation to 51% after five years. This, however, has been questioned by others who found a long term success rate of 85% (mean follow-up 6.5 years) after one or two dilations (22), and many patients were treated effectively for years by a single dilation (22,23). In patients who require redilation, repeated dilations seem to increase the duration of the remission; Eckardt et al (20) found a rise in

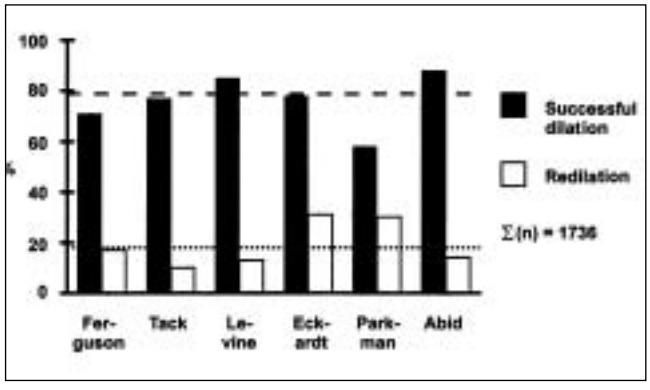

Figure 2) *Overview of the results of pneumatic dilation in different studies comprising a total of 1736 patients. The black bars show the rates of successful dilation, the white bars the rate of patients in whom at least one redilation was necessary. The lines indicate the mean success rate of all studies (79% [dashed line]) and the mean rate of redilation (18% [dotted line]). Data from references 20,24,36-39*

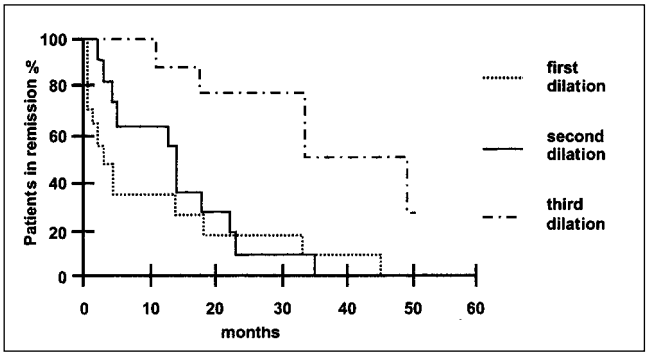

Figure 3) *Duration of remission after repeated dilations in 11 patients who required three dilations (Brown-McHardy [Narco Scientific, USA]). The remission period increases after each dilation. Reproduced with permission from reference 20*

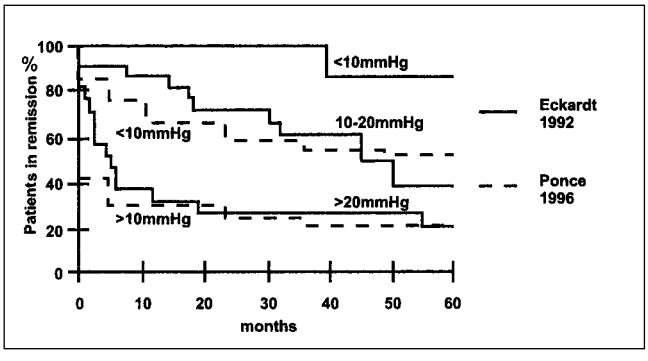

Figure 4) *Probability of remission for patients with different lower esophageal sphincter pressures after pneumatic dilation in the studies by Eckardt et al (reference 20) and Ponce et al (reference 21). The best long term results are achieved when the postdilation lower esophageal sphincter pressure is below 10 mmHg. Adapted with permission from references 20 and 21*

the one-year remission rate – from 36% after the first dilation to 55% after the second and to 89% after the third dilation, respectively.

Outcome predictors: Several studies have investigated whether the effect of pneumatic dilation can be predicted by patient characteristics, dilation parameters or results of postdilation investigations. In a retrospective study comprising 123 patients, the only parameter that showed a significant association with a better long term outcome after pneumatic dilation was a patient age greater than 45 years. All other parameters (sex, LES pressure before dilation, duration of symptoms, esophageal diameter, inflation pressure and inflation time during dilation) were not useful predictors of outcome (24). A prospective study involving 54 patients supported these data; patients older than 40 years of age showed a significantly better response to pneumatic dilation than younger patients, while other parameters (sex, LES pressure before dilation, duration of symptoms, esophageal diameter) showed no significant influence (20). The most valuable factor predicting long term clinical response, however, seems to be the LES pressure four weeks after the dilation (Figure 4). The two-year remission rate was 100% in patients showing a postdilation LES pressure less than 10 mmHg, and 71% if LES pressure was between 10 and 20 mmHg, but only 21% if LES pressure was greater than 20 mmHg (19). Similar results were observed by Ponce et al (21), who also found a significantly better long term efficacy in patients with a postdilation LES pressure less than 10 mmHg (Figure 4).

Neither the dilation pressure nor the dilation time has a significant influence on the results. In a study of 30 patients with achalasia receiving their first dilation, the reduction of the LES pressure was correlated with neither the dilation pressure nor the dilation time (18). Similar results were observed by several other investigators (20,24,25). Another recent prospective, randomized study comprising 81 patients showed that a short dilation time of 6 s is as effective as a long dilation time of 60 s (26). As discussed above, the type of dilator seems to have no significant influence on the results.

Complications: After pneumatic dilation, several complications can occur – the most serious is esophageal perforation. Other major complications are hemorrhage, fever and the development of gastroesophageal reflux disease. Less serious adverse events include intramural hematoma, mucosal tears, prolonged chest pain and transient cardiac arrhythmias. The overall rate of complications (major and minor) was 9% in a retrospective study by Nair et al (27) comprising 178 patients, but 30% in another study comprising 67 patients (28). The complication rate in the latter study, however, was criticized in an accompanying editorial (29) because the majority of these adverse events (namely prolonged chest pain and formation of diverticula at the cardia) had no clinical sequelae. Aside from these minor events, the complication rate in the latter study was 4.4%.

Esophageal perforation occurs in about 2.5% of cases, with a range of 0% to 3% in different studies (Figure 5). Perforation is usually detected by an esophagogram, but it must be kept in mind that an immediate radiological check

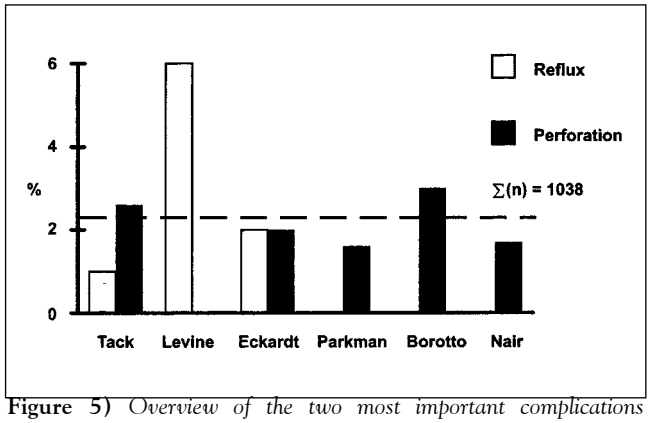

Figure 5) *Overview of the two most important complications (esophageal perforation [black bars] and gastroesophageal reflux disease [white bars]) after pneumatic dilation in different studies (15,24,27,28,37,38) comprising a total of 1038 patients. The line indicates the mean perforation rate of 2.5%*

with water-soluble contrast material following dilation cannot always exclude a perforation that may become clinically evident several hours later (27,30). If perforation occurs, this complication is usually managed conservatively (7,31) if the defects are not too large, are detected early and are located intrathoracically. Some factors seem to be associated with an increased risk of perforation. In a study by Borotto et al (15), long duration of symptoms, only slight weight loss and contraction amplitudes greater than 70 cm H_2O were identified as risk factors for perforations, and Nair et al (27) found that the use of dilation pressures greater than 500 mmHg (10 PSI) significantly increased the risk of perforation (9.1% versus 0.7% in patients with inflation pressures of 50 mmHg [10 PSI] or less). In this study, the risk of major complications was also increased in patients with one or more previous pneumatic dilations, but the risk of perforations was not significantly increased.

Gastroesophageal reflux disease may also develop after pneumatic dilation, but it is usually mild and responds well to conservative treatment (6). The rate of postdilation reflux ranges from 0% to 6% in most studies (Figure 5), but a recent paper found pathological esophageal pH in 35% of the patients after pneumatic dilation (31). Most of these patients were asymptomatic.

Comparison with other forms of treatment for achalasia: Until now, only one prospective, randomized study comparing pneumatic dilation with esophagomyotomy existed (4). In this study, which comprised 81 patients with a median follow-up of 60 months, the long term benefit of esophagomyotomy was significantly better than that of pneumatic dilation (remission rate 95% versus 65%), but the study was criticized because the technique used for dilation was not optimal (32). Treatment costs and, at least in the case of the nonlaparoscopic esophagomyotomy, the rate of complications, particularly the rate of subsequent gastroesophageal reflux disease, are higher after surgical therapy (4,24). The average cost of surgical treatment by open esophagomyotomy was US$19,000, while the average cost of an uncomplicated pneumatic dilation was US$3,654 (24). In addition, it has been shown that many patients can be treated effectively for years with a single pneumatic dilation (22,23). These advantages of pneumatic dilation, however, have to be seen in the light of the rapidly accumulating data on the laparoscopic approach to esophagomyotomy (which suggest an efficacy equal to the open technique but reduced morbidity and reduced cost). Until now, no studies comparing pneumatic dilation with laparoscopic esophagomyotomy have been available.

Since 1994, a third effective form of therapy for achalasia has existed – the intrasphincteric injection of botulinum toxin (3). In the short term, injection of botulinum toxin is equally effective compared with pneumatic dilation (22,33,34). The main drawback of botulinum toxin, however, is its short duration of response. The mean duration of response to a single injection therapy is about seven months (34), and the need for retreatment after two years far exceeds that of pneumatic dilation. While 70% of patients treated by a single pneumatic dilation were in remission after two years, this was the case in only 22% of those treated by a single botulinum toxin injection (35). In addition, the consequences of repeated injections of botulinum toxin are unknown.

CONCLUSIONS

Pneumatic dilation is an effective and safe treatment for the majority of patients suffering from achalasia of the esophagus. Because of the drawbacks of other forms of treatment, pneumatic dilation is still considered to be the first-line treatment for achalasia. In some selected patient groups (young patients, patients not responsive to pneumatic dilation, patients with severe medical disorders excluding surgical therapy if perforation occurs), esophagomyotomy and intrasphincteric injection of botulinum toxin are valuable alternatives. The choice of the dilator and technique used for dilation should be based on the experience of the dilating physician because the results seem to be similar among the different dilators and techniques.

REFERENCES

1. Vantrappen G, Hellemans J. Treatment of achalasia and related motor disorders. Gastroenterology 1980;79:144-54.
2. Bortolotti M, Labo G. Clinical and manometric effects of nifedipine in patients with esophageal achalasia. Gastroenterology 1981;80:39-44.
3. Pasricha P, Ravich W, Hendrix T, et al. Intrasphincteric botulinum toxin for the treatment of achalasia. N Engl J Med 1995;322:774-8.
4. Csendes A, Braghetto I, Mascaro J, Henriquez A. Late subjective and objective evaluation of the results of esophagomyotomy in 100 patients with achalasia of the esophagus. Surgery 1988;104:469-75.
5. Clouse R, Diamant N. Motor physiology and motor disorders of the esophagus. In: Feldman M, Scharschmidt B, Sleisinger M, eds. Gastrointestinal and Liver Disease. Philadelphia: WB Saunders, 1998:467-97.
6. American Society for Gastrointestinal Endoscopy. Esophageal dilation. Gastrointest Endosc 1998;48:702-4.
7. Eberl T, Barnert J, Wienbeck M. Achalasie – Konservative Therapie. In: Fuchs KH, Stein HJ, Thiede A, eds. Gastrointestinale Funktionsstörungen. Berlin: Springer, 1997:460-73.
8. Ciarolla DA, Traube M. Achalasia – Short-term clinical monitoring after pneumatic dilation. Dig Dis Sci 1993;38:1905-8.

9. Barkin JS, Guelrud M, Reiner DK, Goldberg RI, Phillips RS. Forceful balloon dilatation: an outpatient procedure for achalasia. Gastrointest Endosc 1990;36:123-6.
10. Starck H. Die Behandlung der spasmogenen Speiseröhrenerweiterung. Münch Med Wochenschr 1924;71:334-6.
11. Gugulski A, Bartnik W, Bartnik E. Long-term results of treatment of esophageal achalasia using a Starck dilator. Digestion 1996;57:383-7.
12. Mearin F, Armengol JR, Chicharro L, Papo M, Balboa A, Malagelada JR. Forceful dilatation under endoscopic control in the treatment of achalasia: a randomised trial of pneumatic versus metallic dilator. Gut 1994;35:1360-2.
13. Wienbeck M, Barnert J. Therapie der Achalasie. Dtsch Med Wochenschr 1989;114:1971-3.
14. Rabinovici R, Katz E, Goldin E, Kluger Y, Ayalon A. The danger of high compliance balloons for esophageal dilatation in achalasia. Endoscopy 1990;22:63-4.
15. Borotto E, Gaudric M, Danel B, et al. Risk factors of oesophageal perforation during pneumatic dilatation for achalasia. Gut 1996;39:9-12.
16. Stark GA, Castell DO, Richter JE, Wu WC. Proseptive randomized comparison of Brown-McHardy and microvasive balloon dilators in treatment of achalasia. Am J Gastroenterol 1990;85:1322-6.
17. Mühldorfer SM, Hahn EG, Ell C. High- and low-compliance balloon dilators in patients with achalasia: a randomized prospective comparative trial. Gastrointest Endosc 1996;44:398-403.
18. Bittinger M, Barnert J, Wienbeck M. Pneumatic dilatation in achalasia – Which factors have influence on the reduction of LES-pressure? Gastroenterology 1997;112:A72. (Abst)
19. Spiess A, Kahrilas PJ. Treating achalasia – from whalebone to laparoscope. JAMA 1998;280:638-42.
20. Eckardt VF, Aignherr C, Bernhard G. Predictors of outcome in patients with achalasia treated by pneumatic dilation. Gastroenterology 1992;103:1732-8.
21. Ponce J, Garrigues V, Pertejo V, Sala T, Berenguer J. Individual prediction of response to pneumatic dilation in patients with achalasia. Dig Dis Sci 1996;41:2135-41.
22. Katz PO, Gilbert J, Castell DO. Pneumatic dilatation is effective long-term treatment for achalasia. Dig Dis Sci 1998;43:1973-7.
23. Prakash C, Freedland KE, Chan MF, Clouse RE. Botulinum toxin injections for achalasia symptoms can approximate the short term efficacy of a single pneumatic dilation: a survival analysis approach. Am J Gastroenterol 1999;94:328-33.
24. Parkman HP, Reynolds JC, Ouyang A, Rosato EF, Eisenberg J, Cohen S. Pneumatic dilatation or esophagomyotomy treatment for idiopathic achalasia: Clinical outcome and cost analysis. Dig Dis Sci 1993;38:75-85.
25. Gideon RM, Katzka D, Yarze J, Castell DO. Prospective comparison of inflation technique for pneumatic dilatation of achalasia. Am J Gastroenterol 1995;90:A1559. (Abst)
26. Khan AA, Shah SWH, Alam A, Butt AK, Shafqat F, Castell DO. Pneumatic balloon dilation in achalasia: a prospective comparison of balloon distension time. Am J Gastroenterol 1998;93:1064-7.
27. Nair LA, Reynolds JC, Parkman HP, et al. Complications during pneumatic dilation for achalasia or diffuse esophageal spasm – Analysis of risk factors, early clinical characteristics and outcome. Dig Dis Sci 1993;38:1893-904.
28. Eckardt VF, Kanzler G, Westermeier T. Complications and their impact after pneumatic dilation for achalasia: prospective long-term follow-up study. Gastrointest Endosc 1997;45:349-53.
29. Khandelwal M, Ouyang A. Pneumatic dilation for achalasia: are all complications revealed? Gastrointest Endosc 1997;45:437-9.
30. Ott DJ, Donati D, Wu WC, Chen MYM, Gelfand DW. Radiographic evaluation of achalasia immediately after pneumatic dilatation with the Rigiflex dilator. Gastrointest Radiol 1991;16:279-82.
31. Pasricha PJ, Fleischer DE, Kalloo AN. Endoscopic perforations of the upper digestive tract: a review of their pathogenesis, prevention and management. Gastroenterology 1994;106:787-802.
32. Shoenut JP, Duerksen D, Yaffe CS. A prospective assessment of gastroesophageal reflux before and after treatment af achalasia patients: pneumatic dilation versus transthoracic limited myotomy. Am J Gastroenterol 1997;92:1109-12.
33. Richter JE. Surgery or pneumatic dilatation for achalasia: a head-to-head comparison: now are all the questions answered? Gastroenterology 1989;97:1340-1.
34. Annese V, Basciani M, Perri F, et al. Controlled trial of botulinum toxin injection versus placebo and pneumatic dilation in achalasia. Gastroenterology 1996;111:1418-24.
35. Mühldorfer SM, Schneider T, Hochberger J, Hahn EG, Ell C. Intrasphincteric injection of botulinum toxin A versus balloon dilation in patients with achalasia. A randomized prospective comparative trial. Gastrointest Endosc 1998;47:AB74. (Abst)
36. Ferguson MK. Achalasia: current evaluation and therapy. Ann Thorac Surg 1991;52:336-42.
37. Tack J, Janssens J, Vantrappen G. Non-surgical treatment of achalasia. Hepatogastroenterology 1991;38:493-7.
38. Levine MM, Moskowitz GW, Dorf BS, Bank S. Pneumatic dilation in patients with achalasia with a modified Gruntzig dilator (Levine) under direct endoscopic control: Results after 5 years. Am J Gastroenterol 1991;86:1581-4.
39. Abid S, Champion G, Richter JE, McElvein R, Slaughter RL, Koehler RE. Treatment of achalasia: The best of both worlds. Am J Gastroenterol 1994;89:979-85.