New endoscopic techniques for obscure gastrointestinal bleeding

Henk den Ouden MD[1], SAC van Tuyl MD[1], Marcel Groenen MD[2], Mark FJ Stolk MD PhD[1], Ernst J Kuipers MD PhD[2]

H den Ouden, SAC van Tuyl, M Groenen, MFJ Stolk, EJ Kuipers. New endoscopic techniques for obscure gastrointestinal bleeding. Can J Gastroenterol 2007;21(9):597-600.

The case of a postmenopausal woman with a congenital aortic stenosis is presented. She presented with severe iron deficiency anemia. After negative extensive gastrointestinal analysis, she was treated with octreotide for six months. After cessation of octreotide, anemia rapidly recurred. A second capsule endoscopy and a double balloon enteroscopy were performed, and an intestinal vascular malformation was found. After surgical segment resection, the patient had stable, normal levels of hemoglobin and no complaints after 14 months of follow-up.

Key Words: *Capsule endoscopy; Double balloon enteroscopy; Gastrointestinal bleeding; Octreotide*

De nouvelles techniques endoscopiques pour déceler les saignements gastro-intestinaux occultes

On présente le cas d'une femme ménopausée atteinte de sténose aortique congénitale. Elle a consulté en raison d'une grave anémie ferriprive. Après une analyse gastro-intestinale généralisée, elle a reçu un traitement à l'octréotide pendant six mois. Après la fin de ce traitement, l'anémie a vite refait son apparition. Une deuxième endoscopie capsulaire et une entéroscopie à double ballonnet ont permis de repérer une malformation vasculaire de l'intestin. Après la résection chirurgicale du segment atteint, la patiente a maintenu un taux stable et normal d'hémoglobine et n'avait plus de symptômes au bout de quatorze mois de suivi.

The source of obscure gastrointestinal bleeding is often difficult to locate. The small intestine beyond the ligament of Treitz is the source of bleeding in up to 5% of patients presenting with gastrointestinal bleeding (1). In the small bowel, angiodysplasia is the most common cause of obscure bleeding, followed by neoplasm. Until recently, the small bowel was difficult to examine in an effective and patient-friendly manner. Small bowel enteroclysis can reveal strictures and tumours; however, mucosal abnormalities are difficult to detect. Push enteroscopy allows limited access to the proximal small intestine. Intraoperative enteroscopy allows complete examination of the small bowel but is very invasive. New endoscopic techniques such as capsule endoscopy (CE) and double balloon enteroscopy (DBE) enable complete examination of the small bowel. CE is a wireless noninvasive imaging technique. After ingestion, a video capsule takes two photographs per second during its journey through the small intestine. The main indication is obscure intestinal bleeding that cannot be clarified by esophagogastroduodenoscopy and colonoscopy. CE can only be used as a diagnostic tool, because no interventions are possible with the capsule. DBE is a technique in which an enteroscope is introduced from the oral or anal route into the small intestine and is advanced by sequential inflation and desufflation of two balloons attached to the enteroscope and an overtube. DBE allows the same interventions as with conventional endoscopy. At present, the best candidates for the procedure appear to be patients with obscure bleeding. The current case report presents a patient with obscure gastrointestinal bleeding, and discusses the application of CE and DBE.

CASE PRESENTATION

A 51-year-old postmenopausal woman presented with iron deficiency anemia. She felt tired and dizzy, but had never observed overt blood loss and had no abdominal symptoms. Her medical history included a congenital aortic stenosis for which an aortoplasty had been performed when she was nine years old. At 33 years of age, a Bjork-Shiley aortic valve prosthesis was implanted and acenocoumarol was started. After mechanical dysfunction, a Sorin valve prosthesis was implanted six years later. Laboratory investigation showed a hemoglobin level of 6.8 g/dL (68 g/L), severe iron deficiency and no signs of hemolytic anemia. Bone marrow evaluation revealed no abnormalities. Colonoscopy, gastroduodenoscopy, small bowel follow-through, push enteroscopy and CE showed no abnormalities. Oral and intravenous iron supplementation only resulted in a minor increase in hemoglobin level. Over six months, she was treated with 20 mg octreotide injections (Sandostatin LAR, Novartis Pharmaceuticals Canada Inc) under the presumptive diagnosis of obscure gastrointestinal bleeding. This resulted in a complete normalization of hemoglobin levels and disappearance of complaints (Figure 1). After cessation of octreotide, iron deficiency anemia rapidly

[1]*Department of Gastroenterology, St Antonius Hospital, Nieuwegein;* [2]*Erasmus Medical Center, Rotterdam, The Netherlands*
Correspondence and reprints: Dr Mark FJ Stolk, Department of Gastroenterology, St Antonius Hospital, PO Box 2500, 3430 EM Nieuwegein, The Netherlands. Telephone 31-30-609-91-11, fax 31-30-605-63-57, e-mail m.stolk@antonius.net
Received for publication June 14, 2006. Accepted August 12, 2006

DISCUSSION

Despite examination of the gastrointestinal tract by gastroduodenoscopy and colonoscopy, the origin of obscure occult bleeding remains unexplained in 10% of cases (2). Angiodysplasia in the small bowel is the cause of obscure gastrointestinal blood loss in 30% to 40% of these patients (2). These vascular malformations are composed of conglomerates of ectatic, dilated, tortuous, thin-walled vessels. Their pathogenesis is uncertain. Associations with chronic mucosal ischemia and with low-grade venous obstruction have been suggested; a congenital predisposition has also been considered (3-5). The prevalence of gastrointestinal angiodysplasia in the general population is unknown. Most of these vascular lesions are detected in patients older than 60 years of age (3). An association between aortic valve disease and angiodysplasia has been recognized for years (Heyde's syndrome). Evidence is mounting that severe aortic stenosis may cause acquired type II von Willebrand disease. Heyde's syndrome appears to involve bleeding from previously latent intestinal angiodysplasia as a result of acquired type II von Willebrand disease (6,7). Recently, a retrospective analysis (7) of 3.8 million hospital discharges found a significant association between bleeding due to intestinal angiodysplasias and aortic stenosis. However, von Willebrand disease and its acquired form are very rare; only a positive family history or a typical history of recurrent mucosal bleeding episodes from multiple sites (eg, epistaxis or bleeding after tonsillectomy) may lead to assessment of von Willebrand factor.

Octreotide, a synthetic somatostatin analogue, is a peptide shown to markedly reduce splanchnic blood flow through specific subtype receptors (8,9). In a study (10) of three patients with bleeding due to small intestinal angiodysplasia, octreotide was well tolerated and resulted in a decrease in or elimination of the need for transfusions. However, it did not result in regression of the angiodysplastic lesions. In another study (9), 17 patients were treated with octreotide. Treatment stopped bleeding in 10 patients and a transient improvement was observed in another four patients. Therefore, octreotide may be useful to control bleeding from small bowel angiodysplasia, as was also shown in our patient.

CE is a new noninvasive imaging technique for the entire small bowel. It provides good visualization of the small intestinal mucosa. The diagnostic yield for obscure bleeding varies between 60% and 92% (2,11-14), and is now considered an important diagnostic tool in cases of normal gastroduodenoscopy and colonoscopy. It is superior to push enteroscopy, small bowel barium follow-through and computed tomography in patients with obscure gastrointestinal bleeding, iron deficiency anemia and Crohn's disease. Diarrhea, small bowel tumours and celiac disease may also become important indications (15). A recent study (16) assessed the diagnostic yield of repeated CE with a previous negative evaluation. CE revealed a definite or suspected source of bleeding in 35% of the 20 patients. Another study (17) with 24 patients showed a high yield of new findings (75%) on repeat CE. A report on false-negative CE (18) revealed reasons for missed lesions, such as a small intestinal bowel delay of capsule transit longer than 15 min, capsule nonexcretion and dilation of the small bowel without food debris. However, none of these factors were identified in our patient. Although CE does have certain limitations, there is no possibility of air insufflation, rinsing of tissue, taking biopsies and therapeutic interventions. Due to its patient-friendly nature, CE will probably be widely used as a 'screening tool', whereas DBE will be applied when an abnormality is found by CE or when severe symptoms are not explained by CE. DBE allows visualization of the entire small bowel and offers the possibility of taking biopsies and performing therapeutic interventions. Lesions can be marked by submucosal injection of lipiodol or India ink (19,20). Obscure-overt gastrointestinal blood loss is the most important indication for DBE. The exact diagnostic yield and clinical implications still have to be defined. CE and DBE are important diagnostic and therapeutic options for gastrointestinal bleeding. Both are considered essential components of the diagnostic workup for obscure gastrointestinal bleeding (19-22).

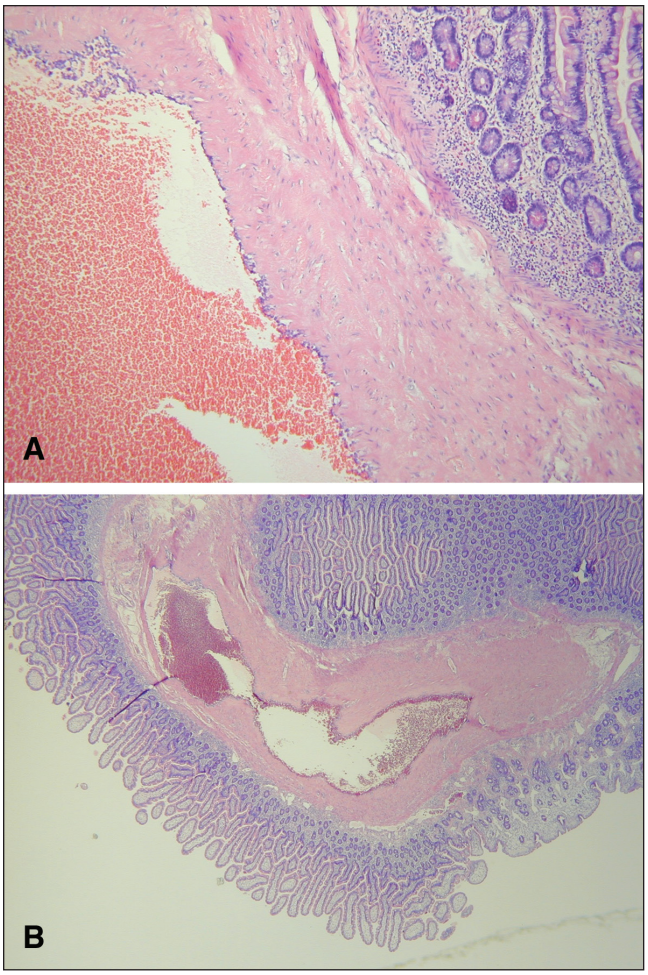

Figure 4) *Histopathological examination showing a large, hemangioma-like, polypous, ectatic vascular conglomerate, partly thin-walled and partly thick-walled. Hematoxylin and eosin stain, original magnification ×100* (**A**) *and ×20* (**B**)

Obscure gastrointestinal bleeding gives a high yield of new findings on repeat CE (17), and DBE also appears to surpass other imaging modalities (19). Thus, new pathological findings are possible (23). The combination of CE and DBE is very important for diagnosis and treatment. The present case with a large, polypous, ectatic vascular conglomerate clearly demonstrates the usefulness of repeated CE and DBE in a patient with obscure gastrointestinal bleeding.

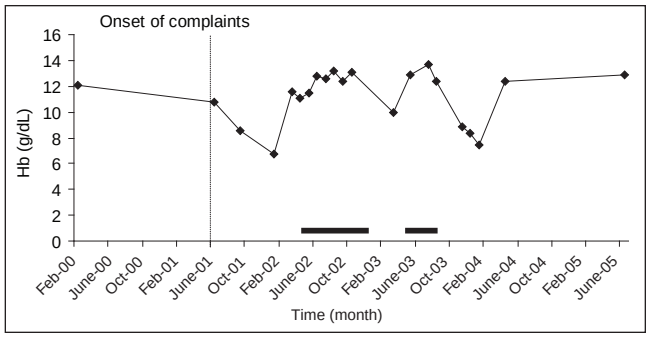

Figure 1) *Hemoglobin (Hb) levels. Horizontal solid bars indicate 20 mg monthly injections of octreotide (Sandostatin LAR, Novartis Pharmaceuticals Canada Inc). Feb February; Oct October*

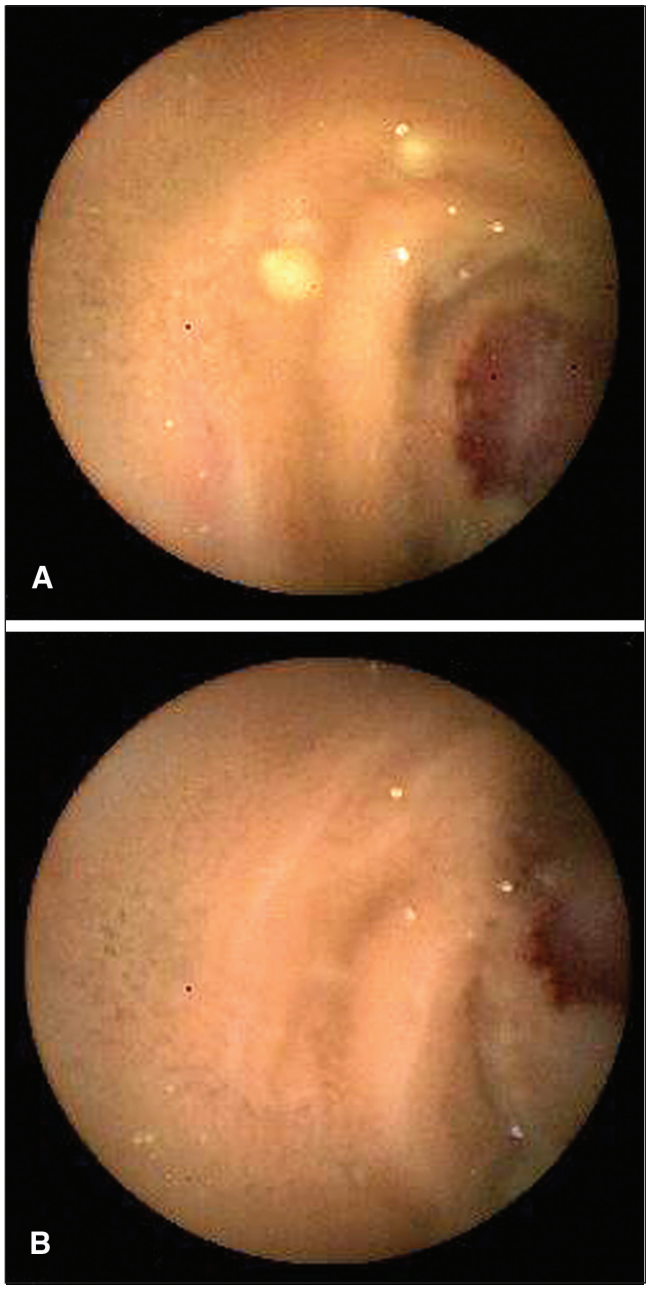

Figure 2) *Second video capsule examination showing a solitary ulcerating angiodysplasia 2 h 9 min after ingestion.* **A** *and* **B** *show different timings (0.5 to 1.0 second apart)*

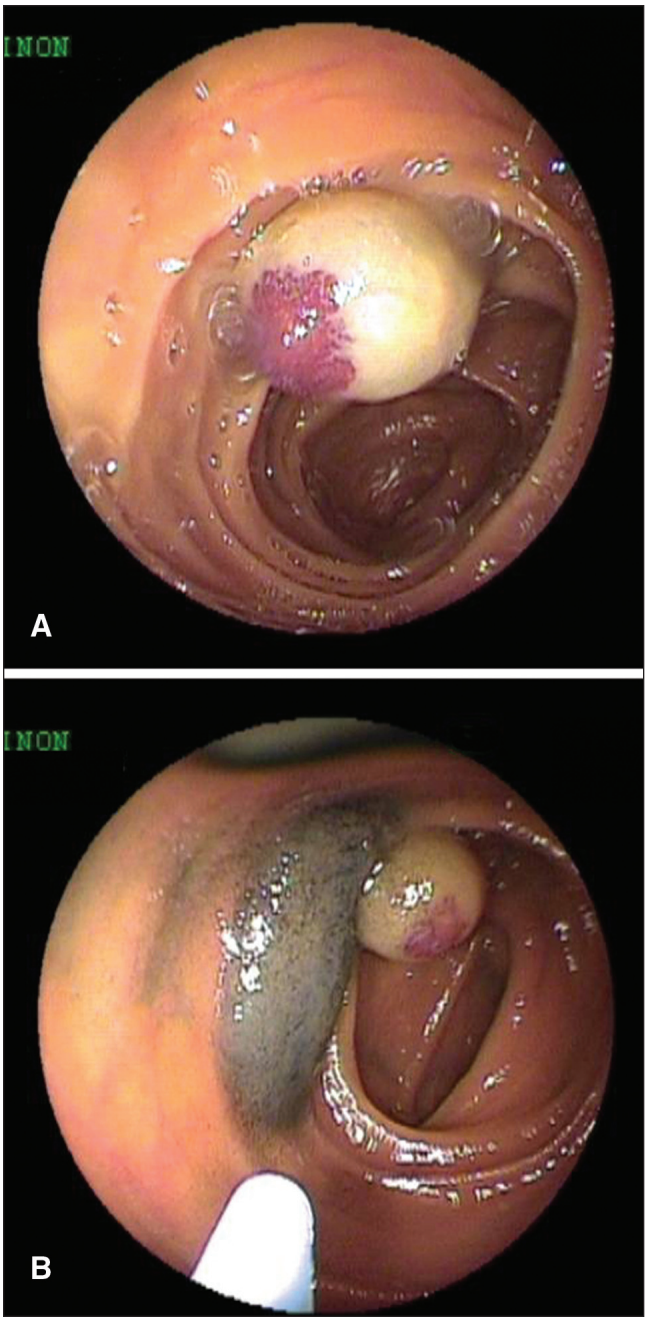

Figure 3) A *Double balloon enteroscopy showing a polypous angiodysplasia.* **B** *The location is marked with India ink and lipiodol*

recurred. Gastroscopy and colonoscopy were repeated, but again revealed no bleeding focus. A second CE showed a solitary ulcerating angiodysplasia in the middle part of the small bowel (Figures 2A, 2B). DBE was subsequently performed and showed a large, submucosal, polypoid, blue-purple tumour (Figure 3A). The lesion was marked at the base by submucosal injection with India ink and lipiodol (Figure 3B); a surgical segment resection of 15 cm was performed by a midline laparotomy. Histopathological examination revealed a large, hemangioma-like, polypous, ectatic vascular conglomerate with variable wall thickness (Figures 4A, 4B). The patient had a quick postoperative recovery, stable, normal levels of hemoglobin and no complaints after 14 months of follow-up.

REFERENCES

1. Lewis BS. Small intestinal bleeding. Gastroenterol Clin North Am 2000;29:67-95.
2. Fireman Z, Friedman S. Diagnostic yield of capsule endoscopy in obscure gastrointestinal bleeding. Digestion 2004;70:201-6.
3. Boley SJ, DiBiase A, Brandt LJ, Sammartano RJ. Lower intestinal bleeding in the elderly. Am J Surg 1979;137:57-64.
4. Baum S, Athanasoulis CA, Waltman AC, et al. Angiodysplasia of the right colon: A cause of gastrointestinal bleeding. AJR Am J Roentgenol 1977;129:789-94.
5. Rogers BH. Endoscopic diagnosis and therapy of mucosal vascular abnormalities of the gastrointestinal tract occurring in elderly patients and associated with cardiac, vascular, and pulmonary disease. Gastrointest Endosc 1980;26:134-8.
6. Pate GE, Chandavimol M, Naiman SC, Webb JG. Heyde's syndrome: A review. J Heart Valve Dis 2004;13:701-12.
7. Pate GE, Mulligan A. An epidemiological study of Heyde's syndrome: An association between aortic stenosis and gastrointestinal bleeding. J Heart Valve Dis 2004;13:713-6.
8. Andersen MR, Aaseby J. Somatostatin in the treatment of gastrointestinal bleeding caused by angiodysplasia. Scand J Gastroenterol 1996;31:1037-9.
9. Nardone G, Rocco A, Balzano T, Budillon G. The efficacy of octreotide therapy in chronic bleeding due to vascular abnormalities of the gastrointestinal tract. Aliment Pharmacol Ther 1999;13:1429-36.
10. Orsi P, Guatti-Zuliani C, Okolicsanyi L. Long-acting octreotide is effective in controlling rebleeding angiodysplasia of the gastrointestinal tract. Dig Liver Dis 2001;33:330-4.
11. Appleyard M, Glukhovsky A, Swain P. Wireless-capsule diagnostic endoscopy for recurrent small-bowel bleeding. N Engl J Med 2001;344:232-3.
12. Swain P, Fritscher-Ravens A. Role of video endoscopy in managing small bowel disease. Gut 2004;53:1866-75.
13. Melmed GY, Lo SK. Capsule endoscopy: Practical applications. Clin Gastroenterol Hepatol 2005;3:411-22.
14. Saurin JC, Delvaux M, Gaudin JL, et al. Diagnostic value of endoscopic capsule in patients with obscure digestive bleeding: Blinded comparison with video push-enteroscopy. Endoscopy 2003;35:576-84.
15. Kalantzis N, Papanikolaou IS, Giannakoulopoulou E, et al. Capsule endoscopy; the cumulative experience from its use in 193 patients with suspected small bowel disease. Hepatogastroenterology 2005;52:414-9.
16. Bar-Meir S, Eliakim R, Nadler M, et al. Second capsule endoscopy for patients with severe iron deficiency anemia. Gastrointest Endosc 2004;60:711-3.
17. Jones BH, Fleischer DE, Sharma VK, et al. Yield of repeat wireless video capsule endoscopy in patients with obscure gastrointestinal bleeding. Am J Gastroenterol 2005;100:1058-64.
18. Tang SJ, Zanati S, Dubcenco, et al. Capsule endoscopy regional transit abnormality revisited. Gastrointest Endosc 2004;60:1029-32.
19. Gerson LB. Double-balloon enteroscopy: The new gold standard for small-bowel imaging? Gastrointest Endosc 2005;62:71-5.
20. May A, Nachbar L, Ell C. Double-balloon enteroscopy (push-and-pull enteroscopy) of the small bowel: Feasibility and diagnostic and therapeutic yield in patients with suspected small bowel disease. Gastrointest Endosc 2005;62:62-70.
21. May A, Nachbar L, Wardak A, Yamamoto H, Ell C. Double-balloon enteroscopy: Preliminary experience in patients with obscure gastrointestinal bleeding or chronic abdominal pain. Endoscopy 2003;35:985-91.
22. Di Caro S, May A, Heine DG, et al; DBE-European Study Group. The European experience with double-balloon enteroscopy: Indications, methodology, safety, and clinical impact. Gastrointest Endosc 2005;62:545-50.
23. Kita H, Yamamoto H, Nakamura T, Shirakawa K, Terano A, Sugano K. Bleeding polyp in the mid small intestine identified by capsule endoscopy and treated by double-balloon endoscopy. Gastrointest Endosc 2005;61:628-9.