Re: Chang A, Krygier D, Chatur N, Yoshida EM. Clozapine-induced fatal fulminant hepatic failure. Can J Gastroenterol 2009;23:376-8.

To the Editor:

We read with interest the recent case of clozapine hepatotoxicity, reported in the May 2009 issue of *The Canadian Journal of Gastroenterology* (1). Before that case, there was only one previous published fatal case and five cases with milder hepatitis (1,2). We report here the third patient with severe hepatitis attributed to clozapine.

Our patient was a 51-year-old man with schizophrenia. He did not have a history of liver disease. He denied risk factors for liver disease. His only comorbidity was gastroesophageal reflux disease for which he had taken esomeprazole for several years. His schizophrenia had been treated with various antipsychotic medications over many years without adverse effects. Clozapine had been started three months before presentation.

The patient initially presented to his home hospital with jaundice and malaise. His initial investigations revealed mild elevation of alanine aminotransferase (ALT), aspartate aminotransferase (AST) and alkaline phosphatase (ALP). His international normalized ratio (INR) was normal at 1.3. After several days in hospital, the patient's INR increased to 2.8; he was subsequently transferred to the Queen Elizabeth II Health Sciences Centre in Halifax, Nova Scotia. On admission, physical examination revealed grade 1 hepatic encephalopathy. He did not have ascites or other stigmata of chronic liver disease. Blood work revealed an ALP level of 1079 U/L, an ALT level of 526 U/L, an AST level of 517 U/L, a gamma-glutamyl transferase level of 394 U/L, a lactate dehydrogenase level of 225 U/L, a total bilirubin level of 217 µmol/L, a direct bilirubin level of 120 µmol/L, an albumin level of 26 g/L and a serum creatinine level of 155 mmol/L. Serological markers for hepatitis A, B and C, cytomegalovirus and Epstein-Barr virus were absent. His serum alpha-1 antitrypsin, ceruloplasmin and hemoglobin levels were normal. Autoimmune markers including antinuclear antibodies, antismooth muscle antibodies and antimitochondrial antibodies were negative. Serum immunoglobulin (Ig) G level was slightly elevated at 20.7 g/L (upper limit of normal = 14.9 g/L); IgA and IgM levels were normal. An abdominal ultrasound with Doppler imaging scans of the liver was normal.

A liver biopsy performed on day 2 of hospitalization revealed massive hepatocellular necrosis with moderate infiltrate of lymphocytes and plasma cells, as well as occasional eosinophils (Figure 1). There was no fibrosis or steatosis. The findings were consistent with immune-mediated injury, similar to what may be encountered with drug-induced hepatitis or autoimmune hepatitis. A clinical diagnosis of drug-induced hepatitis secondary to clozapine was made and the drug was discontinued. Supportive care including ursodeoxycholic acid, N-acetylcysteine, lactulose and vitamin K was provided.

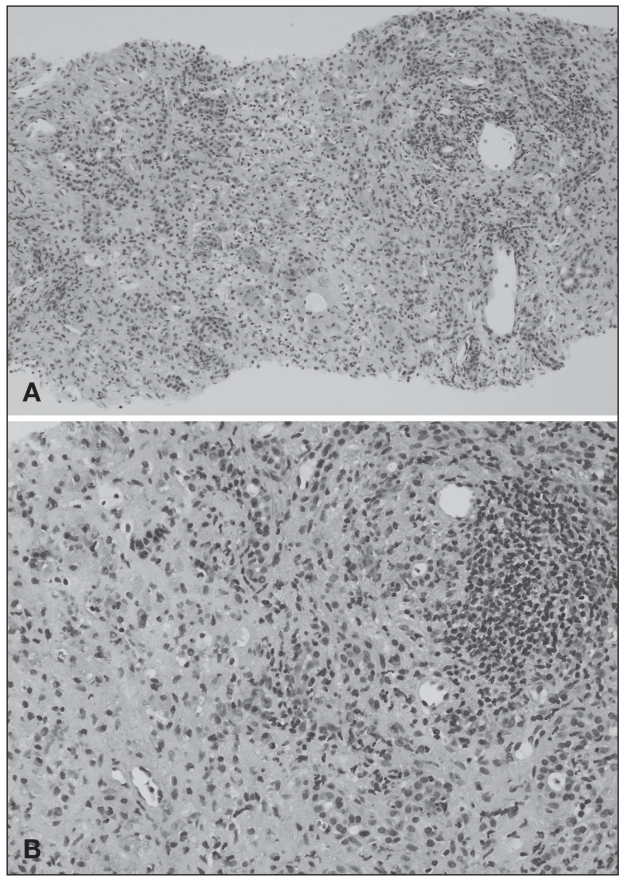

Figure 1) A *The liver biopsy shows marked recent necrosis with no recognizable hepatocytes and close approximation of adjacent portal tracts (hematoxylin and eosin stain, original magnification ×100).* **B** *Higher magnification shows a portal tract with predominantly mononuclear infiltrate (right) and zone 3 (left) with macrophages but no hepatocytes. A partially obstructed hepatic venule is seen at the bottom left (hematoxylin and eosin stain, original magnification ×200)*

One week after admission, the patient had improved clinically and biochemically (ALP level of 696 U/L, ALT level of 190 U/L, AST level of 292 U/L, total bilirubin level of 150 µmol/L and an INR of 1.7) and he had been preparing for discharge home. Unfortunately, he experienced a cardiac arrest; resuscitation attempts were unsuccessful. Autopsy revealed severe candida esophagitis with ulceration and intraluminal hemorrhage. The liver showed severe dropout of hepatocytes (approximately 70%) with regeneration, minimal residual inflammation and no significant fibrosis.

This patient had severe hepatic necrosis, most likely attributable to clozapine. The other drug taken recently by the patient (esomeprazole) has not been associated with severe hepatotoxicity and had been present for several years before presentation. Because the cause of death did not appear to be related to liver failure, we consider this a severe but nonfatal adverse effect of clozapine.

©2010 Pulsus Group Inc. All rights reserved

Clozapine is an atypical antipsychotic primarily used for the treatment of schizophrenia and schizoaffective disorder. It is generally reserved for patients whose symptoms are refractory to other antipsychotic agents. In addition to hepatitis, other significant side effects can occur including agranulocytosis. Due to the increased risk of fatal agranulocytosis (1%), clozapine was removed from the United States market in 1975. It was only reintroduced in 1990, with a strict policy regarding monitoring for agranulocytosis. According to this policy, patients on this medication are required to undergo weekly complete blood cell counts and absolute neutrophil counts for at least the first six months of treatment.

We have submitted this letter to help raise awareness of clozapine-associated hepatotoxicity. Although rare, severe hepatitis can occur and can be potentially life threatening. Periodic blood work is already required for patients on clozapine due to the risk of agranulocytosis. Perhaps adding serum aminotransferase levels to this protocol would enable earlier detection of potential liver injury.

Anna C Chaplin BSc,
Michael A Curley MD FRCPC,
Division of Gastroenterology,

Ian R Wanless MD FRCPC
Department of Pathology,
Victoria General Hospital,
Dalhousie University,
Halifax, Nova Scotia

REFERENCES

1. Chang A, Krygier D, Chatur N, Yoshida E. Clozapine-induced fatal fulminant hepatic failure: A case report. Can J Gastroenterol 2009;23:376-8.
2. MacFarlane B, Davies S, Mannan K, et al. Fatal acute fulminant liver failure due to clozapine: A case report and review of clozapine-induced hepatotoxicity. Gastroenterology 1997;112:1707-9.

Correspondence: Dr Michael Curley, Department of Gastroenterology, Victoria General Hospital, Dalhousie University, Victoria Building, Victoria General Hospital Site, 1276 South Park Street, Halifax, Nova Scotia B3H 2Y9. Telephone 902-404-3511, fax 902-404-3021, e-mail ma_curley@hotmail.com



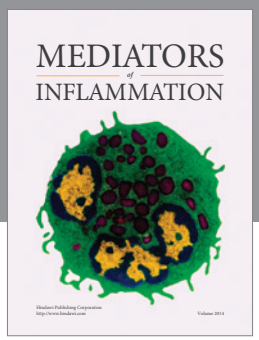

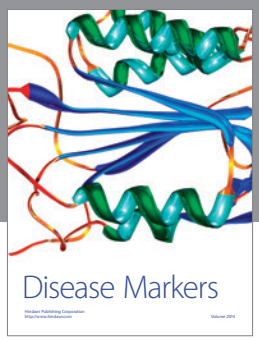



Hindawi
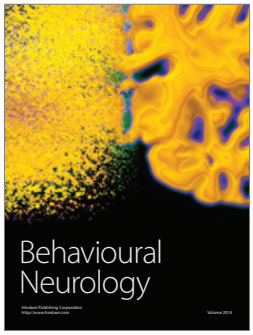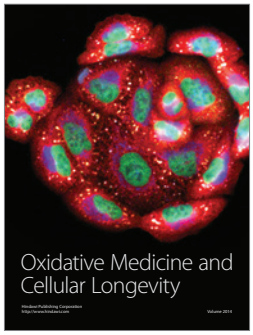
Submit your manuscripts at
http://www.hindawi.com