Occupational head-butting and skin nodules

Jana Pilkey MD FRCPC[1], Karen McClean MD FRCPC[2]

CASE PRESENTATION

A 28-year-old veterinary student presented with nodules on her forehead. Two weeks earlier, she had been butted in the head by a ram while working with a herd. She sustained a small abrasion over the left frontal area of her head. Six days after the injury, she noted the development of local erythema, swelling and pruritus. She had no fever, chills or systemic symptoms. Self treatment with topical polymyxin B sulfate/bacitracin zinc (Polysporin, Pfizer Inc, USA) yielded no improvement in the lesions.

At her initial assessment, two weeks after the injury, an examination showed three lesions above the left eyebrow, one measuring 1.5 cm × 0.6 cm and the other two measuring 0.3 cm to 0.5 cm in diameter. The lesions were vesicular, with an erythematous rim. Lymphadenopathy was not detected and there was no ocular involvement.

Within five days after her initial presentation, the lesions became nodular and the erythematous rim more vivid (Figure 1). Tender preauricular lymphadenopathy developed, and she reported fatigue and general malaise but remained afebrile. Aspiration of a lesion was done to obtain material for culture. Hematology and chemistry laboratory investigations were within normal limits.

Two days later, she developed fever and chills, with periorbital and facial edema. Blood cultures were negative. Intraocular involvement was ruled out with an examination by an ophthalmologist. Despite 72 h of intravenous clindamycin phosphate (600 mg every 8 h), the edema and lymphadenopathy worsened and she was switched to meropenem 1 g intravenously every 8 h. Improvement was detected within 48 h, and she completed a 10-day course.

As the edema resolved, the nodular lesions developed a superficial crust, which subsequently separated, revealing underlying papillomatous lesions. Over the next three weeks, the lesions slowly decreased in size and erythema. Complete healing without scarring ensued.

What was the cause of her skin lesions?

Figure 1) *Skin lesions in nodular stage*

[1]*Division of General Internal Medicine;* [2]*Division of Infectious Diseases, Department of Medicine, University of Saskatchewan, Saskatoon, Saskatchewan*
Correspondence and reprints: Dr Karen McClean, Department of Medicine, University of Saskatchewan, 103 Hospital Drive, Saskatoon, Saskatchewan S7N 0W8. Telephone 306-655-1777, fax 306-975-0383, e-mail karen.mcclean@usask.ca

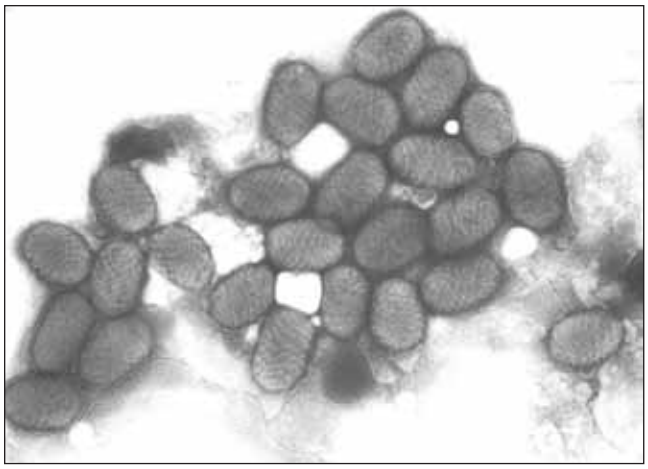

Figure 2) *Electron micrograph photograph of parapox virus recovered in the cell culture of the lesion aspirate. Reprinted with permission from Keith West DVM PhD and Lori Hassard, Prairie Diagnostics, Western College of Veterinary Medicine, University of Saskatchewan, Saskatoon, Saskatchewan*

DIAGNOSIS

The patient was diagnosed with Orf and probable secondary bacterial infection. Aspiration and scrapings of the lesions yielded cytopathic effect in the cell culture, while electron microscopy confirmed the presence of a virus consistent with Orf (Figure 2). An aspirate of the lesion demonstrated no pus cells and no organisms on Gram stain, but yielded an anaerobic Gram-positive coccus and a single colony of *Staphylococcus aureus* on culture. The patient's systemic symptoms (including fever, chills and profound fatigue) and striking local edema – neither of which are common in Orf – suggested a bacterial superinfection. The rapid response to meropenem also supported the clinical suspicion of a bacterial infection.

DISCUSSION

Orf, also known as contagious pustular dermatitis or contagious ecthyma, is an uncommon infection in humans (1,2). It is caused by a DNA parapox virus and spread by direct contact with sheep, goats or, rarely, by fomite transfer from infected animals (1-5). In sheep and goats, Orf presents as a pustular eruption of the mouth and mucous membranes (3-6).

The diagnosis of Orf in humans is usually clinical and, therefore, physicians must be aware of the natural progression of the lesions to avoid misdiagnosis or harmful intervention. The incubation period varies from three days to four weeks (3,6). Six stages of Orf infection have been described by Leavell et al (1). The maculopapular stage is characterized by an erythematous macule or papule. As the lesion progresses to the target stage, it develops a red centre and a middle white ring with an outer red halo. The active stage is an erythematous, weeping nodule. In the regenerative stage, the lesion dries and develops superficial black spots. The papillomatous stage is characterized by surface irregularities with a warty appearance. During the final regressive stage, the lesion develops a dry crust and resolves without scarring (1,3).

Orf lesions are typically painless. Systemic effects, including lymphangitis, lymphadenitis and fever, are uncommon (1,3,4,6). Lesions are most often solitary, and occur on the hands of people who have been in contact with sheep or goats (1-7). Facial involvement is considerably less common (1,4,8), and ocular involvement is very rare (9). Bacterial superinfection is also considered to be an uncommon complication. Only one case series reported isolation of typical bacterial pathogens from Orf lesions (10). These pathogens were isolated in only nine of 119 cases (10). There are no reports in the literature of Orf itself causing extensive local edematous reactions in humans.

Orf is typically diagnosed on clinical grounds in patients with compatible lesions and a history of sheep or goat exposure (1,4). When in doubt, confirmation of the diagnosis can be achieved by viral culture and electron microscopy of material aspirated from lesions. Under electron microscopy, the virions appear brick or ovoid shaped, measuring 200 nm to 300 nm × 150 nm to 250 nm (3). Serological tests are available but are primarily used in epidemiological studies (1,4).

Orf is not a reportable disease and, therefore, the true incidence in Canada is unknown. Orf should be considered in the differential diagnoses of focal skin lesions in individuals with direct or indirect contact with sheep or goats. Except for the infrequent complication of secondary infection, no specific interventions are necessary. Because Orf lesions resolve without scarring (over four to six weeks), biopsy should generally be avoided. In the present case, we confirmed the diagnosis by viral culture of a lesion aspirate and reassured the patient that, despite the dramatic appearance of the lesions, scarring was unlikely.

REFERENCES

1. Leavell UW Jr, McNamara MJ, Muelling R, Talbert WM, Rucker RC, Dalton AJ. Orf. Report of 19 human cases with clinical and pathological observations. JAMA 1968;203:657-64.
2. Chahidi N, de Fontaine S, Lacotte B. Human orf. Br J Plast Surg 1993;46;532-4.
3. Mendez B, Burnett J. Orf. Cutis 1989;44;286-7.
4. Bodnar MG, Miller OF 3rd, Tyler WB. Facial orf. J Am Acad Dermatol 1999;40;815-7.
5. Hoxtell E, Gentry WC Jr, Zelickson AS. Human orf with electron microscopic identification of the virus. Cutis 1975;16;899-904.
6. Gill MJ, Arlette J, Buchan KA, Barber K. Human orf. A diagnostic consideration? Arch Dermatol 1990;126;356-8.
7. Wilkinson JD. Orf: A family with unusual complications. Br J Dermatol 1977;97:477-50.
8. Maki A Jr, Hinsberg A, Percheson P, Marshall DG. Orf: Contagious pustular dermatitis. CMAJ 1988;139;971-2.
9. Freeman G, Bron AJ, Juel-Jensen B. Ocular infection with orf virus. Am J Ophthalmol 1984;97;601-4.
10. Johannessen JV, Krogh HK, Solberg I, Dalen A, van Wijngaarden H, Johansen B. Human Orf. J Cutan Pathol 1975;2:265-83.