

# Video-assisted thoracoscopic lung biopsy as a possible cause of acute interstitial pneumonia in a patient with nonspecific interstitial pneumonia

D Jeffrey Moore MD FRCPC<sup>1</sup>, Colm P McParland MB FRCPC<sup>2</sup>, Martin J Bullock MD FRCPC<sup>3</sup>, Yannick Cartier MD FRCPC<sup>4</sup>, Paul Hernandez MDCM FRCPC<sup>2</sup>

DJ Moore, CP McParland, MJ Bullock, Y Cartier, P Hernandez. Video-assisted thoracoscopic lung biopsy as a possible cause of acute interstitial pneumonia in a patient with nonspecific interstitial pneumonia. *Can Respir J* 2004;11(6):437-440.

The present case report describes a 44-year-old woman who presented with dyspnea due to diffuse interstitial lung disease. High-resolution computed tomography showed features of usual interstitial pneumonia, but the lung biopsy obtained by video-assisted thoracoscopy was consistent with a histological pattern of nonspecific interstitial pneumonia. Following the procedure, the patient developed progressive respiratory distress and died on postoperative day 13 with a clinical picture of acute interstitial pneumonia. The autopsy showed evidence of diffuse alveolar damage superimposed on the background pattern of nonspecific interstitial pneumonia. The present case report supports the notion that patients with a variety of subtypes of idiopathic interstitial pneumonias may be at risk of exacerbation of their underlying disease following thoracic procedures, including video-assisted thoracoscopic lung biopsy.

**Key Words:** *Interstitial lung disease; Lung biopsy; Pulmonary fibrosis*

In the evaluation of a patient with interstitial lung disease, the clinician uses a combination of history, physical examination and laboratory investigations to make a clinical-radiological-pathological diagnosis. High-resolution computed tomography (HRCT) is increasingly being used to support the clinical diagnosis; however, without histological confirmation, the diagnosis remains presumptive. Lung biopsy can be of assistance in determining diagnosis, prognosis and treatment; however, all biopsy procedures are invasive and the clinician must weigh the risks and benefits. We present the case of a 44-year-old woman with nonspecific interstitial pneumonia (NSIP) who deteriorated rapidly following video-assisted thoracoscopic surgery (VATS) lung biopsy, and was subsequently found at autopsy to have developed acute interstitial pneumonia (AIP).

## CASE PRESENTATION

A 44-year-old woman was referred to the respirology clinic at the Queen Elizabeth II Health Sciences Centre (Halifax, Nova Scotia) for assessment of an abnormal chest radiograph. She

## La biopsie pulmonaire thoracoscopique assistée par vidéo comme cause possible de pneumonie interstitielle aiguë chez un patient atteint d'une pneumonie interstitielle non spécifique

Le présent rapport de cas décrit une femme de 44 ans atteinte de dyspnée secondaire à une maladie pulmonaire interstitielle diffuse. La tomographie à haute résolution présentait les caractéristiques d'une pneumonie interstitielle, mais la biopsie du poumon obtenue par thoracoscopie assistée par vidéo s'harmonisait avec un profil histologique de pneumonie interstitielle non spécifique. Après l'intervention, la patiente a développé une détresse respiratoire progressive et est morte le treizième jour suivant, avec des signes cliniques de pneumonie interstitielle aiguë. L'autopsie a révélé la présence de lésions alvéolaires diffuses superposées au profil de fond de pneumonie interstitielle non spécifique. Le présent rapport de cas appuie la notion selon laquelle les patients atteints d'une variété de sous-types de pneumonies interstitielles idiopathiques peuvent être vulnérables à une exacerbation de leur maladie sous-jacente après une intervention thoracique, y compris une biopsie pulmonaire thoracoscopique assistée par vidéo.

complained of a five-year history of nonproductive cough. Dyspnea had become a progressive feature over the previous six months. Exercise tolerance at the time of assessment was limited to a 25 min slow walk on a flat stretch. Cold air, exercise and lower respiratory tract infections exacerbated her symptoms. She had no history of hemoptysis, wheeze or chest pain.

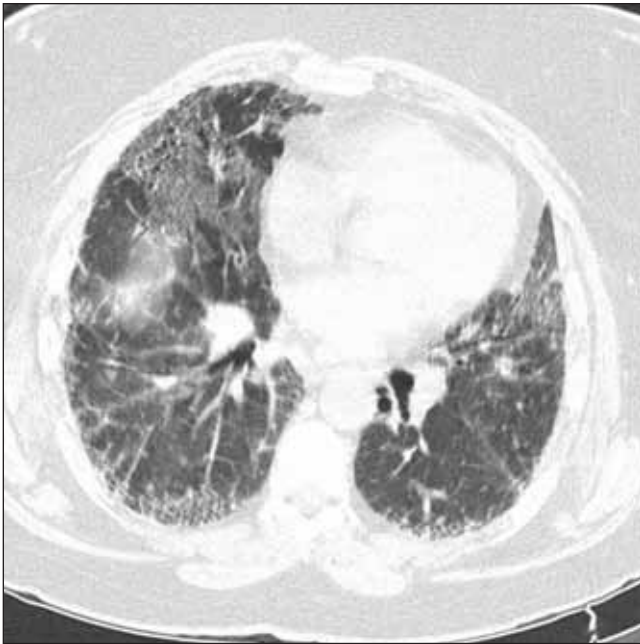The patient's past medical history was notable for hypertension, dyslipidemia and infertility. Medications included metoprolol tartrate, losartan potassium and calcium supplements. The patient had a 30 pack-year smoking history, but had quit four months previously. She worked as a grocery store clerk and had no occupational lung exposures. She had not traveled or visited a farm recently and had no pets. The patient's mother had rheumatoid arthritis and diabetes. Her father had emphysema and early onset ischemic heart disease.

On physical examination, she appeared well and not in distress. Vital signs revealed a pulse of 76 beats/min, blood pressure of 142/90 mmHg, respiratory rate of 20 breaths/min and O<sub>2</sub> saturation of 93% by pulse oximetry on room air at rest. She

---

<sup>1</sup>General Medicine Division, Department of Medicine; <sup>2</sup>Respirology Division, Department of Medicine; <sup>3</sup>Department of Pathology; <sup>4</sup>Department of Radiology, Queen Elizabeth II Health Sciences Centre, Dalhousie University, Halifax, Nova Scotia

Correspondence and reprints: Dr Paul Hernandez, Division of Respirology, Room 4456, Halifax Infirmary, Queen Elizabeth II Health Sciences Centre, 1796 Summer Street, Halifax, Nova Scotia B3H 3A7. Telephone 902-473-3698, fax 902-473-6202, e-mail paul.hernandez@cdha.nshealth.ca



**Figure 1)** High-resolution computed tomography scan of the patient's chest showing a coarse reticular pattern with honeycombing and ground glass opacification, which is consistent with usual interstitial pneumonia

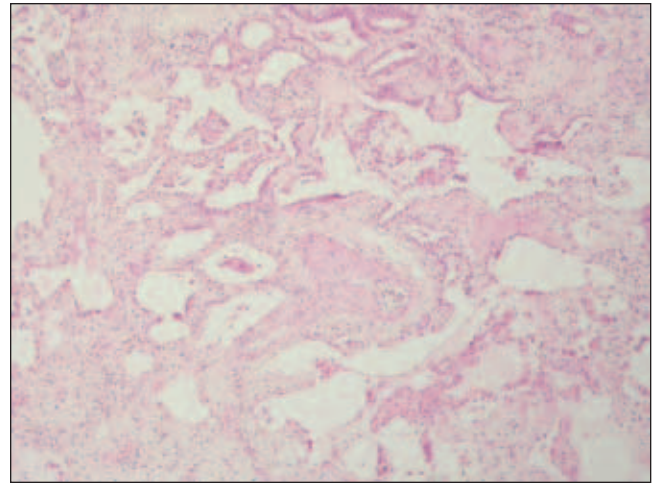
had advanced clubbing of her fingers and toes. Chest expansion was diminished. Chest auscultation revealed fine inspiratory crackles posteriorly at the bases. Jugular venous pressure was normal. The remainder of the physical examination was unremarkable.

Initial laboratory investigations showed a white blood cell count of  $12.1 \times 10^9/L$  (72% neutrophils), hemoglobin at 150 g/L, and platelets at  $385 \times 10^9/L$ . Electrolytes and creatinine were normal. C-reactive peptide was 10.3 mg/L and antinuclear antibody titre was 1:200 with a speckled pattern. A serological screen for connective tissue diseases was otherwise negative.

Pulmonary function tests showed a moderately reduced forced expiratory volume in 1 s of 1.35 L (56% of predicted), a forced vital capacity of 1.50 L (55% of predicted) and a total lung capacity of 2.25 L (54% of predicted). Diffusion capacity demonstrated severely impaired gas exchange (8.1 mL/mmHg/min, 38% of predicted).

The chest radiograph showed marked bilateral volume loss and a diffuse reticular nodular pattern that was worse in the bases than the apices. No pleural or mediastinal abnormalities were evident. An HRCT of the chest demonstrated decreased lung volumes and a coarse reticular pattern with honeycombing, predominately in a subpleural, mid and lower lung zone distribution. Ground glass opacification was present anteriorly in both lungs; areas of bronchiectasis and bronchiolectasis were noted. No pleural or mediastinal abnormalities were identified. The HRCT was interpreted as being most compatible with usual interstitial pneumonia (UIP) (Figure 1).

A provisional clinical-radiographical diagnosis of idiopathic pulmonary fibrosis (IPF) was made. However, given her age (44 years), the patient's clinical presentation was felt to be somewhat atypical for IPF. A referral was made to thoracic surgery for lung biopsy. The patient remained clinically stable on no specific therapy for IPF as an outpatient until surgery was performed two months following the initial respiratory clinic assessment.

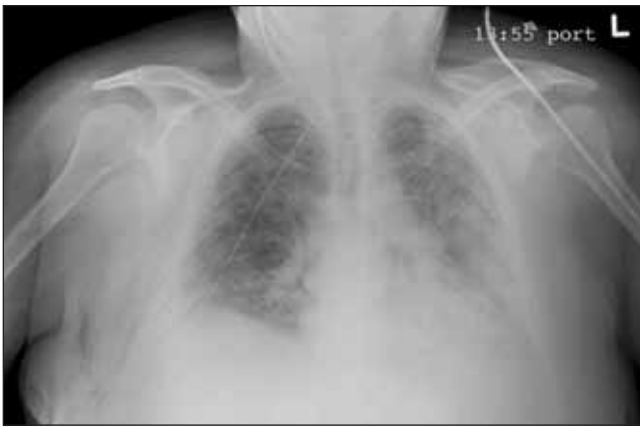

**Figure 2)** Pathology (hematoxylin and eosin stain, original magnification 100 $\times$ ) from the video-assisted thoracoscopic lung biopsy showing thickening and fibrosis of alveolar walls with patchy chronic interstitial inflammation and a small muscular pulmonary artery with a thick wall, which is consistent with nonspecific interstitial pneumonia

A VATS right lung biopsy was performed for diagnostic purposes. The patient was premedicated with midazolam. Propofol and sufentanil citrate were given for induction and maintenance of general anesthesia. Paralysis was achieved with a combination of succinylcholine chloride, rocuronium bromide and gallamine. Following preoxygenation, the patient was intubated with a 7.5 endotracheal tube and then switched to a #35 left double-lumen tube for one-lung anesthesia. The patient was placed in the left decubitus position, draped and prepared with the appropriate monitoring lines. One port was for camera insertion (seventh intercostal space) and two additional working ports (anteriorly and posteriorly in the sixth intercostal space) were placed. Wedge excision from the right lower lobe was taken using multiple applications of the stapler. A single chest tube was placed, the lung re-expanded and incisions closed. Total anesthesia and operative time were 80 min and 20 min, respectively. While in the operating room, the patient remained hemodynamically stable and had very good oxyhemoglobin saturation (92% to 100%). The patient was awakened, extubated and placed on supplemental  $O_2$  before transfer to the postanesthesia care unit.

Examination by the pathologist of the VATS right lower lobe biopsy specimen showed extensive interstitial collagenous fibrosis and thickened alveolar septa. There was mild chronic inflammation in the interstitium, occasional collections of macrophages in the alveolar spaces and focal type 2 pneumocyte hyperplasia. Rare fibroblastic foci were present. No granulomas, active vasculitis or hyaline membranes were present. The changes were temporally uniform, most consistent with an advanced stage of NSIP, fibrotic subtype (Figure 2). Cultures from the lung biopsy specimen were negative.

On postoperative day 1, the patient developed an unexplained fever and a nonproductive cough. A portable chest radiograph showed extensive bilateral air space opacification, compatible with pulmonary edema (Figure 3). She was diuresed for possible volume overload, which resulted in some improvement. Blood, sputum and urine cultures were obtained. The patient was started on ceftriaxone sodium for possible nosocomial pneumonia.



**Figure 3)** Anteroposterior chest radiograph, following video-assisted thoracoscopic lung biopsy of the right lower lobe, showing extensive bilateral air space opacification

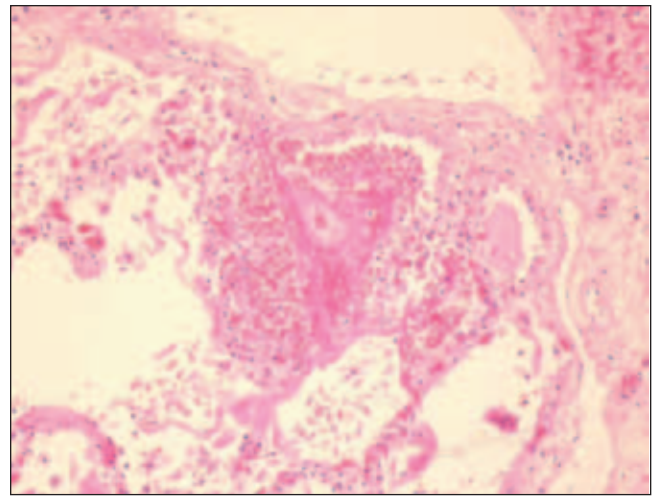
The patient continued to have intermittent fevers and her white blood cell count increased to  $18 \times 10^9/L$ . All cultures were negative. On postoperative day 3, her  $O_2$  saturation decreased further, requiring the initiation of high-fraction face mask  $O_2$ . Exacerbation of NSIP was suspected and she was started on intravenous methylprednisolone but failed to improve. Her respiratory status continued to decline and on postoperative day 13, she required reintubation and transfer to the intensive care unit. Despite sedation, paralysis and attempts at various mechanical ventilatory modes, it was not possible to provide her with adequate oxygenation or ventilation. She died later that same day.

On autopsy, lung sections showed severe interstitial fibrosis, which was worse in the lower lobes, with focal honeycombing noted in the left lower lobe. Superimposed on these features was a moderate degree of interstitial chronic inflammation and heavy accumulation of intra-alveolar macrophages. Focal hyaline membranes were identified, as well as extensive type 2 pneumocyte hyperplasia and squamous metaplasia. The type 2 pneumocytes demonstrated marked cytological atypia in some areas. In addition, there were areas of organizing fibrosis, predominantly within the airspaces. The features suggested an acute-on-chronic process, consistent with NSIP with superimposed diffuse alveolar damage (DAD) (Figure 4). The autopsy findings were otherwise unremarkable.

## DISCUSSION

Classification of the idiopathic interstitial pneumonias (IIP) has long been an area of dispute and confusion. This has stemmed, in part, from uncertainty between the clinical presentation of these entities and their histopathological correlates. The American Thoracic Society and the European Respiratory Society have recently published a joint consensus statement in an attempt to clarify this terminology (1) (Table 1).

Our patient presented with a clinical presentation and radiological pattern (on HRCT) suggestive of IPF, albeit with some minor atypical features. On pathology, the hallmark of UIP is the presence of fibroblastic foci and both temporal and geographic heterogeneity, ie, areas of normal lung, honeycombing, interstitial inflammation and fibrosis may all be seen in close proximity. However, this patient's VATS lung biopsy pathology demonstrated only rare fibroblastic foci and a temporally uniform pattern of interstitial thickening more consistent with the histopathological pattern of NSIP.



**Figure 4)** Pathology (hematoxylin and eosin stain, original magnification 200 $\times$ ) from autopsy of the lung showing thickened alveolar septa with superimposed intra-alveolar hemorrhage, hyaline membranes and marked type 2 pneumocyte hyperplasia, consistent with nonspecific interstitial pneumonia with superimposed diffuse alveolar damage

**TABLE 1**  
Joint American Thoracic Society/European Respiratory Society proposed classification of idiopathic interstitial pneumonias

Combined CRP diagnosis	Histological pattern on biopsy
Idiopathic pulmonary fibrosis (cryptogenic fibrosing alveolitis)	Usual interstitial pneumonia
Nonspecific interstitial pneumonia	Nonspecific interstitial pneumonia (Cellular and fibrosing patterns)
Organizing pneumonia (idiopathic bronchiolitis obliterans organizing pneumonia)	Cryptogenic organizing pneumonia
Acute interstitial pneumonia	Diffuse alveolar damage
Respiratory bronchiolitis interstitial lung disease	Respiratory bronchiolitis
Desquamative interstitial pneumonia	Desquamative interstitial pneumonia
Lymphoid interstitial pneumonia	Lymphoid interstitial pneumonia

CRP Clinical, radiological and pathological. Adapted from reference 1

The possibility that our patient suffered from UIP or a mixture of UIP and NSIP rather than NSIP alone must be considered. This may reflect a sampling error such that the VATS lung biopsy specimen was not entirely representative of the actual lung disease. Flaherty et al (2) have described the impact of taking samples from multiple lobes at the time of surgical lung biopsy. They reported that more than one histological pattern was found between lobes in 26% of 168 of their patients with IIP. Survival was best for patients with NSIP in all lobes sampled; patients with UIP in all lobes had the worst survival, while patients with histological variability (NSIP and UIP, termed discordant UIP) had similarly poor survival as that observed in the patients with UIP in all lobes.

At autopsy, a histological pattern of DAD was observed. DAD is seen in both the acute respiratory distress syndrome and in AIP. It is not possible to distinguish between these two syndromes by pathology alone – clinical correlation is

necessary (3). In patients without a clear toxic, infectious or other insult, a diagnosis of AIP is assumed. In this case, the patient underwent anesthesia and a VATS procedure, but no insults typically associated with acute respiratory distress syndrome were identified. Therefore, it was concluded that the patient had died of AIP on a background of advanced fibrotic NSIP.

We propose that the VATS procedure was responsible for the exacerbation of this patient's underlying, previously stable NSIP. A minimally invasive surgical procedure, VATS has been reported to be a safe and effective alternative to open lung biopsy in establishing the diagnosis of IIP. In a retrospective study (4) comparing 22 consecutive patients who underwent VATS with 21 consecutive patients who underwent open lung biopsy for diagnosis of IIP, VATS was shown to give equivalent specimen volume and diagnostic accuracy without adding operative time or increasing the complication rate. In addition, there was a reduction in the time necessary for pleural drainage and hospital length of stay. The literature contains several case reports and case series describing exacerbation of interstitial lung disease following various thoracic procedures and interventions (5-10). Often, the specific histopathology of the underlying disease was not available in these reports. No other cases were found in the literature where a patient with NSIP developed AIP following a VATS procedure.

Utz et al (5) noted a particularly high short-term mortality in a group of patients with UIP diagnosed by surgical lung biopsy. This was a retrospective analysis of reports by pathologists from all patients who had undergone open thoracotomy or VATS lung biopsy at the Mayo Clinic from 1986 to 1995. Sixty patients with a pathological diagnosis of UIP were identified, 14 of whom had an associated connective tissue disease; the clinicopathological diagnosis was UIP/IPF in the remaining 46 patients. Five patients had evidence of DAD, four of whom were in the UIP/IPF group. Ten of the 60 patients died within 30 days of their biopsy, three biopsies were by VATS and seven were by open thoracotomy. All of the deaths occurred in patients from the UIP/IPF group (10 of 46, 21.7%), including two of the patients with DAD. The authors concluded that "patients with UIP of the idiopathic type, who present with atypical features, may be at higher risk for death following surgical biopsy than patients presenting with more typical features or patients with other interstitial illnesses" (5).

A nationwide Japanese questionnaire-based survey (6) of physicians providing care to 410 patients who had undergone lung biopsy for diffuse lung diseases has been published. Ninety-four per cent of these were performed by VATS. Acute exacerbation of underlying lung disease was noted in nine patients (2.2%). However, the underlying and subsequent pathology was not reported.

Bronchoalveolar lavage (BAL) has also been reported to potentially cause exacerbation of interstitial lung disease. Two Japanese reports (7,8) have been published, each describing two cases of acute exacerbation of IIP following BAL. A larger case series (9) compared the outcome after BAL was performed in 124 patients with IPF with 282 patients with other pulmonary diseases (sarcoidosis, asthma, collagen diseases and other interstitial lung diseases). Three of the patients with IPF had an acute exacerbation of their lung disease immediately following BAL and eventually died despite intensive care unit management.

Autopsy showed interstitial pneumonia and fibrosis. None of the second group of patients was found to have an exacerbation following BAL.

Exacerbation or de novo onset of interstitial pneumonia has been described following lobectomy or pneumonectomy for primary lung cancer. In a case series (10) of 12 patients with prior documentation of IIP undergoing lung resection for cancer, four developed exacerbation of underlying IIP and died. Autopsy findings were not available.

These studies suggest that patients with underlying idiopathic interstitial lung disease are at increased risk of exacerbation following VATS lung biopsy and other intrathoracic procedures. These patients already have an ongoing inflammatory process in their lungs. Although the mechanism is unclear, any one of several factors could precipitate an exacerbation. The inhaled anesthetic agent or high-fraction of inhaled O<sub>2</sub> may act as a chemical stimulus. Positive pressure ventilation and the partial collapse of the lung being biopsied may induce mechanical stress. The local trauma of lung manipulation, surgical resection and cautery may instigate an inflammatory reaction. Subsequent chest tube and pleural drainage may also play a role.

## CONCLUSIONS

It is now becoming recognized that VATS and other invasive thoracic procedures may exacerbate underlying IIP. Nevertheless, these procedures are often pursued in patients who are unwell or deteriorating; it remains uncertain if the observed association of lung biopsy and exacerbation of underlying lung disease is truly causative. The present case described a clinically stable young woman with NSIP diagnosed on VATS lung biopsy who rapidly deteriorated and died, with a clinical picture consistent with AIP and features of DAD found at autopsy. Physicians should be aware of the rare possibility of exacerbating the underlying lung process when considering lung biopsy in the evaluation of IIP.

## REFERENCES

1. American Thoracic Society; European Respiratory Society. American Thoracic Society/European Respiratory Society Multidisciplinary Consensus Classification of the Idiopathic Interstitial Pneumonias. *Am J Respir Crit Care Med* 2002;165:277-304. Erratum in: 2002;166:426.
2. Flaherty KR, Travis WD, Colby TV, et al. Histopathologic variability in usual and nonspecific interstitial pneumonias. *Am J Respir Crit Care Med* 2001;164:1722-7.
3. Bours D, Nicholson AC, Polychronopoulos V, du Bois RM. Acute interstitial pneumonia. *Eur Respir J* 2000;15:412-8.
4. Bensard DD, McIntyre RC Jr, Waring BJ, Simon JS. Comparison of video thoroscopic lung biopsy to open lung biopsy in the diagnosis of interstitial lung disease. *Chest* 1993;103:765-70.
5. Utz JP, Ryu JH, Douglas WW, et al. High short-term mortality following lung biopsy for usual interstitial pneumonia. *Eur Respir J* 2001;17:175-9.
6. Kanazawa M, Kawabata Y, Takayanagi N, et al. [A questionnaire survey of surgical lung biopsy in patients with diffuse lung diseases]. *Nihon Kokyuki Gakkai Zasshi* 2000;38:770-7.
7. Suga T, Sugiyama Y, Ohno S, Kitamura S. [Two cases of IIP which developed acute exacerbation after bronchoalveolar lavage]. *Nihon Kyobu Shikkan Gakkai Zasshi* 1994;32:174-8.
8. Yoshitomi A, Sato A, Tamura R, et al. [Acute exacerbation following bronchoalveolar lavage in idiopathic interstitial pneumonia]. *Nihon Kyobu Shikkan Gakkai Zasshi* 1993;31:1606-11.
9. Hiwatari N, Shimura S, Takishima T, Shirato K. Bronchoalveolar lavage as a possible cause of acute exacerbation in idiopathic pulmonary fibrosis patients. *Tohoku J Exp Med* 1994;174:379-86.
10. Nakagawa K, Yasumitsu T, Kotake Y, et al. [Lung resection for lung carcinoma with idiopathic interstitial pneumonia]. *Nippon Kyobu Geka Gakkai Zasshi* 1994;42:1933-9.



**Hindawi**  
Submit your manuscripts at  
<http://www.hindawi.com>

