Pediatric sand aspiration managed using bronchoscopy and extracorporeal membrane oxygenation

Khaled Baqais MD[1], Meagan Mahoney MD[2], Kathleen Tobler MD[2], Anita Hui MD[3], Mary Noseworthy MD[1]

K Baqais, M Mahoney, K Tobler, A Hui, M Noseworthy. Pediatric sand aspiration managed using bronchoscopy and extracorporeal membrane oxygenation. Can Respir J 2015;22(5):261-262.

Sand aspiration is a rare but potentially fatal occurrence to consider in near-drownings, accidental burials or cave-ins. Optimal management is not well defined.

Key Words: *Bronchoscopy; ECMO; Pediatric; Sand aspiration*

L'aspiration de sable chez un patient d'âge pédiatrique traitée par bronchoscopie et oxygénation extracorporelle

L'aspiration de sable est une occurrence rare au potentiel fatal qu'il faut envisager en cas de quasi-noyade, d'inhumation accidentelle ou d'effondrement. Sa prise en charge optimale est mal définie.

Learning objectives

- To recognize that clinical presentation can vary from moderate respiratory distress to complete airway obstruction leading to cerebral asphyxia.
- To understand that due to rarity, clear diagnostic and treatment recommendations have not been established.

CanMEDS competency: Medical Expert, Collaboration.

Pretest

- What is the mechanism of airway obstruction with sand aspiration?

Visiting the beach is a popular tourist activity worldwide. Unfortunately, the beach environment is abundant with hazards and potential danger to the unsuspecting tourist. While the traditional focus of beach safety has been oriented toward water safety, there is growing concern about the risks posed by the sand environment on beaches. Sand-related incidents resulting from the collapse of sand castles, sand tunnels and sand holes dug on beaches have been reported in recent years (1).

Sand in the tracheobronchial airways adheres to the mucosa and can cause tracheal and bronchial obstruction, which can be life-threatening, even with intensive management (2).

The aim of the present article is to report the successful use of extracorporeal membrane oxygenation (ECMO) for respiratory support, which enabled more efficient removal of sand particles using bronchoscopy and lavage.

CASE PRESENTATION

An 11-year-old previously healthy boy was playing with his friends on a beach in British Columbia. He was buried vertically in sand up to his neck. The sand above his face collapsed on him while he was buried. He was unable to protect himself and his airway. His friends immediately went to get help. Family members pulled him out of the sand immediately and provided rescue breathing because he was not breathing and had no pulse. After he was breathing spontaneously, his family rinsed his mouth and nose with fresh lake water.

Emergency medical services reported a Glasgow Coma scale score of 6 of 10 and placed an oropharyngeal airway. Bilaterally, breath sounds were diminished, with wheeze at the base.

At arrival to the local hospital, the patient was intubated with an endotracheal tube (ETT) and ventilated by bagging; at that time, oxygen saturation (SpO_2) was 98%. Salbutamol inhaler was given without improvement. Capillary blood gas showed acute respiratory acidosis with a partial pressure of carbon dioxide ($PaCO_2$) of 84 mmHg.

During transfer to the authors' tertiary pediatric institution by emergency medical services, ventilation shifted to manual bagging because mean airway pressure fluctuated (peak 70 cmH_2O, nadir 5 cmH_2O) in flight via helicopter.

On presentation, he was hypothermic (35.4°C) and mottled, with venous blood gas values of pH 6.99, $PaCO_2$ 120 mmHg and lactate 3 mmol/L. A chest x-ray (Figure 1) confirmed ETT placement with hyperinflation and sand bronchogram. The ETT was changed after confirmation of a sand plug at the end of the tube.

He was placed on venovenal ECMO at the rate of 75 mL/kg/min because SpO_2 was between 60% and 70%, PaO_2 50 mmHg and $PaCO_2$ 58 mmHg in arterial blood gas. ECMO was associated with immediate improvement in SpO_2 to 90%. Arterial blood gas values at this time were pH 7.24, $PaCO_2$ 48 mmHg, PO_2 117 mmHg and HCO_3 20 mmol/L.

After cardiopulmonary status stabilization, rigid bronchoscopy was unsuccessful. Suspension laryngoscopy through the ETT demonstrated significant airway swelling. Flexible bronchoscopy was then performed, which sufficiently cleaned out the ETT for it to be removed and suspension laryngoscopy was carefully repeated sequentially in the intensive care unit with bronchoscopy with normal saline lavage. This management continued for hours until the mainstem bronchi appeared to be clear.

Dexamethasone and epinephrine were instilled for airway edema. Significant sand debris as well as mucosal inflammation was present (Figure 2). Severe acute hypertension (in the area of 200/100 mmHg) developed with ST segment changes and decreased function on real-time echocardiography, which was controlled with multiple boluses of esmolol infusion (150 µg/kg/min) for 10 min.

An intravenous piperacillin/tazobactam antibiotic was given for seven days with no growth in blood, tracheal lavage and urine cultures. ECMO was continued for three days, followed by successful extubation on day 5. He continued to cough up sand and blood intermittently for seven days after extubation.

The patient was lost to follow-up until 18 months after event, when he was evaluated for asthma due to shortness of breath on exertion; at this time, he had normal neurological, cardiac and respiratory examinations. A pulmonary function test showed mild but reversible obstructive spirometry, with forced expiratory volume in 1 s (FEV_1) 88% of predicted and expiratory ratio (ie, FEV_1/forced vital capacity) of 68%. Moderate bronchial hyperreactivity was demontrated; FEV_1 changed by 13% after bronchodilator, but there was absence of restriction and no diffusion abnormalities.

[1]*Pediatric Respiratory Division;* [2]*Division of Critical Care, Department of Pediatrics;* [3]*Otolaryngology – Head and Surgery, Alberta Children's Hospital, Calgary, Alberta*

Correspondence and reprints: Dr Khaled Baqais, Alberta Children's Hospital, 2888 Shaganappi Trail Northwest, Calgary, Alberta T3B 6A8. Telephone 403-955-7974, e-mail baqais1@hotmail.com

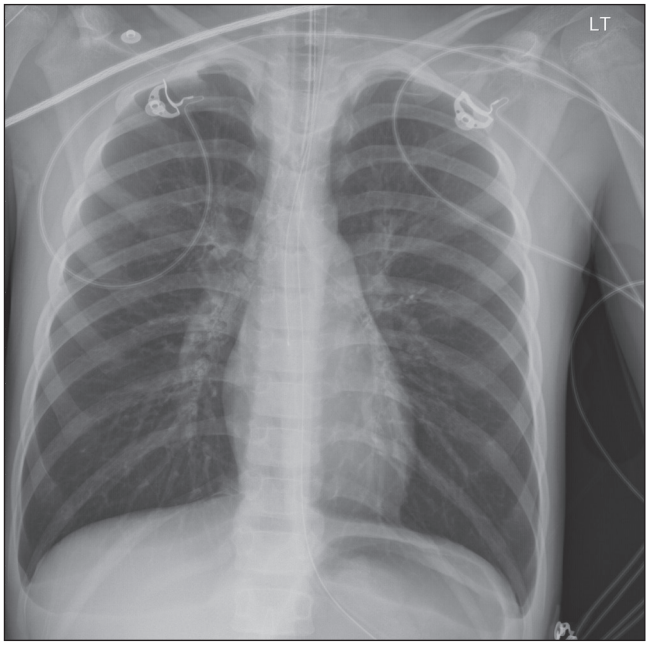

Figure 1) *Chest x-ray revealing bilateral hyperinflation and sand bronchogram*

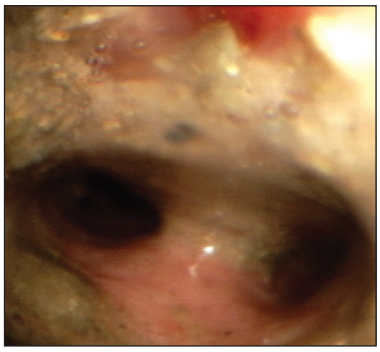

Figure 2) *Bronchoscopy showing sand reaching beyond the carina*

DISCUSSION

Aspiration is a life-threatening event that should be considered in all cave-ins and near-drowning events. A 60% chance of mud, sand or aquatic vegetation aspiration is reported during drowning or near drowning (3).

In 1962, Efron and Beierle (3) described a drowning victim whose mouth and pharynx were full of sand and who had difficulty ventilating. In 2006, approximately 1100 children (<20 years of age) in the United States died from drowning (4,5) .

The pathogenesis of injury with aspiration is laryngospasm, mechanical obstruction or inflammation secondary to chemical irritation (3). Initial signs and symptoms vary depending on the extent of airway obstruction. If complete, anoxic death occurs rapidly; however, if obstruction is partial, dyspnea, rales, wheezing, cyanosis, stridor or cough ensue. Initial clues to significant aspiration include increased peak airway pressures during mechanical ventilation, and visible sand in the mouth and nasopharynx (3).

Chest x-ray findings are generally nonspecific, with fluffy, nodular, confluent perihilar opacities or air bronchograms, and radiodense material in the bronchi and sinuses as well as centrilobular nodules (6). Adult studies have reported sand bronchogram (radiodense material lining the central tracheobronchial tree) in two cases.

Pediatric computed tomography scans show diffuse, ill-defined ground-glass opacities, and bilateral perihilar bronchial thickening with opacification of the peripheral right lateral basal segment bronchus. In one pediatric report, nonbronchoscopic bronchoalveolar lavage (BAL) did not assist in diagnosis, whereas findings from visualization of the airways at bronchoscopy and bronchoscopic BAL provided the diagnosis. The role of bronchoscopy as a diagnostic and therapeutic modality is not clearly defined. Bronchoscopic findings in adults with sand aspiration include bronchial sand casts, sand plugs, scattered sand, mucosal inflammation and friability (7).

Therapeutically, different modalities have been attempted in management: bronchial toileting with bronchodilator (7); exogenous bovine surfactant (7); and bronchoscopy with BAL (6).

There are no clinical trials examining the role of antibiotics or steroids after particulate aspiration (3). Our patient developed severe hypertension after instillation of epinephrine, most likely rapidly absorbed through excoriated tissue.

The present case is the 11th reported pediatric case from the reviewed literature and differs from other cases due to success with ECMO (3,7-15). The use of ECMO enabled more effective removal of sand in the major airway by bronchoscope, with less patient compromise and improved stability. While on ECMO, the patient experienced severe acute hypertension after intratracheal epinephrine managed with multiple boluses of esmolol infusion.

Post-test

- What is the mechanism of airway obstruction with sand aspiration?

The mechanisms of injury with aspiration is laryngospasm, mechanical obstruction, or inflammation secondary to chemical irritation.

ACKNOWLEDGEMENTS: The authors thank Daniel Garros, Gonzalo Garcia Guerra, Hamdy El-Hakim and David Sigalet.

REFERENCES

1. Heggie TW. Sand hazards on tourist beaches. Travel Med Infect Dis 2013;11:123-5.
2. Metcalf KB, Michaels AJ, Edlich RF, Long WB. Extracorporeal membrane oxygenation can provide cardiopulmonary support during bronchoscopic clearance of airways after sand aspiration. J Emerg Med 2013;45:380-3.
3. Efron PA, Beierle EA. Pediatric sand aspiration: Case report and literature review. Pediatr Surg Int 2003;19:409-12.
4. Weiss J, American Academy of Pediatrics Committee on Injury, Violence, and Poison Prevention. Prevention of drowning. Pediatrics 2010;126:e253-62.
5. Peterson B. Morbidity of childhood near-drowning. Pediatrics 1977;59:364-70.
6. Dunagan DP, Cox JE, Chang MC, Haponik EF. Sand aspiration with near-drowning. Radiographic and bronchoscopic findings. Am J Respir Crit Care Med 1997;156:292-5.
7. Kapur N, Slater A, McEniery J, Greer ML, Masters IB, Chang AB. Therapeutic bronchoscopy in a child with sand aspiration and respiratory failure from near drowning – case report and literature review. Pediatr Pulmonol 2009;44:1043-7.
8. Van Dyke JJ, Lake KB. Survival after asphyxia secondary to gravel aspiration. Arch Intern Med 1976;136:471-3.
9. Bergeson PS, Hinchcliffe WA, Crawford RF, Sorenson MJ, Trump DS. Asphyxia secondary to massive dirt aspiration. J Pediatr 1978;92:506-7.
10. Wales J, Jackimczyk K, Rosen P. Aspiration following a cave-in. Ann Emerg Med 1983;12:99-101.
11. Bender EM, Moore EE, Kashuk JL, Hopeman AR. Conservative management of sand aspiration: Case report. Mil Med 1984;149:98-9.
12. Mellema JD, Bratton SL, Inglis A Jr, Morray JP. Use of cardiopulmonary bypass during bronchoscopy following sand aspiration. A case report. Chest 1995;108:1176-7.
13. Choy IO, Idowu O. Sand aspiration: A case report. J Pediatr Surg 1996;31:1448-50.
14. Glinjongol C, Kiatchaipipat S, Thepcharoenniran S. Severe sand aspiration: A case report with complete recovery. J Med Assoc Thai 2004;87:825-8.
15. Kettner M, Ramsthaler F, Horlebein B, Schmidt PH. Fatal outcome of a sand aspiration. Int J Legal Med 2008;122:499-502.