Disease Markers 29 (2010) 123–130
DOI 10.3233/DMA-2010-0734
IOS Press

Clinical manifestations of hyper IgE syndromes

Alexandra F. Freeman* and Steven M. Holland
Laboratory of Clinical Infectious Diseases, NIAID, NIH, Bethesda, MD, USA

Abstract. Over the last 4 years, three genetic etiologies of hyper IgE syndromes have been identified: STAT3, DOCK8, and Tyk2. All of these hyper IgE syndromes are characterized by eczema, sinopulmonary infections, and greatly elevated serum IgE. However, each has distinct clinical manifestations. Mutations in STAT3 cause autosomal dominant HIES (Job's syndrome), which is unique in its diversity of connective tissue, skeletal, and vascular abnormalities. DOCK8 deficiency is characterized by severe cutaneous viral infections such as warts, and a predisposition to malignancies at a young age. Only one individual has been identified with a hyper IgE phenotype associated with Tyk2 deficiency, which is characterized by nontuberculous mycobacterial infection. The identification of these genetic etiologies is leading to advances in understanding the pathogenesis of these syndromes with the goal of improving treatment.

1. Introduction

Until 2006, the Hyper IgE syndromes remained the last of the major primary immunodeficiencies for which no genetic etiologies were known. Then, in 2006, a homozygous deletion in Tyk2 was identified in a boy with elevated IgE, eczema, and infections from Japan [1]. This was followed in 2007 with the finding of dominant negative mutations in *STAT3* as the etiology of autosomal dominant Hyper IgE (Job's) syndrome [2, 3]. Subsequently, in 2009, homozygous and compound heterozygous mutations in *DOCK8* were identified in a subset of individuals diagnosed with autosomal recessive Hyper IgE syndrome [4,5]. Each of these genetic etiologies leads to distinct clinical features, and greater familiarity with these clinical presentations can direct immunologic and genetic studies, and assist with treatment and family counseling.

2. Autosomal dominant (AD) HIES

Mutations in *STAT3* have been found to be the cause of the majority, if not all, cases of AD-HIES (Job's syndrome). AD-HIES is a multi-system disorder with abnormalities of the immune system, skeleton, connective tissues, and vasculature [6–8]. The diagnosis is suggested when both immunologic and connective tissue/skeletal features are present. The pathogenesis of the majority of these varied features remains poorly understood.

2.1. Immunologic/infectious disease manifestations

In the great majority of cases, AD-HIES presents in the newborn period with a rash, which may even be present at birth [9,10]. This rash is typically pustular, and on biopsy may be consistent with eosinophilic pustulosis. This rash may resolve or persist, evolving into an eczematoid dermatitis that is typically driven by *Staphylococcus aureus* infection. Control of *S. aureus* skin colonization typically leads to great improvement in the rash. *S. aureus* skin abscesses occur, and may be "cold", lacking the usual warmth, redness, and pain; however, frank pus, often with increased number of eosinophils, is found on aspiration. *S.aureus* skin colonization control with either antiseptics (i.e. bleach baths) or maintenance antibiotics (such as trimethoprim-sulfamethoxasole), makes these abscesses very infrequent.

*Corresponding author: Alexandra Freeman, MD, NIH Building 10, Room 11N234 Bethesda, MD 20892, USA. Tel.: +1 301 594 9045; Fax: +1 301 496 0773; E-mail: freemaal@mail.nih.gov.

ISSN 0278-0240/10/$27.50

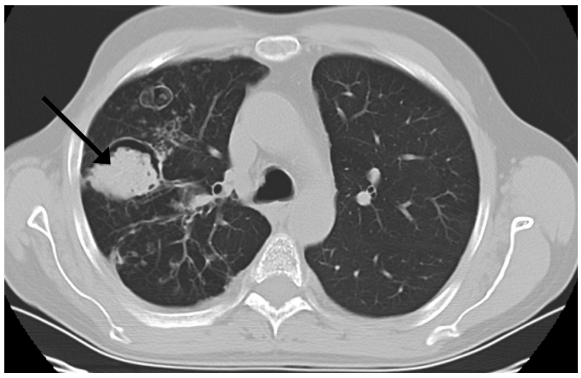

Fig. 1. Chest CT of a 48 year old with AD-HIES showing bronchiectasis, and a pneumatocoele with an Aspergilloma (arrow).

Fig. 2. Patient with AD-HIES and chronic fungal infection of the nail (arrow).

Recurrent bacterial sinus, ear, and lung infections are classic findings in AD-HIES. *S. aureus* is the most frequent etiology of the pneumonias, with *Streptococcus pneumoniae* and *Haemophilus* species occurring frequently as well [7]. Purulence is found in the airways, but similar to the boils, systemic signs of infection may be minimal, which may lead to late diagnosis of significant infections. Although these infections can usually be treated adequately with antimicrobials directed against the infection organism, the healing of the lung is abnormal, and resultant pneumatocoeles and bronchiectasis may occur (Fig. 1). The parenchymal abnormalities of the lung are a source of significant morbidity and mortality for these individuals as more difficult-to-treat microbes, including molds (*Aspergillus*, *Scedosporium* species), Gram-negative bacteria (typically *Pseudomonas aeruginosa*), and nontuberculous mycobacteria cause chronic infections (Fig. 1) [11–13]. Life threatening hemoptysis and disseminated infections may result from these chronic infections. Appropriate management of the pneumatocoeles is not well defined. Surgical resection should be undertaken with caution, as there appears to be a fairly high frequency of complications with prolonged and often complicated bronchopleural fistulae leading to contaminated pleural space infections.

As opposed to certain other primary immunodeficiencies associated with fungal pneumonias (e.g. chronic granulomatous disease), fungi only seem to cause infection in lungs in AD-HIES after parenchymal damage has occurred [13]. However, other opportunists may cause infection. *Pneumocystis jirovecii* pneumonia (PCP) may occur, typically during infancy, prior to pyogenic pneumonias [14,15]. In addition, disseminated dimorphic fungal infections occur occasionally, including *Histoplasma* and *Cryptococcus*, often with infection localized in the gastrointestinal tract [16–19]. Also, *Coccidioides* meningitis has been reported [20]. Mucocutaneous candidiasis occurs frequently and may require chronic suppressive antifungals (Fig. 2).

In general, viral infections are not especially severe, chronic or recurrent in AD-HIES, in contrast to *DOCK8* deficiency (Table 1). Individuals with AD-HIES do not have an increased incidence of warts or *Molluscum contagiosum*. However, there does appear to be a higher incidence of zoster, which tends to be limited to one or contiguous dermatomes (unpublished data).

Asthma and allergies are uncommon in AD-HIES, and anaphylaxis to foods is rare [21]. With the markedly elevated serum IgE, there may be IgE to specific antigens present; however, the clinical significance needs to be interpreted carefully. Some patients do have obstructive lung disease that responds to beta agonist therapy; however, this is much less common than in other diseases with high IgE such as atopy and *DOCK8* deficiency.

2.2. Non-immunologic manifestations

AD-HIES can be differentiated from other etiologies of Hyper IgE by its distinctive connective tissue, skeletal, and dental abnormalities (Table 1). By late childhood or adolescence, a typical facial appearance emerges characterized by asymmetry, deepset eyes, prominent forehead and chin, and a bulbous nose [6, 7,22]. The palate is high, and there are often prominent ridges of the oral mucosa on the palate and central depressions of the tongue [23]. These facial structural changes may result in the higher frequency of sinus and ear infections that are typically encountered. Primary teeth usually fail to exfoliate, which may impair secondary dentition emergence [24].

Table 1
Clinical features of hyper IgE syndromes

	STAT3 mutation HIES	DOCK8 deficiency
Newborn rash	+++	+
Eczema	++++	++++
Skin abscesses	+++	++
Pneumonias	++++	+++
Lung parenchyma changes (bronchiectasis, cysts)	+++	+
Food Allergies	+	+++
Asthma	+	+++
Mucocutaneous viral infections	+	++++
Mucocutaneous candidiasis	+++	++
Retained primary teeth	++++	+
Minimal trauma fractures	+++	+
Scoliosis	+++	
Characteristic facial appearance	+++	+
Malignancy	+	+++

Skeletal abnormalities include osteoporosis, minimal trauma fractures, scoliosis, degenerative spine disease, and craniosynostosis [6,7,25–27]. Although osteoporosis is common, it is not predictive of who will have fractures, and minimal trauma fractures may occur without osteoporosis. Scoliosis curvature may progress to significant degrees requiring therapeutic intervention including rod placement. Fractures and scoliosis that have required surgical correction have typically healed without incident. Significant spinal disease, most frequently observed in the cervical spine, often arises in the 4th and 5th decades of life, resulting in pain, neuropathy, and weakness (Fig. 3). Surgical stabilization has been successful in several patients. Varying degrees of craniosynostosis are common, but do not usually require surgical correction [25–27].

Hyperextensibility of joints is common, and as patients age, joint pain may become more pronounced. Physical therapy can help ameliorate these symptoms.

Vascular abnormalities include arterial tortuosity, dilation and aneurysm [28–31]. These findings have been reported predominantly in the coronary and cerebral arteries, the clinical significance of which remains unknown. With significant aneurysm, anticoagulation with aspirin or other medications should be considered; however, the possibility of hemoptysis in those with significant lung disease must be weighed against the possibility of clot complicating aneurysm. Interestingly, there has been a paucity of atherosclerosis associated with these lesions. Hypertension is increased compared to the general population, and often presents in the 3rd or 4th decades of life.

Intracranial manifestations include Chiari I malformations and focal hyperintensities on brain MRI [32] (Fig. 4). Both of these findings are typically asymptomatic, and surgery has not been required in the vast majority of Chiari malformations. Lacunar infarcts have occurred at relatively young ages in a few patients. Whether the focal hyperintensities and lacunar infarcts are related to vascular abnormalities similar to the coronary lesions remains to be determined.

Fig. 3. Cervical spine disease in a 55 year old with AD-HIES showing angular kyphosis and retrolisthesis.

Esophageal dysmotility is relatively common in adults [33]. Less frequent gastrointestinal features include colon diverticula, spontaneous perforations, and rectal prolapse, similar to what is present in other connective tissue disorders.

2.3. Malignancy

Malignancy is increased in HIES, with lymphomas predominating [34–36]. When diagnosed early, lymphomas have been treated with standard regimens and

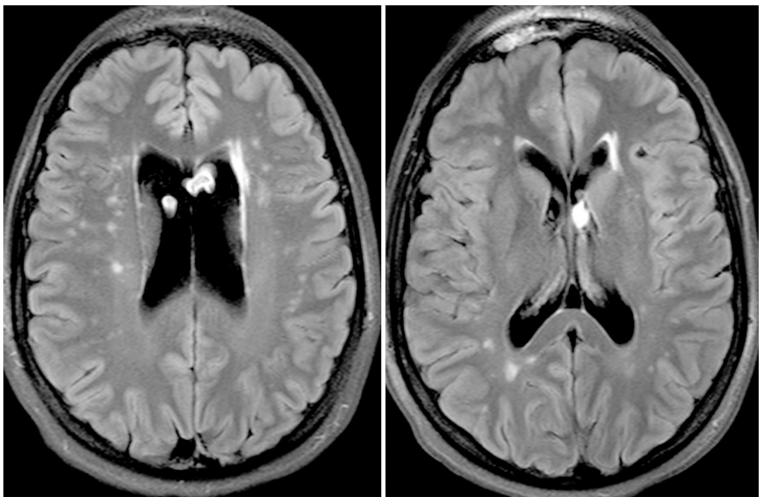

Fig. 4. Brain MRI of a 38 year old revealing multiple focal hyperintensities.

cures without significant morbidity. Other reported malignancies include leukemia and cancers of the vulva, liver, and lung.

2.4. Laboratory abnormalities

Individuals with AD-HIES typically have quite elevated serum IgEs in childhood, with levels usually above 2000 IU/uL. However, with age, these levels may decrease and even approach normal levels in the 4th or 5th decade of life [7]. There is not a clear correlation between disease severity and the serum level of IgE. Eosinophilia is common as well, but does not necessarily correlate with the serum IgE. Other immunoglobulins are frequently normal, although some individuals have low serum IgA, and a few slightly low serum IgG. Specific antibodies are variable. Total lymphocyte counts are usually normal, but on subset analysis, memory T and B cells are decreased [31,37,38]. Memory T cells that produce Il-17 (Th17 cells) are greatly diminished [39–42]. Neutropenia is present in a subset of patients.

2.5. Genetics

AD-HIES should be suspected in individuals with elevated serum IgE and both immunologic and non-immunologic features as described above. Prior to the identification of the involved gene, a scoring system was frequently used for diagnosis, and can still aid in this regard [43]. *STAT3* sequencing is then performed to confirm the diagnosis. STAT3 is a major signal transducer through which many cytokines signal leading to its involvement in such diverse pathways as immunity, wound healing, and cancer. Both pro-inflammatory cytokines, such as IL-6 and anti-inflammatory cytokines, such as IL-10, signal through STAT3 which may explain the dichotomy of AD-HIES of being a disease of too much inflammation as seen locally in the pneumonias with exuberant pus, and also too little inflammation with the relative lack of systemic signs of illness. Mutations are largely located in the SH2 domain, which mediates protein-protein interactions, and the DNA binding domain, which mediates protein-DNA interactions. The majority of reported mutations are missense, and others are small in-frame deletions, with several hotspot mutations. All reports have had protein expression, and the phenotype of the disease across the different domains appears to be relatively consistent [2, 3,42,44].

2.6. Treatment

Treatment of AD-HIES is largely supportive with prophylactic antibiotics directed against *S. aureus* and other infecting organisms. Antimicrobials are typically effective in decreasing the frequency of pneumonia, and thus the risk of parenchymal lung damage, as well as improving the eczematoid dermatitis and abscesses. Antiseptics such as bathing in dilute bleach (roughly $^1/_2$ cup/full tub) for 15 minutes or swimming in chlorinated pools are usually effective in diminishing *S. aureus* colonization. Antifungal prophylaxis may be helpful for individuals with recurrent or chronic candida infections, such as candida nail infections. Chronic anti-aspergillus agents (e.g. voriconazole, posacona-

zole) should be used in individuals with *Aspergillus* lung infections. *Aspergillus* prophylaxis, such as with itraconazole, may be considered for those at risk, especially those with pneumatocoeles; however, this has not been studied. Immunoglobulin replacement has been helpful anecdotally for some individuals with AD-HIES, and should be considered, especially if infections are difficult to control despite prophylactic antibiotics. Bone marrow transplantation is not known to be curative [45,46]. One transplant was performed in a 7 year old girl; improvement in her symptoms was seen initially, but then several years after transplant, the clinical features returned, although somewhat improved, despite full engraftment [45]. In another report, transplant was performed for an adult with lymphoma; improvement in serum IgE was seen, but the patient died of transplant complications [46].

3. DOCK8 deficiency

Homozygous and compound heterozygous mutations in *DOCK8* were recently found to be the cause of a combined immunodeficiency that has been classified as a form of autosomal recessive HIES [4,5]. DOCK8 deficiency shares some similarities with AD-HIES including eczema, sinopulmonary infections, elevated serum IgE and eosinophilia; however, many of the other clinical features differ.

DOCK8 deficiency typically presents with eczema during infancy. As opposed to AD-HIES, the rash may not present in the newborn period, but often becomes apparent at several months of age, such as is typical for atopic dermatitis. The degree of eczema varies, but severe cases occur more frequently than in AD-HIES. Recurrent sinopulmonary infections typically start in early childhood. However, unlike AD-HIES, there is not one pathogen, such as *S. aureus*, that predominates. Both viral and bacterial pathogens are seen, and PCP may occur. In addition, the lung infections may be associated with asthma, which is a common feature in *DOCK8* deficiency. Recurrent lung infections may lead to bronchiectasis, but the pneumatocoeles that are frequent in AD-HIES, are rare in *DOCK8* deficiency. Recurrent sinus and ear infections are common, and tympanostomy tubes may be required.

The most striking and distinguishing clinical feature of *DOCK8* deficiency from AD-HIES is the cutaneous viral infections [4,5]. Difficult to control flat and verrucous warts secondary to human papilloma virus (HPV) and widespread *Molluscum contagiosum* are common

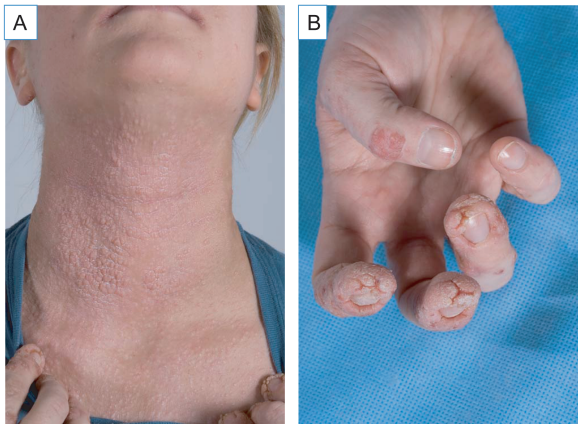

Fig. 5. 22 year old with DOCK8 deficiency with extensive Molluscum (A) and warts (B).

and can be disfiguring (Fig. 5). Recurrent herpes simplex and varicella zoster infections are frequent as well.

Fungal infections are not as common as in AD-HIES, but may occur [4,5]. Mucocutaneous candidiasis, including fingernail candidiasis, and cryptococcal meningitis have been reported.

Infections that have been reported, but occur rarely include invasive staphylococcal infections such as osteomyelitis, *Salmonella* enteritis, *Listeria* meningitis, disseminated *Neisseria meningitidis*, and progressive multifocal leukoencephalopathy (PML) [4,5].

The connective tissue, skeletal, and dental abnormalities that are frequent in AD-HIES are infrequent in *DOCK8* deficiency. There have been a few reports of retained primary teeth, fractures, and scoliosis, but it is not clear that these incidences are above those of the general population [4]. There are reports of eosinophilic esophagitis and eosinophilic pneumonitis; however, as these patients often have significant peripheral eosinophilia, the role of the eosinophils in causing disease is not clear. The coronary arterial abnormalities seen in AD-HIES have not been reported in *DOCK8* deficiency. There are reports of patients with aortic dilation without a genetic diagnosis (prior to discovery of DOCK8 mutations) with a syndrome that sounds consistent with DOCK8 deficiency [47].

3.1. Malignancy

Malignancies appear to be more common in *DOCK8* deficiency than in AD-HIES, with both squamous cell carcinomas and lymphomas occurring frequently [4,5]. The squamous cell carcinomas are most likely related to HPV, and have been difficult to cure. Burkitt's lym-

phoma has been seen, and consistent with non-*DOCK8* Burkitt's, has been aggressive in its presentation. These malignancies have been a common cause of death in the 2nd and 3rd decades of life.

3.2. Laboratory abnormalities

Similar to AD-HIES, eosinophilia and high IgE are common and may be markedly elevated [4,5]. Unlike AD-HIES, serum IgM is frequently decreased despite a typically normal or elevated serum IgG and variable IgA. Specific antibodies are often lacking. Lymphopenia is common, and may progress with age; T, B and NK cells are often all decreased with the CD4/CD8 ratio staying normal. Neutophils and monocyte numbers are usually normal.

3.3. Treatment

The eczema of DOCK8 deficiency may be severe and difficult to control with topical therapies. Several individuals have required systemic immunosuppressive agents, such as corticosteroids. Careful consideration needs to be given prior to initiating these therapies, as they can be very difficult to wean, and their use may lead to worsening of the skin viral infections and potentially increase the risk of opportunistic infections.

Conventional therapies are usually used to control the warts and *Molluscum* lesions, but attempts are often unsuccessful. Interferon-alpha has been used with varying anecdotal success. Immune globulin therapy has been used in many of the patients without specific antibodies, with anecdotal success in some.

Immune reconstitution with hematopoietic stem cell transplantation has been performed in two patients [48]. Extensive *Molluscum* lesions resolved within a year after transplant. Whether transplantation will prevent the malignancies, which are the main source of morbidity for these patients, still needs investigation. In addition, the most appropriate means of transplantation (such as degree of myeloablation) requires study.

4. Tyk2 deficiency

A single patient has been reported with a hyper IgE phenotype and a homozygous four-base pair deletion in the *TYK2* gene leading to absence of TYK2 protein [1]. Similar to other Hyper IgE syndromes, the patient had eczema, recurrent sinopulmonary infections, candidiasis and high serum IgE. Similar to the *DOCK8* deficient patients, he had *Molluscum contagiosum* and herpes infections. However, unlike the other described hyper IgE syndromes, he had infection with BCG, leading to the investigation of the IL-12, IFN-γ STAT1 pathway. This patient's T cells had defective responses to IL-12 and IFN-α, explaining the susceptibility to mycobacterial infection. Another patient with Tyk2 deficiency did not have a hyper IgE phenotype, but did have disseminated nontuberculous mycobacteria infection (personal communication, JL Casanova).

5. Other etiologies of hyper IgE

Several genetic etiologies have been classified as hyper IgE syndromes. However, greatly elevated serum IgE is not specific and is present in other syndromes of immunodeficiency and immune dysregulation [49]. For instance, Wiskott-Aldrich syndrome is associated with eczema, high IgE, recurrent infections, and increased risk of malignancy [50]. WAS is X-linked and associated with thrombocytopenia and frequent autoimmune disease. Omenn syndrome is a form of severe combined immunodeficiency (SCID) that presents in infancy with high IgE, rash (erythroderma), hepatosplenomegaly, lymphadenopathy and infections [51]. Compared to the hyper IgE syndromes, Omenn syndrome typically is a much more serious illness in early infancy. Lymphocyte phenotyping helps distinguish it early on. Other primary immunodeficiencies may have high IgE as a sign of immune dysregulation. Patients with common syndromes, such as atopic dermatitis, may have IgE levels comparable to those seen in HIES, but can be distinguished by the associated clinical features: allergies are typically absent in AD-HIES.

6. Conclusions

In the last 5 years, the major genetic etiologies of several hyper IgE syndromes have been delineated. Their clinical features are distinct, and can assist in determining targeted genetic testing. Treatment will also differ based on the genetic etiology. Hematopoietic stem cell transplantation (HSCT) is not typically considered for HIES, but should be considered in *DOCK8* deficiency, which has a much higher mortality at a young age. Now that the genetic etiologies have been determined, research will focus on the pathogenesis of these syndromes, which still remains poorly understood.

Acknowledgements

This research was supported by the Intramural Research Program of the NIH, NIAID, Bethesda, MD 20892. The views expressed in this article are those of the authors and do not reflect the official policy of the U.S. Government.

References

[1] Y. Minegishi, M. Saito, T. Morio et al., Human tyrosine kinase 2 deficiency reveals its requisite roles in multiple cytokines signals involved in innate and acquired immunity, *Immunity* **25**(20-6), 745–755.

[2] S. Holland, F. DeLeo, H. Elloumi et al., STAT3 Mutations in the Hyper-IgE Syndrome, *N Engl J Med* **357** (2007), 1608–1619.

[3] Y. Minegishi, M. Saito, S. Tsuchiya et al., Dominant Negative Mutations in the DNA binding domain of STAT3 cause hyper-IgE syndrome, *Nature* **448** (2007), 1058–1062.

[4] K.R. Engelhardt, S. McGhee, S. Winkler et al., Large deletions and point mutations involving the dedicator of cytokinesis 8 (DOCK8) in the autosomal-recessive form of hyper-IgE syndrome, *J Allergy Clin Immunol* **124** (2009), 1289–1302.

[5] Q. Zhang, J. Davis, I.T. Lamborn et al., Combined immunodeficiency associated with DOCK8 mutations, *N Engl J Med* **361** (2009), 2046–2055.

[6] R.H. Buckley, The hyper-IgE syndrome, *Clin Rev Allergy Immunol* **20** (2001), 139–154.

[7] B. Grimbacher, S.M. Holland, J.I. Gallin, F. Greenberg, S.C. Hill, H.L. Malech, J.A. Miller, A.C. O'Connell and J.M. Puck, Hyper-IgE syndrome with recurrent infections – an autosomal dominant multisystem disorder, *N Engl J Med* **340** (1999), 692–702.

[8] A.M. Gharib, R.I. Pettigrew, A. Elagha, A. Hsu, P. Welch, S.M. Holland and A.F. Freeman, Coronary abnormalities in hyper-IgE recurrent infection syndrome: depiction at coronary MDCT angiography, *AJR Am J Roentogenology* **193** (2009), W478–W481.

[9] S.L. Chamlin, T.H. McCalmont, B.B. Cunningham et al., Cutaneous manifestations of hyper-IgE syndrome in infants and children, *J Pediatr* **141** (2002), 572–575.

[10] C.L. Eberting, J. Davis, J.M. Puck and S.M. Holland, Dermatitis and the newborn rash of hyper-IgE syndrome, *Arch Dermatol* **140** (2004), 1119–1125.

[11] A.F. Freeman, D.E. Kleiner, H. Nadiminti, J. Davis, M. Quezado, V. Anderson, J.M. Puck and S.M. Holland, Causes of death in hyper-IgE syndrome, *J Allergy Clin Immunol* **119** (2007), 1234–1240.

[12] E. Melia, A.F. Freeman, Y.R. Shea, A.P. Hsu, S.M. Holland and K.N. Olivier, Pulmonary nontuberculous mycobacterial infections in hyper-IgE syndrome, *J Allergy Clin Immunol* **124** (2009), 617–618.

[13] D.C. Vinh, J.A. Sugui, A.P. Hsu, A.F. Freeman and S.M. Holland, Invasive fungal disease in autosomal-dominant hyper-IgE syndrome, *J Allergy Clin Immunol* **125** (2010), 1389–1390.

[14] A.F. Freeman, W. Barson, J. Davis, J.M. Puck and S.M. Holland, *Pneumocystis jiroveci* infection in patients with hyperimmunoglobulin E syndrome, *Pediatrics* **118** (2006), e1271–e1275.

[15] B.Z. Garty, A. Ben-Baruch, A. Rolinksy, C. Woellner, B. Grimbacher and N. Marcus, Pneumocystis jirovecii pneumonia in a baby with hyper-IgE syndrome, *J Pediatr* **169** (2010), 35–37.

[16] J.O. Hutto, C.S. Bryan, F.L. Greene, C.J. White and J.I. Gallin, Cryptococcosis of the colon resembling Crohn's disease in a patient with the hyperimmunoglob-ulinemia E-recurrent infection (Job's) syndrome, *Gastroenterology* **94** (1988), 808–812.

[17] D.H. Jacobs, A.M. Macher, R. Handler et al., Esophageal cryptococcosis in a patient with the hyperimmunoglobulin E-recurrent infection (Job's) syndrome, *Gastroenterology* **87** (1984), 201–203.

[18] S.J. Steiner, M.B. Kleiman, M.R. Corkins, J.C. Christensen and L.J. Wheat, Ileocecal histoplasmosis simulating Crohn disease in a patient with hyperimmunoglobulin E syndrome, *Pediatr Infect Dis J* **28** (2009), 7444–7446.

[19] K. Desai, D.P. Huston and G.R. Harriman, Previously undiagnosed hyper-IgE syndrome in an adult with multiple systemic fungal infections, *J Allergy Clin Immunol* **98** (1996), 1123–1124.

[20] A.E. Powers, J.M. Bender, A. Kumanovics, K. Ampofo, N. Augustine, A.T. Pavia and H.R. Hill, Coccioides immitis meningitis in a patient with hyperimmunoglobulin E syndrome due to a novel mutation in signal transducer and activation of transcription, *Pediat Infect Dis J* **28** (2009), 664–666.

[21] J.D. Milner, M. Sack, R. Huang, S.M. Holland and A.F. Freeman, *Effects of STAT3 Mutations on Atopy and Mast Cell Function*, Abstract, North American Primary Immune Deficiency National Conference. 2010.

[22] W.G. Borges, T. Hensley, J.C. Carey, B.A. Petrak and H.R. Hill, The face of Job, *J Pediatr* **133** (1998), 303–305.

[23] D. Domingo, A.F. Freeman, J. Davis, J.M. Puck, W. Tianxia, S.M. Holland and T.C. Hart, Novel intraoral phenotypes in hyper Immunoglobulin E syndrome, *Oral Diseases* (2007), 1–9.

[24] A.C. O'Connell, J.M. Puck, B. Grimbacher, F. Facchetti, A. Majorana, J.I. Gallin, H.L. Malech and S.M. Holland, Delayed eruption of permanent teeth in hyperimmunoglobulinemia E recurrent infection syndrome, *Oral Surg Oral Med Oral Pathol Oral Radiol Endod* **89** (2000), 177–185.

[25] M. Gahr, W. Mueller, B. Allgeier and C.P. Speer, A boy with recurrent infections, impaired PMN-chemotaxis, increased IgE concentrations and cranial synostosis – a variant of the hyper-IgE syndrome? *Helv Paediatr Acta* **42** (1987), 185–190.

[26] P.H. Höger, E. Boltshauser and W.H. Hitzig, Craniosynostosis in hyper-IgE syndrome, *Eur J Pediatr* **144** (1985), 414–417.

[27] E.M. Smithwick, M. Finelt, S. Pahwa et al., Cranial synostosis in Job's syndrome, *Lancet 1* **826** (1978).

[28] E. Alomar-Melero, T.D. Martin, G.M. Janelle and Y.G. Peng, An unusual giant right coronary artery aneurysm resembles an intracardiac mass, *Anesth Analg* **107** (2008), 1161–1162.

[29] J.C. Ling, A.F. Freeman, A.M. Gharib, A.E. Arai, R.J. Lederman, D.R. Rosing and S.M. Holland, Coronary artery aneurysms in patients with hyper IgE recurrent infection syndrome, *Clin Immunol* **122** (2007), 255–258.

[30] H. Yavuz and R. Chee, A review of the vascular phenotypes of the hyperimmunoglobulin E syndrome, *Clin Exp Immunol* **159** (2010), 238–244.

[31] T.Y. Young, D. Jerome and S. Gupta, Hyperimmunoglobulinemia E syndrome associated with coronary artery aneurysms: deficiency of central memory CD4+ T cells and expansion of effector memory CD4+ T cells, *Ann Allergy Asthma Immunol* **98** (2007), 389–392.

[32] A.F. Freeman, C.J. Collura-Burke, N.J. Patronas et al., Brain abnormalities in patients with hyperimmunoglobulin E syndrome, *Pediatrics* **119** (2007), e1121–e1125.

[33] J. Heimall, M. Arora, T. Heller et al., *Gastrointestinal Manifestations of Autosomal Dominant Gyper IgE Syndrome*, Abstract, North American Primary Immune Deficiency National Conference. 2010.

[34] L.J. Gorin, S.C. Jeha, M.P. Sullivan, H.M. Rosenblatt and W.T. Shearer, Burkitt's lymphoma developing in a 7-year-old boy with hyper-IgE syndrome, *J Allergy Clin Immunol* **83** (1989), 5–10.

[35] G.D. Leonard, E. Posadas, P.C. Herrmann et al., Non-Hodgkin's lymphoma in Job's syndrome: a case report and review of the literature, *Leuk Lymphoma* **45** (2004), 2521–2525.

[36] I. Oztop, B. Demirkan, O. Tarhan et al., The development of a pulmonary adenocarcinoma in a patient with Job's syndrome, a rare immunodeficiency condition, *Tumori* **90** (2004), 132–135.

[37] R.H. Buckley, S.E. Schiff and A.R. AHayward, Reduced frequency of CD45RO+ T lymphocytes in blood of hyper-IgE syndrome patients, *J Allergy Clin Immunol* **87** (1991), 313.

[38] C. Speckmann, A. Enders and C. Woellner, Reduced memory B cells in patients with hyper IgE syndrome, *Clin Immunol* **129** (2008), 448–454.

[39] L. DeBeaucoudrey, A. Puel, O. Filipe-Santos, A. Cobat, P. Ghandil, M. Chrabieh, J. Feinberg, H. von Bernuth, A. Samarina, L. Janniere, C. Fieschi, J.L. Stephan, C. Boileau, S. Lyonnet, G. Jondeau, V. Cormier-Daire, M. Le Merrer, C. Hoarau, Y. Lebranchu et al., Mutations in STAT3 and IL12RB1 impair the development of human IL-17 producing cells, *J Exp Med* **205** (2008), 1543–1550.

[40] C.S. Ma, G.Y. Chew, N. Simpson, A. Priyadarshi, M. Wong, B. Grimbacher, D.A. Fulcher, S.G. Tangye and M.C. Cook, Deficiency of Th17 cells in hyper IgE syndrome due to mutations in STAT3, *J Exp Med* **205** (2008), 1551–1557.

[41] J.D. Milner, J.M. Brenchley, A. Laurence, A.F. Freeman, B.J. Hill, K.M. Elias, Y. Kanno, C. Spalding, H.Z. Elloumi, M.L. Paulson, J. Davis, A. Hsu, A.I. Asher, J. O'shea, S.M. Holland, W.E. Paul and D.C. Douek, Impaired Th17 cell differentiation in subjects with autosomal dominant hyper-IgE syndrome, *Nature* **452** (2008), 773–776.

[42] E.D. Renner, S. Ryalaarsdam, S. Anover-Sombke, A.L. Rack, J. Reichenbach, J.C. Carey, Q. Zhu, A.F. Jansson, J. Barboza, L.F. Schimke, M.F. Leppert, M.M. Getz, R.A. Seger, H.R. Hill, B.H. Belohradsky, T.R. Torgerson and H.D. Ochs, Novel signal transducer and activator of transcription 3 (STAT3) mutations, reduced T(H)17 cells numbers, and STAT3 phosphorylation in hyper-IgE syndrome, *J Allergy Clin Immunol* **122** (2008), 181–187.

[43] B. Grimbacher, A.A. Schaffer, S.M. Holland, J. Davis, J.I. Gallin, H.L. Malech, T.P. Atkinson, B.H. Belohradsky, R.H. Buckley, F. Cossu, T. Espanol, B.Z. Garty, N. Matamoros, L.A. Myers, R.P. Nelson, H.D. Ochs, E.D. Renner, N. Wellinghausen and J.M. Puck, Genetic linkage of hyper-IgE syndrome to chromosome 4, *Am J Hum Genet* **65** (1999), 735–744.

[44] C. Woellner, E.M. Gertz, A.A. Schaffer et al., Mutations in STAT3 and diagnostic guidelines for hyper-IgE syndrome, *J Allergy Clin Immunol* **125** (2010), 424–432.

[45] A.R. Gennery, T.J. Flood, M. Abinun and A.J. Cant, Bone marrow transplantation does not correct the hyper IgE syndrome, *Bone Marrow Transplant* **25** (2000), 1303–1305.

[46] T.A. Nester, A.H. Wagnon, W.F. Reilly, G. Spitzer, C.R. Kjeldsberg and H.R. Hill, Effects of allogeneic peripheral stem cell transplantation in a patient with job syndrome of hyperimmunoglobulinemia E and recurrent infections, *Am J Med* **105** (1998), 162–164.

[47] J.W.M. Van der Meer, C.M.R. Weemaes, Van Krieken et al., Critical aneurismal dilatation of the thoracic aorta in young adolescents with variant hyperimmunoglobulin E syndrome, *J of Internal Med* **259** (2006), 615–618.

[48] BMT, DOCK8 paper- to be published.

[49] E. Ozcan, L.D. Notarangelo and R.S. Geha, Primary immune deficiencies with aberrant IgE production, *J Allergy Clin Immunol* **122** (2008), 1054–1062.

[50] H.D. Ochs, A.H. Filipovich, P. Veys, M.J. Cowan and N. Kapoor, Wiskott-Aldrich syndrome: diagnosis, clinical and laboratory manifestations, and treatment, *Biol Blood Marrow Transplant* **15**(1 Suppl) (2009), 84–90.

[51] A. Villa, L.D. Notarangelo and C.M. Roifman, Omenn syndrome: Inflammation in leaky severe combined immunodeficiency, *J Allergy Clin Immunol* **122** (2008), 1082–1086.