

Erratum

Erratum to “Short Implants in Partially Edentulous Maxillae and Mandibles: A 10 to 20 Years Retrospective Evaluation”

**Diego Lops,¹ Eriberto Bressan,² Gianluca Pisoni,¹ Niccolò Cea,¹
Boris Corazza,² and Eugenio Romeo³**

¹ Department of Prosthodontics, S. Paul Hospital Dental Clinic, School of Dentistry, University of Milan, 20142 Milan, Italy

² Department of Implant Dentistry, Padova University Institute of Clinical Dentistry, 35020 Padova, Italy

³ Department of Implant Dentistry, S. Paul Hospital Dental Clinic, School of Dentistry, University of Milan, 20142 Milan, Italy

Correspondence should be addressed to Diego Lops; diego.lops@guest.unimi.it

Received 31 March 2013; Accepted 29 May 2013

Copyright © 2013 Diego Lops et al. This is an open access article distributed under the Creative Commons Attribution License, which permits unrestricted use, distribution, and reproduction in any medium, provided the original work is properly cited.

There were some modifications in Tables 1 and 4.

TABLE 1: Implant distribution by diameter, length, and type.


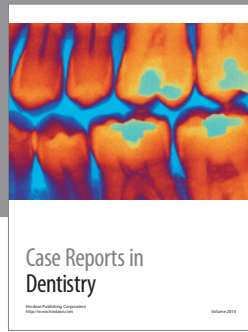
Length	Diameter	Number
8 mm	3.3 mm	21
	4.1 mm	66
	4.8 mm	21
		108
10 mm	3.3 mm	33
	4.1 mm	89
	4.8 mm	37
		149

TABLE 4: Short and standard implants distribution: compliances and failures.

Site	Implant size (mm)	Type of prosthesis	Cause of compliance	Cause of failure
24	3.3 × 8	FCD	—	Mobility due to severe peri-implantitis
36	4.1 × 8	FPD	—	Mobility due to severe peri-implantitis
16	4.1 × 8	FPD	—	Mobility due to severe peri-implantitis
15	4.1 × 8	FPD	—	Mobility due to severe peri-implantitis
46	4.8 × 8	ST	Pathologic peri-implant bone resorption	—
35	4.1 × 8	FPD	Successfully treated peri-implantitis	—
24	4.1 × 8	ST	Successfully treated peri-implantitis	—
15	4.1 × 8	FPD	Successfully treated peri-implantitis	—
25	4.1 × 8	ST	Successfully treated peri-implantitis	—
24	4.1 × 8	FCD	Pathologic peri-implant bone resorption	—
16	4.1 × 8	ST	Pathologic peri-implant bone resorption	—
24	4.1 × 8	FPD	Successfully treated peri-implantitis	—
45	4.1 × 8	FPD	Pathologic peri-implant bone resorption	—
16	4.8 × 10	ST	—	Mobility due to severe peri-implantitis
24	4.1 × 10	FCD	—	Mobility due to severe peri-implantitis
25	3.3 × 10	FPD	—	Mobility due to severe peri-implantitis
36	4.1 × 10	FPD	—	Mobility due to severe bone resorption
37	4.1 × 10	FPD	Successfully treated peri-implantitis	—
14	4.1 × 10	FPD	Pathologic peri-implant bone resorption	—
25	4.8 × 10	FPD	Successfully treated peri-implantitis	—
16	4.1 × 10	ST	Successfully treated peri-implantitis	—
46	4.1 × 10	FPD	Successfully treated peri-implantitis	—
25	4.1 × 10	FPD	Successfully treated peri-implantitis	—
35	4.1 × 10	ST	Pathologic peri-implant bone resorption	—
25	4.1 × 10	ST	Pathologic peri-implant bone resorption	—
34	4.1 × 10	FPD	Pathologic peri-implant bone resorption	—
16	4.8 × 10	FPD	Pathologic peri-implant bone resorption	—
44	4.1 × 10	FPD	Successfully treated peri-implantitis	—

Tooth numbers: 14 = maxillary right first premolar, 15 = maxillary right second premolar, 16 = maxillary right first molar, 24 = maxillary left first premolar, 25 = maxillary left second premolar, 35 = mandibular right second premolar, 36 = mandibular left first molar, 37 = mandibular left second molar 44 = mandibular right first premolar, and 46 = mandibular right first molar.

ST = single tooth prosthesis, FCD = fixed complete dentures, PFD = partial fixed dentures.



Hindawi
Submit your manuscripts at
<http://www.hindawi.com>

