Hindawi Publishing Corporation
International Journal of Dentistry
Volume 2016, Article ID 6282587, 5 pages
http://dx.doi.org/10.1155/2016/6282587

Clinical Study

A New Total Digital Smile Planning Technique (3D-DSP) to Fabricate CAD-CAM Mockups for Esthetic Crowns and Veneers

F. Cattoni,[1] F. Mastrangelo,[1] E. F. Gherlone,[1] and G. Gastaldi[1,2]

[1]*Dental School, Vita Salute University, 20132 Milan, Italy*
[2]*Dental and Maxillofacial Surgery Unit, San Rocco Clinical Institute, Ome, 25050 Brescia, Italy*

Correspondence should be addressed to F. Cattoni; cattonif@tiscalinet.it

Received 5 April 2016; Revised 31 May 2016; Accepted 1 June 2016

Academic Editor: Jamil A. Shibli

Purpose. Recently, the request of patients is changed in terms of not only esthetic but also previsualization therapy planning. The aim of this study is to evaluate a new 3D-CAD-CAM digital planning technique that uses a total digital smile process. *Materials and Methods.* Study participants included 28 adult dental patients, aged 19 to 53 years, with no oral, periodontal, or systemic diseases. For each patient, 3 intra- and extraoral pictures and intraoral digital impressions were taken. The digital images improved from the 2D Digital Smile System software and the scanner stereolithographic (STL) file was matched into the 3D-Digital Smile System to obtain a virtual previsualization of teeth and smile design. Then, the mockups were milled using a CAM system. Minimally invasive preparation was carried out on the enamel surface with the mockups as position guides. *Results.* The patients found both the digital smile design previsualization (64.3%) and the milling mockup test (85.7%) very effective. *Conclusions.* The new total 3D digital planning technique is a predictably and minimally invasive technique, allows easy diagnosis, and improves the communication with the patient and helps to reduce the working time and the errors usually associated with the classical prosthodontic manual step.

1. Introduction

In recent years, the concept of what makes a smile beautiful has changed significantly [1, 2]. Nowadays, patients expect complex functional rehabilitations that are esthetically appealing [2–5]. An important goal in prosthodontic is to use minimally invasive treatment to improve the appearance of the smile [3–6] as a way to valorize the entire image of the patient [7] while maintaining the health and function of teeth and soft tissue [8, 9].

Porcelain laminate veneers (PLVs), minimally invasive solutions to dental esthetic problems, have the most long-term success [7, 10–14]. There are a number of stages in rehabilitative dental treatment, from making the impression and developing the model to creating the diagnostic wax-up and to constructing the laboratory mockup. The planning associated with creating a mockup is a very important as it affects patients' understanding of the expected result [15, 16]. Whether the patient is happy with the overall treatment depends on how similar the prosthesis is to the mockup [17, 18]. The shape of the teeth, the adaptation of the prosthesis, and the size and the color of the new elements in relation to the soft tissue, lips, and the whole face are very important in the decision-making [19].

A large number of errors can occur at the various stages of the traditional prosthetic workflow, each stage requires a transfer of two-dimensional and three-dimensional (3D) data between operators. As computer-aided design and computer-aided manufacturing (CAD/CAM) and new materials are leading to a paradigm shift in what many practitioners regard as standard care for patients, a priority is to drastically reduce operator error [20].

The aim of this research was to evaluate new total 3D digital smile planning technique (3D-DSP) used in the previsualization stage prior to milling poly(methyl methacrylate) (PMMA) mockups in the process of creating PLVs using a CAD/CAM system.

Table 1: Number of the patient veneers restorations.

	Number of treated patients	%
Males	9	32.2
Female	19	67.8
Total	28	100

Table 2: Distribution of porcelain laminate veneers according to location.

		Veneers	
		Number (n)	Percentage (%)
Maxilla	Anterior	54	50
	Posterior	30	27.8
	Total	84	77.8
Mandible	Anterior	10	9.3
	Posterior	14	12.9
	Total	24	22.2
Total		108	100

2. Materials and Methods

Between September 2012 and July 2015, 28 patients (9 male and 19 female) aged 19 to 53 years (mean age of 36 years) took part in this study at the dental clinic at San Raffaele University, Milan, Italy. None of the patients had any oral, periodontal, or systemic diseases (Tables 1 and 2).

After radiological, phonetic, and static and dynamic occlusal evaluation, each patient had three intra- and extraoral digital images taken while wearing special eyewear (Digital Smile System Srl, Italy) (Figures 1 and 2). An intraoral scanner (Scanner 3D Progress, MHT, Italy) was used to get intraoral digital impressions of the maxilla and mandible arches in open and occlusal states. All the digital images, obtained from the processing of the pictures into the software 2D-Digital Smile System (Digital Smile System Srl, Italy) (Figure 3) and the STL file from the intraoral scans, were combined into the 3D-Digital Smile System (EGS Srl, Italy) to display the patient's teeth and, from this, a virtual design of the potential dental prosthesis was created. When the patient agreed to this virtual 3D view of their planned-for prosthetics, a PMMA mockup (Bredent Srl, Italy) was milled using a CAM system (Zirkonzahn Srl, Italy) (Figure 4). Each mockup was tested in the patient's oral cavity to make sure they would consent to the esthetic therapy and be satisfied with the end result (Figure 5). The newly milled mockups, cemented using spot-etch technique [21, 22], were used to guide the position of the prosthetics and maintain the margins on the enamel surface of the teeth [23–25] (Figure 6). The double cord techniques with the intraoral scanner (Scanner 3D Progress, MHT, Italy) was used to make all the definitive impression of the prepared teeth (Figure 7). The PLVs (IPS e.max System, Ivoclar Vivadent Srl, Italy) were produced using CAD/CAM technique (Zirkonzahn Srl, Italy). A total of 78 Variolink veneers (Ivoclar Vivadent Corp., Liechtenstein) and 30 Clearfil Esthetic Cement veneers (Kuraray America Inc., USA) were cemented onto vital teeth (Table 3) (Figure 8).

Figure 1: Initial clinical case intraoral photography.

Figure 2: Initial clinical case extraoral photography.

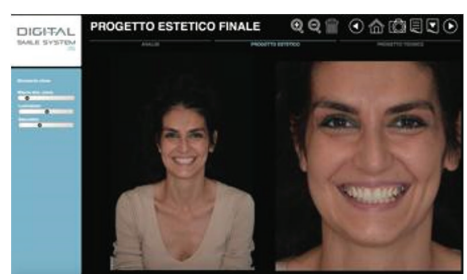

Figure 3: Digital smile design into Digital Smile System 2D.

Each patient had final intra- and extraoral digital images taken (Figures 9 and 10). Follow-up took place after 2 years.

3. Results

The preoperative patient parameters showed bruxism (22.2%), tooth trauma (14.8%), abrasion (11.2%), discoloration (22.2%), crowding (14.8%), diastema (7.4%), and caries (7.4%) (Table 4). The follow-up 2 years later revealed 1 total fracture, 2 sensitive teeth, and 1 gingival recession (0.9%). None of the 108 PLVs showed debonding,

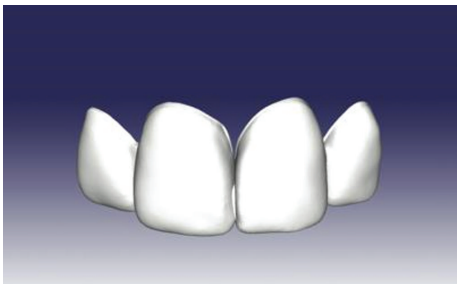

Figure 4: CAD design of the mockup.

Figure 5: Intraoral evaluation of milling CAD-CAM mockup.

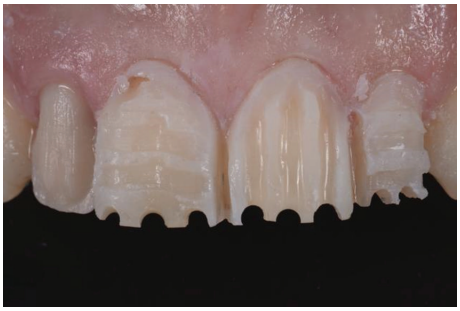

Figure 6: Mockup guide for teeth preparation.

Figure 7: Double cord retraction technique.

Figure 8: Adhesive cementation of the definitive veneers.

Table 3: Distribution of PLVs according to bonding material.

Veneers (CAD-CAM)	108	100
Variolink veneers (Ivoclar Vivadent)	78	72.2
Clearfil esthetic cement (Kuraray)	30	27.8
Total	108	100

chipping, microleakage, discoloration, or secondary caries, and no root canal therapy was necessary (Table 5).

Patients responded to a questionnaire to determine their satisfaction with the digital smile design planning and the test in the form of the mockup. They graded both the planning and the test as effective, very effective, or ineffective. For the digital smile design previsualization, with visual analogical scale (VAS scale), 18 (64%) of patients found it very effective and 10 (36%) effective; 24 (86%) found the milling mockup very effective and 4 (14%) effective (Table 6).

4. Discussion

In all prosthodontic aesthetic treatment, the accurate design planning and the basic communication phase with the patient play a crucial role in the therapy. The best previsual means most widely used as a measure of explanation with a patient is the therapeutic planning, associated with the creation of a mockup [17, 19]. With contemporary digitalized techniques, it is possible to redesign a patient's smile [15, 16]. Effective previsualization followed by a mockup is the ideal way to explain changes to a patient and receive their approval [17–19]. Traditional "analogical techniques" are based on a planning process that involves radiological and clinical evaluation, intra- and extraoral photographic analysis, static and dynamic occlusal evaluation, and traditional impressions [21]. The more traditional techniques that use the free-hand "composite technique" before the wax-up do not evaluate the design of the smile [25, 26].

A secondary evolution of digital prosthetic planning is limited to bidimensional digital work flow [21] and requires, after digital smile design protocol, the stone model, the manual processing of a laboratory diagnostic wax-up, and the printing of the classic mockup in the patient's oral cavity through the use of silicone keys. In traditional planning techniques, the data transfer from virtual design to laboratory is difficult and potentially full of errors because it uses a manual process to obtain the computer design of canine zenith lines for the laboratory stone model [21]. This manual process is necessary to transfer all the measurements of the teeth to the new smile project design. Another difficult and unpredictable process is the mockup printing in the patient's

Figure 9: Final result: intraoral photography.

Figure 10: Final result: extraoral photography.

Table 4: Preoperative parameters.

	Patients		Teeth	
	Number (n)	Percentage (%)	Number (n)	Percentage (%)
Trauma	2	7.2	16	14.8
Bruxism	4	14.3	24	22.2
Abrasion	6	21.4	12	11.2
Discoloration	6	21.4	24	22.2
Crowding	4	14.3	16	14.8
Diastema	2	7.1	8	7.4
Caries	4	14.3	8	7.4
Total	28	100	108	100

Table 5: Distribution of failures according to preparation design.

	Among 28 patients	%	Among 108 veneers	%
Fracture	1	3.6	1	0.9
Chipping	0	0	0	0
Debonding	0	0	0	0
Microleakage	0	0	0	0
Secondary caries	0	0	0	0
Sensitivity	2	7.1	2	1.8
Root canal treatment	0	0	0	0
Gingival recession	1	3.6	1	0.9
Discoloration	0	0	0	0

oral cavity with a silicone mask (made on a wax-up) [10–21]. Our new planning technique allows a new totally digital and CAD-CAM process, from the initial photo shoot to CAD/CAM-milling mockup, to reduce the errors usually associated with the classical manual steps and to improve the accuracy of the prosthetic procedure. All digital data transfer from the clinical 3D planning to the laboratory CAD/CAM process is simpler, faster, and more predictable. However, having photographs plays a crucial role: the patient-approved virtual smile is used to guide the final design of the teeth, which are usually made with the CAD/CAM process.

Table 6: Appreciation of the previsualization with VAS scale.

Test with smile design	Very effective	18	64.3%
	Effective	10	35.7%
	Ineffective	0	0%
	Total	28	100%
Test with mockup	Very effective	24	85.7%
	Effective	4	14.3%
	Ineffective	0	0%
	Total	28	100%

5. Conclusions

A 2-year follow-up of prosthetic PLVs created using the new total digital smile planning technique in vital teeth in the esthetic zone showed that it is possible to obtain excellent results in both functional and esthetic rehabilitation and high patient satisfaction. The new procedure also reduces the amount of time spent in the clinic and laboratory, increases the predictability of data matching to build CAD/CAM-milling mockups, reduces trauma caused by handling hard dental tissues, and improves accuracy and reproducibility of the final mockup. The total new digital smile planning technique is minimally invasive and facilitates diagnosis, improves communication with the patient, reduces processing times, and increases predictability of the results with very little discomfort and very high esthetic final results. The present study has limits, such as the limited number of patients enrolled: further studies on a larger sample of patients are therefore needed to confirm our present results.

Competing Interests

The authors declare that they have no competing interests.

Acknowledgments

The authors are grateful to Laboratorio Latezera Srl, Savona, Italy, and Dr. Fabio Manazza, for their valuable help and support.

References

[1] C. R. Rufenacht, *Fundamentals of Esthetics*, Quintessence, Chicago, Ill, USA, 1990.

[2] M. Peumans, B. Van Meerbeek, P. Lambrechts, and G. Vanherle, "Porcelain veneers: a review of the literature," *Journal of Dentistry*, vol. 28, no. 3, pp. 163–177, 2000.

[3] M. R. Mack, "Perspective of facial esthetics in dental treatment planning," *Journal of Prosthetic Dentistry*, vol. 75, no. 2, pp. 169–176, 1996.

[4] F. G. Mangano, C. Mangano, M. Ricci, R. L. Sammons, J. A. Shibli, and A. Piattelli, "Esthetic evaluation of single-tooth morse taper connection implants placed in fresh extraction sockets or healed sites," *Journal of Oral Implantology*, vol. 39, no. 2, pp. 172–181, 2013.

[5] F. Mangano, C. Mangano, M. Ricci, R. L. Sammons, J. A. Shibli, and A. Piattelli, "Single-tooth Morse taper connection implants placed in fresh extraction sockets of the anterior maxilla: an aesthetic evaluation," *Clinical Oral Implants Research*, vol. 23, no. 11, pp. 1302–1307, 2012.

[6] G. L. Patzer, *The Physical Attractiveness Phenomena*, Plenum Publishing, New York, NY, USA, 1985.

[7] G. Gürel, "Predictable, precise, and repeatable tooth preparation for porcelain laminate veneers," *Practical Procedures & Aesthetic Dentistry*, vol. 15, no. 1, pp. 17–26, 2003.

[8] R. E. Goldstein, *Esthetics in Dentistry*, Lippincott, Philadelphia, Pa, USA, 1976.

[9] P. Richer, *Artistic Anatomy*, Watson Guptill, New York, NY, USA, 1971.

[10] G. Gürel, "Porcelain laminate veneers: minimal tooth preparation by design," *Dental Clinics of North America*, vol. 51, no. 2, pp. 419–431, 2007.

[11] D. Dieschi and R. Spreafico, *Adhesive Metal-Free Restorations: Current Concepts for the Esthetic Treatment of Posterior Teeth*, Quintessence, Chicago, Ill, USA, 1997.

[12] J.-H. Chen, C.-X. Shi, M. Wang, S.-J. Zhao, and H. Wang, "Clinical evaluation of 546 tetracycline-stained teeth treated with porcelain laminate veneers," *Journal of Dentistry*, vol. 33, no. 1, pp. 3–8, 2005.

[13] M. Granell-Ruiz, A. Fons-Font, C. Labaig-Rueda, A. Martínez-González, J.-L. Román-Rodríguez, and M. F. Solá-Ruiz, "A clinical longitudinal study 323 porcelain laminate veneers. Period of study from 3 to 11 years," *Medicina Oral, Patologia Oral y Cirugia Bucal*, vol. 15, no. 3, pp. e531–e537, 2010.

[14] M. F. Land and C. D. Hopp, "Survival rates of all-ceramic systems differ by clinical indication and fabrication method," *Journal of Evidence-Based Dental Practice*, vol. 10, no. 1, pp. 37–38, 2010.

[15] D. Little, "The impact of aesthetics in restorative treatment planning," *Dentistry Today*, vol. 34, no. 5, pp. 475–491, 2015.

[16] J.-H. Chen, H.-L. Huang, Y.-C. Lin, T.-M. Chou, J. Ebinger, and H.-E. Lee, "Dentist-patient communication and denture quality associated with complete denture satisfaction among Taiwanese elderly wearers," *The International Journal of Prosthodontics*, vol. 28, no. 5, pp. 531–537, 2015.

[17] J. Gurrea and A. Bruguera, "Wax-up and mock-up. A guide for anterior periodontal and restorative treatments," *The International Journal of Esthetic Dentistry*, vol. 9, no. 2, pp. 146–162, 2014.

[18] P. Magne, "A new approach to the learning of dental morphology, function, and esthetics: the '2D-3D-4D' concept," *The International Journal of Esthetic Dentistry*, vol. 10, no. 1, pp. 32–47, 2015.

[19] H. Simon and P. Magne, "Clinically based diagnostic wax-up for optimal esthetics: the diagnostic mock-up," *Journal of the California Dental Association*, vol. 36, no. 5, pp. 355–362, 2008.

[20] F. Beuer, J. Schweiger, and D. Edelhoff, "Digital dentistry: an overview of recent developments for CAD/CAM generated restorations," *British Dental Journal*, vol. 204, no. 9, pp. 505–511, 2008.

[21] E. A. McLaren, "Bonded functional esthetic prototype: an alternative pre-treatment mock-up technique and cost-effective medium-term esthetic solution," *Compendium of Continuing Education in Dentistry*, vol. 34, no. 8, pp. 596–607, 2013.

[22] L. Grütter and F. Vailati, "Full-mouth adhesive rehabilitation in case of severe dental erosion, a minimally invasive approach following the 3-step technique," *European Journal of Esthetic Dentistry*, vol. 8, no. 3, pp. 358–375, 2013.

[23] M. G. Buonocore, "A simple method of increasing the adhesion of acrylic filling materials," *Journal of Dental Research*, vol. 34, no. 6, pp. 849–853, 1955.

[24] A. Aykor and E. Ozel, "Five-year clinical evaluation of 300 teeth restored with porcelain laminate veneers using total-etch and a modified self-etch adhesive system," *Operative Dentistry*, vol. 34, no. 5, pp. 516–523, 2009.

[25] G. Gurel, S. Morimoto, M. A. Calamita, C. Coachman, and N. Sesma, "Clinical performance of porcelain laminate veneers: outcomes of the aesthetic pre-evaluative temporary (APT) technique," *The International Journal of Periodontics & Restorative Dentistry*, vol. 32, no. 6, pp. 625–635, 2012.

[26] M. Reshad, D. Cascione, and P. Magne, "Diagnostic mock-ups as an objective tool for predictable outcomes with porcelain laminate veneers in esthetically demanding patients: a clinical report," *Journal of Prosthetic Dentistry*, vol. 99, no. 5, pp. 333–339, 2008.