

## Figure 10. VASCULAR ACCESS DIAGRAM

Procedure Date: \_\_\_\_\_

Patient Name: \_\_\_\_\_

Dialysis Clinic: \_\_\_\_\_

Procedure Performed by: \_\_\_\_\_

---

---

**PROCEDURE (S):** *Check All That Apply*

AV Fistula     AV Graft     DRIL

Catheter

Fistulogram     Thrombectomy     Stent

Angioplasty     Ultrasound

Other \_\_\_\_\_

**ACCESS TYPE:**

AV Fistula     AV Graft   

Other \_\_\_\_\_

Access Can Be Used When: \_\_\_\_\_

**DIAGNOSIS: poorly matured fistula**

**ULTRASOUND FINDINGS:****INFLOW ARTERY:**

Radial artery:

- Mid PSV 80 cm/sec, EDV 14 cm/sec
- Distal PSV 69 cm/sec, EDV 16 cm/sec
- Pre- anastomosis: PSV 130 cm/sec, EDV 51 cm/sec
- The artery is heavily calcified and small near the wrist.

Radiocephalic anastomosis: PSV 892 cm/sec, EDV 262 cm/sec. There is a stenosis.

**ACCESS:**

Cephalic vein:

- Wrist PSV 90 cm/sec, EDV 34 cm/sec
- Forearm distal: PSV 20 cm/sec, EDV 12 cm/sec. Diameter 0.47 cm
- Forearm mid: PSV 25 cm/sec, EDV 14 cm/sec. Diameter 0.34 cm
- Forearm proximal: PSV 23 cm/sec, EDV 10 cm/sec. Diameter 0.46cm
- Antecubital fossa: diameter 0.25 cm.
- The vein becomes small in the upper arm. The basilic vein in the upper arm drains the fistula.

Volume flow in the mid forearm is 75 ml/min

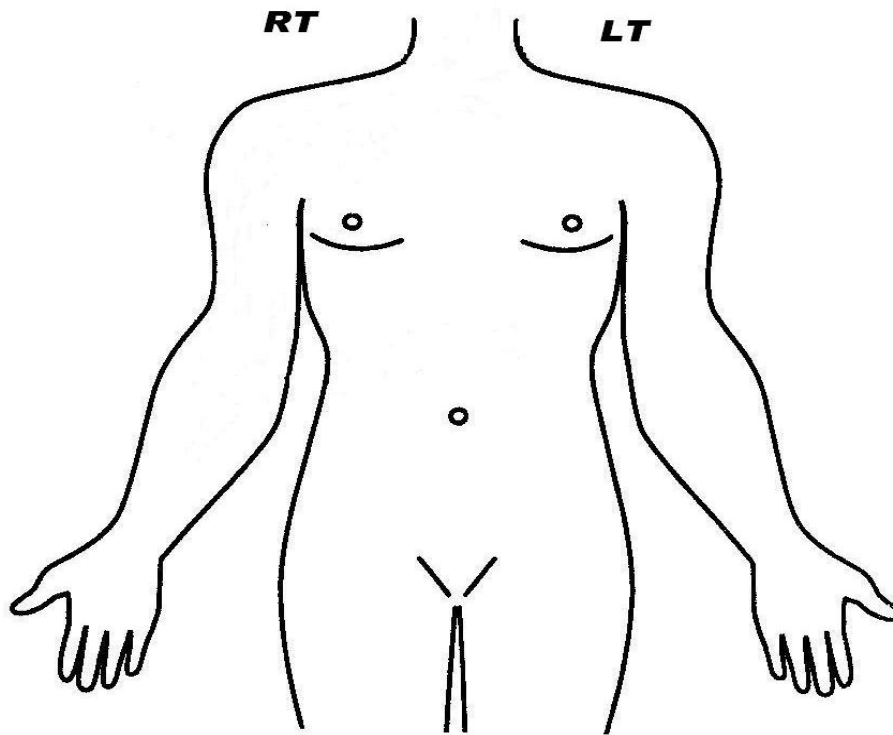
**OUTFLOW:**

The innominate vein, subclavian vein and axillary vein are patent with normal Doppler waveforms. The internal jugular vein is small and not compressible in the proximal segment consistent with remote (old) deep vein thrombosis.

# VASCULAR ACCESS DIAGRAM

SPECIAL INSTRUCTIONS:

---



**FAXED TO:**

Dialysis Center     Copy Given to Patient

Date: \_\_\_\_\_

Instructions given to:

\_\_\_\_\_

Faxed By: \_\_\_\_\_

**MD SIGNATURE:** \_\_\_\_\_