

## Review Article

# Management of Acute Spinal Fractures in Ankylosing Spondylitis

Saad B. Chaudhary, Heidi Hullinger, and Michael J. Vives

Department of Orthopaedic Surgery, New Jersey Medical School, UMDNJ, 140 Bergen Street, ACC D-1610, Newark, NJ 07103, USA

Correspondence should be addressed to Saad B. Chaudhary, [chaudhs1@umdnj.edu](mailto:chaudhs1@umdnj.edu)

Received 28 March 2011; Accepted 25 April 2011

Academic Editors: J. Bruges Armas and A. Kessel

Copyright © 2011 Saad B. Chaudhary et al. This is an open access article distributed under the Creative Commons Attribution License, which permits unrestricted use, distribution, and reproduction in any medium, provided the original work is properly cited.

Ankylosing Spondylitis (AS) is a multifactorial and polygenic rheumatic condition without a well-understood pathophysiology (Braun and Sieper (2007)). It results in chronic pain, deformity, and fracture of the axial skeleton. AS alters the biomechanical properties of the spine through a chronic inflammatory process, yielding a brittle, minimally compliant spinal column. Consequently, this patient population is highly susceptible to unstable spine fractures and associated neurologic devastation even with minimal trauma. Delay in diagnosis is not uncommon, resulting in inappropriate immobilization and treatment. Clinicians must maintain a high index of suspicion for fracture when evaluating this group to avoid morbidity and mortality. Advanced imaging studies in the form of multidetector CT and/or MRI should be employed to confirm the diagnosis. Initial immobilization in the patient's preinjury alignment is mandatory to prevent iatrogenic neurologic injury. Both nonoperative and operative treatments can be employed depending on the patient's age, comorbidities, and fracture stability. Operative techniques must be individually tailored for this patient population. A multidisciplinary team approach is best with preoperative nutritional assessment and pulmonary evaluation.

## 1. Introduction

Ankylosing spondylitis is a seronegative arthropathy primarily affecting the sacroiliac joints and the spinal column. Other large joints including the hips, knees, and shoulders can also show degeneration. AS is strongly associated with the HLA-B27 gene; 90–95% of patients with ankylosing spondylitis are positive for HLA-B27; however, only 1–5% of B27-positive individuals develop AS. Men are more often affected than women, with a ratio of 2:1 [1–3]. The disease prevalence is 1–3 in 1000, and the typical age of onset is between the second and the fifth decade of life [4]. AS can be diagnosed based on clinical and/or radiologic findings. According to the *modified New York criteria*, a patient can be classified as having definite Ankylosing Spondylitis if they present with one clinical and one radiological criteria: *radiographic evidence* includes either unilateral (grade 3) or bilateral (grade 2) sacroiliitis, and the *clinical presentation* should be consistent with chronic low-back pain (>3 months) relieved by exercise but not with rest, or limitation of motion in the lumbar spine in both coronal and sagittal planes, and/or

decreased chest expansion relative to age-matched controls [5]. While these criteria are currently used for classification, they are not particularly sensitive in early disease states, and HLA-B27 typing along with MRI evidence of sacroiliitis can be useful adjuncts [6].

## 2. Pathophysiology

The hallmark for Ankylosing spondylitis is inflammatory sacroiliitis with cartilage destruction and bony erosions followed by ascending inflammation of the vertebral apophysis and entheses. In the vertebral body, this inflammation leads to erosions where the annulus fibrosis of the intervertebral disk inserts, creating squared vertebrae with “shiny corners,” known as Romanov lesions [7]. Inflammation is also seen in the form of synovitis at the zygapophyseal joints. Unlike rheumatoid arthritis, in which inflammation primarily leads to bony erosion, in ankylosing spondylitis, it leads to bone formation in the form of enthesophytes and syndesmo-phytes. The former are bony outgrowths at the entheses,

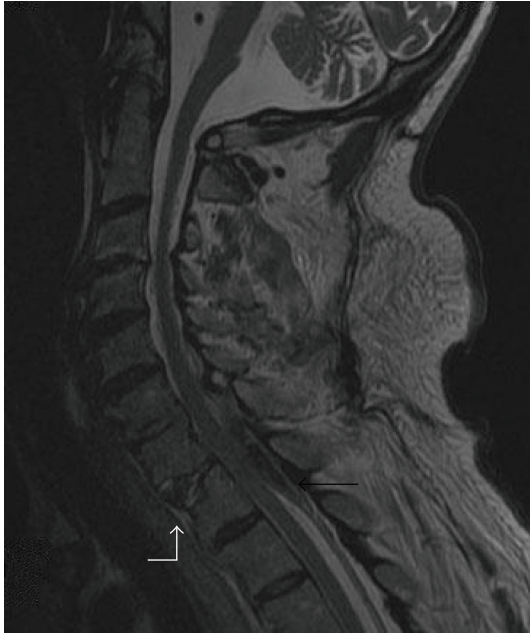

FIGURE 1: Sagittal magnetic resonance imaging delineating a posterior epidural hematoma (black arrow) accompanying a cervicothoracic fracture dislocation (white arrow).

while the latter form bridges between vertebrae [7]. Calcification of the longitudinal ligaments further restricts normal spinal movement resulting in the classic “bamboo spine” appearance. This rigid spine functions like a long bone and is one key factor predisposing AS patients to spinal fractures.

### 3. Fractures

Spinal fractures are up to four times more common in patients with ankylosing spondylitis than the general population, with a lifetime incidence ranging from 5% to 15% [7, 8]. Fractures in this population have a high incidence of neurologic complications, with spinal cord injury at initial presentation in two-thirds of patients sustaining a traumatic fracture in one large review [8]. Spinal cord injury can result from a number of causes, including dislocation or initial bony displacement, epidural hematoma (Figure 1), buckling of the ossified ligamentum flavum, or disk herniation [7, 9, 10]. Diagnosis may be delayed in many cases, which in turn increases the risk of neurologic deterioration before definitive management; up to 15% of patients have a secondary deterioration of neurologic status [8, 11]. Overall, the incidence of spinal cord injury in AS patients is approximately eleven times higher than the general population [12].

Mortality risk is also significantly increased in AS patients following traumatic spinal fracture when compared to the general population. The mortality rate ranges from 18 to 32% in various series [8, 9]. The most frequent cause of death both in the acute phase and at later followup is respiratory complications such as pneumonia; this is likely potentiated by preexisting pulmonary pathology, discussed in further detail below. Advanced age is the most important predictor

of patient mortality, with greater number of comorbidities and a lower mechanism of injury being contributing factors as well. Surprisingly, concomitant spinal cord injury has not been shown to have a correlation with mortality in these patients [9].

Spinal fractures in patients with Ankylosing Spondylitis frequently result from a low-energy mechanism, such as a fall from standing height. The susceptibility to fracture after a trivial injury is due to a variety of factors. In AS, ossification of the spinal ligaments and calcification of the annulus fibrosis alter the biomechanics of the spine, creating long lever arms limiting the ability to absorb even minor impacts [9, 11]. Osteoporosis stemming from stress shielding, immobility, and increased bony resorption also contributes to risk of fracture for both the young and the older AS patient population [3, 13, 14]. AS patients also have an amplified risk of sustaining falls due to altered gait, impaired balance, and compromised horizontal gaze secondary to fixed spinal deformity. Additional risk factors for fracture in this population are advanced age, longer disease duration, progressive kyphosis, and alcohol use [11].

Most acute spinal fractures in the AS population occur in the cervical spine (81.2%), particularly at C5-C6 and C6-C7 [8, 9]. This region is particularly susceptible to injury because of oblique facet joints, proximity to the weight of the head, and its location at the junction of a fused thoracic area with a more mobile head and neck [8]. Approximately 75% of these fractures are a hyperextension mechanism, largely due to preexisting kyphotic deformity that makes a patient more susceptible to an extension moment. Other patterns include flexion-type, rotation-type, and acute compression fractures [8, 9]. Many fractures pass through the intervertebral disk as opposed to the vertebral body, as the disk's elasticity is decreased and the annulus is calcified [11, 15]. The vast majority of these injuries are 3-column injuries resulting in an unstable spine.

### 4. Cervical Fractures

The subaxial cervical spine is the most frequent site for acute spinal fractures in Ankylosing Spondylitis [8]. Cervical fractures in AS patients are considered highly unstable with an increased risk for neurologic deficits (29%–91%) and nearly twice the mortality rate (35%) of the normal population [16–19]. Unfortunately, this diagnosis can frequently be missed or delayed. Patients often present late in the course as they cannot distinguish the pain of an acute fracture from their chronic inflammatory pain. Moreover, on initial evaluation, the fracture may not be detectable with plain radiographs alone due to preexisting kyphotic deformity with distorted anatomy, and high-riding shoulders (Figure 2(a)) that can obscure the lower cervical spine. In a retrospective review by Anwar et al., 60% of cervical fracture dislocations were undetectable on initial radiographs [11]. For this reason, there is a low threshold for obtaining advanced imaging (CT or MRI) in AS patients with a suspected cervical spine injury (Figures 2(b) and 2(c)). Modern, multidetector CT scans with reformats may have increased sensitivity

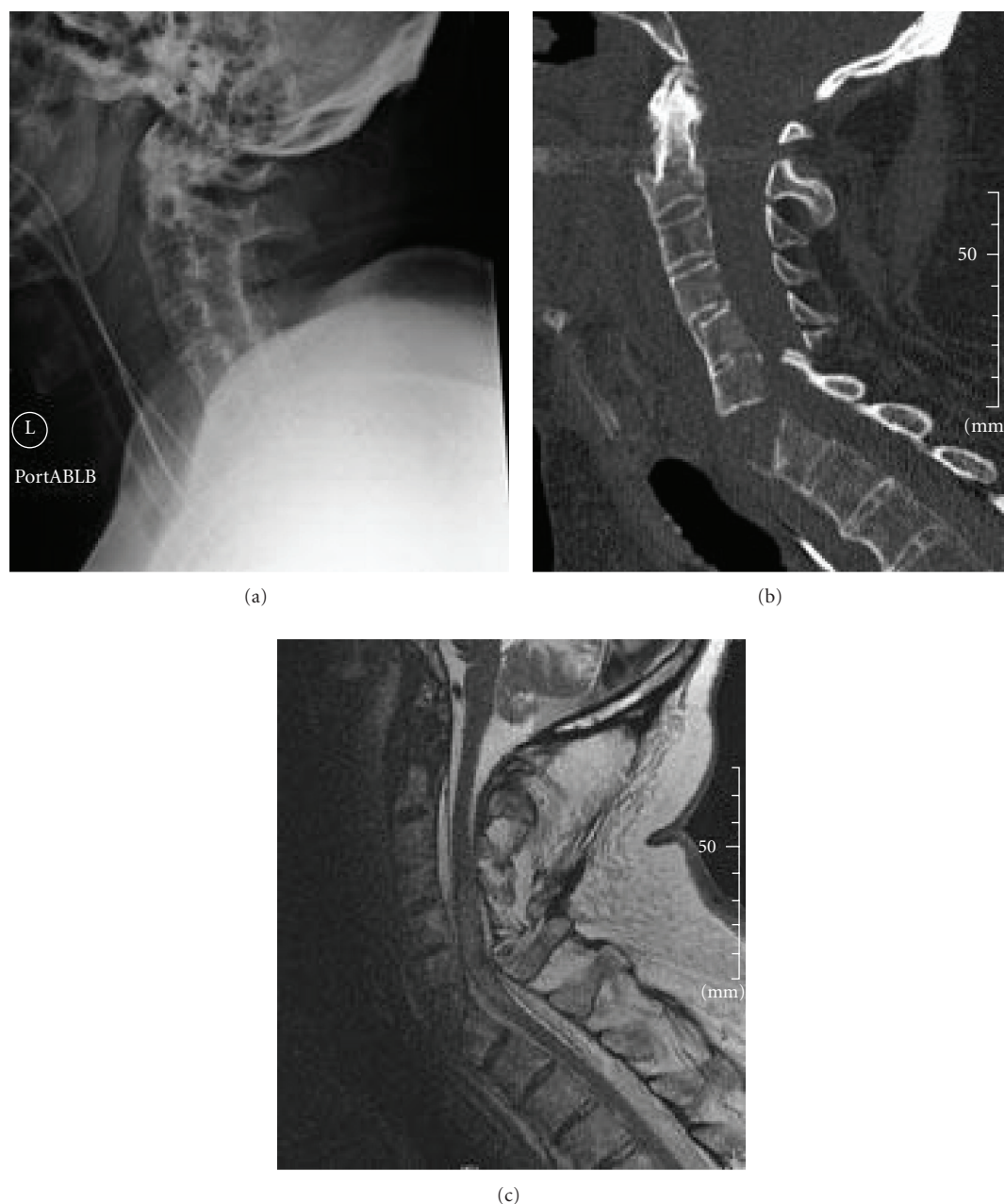

FIGURE 2: (a) Lateral C-spine X-ray providing an incomplete evaluation of the cervicothoracic junction and failing to delineate the fracture due to high-riding shoulders and kyphotic deformity. (b) Sagittal reconstruction of the computed tomographic scan of a 75-year-old male with a displaced extension-type fracture through the subaxial cervical spine. (c) Sagittal magnetic resonance image of the same patient demonstrating compression and edema of the spinal cord due to the displaced fracture.

for detecting subtle fractures compared with conventional single-detector CT scans [20]. In some patients, pronounced preexisting kyphotic deformity may preclude their ability to fit in a closed MRI scanner.

Once the cervical injury is recognized, it is imperative to determine the patient's preinjury alignment. Nearly 50% of patients with ankylosing spondylitis have some degree of preexisting fixed hyperkyphosis due in part to chronic inflammatory changes with wedging of vertebral bodies and microfractures [21]. It is important to consider this before

initial C-spine immobilization for suspected cervical fractures. Traditional collars may cause hyperextension through the fracture site, worsening the deformity and increasing the risk of a spinal cord injury [22, 23].

In a controlled environment and under the direction of a trained spinal surgeon, any significant displacement or malalignment of the cervical fracture warrants gentle low-weight traction for realignment. The goal is to recreate the preinjury alignment, which is generally in some degree of kyphosis. Thus, the force vector should be directed anteriorly

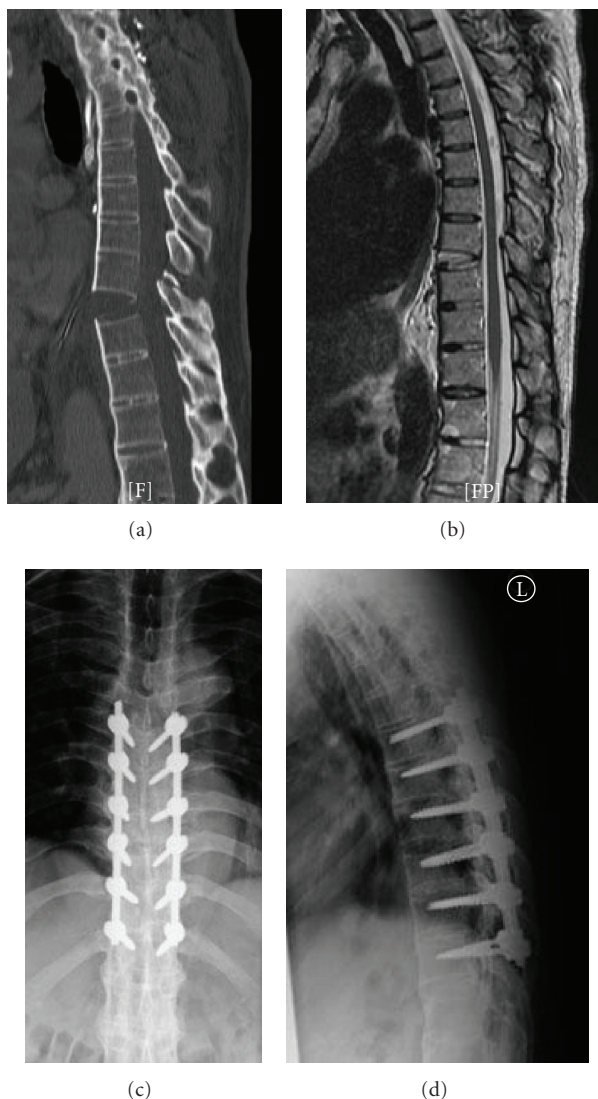


FIGURE 3: Sagittal computed tomography (a) and magnetic resonance image (b) of a 40-year-old male with an extension injury through the T9-10 disc extending posteriorly into the T9 posterior elements. Postoperative anteroposterior (c) and lateral (d) radiographs after realignment and posterior instrumented fusion.

and superiorly [24, 25]. The extent of fracture instability coupled with longstanding deconditioning of the paraspinal musculature leads these fractures to be easily over-distracted [10]. Consequently, the axial traction utilized to realign the spine should generally not exceed 5 to 10 pounds in these patients; any residual or uncorrectable deformity may be managed with intraoperative reduction [15, 24, 25]. The head and upper back may need to be supported by pillows or foam wedges to help maintain the alignment achieved by the low-weight traction.

## 5. Thoracolumbar Fractures

Thoracolumbar fractures are significantly less common than cervical fractures in patients with ankylosing spondylitis. A majority of these fractures occur at the thoracolumbar junction. Trent et al. originally classified these fractures into three

types: shearing injury, wedge compression, or pseudarthrosis from chronic nonunion. Typically, the shearing injuries are seen acutely; compression fractures generally have a chronic presentation while pseudarthrosis can be seen subacutely after a missed fracture or in patients with microfractures leading to fibrosis [26].

The “shearing” pattern as described by Trent can be subdivided into two fracture patterns: a distractive-flexion injury, comparable to a Chance fracture, or a distractive-extension injury. In one small series, the majority of TL fractures in ankylosing spondylitis were extension-type [27]; however, there are no large-scale reviews evaluating these types of fractures. Most of these injuries are highly unstable, traversing across all three columns [26–28] and often require surgical treatment (Figure 3). The forces acting across the fracture site are drastically increased by the long lever arms of the fused thoracic and the lumbar spine segments. This is

further potentiated at the thoracolumbar junction due to the sheer weight of the thorax above. Extreme caution must be exercised with regard to patient positioning and transfers of AS patients with shear fractures, especially in patients with a preexisting kyphotic deformity. Supine positioning in such patients will create an extension deformity across the fracture site by placing pressure at the apex of the kyphosis and can result in significant neurologic injury. Therefore, the entire body must be supported at all times until stabilization is achieved, particularly during advanced imaging, when the patient is traditionally laying flat [26]. Despite the unstable nature of these injuries, the risk of neurologic deficit is lower when compared to the cervical fractures; incidence ranges from 33% to 50% [9, 27].

The wedge compression type or the pseudarthrosis type of fractures though seen subacutely or chronically in the AS population, must also be assessed critically and regularly. It is important to note that these fracture types may present with an acute-on-chronic onset of pain and an increasing kyphotic deformity. Progressive pain and deformity may ultimately cause significant disability requiring surgical management. When evaluating these injuries, it is important to rule out posterior element involvement, which would render these fractures unstable.

Associated visceral injuries, although rare, must also be considered during the management of thoracolumbar fractures in patients with ankylosing spondylitis. Preexisting spinal deformity combined with elastic tissue dysfunction creates the potential for visceral adhesions and injuries with fracture displacement. Case reports of rare intrathoracic complications including tracheal rupture and aortic laceration or dissection in AS patients have been cited in the literature [8]. Ankylosing spondylitis is associated with inflammation and adventitial scarring of the aorta, which then can become tethered to the anterior longitudinal ligament and thus subjected to shearing forces in an acute trauma [8, 29].

## 6. Treatment Considerations

The course of management is determined by both the fracture pattern and the patient's overall medical status. Patients with ankylosing spondylitis often have medical comorbidities, including aortic insufficiency, cardiac conduction abnormalities, uveitis, and pulmonary disease. The inflammatory process leads to ankylosing of the spinal motion segments and the costovertebral joints. Ultimately, a fixed kyphotic thoracic spine along with an ankylosed noncompliant ribcage propagates a restrictive lung disease pattern in this population. Furthermore, AS patients are also prone to developing pulmonary fibrosis late in the disease [29, 30].

Treatment options range from external orthoses to traction, halo vest placement, or surgical management. Stable fracture patterns are amenable to a more conservative approach, such as mobilization in a cervical collar or a clamshell thoracolumbosacral orthosis (TLSO) [8, 9, 27]. Again, it is imperative to be mindful of any preexisting kyphosis

when fitting these patients with external orthoses. Nonoperative treatment requires a close and frequent followup to ensure the maintenance of appropriate spinal alignment as fracture displacement despite brace immobilization may necessitate a surgical intervention.

Unstable fracture patterns with displacement may initially need low-weight traction to restore the preinjury alignment and relieve neurologic compression. While in the past this was sometimes used as definitive management, currently the treatment for unstable fracture patterns is either halo placement or surgical management. Definitive surgical indications, assuming a medically optimized patient, include deteriorating neurologic status, irreducible deformity, and presence of an epidural hematoma or another source of spinal cord compression [3, 10, 15]. Surgical management in this population has an increased rate of neurologic recovery compared to nonsurgical treatment [3, 8, 15].

Historically, the management of unstable fractures without a neurologic deficit, or the treatment of stable injuries with a mild neurologic deficit, was not well defined. Early series showed high rates of morbidity and mortality with surgical management, and consequently some authors recommended nonsurgical management, such as halo placement for these patients [10, 31]. A well-recognized benefit of halo management is the ability to gradually correct the severely kyphotic malalignment in patients with ankylosing spondylitis [10]. However, there is increasing evidence that AS patients have a higher complication rate when treated nonsurgically versus surgically. Noted complications of nonoperative halo stabilization include pin protrusion through the skull, intracerebral hemorrhage [32], nonunion, and a high redislocation rate (up to 35%) [10]. Halo treatment can also result in a high mortality rate, especially for the elderly population. Caron et al., in their large retrospective review, showed a mortality rate of 51% in the nonoperative group versus 23% in the operative group with age > 70 being a major risk factor [9].

## 7. Surgical Management

A multidisciplinary team approach with a thorough preoperative plan is essential for good outcomes in the high-risk AS patients. Patients may have preexisting pulmonary disease requiring evaluation and optimization by the pulmonary service. The anesthesia team should be aware of the cervical kyphotic deformity, as well as the location of the fracture; attempts to hyperextend the neck will either be restricted or will cause extension through the fracture resulting in neurologic embarrassment. Either nasotracheal intubation or fiberoptic intubation can be utilized instead of traditional methods [25]. Patients may also have a significant soft tissue injury, accompanying the fracture that could predispose them to wound healing complications, and a perioperative plastic surgery consultation may be appropriate to help manage skin necrosis and wound closure. Surgical positioning must be modified to accommodate for the preexisting spinal deformity and ensure support in all regions.

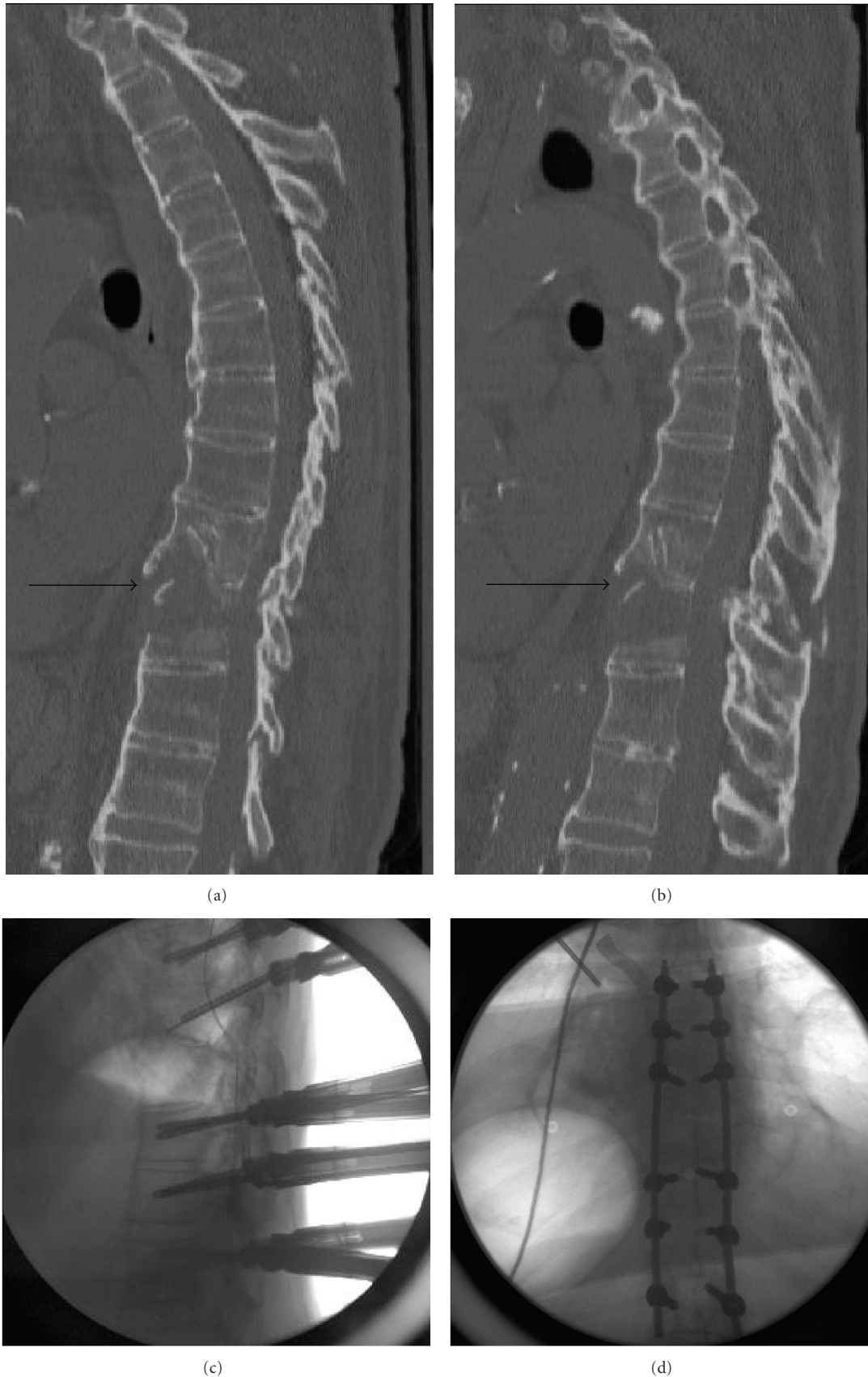


FIGURE 4: Sagittal computed tomography (a) and (b) of an octogenarian male with a distractive-extension injury through the T9-10 disc (black arrow) with anterior column deficiency due to osteoporosis and fracture extension into posterior elements. Intraoperative lateral (c) and anteroposterior (d) fluoroscopy depicting percutaneous fixation of the unstable thoracic fracture dislocation in an octogenarian with multiple medical comorbidities.

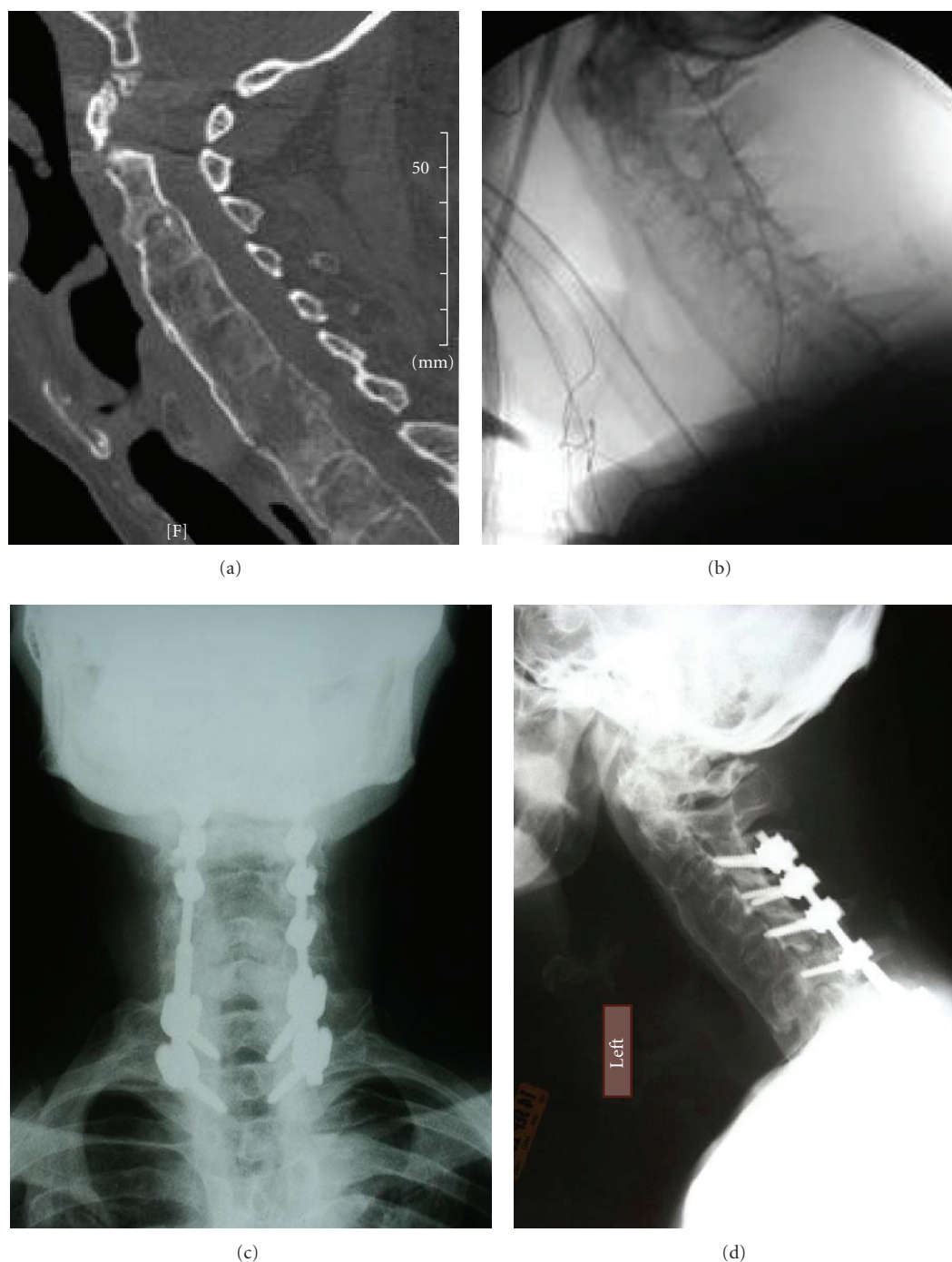


FIGURE 5: (a) Sagittal-reconstruction computed tomography demonstrating a nondisplaced shear fracture through the C6 vertebral body and C5 posterior elements. (b) Intraoperative fluoroscopy performed after the patient was positioned prone to confirm maintenance of his preexisting alignment. Postoperative anteroposterior (c) and lateral (d) X-ray demonstrating posterior C3-T2 fusion with lateral mass fixation in the cervical spine and pedicle screw fixation in the upper thoracic spine.

The surgical approach depends both on patient characteristics as well as fracture location and pattern. Given the frequent cardiopulmonary comorbidities in AS patients, an anterior-posterior (360°) procedure increases the surgical time and the likelihood of morbidity and mortality. Therefore, a deliberate preoperative evaluation of the fracture

pattern, posterior ligamentous restraint, neurologic compression and function, preexisting deformity, and bone quality must be performed. Often these injuries are managed by a single posterior approach. In the medically tenuous patients, staged procedures with minimally invasive fixation techniques using percutaneous screw fixation should

be considered for initial and immediate stability across an unstable fracture followed by a formal open fusion procedure (Figure 4).

If the anterior column is competent for load-bearing and indirect anterior bony apposition can be obtained, a posterior-only approach is reasonable [15, 30]. Decompressive laminectomy should be undertaken if there is evidence of spinal cord compression on imaging or if there has been neurologic deterioration [3, 15]. It is critical to obtain sound bony fixation and stability along with a good fusion bed. Bone graft options for the fusion include local bone from decompression, autologous rib harvest, or iliac crest bone graft. A rib harvest theoretically increases the risk of pulmonary complications and should only be considered if an anterior transthoracic approach is necessary although Taggard and Traynelis found no such correlation in their series [30]. Iliac crest bone graft is usually considered the gold standard; however, it may limit the patients' postoperative mobilization, potentially leading to pulmonary and other complications [15]. Allograft bone and bone graft extenders can also be employed to enhance fusion. Osteoporosis combined with abnormally increased forces across the fracture site from the long lever arms of the ankylosed spine segments can result in construct failure and screw pull-out. Therefore, multiple points of fixation both above and below the fracture site are required. For injuries in the lower cervical spine, this can be accomplished by lateral mass screws up to the C-3 level. In some cases, pedicle screws at the C-2 level may be required. Distal fixation in the thoracic spine can be accomplished with pedicle screws for three-column purchase (Figure 5). Strong consideration must be given to using a thicker rod diameter or a stiffer rod material, that is, cobalt chrome or stainless steel when the reconstruction spans the cervicothoracic junction. Screw augmentation with polymethylmethacrylate (PMMA) may prevent screw pullout.

A biomechanically sound fixation construct should not only prevent future displacement at the fracture site, but also aim to improve the spinal deformity and sagittal balance. Recently, there have been published reports of cases in which preexisting kyphotic deformity is corrected in conjunction with stabilization of an acute fracture [15, 25]. Kanter et al. noted that the correction of the cervico-thoracic kyphotic deformity ("chin-on-chest" deformity) can be accomplished by performing a traditional wedge osteotomy at the C7-T1 level in these patients [15]. Meanwhile, Schneider et al. described a different technique to acutely correct preexisting chin-on-chest deformity via an extension osteotomy through the cervical fracture site, using a halo to gradually obtain correction intraoperatively under continuous neuro-monitoring [25]. Thoracolumbar kyphotic deformities in AS patients with fractures can similarly be managed with wedge osteotomies, instrumentation, and bone grafting [26, 33]. Notwithstanding these case reports, the current standard of care is to maintain the preexisting position of kyphosis during acute fracture management, followed by an elective extension osteotomy for deformity correction to avoid neurologic injury.

Postoperatively, immobilization may be obtained either with a halo-vest orthosis or via an external orthosis. Prior to

10 years ago, immobilization was frequently undertaken with a halo vest [24, 33]; however, more recently, external braces have been used with low rates of failure [3, 30]. Regardless of the mode used, it is imperative to expedite out-of-bed activity and initiate rapid mobility in the early postoperative course to minimize pulmonary complications.

## 8. Conclusion

Patients with ankylosing spondylitis have a higher incidence of acute spinal fractures than the general population due to osteoporotic bone, spinal rigidity, and problems with balance and forward gaze. Fractures most commonly occur in the cervical spine followed by the thoracolumbar junction, with a hyperextension or flexion pattern traversing all three columns. There is frequently a delay in diagnosis, with a concomitant risk of neurologic deterioration. As a rule, patients with ankylosing spondylitis presenting even with a trivial history of trauma should be critically evaluated for acute spinal fractures using advanced imaging modalities (CT or MRI). These fractures are often unstable, and care must be taken to maintain the preexisting kyphotic alignment during patient positioning and transfers to minimize iatrogenic neurologic injuries. Fracture complications in the AS patient population are high, with upwards of 65% sustaining neurologic injury and a mortality rate reaching 15% to 30%. Surgical management should be undertaken in patients with unstable fracture patterns, progressive kyphosis, or neurologic deterioration. Surgical treatment commonly involves posterior instrumentation and bone grafting, with decompression if indicated. Neurologic improvement is more common in patients who undergo surgery, but postoperative respiratory complications are common.

## References

- [1] J. Braun and J. Sieper, "Ankylosing spondylitis," *Lancet*, vol. 369, no. 9570, pp. 1379–1390, 2007.
- [2] M. A. Brown, "Progress in spondylarthritis. Progress in studies of the genetics of ankylosing spondylitis," *Arthritis Research & Therapy*, vol. 11, no. 5, p. 254, 2009.
- [3] G. Sapkas, K. Kateros, S. A. Papadakis et al., "Surgical outcome after spinal fractures in patients with ankylosing spondylitis," *BMC Musculoskeletal Disorders*, vol. 10, no. 1, article 96, 2009.
- [4] J. A. Finkelstein, J. R. Chapman, and S. Mirza, "Occult vertebral fractures in ankylosing spondylitis," *Spinal Cord*, vol. 37, no. 6, pp. 444–447, 1999.
- [5] H. S. Goei The, M. M. Steven, S. M. van der Linden, and A. Cats, "Evaluation of diagnostic criteria for ankylosing spondylitis: a comparison of the Rome, New York and modified New York criteria in patients with a positive clinical history screening test for ankylosing spondylitis," *British Journal of Rheumatology*, vol. 24, no. 3, pp. 242–249, 1985.
- [6] M. Rudwaleit, "New approaches to diagnosis and classification of axial and peripheral spondyloarthritis," *Current Opinion in Rheumatology*, vol. 22, no. 4, pp. 375–380, 2010.
- [7] M. L. Mundwiler, K. Siddique, J. M. Dym, B. Perri, J. P. Johnson, and M. H. Weisman, "Complications of the spine in ankylosing spondylitis with a focus on deformity correction," *Neurosurgical Focus*, vol. 24, no. 1, article E6, 2008.

- [8] L. A. Westerveld, J. J. Verlaan, and F. C. Oner, "Spinal fractures in patients with ankylosing spinal disorders: a systematic review of the literature on treatment, neurological status and complications," *European Spine Journal*, vol. 18, no. 2, pp. 145–156, 2009.
- [9] T. Caron, R. Bransford, Q. Nguyen, J. Agel, J. Chapman, and C. Bellabarba, "Spine fractures in patients with ankylosing spinal disorders," *Spine*, vol. 35, no. 11, pp. E458–E464, 2010.
- [10] D. W. Rowed, "Management of cervical spinal cord injury in ankylosing spondylitis: the intervertebral disc as a cause of cord compression," *Journal of Neurosurgery*, vol. 77, no. 2, pp. 241–246, 1992.
- [11] F. Anwar, A. Al-Khayer, G. Joseph, M. H. Fraser, M. V. Jigajinni, and D. B. Allan, "Delayed presentation and diagnosis of cervical spine injuries in long-standing ankylosing spondylitis," *European Spine Journal*, vol. 20, no. 3, pp. 403–407, 2011.
- [12] W. B. Jacobs and M. G. Fehlings, "Ankylosing spondylitis and spinal cord injury: origin, incidence, management, and avoidance," *Neurosurgical Focus*, vol. 24, no. 1, article E12, 2008.
- [13] M. Magrey and M. A. Khan, "Osteoporosis in ankylosing spondylitis," *Current Rheumatology Reports*, vol. 12, no. 5, pp. 332–336, 2010.
- [14] V. Vasdev, D. Bhakuni, M. K. Garg, K. Narayanan, R. Jain, and D. Chadha, "Bone mineral density in young males with ankylosing spondylitis," *International Journal of Rheumatic Diseases*, vol. 14, no. 1, pp. 68–73, 2011.
- [15] A. S. Kanter, M. Y. Wang, and P. V. Mummaneni, "A treatment algorithm for the management of cervical spine fractures and deformity in patients with ankylosing spondylitis," *Neurosurgical Focus*, vol. 24, no. 1, article E11, 2008.
- [16] D. Vosse, E. Feldtkeller, J. Erlendsson, P. Geusens, and S. van der Linden, "Clinical vertebral fractures in patients with ankylosing spondylitis," *Journal of Rheumatology*, vol. 31, no. 10, pp. 1981–1985, 2004.
- [17] B. Graham and P. K. Van Peteghem, "Fractures of the spine in ankylosing spondylitis. Diagnosis, treatment and complications," *Spine*, vol. 14, no. 8, pp. 803–807, 1989.
- [18] A. Fast, S. Parikh, and E. L. Marin, "Spine fractures in ankylosing spondylitis," *Archives of Physical Medicine and Rehabilitation*, vol. 67, no. 9, pp. 595–597, 1986.
- [19] M. W. Fox, B. M. Onofrio, and J. E. Kilgore, "Neurological complications of ankylosing spondylitis," *Journal of Neurosurgery*, vol. 78, no. 6, pp. 871–878, 1993.
- [20] J. S. Harrop, A. Sharan, G. Anderson et al., "Failure of standard imaging to detect a cervical fracture in a patient with ankylosing spondylitis," *Spine*, vol. 30, no. 14, pp. E417–E419, 2005.
- [21] D. Vosse, D. van der Heijde, R. Landewé et al., "Determinants of hyperkyphosis in patients with ankylosing spondylitis," *Annals of the Rheumatic Diseases*, vol. 65, no. 6, pp. 770–774, 2006.
- [22] E. W. Bergmann, "Fractures of the ankylosed spine," *Journal of Bone and Joint Surgery—Series A*, vol. 31, no. 3, pp. 669–671, 1949.
- [23] A. Clarke, S. James, and S. Ahuja, "Ankylosing spondylitis : inadvertent application of a rigid collar after cervical fracture, leading to neurological complications and death," *Acta Orthopaedica Belgica*, vol. 76, no. 3, pp. 413–415, 2010.
- [24] K. N. Detwiler, C. M. Loftus, J. C. Godersky, and A. H. Meneses, "Management of cervical spine injuries in patients with ankylosing spondylitis," *Journal of Neurosurgery*, vol. 72, no. 2, pp. 210–215, 1990.
- [25] P. S. Schneider, J. Bouchard, K. Moghadam, and G. Swamy, "Acute cervical fractures in ankylosing spondylitis: an opportunity to correct preexisting deformity," *Spine*, vol. 35, no. 7, pp. E248–E252, 2010.
- [26] G. Trent, G. W. D. Armstrong, and J. O'Neil, "Thoracolumbar fractures in ankylosing spondylitis: high-risk injuries," *Clinical Orthopaedics and Related Research*, no. 227, pp. 61–66, 1988.
- [27] P. W. Hitchon, A. M. From, M. D. Brenton, J. A. Glaser, and J. C. Torner, "Fractures of the thoracolumbar spine complicating ankylosing spondylitis," *Journal of Neurosurgery*, vol. 97, no. 2, pp. 218–222, 2002.
- [28] M. I. Gelman and J. S. Umber, "Fractures of the thoracolumbar spine in ankylosing spondylitis," *American Journal of Roentgenology*, vol. 130, no. 3, pp. 485–492, 1978.
- [29] G. S. Firestein and W. B. Saunders, *Kelley's Textbook of Rheumatology*, 8th edition, 2008.
- [30] D. A. Taggard and V. C. Traynelis, "Management of cervical spinal fractures in ankylosing spondylitis with posterior fixation," *Spine*, vol. 25, no. 16, pp. 2035–2039, 2000.
- [31] A. Grisolia, R. L. Bell, and L. F. Peltier, "Fractures and dislocations of the spine complicating ankylosing spondylitis. A report of six cases," *Journal of Bone and Joint Surgery—Series A*, vol. 49, no. 2, pp. 339–344, 1967.
- [32] J. Schröder, U. Liljenqvist, C. Greiner, and H. Wassmann, "Complications of halo treatment for cervical spine injuries in patients with ankylosing spondylitis—Report of three cases," *Archives of Orthopaedic and Trauma Surgery*, vol. 123, no. 2-3, pp. 112–114, 2003.
- [33] M. W. Fox, B. M. Onofrio, and J. E. Kilgore, "Neurological complications of ankylosing spondylitis," *Journal of Neurosurgery*, vol. 78, no. 6, pp. 871–878, 1993.

