

## Retraction

# Retracted: Study of Subfascial Endoscopic Perforator Surgery Combined with Endovenous Laser Treatment in the Treatment of Great Saphenous Varicose Veins

### Journal of Healthcare Engineering

Received 10 October 2023; Accepted 10 October 2023; Published 11 October 2023

Copyright © 2023 Journal of Healthcare Engineering. This is an open access article distributed under the Creative Commons Attribution License, which permits unrestricted use, distribution, and reproduction in any medium, provided the original work is properly cited.

This article has been retracted by Hindawi following an investigation undertaken by the publisher [1]. This investigation has uncovered evidence of one or more of the following indicators of systematic manipulation of the publication process:

- (1) Discrepancies in scope
- (2) Discrepancies in the description of the research reported
- (3) Discrepancies between the availability of data and the research described
- (4) Inappropriate citations
- (5) Incoherent, meaningless and/or irrelevant content included in the article
- (6) Peer-review manipulation

The presence of these indicators undermines our confidence in the integrity of the article's content and we cannot, therefore, vouch for its reliability. Please note that this notice is intended solely to alert readers that the content of this article is unreliable. We have not investigated whether authors were aware of or involved in the systematic manipulation of the publication process.

In addition, our investigation has also shown that one or more of the following human-subject reporting requirements has not been met in this article: ethical approval by an Institutional Review Board (IRB) committee or equivalent, patient/participant consent to participate, and/or agreement to publish patient/participant details (where relevant).

Wiley and Hindawi regrets that the usual quality checks did not identify these issues before publication and have since put additional measures in place to safeguard research integrity.

We wish to credit our own Research Integrity and Research Publishing teams and anonymous and named external researchers and research integrity experts for contributing to this investigation.

The corresponding author, as the representative of all authors, has been given the opportunity to register their agreement or disagreement to this retraction. We have kept a record of any response received.

### References

- [1] L. Wang, J. Du, and H. Zhang, "Study of Subfascial Endoscopic Perforator Surgery Combined with Endovenous Laser Treatment in the Treatment of Great Saphenous Varicose Veins," *Journal of Healthcare Engineering*, vol. 2022, Article ID 1801099, 7 pages, 2022.

## Research Article

# Study of Subfascial Endoscopic Perforator Surgery Combined with Endovenous Laser Treatment in the Treatment of Great Saphenous Varicose Veins

Li Wang, Jianqing Du, and Hong Zhang 

*Vascular and General Surgery, Affiliated Hospital of Chengde Medical University, Chengde 067000, China*

Correspondence should be addressed to Hong Zhang; [cdzh1977@163.com](mailto:cdzh1977@163.com)

Received 4 March 2022; Revised 3 April 2022; Accepted 7 April 2022; Published 16 April 2022

Academic Editor: Hangjun Che

Copyright © 2022 Li Wang et al. This is an open access article distributed under the Creative Commons Attribution License, which permits unrestricted use, distribution, and reproduction in any medium, provided the original work is properly cited.

Great saphenous varicose vein (GSVV) is a venous reflux disease of the lower extremity. In order to explore the clinical effect of subfascial endoscopic perforator surgery (SEPS) with endovenous laser treatment (EVL) in the treatment of GSVV, 80 patients who underwent unilateral saphenous varicose surgery are analyzed. The operation results show that the patients who used SEPS + EVLT have less operation time and mean blood loss, shorter postoperative active time and hospitalization stay, better curative effect, and higher notch aesthetics ( $P < 0.05$ ). SEPS combined with EVLT has a remarkable curative effect in the treatment of saphenous varicose veins of lower extremity, which can significantly shorten the hospitalization time of patients and improve the coagulation index and stress index.

## 1. Introduction

GSVV is a venous reflux disease of the lower extremity that is caused by the inability of the deep venous valve to close tightly. GSVV can manifest as superficial varicose veins, segmental cystic, or columnar dilatation of the main or branch of the veins, as well as lower extremity swelling, pain, hyperpigmentation, pruritus, and even ulceration [1, 2]. Factors that can cause increased intraabdominal pressure such as smoking, long-term standing, or sedentary are all risk factors for saphenous varicose veins [3]. Relevant literature reports that the prevalence of GSVV in women is higher than that in men, with prevalence rates ranging from 10% to 15% and 20% to 25%, respectively [4, 5]. If GSVV is not treated in time, complications such as superficial thrombophlebitis, venous heart ulcer, and variceal bleeding can occur, which seriously affect the work and life of patients [6].

Surgery is the main method for the treatment of GSVV. Through surgery, it can help patients restore the venous valve closure function as much as possible and

inhibit venous blood backflow, thereby, improving venous hypertension and blood stasis, quickly relieving patients' symptoms and signs, and helping patients restore the function of the affected limb. High saphenous vein ligation is an effective method for the treatment of GSVV, which can completely strip the diseased saphenous vein, but it will cause great trauma to the surrounding tissue during the stripping process, and it is easy to damage the saphenous nerve and cause postoperative paresthesia [7, 8]. In addition, the residual vascular bed after high ligation is prone to accumulation of blood and fluid, and the incision often affects the appearance. With the improvement of medical technology, the treatment of GSVV has gradually entered the era of minimally invasive beauty. Subfascial endoscopic perforator surgery (SEPS) is to cut the skin to the deep fascia and ligate the communicating vein under the guidance of direct vision. SEPS has the advantages of simple operation, small trauma, clear visual field, low recurrence rate, and good curative effect. Endovenous laser treatment (EVL) is also one of the minimally invasive methods of endovenous treatment.

The principle of treatment is to use the thermal effect released by the laser to damage the venous endothelium, damage the vein wall, and deposit thrombosis to occlude the varicose vein, which in turn obliterates the vena cava [9, 10]. At present, most patients in clinical practice generally require combined treatment due to etiology, symptoms, severity, and other reasons.

The rest of this study is organized as follows: Section 2 discusses related work and analysis, followed by the clinical treatment methods and evaluation indicators in Section 3. Comparative analysis and data statistics are given in Section 4. Section 5 concludes the study with summary and future research directions.

## 2. Related Work

Under the guidance of previous studies related to minimally invasive surgery, this study used SEPS combined with EVLT to treat patients with unilateral GSVV. Comparing the changes in perioperative indicators with traditional surgery, more comprehensive data for the treatment of GSVV can be supported.

With the progression of the GSVV, it can also lead to skin pigmentation, eczema, and ulcers, and effective treatment should be implemented in time to relieve the pain of the patients [11, 12]. Surgical therapy can change the local hemodynamic state from the anatomical level and prevent the pathological process. It is the main way of clinical treatment of severe saphenous varicose veins. With the further development of minimally invasive technology and equipment, a series of minimally invasive procedures have been gradually applied in clinical practice.

The traditional communicating branch vein ligation is a destructive treatment method, which requires high segmental dissection of the trunk of the great saphenous vein. In addition, multiple surgical incisions are required to ligate the communicating branch veins, and the intraoperative trauma is large, which may easily cause damage to the skin, veins, soft tissues, and nerves. These injuries increase patient distress and prolong postoperative active and hospitalization time. These injuries increase patient distress and prolong postoperative active and hospitalization. SEPS is performed by endoscopic ligation of the deep subfascial communicating branch vein, and its precise positioning can reduce unnecessary trauma, thereby shortening the time for patients to get out of postoperative active and hospitalization stay after surgery [13, 14]. It is found that SEPS can reduce the occlusion rate of the incidence of ulcers in patients after surgery. EVLT uses percutaneous puncture to occlude the superficial varicose vein under the action of cautery, which can preserve the normal saphenous vein and reduce the damage caused by ligation [15, 16]. Cavallini and other scholars believed that EVLT can reduce the risk of saphenofemoral valve regurgitation after ligation and stripping of the great saphenous vein [17]. The results of this study also show that compared with the patients who used traditional communicating branch ligation + EVLT, the patients who used SEPS + EVLT have more significant curative effects and higher notch aesthetics.

It is worth noting that surgical trauma can cause traumatic stress in the body and make blood in a hypercoagulable state, which is not conducive to the postoperative recovery of patients [18]. In this study, when comparing the coagulation indexes of patients during the perioperative period, it is found that the levels of PT and TT in the two groups postoperative are lower than preoperative, but the levels in the patients who used SEPS + EVLT are higher than those who used traditional communicating branch ligation + EVLT. When comparing the stress indicators of the two groups, it is found that contrast by preoperative, the levels of IL-6 and hs-CRP in the two groups are increased in postoperative, and the levels in the patients who used SEPS + EVLT are lower than those who used traditional communicating branch ligation + EVLT. Main serological manifestations of surgical trauma stress response in GSVV patients with elevated levels of IL-6 and hs-CRP after surgery. Elevated levels of IL-6 and hs-CRP can damage the vascular endothelial function of patients, promote platelet aggregation, affect the coagulation system of patients, and are not conducive to the recovery of postoperative limb skills [19, 20]. In addition, due to the hypercoagulability of blood in patients with GSVV, the body damage caused by surgery may aggravate the disorder of the coagulation system, resulting in abnormal changes in the levels of PT and TT.

## 3. Clinical Treatment Methods and Evaluation Indicators

**3.1. Research Object.** The data of 80 patients who underwent unilateral GSVV surgery from January 2019 to January 2021 are retrospectively analyzed. Patients are selected with the following rules: first, meet the relevant diagnostic criteria of GSVV and have been confirmed by imaging. Second, it is unilateral lesions. Third, clinical, etiological, anatomical, pathophysiological classification (CEAP) grade C5-C6. Finally, the data of preoperative examination, operation-related parameters, and postoperative reexamination are complete. Exclusion criteria are as follows: first, combined with other vascular diseases. Second, insufficiency of important organs. Third, venous vascular disease due to congenital factors. Fourth, combined with malignant tumors. Finally, the history of lower extremity venous surgery.

The number of patients in the study is 80. In the light of the surgical methods, the patients are divided into the control (traditional communicating branch ligation + EVLT) and the combine group (SEPS + EVLT).

**3.2. Therapeutic Methods.** The combined group is treated with SEPS + EVLT. The patient is placed in a supine position with the head loared and the feet high, the affected limb flexed and the knee is abducted by 130°, the hip joint is slightly externally rotated, and the knee is properly elevated. Routine sterile drape and anesthesia are performed. A transverse skin incision of about 1 cm in length is made 6 cm below the tibial tuberosity and 4 cm medial to the tibia, and the subcutaneous tissue is incised successively until the deep

fascia. The subfascial space is bluntly separated with the fingers, and the separation range is up to 5 cm medial to form an operating space.

Between the deep fascia and the muscularis layer along the incision, a laparoscopic system is placed, and CO<sub>2</sub> is filled under the fascia to maintain a pressure of 12 mmHg. Under the direct vision of the endoscope, a second incision with a length of about 0.5 cm is made at about 5 cm inside and about 3 cm below the original incision, and a Trocar and an ultrasonic scalpel are placed. Blunt dissection of the loose connective tissue is under the deep fascia, exposure of the communicating veins, and separation of communicating veins of varying thickness. The communicating veins are separated one by one using the ultrasonic scalpel, and the separation range is from the anterior border of the tibia to the midline, down to the Achilles tendon and medial malleolus, to avoid missing the communicating veins. The endoscopy system is withdrawn, the residual gas in the cavity is discharged, and the two surgical incisions are sutured intermittently.

An incision is made 2 cm anterior to the medial malleolus and a laser fiber is placed. An 18G trocar is used to puncture the great saphenous vein at the medial malleolus, and a 5F catheter dilator is introduced. The laser fiber is inserted into the 5F straight catheter and sent to the saphenofemoral vein, the catheter is retracted, and the fiber is pushed forward until the catheter is exposed 3 cm. Connect the semiconductor laser therapy instrument and adjust the laser wavelength to 810 nm and the laser emission power to 12–15 W. Using a continuous pulse method, the fiber is withdrawn and the laser is cauterized until the medial malleolus. The catheter and fiber are withdrawn slowly at the same time to close the vein wall. After the operation, the surgical area of the affected limb is compressed with an elastic bandage.

The control group is treated with traditional communicating branch vein ligation + EVLT: the patient position, EVLT treatment method, and postoperative treatment are the same as those in the combined group. Traditional communicating branch vein ligation: according to the preoperative color Doppler ultrasound to locate the surface markings of the communicating branch vein, the communicating branch vein is separated with a small incision and ligated in the superficial fascia layer.

**3.3. Observation Indexes.** Time of operation, mean bleeding volume, postoperative activity time, hospitalization time, and other related indicators are recorded. The operation time is from the start of anesthesia to the end of compression bandage with elastic bandage.

The clinical efficacy is evaluated according to the patients' lower extremity symptoms and vascular color Doppler ultrasonography 1 month after operation. The clinical symptoms basically disappeared, there is no obvious varicose veins, and the color ultrasound shows that there is no regurgitation in the great saphenous vein, and it is evaluated as curative. The clinical symptoms are significantly improved, slight varicose veins are seen, and the color ultrasound shows that the partial regurgitation of the great

saphenous vein is evaluated as effective. Patients with no improvement in clinical symptoms, obvious varicose veins, and regurgitation of the great saphenous vein still visible on vascular color ultrasound are evaluated as invalid.

The self-made incision satisfaction questionnaire is used to evaluate the patients' satisfaction with the notch aesthetics. The incision aesthetics score ranged 0–10, and the scores are proportional to satisfaction.

Some things are measured 1 day before surgery and 1 day and 3 days after surgery: prothrombin time (PT), thrombin time (TT), interleukin-6 (IL-6), and high-sensitive C-reactive protein (hs-CRP) levels.

**3.4. Statistical Methods.** SPSS 25.0 and GraphPad Prism 8.3 statistical software are used to analyze the research data. Qualitative data are expressed by frequency and percentage, and the chi-square test and rank sum test are performed. Quantitative data conforming to a normal distribution are expressed in the form of mean ± standard deviation, and the *t*-test is used.  $P < 0.05$  indicated that the difference is significant.

## 4. Comparative Analysis and Data Statistics

**4.1. Baseline Data.** The baseline data of patients with different treatment methods are compared before surgery, and it is found that there is no great difference in the baseline data of the two groups of patients ( $P > 0.05$ ). Table 1 provides the specific data.

**4.2. Patient Surgery-Related Indicators.** Comparing the operation-related indicators between the two groups, it is found that the time of operation, mean bleeding volume, postoperative active time, and hospitalization time of the patients who used SEPS + EVLT are lower than those who used traditional communicating branch ligation + EVLT ( $P < 0.05$ ), as given in Table 2.

**4.3. Curative Effect and Incision Aesthetics.** It can be seen from Table 3 that the results of the rank sum test indicated that the curative effect of the two groups of patients is significantly different. Table 3 provides the curative effect and incision.

The evaluation of the aesthetics of the incision in the two groups of patients and the patients who used SEPS + EVLT are significantly more satisfied with the aesthetics of the incision than the patients who used traditional communicating branch ligation + EVLT ( $P < 0.05$ ). Figure 1 shows the comparison of notch aesthetics. In Figure 1,  $*P < 0.05$ .

**4.4. Changes of Related Indexes of the Coagulation System during the Perioperative Period.** Comparing the changes of blood coagulation system-related indexes between the two groups, it is found that at 1 and 3 days postoperative, the levels of PT and TT in the two groups are lower than those preoperative, as given in Table 4.

The levels in the patients who used SEPS + EVLT are higher than those who used traditional communicating

TABLE 1: Baseline data of patients.

Baseline information	Control ( <i>n</i> = 40)	Combine ( <i>n</i> = 40)	<i>t</i> / $\chi^2$	<i>P</i>
Gender				
Male	14 (35.00)	17 (42.50)	0.474	0.491
Female	26 (65.00)	23 (57.50)		
Age	55.26 ± 5.93	56.31 ± 6.21	0.773	0.442
Disease duration (years)	6.09 ± 1.34	6.31 ± 1.28	0.751	0.455
BMI (kg/m <sup>2</sup> )	23.05 ± 0.97	22.98 ± 1.01	0.316	0.752
Affected limb				
Left	18 (45.00)	21 (52.50)	0.45	0.502
Right	22 (55.00)	19 (47.50)		
CEPA grade				
C5	31 (77.50)	29 (72.50)	0.267	0.606
C6	9 (22.50)	11 (27.50)		

TABLE 2: Surgery-related indicators of patients.

Group	Time of operation (min)	Mean bleeding volume (mL)	Postoperative activity time (d)	Hospitalization time (d)
Control ( <i>n</i> = 40)	92.13 ± 9.15	41.26 ± 7.59	5.84 ± 1.13	9.25 ± 1.31
Combine ( <i>n</i> = 40)	67.58 ± 8.06	19.26 ± 6.28	3.59 ± 0.95	6.74 ± 0.95
<i>t</i>	12.731	14.122	9.639	9.81
<i>P</i>	< 0.001	< 0.001	< 0.001	< 0.001

TABLE 3: Curative effect and incision aesthetics.

Group	Curative	Effective	Invalid	Notch aesthetics
Control ( <i>n</i> = 40)	15 (37.50)	18 (45.00)	7 (17.50)	7.31 ± 1.25
Combine ( <i>n</i> = 40)	22 (55.00)	17 (42.50)	1 (2.50)	8.14 ± 0.97
<i>Z</i> / <i>t</i>		-2.029		3.318

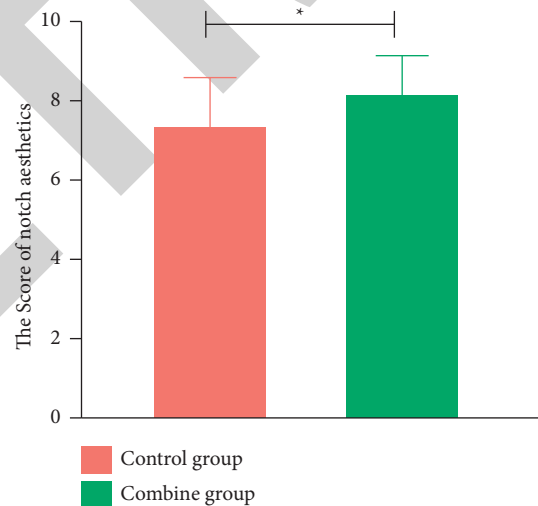


FIGURE 1: Comparison of notch aesthetics.

branch ligation + EVLT ( $P < 0.05$ ). Those results are plotted as a bar chart, as shown in Figure 2. In Figure 2,  $*P < 0.05$ .

4.5. *Changes in the Level of Stress Indicators.* Comparing the changes of stress indexes in the two groups, it is found that at 1 and 3 days postoperative, the levels of IL-6 and hs-CRP in the

two groups are increased compared with those preoperative. Table 5 provides the changes in the level of stress indicators.

The levels in the patients who used SEPS + EVLT are lower than those who used traditional communicating branch ligation + EVLT ( $P < 0.05$ ). Those results are plotted as a bar chart, as shown in Figure 3. In Figure 3,  $*P < 0.05$ .

TABLE 4: Changes of related indexes of the coagulation system during the perioperative period.

Index	Group	Preoperative 1 day	Postoperative 1 day	Postoperative 3 day
PT (s)	Control ( <i>n</i> = 40)	11.79 ± 1.29	8.16 ± 0.94	9.51 ± 0.98
	Combine ( <i>n</i> = 40)	12.03 ± 1.31	9.75 ± 1.02	10.82 ± 1.14
	<i>t</i>	0.826	7.250	5.511
	<i>P</i>	0.442	< 0.001	< 0.001
TT (s)	Control ( <i>n</i> = 40)	15.22 ± 1.97	12.17 ± 1.06	14.22 ± 1.21
	Combine ( <i>n</i> = 40)	15.83 ± 1.92	13.84 ± 1.11	15.68 ± 1.27
	<i>t</i>	1.402	6.882	5.264
	<i>P</i>	0.165	< 0.001	< 0.001

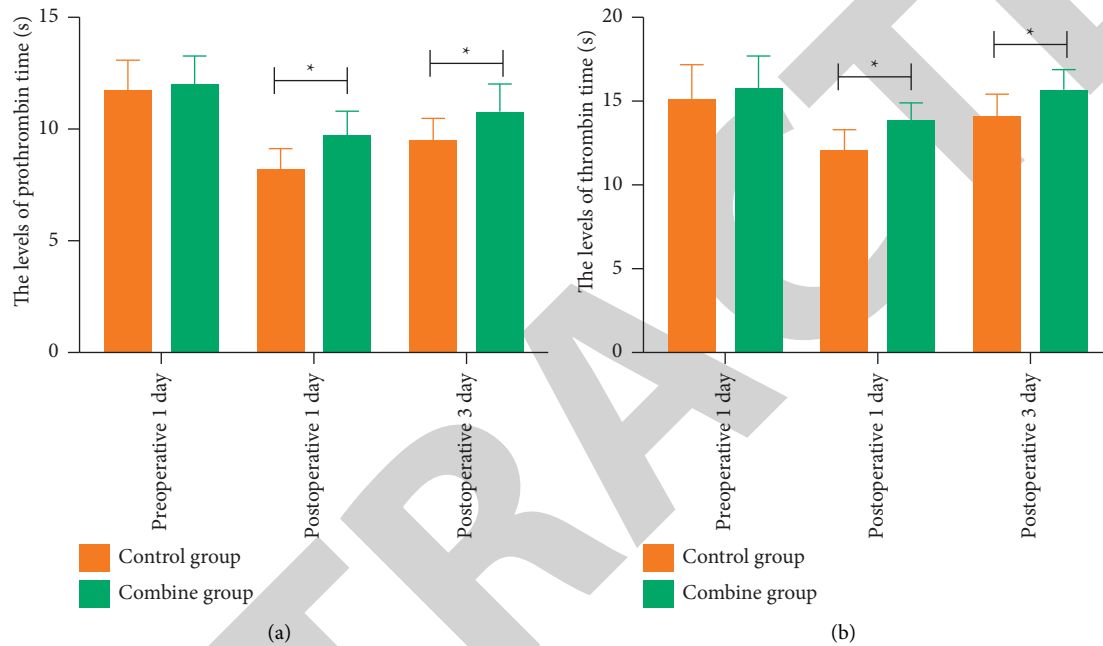


FIGURE 2: Changes of related indexes of the coagulation system in patients during the perioperative period: (a) changes of related indexes of the coagulation system in patients from 0 to 15; (b) changes of related indexes of the coagulation system in patients from 0 to 20.

TABLE 5: Changes in the level of stress indicators.

Index	Group	Preoperative 1 day	Postoperative 1 day	Postoperative 3 day
IL-6 (ng/L)	Control ( <i>n</i> = 40)	13.02 ± 1.26	30.25 ± 2.59	26.77 ± 2.05
	Combine ( <i>n</i> = 40)	12.85 ± 1.31	24.33 ± 2.47	19.32 ± 5.16
	<i>t</i>	0.592	10.460	8.486
	<i>P</i>	0.556	< 0.001	< 0.001
hs-CRP (mg/L)	Control ( <i>n</i> = 40)	18.26 ± 3.52	38.22 ± 4.59	32.02 ± 4.16
	Combine ( <i>n</i> = 40)	18.97 ± 3.84	31.15 ± 4.05	26.55 ± 3.45
	<i>t</i>	0.862	7.305	6.401
	<i>P</i>	0.391	< 0.001	< 0.001

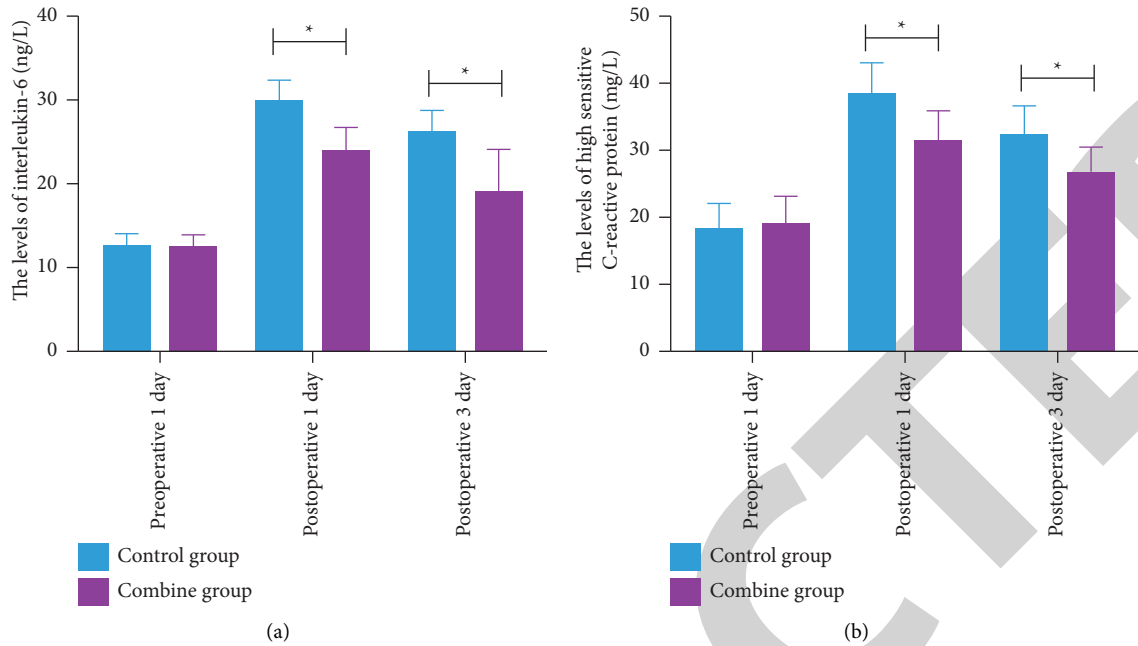


FIGURE 3: Changes in the level of stress indicators: (a) changes of related indexes of the coagulation system in patients from 0 to 40; (b) changes of related indexes of the coagulation system in patients from 0 to 50.

## 5. Conclusions

The therapeutic effect of SEPS + EVLT and traditional communicating branch vein ligation + EVLT on GSVV patients are compared in this study. The results show that SEPS + EVLT could significantly reduce the operation time and mean bleeding volume of patients and shorten the postoperative active time and hospitalization time. In addition, due to the hypercoagulability of blood in GSVV patients, the body injury caused by surgery can aggravate the disorder of the coagulation system, which will lead to abnormal changes in the levels of PT and TT. The traditional communicating branch vein ligation can cause great damage to the vein wall, strong stress in the body, and the function of vascular endothelial cells. At the same time, the traditional communicating branch vein ligation has many incisions, and a large number of bandages are used to wrap the wound after surgery, which limits the movement of the body and may aggravate blood coagulation. The surgical operation of SEPS combined with EVLT is more precise, which can effectively avoid damage to the surrounding normal veins and soft tissues, maintain the stability of the vascular endothelium, and reduce the stress response. The treatment mode of SEPS combined with EVLT therapy can reduce the postoperative stress response of patients and is not easy to have serious adverse effects on the coagulation system, so that a higher clinical effect can be obtained.

To sum up, SEPS combined with EVLT has a significant curative effect in the treatment of saphenous varicose veins of lower extremity. It can significantly shorten the hospitalization time of patients, improve the treatment effect and notch aesthetics, and improve the coagulation index and stress index.

## Data Availability

The simulation experiment data used to support the findings of this study are available from the corresponding author upon request.

## Conflicts of Interest

The authors declare that there are no conflicts of interest.

## Acknowledgments

This work was supported by S&T Program of Chengde (201904A049).

## References

- [1] A. Kundal, N. Kumar, D. Rajput, and U. Chauhan, "Great saphenous vein sparing versus stripping in Trendelenburg operation for primary varicose veins: a prospective study," *Polish Journal of Surgery*, vol. 93, no. 1, pp. 34–39, 2020.
- [2] S. Yoshida, I. Koshima Haddad, H. Imai et al., "Combined lymphovenous anastomosis and great saphenous vein stripping for comorbid lymphedema and varicose veins," *Lymphatic Research and Biology*, vol. 3, p. 31, 2020.
- [3] Y. Tseng, C. Chen, M. Wong et al., "Blood flow analysis of the great saphenous vein in the su-pine position in clinical manifestations of varicose veins of different severities: application of phase-contrast magnetic resonance imaging data," *Diagnostics*, vol. 102, no. 7, p. 118, 2020.
- [4] P. Sandhya, R. Mohil, and R. Sricharan, "Randomised controlled study to compare radiofrequency ablation with minimally invasive ultrasound-guided non-flush ligation and stripping of great saphenous vein in the treatment of varicose veins," *Annals of the Royal College of Surgeons of England*, vol. 39, no. 2, pp. 105–111, 2020.

- [5] S. D. Bendix, E. L. Peterson, L. S. Kabbani, M. R. Weaver, and J. C. Lin, "Effect of endovenous ablation assessment stratified by great saphenous vein size, gender, clinical severity, and patient-reported outcomes," *Journal of Vascular Surgery: Venous and Lymphatic Disorders*, vol. 9, no. 1, pp. 128–136, 2021.
- [6] M. Leo, R. Stefano, and A. I. Raffaele, "Foam sclerotherapy of the great saphenous vein in association with pre-terminal saphenous junction ligation/division as an office-based procedure: 12-Month results," *Phlebology: The Journal of Venous Disease*, vol. 33, no. 5, pp. 321–329, 2018.
- [7] S. Rajendran, H. R. Nair, M. Irshad K, M. Unais T, and N. J. Thaikattil, "Ultrasound-assisted varicose vein surgery and endovenous laser ablation using 1470-nm laser for treatment of great saphenous vein incompetence has similar outcomes at 1 year in a single-center prospective randomized study," *Journal of Vascular Surgery: Venous and Lymphatic Disorders*, vol. 10, no. 2, pp. 370–375, 2022.
- [8] F. Su, L. Cheng, and Q. Tong, "Effectiveness of tumescent solution combined with negative pressure wound therapy in traditional high ligation and stripping of the great saphenous vein," *Medicine*, vol. 99, no. 1, Article ID e19040, 2020.
- [9] H. Kusagawa, N. Haruta, and R. Shinhara, "Surgical methods and clinical results of subfascial endoscopic perforator surgery in Japan," *Phlebology*, vol. 14, no. 3, pp. 678–686, 2018.
- [10] G. Gao, L. Cao, X. Du et al., "Comparison of minimally invasive surgery transforaminal lumbar interbody fusion and TLIF for treatment of lumbar spine stenosis," *Journal of Healthcare Engineering*, vol. 2022, pp. 1–12, Article ID 9389239, 2022.
- [11] M. Fresa, E. Ezzi, A. Roessingh, S. D. Qanadli, B. Ney, and L. Mazzolai, "Ultrasound-guided percutaneous endovenous laser treatment combined with sclerotherapy for the treatment of large intramuscular venous malformations," *International Angiology*, vol. 41, no. 1, pp. 1–8, 2021.
- [12] J. Cragg, Z. Yang, X. Xie, J. Zhao, and P. Kang, "Adductor canal block provides better performance after total knee arthroplasty compared with femoral nerve block: a systematic review and meta-analysis," *International Orthopaedics*, vol. 40, no. 5, pp. 925–933, 2016.
- [13] D. McCarthy and I. Nyamekye, "The recommended goal in the United Kingdom's National Institute for Health and Care Excellence Clinical Guideline 168 for immediate referral of patients with bleeding varicose veins is not being achieved," *Journal of Vascular Surgery Venous Lymphat Disord*, vol. 9, no. 2, pp. 377–382, 2021.
- [14] K. Novotný, M. Roček, R. Pádr et al., "Treating great and small saphenous vein insufficiency with histoacryl in patients with symptomatic varicose veins and increased risk of surgery," *VASA. Zeitschrift für Gefasskrankheiten*, vol. 47, no. 5, pp. 416–424, 2018.
- [15] P. Zhang, H. Zhang, Y. Li, W. Chen, X. Y. Zhang, and H. J. Li, "Improved LHS based cumulant method for probabilistic load flow calculation," *Acta Energiæ Solaris Sinica*, vol. 42, no. 1, pp. 14–20, 2021.
- [16] E. Tanda, G. Ruiu, G. Pistincu, and S. Camparini, "Images in vascular medicine: foreign body reaction to surgical clips after subfascial endoscopic perforator surgery," *Vascular Medicine*, vol. 26, no. 6, pp. 670–671, 2021.
- [17] A. Cavallini, D. Marcer, and S. Ferrari Ruffino, "Endovenous laser treatment of groin and popliteal varicose veins recurrence," *Phlebology: The Journal of Venous Disease*, vol. 33, no. 3, pp. 195–205, 2018.
- [18] V. Manou-Stathopoulou, M. Korbonits, and G. L. Ackland, "Redefining the perioperative stress response: a narrative review," *British Journal of Anaesthesia*, vol. 123, no. 5, pp. 570–583, 2019.
- [19] J. Crippa, G. M. Mari, A. Miranda, A. T. M. Costanzi, and D. Maggioni, "Surgical stress response and enhanced recovery after laparoscopic surgery—a systematic review," *Chirurgia*, vol. 113, no. 4, pp. 455–463, 2018.
- [20] H. Bielas, R. E. Meister-Langraf, J.-P. Schmid et al., "Acute stress disorder and C-reactive protein in patients with acute myocardial infarction," *European Journal of Preventive Cardiology*, vol. 25, no. 3, pp. 298–305, 2018.