

SUPPLEMENTARY FILES

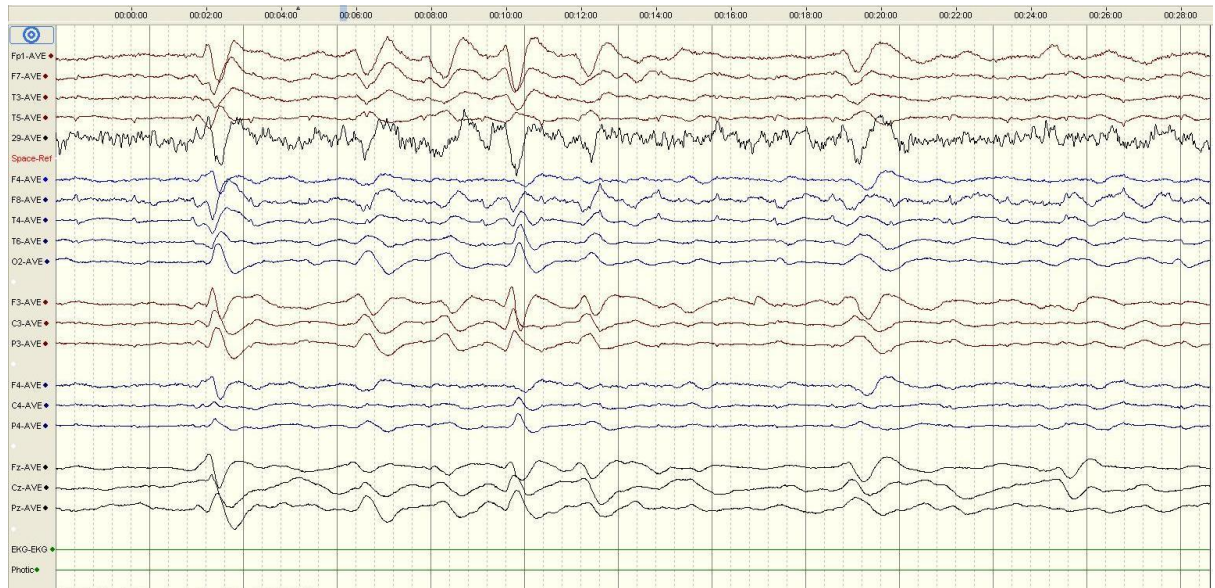

Figure S1: EEG epoch of encephalopathic patient with triphasic waves

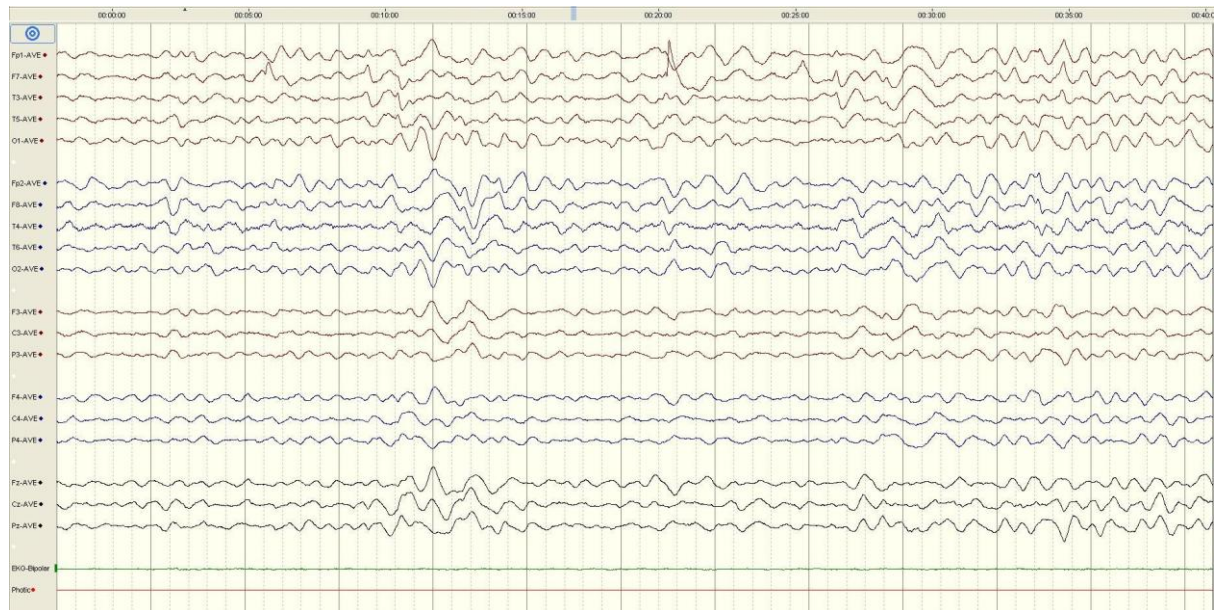

Figure S2: EEG sample showing EEG of encephalopathic patients with marked slowing of EEG

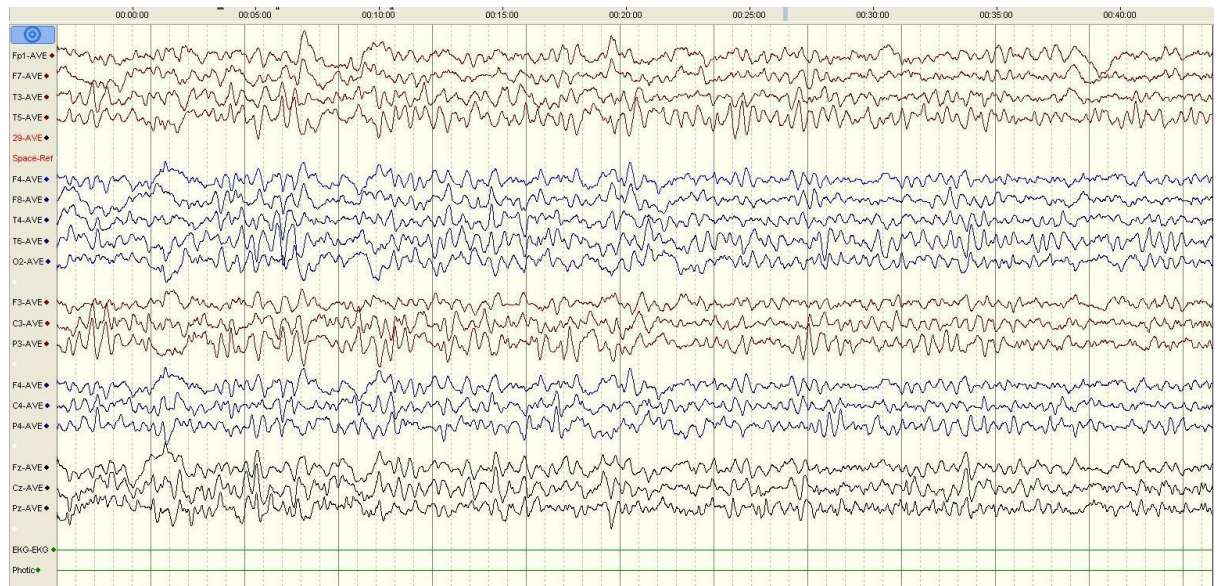


Figure S3: Normal EEG