Hindawi
Scanning
Volume 2023, Article ID 9814192, 1 page
https://doi.org/10.1155/2023/9814192

Retraction

Retracted: Changes of Volume Parameters in the Treatment of Graves Ophthalmopathy by Endoscopic Transethmoidal Decompression of the Orbital Inner Wall Combined with Fat Decompression

Scanning

Received 12 December 2023; Accepted 12 December 2023; Published 13 December 2023

This article has been retracted by Hindawi, as publisher, following an investigation undertaken by the publisher [1]. This investigation has uncovered evidence of systematic manipulation of the publication and peer-review process. We cannot, therefore, vouch for the reliability or integrity of this article.

Please note that this notice is intended solely to alert readers that the peer-review process of this article has been compromised.

Wiley and Hindawi regret that the usual quality checks did not identify these issues before publication and have since put additional measures in place to safeguard research integrity.

We wish to credit our Research Integrity and Research Publishing teams and anonymous and named external researchers and research integrity experts for contributing to this investigation.

The corresponding author, as the representative of all authors, has been given the opportunity to register their agreement or disagreement to this retraction. We have kept a record of any response received.

References

[1] W. Fu, "Changes of Volume Parameters in the Treatment of Graves Ophthalmopathy by Endoscopic Transethmoidal Decompression of the Orbital Inner Wall Combined with Fat Decompression," *Scanning*, vol. 2022, Article ID 8149247, 6 pages, 2022.

Hindawi
Scanning
Volume 2022, Article ID 8149247, 6 pages
https://doi.org/10.1155/2022/8149247

Research Article

Changes of Volume Parameters in the Treatment of Graves Ophthalmopathy by Endoscopic Transethmoidal Decompression of the Orbital Inner Wall Combined with Fat Decompression

Weina Fu

Department of Ophthalmology, Ningbo Medical Center Lihuili Hospital, Ningbo, Zhejiang 315040, China

Correspondence should be addressed to Weina Fu; 201804125@stu.ncwu.edu.cn

Received 5 July 2022; Revised 5 August 2022; Accepted 16 August 2022; Published 24 August 2022

Academic Editor: Danilo Pelusi

Objective. To observe the orbital volume changes and the analysis of surgical effect of Graves orbitopathy (GO) after endoscopic medial wall decompression combined with muscle cone fat. *Methods*. Twenty-two patients (30 eyes) with Graves orbital disease who visited the Department of Ophthalmology of Ningbo Medical Center from December 2019 to September 2021 were retrospectively collected. All patients were diagnosed as nonorganic active stage before operation, and all of them received endoscopic transethmoidal decompression of the medial orbital wall combined with intramuscular orbital fat decompression due to decreased vision, visual field defect or color vision disorder, and concomitant proptosis. Regular follow-up after operation. The curative effect is judged according to the degree of improvement of visual acuity, color vision, degree of correction of exophthalmos, diplopia, and other complications at 9 months after operation. Orbital CT combined with computer aided measurement software (Mimics 21) was used to measure the changes of orbital volume before and after exophthalmos surgery. The relationship between the value and eyeball regression is analyzed. *Results*. Preoperative exophthalmos ranged from 17.4 mm to 27.6 mm, with an average of (22.08 ± 2.86) mm. The postoperative exophthalmos was 14-25 mm, with an average of (19.52 ± 3.10) mm. Among them, 7 eyes (23.3%) had exophthalmos regression less than 1 mm, 6 eyes (20%) had a regression of 1-2 mm, 7 eyes (23.3%) had a regression of 2-3 mm, 5 eyes (16.7%) had a regression of 3-4 mm, and 5 eyes (16.7%) had a regression of 4-5.3 mm. The exophthalmos after operation was significantly lower than that before operation, and the difference was statistically significant ($t = 9.909$, $P < 0.05$). The preoperative orbital volume was 18.6 cm^3-25.3 cm^3 with an average of (22.39 ± 1.91) cm^3. The postoperative orbital volume was 19.8 cm^3-26.6 cm^3, with an average of (23.89 ± 1.90) cm^3.The orbital volume change range is 0.1 cm^3-3.8 cm^3, and the average orbital volume change is (1.51 ± 1.00) cm^3. Compared with preoperative orbital volume, the difference was statistically significant ($t = -8.074$, $P < 0.05$). *Conclusion*. Endoscopic decompression of the medial orbital wall through the ethmoid approach combined with decompression of the orbital fat within the muscle cone can effectively correct the exophthalmos while decompressing the orbital apex, and it is minimally invasive and has no facial scars. It has the advantages of extremely low incidence of postoperative diplopia and eye shift. There is a significant correlation between orbital volume changes and the regression of exophthalmos, which can provide reference for clinical guidance of surgical methods and prediction of surgical results.

1. Introduction

Graves' orbital disease (GO) is the most common extrathyroid manifestation of Graves' disease, which is found in about 25-50% of patients [1, 2]. GO is a common clinical disease and requires multidisciplinary treatment. A high incidence of orbital diseases has occurred in recent years. The incidence rate of eye diseases has been increasing year by year. The increase of orbital muscle contents and orbital pressure increase the incidence of ocular protrusion, the incidence of

eye closure, corneal keratopathy, and diplopia and oppressive optic neuropathy may result in decreased vision or even blindness in [3, 4]. Orbital decompression surgery releases more orbital space by removing part of the bony orbital wall, so as to increase the orbital volume, reduce the pressure of orbital contents, and retract the eyeball [5, 6]. The operation can achieve two main purposes: one is to improve the decline of visual function caused by great orbital pressure, and the other is to improve exophthalmos and repair facial appearance. The traditional orbital decompression is carried out under direct vision through the external orbital approach, which has obvious disadvantages, narrow operation field, inaccurate positioning, and large tissue trauma. In recent years, our hospital has carried out transnasal endoscopic orbital decompression in the treatment of graves orbital disease. It is a minimally invasive operation with small trauma, definite curative effect, and rapid recovery. At present, this operation is the best treatment for severe go and mild go eager to improve facial appearance.

2. General Information

Twenty two patients (30 eyes) diagnosed as Graves orbital disease and treated with orbital decompression surgery in the ophthalmology department of Li Huili Hospital of Ningbo medical center from December 2019 to September 2021 were collected retrospectively. Among them, 11 cases (15 eyes) were female and 11 cases (15 eyes) were male. The age ranged from 26 to 60 years, with an average of (43.17.00 ± 10.11) years. 3 cases were monocular and were followed up for more than 3 months. It was approved by the hospital ethics committee (ky2022pj009). The inclusion criteria are as follows: (1) meet the diagnosis of go; (2) no history of orbital decompression and ocular radiotherapy in the past; (3) available preoperative and postoperative ophthalmic examinations; (4) over 20 years old; (5) all patients were in the period of nonorganized activity for at least 6 months; (7) all patients failed to improve their visual acuity or were eager to improve their appearance due to the decline of visual acuity caused by exophthalmos, exposed corneal ulcer, diplopia, and optic neuropathy after conservative treatment. In all cases, as in the seventh case, patient informed consent can be obtained.

Meanwhile, the exclusion criteria were as follows: indications for orbital surgery other than go. The follow-up period was less than 3 months. Paitens who are under 18 years and patients in the fourth category will lack of informed consent for the study.

All patients underwent transnasal endoscopic medial orbital wall combined with muscle cone fat decompression. The operation was completed by the same operator. Methylprednisolone 500 mg was used for 3 days after operation. All patients underwent orbital CT before and 3 months after operation.

3. Inspection Indicators and Methods

3.1. Routine Inspection. Routine examinations include best corrected visual acuity, intraocular pressure, slit lamp examination, fundus visual field, ocular motion, diplopia, nasal endoscopy.

3.2. Measurement of Exophthalmos. Select the layer with the fullest lens as the measurement layer, connect the front edge of the lateral bone wall of both eyes, and measure the vertical distance from the corneal apex to the line. All results were measured by the same doctor for 3 times, and the average value was obtained.

3.3. CT Examination. The examination was performed with brillce 16 row spiral CT scanner (Philips, USA). The examinee was in supine position, the cross section was infraorbital line, and the coronal plane was perpendicular to the hard palate. The setting voltage is 120 kv, the current is 250 mA, the layer thickness is 1 mm, the layer spacing is 0.5 mm, the pitch is 0.69, and the matrix is 512 × 512. The window width is 300 hu, and the window level is 35 7hu. Keep the hard palate parallel to the baseline.

3.4. Data Transmission and Processing. The orbital CT examination results are output in DICOM format and transferred to eword image integration platform (Ningbo Quanwangyun Medical Technology Co., Ltd.). During measurement, the DICOM file was imported into mimics (materials interactive medical image control system) 21.0 software for three-dimensional reconstruction of orbital bone.

3.5. Orbital Volume Measurement. The anatomical marker points are (1) anterior orbital marker points: outer edge of orbit (the junction of zygomatic frontal suture and orbital arch surface), (2) dacryon point (the junction of lacrimal bone, frontal bone, and maxillary frontal tubercle), (3) supraorbital notch and infraorbital notch, and (4) posterior orbital marker points: lateral wall of optic canal. Using Mimics 21.0 measurement software, first create a mask, manually draw the orbital volume image from the horizontal level with a multislice edit brush (the description method is similar to the magnetic lasso tool of Photoshop software layer), and use the interpolate function to obtain the continuous level of orbital volume. At this time, the measurer can verify the description in the horizontal, coronal, and sagittal positions to make the corrected contour consistent with the actual contour. Finally, the orbital volume model is established by using the three-dimensional reconstruction function of the measurement software mimics 21.0, and the orbital volume is automatically calculated by the mask properties function system, see Figure 1.

4. Operation Method and Postoperative Treatment

The operative method was endonasal endoscopic orbital wall decompression + muscle cone fat decompression. Operated by the same ophthalmologist, the nasal mucosa convergence and surface anesthesia were completed through air tube intubation, intravenous compound anesthesia, routine disinfection, and towel laying. The operation steps were as follows: excision of sulcus process and medial wall of maxillary sinus under nasal endoscope and expansion of natural

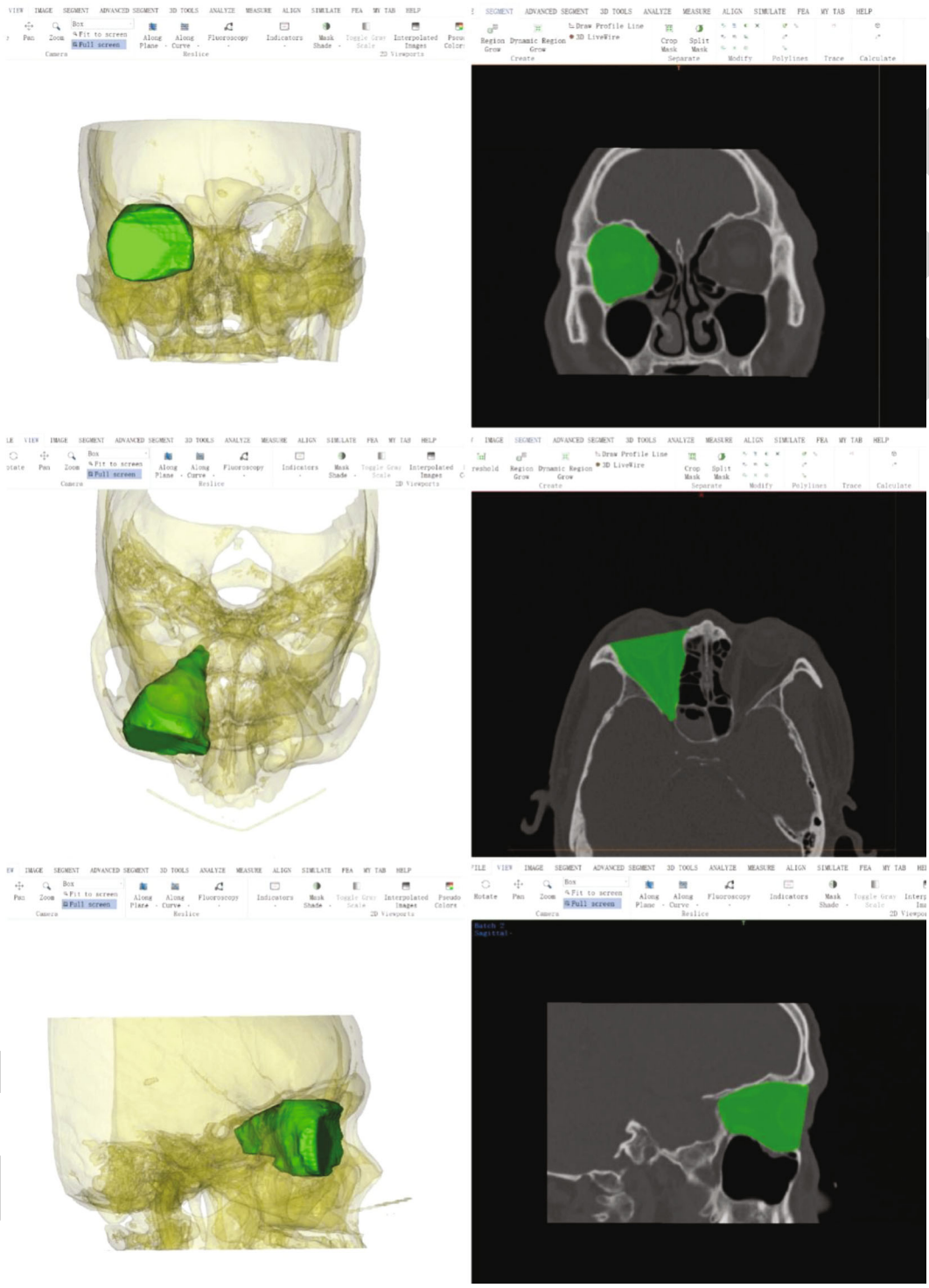

Figure 1: 3D image model of orbit reconstructed by mimics 21 software.

opening of maxillary sinus; remove the bone at the root of the middle turbinate, enter the upper nasal tract, remove the upper turbinate, and expand the natural mouth of the sphenoid sinus; grind the drill and thin the bone of the optic nerve spine, completely expose the paper template of the ethmoid bone, the orbital apex, and the front end of the optic nerve canal; remove the ethmoid paperboard, the bone of the medial part of the orbital floor, the bone of the lower part of the orbit, the bone of the orbital apex, and the anterior optic nerve canal; cut the orbital fascia to the orbital apex vertically; and cut the general health ring to decompress the orbital apex. The fat outside the medial muscle cone and part of the fat inside the muscle cone were removed by forceps. The operation cavity was filled after

Table 1: Preoperative and postoperative visual acuity distribution of GO patients.

Corrected vision	Preoperative cases	Number of postoperative cases	Intraocular pressure mmHg	Preoperative cases	Number of postoperative cases
0.2	1	1	12-21	26	28
0.5	2	2	22-23	1	1
0.7-0.8	3	4	25-30	3	1
1.0-1.2	21	20			
1.5	3	3			

no active bleeding was observed. After operation, broad-spectrum antibiotics were used routinely, and the packing in ethmoid sinus and nasal cavity was removed within 24-48 hours to prevent intraoperative and orbital infection. The patients were followed up for 3 months to 1 year.

5. Statistical Methods

IBM SPSS statistics 26 software is used for data analysis, and the measurement data are expressed as mean ± standard deviation ($x \pm s$). Paired sample t-test was used to compare the parameters (visual acuity, intraocular pressure, exophthalmos, and orbital volume) before and after operation. The correlation between the changes of each measured volume parameter before and after operation and ocular regression was analyzed by linear correlation. The difference was statistically significant ($P < 0.05$).

6. Results

6.1. Vision and Intraocular Pressure. The postoperative visual acuity of 1 eye (3.3%) in 30 eyes decreased by 0.5, 4 eyes (13.3%) improved by 0.1-0.3, and the other 25 eyes (83.3%) had no change before and after operation. Intraocular pressure decreased by 0.2-15 mmHg (1 mmh = 0.133 kPa) in 10 eyes (33.3%), including 2 eyes (6.7%) with a decrease of more than 10 mmHg and 5 eyes (16.7%) with a decrease of less than 5 mmHg. The intraocular pressure of the other 20 eyes (66.7%) was in the normal range before and after operation, see Table 1.

6.2. Exophthalmos. Preoperative exophthalmos was 17.4-27.6 mm, with an average of (22.08 ± 2.86) mm. The postoperative exophthalmos was 14-25 mm, with an average of (19.52 ± 3.10) mm. Among them, 7 eyes (23.3%) had a postoperative proptosis retreat of ≤1 mm, 6 eyes (20%) had a postoperative proptosis retreat of 1-2 mm, 7 eyes (23.3%) had a postoperative proptosis retreat of 2-3 mm, 5 eyes (16.7%) had a postoperative proptosis retreat of 3-4 mm, and 5 eyes (16.7%) had a postoperative proptosis retreat of 4-5.3 mm. The degree of exophthalmos after operation was significantly lower than that before operation ($t = 9.909$, $P < 0.05$), see Table 2.

6.3. Orbital Volume. The preoperative orbital volume was 18.6-25.3 cm^3, with an average of (22.39 ± 1.91) cm^3. The postoperative orbital volume was 19.8-26.6 cm3, with an average of (23.89 ± 1.90) cm^3. The change range of orbital volume was 0.1-3.8 cm^3, and the average change of orbital volume was (1.51 ± 1.00) cm^3. There was significant difference in orbital volume before and after operation ($t = -8.074$, $P < 0.05$), see Table 3.

Table 2: Changes of intraocular protrusion in GO patients before and after operation ($x \pm s$).

Observation time	Exophthalmos (mm, $X \pm s$)	Min-max
Preoperative	22.08 ± 2.86	17.4-27.6
After operation	19.52 ± 3.10	14-25
Change a value	2.56 ± 1.41	0.4-5.3
t value	9.909	
P value	0.000	

6.4. Correlation Analysis between Absolute Value of Eyeball Retraction and Orbital Volume Change. The changes of orbital volume before and after operation were positively correlated with the retraction of eyeball ($r = 0.805$, $P = 0.000$), and the difference was statistically significant ($P < 0.05$).

6.5. Complications. 15 eyes (50%) had no diplopia before and after operation, 10 eyes (33.3%) had no improvement in diplopia after operation, and 5 eyes (16.7%) had new diplopia after operation. In 2 eyes (6.7%), the entropion of the lower eyelid was aggravated.

7. Discussion

The pathological changes of GO are mainly manifested in extraocular muscle fibrosis and fat production. Lymphocytes participate in the autoimmune process of the disease and can secrete specific cytokines, which play an important role in the process of tissue changes and fibrosis in go patients [7]. In addition, fibroblasts participate in the occurrence and progress of go and can differentiate into different subtypes. On the one hand, they can produce hydrophilic substances such as hyaluronic acid and mucopolysaccharide to cause edema. On the other hand, they can differentiate into preadipocytes and adipocytes under certain conditions. Finally, the volume of orbital tissue increases, resulting in eyelid edema, eyelid retraction, exophthalmos, limitation of extraocular muscle function, and even exposure keratitis and thyroid optic neuropathy [8].

Because the research on the pathogenesis has not been clear, and there is no specific etiological treatment, the

Table 3: Changes of orbital volume before and after operation in GO patients ($x \pm s$).

Observation time	Orbital volume	Min-max
Preoperative	22.39 ± 1.91	18.6-25.3
After operation	23.89 ± 1.90	19.8-26.6
Change a value	1.51 ± 1.00	0.1-3.8
t value	-8.074	
P value	0.000	

current treatment is only symptomatic. The treatment of GO is carried out according to the stage and degree of the disease. Nonsurgical treatment of orbital decompression in active phase includes glucocorticoid therapy (GC) or other immunosuppressive drug therapy (such as rituximab) and orbital radiotherapy (RTH) [9, 10]. The above methods may shorten the course of the disease. The surgical treatment of orbital decompression in active stage [11, 12] is only used for the manifestations of poor curative effect of nonsurgical treatment but specific destructive visual impairment, such as thyroid related optical neuropathy (Don), which aims to relieve the compression of the optic nerve caused by the increase of orbital pressure by reducing the volume of orbital soft tissue (fat decompression) or expanding orbital volume (bone orbital decompression). However, surgery has limitations (including increased risk and unpredictable postoperative outcomes), and surgery usually does not shorten the course of orbital disease. When the condition of go is inactive, surgical treatment can be carried out as rehabilitation ophthalmic surgery [13]. The order of rehabilitation surgery includes orbital decompression, strabismus surgery, and finally, eyelid surgery as needed. Orbital decompression includes removing one or more orbital bone walls to strive for more accommodation space for overgrown muscle and adipose tissue, so as to reduce intraorbital pressure and retract the eyeball. In principle, each of the four orbital bone walls can be decompressed, but the most commonly used type of orbital decompression is endoscopic medial wall decompression and its expansion or medial wall combined with inferior wall decompression. Orbital decompression surgery is required when no improvement is observed after conservative treatment. The main advantages of transnasal endoscopic orbital decompression are as follows: (1) the anatomical structure and operation field can be well observed; (2) intraoperative evaluation of orbital tissue can accurately control the movement of fat into the nasal cavity and preserve the physiological drainage path of paranasal sinus; (3) the wound is small, the postoperative recovery is fast, and the hospital stay of patients is shortened.

The development of computed tomography (CT) and various computer-aided measurement software has achieved today's "era of surgical refinement." Researchers and surgeons can measure the volume of each orbital structure in a three-dimensional way [14]. In addition to the "emergency medical decompression" in the active phase, in the inactive phase, they can customize the expected and clear operation plan according to the patient's individual anatomical structure, give full play to the advantages of Science and technology, and minimize the surgical complications. In this study, the orbital volume was measured by three-dimensional CT combined with mimics (materials interactive medical image control system) 21.0 software. The results showed that the orbital volume increased significantly after endoscopic medial wall decompression combined with muscle cone fat decompression in go patients, which was positively correlated with the degree of eyeball retraction. Previous studies have shown that the eyeball regression value of go patients after medial orbital decompression combined with fat decompression is 4 ~ 9 mm [15, 16], which is similar to the results of this study. Endoscopic medial wall decompression has been one of the classic decompression methods of go. Endoscopic operation under direct vision has less damage and definite curative effect. However, the degree of exophthalmos corrected by medial wall decompression alone is very limited. Therefore, in order to achieve better decompression effect, this study combined to suck out the fat in the muscle cone during the operation. Previous studies have shown that there may be other factors unrelated to the operation that play an important role in eyeball retraction, such as individual orbital shape, the ratio of eyeball to orbital volume, and the hardness of eyeball soft tissue. The latter may affect the herniation of orbital soft tissue into the newly formed orbital space. This study focused on the changes of orbital volume before and after operation. The results showed that there was a positive correlation between the changes of orbital volume before and after operation and the retraction of eyeball ($r = 0.805$, $P = 0.000$), and the difference was statistically significant ($P < 0.05$). The results showed that 5 eyes (16.7%) had new diplopia, and 2 eyes (6.7%) had entropion and aggravation of eyelashes. It is reported that the incidence of new diplopia after endoscopic decompression is still 19-45% [17–19]. This huge difference in reported results may reflect the difference of surgical technology. The possible causes of new diplopia after operation are as follows: after decompression of the medial wall, the internal rectus muscle moves into the nasal cavity; surgical trauma will destroy the stability of adipose tissue, and adipose tissue may regenerate after operation. At present, there are three main methods that can avoid or reduce the occurrence of postoperative diplopia: balanced orbital decompression of inner and outer wall; the orbital sling is a periorbital band that retains about 1 cm along the medial rectus muscle to support the medial rectus muscle and prevent its excessive displacement, which can reduce the occurrence of diplopia and eyeball sinking; retain the orbital strut structure, which is the bone at the bone connection between ethmoid bone and maxilla. Diplopia is easy to occur after removing the strut structure in the decompression of inner inferior wall. Some patients show temporary diplopia, which can be improved by conservative treatment. Adequate orbital decompression may be at the cost of increasing the risk of postoperative diplopia. Reasonably measure the balance between the removal of fat and bone wall, the degree of eyeball regression, and the risk of postoperative strabismus. Therefore, the purpose of this study is to expand the sample size for further research and to clarify the best benefit point

and the least complications among the preoperative and postoperative orbital volume difference, the amount of eyeball retraction, and the degree of postoperative diplopia (caused by strabismus). Preoperative and postoperative digital orbital CT scanning and three-dimensional reconstruction evaluation also provide very important information about orbital changes after decompression, so as to provide reference basis for clinical guidance of surgical methods and prediction of surgical effects.

Data Availability

The data used to support the findings of this study are available from the corresponding author upon request.

Conflicts of Interest

The author declares no conflicts of interest.

References

[1] L. Clauser, M. Galiè, E. Sarti, and V. Dallera, "Rationale of treatment in Graves ophthalmopathy," *Plastic and Reconstructive Surgery*, vol. 108, no. 7, pp. 1880–1894, 2001.

[2] R. A. Goldberg, "Advances in surgical rehabilitation in thyroid eye disease," *Thyroid*, vol. 18, no. 9, pp. 989–995, 2008.

[3] M. L. Tanda, E. Piantanida, L. Liparulo et al., "Prevalence and natural history of Graves' orbitopathy in a large series of patients with newly diagnosed graves' hyperthyroidism seen at a single center," *The Journal of Clinical Endocrinology and Metabolism*, vol. 98, no. 4, pp. 1443–1449, 2013.

[4] L. Bartalena, L. Baldeschi, and B. Kostas, "The 2016 European thyroid association/European group on graves' orbitopathy guidelines for the management of graves' orbitopathy," *European thyroid journal*, vol. 5, no. 1, pp. 9–26, 2016.

[5] S. Zgliczyński, H. Jastrzebska, T. Górowski et al., "Results of 3-stage treatment:(I) corticotherapy,(II) linear acceleration and (III) orbital decompression in 206 patients with malignant Graves ophthalmopathy," *Endokrynologia Polska*, vol. 43, no. 3, pp. 274–286, 1992.

[6] B. A. Schiff, C. P. Mcmullen, and J. Farinhas, "Use of computed tomography to assess volume change after endoscopic orbital decompression for Graves' ophthalmopathy," *American Journal of Otolaryngology*, vol. 36, no. 6, pp. 729–735, 2015.

[7] H. Lahooti, K. R. Parmar, and J. R. Wall, "Pathogenesis of thyroid-associated ophthalmopathy: does autoimmunity against calsequestrin and collagen XIII play a role?," *Clinical Ophthalmology (Auckland, NZ)*, vol. 4, 2010.

[8] G. A. Brent, "Graves' disease," *New England Journal of Medicine*, vol. 358, no. 24, pp. 2594–2605, 2008.

[9] G. J. Kahaly, S. Pitz, G. Hommel, and M. Dittmar, "Randomized, single blind trial of intravenous versus oral steroid monotherapy in Graves' orbitopathy," *The Journal of Clinical Endocrinology & Metabolism*, vol. 90, no. 9, pp. 5234–5240, 2005.

[10] L. Bartalena, G. E. Krassas, W. M. Wiersinga et al., "Efficacy and safety of three different cumulative doses of intravenous methylprednisolone for moderate to severe and active Graves' orbitopathy," *The Journal of Clinical Endocrinology & Metabolism*, vol. 97, no. 12, pp. 4454–4463, 2012.

[11] A. H. Alsuhaibani and J. A. Nerad, *Thyroid-associated orbitopathy//Seminars in plastic surgery*, 21:Copyright© 2007 by Thieme Medical Publishers, Inc, 333 Seventh Avenue, New, 2007.

[12] K. G. Gold, S. Scofield, S. R. Isaacson, M. W. Stewart, and M. Kazim, "Orbital radiotherapy combined with corticosteroid treatment for thyroid eye disease-compressive optic neuropathy," *Ophthalmic Plastic & Reconstructive Surgery*, vol. 34, no. 2, pp. 172–177, 2018.

[13] T. Bednarczuk and E. Bar-andziak, "Management of graves' orbitopathy. Comments on the eugogo consensus statement," *Endokrynologia Polska*, vol. 60, no. 4, pp. 312–330, 2009.

[14] E. Weis, M. K. Heran, A. Jhamb et al., "Quantitative computed tomographic predictors of compressive optic neuropathy in patients with thyroid orbitopathy: a volumetric analysis," *Ophthalmology*, vol. 119, no. 10, pp. 2174–2178, 2012.

[15] Z. Lv, D. Selva, W. Yan, P. Daniel, Y. Tu, and W. Wu, "Endoscopical orbital fat decompression with medial orbital wall decompression for dysthyroid optic neuropathy," *Current Eye Research*, vol. 41, no. 2, pp. 150–158, 2016.

[16] S. Gulati, H. O. Ueland, O. H. Haugen, A. Danielsen, and E. Rødahl, "Long-term follow-up of patients with thyroid eye disease treated with endoscopic orbital decompression," *Acta Ophthalmologica*, vol. 93, no. 2, pp. 178–183, 2015.

[17] R. A. Goldberg, J. D. Perry, V. Hortaleza, and J. T. Tong, "Strabismus after balanced medial plus lateral wall versus lateral wall only orbital decompression for dysthyroid orbitopathy," *Ophthalmic Plastic & Reconstructive Surgery*, vol. 16, no. 4, pp. 271–277, 2000.

[18] A. H. Alsuhaibani, K. D. Carter, B. Policeni, and J. A. Nerad, "Orbital volume and eye position changes after balanced orbital decompression," *Ophthalmic Plastic & Reconstructive Surgery*, vol. 27, no. 3, pp. 158–163, 2011.

[19] M. R. Dubin, A. Tabaee, J. T. Scruggs, M. Kazim, and L. G. Close, "Image-guided endoscopic orbital decompression for Graves' orbitopathy," *Annals of Otology, Rhinology & Laryngology*, vol. 117, no. 3, pp. 177–185, 2008.