Interdisciplinary Perspectives on Infectious Diseases

Parasitic Diseases, Diagnostic Approaches, and Therapies

Guest Editors: Herbert B. Tanowitz, Louis M. Weiss, and Louis V. Kirchhoff

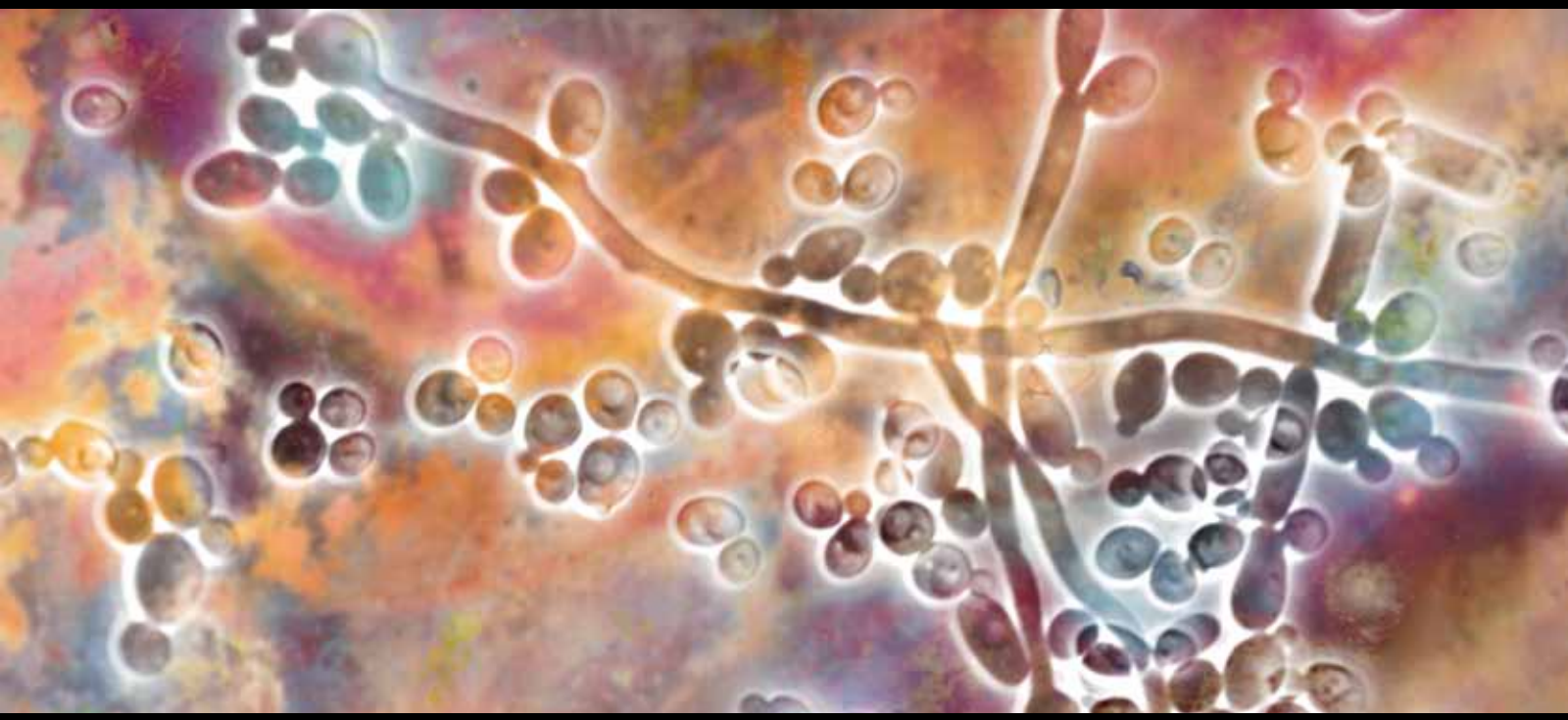

Parasitic Diseases, Diagnostic Approaches, and Therapies

Interdisciplinary Perspectives on Infectious Diseases

Parasitic Diseases, Diagnostic Approaches, and Therapies

Guest Editors: Herbert B. Tanowitz, Louis M. Weiss, and Louis V. Kirchhoff

Contents

Hindawi Publishing Corporation
Interdisciplinary Perspectives on Infectious Diseases
Volume 2009, Article ID 893890, 2 pages
doi:10.1155/2009/893890

Editorial

Parasitic Diseases, Diagnostic Approaches, and Therapies

Herbert B. Tanowitz and Louis M. Weiss

Albert Einstein College of Medicine, Yeshiva University, Bronx, NY 10461, USA

Correspondence should be addressed to Herbert B. Tanowitz, herbert.tanowitz@einstein.yu.edu

Received 20 October 2009; Accepted 20 October 2009

The diagnosis and treatment of parasitic diseases has undergone major changes because of increased awareness and technological advances that now allow for more rapid and accurate diagnosis of parasitic diseases. These advances are critically important for the continuing diagnosis of these infections as there has been a steady decline in the quantity and quality of laboratory technicians who are expert in the classical techniques of examining stool and blood smears for parasites. The majority of laboratories have an increased reliance on nonclassical parasitological techniques for the accurate diagnosis of these infections. Dr. Ndao from McGill University has given an overview of many of these newer diagnostic methods.

Malaria is a major pathogen in most of the world, and Drs Murray and Bennett from the US Army provide a timely review of the current status of rapid diagnosis of malaria using nontraditional methods. These rapid techniques have been a great advance since, in many laboratories; there are now few individuals that are expert in examining smears. In addition, these rapid techniques can be used by field workers and military personnel. These new methods make the diagnosis more rapid and accurate leading to a more rapid institution of appropriate treatment. Amebiasis continues to be an important cause of morbidity and mortality worldwide. Drs. Singh, Haupt, and Petri, in their review provide an update on the rapid diagnosis of *Entamoeba histolytica*. Diseases caused by Microsporidia are found in both immune-competent and immune-compromised hosts such as those with HIV/AIDS. The diagnosis is often difficult to make. In their article, Drs. Ghosh and Weiss review the state of molecular diagnostics for microsporidian infections. Human infections caused by free-living amoebas have not received sufficient attention in literature despite the fact that they may cause disabilities and death. Dr. Marciano-Cabral's group has reviewed the current state of the diagnosis of these important organisms. The review by Vannier and Krause provides an excellent update on the status of the diagnosis and treatment of babesiosis. Importantly, this infection still poses a threat not only from natural infection via the bite of a tick but also through blood transfusion.

New diagnostic techniques have been developed for metazoan as well as protozoan infections. Neurocysticercosis has received increasing attention as a cause of seizures worldwide. There has also been an awareness of this disease because of the immigration of individuals from endemic areas to non-endemic areas of the world. Drs. Coyle and Tanowitz provide a review of the diagnostic and therapeutic options for management of this infection. Another helmintic disease of humans with complex management issues is that caused by Echinococcus and this is reviewed by Siracusano and colleagues.

The articles by Dr. Baccchi and Dr. de Souza deal with the chemotherapy of trypanosomiasis, both African and American. Drs. Hochman and Kim explore the recent data on the HIV-malaria interaction. Since both HIV and malaria coexist in sub-saharan Africa, this review is timely. Dr. Petersen examines canine leishmaniasis and it implications for human disease.

This year 2009 marks the 100th anniversary of the discovery of Chagas disease. This disease caused by the parasite *Trypanosoma cruzi* continues to be an important cause of cardiomyopathic heart disease in endemic areas of Latin America and is being increasingly recognized in non-endemic areas such as North America and Europe. The article by Dr. Gupta et al. from the Garg group in the University of Texas has offered a unique insight into the role of oxidative stress in the pathogenesis of chagasic cardiomyopathy. Adipose tissue is the largest endocrine

organ in the body and its role in infection has only recently been appreciated. The laboratory group at the Albert Einstein College of Medicine offers a review of the role of adipose tissue in the pathogenesis of Chagas diseases, providing a new perspective on this overlooked facet of pathogen host interaction. There has been little success in changing the chronic manifestations of Chagas Disease by using antiparasitic therapy. A new approach to this problem is discussed in the article by Dr. Campos de Carvalho et al. who provide data suggesting that stem cell therapy may be useful in the treatment of the cardiomyopathy caused by *T. cruzi* infection.

We have obtained articles on a range of topics which highlight many of the new issues in the field of parasitological diagnosis and treatment. It is our belief that this collection of articles provides an important summary of these issues and will be of use to both clinicians and researchers working on parasitic diseases.

Herbert B. Tanowitz
Louis M. Weiss

Hindawi Publishing Corporation
Interdisciplinary Perspectives on Infectious Diseases
Volume 2009, Article ID 278246, 15 pages
doi:10.1155/2009/278246

Review Article

Diagnosis of Parasitic Diseases: Old and New Approaches

Momar Ndao

National Reference Centre for Parasitology, McGill University Centre for Tropical Diseases, Montreal General Hospital, 1650 Cedar Avenue R3-137, Montreal, QC, Canada H3G 1A4

Correspondence should be addressed to Momar Ndao, momar.ndao@mcgill.ca

Received 31 May 2009; Accepted 29 August 2009

Recommended by Herbert B. Tanowitz

Methods for the diagnosis of infectious diseases have stagnated in the last 20–30 years. Few major advances in clinical diagnostic testing have been made since the introduction of PCR, although new technologies are being investigated. Many tests that form the backbone of the "modern" microbiology laboratory are based on very old and labour-intensive technologies such as microscopy for malaria. Pressing needs include more rapid tests without sacrificing sensitivity, value-added tests, and point-of-care tests for both high- and low-resource settings. In recent years, research has been focused on alternative methods to improve the diagnosis of parasitic diseases. These include immunoassays, molecular-based approaches, and proteomics using mass spectrometry platforms technology. This review summarizes the progress in new approaches in parasite diagnosis and discusses some of the merits and disadvantages of these tests.

1. Introduction

Currently, the detection and diagnosis of parasite infections rely on several laboratory methods in addition to clinical symptoms, clinical history, travel history, and geographic location of patient. The primary tests currently used to diagnose many parasitic diseases have changed little since the development of the microscope in the 15th century by Antonie van Leeuwenhoek. Furthermore, most of the current tests cannot distinguish between past, latent, acute, and reactivated infections and are not useful for following response to therapy or for prognosis.

Recent developments in new diagnostic tools, however, have opened new avenues for a vast improvement in parasite detection. Firstly, a number of newer serology-based assays that are highly specific and sensitive have emerged, such as the Falcon assay screening test ELISA (FAST-ELISA) [1], Dot-ELISA [2, 3], rapid antigen detection system (RDTS) [4], and luciferase immunoprecipitation system (LIPS) [5]. Secondly, molecular-based approaches such as loop-mediated isothermal amplification (LAMP) [6], real-time polymerase chain reaction [7], and Luminex [8] have shown a high potential for use in parasite diagnosis with increased specificity and sensitivity. Thirdly, proteomic technology has also been introduced for the discovery of biomarkers using tissues or biological fluids from the infected host.

The aim of this review is to highlight the potential for these new technologies in parasite diagnosis. For convenience, old and new parasitic diagnostic tools are summarized in Tables 1 and 2. The diagnostic tools offered by the CDC (Centre for Disease Control, Atlanta, USA) and the NRCP (National Reference Centre for Parasitology, Montréal, Canada) are also highlighted in Tables 3 and 4.

2. Microscopy

For many years, microscopy has been the only tool available for the detection of parasites through inspection of blood smears [10–14], tissue specimens [15–17], feces, lymph node aspirates [18, 19], bone marrow [20], and even cerebrospinal fluid [21]. However, sample preparation for direct observation is time-consuming, labour intensive, and proper diagnosis depends on qualified laboratory technicians. In the case of slide reading, a second independent reading is preferable, but not always required for accurate diagnosis. If need be, divided readings are resolved by a third reader. In endemic regions, where resources are limited, this proves to

Table 1: Diagnostic tools for the detection of specific blood-borne parasitic diseases.

	African trypanosomiasis	Babesiosis	Chagas disease	Leishmaniasis	Malaria	Toxoplasmosis
	Trypanosoma brucei	*Babesia microti*	*Trypanosoma cruzi*	*Leishmania species*	*Plasmodium species*	*Toxoplasma gondii*
MICROSCOPY	[23]	[10]	[11]	[12]	[13]	—
SEROLOGY-BASED ASSAYS	—	—	—	—	—	—
ELISA	[24, 25]	[26]	[27–30]	—	—	[31]
FAST-ELISA	—	—	—	—	[32, 33]	—
Dot-ELISA or Dipstick	[34]	—	[35]	[2, 18]	—	—
RIPA-ELISA	—	—	[36, 37]	—	—	—
DHA or IHA	[38]	—	—	[18]	—	—
DFA or IFA	[39]	[40, 41]	—	—	[42]	[43]
Immunoblot	—	—	[44, 45]	—	—	[46]
PRISM	—	—	[47]	—	—	—
RDT	—	—	[48]	—	[49]	—
MOLECULAR-BASED ASSAYS	—	—	—	—	—	—
PCR	[23]	[50, 51]	[52–54]	[55]	[56]	[57, 58]
RT-PCR	[59]	—	—	[60–62]	[4, 56]	[63]
QT-NASBA	—	—	—	[64]	[65, 66]	—
RT-QB-NASBA	—	—	—	—	[67]	—
LAMP	[68]	—	[69]	—	[70–74]	—
Luminex	—	—	—	—	[75]	—
PCR-ELISA	—	—	—	[62, 76]	[77–79]	—
OC-PCR	[80]	—	—	[81]	—	—
PROTEOMICS	—	—	—	—	—	—
Mass Spectrometry (LDMS, MALDI-TOF, SELDI-TOF)	[82, 83]	—	—	—	[84–86]	—

FAST-ELISA: Falcon assay screening test; RIPA-ELISA: radioimmunoprecipitation assay; DHA or IHA: direct or indirect hemagglutination assay; DFA or IFA: direct or indirect immunofluorescence assay; RDT: rapid diagnostic test; LIPS: luciferase immunoprecipitation system; CATT: Card Agglutination test for Trypanosomiasis; PCR: polymerase chain reaction; RT-PCR: real-time polymerase chain reaction; QT-NASBA: quantitative nucleic acid sequenced-based amplification; RT-QT-NASBA: real-time quantitative nucleic acid sequenced-based amplification; LAMP: loop-mediated isothernal amplification; OC-PCR: oligochromatography Polymerase chain reaction; LDMS: laser desorption mass spectrometry; MALDI-ToF: matrix-assisted laser desorption/ionization time of flight; SELDI-Tof: surface-enhanced laser desorption/ionization time of flight, IFA: immunofluorescent assay, EIA: Enzyme immunoassay, RT-PCR: Real time PCR, IB: immunoblot.

be difficult and misdiagnosis can significantly impact patient care. In reality, all major intestinal helminth infections are still solely dependent on microscopy for diagnosis. As for other parasite infections, many are confirmed by the use of microscopy in conjunction to other methods of diagnosis including serology-based assays and more recently molecular-based assays.

3. Serology-Based Assays

In situations where biologic samples or tissue specimens are unavailable, serology alone is the gold standard for diagnosis. Serology-based diagnosis tools can be divided into two categories: antigen-detection assays and antibody-detection assays. These include the enzyme-linked immunosorbent assay (ELISA), also called enzyme immunoassay (EIA), and all its derived tests such as the Falcon assay screening test ELISA (FAST-ELISA) and the dot-ELISA. Other assays include the hemagglutination (HA) test, indirect or direct immunofluorescent antibody (IFA or DFA) tests, complement fixation (CF) test, and immunoblotting and rapid diagnostic tests (RDTs).

Although the ease of use and turnaround times for serologic assays are similar to microscopy, serology-based

Table 2: Diagnostic tools for the detection of specific intestinal parasitic diseases.

	PROTOZOA	TREMATODES		CESTODES		NEMATODES	
	Cryptosporidiosis	Fasciolosis	Schistosomiasis	Taeniasis/ Cysticercosis	Hydatidosis	Filariasis	Strongylodiasis
	Cryptosporidium parvum, C. hominis	*Fasciola hepatica, F. gigantica*	*Schistosoma mansoni*	*Taenia solium*	*Echinococcus granulosus, E. multilocularis*	*Wuchereria bancrofti, Brugia malayi, B. timori, Loa loa*	*Strongyloides stercoralis*
MICROSCOPY	[87]	[88]	[89]	—	[90]	[91]	[92]
SEROLOGY BASED ASSAYS	—	—	—	—	—	—	—
ELISA	[93, 94]	[88, 95]	[96, 97]	[98–101]	[102–106]	[14]	[107–111]
FAST-ELISA	—	[112]	[1]	—	—	—	—
Dot-ELISA or Dipstick	—	[113, 114]	[115]	—	[116, 117]	[118–120]	—
DHA or IHA	—	—	[121]	—	[122]	[123]	[124]
DFA or IFA	[93, 125, 126]	—	—	—	—	—	[127, 128]
Immunoblot	—	[112]	[129]	[130, 131]	[122]	—	[132]
LIPS	—	—	—	—	—	[133]	[134]
MOLECULAR-BASED ASSAYS	—	—	—	—	—	—	—
PCR	[135, 136]	—	[137, 138]	[139, 140]	—	[141–143]	[144]
RT-PCR	[145–147]	—	[148, 149]	—	—	—	[150]
LAMP	[151, 152]	—	—	[153]	—	—	—
Luminex	[154]	—	—	—	—	—	—
PCR-ELISA	—	—	—	—	—	[155]	—
OC-PCR	—	—	[156]	—	—	—	—
PROTEOMICS	—	—	—	—	—	—	—
Mass Spectrometry (LDMS, MALDI-TOF, SELDI-TOF)	—	[157]	—	[158]	—	—	—

Abbreviations: see Table 1.

Table 3: Diagnostic tools for the detection of specific blood-borne parasitic diseases offered by the CDC and the NRCP.

	African trypanosomiasis	Babesiosis	Chagas disease	Leishmaniasis	Malaria	Toxoplasmosis
	Trypanosoma brucei species	*Babesia microti*	*Trypanosoma cruzi*	*Leishmania species*	*Plasmodium species*	*Toxoplasma gondii*
CDC DIAGNOSTIC TOOLS	Microscopy	Microscopy IFA, PCR	Microscopy culture, IFA, EIA	Microscopy, Culture, IFA	Microscopy PCR, IFA	Microscopy IFA, EIA
NRCP DIAGNOSTIC TOOLS	Microscopy, culture, CATT, PCR	Microscopy, IFA	Microscopy, culture, EIA, RT-PCR	Microscopy, Culture, IFA, RT-PCR	Microscopy, IFA, IB, PCR	RT-PCR

CDC: Centre for Disease Control, Atlanta, Georgia, USA. NRCP: National Reference Centre for Parasitology, Montreal General Hospital, Montreal, Quebec, Canada. Abbreviations: see Table 1.

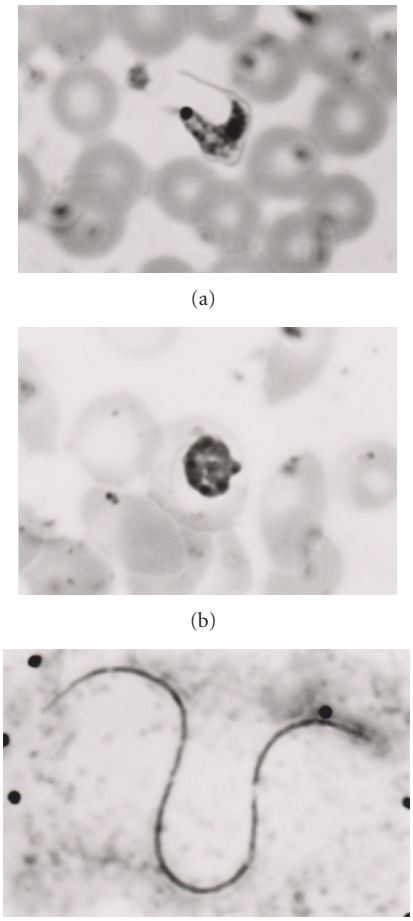

Figure 1: *Microscopy*. Comparison of *Trypanosoma cruzi* trypomastogote (a) with *Plasmodium malariae* schizont (b) and with microfilaria (c: *Mansonella perstans*) in squirrel monkey blood smear. Giemsa stain: 70x oil-immersion objective (a) and (b) and 27.2x objective (c), adapted with permission of Comparative Medicine from [9].

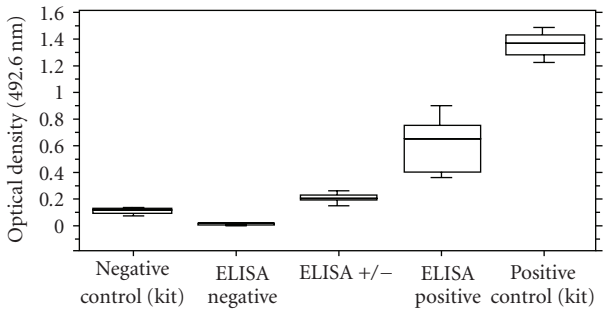

Figure 2: *Serology-based assays: ELISA*. Enzyme-linked immunosorbent assay (ELISA) absorbance values for antibodies to *T. cruzi* in monkey samples. Median values are indicated by horizontal lines within the boxes; the 25th and 75th percentiles are enclosed by the boxes; the 5th and 95th percentiles are enclosed by the bars outside the boxes. Adapted with permission of Comparative Medicine from [9].

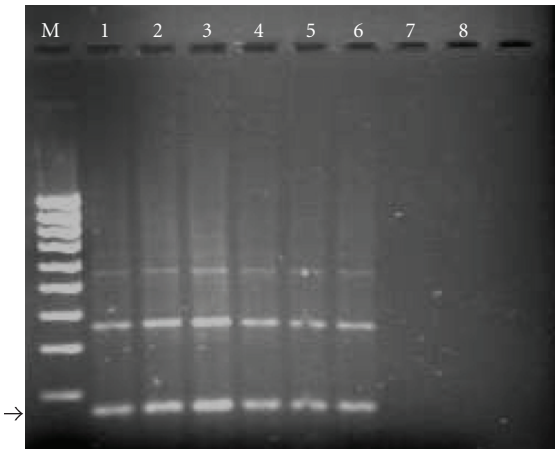

Figure 3: Molecular-based assay: PCR. Example of PCR results obtained for seven monkey samples, using the TCRUZ primers. Blood samples were processed as described in Materials and Methods. The PCR products were electrophoresed in a 2% agarose gel and stained with ethidium bromide. The 168 bp band (arrow) is the expected *T. cruzi*-specific product. The 360 and 550 bp are also specific products resulting from amplification of two or three of the 195 bp repeats found in tandem arrays in the *T. cruzi* genome. Lanes 1 to 6 contain the amplification products of DNA from *T. cruzi*-infected monkeys; 7, blood from noninfected monkey; 8, negative control (distilled water); and M, 100 bp ladder, adapted, with permission of Comparative Medicine from [9].

assays are more sensitive and specific. It becomes important for individuals whose blood smears do not permit identification of the parasite (e.g., differentiating between *Babesia* and *Plasmodium*) [159] or for patients exhibiting low-parasitemia and/or who are asymptomatic (e.g., Chagasic patients) [54]. Classifying an infected asymptomatic patient as negative could lead to transmission of the parasite during blood transfusions or organ transplants. In the case of *Fasciola* infection, serology tests have also been shown to be useful in the confirmation of chronic fascioliasis when egg production is low or sporadic [112]. Finally, having these tests readily available allows for the monitoring of parasite clearance following therapy.

3.1. Falcon Assay Screening Test ELISA (FAST-ELISA). The Falcon assay screening test ELISA (FAST-ELISA) consists of using synthetic and recombinant peptides to evaluate antibody responses to an antigen [1]. In the past, the method has been applied to the study of malaria [32], fasciolosis [112], schistosomiasis (reviewed in [160]), and taeniasis [161]. However, this technique is subjected to the same drawbacks as most serology-based tests. Antibodies raised against a peptide from one parasite protein may cross-react with proteins from other species. Moreover, antibodies raised against a peptide may react in some assays but not in others and some regions of a peptide may be more immunogenic than others. No recent studies have been published on the use of the FAST-ELISA for the diagnosis of parasitic infections.

Table 4: Diagnostic tools for the detection of specific intestinal parasitic diseases offered by the CDC and the NRCP.

	PROTOZOA	TREMATODES		CESTODES		NEMATODES	
	Cryptosporidiosis	Fasciolosis	Schistosomiasis	Taeniasis Cysticercosis	Hydatidosis	Filariasis	Strongylodiasis
	Cryptosporidium parvum, C. hominis	*Fasciola hepatica, F. gigantica*	*Schistosoma mansoni*	*Taenia solium*	*Echinococcus granulosus, E. multilocularis*	*Wuchereria bancrofti, Brugia malayi, B. timori, Loa loa*	*Strongyloides stercoralis*
CDC DIAGNOSTIC TOOLS	Microscopy, EIA, PCR, RT-PCR	—	Microsocopy, FAST-ELISA, IB	Immunoblot,	IB	Microscopy, EIA	Microscopy, EIA
NRCP DIAGNOSTIC TOOLS	Microscopy, EIA	Microscopy, EIA	Microscopy, EIA	IB	EIA	Microscopy, EIA	Microscopy, culture, EIA, IB

CDC: Centre for Disease Control, Atlanta, Georgia, USA. NRCP: National Reference Centre for Parasitology, Montreal General Hospital, Montreal, Quebec, Canada.

3.2. Dot-ELISA. The main difference between the regular ELISA and the dot-ELISA lies in the surface used to bind the antigen of choice. In the dot-ELISA, the plastic plate is replaced by a nitrocellulose or other paper membrane onto which a small amount of sample volume is applied. The choice of binding matrix greatly improved the specificity and sensitivity of the assay by reducing the binding of nonspecific proteins usually observed when plastic binding matrixes are used. The principle is similar to the immunoblot. The dotted membrane is incubated first with an antigen-specific antibody followed by an enzyme-conjugated anti-antibody. The addition of a precipitable, chromogenic substrate causes the formation of a colored dot on the membrane which can be visually read [2]. The benefits of this technique include its ease of use, its rapidity, and the ease of result interpretation. It is fast, and cost-effective and more importantly can be used in the field (e.g., as a dipstick). For all these reasons, the Dot-ELISA has been and still is extensively used in the detection of human and animal parasitic diseases, including amebiasis, babesiosis, fascioliasis, cutaneous and visceral leishmaniasis, cysticercosis, echinococcosis, malaria, schistosomiasis, toxocariasis, toxoplasmosis, trichinosis, and trypanosomiasis (all reviewed in [3]). In the last few years, published studies have demonstrated the use of the dot-ELISA for the detection of *Fasciola gigantica* [113], *Haemonchus contortus* [162], *Theileria equi* [163], *Trypanosoma cruzi* [164], and *Trypanosoma brucei* [34]. In the latter study the researchers were able to demonstrate that the dot-ELISA had better sensitivity and specificity than the ELISA in the detection of antineurofilament and antigalactocerebrosides antibodies in cerebrospinal fluid of subjects infected with African trypanosomes. They attributed the greater sensitivity and specificity of the dot-ELISA to the use of the nitrocellulose membrane and showed that their assay was successfully reproducible in the field.

3.3. Rapid Antigen Detection System (RDTS). Rapid antigen detection tests (RDTs) based on immunochromatographic antigen detection have been implemented in many diagnostic laboratories as an adjunct to microscopy for the diagnosis of malaria. RDTs consist of capturing soluble proteins by complexing them with capture antibodies embedded on a nitrocellulose strip. A drop of blood sample is applied to the strip and eluted from the nitrocellulose strip by the addition of a few drops of buffer containing a labeled antibody. The antigen-antibody complex can then be visualized directly from the membrane [4].

Since the appearance of the first RDTs in the 990s, major improvements have been made to the technique, making the use of RDTs in rural endemic regions feasible. RDTs are now rapid, stable at temperatures up to 40°C, easy to use, and cost-effective thereby providing many advantages over traditional microscopic methods [165]. RDTs are useful in the identification of *P. falciparum* and *P. vivax* infections but cannot be used to identify *P. malariae* and *P. ovale* infections [4]. In addition, they are useless at detecting very low-density infections. PCR-based approaches remain the tool of choice in that situation. More than 80 RDTs exist for the detection of either histidine-rich protein (HRP) specific to *P. falciparum* or species-specific isotypes of lactate dehydrogenase (LDH) [49]. However, as reported by Murray et al. [165] only 23 have met the WHO's criteria for international marketing.

Malaria RDTs have recently been introduced in African countries to help prevent misdiagnosis of malaria infections and to subsequently reduce the practice of presumptive treatment [49]. In fact, the tendency to treat slide-negative samples with antimalarials is still a common phenomenon. This practice causes concern not only for the patient's health care but also to the costs it generates in prescribing the more expensive antimalarial sulfadoxine/pyrimethamine and artemisinin-based combinations [165]. Finally, misuse of antimalarials could lead to the appearance of drug-resistant strains.

3.4. Luciferase Immunoprecipitation System (LIPS). The luciferase immunoprecipitation system (LIPS) is a modified ELISA-based assay in which serum containing antigen-specific antibodies can be identified by measuring light production. Basically, an antigen of choice is fused to the enzyme reporter Renilla luciferase (Ruc) and expressed as a Ruc-fusion in mammalian cells to allow for mammalian-specific posttranslational modifications. The crude protein extract is then incubated with the test serum and protein A/G beads. During the incubation, the Ruc-antigen fusion becomes immobilized on the A/G beads, which allows the antigen-specific antibody to be quantitated by washing the beads and adding coelenterazine substrate and measuring light production [5].

In recent years, LIPS has been successfully applied for the identification of sera samples infected with *Strongyloides stercoralis* (using a Ruc-NIE fusion) [134] and *Loa loa* (using a Ruc-LlSXP-1 fusion) [133]. Some of the advantages of the LIPS technology include its rapidity and accuracy in detecting infected patients. Sensitivity is improved in part by the use of mammalian cells which produce fusion antigens free of contaminating bacterial proteins. In addition, low backgrounds are produced compared to the ELISA. This greatly facilitates the separation between negative and positive samples. In addition, the *Strongyloides* LIPS based on the NIE antigen showed greater specificity than the ELISA as no cross-reaction was observed with serum from filarial-infected subjects [134].

A LIPS assay can be performed in 2.5 hours. Burbelo et al. 2008 [133] were able to obtain 100% specificity and sensitivity when performing an LIPS assay based on the *Loa loa* SXP-1 antigen with only a small-degree of cross-reactivity with a few *Onchocerca volvulus*- and *Wuchereria bancrofti*-infected patient sera. By decreasing the incubation times of a normal LIPS assay, they were able to minimize cross-reaction. Many of the *O. volvulus* sera samples tested as positive with the LIPS assay were negative using this 15-minute LIPS assay also called QLIPS. Of interest for the application of this technique in the field is the observation that blood obtained by finger-prick (contaminated with red blood cells and other components) did not interfere with the LIPS assay. Further studies will be useful in exploring and validating the accuracy and potential usefulness of the LIPS and QLIPS assays in the field.

As discussed, immunodiagnostics tests have some serious limitations. Parasitic diseases such as amebiasis, cryptosporidiosis, filariasis, giardiasis, malaria, cysticercosis, schistosomiasis, and African trypanosomiasis do not have commercially or FDA approved antibody detection tests for their diagnosis. Experimental results have been too variable due to the type of antigen preparations used (e.g., crude, recombinant purified, adult worm, egg) and also because of the use of nonstandardized test procedures. Cross-reaction leading to false-positives and misdiagnosis is also a problem, especially in regions where more than one parasite is endemic. Despite the fact that some parasites in South America share common epitopes, it is common to see coinfection with *Trypanosoma cruzi* and *Leishmania* species [166]. It is also a problem in Africa, where cross-reactivity exists between filarial and other helminth antigens [133]. To a lesser extent but nonetheless important is the inability of antibody-detection tests to differentiate between past and currently active infections [167]. Furthermore, antibody-detection tests cannot be used in parasitic infections that do not develop a significant antibody response. This has been observed in some individuals carrying *Echinococcus* cysts [168] or during cutaneous leishmaniasis (http://www.dpd.cdc.gov/dpdx/HTML/Leishmaniasis.htm). Similarly, in the case of African trypanosomiasis diagnosis, such tests are of limited use because seroconversion occurs only after the onset of clinical symptoms [83].

For all these reasons, there is still a need to improve on the current diagnosis approaches available. Since the advent of the polymerase chain reaction (PCR), parasitologists have turned to molecular-based approaches in the hopes to better the existing diagnosis tools.

4. Molecular-Based Approaches

4.1. Nucleic Acid-Based Approaches. The many limitations of microscopy and serology-based assays have influenced parasitologists towards the use of gene amplification methods made possible with the advent of the polymerase chain reaction (PCR). Besides the traditional PCR, including nested and multiplexed PCR, we have seen the implementation of the real-time PCR (RT-PCR) for the detection of several parasitic infections. Newer technologies such as loop-mediated isothermal amplification and Luminex-based assays have also emerged as possible new approaches for the diagnosis of parasitic diseases.

Molecular-based approaches based on nucleic acids offer greater sensitivity and specificity over the existing diagnostic tests. They permit the detection of infections from very low parasitized samples including those from asymptomatic patient's samples [169]. Moreover, multiplexed PCR allows for the detection of multiple sequences in the same reaction tube proving useful in the diagnosis of several parasitic infections simultaneously [170].

4.2. Real-Time Polymerase Chain Reaction (RT-PCR). RT-PCR system unlike conventional PCR, allow for the quantification of the original template's concentration through the use of various fluorescent chemistries, such as Sybergreen, Taqman probes, fluorescence resonance energy transfer (FRET), and Scorpion primers [7]. The concentration is measured through comparison to standard curves. This eliminates the need to visualize the amplicons by gel electrophoresis thereby greatly reducing the risk of contamination and the introduction of false-positives. When multiplexed, RT-PCR allows for the high-throughput analysis of different sequences in one single-closed tube reaction [171]. Using multiplexed RT-PCR, Shokoples et al. [4] were able to identify the four human *Plasmodium* species (*falciparum*, *vivax*, *malariae*, and *ovale*) in a single reaction tube even in very low parasitized samples. Running the multiplex assay not only reduced the cost per test but also allowed for a rapid turnaround time, the assay taking only three hours to

complete. It is a clear advantage over microscopy which is labour intensive and time-consuming with slow turnaround times especially during high-throughput settings. Similarly, multiplexed RT-PCR proved useful in differentiating drug-sensitive strains of malaria [172]. This is important for proper antimalarial prescription. In another example, Diez et al. [54] were able to detect the presence of *T. cruzi* infection following heart transplants using PCR. This allowed immediate treatment of the patients before reactivation of Chagas disease could occur. These examples demonstrate that efficient and early diagnosis can directly impact patients care and that PCR-based approaches have the potential to help in making the right choice for treatment.

Although DNA-based methods have shown excellent sensitivity and specificity, the introduction of these methods in daily laboratory practice is still uncommon especially in rural endemic regions. In addition, as observed with many serology-based assays, PCR-based methods also suffer by the lack of standardization [22]. DNA extraction, choice of primer sets, and use of various amplification protocols are all factors that may cause this diversification in results [173]. Adding an automated DNA extraction step would certainly improve PCR assays for use in the diagnosis of parasitic diseases.

4.3. Loop-Mediated Isothermal Amplification (LAMP). Loop-mediated isothermal amplification (LAMP) is a unique amplification method with extremely high specificity and sensitivity able to discriminate between a single nucleotide difference [6]. It is characterised by the use of six different primers specifically designed to recognise eight distinct regions on a target gene, with amplification only occurring if all primers bind and form a product [174]. In the past, LAMP has been successfully applied for the rapid detection of both DNA and RNA viruses such as the West Nile [175] and SARS viruses [176]. Recently, parasitologists have adapted the LAMP approach for the detection of several parasitic diseases including the human parasites *Entamoeba* [177], *Trypanosoma* [68], *Taenia* [153], *Plasmodium* [70], and *Cryptosporidium* [152], the animal parasites *Theilera* [178] and *Babesia* [178, 179], and even to the identification of vector mosquitoes carrying *Plasmodium* [73] and *Dirofilaria immitis* [180] parasites. Most of these studies have brought to light the many advantages of this method over the common PCR technique.

Unlike a regular PCR reaction, LAMP is carried out at a constant temperature (usually in the range of 60–65°C). This unique feature not only results in higher yields, but also eliminates the need to buy a thermal cycler and shortens the reaction time by eliminating time lost during thermal changes. In addition, the reaction can be carried out without extracting the DNA from the collected samples as shown in the case of RIME, a nonautonomous retroelement found in *Trypanosoma brucei rhodesiense* and *T. b. gambiense* [68]. In 35 minutes, using a simple water bath, RIME LAMP was able to detect both *T. b. gambiense* and *T. b. rhodesiense* directly from blood, serum, and CSF samples. More importantly, the study has shown reproducibility in the field. In addition to the above advantages, LAMP reactions are easy to set up, and results can readily be assessed. The sample of interest is mixed with primers, substrates, and a DNA polymerase capable of strand displacement in a microcentrifuge tube. During the reaction, large amounts of pyrophosphate ions are produced, leading to the formation of a white precipitate [181]. This turbidity is proportional with the amount of DNA synthesized therefore one can assess the reaction by real-time measurement of turbidity or more importantly, simply through the naked-eye.

For all these reasons, the future adoption of LAMP as a diagnostic tool for parasite infections in rural endemic regions shows promise. Furthermore, as more groups apply LAMP to the field of parasitology, we will see the appearance of LAMP-modified assays that meet specific detection needs. For example, in a recent study on bovine Babesia [182], a multiplex-LAMP (mLAMP) assay was developed to simultaneously detect *B. bovis* and *B. bigemina* from DNA extracted from blood spotted on filter paper. Similarly, Han et al. [71] implemented a LAMP assay based on the 18S rRNA gene for the detection of the four human *Plasmodium* species (*falciparum*, *vivax*, *malariae*, and *ovale*). LAMP had a similar sensitivity and a greater specificity than nested PCR, yielding similar results but at a faster turnaround time. Their results are consistent with other studies demonstrating the rapidity and the improved specificity and sensitivity obtained using the LAMP assay.

4.4. Luminex xMAP Technology. Luminex technology is a bead-based flow-cytometric assay that allows the detection of various targets simultaneously (http://www.luminexcorp.com/). The microsphere beads can be covalently bound to antigens, antibodies, or oligonucleotides that will serve as probes in the assay. Up to 100 microspheres are available each emitting unique fluorescent signals when excited by laser therefore allowing the identification of different targets [183]. Adapted to the study of parasites, the Luminex assay could identify multiple organisms or different genotypes of one particular organism during the same reaction utilizing very low volume. The approach could prove useful in the study of antigenic diversity and drug-resistance alleles and for the diagnosis of parasitic diseases.

Luminex was applied to the study of *Cryptosporidium* [154]. *C. hominis* and *C. parvum* cannot be distinguished using antigen detection or serology assays. Only DNA-based approaches have been successful in doing so by exploiting the single nucleotide difference in the microsatellite-2 region (ML-2) of both species [154]. Ultimately DNA sequencing is the diagnosis tool of choice but it is costly, labour-intensive and time-consuming. In a recent study, Bandyopadhyay et al. [154] successfully detected and distinguished *C. hominis* and *C. parvum* in 143 DNA extracts using Luminex technology by using oligonucleotide probes specific to the ML-2 regions of each species. Turnaround time was about 5 hours making this assay not only much faster but also less expensive than PCR followed by DNA sequencing. It also proved to be 100% specific and more sensitive than a direct fluorescent antibody (DFA) test, a method routinely

used to identify *Cryptosporidium* and *Giardia* species. Note that DFA cannot differentiate between *C. hominis* and *C. parvum*.

Similarly in other research, Luminex technology was able to detect all-blood stage parasite levels of the four human *Plasmodium* species (*falciparum*, *vivax*, *malariae*, and *ovale*) simultaneously [75]. This study demonstrated that Luminex technology can improve the speed, the accuracy, and the reliability of other PCR methods. For example, the need for gel electrophoresis to differentiate the LDR products representing the four human Plasmodium species is eliminated. Second, all samples are handled simultaneously and continuously through a 96-well plate format from DNA extraction all through data analysis. The process is automated and therefore uniformity can be achieved. Finally, the high-throughput capability of the Luminex system confers it a clear advantage over the use of labour-intensive microscopy for large scale studies.

4.5. Proteomics. Since proteins are the main catalysts, structural elements, signalling messengers, and molecular machines of biological tissues, proteomic studies are able to provide substantial clinical relevance. Proteins can be utilized as biomarkers for tissues, cell types, developmental stages, and disease states as well as potential targets for drug discovery and interventional approaches. The next generation of diagnostic tests for infectious diseases will emerge from proteomic studies of serum and other body fluids. Recent advances in this area are attributable largely to the introduction of mass spectrometry platforms capable of screening complex biological fluids for individual protein and peptide "biomarkers." Proteomic strategy can identify proteins in two ways: bottom-up and top-down approaches. In the former, the proteins in a biological fluid are proteolytically shattered into small fragments that can be easily sequenced and the resultant spectra are compared with those in established peptide databases. This is the protein equivalent of "shotgun" genomics. Bottom-up strategies are difficult to quantitate and cannot identify modified molecules (e.g., alternately spliced, glycosylated). Since each open reading frame in the human genome is thought to generate at least 10 modified proteins, this issue is a major limitation.

The classic top-down strategy is 2-dimensional gel electrophoresis. Top-down strategies seek to identify proteins and peptides (and their natural variants) in complex biological fluids. Two-dimensional (2D) gel electrophoresis was first described in 1975. With this method, proteins are resolved in the first dimension based on pH (a process called isoelectric focusing) and in the second dimension by their molecular weight. This technique is labor intensive, and low throughput and requires large amounts of sample. Such limitations have encouraged the search for improved approaches. Other techniques used for the expression analysis of proteins are matrix-assisted laser desorption ionization time-of-flight mass spectrometry (MALDI-TOF MS), surface-enhanced laser desorption ionization time of flight mass spectrometry (SELDI-TOF MS), liquid chromatography combined with MS (LC–MS–MS), isotope-coded affinity tags (ICAT), and isotope tags for relative and absolute quantification (iTRAQ).

The development of automated, high-throughput proteomic technologies such as MALDI-TOF and SELDI-TOF MS has enabled large numbers of clinical samples to be analyzed simultaneously in a short time. These platforms have made "population-based proteomics" feasible for the first time (reviewed in [184]). All proteomics-based diagnostic efforts seek to identify biomarkers that, alone or in combination, can distinguish between "case" and "control" groups.

The main limitation of SELDI compared to MALDI resides in the fact that SELDI has lower resolution and lower mass accuracy. In addition, SELDI is unsuitable for high molecular weight proteins (>100 kDa) and is limited to the detection of bound proteins on to the ProteinChip Array.

Most studies published about parasitic diseases have focused on SELDI. The SELDI, a derivation of MALDI, allows sample binding to chemically active ProteinChip surfaces. Several types of ProteinChip arrays are available with differing abilities to bind proteins with different chemical (anionic, cationic, hydrophobic, metallic, and normal phase) or biological (antibody, enzymes, receptors) properties, thereby allowing the direct analysis of proteins from complex biological samples without the need for prior separation by 2D gel electrophoresis. The output of the SELDI is a spectrum of mass-to-charge ratios (m:z values) with their corresponding relative intensities (approximating to relative abundance).

SELDI analyses were initially applied to the discovery of early diagnostic or prognostic biomarkers of cancer (reviewed in [185]). Recently, this technique has been applied to the study of serum biomarkers of infectious diseases such as Severe Acute Respiratory Syndrome [186], African trypanosomiasis [83], fascioliasis [157], cysticercosis [158], and Chagas diseases (Ndao et al., submitted). Such studies have focused on identifying a distinctive configuration of circulating serum proteins that are indicative of a specific pathophysiological state, a so-called "proteomic fingerprint."

The real potential of proteomic fingerprinting is in its use as a discovery tool for novel biomarkers that can then be incorporated into simple bedside diagnostics based on affordable technologies such as immunologically based antigen-detection tests that could be implemented in dipstick or cassette formats.

Acknowledgments

The author would like to thank the Public Health Agency of Canada and the National Microbiology Laboratory for supporting the National Reference Centre for Parasitology.

References

[1] K. Hancock and V. C. W. Tsang, "Development and optimization of the FAST-ELISA for detecting antibodies to Schistosoma mansoni," *Journal of Immunological Methods*, vol. 92, no. 2, pp. 167–176, 1986.

[2] M. G. Pappas, R. Hajkowski, and W. T. Hockmeyer, "Dot enzyme-linked immunosorbent assay (Dot-ELISA): a micro technique for the rapid diagnosis of visceral leishmaniasis," *Journal of Immunological Methods*, vol. 64, no. 1-2, pp. 205–214, 1983.

[3] M. G. Pappas, "Recent applications of the Dot-ELISA in immunoparasitology," *Veterinary Parasitology*, vol. 29, no. 2-3, pp. 105–129, 1988.

[4] S. E. Shokoples, M. Ndao, K. Kowalewska-Grochowska, and S. K. Yanow, "Multiplexed real-time PCR assay for discrimination of Plasmodium species with improved sensitivity for mixed infections," *Journal of Clinical Microbiology*, vol. 47, no. 4, pp. 975–980, 2009.

[5] P. D. Burbelo, R. Goldman, and T. L. Mattson, "A simplified immunoprecipitation method for quantitatively measuring antibody responses in clinical sera samples by using mammalian-produced Renilla luciferase-antigen fusion proteins," *BMC Biotechnology*, vol. 5, article 22, 2005.

[6] M. M. Parida, S. Sannarangaiah, P. K. Dash, P. V. L. Rao, and K. Morita, "Loop mediated isothermal amplification (LAMP): a new generation of innovative gene amplification technique; perspectives in clinical diagnosis of infectious diseases," *Reviews in Medical Virology*, vol. 18, no. 6, pp. 407–421, 2008.

[7] K. L. Muldrew, "Molecular diagnostics of infectious diseases," *Current Opinion in Pediatrics*, vol. 21, no. 1, pp. 102–111, 2009.

[8] B. D. Tait, F. Hudson, L. Cantwell, et al., "Review article: luminex technology for HLA antibody detection in organ transplantation," *Nephrology*, vol. 14, no. 2, pp. 247–254, 2009.

[9] M. Ndao, N. Kelly, D. Normandin, et al., "Trypanosoma cruzi infection of squirrel monkeys: comparison of blood smear examination, commercial enzyme-linked immunosorbent assay, and polymerase chain reaction analysis as screening tests for evaluation of monkey-related injuries," *Comparative Medicine*, vol. 50, no. 6, pp. 658–665, 2000.

[10] G. R. Healy and T. K. Ruebush II, "Morphology of Babesia microti in human blood smears," *American Journal of Clinical Pathology*, vol. 73, no. 1, pp. 107–109, 1980.

[11] H. B. Tanowitz, L. V. Kirchhoff, D. Simon, S. A. Morris, L. M. Weiss, and M. Wittner, "Chagas' disease," *Clinical Microbiology Reviews*, vol. 5, no. 4, pp. 400–419, 1992.

[12] B. L. Herwaldt, "Leishmaniasis," *The Lancet*, vol. 354, no. 9185, pp. 1191–1199, 1999.

[13] P. Duffy and M. Fried, "Malaria: new diagnostics for an old problem," *The American Journal of Tropical Medicine and Hygiene*, vol. 73, no. 3, pp. 482–483, 2005.

[14] W. D. Melrose, D. D. Durrheim, and G. W. Burgess, "Update on immunological tests for lymphatic filariasis," *Trends in Parasitology*, vol. 20, no. 6, pp. 255–257, 2004.

[15] F. Cobo, L. Aliaga, P. Talavera, and A. Concha, "The histological spectrum of non-granulomatous localized mucosal leishmaniasis caused by Leishmania infantum," *Annals of Tropical Medicine and Parasitology*, vol. 101, no. 8, pp. 689–694, 2007.

[16] D. J. P. Ferguson, W. M. Hutchison, and E. Pettersen, "Tissue cyst rupture in mice chronically infected with Toxoplasma gondii. An immunocytochemical and ultrastructural study," *Parasitology Research*, vol. 75, no. 8, pp. 599–603, 1989.

[17] T. A. Sims, J. Hay, and I. C. Talbot, "An electron microscope and immunohistochemical study of the intracellular location of Toxoplasma tissue cysts within the brains of mice with congenital toxoplasmosis," *British Journal of Experimental Pathology*, vol. 70, no. 3, pp. 317–325, 1989.

[18] F. Chappuis, S. Rijal, A. Soto, J. Menten, and M. Boelaert, "A meta-analysis of the diagnostic performance of the direct agglutination test and rK39 dipstick for visceral leishmaniasis," *British Medical Journal*, vol. 333, no. 7571, pp. 723–726, 2006.

[19] S. Ozensoy, Y. Ozbel, N. Turgay, et al., "Serodiagnosis and epidemiology of visceral leishmaniasis in Turkey," *The American Journal of Tropical Medicine and Hygiene*, vol. 59, no. 3, pp. 363–369, 1998.

[20] I. Cruz, C. Chicharro, J. Nieto, et al., "Comparison of new diagnostic tools for management of pediatric Mediterranean visceral leishmaniasis," *Journal of Clinical Microbiology*, vol. 44, no. 7, pp. 2343–2347, 2006.

[21] A. M. Croft, C. J. Jackson, H. M. Friend, and E. J. Minton, "African trypanosomiasis in a British soldier," *Journal of the Royal Army Medical Corps*, vol. 152, no. 3, pp. 156–160, 2006.

[22] T. S. Murray and M. Cappello, "The molecular diagnosis of parasitic diseases," *Pediatric Infectious Disease Journal*, vol. 27, no. 2, pp. 163–164, 2008.

[23] F. Chappuis, L. Loutan, P. Simarro, V. Lejon, and P. Buscher, "Options for field diagnosis of human African trypanosomiasis," *Clinical Microbiology Reviews*, vol. 18, no. 1, pp. 133–146, 2005.

[24] V. Lejon, P. Buscher, E. Magnus, A. Moons, I. Wouters, and N. Van Meirvenne, "A semi-quantitative ELISA for detection of *Trypanosoma brucei* gambiense specific antibodies in serum and cerebrospinal fluid of sleeping sickness patients," *Acta Tropica*, vol. 69, no. 2, pp. 151–164, 1998.

[25] V. Lejon, J. Kwete, and P. Buscher, "Short communication: towards saliva-based screening for sleeping sickness?" *Tropical Medicine and International Health*, vol. 8, no. 7, pp. 585–588, 2003.

[26] C. C. Loa, M. E. Adelson, E. Mordechai, I. Raphaelli, and R. C. Tilton, "Serological diagnosis of human babesiosis by IgG enzyme-linked immunosorbent assay," *Current Microbiology*, vol. 49, no. 6, pp. 385–389, 2004.

[27] M. Nakazawa, D. S. Rosa, V. R. A. Pereira, et al., "Excretory-secretory antigens of Trypanosoma cruzi are potentially useful for serodiagnosis of chronic Chagas' disease," *Clinical and Diagnostic Laboratory Immunology*, vol. 8, no. 5, pp. 1024–1027, 2001.

[28] M. Berrizbeitia, M. Ndao, J. Bubis, et al., "Purified excreted-secreted antigens from trypanosoma cruzi trypomastigotes as tools for diagnosis of Chagas' disease," *Journal of Clinical Microbiology*, vol. 44, no. 2, pp. 291–296, 2006.

[29] E. S. Umezawa, S. F. Bastos, J. R. Coura, et al., "An improved serodiagnostic test for Chagas' disease employing a mixture of Trypanosoma cruzi recombinant antigens," *Transfusion*, vol. 43, no. 1, pp. 91–97, 2003.

[30] J. F. da Silveira, E. S. Umezawa, and A. O. Luquetti, "Chagas disease: recombinant Trypanosoma cruzi antigens for serological diagnosis," *Trends in Parasitology*, vol. 17, no. 6, pp. 286–291, 2001.

[31] E. Beghetto, W. Buffolano, A. Spadoni, et al., "Use of an immunoglobulin G avidity assay based on recombinant antigens for diagnosis of primary Toxoplasma gondii infection during pregnancy," *Journal of Clinical Microbiology*, vol. 41, no. 12, pp. 5414–5418, 2003.

[32] G. H. Campbell, S. B. Aley, W. R. Ballou, et al., "Use of synthetic and recombinant peptides in the study of host-parasite interactions in the malarias," *The American Journal*

of Tropical Medicine and Hygiene, vol. 37, no. 3, pp. 428–444, 1987.

[33] M. Salcedo, L. Barreto, M. Rojas, R. Moya, J. Cote, and M. E. Patarroyo, "Studies on the humoral immune response to a synthetic vaccine against Plasmodium falciparum malaria," *Clinical and Experimental Immunology*, vol. 84, no. 1, pp. 122–128, 1991.

[34] B. Courtioux, S. Bisser, P. M'Belesso, et al., "Dot enzyme-linked immunosorbent assay for more reliable staging of patients with human African trypanosomiasis," *Journal of Clinical Microbiology*, vol. 43, no. 9, pp. 4789–4795, 2005.

[35] F. G. Araujo, "A method for demonstration of antibodies to Trypanosoma cruzi by using antigen-coated nitrocellulose paper strips," *The American Journal of Tropical Medicine and Hygiene*, vol. 34, no. 2, pp. 242–245, 1985.

[36] L. V. Kirchhoff, A. A. Gam, R. A. Gusmao, R. S. Goldsmith, J. M. Rezende, and A. Rassi, "Increased specificity of serodiagnosis of Chagas' disease by detection of antibody to the 72- and 90-kilodalton glycoproteins of Trypanosoma cruzi," *Journal of Infectious Diseases*, vol. 155, no. 3, pp. 561–564, 1987.

[37] D. A. Leiby, S. Wendel, D. T. Takaoka, R. M. Fachini, L. C. Oliveira, and M. A. Tibbals, "Serologic testing for Trypanosoma cruzi: comparison of radioimmunoprecipitation assay with commercially available indirect immunofluorescence assay, indirect hemagglutination assay, and enzyme-linked immunosorbent assay kits," *Journal of Clinical Microbiology*, vol. 38, no. 2, pp. 639–642, 2000.

[38] E. Magnus, T. Vervoort, and N. Van Meirvenne, "A card-agglutination test with stained trypanosomes (C.A.T.T.) for the serological diagnosis of T. B. gambiense trypanosomiasis," *Annales de la Société Belge de Médecine Tropicale*, vol. 58, no. 3, pp. 169–176, 1978.

[39] F. Noireau, J. L. Lemesre, M. Y. Nzoukoudi, M. T. Louembet, J. P. Gouteux, and J. L. Frezil, "Serodiagnosis of sleeping sickness in the Republic of the Congo: comparison of indirect immunofluorescent antibody test and card agglutination test," *Transactions of the Royal Society of Tropical Medicine and Hygiene*, vol. 82, no. 2, pp. 237–240, 1988.

[40] P. J. Krause, R. Ryan, S. Telford III, D. Persing, and A. Spielman, "Efficacy of immunoglobulin M serodiagnostic test for rapid diagnosis of acute babesiosis," *Journal of Clinical Microbiology*, vol. 34, no. 8, pp. 2014–2016, 1996.

[41] P. J. Krause, S. R. Telford III, R. Ryan, et al., "Diagnosis of babesiosis: evaluation of a serologic test for the detection of Babesia microti antibody," *Journal of Infectious Diseases*, vol. 169, no. 4, pp. 923–926, 1994.

[42] A. J. Sulzer and M. Wilson, "The fluorescent antibody test for malaria," *CRC Critical Reviews in Clinical Laboratory Sciences*, vol. 2, no. 4, pp. 601–619, 1971.

[43] M. E. Camargo, "Improved technique of indirect immunofluorescence for serological diagnosis of toxoplasmosis," *Revista do Instituto de Medicina Tropical de Sao Paulo*, vol. 12, pp. 117–118, 1964.

[44] E. S. Umezawa, M. S. Nascimento, and A. M. S. Stolf, "Enzyme-linked immunosorbent assay with Trypanosoma cruzi excreted-secreted antigens (TESA-ELISA) for serodiagnosis of acute and chronic Chagas' disease," *Diagnostic Microbiology and Infectious Disease*, vol. 39, no. 3, pp. 169–176, 2001.

[45] K. Y. Cheng, C.-D. Chang, V. A. Salbilla, et al., "Immunoblot assay using recombinant antigens as a supplemental test to confirm the presence of antibodies to Trypanosoma cruzi," *Clinical and Vaccine Immunology*, vol. 14, no. 4, pp. 355–361, 2007.

[46] V. Rilling, K. Dietz, D. Krczal, F. Knotek, and G. Enders, "Evaluation of a commercial IgG/IgM Western blot assay for early postnatal diagnosis of congenital toxoplasmosis," *European Journal of Clinical Microbiology and Infectious Diseases*, vol. 22, no. 3, pp. 174–180, 2003.

[47] C.-D. Chang, K. Y. Cheng, L. X. Jiang, et al., "Evaluation of a prototype Trypanosoma cruzi antibody assay with recombinant antigens on a fully automated chemiluminescence analyzer for blood donor screening," *Transfusion*, vol. 46, no. 10, pp. 1737–1744, 2006.

[48] A. O. Luquetti, C. Ponce, E. Ponce, et al., "Chagas' disease diagnosis: a multicentric evaluation of Chagas Stat-Pak, a rapid immunochromatographic assay with recombinant proteins of Trypanosoma cruzi," *Diagnostic Microbiology and Infectious Disease*, vol. 46, no. 4, pp. 265–271, 2003.

[49] C. Drakeley and H. Reyburn, "Out with the old, in with the new: the utility of rapid diagnostic tests for malaria diagnosis in Africa," *Transactions of the Royal Society of Tropical Medicine and Hygiene*, vol. 103, no. 4, pp. 333–337, 2009.

[50] P. J. Krause, S. Telford III, A. Spielman, et al., "Comparison of PCR with blood smear and inoculation of small animals for diagnosis of Babesia microti parasitemia," *Journal of Clinical Microbiology*, vol. 34, no. 11, pp. 2791–2794, 1996.

[51] D. H. Persing, D. Mathiesen, W. F. Marshall, et al., "Detection of Babesia microti by polymerase chain reaction," *Journal of Clinical Microbiology*, vol. 30, no. 8, pp. 2097–2103, 1992.

[52] D. R. Moser, L. V. Kirchhoff, and J. E. Donelson, "Detection of Trypanosoma cruzi by DNA amplification using the polymerase chain reaction," *Journal of Clinical Microbiology*, vol. 27, no. 7, pp. 1477–1482, 1989.

[53] R. Gutierrez, V. M. Angulo, Z. Tarazona, C. Britto, and O. Fernandes, "Comparison of four serological tests for the diagnosis of Chagas disease in a Colombian endemic area," *Parasitology*, vol. 129, no. 4, pp. 439–444, 2004.

[54] M. Diez, L. Favaloro, A. Bertolotti, et al., "Usefulness of PCR strategies for early diagnosis of Chagas' disease reactivation and treatment follow-up in heart transplantation," *American Journal of Transplantation*, vol. 7, no. 6, pp. 1633–1640, 2007.

[55] S. Singh, A. Dey, and R. Sivakumar, "Applications of molecular methods for Leishmania control," *Expert Review of Molecular Diagnostics*, vol. 5, no. 2, pp. 251–265, 2005.

[56] L. K. Erdman and K. C. Kain, "Molecular diagnostic and surveillance tools for global malaria control," *Travel Medicine and Infectious Disease*, vol. 6, no. 1-2, pp. 82–99, 2008.

[57] P. V. Vidigal, D. V. Santos, F. C. Castro, J. C. Couto, R. W. Vitor, and G. Brasileiro Filho, "Prenatal toxoplasmosis diagnosis from amniotic fluid by PCR," *Revista da Sociedade Brasileira de Medicina Tropical*, vol. 35, no. 1, pp. 1–6, 2002.

[58] M. H. Bessieres, A. Berrebi, S. Cassaing, et al., "Diagnosis of congenital toxoplasmosis: prenatal and neonatal evaluation of methods used in Toulouse University Hospital and incidence of congenital toxoplasmosis," *Memorias do Instituto Oswaldo Cruz*, vol. 104, no. 2, pp. 389–392, 2009.

[59] S. Becker, J. R. Franco, P. P. Simarro, A. Stich, P. M. Abel, and D. Steverding, "Real-time PCR for detection of Trypanosoma brucei in human blood samples," *Diagnostic Microbiology and Infectious Disease*, vol. 50, no. 3, pp. 193–199, 2004.

[60] S. Bretagne, R. Durand, M. Olivi, et al., "Real-time PCR as a new tool for quantifying Leishmania infantum in liver in infected mice," *Clinical and Diagnostic Laboratory Immunology*, vol. 8, no. 4, pp. 828–831, 2001.

[61] C. Mary, F. Faraut, L. Lascombe, and H. Dumon, "Quantification of Leishmania infantum DNA by a real-time PCR assay with high sensitivity," *Journal of Clinical Microbiology*, vol. 42, no. 11, pp. 5249–5255, 2004.

[62] N. Rolao, S. Cortes, O. R. Rodrigues, and L. Campino, "Quantification of Leishmania infantum parasites in tissue biopsies by real-time polymerase chain reaction and polymerase chain reaction-enzyme-linked immunosorbent assay," *Journal of Parasitology*, vol. 90, no. 5, pp. 1150–1154, 2004.

[63] S. Romand, M. Chosson, J. Franck, et al., "Usefulness of quantitative polymerase chain reaction in amniotic fluid as early prognostic marker of fetal infection with Toxoplasma gondii," *American Journal of Obstetrics and Gynecology*, vol. 190, no. 3, pp. 797–802, 2004.

[64] W. F. van der Meide, G. J. Schoone, W. R. Faber, et al., "Quantitative nucleic acid sequence-based assay as a new molecular tool for detection and quantification of Leishmania parasites in skin biopsy samples," *Journal of Clinical Microbiology*, vol. 43, no. 11, pp. 5560–5566, 2005.

[65] G. J. Schoone, L. Oskam, N. C. M. Kroon, H. D. F. H. Schallig, and S. A. Omar, "Detection and quantification of Plasmodium falciparum in blood samples using quantitative nucleic acid sequence-based amplification," *Journal of Clinical Microbiology*, vol. 38, no. 11, pp. 4072–4075, 2000.

[66] S. A. Omar, P. F. Mens, G. J. Schoone, et al., "Plasmodium falciparum: evaluation of a quantitative nucleic acid sequence-based amplification assay to predict the outcome of sulfadoxine-pyrimethamine treatment of uncomplicated malaria," *Experimental Parasitology*, vol. 110, no. 1, pp. 73–79, 2005.

[67] P. F. Mens, G. J. Schoone, P. A. Kager, and H. D. F. H. Schallig, "Detection and identification of human Plasmodium species with real-time quantitative nucleic acid sequence-based amplification," *Malaria Journal*, vol. 5, article 80, 2006.

[68] Z. K. Njiru, A. S. J. Mikosza, E. Matovu, et al., "African trypanosomiasis: sensitive and rapid detection of the subgenus Trypanozoon by loop-mediated isothermal amplification (LAMP) of parasite DNA," *International Journal for Parasitology*, vol. 38, no. 5, pp. 589–599, 2008.

[69] O. M. M. Thekisoe, N. Kuboki, A. Nambota, et al., "Species-specific loop-mediated isothermal amplification (LAMP) for diagnosis of trypanosomosis," *Acta Tropica*, vol. 102, no. 3, pp. 182–189, 2007.

[70] L. L. M. Poon, B. W. Y. Wong, E. H. T. Ma, et al., "Sensitive and inexpensive molecular test for falciparum malaria: defecting Plasmodium falciparum DNA directly from heat-treated blood by loop-mediated isothermal amplification," *Clinical Chemistry*, vol. 52, no. 2, pp. 303–306, 2006.

[71] E.-T. Han, R. Watanabe, J. Sattabongkot, et al., "Detection of four Plasmodium species by genus- and species-specific loop-mediated isothermal amplification for clinical diagnosis," *Journal of Clinical Microbiology*, vol. 45, no. 8, pp. 2521–2528, 2007.

[72] D. H. Paris, M. Imwong, A. M. Faiz, et al., "Loop-mediated isothermal PCR (LAMP) for the diagnosis of falciparum malaria," *The American Journal of Tropical Medicine and Hygiene*, vol. 77, no. 5, pp. 972–976, 2007.

[73] H. Aonuma, M. Suzuki, H. Iseki, et al., "Rapid identification of Plasmodium-carrying mosquitoes using loop-mediated isothermal amplification," *Biochemical and Biophysical Research Communications*, vol. 376, no. 4, pp. 671–676, 2008.

[74] M. Yamamura, K. Makimura, and Y. Ota, "Evaluation of a new rapid molecular diagnostic system for Plasmodium falciparum combined with DNA filter paper, loop-mediated isothermal amplification, and melting curve analysis," *Japanese Journal of Infectious Diseases*, vol. 62, no. 1, pp. 20–25, 2009.

[75] D. T. McNamara, L. J. Kasehagen, B. T. Grimberg, J. Cole-Tobian, W. E. Collins, and P. A. Zimmerman, "Diagnosing infection levels of four human malaria parasite species by a polymerase chain reaction/ligase detection reaction fluorescent microsphere-based assay," *The American Journal of Tropical Medicine and Hygiene*, vol. 74, no. 3, pp. 413–421, 2006.

[76] S. De Doncker, V. Hutse, S. Abdellati, et al., "A new PCR-ELISA for diagnosis of visceral leishmaniasis in blood of HIV-negative subjects," *Transactions of the Royal Society of Tropical Medicine and Hygiene*, vol. 99, no. 1, pp. 25–31, 2005.

[77] A. Humar, M. A. Harrington, and K. C. Kain, "Evaluation of a non-isotopic polymerase chain reaction-based assay to detect and predict treatment failure of Plasmodium vivax malaria in travellers," *Transactions of the Royal Society of Tropical Medicine and Hygiene*, vol. 91, no. 4, pp. 406–409, 1997.

[78] K. J. Y. Zhong and K. C. Kain, "Evaluation of a colorimetric PCR-based assay to diagnose Plasmodium falciparum malaria in travelers," *Journal of Clinical Microbiology*, vol. 37, no. 2, pp. 339–341, 1999.

[79] A. Calderaro, G. Piccolo, C. Zuelli, et al., "Evaluation of a new plate hybridization assay for the laboratory diagnosis of imported malaria in Italy," *New Microbiologica*, vol. 27, no. 2, pp. 163–171, 2004.

[80] S. Deborggraeve, F. Claes, T. Laurent, et al., "Molecular dipstick test for diagnosis of sleeping sickness," *Journal of Clinical Microbiology*, vol. 44, no. 8, pp. 2884–2889, 2006.

[81] R. Reithinger and J.-C. Dujardin, "Molecular diagnosis of leishmaniasis: current status and future applications," *Journal of Clinical Microbiology*, vol. 45, no. 1, pp. 21–25, 2007.

[82] D. Agranoff, A. Stich, P. Abel, and S. Krishna, "Proteomic fingerprinting for the diagnosis of human African trypanosomiasis," *Trends in Parasitology*, vol. 21, no. 4, pp. 154–157, 2005.

[83] M. C. Papadopoulos, P. M. Abel, D. Agranoff, et al., "A novel and accurate diagnostic test for human African trypanosomiasis," *The Lancet*, vol. 363, no. 9418, pp. 1358–1363, 2004.

[84] M. Nyunt, J. Pisciotta, A. B. Feldman, et al., "Detection of Plasmodium falciparum in pregnancy by laser desorption mass spectrometry," *The American Journal of Tropical Medicine and Hygiene*, vol. 73, no. 3, pp. 485–490, 2005.

[85] P. A. Demirev, A. B. Feldman, D. Kongkasuriyachai, P. Scholl, D. Sullivan Jr., and N. Kumar, "Detection of malaria parasites in blood by laser desorption mass spectrometry," *Analytical Chemistry*, vol. 74, no. 14, pp. 3262–3266, 2002.

[86] P. F. Scholl, D. Kongkasuriyachai, P. A. Demirev, et al., "Rapid detection of malaria infection in vivo by laser desorption mass spectrometry," *The American Journal of Tropical Medicine and Hygiene*, vol. 71, no. 5, pp. 546–551, 2004.

[87] R. J. ten Hove, M. van Esbroeck, T. Vervoort, J. van den Ende, L. van Lieshout, and J. J. Verweij, "Molecular diagnostics of intestinal parasites in returning travellers," *European Journal of Clinical Microbiology and Infectious Diseases*, vol. 28, no. 9, pp. 1045–1053, 2009.

[88] M. Cordova, L. Reategui, and J. R. Espinoza, "Immunodiagnosis of human fascioliasis with Fasciola hepatica cysteine

proteinases," *Transactions of the Royal Society of Tropical Medicine and Hygiene*, vol. 93, no. 1, pp. 54–57, 1999.

[89] N. Katz, A. Chaves, and J. Pellegrino, "A simple device for quantitative stool thick-smear technique in Schistosomiasis mansoni," *Revista do Instituto de Medicina Tropical de Sao Paulo*, vol. 14, no. 6, pp. 397–400, 1972.

[90] W. Zhang and D. P. McManus, "Recent advances in the immunology and diagnosis of echinococcosis," *FEMS Immunology and Medical Microbiology*, vol. 47, no. 1, pp. 24–41, 2006.

[91] R. Chandrashekar, K. C. Curtis, R. M. Ramzy, F. Liftis, B.-W. Li, and G. J. Weil, "Molecular cloning of Brugia malayi antigens for diagnosis of lymphatic filariasis," *Molecular and Biochemical Parasitology*, vol. 64, no. 2, pp. 261–271, 1994.

[92] A. A. Siddiqui and S. L. Berk, "Diagnosis of Strongyloides stercoralis infection," *Clinical Infectious Diseases*, vol. 33, no. 7, pp. 1040–1047, 2001.

[93] T. Weitzel, S. Dittrich, I. Mohl, E. Adusu, and T. Jelinek, "Evaluation of seven commercial antigen detection tests for Giardia and Cryptosporidium in stool samples," *Clinical Microbiology and Infection*, vol. 12, no. 7, pp. 656–659, 2006.

[94] M. T. Katanik, S. K. Schneider, J. E. Rosenblatt, G. S. Hall, and G. W. Procop, "Evaluation of ColorPAC Giardia/Cryptosporidium rapid assay and ProSpect Giardia/Cryptosporidium microplate assay for detection of Giardia and Cryptosporidium in fecal specimens," *Journal of Clinical Microbiology*, vol. 39, no. 12, pp. 4523–4525, 2001.

[95] J. R. Espinoza, V. Maco, L. Marcos, et al., "Evaluation of FAS2-ELISA for the serological detection of Fasciola hepatica infection in humans," *The American Journal of Tropical Medicine and Hygiene*, vol. 76, no. 5, pp. 977–982, 2007.

[96] A. Rabello, "Diagnosing schistosomiasis," *Memorias do Instituto Oswaldo Cruz*, vol. 92, no. 5, pp. 669–676, 1997.

[97] J. Pardo, J. L. P. Arellano, R. Lopez-Velez, C. Carranza, M. Cordero, and A. Muro, "Application of an ELISA test using Schistosoma bovis adult worm antigens in travellers and immigrants from a schistosomiasis endemic area and its correlation with clinical findings," *Scandinavian Journal of Infectious Diseases*, vol. 39, no. 5, pp. 435–440, 2007.

[98] N. Rosas, J. Sotelo, and D. Nieto, "ELISA in the diagnosis of neurocysticercosis," *Archives of Neurology*, vol. 43, no. 4, pp. 353–356, 1986.

[99] J. C. Allan, G. Avila, J. Garcia Noval, A. Flisser, and P. S. Craig, "Immunodiagnosis of taeniasis by coproantigen detection," *Parasitology*, vol. 101, no. 3, pp. 473–477, 1990.

[100] H. H. Garcia, R. M. E. Parkhouse, R. H. Gilman, et al., "Serum antigen detection in the diagnosis, treatment, and follow-up of neurocysticercosis patients," *Transactions of the Royal Society of Tropical Medicine and Hygiene*, vol. 94, no. 6, pp. 673–676, 2000.

[101] E. C. Bueno, C. M. Scheel, A. J. Vaz, et al., "Application of synthetic 8-kD and recombinant GP50 antigens in the diagnosis of neurocysticercosis by enzyme-linked immunosorbent assay," *The American Journal of Tropical Medicine and Hygiene*, vol. 72, no. 3, pp. 278–283, 2005.

[102] B. Gottstein, "Molecular and immunological diagnosis of echinococcosis," *Clinical Microbiology Reviews*, vol. 5, no. 3, pp. 248–261, 1992.

[103] V. G. Virginio, A. Hernandez, M. B. Rott, et al., "A set of recombinant antigens from Echinococcus granulosus with potential for use in the immunodiagnosis of human cystic hydatid disease," *Clinical and Experimental Immunology*, vol. 132, no. 2, pp. 309–315, 2003.

[104] A. M. Qaqish, M. A. Nasrieh, K. M. Al-Qaoud, P. S. Craig, and S. K. Abdel-Hafez, "The seroprevalences of cystic echinococcosis, and the associated risk factors, in rural-agricultural, bedouin and semi-bedouin communities in Jordan," *Annals of Tropical Medicine and Parasitology*, vol. 97, no. 5, pp. 511–520, 2003.

[105] A. Hernández, G. Cardozo, S. Dematteis, et al., "Cystic echinococcosis: analysis of the serological profile related to the risk factors in individuals without ultrasound liver changes living in an endemic area of Tacuarembó, Uruguay," *Parasitology*, vol. 130, no. 4, pp. 455–460, 2005.

[106] D. Carmena, A. Benito, and E. Eraso, "The immunodiagnosis of Echinococcus multilocularis infection," *Clinical Microbiology and Infection*, vol. 13, no. 5, pp. 460–475, 2007.

[107] R. M. Genta, "Predictive value of an enzyme-linked immunosorbent assay (ELISA) for the serodiagnosis of strongyloidiasis," *American Journal of Clinical Pathology*, vol. 89, no. 3, pp. 391–394, 1988.

[108] D. J. Conway, N. S. Atkins, J. E. Lillywhite, et al., "Immunodiagnosis of Strongyloides stercoralis infection: a method for increasing the specificity of the indirect ELISA," *Transactions of the Royal Society of Tropical Medicine and Hygiene*, vol. 87, no. 2, pp. 173–176, 1993.

[109] F. M. de Paula, E. de Castro, M. Gonçalves-Pires, M. Marçal, D. M. Campos, and J. M. Costa-Cruz, "Parasitological and immunological diagnoses of strongyloidiasis in immunocompromised and non-immunocompromised children at Uberlândia, State of Minas Gerais, Brazil," *Revista do Instituto de Medicina Tropical de Sao Paulo*, vol. 42, no. 1, pp. 51–55, 2000.

[110] M. R. Loutfy, M. Wilson, J. S. Keystone, and K. C. Kain, "Serology and eosinophil count in the diagnosis and management of strongyloidiasis in a non-endemic area," *The American Journal of Tropical Medicine and Hygiene*, vol. 66, no. 6, pp. 749–752, 2002.

[111] S. Lim, K. Katz, S. Krajden, M. Fuksa, J. S. Keystone, and K. C. Kain, "Complicated and fatal Strongyloides infection in Canadians: risk factors, diagnosis and management," *Canadian Medical Association Journal*, vol. 171, no. 5, pp. 479–484, 2004.

[112] G. V. Hillyer, M. S. de Galanes, J. Rodriguez-Perez, et al., "Use of the Falcon™ assay screening test-enzyme-linked immunosorbent assay (FAST-ELISA) and the enzyme-linked immunoelectrotransfer blot (EITB) to determine the prevalence of human fascioliasis in the Bolivian Altiplano," *The American Journal of Tropical Medicine and Hygiene*, vol. 46, no. 5, pp. 603–609, 1992.

[113] N. Kumar, S. Ghosh, and S. C. Gupta, "Early detection of Fasciola gigantica infection in buffaloes by enzyme-linked immunosorbent assay and dot enzyme-linked immunosorbent assay," *Parasitology Research*, vol. 103, no. 1, pp. 141–150, 2008.

[114] G. L. Zimmerman, M. J. Nelson, and C. R. B. Clark, "Diagnosis of ovine fascioliasis by a dot enzyme-linked immunosorbent assay: a rapid microdiagnostic technique," *American Journal of Veterinary Research*, vol. 46, no. 7, pp. 1513–1515, 1985.

[115] A. L. T. Rabbello, M. M. A. Garcia, E. Dias Neto, R. S. Rocha, and N. Katz, "Dot-dye-immunoassay and dot-ElISA for the serological differentiation of acute and chronic schistosomiasis mansoni using keyhole limpet haemocyanin as antigen," *Transactions of the Royal Society of Tropical Medicine and Hygiene*, vol. 87, no. 3, pp. 279–281, 1993.

[116] M. G. Pappas, P. M. Schantz, L. T. Cannon Sr., and S. P. Wahlquist, "Dot-ELISA for the rapid serodiagnosis of human hydatid disease," *Diagnostic Immunology*, vol. 4, no. 6, pp. 271–276, 1986.

[117] M. M. Al-Sherbiny, A.-A. M. M. K. Farrag, M. H. Fayad, M. K. Makled, G. M. Tawfeek, and N. M. S. Ali, "Application and assessment of a dipstick assay in the diagnosis of hydatidosis and trichinosis," *Parasitology Research*, vol. 93, no. 2, pp. 87–95, 2004.

[118] P. J. Lammie, G. Weil, R. Noordin, et al., "Recombinant antigen-based antibody assays for the diagnosis and surveillance of lymphatic filariasis—a multicenter trial," *Filaria Journal*, vol. 3, no. 1, article 9, 2004.

[119] M. Jamail, K. Andrew, D. Junaidi, A. K. Krishnan, M. Faizal, and N. Rahmah, "Field validation of sensitivity and specificity of rapid test for detection of Brugia malayi infection," *Tropical Medicine and International Health*, vol. 10, no. 1, pp. 99–104, 2005.

[120] N. Rahmah, S. Taniawati, R. K. Shenoy, et al., "Specificity and sensitivity of a rapid dipstick test (Brugia Rapid) in the detection of Brugia malayi infection," *Transactions of the Royal Society of Tropical Medicine and Hygiene*, vol. 95, no. 6, pp. 601–604, 2001.

[121] T. van Gool, H. Vetter, T. Vervoort, M. J. Doenhoff, J. Wetsteyn, and D. Overbosch, "Serodiagnosis of imported schistosomiasis by a combination of a commercial indirect hemagglutination test with Schistosoma mansoni adult worm antigens and an enzyme-linked immunosorbent assay with S. mansoni egg antigens," *Journal of Clinical Microbiology*, vol. 40, no. 9, pp. 3432–3437, 2002.

[122] M. A. Nasrieh and S. K. Abdel-Hafez, "Echinococcus granulosus in Jordan: assessment of various antigenic preparations for use in the serodiagnosis of surgically confirmed cases using enzyme immuno assays and the indirect haemagglutination test," *Diagnostic Microbiology and Infectious Disease*, vol. 48, no. 2, pp. 117–123, 2004.

[123] G. J. Weil, P. J. Lammie, and N. Weiss, "The ICT filariasis test: a rapid-format antigen test for diagnosis of bancroftian filariasis," *Parasitology Today*, vol. 13, no. 10, pp. 401–404, 1997.

[124] Y. Sato, H. Toma, S. Kiyuna, and Y. Shiroma, "Gelatin particle indirect agglutination test for mass examination for strongyloidiasis," *Transactions of the Royal Society of Tropical Medicine and Hygiene*, vol. 85, no. 4, pp. 515–518, 1991.

[125] L. S. Garcia and R. Y. Shimizu, "Evaluation of nine immunoassay kits (enzyme immunoassay and direct fluorescence) for detection of Giardia lamblia and Cryptosporidium parvum in human fecal specimens," *Journal of Clinical Microbiology*, vol. 35, no. 6, pp. 1526–1529, 1997.

[126] L. S. Garcia, A. C. Shum, and D. A. Bruckner, "Evaluation of a new monoclonal antibody combination reagent for direct fluorescence detection of Giardia cysts and Cryptosporidium oocysts in human fecal specimens," *Journal of Clinical Microbiology*, vol. 30, no. 12, pp. 3255–3257, 1992.

[127] J. M. Costa-Cruz, C. B. Hullamah, M. R. Gonçalves-Pires, D. M. B. Campos, and M. A. Vieira, "Cryo-microtome sections of coproculture larvae of strongyloides stercoralis and strongyloides raft/as antigen sources for the immunodiagnosis of human strongyloidiasis," *Revista do Instituto de Medicina Tropical de Sao Paulo*, vol. 39, no. 6, pp. 313–317, 1997.

[128] E. R. Machado, M. T. Ueta, M. R. Gonçalves-Pires, J. B. Alves de Oliveira, L. H. Faccioli, and J. M. Costa-Cruz, "Diagnosis of human strongyloidiasis using particulate antigen of two strains of Strongyloides venezuelensis in indirect immunofluorescence antibody test," *Experimental Parasitology*, vol. 99, no. 1, pp. 52–55, 2001.

[129] M. M. Al-Sherbiny, A. M. Osman, K. Hancock, A. M. Deelder, and V. C. W. Tsang, "Application of immunodiagnostic assays: detection of antibodies and circulating antigens in human schistosomiasis and correlation with clinical findings," *The American Journal of Tropical Medicine and Hygiene*, vol. 60, no. 6, pp. 960–966, 1999.

[130] V. C. W. Tsang, J. A. Brand, and A. E. Boyer, "An enzyme-linked immunoelectrotransfer blot assay and glycoprotein antigens for diagnosing human cysticercosis (Taenia solium)," *Journal of Infectious Diseases*, vol. 159, no. 1, pp. 50–59, 1989.

[131] P. P. Wilkins, J. C. Allan, M. Verastegui, et al., "Development of a serologic assay to detect Taenia solium taeniasis," *The American Journal of Tropical Medicine and Hygiene*, vol. 60, no. 2, pp. 199–204, 1999.

[132] L. P. Silva, I. S. Da Costa Barcelos, A. B. Passos-Lima, F. S. Espindola, D. M. Barbosa Campos, and J. M. Costa-Cruz, "Western blotting using Strongyloides ratti antigen for the detection of IgG antibodies as confirmatory test in human strongyloidiasis," *Memorias do Instituto Oswaldo Cruz*, vol. 98, no. 5, pp. 687–691, 2003.

[133] P. D. Burbelo, R. Ramanathan, A. D. Klion, M. J. Iadarola, and T. B. Nutman, "Rapid, novel, specific, high-throughput assay for diagnosis of Loa loa infection," *Journal of Clinical Microbiology*, vol. 46, no. 7, pp. 2298–2304, 2008.

[134] R. Ramanathan, P. D. Burbelo, S. Groot, M. J. Iadarola, F. A. Neva, and T. B. Nutman, "A luciferase immunoprecipitation systems assay enhances the sensitivity and specificity of diagnosis of Strongyloides stercoralis infection," *Journal of Infectious Diseases*, vol. 198, no. 3, pp. 444–451, 2008.

[135] D. W. Johnson, N. J. Pieniazek, D. W. Griffin, L. Misener, and J. B. Rose, "Development of a PCR protocol for sensitive detection of Cryptosporidium oocysts in water samples," *Applied and Environmental Microbiology*, vol. 61, no. 11, pp. 3849–3855, 1995.

[136] U. M. Morgan, C. C. Constantine, D. A. Forbes, and R. C. A. Thompson, "Differentiation between human and animal isolates of Cryptosporidium parvum using rDNA sequencing and direct PCR analysis," *Journal of Parasitology*, vol. 83, no. 5, pp. 825–830, 1997.

[137] F. G. C. Abath, A. L. D. V. Gomes, F. L. Melo, C. S. Barbosa, and R. P. Werkhauser, "Molecular approaches for the detection of Schistosoma mansoni: possible applications in the detection of snail infection, monitoring of transmission sites, and diagnosis of human infection," *Memorias do Instituto Oswaldo Cruz*, vol. 101, supplement 1, pp. 145–148, 2006.

[138] L. A. Pontes, E. Dias-Neto, and A. Rabello, "Detection by polymerase chain reaction of Schistosoma mansoni DNA in human serum and feces," *The American Journal of Tropical Medicine and Hygiene*, vol. 66, no. 2, pp. 157–162, 2002.

[139] L. M. Gonzalez, E. Montero, S. Puente, et al., "PCR tools for the differential diagnosis of Taenia saginata and Taenia solium taeniasis/cysticercosis from different geographical locations," *Diagnostic Microbiology and Infectious Disease*, vol. 42, no. 4, pp. 243–249, 2002.

[140] H. Yamasaki, M. Nakao, Y. Sako, K. Nakaya, M. O. Sato, and A. Ito, "Mitochondrial DNA diagnosis for taeniasis and cysticercosis," *Parasitology International*, vol. 55, supplement 1, pp. S81–S85, 2006.

[141] R. M. Ramzy, "Field application of PCR-based assays for monitoring Wuchereria bancrofti infection in Africa," *Annals*

of Tropical Medicine and Parasitology, vol. 96, supplement 2, pp. S55–S59, 2002.

[142] M. Zhong, J. McCarthy, L. Bierwert, et al., "A polymerase chain reaction assay for detection of the parasite Wuchereria bancrofti in human blood samples," *The American Journal of Tropical Medicine and Hygiene*, vol. 54, no. 4, pp. 357–363, 1996.

[143] S. A. Williams, L. Nicolas, M. Lizotte-Waniewski, et al., "A polymerase chain reaction assay for the detection of Wuchereria bancrofti in blood samples from French Polynesia," *Transactions of the Royal Society of Tropical Medicine and Hygiene*, vol. 90, no. 4, pp. 384–387, 1996.

[144] S. Ramachandran, A. A. Gam, and F. A. Neva, "Molecular differences between several species of Strongyloides and comparison of selected isolates of S. stercoralis using a polymerase chain reaction-linked restriction fragment length polymorphism approach," *The American Journal of Tropical Medicine and Hygiene*, vol. 56, no. 1, pp. 61–65, 1997.

[145] J. R. Limor, A. A. Lal, and L. Xiao, "Detection and differentiation of Cryptosporidium parasites that are pathogenic for humans by real-time PCR," *Journal of Clinical Microbiology*, vol. 40, no. 7, pp. 2335–2338, 2002.

[146] R. ten Hove, T. Schuurman, M. Kooistra, L. Möller, L. van Lieshout, and J. J. Verweij, "Detection of diarrhoea-causing protozoa in general practice patients in The Netherlands by multiplex real-time PCR," *Clinical Microbiology and Infection*, vol. 13, no. 10, pp. 1001–1007, 2007.

[147] N. Jothikumar, A. J. da Silva, I. Moura, Y. Qvarnstrom, and V. R. Hill, "Detection and differentiation of Cryptosporidium hominis and Cryptosporidium parvum by dual TaqMan assays," *Journal of Medical Microbiology*, vol. 57, no. 9, pp. 1099–1105, 2008.

[148] R. J. ten Hove, J. J. Verweij, K. Vereecken, K. Polman, L. Dieye, and L. van Lieshout, "Multiplex real-time PCR for the detection and quantification of Schistosoma mansoni and S. haematobium infection in stool samples collected in northern Senegal," *Transactions of the Royal Society of Tropical Medicine and Hygiene*, vol. 102, no. 2, pp. 179–185, 2008.

[149] A. L. D. V. Gomes, F. L. Melo, R. P. Werkhauser, and F. G. C. Abath, "Development of a real time polymerase chain reaction for quantitation of Schistosoma mansoni DNA," *Memorias do Instituto Oswaldo Cruz*, vol. 101, supplement 1, pp. 133–136, 2006.

[150] J. J. Verweij, M. Canales, K. Polman, et al., "Molecular diagnosis of Strongyloides stercoralis in faecal samples using real-time PCR," *Transactions of the Royal Society of Tropical Medicine and Hygiene*, vol. 103, no. 4, pp. 342–346, 2009.

[151] P. Karanis, O. Thekisoe, K. Kiouptsi, J. Ongerth, I. Igarashi, and N. Inoue, "Development and preliminary evaluation of a loop-mediated isothermal amplification procedure for sensitive detection of Cryptosporidium oocysts in fecal and water samples," *Applied and Environmental Microbiology*, vol. 73, no. 17, pp. 5660–5662, 2007.

[152] M. A. Bakheit, D. Torra, L. A. Palomino, et al., "Sensitive and specific detection of Cryptosporidium species in PCR-negative samples by loop-mediated isothermal DNA amplification and confirmation of generated LAMP products by sequencing," *Veterinary Parasitology*, vol. 158, no. 1-2, pp. 11–22, 2008.

[153] A. Nkouawa, Y. Sako, M. Nakao, K. Nakaya, and A. Ito, "Loop-mediated isothermal amplification method for differentiation and rapid detection of Taenia species," *Journal of Clinical Microbiology*, vol. 47, no. 1, pp. 168–174, 2009.

[154] K. Bandyopadhyay, K. L. Kellar, I. Moura, et al., "Rapid microsphere assay for identification of Cryptosporidium hominis and Cryptosporidium parvum in stool and environmental samples," *Journal of Clinical Microbiology*, vol. 45, no. 9, pp. 2835–2840, 2007.

[155] P. Fischer, X. Liu, M. Lizotte-Waniewski, I. H. Kamal, R. M. R. Ramzy, and S. A. Williams, "Development of a quantitative, competitive polymerase chain reaction-enzyme-linked immunosorbent assay for the detection of Wuchereria bancrofti DNA," *Parasitology Research*, vol. 85, no. 3, pp. 176–183, 1999.

[156] O. P. Akinwale, T. Laurent, P. Mertens, et al., "Detection of schistosomes polymerase chain reaction amplified DNA by oligochromatographic dipstick," *Molecular and Biochemical Parasitology*, vol. 160, no. 2, pp. 167–170, 2008.

[157] M.-C. Rioux, C. Carmona, D. Acosta, et al., "Discovery and validation of serum biomarkers expressed over the first twelve weeks of Fasciola hepatica infection in sheep," *International Journal for Parasitology*, vol. 38, no. 1, pp. 123–136, 2008.

[158] N. Deckers, P. Dorny, K. Kanobana, et al., "Use of ProteinChip technology for identifying biomarkers of parasitic diseases: the example of porcine cysticercosis (Taenia solium)," *Experimental Parasitology*, vol. 120, no. 4, pp. 320–329, 2008.

[159] W. J. Carter, Z. Yan, N. D. Cassai, and G. S. Sidhu, "Detection of extracellular forms of babesia in the blood by electron microscopy: a diagnostic method for differentiation from Plasmodium falciparum," *Ultrastructural Pathology*, vol. 27, no. 4, pp. 211–216, 2003.

[160] S. E. Maddison, "The present status of serodiagnosis and seroepidemiology of schistosomiasis," *Diagnostic Microbiology and Infectious Disease*, vol. 7, no. 2, pp. 93–105, 1987.

[161] R. C. Ko and T. F. Ng, "Evaluation of excretory/secretory products of larval Taenia solium as diagnostic antigens for porcine and human cysticercosis," *Journal of Helminthology*, vol. 72, no. 2, pp. 147–154, 1998.

[162] A. Prasad, A. Nasir, and N. Singh, "Detection of anti-Haemonchus contortus antibodies in sheep by dot-ELISA with immunoaffinity purified fraction of ES antigen during prepatency," *Indian Journal of Experimental Biology*, vol. 46, no. 2, pp. 94–99, 2008.

[163] S. Kumar, R. Kumar, A. K. Gupta, and S. K. Dwivedi, "Passive transfer of Theileria equi antibodies to neonate foals of immune tolerant mares," *Veterinary Parasitology*, vol. 151, no. 1, pp. 80–85, 2008.

[164] H. J. Carrasco, A. Torrellas, C. Garcia, M. Segovia, and M. D. Feliciangeli, "Risk of Trypanosoma cruzi I (Kinetoplastida: Trypanosomatidae) transmission by Panstrongylus geniculatus (Hemiptera: Reduviidae) in Caracas (Metropolitan District) and neighboring States, Venezuela," *International Journal for Parasitology*, vol. 35, no. 13, pp. 1379–1384, 2005.

[165] C. K. Murray, R. A. Gasser Jr., A. J. Magill, and R. S. Miller, "Update on rapid diagnostic testing for malaria," *Clinical Microbiology Reviews*, vol. 21, no. 1, pp. 97–110, 2008.

[166] A. D. C. Vexenat, J. M. Santana, and A. R. L. Teixeira, "Cross-reactivity of antibodies in human infections by the kinetoplastid protozoa Trypanosoma cruzi, Leishmania chagasi and Leishmania (Viannia) braziliensis," *Revista do Instituto de Medicina Tropical de Sao Paulo*, vol. 38, no. 3, pp. 177–185, 1996.

[167] B. Singh, "Molecular methods for diagnosis and epidemiological studies of parasitic infections," *International Journal for Parasitology*, vol. 27, no. 10, pp. 1135–1145, 1997.

[168] P. Moro and P. M. Schantz, "Echinococcosis: a review," *International Journal of Infectious Diseases*, vol. 13, no. 2, pp. 125–133, 2009.

[169] P. Mens, N. Spieker, S. Omar, M. Heijnen, H. Schallig, and P. A. Kager, "Is molecular biology the best alternative for diagnosis of malaria to microscopy? A comparison between microscopy, antigen detection and molecular tests in rural Kenya and urban Tanzania," *Tropical Medicine and International Health*, vol. 12, no. 2, pp. 238–244, 2007.

[170] D. S. Zarlenga and J. Higgins, "PCR as a diagnostic and quantitative technique in veterinary parasitology," *Veterinary Parasitology*, vol. 101, no. 3-4, pp. 215–230, 2001.

[171] R. B. Gasser, "Molecular tools—advances, opportunities and prospects," *Veterinary Parasitology*, vol. 136, no. 2, pp. 69–89, 2006.

[172] G. A. Farcas, R. Soeller, K. Zhong, A. Zahirieh, and K. C. Kain, "Real-time polymerase chain reaction assay for the rapid detection and characterization of chloroquine-resistant Plasmodium falciparum malaria in returned travelers," *Clinical Infectious Diseases*, vol. 42, no. 5, pp. 622–627, 2006.

[173] S. Bretagne and J.-M. Costa, "Towards a nucleic acid-based diagnosis in clinical parasitology and mycology," *Clinica Chimica Acta*, vol. 363, no. 1-2, pp. 221–228, 2006.

[174] T. Notomi, H. Okayama, H. Masubuchi, et al., "Loop-mediated isothermal amplification of DNA," *Nucleic Acids Research*, vol. 28, no. 12, p. E63, 2000.

[175] M. Parida, G. Posadas, S. Inoue, F. Hasebe, and K. Morita, "Real-time reverse transcription loop-mediated isothermal amplification for rapid detection of West Nile virus," *Journal of Clinical Microbiology*, vol. 42, no. 1, pp. 257–263, 2004.

[176] L. L. M. Poon, B. W. Y. Wong, K. H. Chan, et al., "Evaluation of real-time reverse transcriptase PCR and real-time loop-mediated amplification assays for severe acute respiratory syndrome coronavirus detection," *Journal of Clinical Microbiology*, vol. 43, no. 7, pp. 3457–3459, 2005.

[177] S. Y. Liang, Y. H. Chan, K. T. Hsia, et al., "Development of loop-mediated isothermal amplification assay for detection of Entamoeba histolytica," *Journal of Clinical Microbiology*, vol. 47, no. 6, pp. 1892–1895, 2009.

[178] A. Alhassan, O. M. M. Thekisoe, N. Yokoyama, et al., "Development of loop-mediated isothermal amplification (LAMP) method for diagnosis of equine piroplasmosis," *Veterinary Parasitology*, vol. 143, no. 2, pp. 155–160, 2007.

[179] G. Guan, A. Chauvin, J. Luo, et al., "The development and evaluation of a loop-mediated isothermal amplification (LAMP) method for detection of Babesia spp. infective to sheep and goats in China," *Experimental Parasitology*, vol. 120, no. 1, pp. 39–44, 2008.

[180] H. Aonuma, A. Yoshimura, N. Perera, et al., "Loop-mediated isothermal amplification applied to filarial parasites detection in the mosquito vectors: *Dirofilaria immitis* as a study model," *Parasites and Vectors*, vol. 2, no. 1, article 15, 2009.

[181] Y. Mori, K. Nagamine, N. Tomita, and T. Notomi, "Detection of loop-mediated isothermal amplification reaction by turbidity derived from magnesium pyrophosphate formation," *Biochemical and Biophysical Research Communications*, vol. 289, no. 1, pp. 150–154, 2001.

[182] H. Iseki, A. Alhassan, N. Ohta, et al., "Development of a multiplex loop-mediated isothermal amplification (mLAMP) method for the simultaneous detection of bovine Babesia parasites," *Journal of Microbiological Methods*, vol. 71, no. 3, pp. 281–287, 2007.

[183] S. A. Dunbar, "Applications of Luminex xMAP technology for rapid, high-throughput multiplexed nucleic acid detection," *Clinica Chimica Acta*, vol. 363, no. 1-2, pp. 71–82, 2006.

[184] N. Tang, P. Tornatore, and S. R. Weinberger, "Current developments in SELDI affinity technology," *Mass Spectrometry Reviews*, vol. 23, no. 1, pp. 34–44, 2004.

[185] Z. Xiao, D. Prieto, T. P. Conrads, T. D. Veenstra, and H. J. Issaq, "Proteomic patterns: their potential for disease diagnosis," *Molecular and Cellular Endocrinology*, vol. 230, no. 1-2, pp. 95–106, 2005.

[186] R. T. K. Pang, T. C. W. Poon, K. C. A. Chan, et al., "Serum proteomic fingerprints of adult patients with severe acute respiratory syndrome," *Clinical Chemistry*, vol. 52, no. 3, pp. 421–429, 2006.

Hindawi Publishing Corporation
Interdisciplinary Perspectives on Infectious Diseases
Volume 2009, Article ID 415953, 7 pages
doi:10.1155/2009/415953

Review Article

Rapid Diagnosis of Malaria

Clinton K. Murray and Jason W. Bennett

Infectious Disease Service, Brooke Army Medical Center, 3851 Roger Brooke Drive, Fort Sam Houston, TX 78234, USA

Correspondence should be addressed to Clinton K. Murray, clinton.murray@amedd.army.mil

Received 29 January 2009; Accepted 27 April 2009

Recommended by Herbert B. Tanowitz

Malaria's global impact is expansive and includes the extremes of the healthcare system ranging from international travelers returning to nonendemic regions with tertiary referral medical care to residents in hyperendemic regions without access to medical care. Implementation of prompt and accurate diagnosis is needed to curb the expanding global impact of malaria associated with ever-increasing antimalarial drug resistance. Traditionally, malaria is diagnosed using clinical criteria and/or light microscopy even though both strategies are clearly inadequate in many healthcare settings. Hand held immunochromatographic rapid diagnostic tests (RDTs) have been recognized as an ideal alternative method for diagnosing malaria. Numerous malaria RDTs have been developed and are widely available; however, an assortment of issues related to these products have become apparent. This review provides a summary of RDT including effectiveness and strategies to select the ideal RDT in varying healthcare settings.

1. Introduction

According to the World Malaria Report released by the World Health Organization (WHO) in 2008, there were 247 million malaria cases among 3.3 billion people at risk in 2006 from 109 countries resulting in an estimated 881,000 deaths. These deaths were primarily in Africa (91%) and in children under 5 years of age (85%) [1]. Effective management of malaria per the WHO has focused on long-lasting insecticidal nets, indoor residual spraying of insecticide, intermittent preventive therapy in pregnancy, and artemisinin-based combination therapy (ACT). Fundamental to improving the care of patients infected with malaria is prompt and accurate diagnosis in order to prevent excess morbidity and mortality while avoiding unnecessary use of antimalarial agents and minimizing the spread of resistance to antimalarial drugs. Diagnostic strategies need to be effective not only in resource-limited areas where malaria has a substantial burden on society but also in developed countries where expertise in the diagnosis of malaria is frequently lacking [2, 3].

Historical strategies to diagnose malaria emphasize clinical diagnostic algorithms, light microscopy, and empiric therapy. The accuracy of clinical diagnosis, the most commonly employed method, is poor, even in countries with high incidence rates of malaria due to overlapping clinical symptoms with other tropical diseases and the fact that coinfections can occur [4–11]. In an era when chloroquine therapy was widely effective and the primary antimalarial agent used around the world, definitive diagnosis was not necessary. Today, given the paucity of effective antimalarial agents with widespread use of ACT, an increased emphasis on diagnosis is necessary. This is especially true now that artesunate failures have been noted [12]. Microscopy remains the gold standard for detection of malaria parasitemia as it can provide information on both the species of parasite and parasite density of infection [13]. However, the procedure is labor-intensive and time-consuming, requiring substantial training and expertise due to fleeting skills [14–26]. These problems are magnified in nonendemic regions where light microscopy to diagnose malaria is infrequently performed, resulting in missed diagnosis, misidentification of *Plasmodium* species, and therapeutic delays [19]. Methods using advances in technology have been evaluated as alternatives to light microscopy. While these methods have varying strengths and weaknesses, they are limited by equipment, supplies, expertise, cost, time,

applicability in acute infection, and/or availability [13, 27].

New immunochromatographic rapid diagnostic tests (RDTs) for malaria were introduced in the early 1990s but have suffered from numerous problems as recently reviewed [13, 27–31]. Strategies to improve the impact of malaria RDT have included The Special Programme for Research and Training in Tropical Diseases which has introduced principles for development and evaluation of diagnostic tests for infectious diseases [32]. The WHO has also undertaken a malaria RDT evaluation program to improve the overall impact of these tests (http://www.wpro.who.int/sites/rdt/who_rdt_evaluation/ accessed 19 January 2009)

Requirements for malaria RDT vary based on malaria local epidemiology and the goals of a malaria control program; focusing on performance and operational characteristics (Table 1) [33, 34]. Expectations of an ideal malaria RDT are minimal operator training, ease of platform with minimal steps, reproducibility of results, rapid availability of results (<20 minutes), and low cost. Ideally, the test should be able to detect recrudescence or relapse and clearance of parasitemia if therapeutic monitoring is necessary (Table 1). The WHO has recommended a minimum standard of 95% sensitivity at parasite densities of 100/uL [33]. In Sub-Saharan Africa, malaria RDT needs a high sensitivity for *Plasmodium falciparum*, but specificity is required to avert inflated estimates of the burden of malaria, misperceptions of inadequate therapeutic responses when fever is due to other illnesses, and unnecessary drug pressure. High specificity and the ability to detect *nonfalciparum Plasmodium* species are necessary in low-incidence regions due to low rates of malaria, and the lower virulence of these species is allowing for repeat testing. The quality of manufacturing and reproducibility of the test results are critical. In addition, field conditions require the RDT to be stable under extremes of temperatures and humidity during use and storage.

2. Malaria Rapid Diagnostic Tests

Malaria RDT employ lateral flow immunochromatographic technology similar to rapid pregnancy tests. In these assays, the clinical sample migrates as a liquid across the surface of a nitrocellulose membrane by capillary action [13, 27, 33, 34]. For a given targeted parasite antigen, two sets of monoclonal or polyclonal antibodies are used, a capture antibody and a detection antibody. Monoclonal antibodies in contrast to polyclonal antibodies can be very specific but less sensitive. Also, the source of antigen used (purified native protein, recombinant proteins, or peptides) can make significant differences in the performance characteristics of RDT.

The malaria antigens currently used as diagnostic targets are either specific to a *Plasmodium* species or are conserved across all four of the human malaria parasites. Falciparum-specific monoclonals include histidine-rich protein-2 (HRP-2) and *P. falciparum* lactate dehydrogenase (pfLDH) [32, 33]. Targets conserved across all human malaria have been identified on lactate dehydrogenase (pLDH) and aldolase enzymes [35–38].

HRP-2 is a *P. falciparum*-specific water-soluble protein, localized in the parasite cytoplasm and on the surface membrane of infected erythrocyte. It is present on protrusions, known as knobs, thought to account for sequestration of the trophozoites and schizonts in postcapillary venules. There is increasing concentration of HRP-2 as the parasite advances from ring stage to trophozoite, and it readily diffuses into the plasma [39, 40]. HRP-2 is predominately found in the asexual stages, but it is also found in young *P. falciparum* gametocytes. This possibly allows detection at lower parasitemias and at detectable levels 28 days after clinical presentation, well after resolution of symptoms and apparent clearance of parasites from patients [41–44]. Therefore, this antigen has not yet proven valuable in monitoring response to therapy. Mutants can escape recognition by monoclonal antibodies and may be responsible for false negative tests [45, 46]. An assessment of HRP-2 from nineteen countries revealed that only 84% of *P. falciparum* could be detected.

Another antigen target to detect sexual and asexual stage malaria parasites is Plasmodium lactose dehydrogenase (pLDH), which is the final enzyme in the malaria parasite's glycolytic pathway. Monoclonal antibodies against pLDH can target all human malaria species or can specifically differentiate *P. falciparum* or *P. vivax* [36]. Aldolase, another key enzyme in the glycosis pathway conserved across all malaria parasites, can be used as a universal antigen target [47, 48]. Other antigens have been recognized as possible components of future diagnostic tests, but evaluations of *P. ovale*- or *P. malariae*-specific antigens have not been widely tested [38, 49, 50]. Aldolase and pLDH rapidly fall to undetectable levels after initiation of effective therapy, however they are expressed in gametocytes, as does HRP-2, which may allow detection of *P. falciparum* after the clinical infection is cleared [51].

2.1. Available Malaria Rapid Diagnostic Tests. Numerous reviews have highlighted the rapid turnover of commercially available products and varying quality control issues in manufacture and product stability [13, 27–29, 52]. Articles in peer-reviewed journals of independent evaluations have not existed for many products. In addition, there are numerous methodological flaws associated with many of the published evaluations limiting the ability to compare malaria RDT [13, 27]. The WHO has listed online RDT manufacturers and distributors. To be included in these summaries requires evidence of good manufacturing practices as documented by either compliance with ISO 13485:2003 or 21 CFR 820 from the US Food and Drug Administration. Overall it appears that RDTs using HRP-2 are generally more sensitive than falciparum-specific pLDH for diagnosing infections caused by *P. falciparum* when using RDT. However, data assessing the utility of pLDH and aldolase in nonfalciparum infections is limited.

Currently the BinaxNOW® Malaria test kit is the only US FDA approved kit. It is based upon the HRP-2 and aldolase antigens (Binax, INC., Inverness Medical

Table 1: Ideal requirements for a malaria rapid diagnostic test (RDT).

Common requirements			
Rapid results (<20 minutes)			
Easy to use with minimal training and simple instructions			
Environmentally stable device (heat, humidity, air movement, lighting) during use and storage			
Reproducible results including quality manufacturing			
Detect below parasite density of <100 parasites/μL with appropriate specificity			
Region-specific requirements			
	Sub-Saharan Africa	Other malaria endemic areas	Malaria free countries
P. falciparum-specific	+++	−	−
Detects all human malaria	+	+++	+++
Plasmodium species specific	+	+++	+++
Able to detect mixed infections	+	+++	+++
High sensitivity (< 50 parasites/μL)	−	+++	+++
High specificity	−	+++	+++
Semi-quantitative	−	−	+++
Able to monitor response to therapy	+	+++ (if drug-resistant *P. falciparum*)	+
Assay specifications:			
ICH GMP	−	−	+++
Stable to 40° C	+++	+++	−
Long shelf life	+++	+++	+++
Point-of-care use (CLIA waived)	−	−	+++
Cost	< $1 per test	$1–3 per test	<microscopy (~ $20/test)

+++ (high priority), + (low priority), − (not necessary), International Conference on Harmonization (ICH); Good Manufacturing Practices (GMP); Clinical Laboratory Improvement Amendment (CLIA).

Professional Diagnostic, Scarborough, Me, USA). One large trial revealed an overall sensitivity of 82% [44]. The overall specificity for *P. falciparum* was 94% [44]. Again, using the BinaxNOW Malaria test kit, a second trial primarily assessed the utility of finger-stick versus venipuncture obtained blood samples [53]. The finger-stick technique revealed an overall sensitivity of 100% for *P. falciparum* and 83% for *P. vivax*. Venipuncture produced similar results to fingerstick for the detection of *P. falciparum* and *P. vivax* (Table 2). According to the package insert, the overall sensitivity and specificity are 95% and 94% for *P. falciparum*, 69% and 100% for *P. vivax*, respectively (Table 2). The sensitivity for detecting *P. malariae* was 44% (7 of 16 positive samples) and 50% for *P. ovale* (1 of 2 positive samples), although these numbers were too small to determine reliable sensitivity and specificity. Although the kit is not approved for diagnosing mixed *P. falciparum* and *P. vivax* infections, the sensitivity was 94%. No clear data exists for using RDT to detect a recently described species of malaria, *P. knowlesi*, that has been reported to infect humans [54].

Overall, the BinaxNOW® Malaria test kit meets many of the needs required of an ideal malaria diagnostic platform; however, it has also a number of limitations including the FDA indications comment that this kit is only for use in laboratories that have or can acquire blood samples containing *P. falciparum* for use as a positive control. It is also approved for use in the evaluation of symptomatic patients, with negative results requiring confirmation by thick and thin smears. Therefore individual clinicians or patients themselves might not have rapid results to initiate immediate therapy. Other limitations include the kit's ability to detect viable and nonviable malaria organisms, including gametocytes and sequestered *P. falciparum* parasites. In some settings, such as pregnancy, this is possibly advantageous; however, this prohibits monitoring the level of parasitemia, which is often used in management decisions. Additionally this prevents the monitoring of therapeutic response as antigens persist after elimination of the parasite. Finally, positive rheumatoid factor has been associated with false positive results. Overall, many of these limitations also plague other RDT [13, 27].

2.2. Applicability of Malaria Rapid Diagnostic Tests. It has been estimated that 16 million RDTs were delivered in 2006 of which 10.8 million were in Africa and 2.8 million in India [1]. Malaria RDTs are used at almost every level of the healthcare system. Most of the data supports using these devices in settings where trained personnel perform the assay in targeted adult patient populations presenting with a febrile illness. There is limited data in children [44]. Among pregnant women, *P. falciparum* malaria is associated with placental sequestration of parasites that can reduce the sensitivity of microscopic diagnosis. In this clinical scenario, the detection of HRP-2 might improve diagnostic capability as this antigen is recovered peripherally [55]. However, the relevance of persistent HRP-2 antigen for up to a month after therapy is unclear in this setting. Overall, the ideal setting for these devices would include use by village workers

Table 2: Performance characteristics of the BinaxNOW® malaria kit for *Plasmodium falciparum* and *P. vivax*(data obtained from package insert).

	Plasmodium falciparum	*Plasmodium vivas*
Parasitemia level (per υL)	Percent sensitivity (95% confidence interval)	Percent sensitivity (95% confidence interval) %)
>5000	99.7% (98%–100%)	93.5% (91%–96%)
1000–5000	99.2% (96%–100%)	81.0% (76%–85%)
500–1000	92.6% (76%–99%)	47.4% (36%–59%)
100–500	89.2% (75%–97%)	23.6% (17%–31%)
0–100	53.9% (37%–70%)	6.2% (3%–12%)
Overall	95.3% (93%–97%)	68.9% (66%–72%)
Specificity	94.2% (93%–95%)	99.8% (99%–100%)
Venous versus fingerstick samples	100% (96–100%) versus 98.8% (94–100%)	81.6% (74–87%) versus 80.6% (73–87%)
Specificity	94.7% (93–96%) versus 90.4% (88-92%)	99.7% (99–100%) versus 99.5% (99–100%)

without formal medical laboratory training, or travelers for self-diagnosis and treatment; however, there is conflicting evidence on the utility of RDT in these settings [56–59]. The diagnosis of *P. falciparum* has been made on convalescent serologic (day 14–21 after febrile illness) or post-mortem assessments, all supporting possible diagnosis after initiation of empiric therapy [13, 60].

Other possible indications for malaria RDT could include malaria prevalence surveys; however, they are insensitive for use in asymptomatic screening and high throughput detection cannot be achieved with individually packaged RDT [17, 61–64]. Currently the American Red Cross does not screen blood donation units for malaria, instead deferring donations based upon exposure risks.

2.3. Selection of Malaria Rapid Diagnostic Tests. Selection of specific malaria RDT is based upon region specific criteria including the expected health benefit, implementation plans, monitoring process, and cost with a focus on expected species of infection, level of parasitemia, and treatment paradigms. Parasitological confirmation of the diagnosis of malaria is recommended in all cases except for children under 5 years of age residing in areas of high prevalence of *P. falciparum*. It is unclear if the risk of not treating false-negative tests outweighs the benefits of empiric therapy.

The WHO has typically outlined 3 broad zones for selecting devices. Zone 1 occurs primarily in Sub-Saharan Africa and in lowland Papua New Guinea where infections occur with *P. falciparum* only or where nonfalciparum species occur as coinfections with *P. falciparum*. The HRP-2-based kits are probably best in this region because of overall improved antigen detection for *P. falciparum*. Zone 2 occurs in endemic areas of Asia, the Americas, and in isolated areas in Africa specifically the Ethiopian highlands, where falciparum and nonfalciparum malaria typically cocirculate. RDT in these regions will need to distinguish between falciparum and nonfalciparum infections. Zone 3 contains areas with nonfalciparum malaria only; including the *P. vivax* areas of East Asia and Central America. Here, RDT should focus on *P. vivax*-specific or pan-Plasmodium specific antigen detection without a need to detect or differentiate falciparum. Even in *P. falciparum* predominate regions, it is possible for 1–10% of patients to be coinfected including cases requiring anti-relapse therapy with primaquine [65].

Although the major burden of malaria is in endemic countries, malarious regions are frequent destinations of the roughly 900 million yearly international travelers (www.unwto.org/index.php, accessed 24 January 2009). These travelers might require management of their malaria infection while abroad or upon returning home; however, laboratory personnel in nonendemic regions often lack experience or expertise in microscopic diagnosis of malaria [66]. Based upon a large meta-analysis of malaria RDT use in travelers, RDT may be an effective adjunct to microscopy in centers without substantial expertise in tropical medicine [52, 67]. However, expert microscopy is still needed for species identification and confirmation. Strategies need to be developed to determine how best to evaluate and field malaria RDT for use in nonendemic regions and for travelers who will be on holiday for prolonged periods of time in highly endemic regions.

3. Conclusions

Malaria is a life-threatening infection impacting the most developed countries of the world along with regions of the world lacking basic healthcare infrastructure. Increasing burden of disease, emerging antimalarial drug resistance, and broad implementation of ACT are placing greater emphasis on rapid and accurate diagnosis of patients infected with malaria. Given the difficulty performing microscopy, especially in endemic areas, alternative diagnostic strategies are needed. A highly effective RDT could avert over 100.000 malaria related deaths and about 400 million unnecessary treatments [68]. In addition, it is likely that RDTs will be cost-effective due to improved treatment and health outcomes for febrile disease not due to malaria along with cost savings associated with antimalarial drugs [69]. Although there is now an FDA approved malaria RDT, RDTs have limitations to include the inability to detect mixed infections, all species of *Plasmodium*, and infections at low concentrations of parasites, along with an inability to monitor response to therapy. In addition, in the case of a negative result, microscopy is still recommended. Therefore

RDTs do not eliminate the need to obtain thick and thin smears, and maintaining expertise in microscopy is still a global priority until a new gold-standard is developed. However, malaria RDTs are ushering in a new era of diagnosis to improve the overall global healthcare system.

Disclaimer

The opinions or assertions contained herein are the private views of the authors and are not to be construed as official or reflecting the views of the US Department of the Army, the US Department of Defense, or the US government. The authors are employees of the US government and this work was performed as part of their official duties. As such, there is no copyright to be transferred.

References

[1] WHO, World Malaria Report, 2008.

[2] D. Bell, C. Wongsrichanalai, and J. W. Barnwell, "Ensuring quality and access for malaria diagnosis: how can it be achieved?" *Nature Reviews Microbiology*, vol. 4, no. 9, supplement, pp. 682–695, 2006.

[3] H. Reyburn, H. Mbakilwa, R. Mwangi, et al., "Rapid diagnostic tests compared with malaria microscopy for guiding outpatient treatment of febrile illness in Tanzania: randomised trial," *British Medical Journal*, vol. 334, no. 7590, p. 403, 2007.

[4] D. Chandramohan, S. Jaffar, and B. Greenwood, "Use of clinical algorithms for diagnosing malaria," *Tropical Medicine & International Health*, vol. 7, no. 1, pp. 45–52, 2002.

[5] J. A. Berkley, K. Maitland, I. Mwangi, et al., "Use of clinical syndromes to target antibiotic prescribing in seriously ill children in malaria endemic area: observational study," *British Medical Journal*, vol. 330, no. 7498, pp. 995–999, 2005.

[6] R. P. Peters, E. E. Zijlstra, M. J. Schijffelen, et al., "A prospective study of bloodstream infections as cause of fever in Malawi: clinical predictors and implications for management," *Tropical Medicine & International Health*, vol. 9, no. 8, pp. 928–934, 2004.

[7] C. Wongsrichanalai, C. K. Murray, M. Gray, et al., "Co-infection with malaria and leptospirosis," *The American Journal of Tropical Medicine and Hygiene*, vol. 68, no. 5, pp. 583–585, 2003.

[8] J. R. M. Armstrong-Schellenberg, T. Smith, P. L. Alonso, and R. J. Hayes, "What is clinical malaria? Finding case definitions for field research in highly endemic areas," *Parasitology Today*, vol. 10, no. 11, pp. 439–442, 1994.

[9] C. Luxemburger, F. Nosten, D. E. Kyle, L. Kiricharoen, T. Chongsuphajaisiddhi, and N. J. White, "Clinical features cannot predict a diagnosis of malaria or differentiate the infecting species in children living in an area of low transmission," *Transactions of the Royal Society of Tropical Medicine and Hygiene*, vol. 92, no. 1, pp. 45–49, 1998.

[10] D. H. Hamer, M. Ndhlovu, D. Zurovac, et al., "Improved diagnostic testing and malaria treatment practices in Zambia," *The Journal of the American Medical Association*, vol. 297, no. 20, pp. 2227–2231, 2007.

[11] V. D'Acremont, C. Lengeler, H. Mshinda, D. Mtasiwa, M. Tanner, and B. Genton, "Time to move from presumptive malaria treatment to laboratory-confirmed diagnosis and treatment in African children with fever," *PLoS Medicine*, vol. 6, no. 1, article e252, pp. 1–3, 2009.

[12] A. P. Alker, P. Lim, R. Sem, et al., "Pfmdr1 and in vivo resistance to artesunate-mefloquine in falciparum malaria on the Cambodian-Thai border," *The American Journal of Tropical Medicine and Hygiene*, vol. 76, no. 4, pp. 641–647, 2007.

[13] C. K. Murray, R. A. Gasser Jr., A. J. Magill, and R. S. Miller, "Update on rapid diagnostic testing for malaria," *Clinical Microbiology Reviews*, vol. 21, no. 1, pp. 97–110, 2008.

[14] D. C. Warhurst and J. E. Williams, "ACP broadsheet no 148. July 1996. Laboratory diagnosis of malaria," *Journal of Clinical Pathology*, vol. 49, no. 7, pp. 533–538, 1996.

[15] L. M. Milne, M. S. Kyi, P. L. Chiodini, and D. C. Warhurst, "Accuracy of routine laboratory diagnosis of malaria in the United Kingdom," *Journal of Clinical Pathology*, vol. 47, no. 8, pp. 740–742, 1994.

[16] F. E. McKenzie, J. Sirichaisinthop, R. S. Miller, R. A. Gasser Jr., and C. Wongsrichanalai, "Dependence of malaria detection and species diagnosis by microscopy on parasite density," *The American Journal of Tropical Medicine and Hygiene*, vol. 69, no. 4, pp. 372–376, 2003.

[17] R. E. Coleman, J. Sattabongkot, S. Promstaporm, et al., "Comparison of PCR and microscopy for the detection of asymptomatic malaria in a *Plasmodium falciparum/vivax* endemic area in Thailand," *Malaria Journal*, vol. 5, article 121, pp. 1–7, 2006.

[18] D. Zurovac, B. Midia, S. A. Ochola, M. English, and R. W. Snow, "Microscopy and outpatient malaria case management among older children and adults in Kenya," *Tropical Medicine & International Health*, vol. 11, no. 4, pp. 432–440, 2006.

[19] K. C. Kain, M. A. Harrington, S. Tennyson, and J. S. Keystone, "Imported malaria: prospective analysis of problems in diagnosis and management," *Clinical Infectious Diseases*, vol. 27, no. 1, pp. 142–149, 1998.

[20] L. Barat, J. Chipipa, M. Kolczak, and T. Sukwa, "Does the availability of blood slide microscopy for malaria at health centers improve the management of persons with fever in Zambia?" *The American Journal of Tropical Medicine and Hygiene*, vol. 60, no. 6, pp. 1024–1030, 1999.

[21] M. Zhou, Q. Liu, C. Wongsrichanalai, et al., "High prevalence of *Plasmodium malariae* and *Plasmodium ovale* in malaria patients along the Thai-Myanmar border, as revealed by acridine orange staining and PCR-based diagnoses," *Tropical Medicine & International Health*, vol. 3, no. 4, pp. 304–312, 1998.

[22] D. N. Durrheim, P. J. Becker, and K. Billinghurst, "Diagnostic disagreement—the lessons learnt from malaria diagnosis in Mpumalanga," *South African Medical Journal*, vol. 87, no. 8, p. 1016, 1997.

[23] N. W. Stow, J. K. Torrens, and J. Walker, "An assessment of the accuracy of clinical diagnosis, local microscopy and a rapid immunochromatographic card test in comparison with expert microscopy in the diagnosis of malaria in rural Kenya," *Transactions of the Royal Society of Tropical Medicine and Hygiene*, vol. 93, no. 5, pp. 519–520, 1999.

[24] S. P. Kachur, E. Nicolas, V. Jean-François, et al., "Prevalence of malaria parasitemia and accuracy of microscopic diagnosis in Haiti, October 1995," *Revista Panamericana de Salud Pùblica*, vol. 3, no. 1, pp. 35–39, 1998.

[25] A. H. D. Kilian, W. G. Metzger, E. J. Mutschelknauss, et al., "Reliability of malaria microscopy in epidemiological studies: results of quality control," *Tropical Medicine & International Health*, vol. 5, no. 1, pp. 3–8, 2000.

[26] D. Payne, "Use and limitations of light microscopy for diagnosing malaria at the primary health care level," *Bulletin*

of the World Health Organization, vol. 66, no. 5, pp. 621–626, 1988.

[27] C. Wongsrichanalai, M. J. Barcus, S. Muth, A. Sutamihardja, and W. A. Wernsdorfer, "A review of malaria diagnostic tools: microscopy and rapid diagnostic test (RDT)," *The American Society of Tropical Medicine and Hygiene*, vol. 77, no. 6, supplement, pp. 119–127, 2007.

[28] A. Moody, "Rapid diagnostic tests for malaria parasites," *Clinical Microbiology Reviews*, vol. 15, no. 1, pp. 66–78, 2002.

[29] C. K. Murray, D. Bell, R. A. Gasser Jr., and C. Wongsrichanalai, "Rapid diagnostic testing for malaria," *Tropical Medicine & International Health*, vol. 8, no. 10, pp. 876–883, 2003.

[30] C. J. Shiff, Z. Premji, and J. N. Minjas, "The rapid manual *Para*Sight®-F test : a new diagnostic tool for *Plasmodium falciparum* infection," *Transactions of the Royal Society of Tropical Medicine and Hygiene*, vol. 87, no. 6, pp. 646–648, 1993.

[31] D. P. Mason, F. Kawamoto, K. Lin, A. Laoboonchai, and C. Wongsrichanalai, "A comparison of two rapid field immunochromatographic tests to expert microscopy in the diagnosis of malaria," *Acta Tropica*, vol. 82, no. 1, pp. 51–59, 2002.

[32] S. Banoo, D. Bell, P. Bossuyt, et al., "Evaluation of diagnostic tests for infectious diseases: general principles," *Nature Reviews Microbiology*, vol. 4, no. 12, supplement, pp. S20–S32, 2006.

[33] D. Bell and R. W. Peeling, "Evaluation of rapid diagnostic tests: malaria," *Nature Reviews Microbiology*, vol. 4, no. 9, supplement, pp. S34–S38, 2006.

[34] WHO, "New perspectives: malaria diagnosis," Report of a Joint WHO/USAID Informal Consultation, World Health Organization, Geneva, Switzerland, October 1999.

[35] M. T. Makler and D. J. Hinrichs, "Measurement of the lactate dehydrogenase activity of *Plasmodium falciparum* as an assessment of parasitemia," *The American Journal of Tropical Medicine and Hygiene*, vol. 48, no. 2, pp. 205–210, 1993.

[36] M. T. Makler, R. C. Piper, and W. K. Milhous, "Lactate dehydrogenase and the diagnosis of malaria," *Parasitology Today*, vol. 14, no. 9, pp. 376–377, 1998.

[37] W. M. Brown, C. A. Yowell, A. Hoard, et al., "Comparative structural analysis and kinetic properties of lactate dehydrogenases from the four species of human malarial parasites," *Biochemistry*, vol. 43, no. 20, pp. 6219–6229, 2004.

[38] J. R. Forney, C. Wongsrichanalai, A. J. Magill, et al., "Devices for rapid diagnosis of malaria: evaluation of prototype assays that detect *Plasmodium falciparum* histidine-rich protein 2 and a *Plasmodium vivax*-specific antigen," *Journal of Clinical Microbiology*, vol. 41, no. 6, pp. 2358–2366, 2003.

[39] R. J. Howard, S. Uni, M. Aikawa, et al., "Secretion of a malarial histidine-rich protein (Pf HRP II) from *Plasmodium falciparum*-infected erythrocytes," *The Journal of Cell Biology*, vol. 103, no. 4, pp. 1269–1277, 1986.

[40] E. P. Rock, K. Marsh, A. J. Saul, et al., "Comparative analysis of the *Plasmodium falciparum* histidine-rich proteins HRP-I, HRP-II and HRP-III in malaria parasites of diverse origin," *Parasitology*, vol. 95, part 2, pp. 209–227, 1987.

[41] T. D. Swarthout, H. Counihan, R. K. K. Senga, and I. van den Broek, "Paracheck-Pf® accuracy and recently treated *Plasmodium falciparum* infections: is there a risk of overdiagnosis?" *Malaria Journal*, vol. 6, article 58, pp. 1–6, 2007.

[42] J. Karbwang, O. Tasanor, T. Kanda, et al., "*Para*Sight™-F test for the detection of treatment failure in multidrug resistant *Plasmodium falciparum* malaria," *Transactions of the Royal Society of Tropical Medicine and Hygiene*, vol. 90, no. 5, pp. 513–515, 1996.

[43] J. Richter, K. Göbels, I. Müller-Stöyer, B. Hoppenheit, and D, Häussinger, "Co-reactivity of plasmodial histidine-rich protein 2 and aldolase on a combined immuno-chromographic-malaria dipstick (ICT) as a potential semi-quantitative marker of high *Plasmodium falciparum* parasitaemia," *Parasitology Research*, vol. 94, no. 5, pp. 384–385, 2004.

[44] R. A. Gasser Jr., A. J. Magill, T. K. Ruebush II, et al., "Malaria diagnosis: performance of NOW® ICT malaria in a large scale field trial," in *Proceedings of the 54th Annual Meeting of the American Society of Tropical Medicine and Hygiene*, Washington, DC, USA, December 2005.

[45] N. Lee, J. Baker, K. T. Andrews, et al., "Effect of sequence variation in *Plasmodium falciparum* histidine-rich protein 2 on binding of specific monoclonal antibodies: implications for rapid diagnostic tests for malaria," *Journal of Clinical Microbiology*, vol. 44, no. 8, pp. 2773–2778, 2006.

[46] J. Baker, J. McCarthy, M. Gatton, et al., "Genetic diversity of *Plasmodium falciparum* histidine-rich protein 2 (PfHRP2) and its effect on the performance of PfHRP2-based rapid diagnostic tests," *The Journal of Infectious Diseases*, vol. 192, no. 5, pp. 870–877, 2005.

[47] N. Lee, J. Baker, D. Bell, J. McCarthy, and Q. Cheng, "Assessing the genetic diversity of the aldolase genes of *Plasmodium falciparum* and *Plasmodium vivax* and its potential effect on performance of aldolase-detecting rapid diagnostic tests," *Journal of Clinical Microbiology*, vol. 44, no. 12, pp. 4547–4549, 2006.

[48] G. L. Genrich, J. Guarner, C. D. Paddock, et al., "Fatal malaria infection in travelers: novel immunohistochemical assays for the detection of *Plasmodium falciparum* in tissues and implications for pathogenesis," *The American Journal of Tropical Medicine and Hygiene*, vol. 76, no. 2, pp. 251–259, 2007.

[49] I. B. Suh, H. K. Choi, S. W. Lee, et al., "Reactivity of sera from cases of *Plasmodium vivax* malaria towards three recombinant antigens based on the surface proteins of the parasite," *Annals of Tropical Medicine and Parasitology*, vol. 97, no. 5, pp. 481–487, 2003.

[50] A. K. Nyame, Z. S. Kawar, and R. D. Cummings, "Antigenic glycans in parasitic infections: implications for vaccines and diagnostics," *Archives of Biochemistry and Biophysics*, vol. 426, no. 2, pp. 182–200, 2004.

[51] I. Mueller, I. Betuela, M. Ginny, J. C. Reeder, and B. Genton, "The sensitivity of the OptiMAL rapid diagnostic test to the presence of *Plasmodium falciparum* gametocytes compromises its ability to monitor treatment outcomes in an area of Papua New Guinea in which malaria is endemic," *Journal of Clinical Microbiology*, vol. 45, no. 2, pp. 627–630, 2007.

[52] A. Marx, D. Pewsner, M. Egger, et al., "Meta-analysis: accuracy of rapid tests for malaria in travelers returning from endemic areas," *The American Journal of Tropical Medicine and Hygiene*, vol. 142, no. 10, pp. 836–846, 2005.

[53] R. S. Miller, N. Uthaimongkol, M. F. Fukuda, et al., "Comparison of performance characteristics of the Binax NOW® Malaria test using venous and fingerstick samples," in *Proceedings of the 55th Annual Meeting of the American Society of Tropical Medicine and Hygiene*, Atlanta, Ga, USA, November 2006.

[54] T. F. McCutchan, R. C. Piper, and M. T. Makler, "Use of malaria rapid diagnostic test to identify *Plasmodium knowlesi*

infection," *Emerging Infectious Diseases*, vol. 14, no. 11, pp. 1750–1752, 2008.

[55] R. F. Leke, R. R. Djokam, R. Mbu, et al., "Detection of the *Plasmodium falciparum* antigen histidine-rich protein 2 in blood of pregnant women: implications for diagnosing placental malaria," *Journal of Clinical Microbiology*, vol. 37, no. 9, pp. 2992–2996, 1999.

[56] M. Trachsler, P. Schlagenhauf, and R. Steffen, "Feasibility of a rapid dipstick antigen-capture assay for self-testing of travellers' malaria," *Tropical Medicine & International Health*, vol. 4, no. 6, pp. 442–447, 1999.

[57] S. A. Harvey, L. Jennings, M. Chinyama, F. Masaninga, K. Mulholland, and D. R. Bell, "Improving community health worker use of malaria rapid diagnostic tests in Zambia: package instructions, job aid and job aid-plus-training," *Malaria Journal*, vol. 7, article 160, pp. 1–12, 2008.

[58] T. Endeshaw, T. Gebre, J. Ngondi, et al., "Evaluation of light microscopy and rapid diagnostic test for the detection of malaria under operational field conditions: a household survey in Ethiopia," *Malaria Journal*, vol. 7, article 118, pp. 1–7, 2008.

[59] A. H. Roukens, J. Berg, A. Barbey, and L. G. Visser, "Performance of self-diagnosis and standby treatment of malaria in international oilfield service employees in the field," *Malaria Journal*, vol. 7, article 128, pp. 1–8, 2008.

[60] R. L. Miller, S. Ikram, G. J. Armelagos, et al., "Diagnosis of *Plasmodium falciparum* infections in mummies using the rapid manual *Para*Sight-F test," *Transactions of the Royal Society of Tropical Medicine and Hygiene*, vol. 88, no. 1, pp. 31–32, 1994.

[61] S. A. Shekalaghe, J. T. Bousema, K. K. Kunei, et al., "Submicroscopic *Plasmodium falciparum* gametocyte carriage is common in an area of low and seasonal transmission in Tanzania," *Tropical Medicine & International Health*, vol. 12, no. 4, pp. 547–553, 2007.

[62] P. Mens, N. Spieker, S. Omar, M. Heijnen, H. Schallig, and P. A. Kager, "Is molecular biology the best alternative for diagnosis of malaria to microscopy? A comparison between microscopy, antigen detection and molecular tests in rural Kenya and urban Tanzania," *Tropical Medicine & International Health*, vol. 12, no. 2, pp. 238–244, 2007.

[63] R. E. Coleman, N. Maneechai, N. Rachaphaew, et al., "Comparison of field and expert laboratory microscopy for active surveillance for asymptomatic *Plasmodium falciparum* and *Plasmodium vivax* in western Thailand," *The American Journal of Tropical Medicine and Hygiene*, vol. 67, no. 2, pp. 141–144, 2002.

[64] A. D. Kitchen and P. L. Chiodini, "Malaria and blood transfusion," *Vox Sanguinis*, vol. 90, no. 2, pp. 77–84, 2006.

[65] G. Snounou and N. J. White, "The co-existence of *Plasmodium*: sidelights from falciparum and vivax malaria in Thailand," *Trends in Parasitology*, vol. 20, no. 7, pp. 333–339, 2004.

[66] B. Susi, T. Whitman, D. L. Blazes, T. H. Burgess, G. J. Martin, and D. Freilich, "Rapid diagnostic test for *Plasmodium falciparum* in 32 Marines medically evacuated from liberia with a febrile illness," *Annals of Internal Medicine*, vol. 142, no. 6, pp. 476–477, 2005.

[67] W. M. Stauffer, A. M. Newberry, C. P. Cartwright, et al., "Evaluation of malaria screening in newly arrived refugees to the United States by microscopy and rapid antigen capture enzyme assay," *Pediatric Infectious Disease Journal*, vol. 25, no. 10, pp. 948–950, 2006.

[68] M. E. Rafael, T. Taylor, A. Magil, Y.-W. Lim, F. Girosi, and R. Allan, "Reducing the burden of childhood malaria in Africa: the role of improved," *Nature*, vol. 444, supplement 1, pp. 39–48, 2006.

[69] S. Shillcutt, C. Morel, C. Goodman, et al., "Cost-effectiveness of malaria diagnostic methods in sub-Saharan Africa in an era of combination therapy," *Bulletin of the World Health Organization*, vol. 86, no. 2, pp. 101–110, 2008.

Hindawi Publishing Corporation
Interdisciplinary Perspectives on Infectious Diseases
Volume 2009, Article ID 547090, 8 pages
doi:10.1155/2009/547090

Review Article

Rapid Diagnosis of Intestinal Parasitic Protozoa, with a Focus on *Entamoeba histolytica*

Anjana Singh,[1,2] Eric Houpt,[1] and William A. Petri[1,3]

[1] *University of Virginia, Charlottesville, P.O. Box 801340, VA 22908-1340, USA*
[2] *Central Department of Microbiology, Tribhuvan University, Kirtipur, Kathmandu, Nepal*
[3] *Infectious Diseases and International Health, University of Virginia, MR4 Building, Health System, Charlottesville, VA 22908-1340, USA*

Correspondence should be addressed to William A. Petri, wap3g@virginia.edu

Received 28 January 2009; Accepted 30 March 2009

Recommended by Herbert B. Tanowitz

Entamoeba histolytica is an invasive intestinal pathogenic parasitic protozoan that causes amebiasis. It must be distinguished from *Entamoeba dispar* and *E. moshkovskii*, nonpathogenic commensal parasites of the human gut lumen that are morphologically identical to *E. histolytica*. Detection of specific *E. histolytica* antigens in stools is a fast, sensitive technique that should be considered as the method of choice. Stool real-time PCR is a highly sensitive and specific technique but its high cost make it unsuitable for use in endemic areas where there are economic constraints. Serology is an important component of the diagnosis of intestinal and especially extraintestinal amebiasis as it is a sensitive test that complements the detection of the parasite antigens or DNA. Circulating Gal/GalNac lectin antigens can be detected in the serum of patients with untreated amoebic liver abscess. On the horizon are multiplex real-time PCR assays which permit the identification of multiple enteropathogens with high sensitivity and specificity.

1. Introduction

The World Health Organization (WHO) ranks diarrheal disease as the second highest cause of morbidity and mortality in children in the developing world [1–3]. Enteric protozoa are one case of diarrheal disease in children. Intestinal protozoa are transmitted by the fecal-oral route and exhibit life cycles consisting of a cyst stage and a trophozoite stage. The cysts consist of a resistant wall and are excreted in the feces. The cyst wall functions to protect the organism from desiccation in the external environment. Unhygienic conditions promote transmission of most protozoa. Traditionally parasites have been identified by simple microscopy and serologic methods. New approaches include antigen detection and PCR [4–7].

2. Intestinal Parasites: *Cryptosporidium, Cyclospora, Entamoeba* spp., *Giardia, Isospora*

2.1. Cryptosporidium. The genus *Cryptosporidium* was identified in mice by Edward Tyzzer in 1907 [3]. It was found as human pathogen in 1976. Many species infect humans and a wide range of animals. *Cryptosporidium parvum* and *Cryptosporidium hominis* are the most prevalent species causing disease in humans [8]. Human cryptosporidiosis is also seen with *C. felis, C. meleagridis, C. canis, C. suis,* and *C. muris* [9–11]. In developing countries *Cryptosporium* spp. infections occur mostly in children younger than five years, with most under two years of age [12, 13]. *C. hominis* is the genus which infects only humans while *C. parvum* infects humans and cattle [11]. Recent literature shows that *C. hominis* is the commonest strain found in human stools [9, 14]. Each oocyst measures about 5.2 $\times$ 4.6 micrometers and contains four infective sporozoites. Recently *C. hominis* subgenotyping indicated that the infections included a wide range of subtypes consisting of three subtype families (Ia, Ib, and Id) [3].

2.2. Cyclospora. Cyclospora cayetanensis is a sporulating parasitic protozoan that infects the upper small intestinal tract. It has been identified as both a food and waterborne pathogen endemic in many developing countries. The disease first came to medical attention in the 1970s [15]. It

is an important agent of Traveler's Diarrhea in developed countries and was responsible for numerous food borne outbreaks in the United States and Canada in the late 1990s. Approximately 1500 people during 1996 had *Cyclospora cayetanensis* diarrhea from Guatemalan raspberries. This epidemic recurred in 1997, emphasizing the risks of the global economy and food supply [16]. The ribosomal DNA of *C. cayetanensis* and three other species show a high degree of homology within each other. The *Cyclospora* homology and the lack of its sequence data from other species have hindered identification methods [17]. The incidence of infection of *Cyclospora* is high in the warmer months. Cyclosporiasis was found to be associated with ownership of domestic animals, especially birds, guinea pigs, and rabbits [18]. Many aspects of this disease and its transmission remain still an enigma.

2.3. Entamoeba spp.

2.3.1. Entamoeba dispar. *E. dispar* exists in the colonic lumen as a harmless saprophyte [19]. *E. dispar* and *E. histolytica* are morphologically identical and phylogenetically closely related (~98% identity of rRNA sequences). Both species have a similar host range but have vastly different properties with regard to pathogenicity in vivo [20]. Both *E. histolytica* and *E. dispar* are able to colonize humans but only *E. histolytica* is able to cause invasive disease (colitis and extraintestinal manifestations). Tissue destruction is not seen with *E. dispar* in vivo. Earlier a panel of researchers concluded that colonization with *E. dispar* has never been documented to cause invasive disease in humans therefore the parasite does not necessitate treatment [21–23].

2.3.2. Entamoeba histolytica. The main purpose of detection and differentiation of *E. histolytica* species in stool samples is the detection of the causative agent of amoebic dysentery. About 40–50 million people develop clinical amoebiasis each year, resulting on up to 100 000 deaths [24]. The causative agent of amebic colitis and liver abscess is *E. histolytica*. The non pathogenic parasites *E. dispar* and *E. moshkovskii* are more common and identical in appearance to *E. histolytica* [25, 26]. Invasive strains of *E. histolytica* may cause the deaths; the value (above) for the prevalence of *E. histolytica* is an overestimate since it dates from before the separation of the pathogen *E. histolytica* from the nonpathogen *E. dispar* [26]. Furthermore there are six additional species of amebae (*Entamoeba coli, Entamoeba hartmanni, Entamoeba polecki, Entamoeba chattoni, Iodamoeba butschlii* and *Endolimax nana*) that infect humans [27–37]. There are other amebae that infect humans, that is, Acanthamoeba that cause intestinal infections in humans. *E. nana* and *I. butschlii* colonize the human intestine and are nonpathogenic [38]. Infection due to *E. dispar* is 10 times more common than *E. histolytica*in developed countries [39–43]. Similarly even in a developing country *E. histolytica* and *E. dispar* can be equally prevalent [35]. *E. histolytica* and *E. dispar* share almost 90% genomic identity, and *E. moshkovskii* is also closely genetically related [44].

2.3.3. Entamoeba moshkovskii. The free-living and parasitic amoeba *Entamoeba moshkovskii* is indistinguishable in its cyst and trophozoite forms from *E. histolytica* and *E. dispar*. *E. moshkovskii* has recently been shown to be a common infection of humans in the Indian subcontinent. Early isolates of *E. moshkovskii* were from sewage [45]. *E. moshkovskii* is osmotolerant and identified by growth at room temperature and by riboprinting [45–48]. Human isolates of *E. moshkovskii* have come from North America, South Africa, Bangladesh, and Italy [49, 50]. The pathogenic role of *E. moshkovskii* is yet to be defined. To minimize the confusion with *E. histolytica*/*E. dispar* a diagnostic tool is needed. *E. moshkovskii* prevalence suggests that the infection is common among children [50].

2.4. Giardia. *Giardia* is a binucleated flagellated protozoan and was discovered by Van Leeuwenhoek in 1681. Giardiasis is the most frequent cause of nonbacterial diarrhea throughout the world [51]. Each year 500 000 new cases are reported and about 200 million people develop symptomatic giardiasis [52]. These parasites can be found in mammals and other animals, including reptiles and birds. *Giardia lamblia* (syn. *duodenalis* or *intestinalis*) has two anterior nuclei of equal size that contain complete copies of the genome [53]. The parasite has a ventral adhesive disc made of microtubules. There are four pairs of flagella (one anterior pair, two posterior pairs) and a caudal pair that emerges from the disc. The complex working of the unique *Giardia* cytoskeleton has been reviewed [54]. *Giardia* cysts are resistant to chlorination and ozonolysis and can remain viable for several weeks, especially in cold surface water. The acquisition of *Giardia* occurs most commonly through ingestion of the cyst in contaminated water or food. Even flies can spread viable *Giardia lamblia* cysts on their exoskeleton, which they have acquired naturally from unhygienic sources [55]. There are two distinct genotypes of *G. lamblia* that infect humans, commonly referred to as assemblages A and B. Molecular analyses have shown the genetic variance between the two assemblages to be greater than that used to delineate other species of protozoa [56]. Furthermore, it has been hypothesized that there may be phenotypic differences between assemblages. One study showed an association between intermittent diarrhoea and assemblage A and between persistent diarrhoea and assemblage B [57]. Others studies showed that children with assemblage A were more likely to be symptomatic [58]. A recent study showed that the majority of *G. lamblia* infections in a northeastern Brazilian community were assemblage B [59].

2.5. Isospora. Isosporiasis is a human intestinal disease caused by the parasite *Isospora belli*. It is found worldwide, especially in tropical and subtropical areas. It was first documented in 1915. Infection is seen most frequently in immunocompromised individuals. *I. belli* is a coccidian protozoa in phylum Apicomplexa that parasitizes epithelium of upper small intestine of humans and causes diarrheal disease. The entire life cycle of *Isospora* consists of asexual development and sexual reproduction that take place in

the same host. Transmission of *I. belli* oocysts seems to be confined to the anthroponotic cycle because humans are the only known natural host [60]. The oocysts of *I. belli* usually require less than one day to a few days to complete sporogonic development and become infective [61, 62].

3. Methodological Approaches, with a Focus on Amebiasis Diagnostics

3.1. Microscopic. For amebiasis, microscopy cannot distinguish *E. histolytica* from the more common parasites *E. dispar* and *E. moshkovskii.* It is therefore an obsolete approach to the diagnosis of amebiasis, but still conducted in most parts of the world where modern diagnostic approaches have failed to take hold. For microscopy each stool sample should be divided into two portions. Direct microscopy should be done by mixing a small amount of the specimen in 0.9% sodium chloride solution (wet mount) or Lugol's iodine solution. This allows the detection of motile trophozoites of *Entamoeba histolytica/dispar* and can also provide information on the contents of the stool, that is, the presence of leucocytes and red blood cells. The second portion of the stool sample is then stained with trichrome and/or iodine to identify trophozoites and cysts. Three negative stool samples are required before it can be accepted to report that there is no amoebic infection [63]. Trophozoites containing ingested RBCs are more common with *E. histolytica* than *E. dipar* [64–66]. The sensitivity of microscopy is as less as 60% and confounded with misleading results due to misidentification of macrophages as trophozoites, (polymorphonuclear leukocytes) PMNs as cysts (particularly when lobed nuclei of PMNs break apart), and other "*Entamoeba* species" [64, 66–70].

3.2. Serology. The combination of serology and stool antigen assays is more sensitive and specific than microscopy for the diagnosis of *Entamoeba histolytica* infection [42]. The tests of choice for serology are indirect fluorescent antibody test (IFAT), counter immunoelectrophoresis (CIEP), or enzyme linked immunosorbent assay (ELISA). Serologic tests are positive at the time of clinical presentation of amebiasis in 60–90% of cases, with positive serology seen in the overall population of endemic areas of 5–10% (raising the issue of both false positive and false negative results with serology).

3.2.1. Dipstick. Point of care tests to detect amebiasis would be appropriate technology for the developing world. There are at least two such tests that are in the early stages of development [71, 72].

3.2.2. Rapid Antigen Detection. Stool oocyst and parasites (O&Ps) exam cannot distinguish morphologically the three closely related common amoebae: pathogenic *E. histolytica* and commensal *E. dispar* and *E. moshkovskii*. Differentiation of *E. histolytica* from *E. dispar* most practically can be accomplished by antigen detection. Currently there are several antigen detection tests commercially available for in vitro diagnostic use. The TechLab *E. histolytica* II test detects exclusively *E. histolytica* [73, 74]. Commercial enzyme-linked immunosorbent assays from Merlin and Alexon do not differentiate between *E. histolytica* and *E. dispar* [75, 76]. Buss et al. concluded that the two ELISAs used in their study were relatively quick and easy to perform but the Techlab *E. histolytica* II ELISA outperformed the R-Biopharm Ridascreen *Entamoeba* test [77]. Sensitivity and specificity of the TechLab kit have been studied from all over the world viz. Bangladesh [73], Canada [42], the Netherlands [78], the United Kingdom [79], and India [80].

E. histolytica infection can also be detected through Gal/GalNAc lectin antigen in serum. The advantage is that it is a more sensitive method than detection of antilectin antibody for the early diagnosis of amebic liver abscess (ALA). It is also more specific and uses a well-defined antigen, the Gal/GalNAc lectin. It can also, unlike antibody detection tests, be used as a test of treatment [81]. A disadvantage of this method is that the sensitivity of this method is significantly decreased in ALA patients after initiation of antiamoebic therapy.

Salivary antigen has also been tested as a predictor for invasive disease. In one of the studies it was found that the presence of lectin in saliva had moderate sensitivity (65.8%) and high specificity (97.4%) in early infections (<1 week amebic colitis). Although the noninvasive sample collection is an advantage, the sensitivity of this assay appears to be lower than that of serum antigen detection [82].

3.3. PCR

3.3.1. Conventional PCR. Diagnosis of *E. histolytica* by PCR tests started in the early 1990s. Differentiation of *E. histolytica* from *E. dispar* by restriction fragment analysis of a single gene amplified in vitro was first reported in 1991 [83]. PCR-based approaches have been endorsed by the WHO, and in developed countries has found application in clinical and epidemiological studies [84–87]. Identification of *E. histolytica* can be done from various clinical specimens, such as stool, tissues, and liver abscess aspirate [70]. Though PCR of 18S rDNA is expensive, it is as sensitive as ELISA techniques [88–93]. PCR methods were found to be highly sensitive and specific for detecting parasite DNA from microscopy-positive samples using both manual and automated methods [94–101]. PCR assays targeting 18S rDNA are widely used for the detection and differentiation of *Entamoeba* species. This can be easily detected from a DNA fragment of a single-copy gene or from multicopy, extrachromosomal plasmids in the amoebae [102]. Amplification of *E. histolytica* and *E. dispar* DNA fragments from human stool by conventional PCR has been established to be a sensitive and specific method for its detection [100]. Extraction of DNA was performed directly from stool and amplified using primers that amplify the extra chromosomal circular DNA [100, 101, 103]. Microscopically positive *E. histolytica* positive clinical 27/30 (90%) fecal specimens and 3/30 (10%) liver abscess aspirates from Pharmongkutklao and Ramathibodi hospitals in Bangkok, Thailand were evaluated by PCR. All specimens were reported as positive for *Entamoeba* cysts or trophozoites

by microscopic examination. After being tested with a genus-specific PCR assay [35], 25/30 (83%) samples were positive for *Entamoeba* spp. whereas 5/30 (16.6%) samples were negative. By using the PCR assay developed successfully identified 10/30 (33.3%) clinical samples tested: 4/10 (40%) was positive for *E. histolytica* 6/10 (60%) for *E. dispar.* The same results were obtained when previously described *E. histolytica*-specific and *E. dispar*-specific primers were used [104]. No amplification of *E. moshkovskii* was observed with any specimens [85].

For the simultaneous detection and differentiation of *E. histolytica* and *E. dispar* from DNA extracted from microscopy-positive fecal samples (fresh and formalin-fixed) multiplex PCR was developed with a reported sensitivity and specificity of 94% and 100%, respectively [86, 105, 106]. Haque et al. identified *E. moshkovskii* in fecal specimens using a riboprinting method [49]. A PCR test for the identification of *E. moshkovskii* in fecal samples was developed and shown to have a high sensitivity and specificity using DNA extracted directly from stool samples with the QIAGEN stool extraction kit [106, 107]. A simpler PCR molecular detection tool developed by Ali et al. for diagnosing *E. moshkovskii* infections was used to detect the parasite directly in stool. Out of 109 tested stool specimens from preschool children in Bangladesh by PCR, *E. histolytica* was detected in 17/109 (15.6%), *E. dispar* in 39/109 (35.8%), *E. moshkovskii* in 23/109 (21.1%), mixed infection of *E. histolytica* and *E. dispar* in 17 (73.9%), and *E. dispar* and *E. moshkovskii* coinfection in 11/23 (48%) [50]. The high association of *E. moshkovskii* with *E. dispar* may have obscured its identification in previous studies.

3.3.2. Real-Time PCR. The beauty of a newly developed real-time PCR (qPCR) methodology for laboratory diagnosis of infectious diseases is that it is more sensitive than conventional PCR, is more rapid, leading to shorter turnaround times, has a reduced risk of amplicon contamination from laboratory environments, and has reduced reagent costs [108]. Specific detection of the amplicon occurs, enabling continuous monitoring of amplicon (PCR product) formation throughout the reaction. In comparison to conventional PCR, real-time PCR is more sensitive and is also quantitative. Several qPCR methods have been designed [109–111]. Clinical specimens may contain impurities that might inhibit enzyme-based nucleic acid amplification. Therefore, the use of internal controls (ICs) for the routine diagnostic PCR provides assurance that the clinical specimens are successfully amplified and detected.

For single-plex real-time PCR detection of *E. histolytica,* Qvarnstrom et al. used TaqMan probes targeting the 18S rRNA gene, with the SYBR Green approach offering a good alternative (but not sequence-specific) to the TaqMan assay [109].

Verweij et al. developed a multiplex qPCR assay for detection of three different intestinal parasites *E. histolytica*, *G. lamblia*, and *C. parvum*. Their study showed 100% (20/20) amplification of *E. histolytica* and *G. lamblia* DNA in microscopically positive isolates. Further, in 20 samples in which modified acid-fast staining revealed *Cryptosporidium* oocysts and in 4/7 (57%) samples from an immunocompromised child with complaints of diarrhea, *C. parvum* DNA was detected with the qPCR tested [111]. Verweij et al. showed multiplex PCR 100% specificity and sensitivity for *E. histolytica* and *G. lamblia,* and *C. parvum* [112].

Later Haque et al. produced a multiplex real-time PCR assay for the detection of *E. histolytica*, *G. lamblia*, and *C. parvum*. The detection limit for the multiplex real-time PCR was 1 trophozoite of *E. histolytica* per extraction (100 μL), 10 trophozoites of *G. intestinalis* per extraction, and 100 oocysts of *Cryptosporidium* per extraction [21]. The multiplex qPCR assay demonstrated 83/97 (85%) agreement with microscopy for *Giardia*, with specificity for *E. histolytica* and *G. lamblia,* and *C. parvum* of 98%, 97%, and 100%, respectively [21].

In another study qPCR for *E. histolytica* was positive in 20/23 (87%) liver abscess pus specimens, with the 3 negative specimens from samples collected from patients who had already received antiamebic therapy [108]. Results have been highly specific and sensitive [40].

Stroup et al. developed a *Cryptosporidium* qPCR species-specific probe assay that is sensitive and simple to perform. The assay was done on 123 human stool specimens from Bangladesh and Tanzania and exhibited a sensitivity and specificity of >91% versus microscopy. *Cryptosporidium parvum*-specific and *Cryptosporidium meleagridis*-specific scorpion qPCR assays provided 100% accurate speciation compared with Vspl RFLP analysis and sequencing [113].

An *Isospora belli* qPCR assay was performed with 21 positive and 120 negative stool samples and achieved 100% specificity and sensitivity. PCR could supplement the clinical laboratory diagnosis of isosporiasis, in particular in patients with a history of diarrhea developing during or immediately after travel to developing countries [114].

4. Future Approaches

The burden of enteric protozoan infections is so great in developed and developing countries that there is a need for better diagnostic tests. The production of point-of-care lateral flow "dipstick" antigen detection tests and high-throughput screening tests based on antigen detection or PCR are clear priorities.

5. Conclusions

In the clinical laboratories the diagnosis of intestinal amebiasis should use a combination of detection of the parasite by antigen detection or PCR (using *E. histolytica* specific tests) and serological testing, and/or by colonoscopy and biopsy of intestinal amebic lesions, and in the case of amebic liver abscess by a combination of serology and drainage of the liver abscess with testing of the fluid for the parasite ideally by PCR. The development of molecular tools, including antigen detection and PCR and qPCR, to detect *E. histolytica, E. dispar*, *E. moshkovskii*, *Giardia* spp, and *Cryptosporidium* spp. DNA in stool or liver abscess samples promises to provide major advances. The amalgamation of many new

technologies into the diagnostic laboratory will represent a challenge to all, but may lead to a better understanding of the public health problems represented by these diseases.

Acknowledgments

A. Singh is thankful to Fulbright Scholar Program, Council for International Exchange of Scholars (CIES), USA, for granting her post-doctoral fellowship in the Department of Infectious and International Health, Health System, University of Virginia. She is also grateful to Central Department of Microbiology, Tribhuvan University, Kirtipur, Kathmandu, Nepal for granting her the study leave for this study. Work from the authors' laboratories has been supported by NIH Grant AI043596.

References

[1] WHO, "Making every mother and child count," World Health Report, World Health Organization, Geneva, Switzerland, 2005.

[2] WHO, "Fighting disease, fostering development," World Health Report, World Health Organization, Geneva, Switzerland, 1996.

[3] L. Pelayo, F. A. Nuñez, L. Rojas, et al., "Molecular and epidemiological investigations of cryptosporidiosis in Cuban children," *Annals of Tropical Medicine and Parasitology*, vol. 102, no. 8, pp. 659–669, 2008.

[4] B. Svenungsson, A. Lagergren, E. Ekwall, et al., "Enteropathogens in adult patients with diarrhea and healthy control subjects: a 1-year prospective study in a Swedish clinic for infectious diseases," *Clinical Infectious Diseases*, vol. 30, no. 5, pp. 770–778, 2000.

[5] J. Gascón, M. Vargas, D. Schellenberg, et al., "Diarrhea in children under 5 years of age from Ifakara, Tanzania: a case-control study," *Journal of Clinical Microbiology*, vol. 38, no. 12, pp. 4459–4462, 2000.

[6] Y. Germani, M. Morillon, E. Begaud, H. Dubourdieu, R. Costa, and J. Thevenon, "Two-year study of endemic enteric pathogens associated with acute diarrhea in New Caledonia," *Journal of Clinical Microbiology*, vol. 32, no. 6, pp. 1532–1536, 1994.

[7] M. Youssef, A. Shurman, M.-E. Bougnoux, M. Rawashdeh, S. Bretagne, and N. Strockbine, "Bacterial, viral and parasitic enteric pathogens associated with acute diarrhea in hospitalized children from northern Jordan," *FEMS Immunology & Medical Microbiology*, vol. 28, no. 3, pp. 257–263, 2000.

[8] O. Y. Bushen, A. Kohli, R. C. Pinkerton, et al., "Heavy cryptosporidial infections in children in northeast Brazil: comparison of *Cryptosporidium hominis* and *Cryptosporidium parvum*," *Transactions of the Royal Society of Tropical Medicine and Hygiene*, vol. 101, no. 4, pp. 378–384, 2007.

[9] V. Cama, R. H. Gilman, A. Vivar, et al., "Mixed *Cryptosporidium* infections and HIV," *Emerging Infectious Diseases*, vol. 12, no. 6, pp. 1025–1028, 2006.

[10] D. B. Huang and A. C. White, "An updated review on *Cryptosporidium* and *Giardia*," *Gastroenterology Clinics of North America*, vol. 35, no. 2, pp. 291–314, 2006.

[11] A. Samie, P. O. Bessong, C. L. Obi, et al., "*Cryptosporidium* species: preliminary descriptions of the prevalence and genotype distribution among school children and hospital patients in the Venda region, Limpopo Province, South Africa," *Experimental Parasitology*, vol. 114, no. 4, pp. 314–322, 2006.

[12] J. K. Tumwine, A. Kekitiinwa, N. Nabukeera, et al., "*Cryptosporidium parvum* in children with diarrhea in Mulago Hospital, Kampala, Uganda," *The American Journal of Tropical Medicine and Hygiene*, vol. 68, no. 6, pp. 710–715, 2003.

[13] E. B. Steinberg, C. E. Mendoza, R. Glass, et al., "Prevalence of infection with waterborne pathogens: a seroepidemiologic study in children 6–36 months old in San Juan Sacatepequez, Guatemala," *The American Journal of Tropical Medicine and Hygiene*, vol. 70, no. 1, pp. 83–88, 2004.

[14] E. Houpt, O. Y. Bushen, N. E. Sam, et al., "Short report: asymptomatic *Cryptosporidium hominis* infection among human immundeficiency virus-infected patients in Tanzania," *The American Journal of Tropical Medicine and Hygiene*, vol. 73, no. 3, pp. 520–522, 2005.

[15] C. C. Mundaca, P. A. Torres-Slimming, R. V. Araujo-Castillo, et al., "Use of PCR to improve diagnostic yield in an outbreak of cyclosporiasis in Lima, Peru," *Transactions of the Royal Society of Tropical Medicine and Hygiene*, vol. 102, no. 7, pp. 712–717, 2008.

[16] C. D. Huston and W. A. Petri Jr., "Emerging and reemerging intestinal protozoa," *Current Opinion in Gastroenterology*, vol. 17, no. 1, pp. 17–23, 2001.

[17] J. M. Shields and B. H. Olson, "*Cyclospora cayetanensis*: a review of an emerging parasitic coccidian," *International Journal for Parasitology*, vol. 33, no. 4, pp. 371–391, 2003.

[18] C. Bern, B. Hernandez, M. B. Lopez, M. J. Arrowood, A. M. De Merida, and R. E. Klein, "The contrasting epidemiology of *Cyclospora* and *Cryptosporidium* among outpatients in Guatemala," *The American Journal of Tropical Medicine and Hygiene*, vol. 63, no. 5-6, pp. 231–235, 2000.

[19] W. A. Petri Jr. and U. Singh, "Diagnosis and management of amebiasis," *Clinical Infectious Diseases*, vol. 29, no. 5, pp. 1117–1125, 1999.

[20] A. Jetter, B. Walderich, D. Britten, et al., "An epidemiological study of *Entamoeba histolytica* and *E. dispar* infection in eastern Turkey using a colorimetric polymerase chain reaction," *Archives of Medical Research*, vol. 28, pp. 319–321, 1997.

[21] R. Haque, S. Roy, A. Siddique, et al., "Multiplex real-time PCR assay for detection of *Entamoeba histolytica*, *Giardia intestinalis*, and *Cryptosporidium* spp.," *The American Journal of Tropical Medicine and Hygiene*, vol. 76, no. 4, pp. 713–717, 2007.

[22] T. F. H. G. Jackson, "*Entamoeba histolytica* and *Entamoeba dispar* are distinct species; clinical, epidemiological and serological evidence," *International Journal for Parasitology*, vol. 28, no. 1, pp. 181–186, 1998.

[23] D. Trissl, A. Martinez-Palomo, M. de la Torre, R. de la Hoz, and E. Perez de Suarez, "Surface properties of *Entamoeba*: increased rates of human erythrocyte phagocytosis in pathogenic strains," *Journal of Experimental Medicine*, vol. 148, no. 5, pp. 1137–1143, 1978.

[24] A. L. Walsh, "Prevalence in *Entamoeba histolytica* infection," in *Amebiasis: Human Infection by Entamoeba histolytica*, J. I. Ravdin, Ed., pp. 93–105, John Wiley & Sons, New York, NY, USA, 1988.

[25] World Health Organization, "Amoebiasis," *Weekly Epidemiological Record*, vol. 72, pp. 97–100, 1997.

[26] L. S. Diamond and C. G. Clark, "A redescription of *Entamoeba histolytica* Schaudinn, 1903 (Emended Walker, 1911)

separating it from *Entamoeba dispar* Brumpt, 1925," *The Journal of Eukaryotic Microbiology*, vol. 40, no. 3, pp. 340–344, 1993.

[27] J. D. Silberman, C. G. Clark, L. S. Diamond, and M. L. Sogin, "Phylogeny of the genera *Entamoeba* and *Endolimax* as deduced from small-subunit ribosomal RNA sequences," *Molecular Biology and Evolution*, vol. 16, no. 12, pp. 1740–1751, 1999.

[28] E. K. Markell, D. T. John, and W. A. Krotoski, "Lumen-dwelling protozoa," in *Markell and Voge's Medical Parasitology*, pp. 24–89, W. B. Saunders, Philadelphia, Pa, USA, 8th edition, 1999.

[29] D. T. John and W. A. Petri Jr., *Markell and Voge's Medical Parasitology*, Elsevier, Amsterdam, The Netherlands, 9th edition, 2006.

[30] L. Chacin-Bonilla, "*Entamoeba polecki*: human infections in Venezuela," *Transactions of the Royal Society of Tropical Medicine and Hygiene*, vol. 86, no. 6, p. 634, 1992.

[31] T. K. Graczyk, C. K. Shiff, L. Tamang, F. Munsaka, A. M. Beitin, and W. J. Moss, "The association of *Blastocystis hominis* and *Endolimax nana* with diarrheal stools in Zambian school-age children," *Parasitology Research*, vol. 98, no. 1, pp. 38–43, 2005.

[32] M. Wahlgren, "*Entamoeba coli* as cause of diarrhea?" *The Lancet*, vol. 337, no. 8742, p. 675, 1991.

[33] A. González-Ruiz, R. Haque, A. Aguirre, et al., "Value of microscopy in the diagnosis of dysentery associated with invasive *Entamoeba histolytica*," *Journal of Clinical Pathology*, vol. 47, no. 3, pp. 236–239, 1994.

[34] R. Haque, L. M. Neville, P. Hahn, and W. A. Petri Jr., "Rapid diagnosis of *Entamoeba* infection by using *Entamoeba* and *Entamoeba histolytica* stool antigen detection kits," *Journal of Clinical Microbiology*, vol. 33, no. 10, pp. 2558–2561, 1995.

[35] J. J. Verweij, A. M. Polderman, and C. Graham Clark, "Genetic variation among human isolates of uninucleated cyst-producing *Entamoeba* species," *Journal of Clinical Microbiology*, vol. 39, no. 4, pp. 1644–1646, 2001.

[36] R. Haque, C. D. Huston, M. Hughes, E. Houpt, and W. A. Petri Jr., "Amebiasis," *The New England Journal of Medicine*, vol. 348, no. 16, pp. 1565–1573, 2003.

[37] I. K. M. Ali, C. G. Clark, and W. A. Petri Jr., "Molecular epidemiology of amebiasis," *Infection, Genetics and Evolution*, vol. 8, no. 5, pp. 698–707, 2008.

[38] K. D. Kappus, R. G. Lundgren Jr., D. D. Juranek, J. M. Roberts, and H. C. Spencer, "Intestinal parasitism in the United States: update on a continuing problem," *The American Journal of Tropical Medicine and Hygiene*, vol. 50, no. 6, pp. 705–713, 1994.

[39] V. Gathiram and T. F. H. G. Jackson, "A longitudinal study of asymptomatic carriers of pathogenic zymodemes of *Entamoeba histolytica*," *South African Medical Journal*, vol. 72, no. 10, pp. 669–672, 1987.

[40] J. Blessmann, I. K. M. Ali, P. A. Ton Nu, et al., "Longitudinal study of intestinal *Entamoeba histolytica* infections in asymptomatic adult carriers," *Journal of Clinical Microbiology*, vol. 41, no. 10, pp. 4745–4750, 2003.

[41] R. Haque, D. Mondal, P. Duggal, et al., "*Entamoeba histolytica* infection in children and protection from subsequent amebiasis," *Infection and Immunity*, vol. 74, no. 2, pp. 904–909, 2006.

[42] D. R. Pillai, J. S. Keystone, D. C. Sheppard, J. D. MacLean, D. W. MacPherson, and K. C. Kain, "*Entamoeba histolytica* and *Entamoeba dispar*: epidemiology and comparison of diagnostic methods in a setting of nonendemicity," *Clinical Infectious Diseases*, vol. 29, no. 5, pp. 1315–1318, 1999.

[43] W. A. Petri Jr., R. Haque, D. Lyerly, and R. R. Vines, "Estimating the impact of amebiasis on health," *Parasitology Today*, vol. 16, no. 8, pp. 320–321, 2000.

[44] C. G. Clark and L. S. Diamond, "Intraspecific variation and phylogenetic relationships in the genus *Entamoeba* as revealed by riboprinting," *Journal of Eukaryotic Microbiology*, vol. 44, no. 2, pp. 142–154, 1997.

[45] D. A. Dreyer, "Growth of a strain of *Entamoeba histolytica* at room temperature," *Texas Reports on Biology and Medicine*, vol. 19, pp. 393–396, 1961.

[46] N. Entner and H. Most, "Genetics of *Entamoeba*: characterization of two new parasitic strains which grow at room temperature (and at 37°C)," *Journal of Protozoology*, vol. 12, pp. 10–13, 1965.

[47] C. S. Richards, M. Goldman, and L. T. Cannon, "Cultivation of *Entamoeba histolytica* and *Entamoeba histolytica*-like strains at reduced temperature and behavior of the amebae in diluted media," *The American Journal of Tropical Medicine and Hygiene*, vol. 15, no. 4, pp. 648–655, 1966.

[48] C. G. Clark and L. S. Diamond, "The Laredo strain and other '*Entamoeba histolytica*-like' amoebae are *Entamoeba moshkovskii*," *Molecular and Biochemical Parasitology*, vol. 46, no. 1, pp. 11–18, 1991.

[49] R. Haque, I. K. M. Ali, C. G. Clark, and W. A. Petri Jr., "A case report of *Entamoeba moshkovskii* infection in a Bangladeshi child," *Parasitology International*, vol. 47, no. 3, pp. 201–202, 1998.

[50] I. K. M. Ali, M. B. Hossain, S. Roy, et al., "*Entamoeba moshkovskii* infections in children in Bangladesh," *Emerging Infectious Diseases*, vol. 9, no. 5, pp. 580–584, 2003.

[51] R. D. Adam, "Biology of *Giardia lamblia*," *Clinical Microbiology Reviews*, vol. 14, no. 3, pp. 447–475, 2001.

[52] U.S. Department of Health and Human Services, *Addressing Emerging Infectious Disease Threats: A Prevention Strategy for the United States*, Centers for Disease Control and Prevention, Atlanta, Ga, USA, 1994.

[53] L. Z. Yu, C. W. Birky Jr., and R. D. Adam, "The two nuclei of *Giardia* each have complete copies of the genome and are partitioned equationally at cytokinesis," *Eukaryotic Cell*, vol. 1, no. 2, pp. 191–199, 2002.

[54] H. G. Elmendorf, S. C. Dawson, and J. M. McCaffery, "The cytoskeleton of *Giardia lamblia*," *International Journal for Parasitology*, vol. 33, no. 1, pp. 3–28, 2003.

[55] T. K. Graczyk, B. H. Grimes, R. Knight, A. J. Da Silva, N. J. Pieniazek, and D. A. Veal, "Detection of *Cryptosporidium parvum* and *Giardia lamblia* carried by synanthropic flies by combined fluorescent in situ hybridization and a monoclonal antibody," *The American Journal of Tropical Medicine and Hygiene*, vol. 68, no. 2, pp. 228–232, 2003.

[56] R. C. A. Thompson, R. M. Hopkins, and W. L. Homan, "Nomenclature and genetic groupings of *Giardia* infecting mammals," *Parasitology Today*, vol. 16, no. 5, pp. 210–213, 2000.

[57] W. L. Homan and T. G. Mank, "Human giardiasis: genotype linked differences in clinical symptomatology," *International Journal for Parasitology*, vol. 31, no. 8, pp. 822–826, 2001.

[58] R. Haque, S. Roy, M. Kabir, S. E. Stroup, D. Mondal, and E. Houpt, "*Giardia* assemblage A infection and diarrhea in Bangladesh," *The Journal of Infectious Diseases*, vol. 192, no. 12, pp. 2171–2173, 2005.

[59] A. Kohli, O. Y. Bushen, R. C. Pinkerton, et al., "*Giardia duodenalis* assemblage, clinical presentation and markers of intestinal inflammation in Brazilian children," *Transactions of the Royal Society of Tropical Medicine and Hygiene*, vol. 102, no. 7, pp. 718–725, 2008.

[60] D. S. Lindsay, J. P. Dubey, and B. L. Blagburn, "Biology of *Isospora* spp. from humans, nonhuman primates, and domestic animals," *Clinical Microbiology Reviews*, vol. 10, no. 1, pp. 19–34, 1997.

[61] V. Zaman, "Observations on human *Isospora*," *Transactions of the Royal Society of Tropical Medicine and Hygiene*, vol. 62, no. 4, pp. 556–557, 1968.

[62] N. Morakote, Y. Muangyimpong, P. Somboon, and C. Khamboonruang, "Acute human isosporiasis in Thailand: a case report," *The Southeast Asian Journal of Tropical Medicine and Public Health*, vol. 18, no. 1, pp. 107–111, 1987.

[63] E. Li and S. L. Stanley Jr., "Protozoa. Amebiasis," *Gastroenterology Clinics of North America*, vol. 25, no. 3, pp. 471–492, 1996.

[64] A. González-Ruiz, R. Haque, A. Aguirre, et al., "Value of microscopy in the diagnosis of dysentery associated with invasive *Entamoeba histolytica*," *Journal of Clinical Pathology*, vol. 47, no. 3, pp. 236–239, 1994.

[65] W. D. Strachan, W. M. Spice, P. L. Chiodini, A. H. Moody, and J. P. Ackers, "Immunological differentiation of pathogenic and non-pathogenic isolates of *Entamoeba histolytica*," *Lancet*, vol. 331, no. 8585, pp. 561–563, 1988.

[66] R. Haque, L. M. Neville, P. Hahn, and W. A. Petri Jr., "Rapid diagnosis of *Entamoeba* infection by using *Entamoeba* and *Entamoeba histolytica* stool antigen detection kits," *Journal of Clinical Microbiology*, vol. 33, no. 10, pp. 2558–2561, 1995.

[67] D. J. Korgstad, H. C. Spencer Jr., G. R. Healy, N. N. Gleason, D. J. Sexton, and C. A. Herron, "Amebiasis: epidemiologic studies in the United Sates, 1971–1974," *Annals of Internal Medicine*, vol. 88, no. 1, pp. 89–97, 1978.

[68] R. Haque, A. S. G. Faruque, P. Hahn, D. M. Lyerly, and W. A. Petri Jr., "*Entamoeba histolytica* and *Entamoeba dispar* infection in children in Bangladesh," *The Journal of Infectious Diseases*, vol. 175, no. 3, pp. 734–736, 1997.

[69] R. Haque, I. K. M. Ali, C. G. Clark, and W. A. Petri Jr., "A case report of *Entamoeba moshkovskii* infection in a Bangladeshi child," *Parasitology International*, vol. 47, no. 3, pp. 201–202, 1998.

[70] M. Tanyuksel and W. A. Petri Jr., "Laboratory diagnosis of amebiasis," *Clinical Microbiology Reviews*, vol. 16, no. 4, pp. 713–729, 2003.

[71] M. Leo, R. Haque, M. Kabir, et al., "Evaluation of *Entamoeba histolytica* antigen and antibody point-of-care tests for the rapid diagnosis of amebiasis," *Journal of Clinical Microbiology*, vol. 44, no. 12, pp. 4569–4571, 2006.

[72] H. R. van Doorn, H. Hofwegen, R. Koelewijn, et al., "Use of rapid dipstick and latex agglutination tests and enzyme-linked immunosorbent assay for serodiagnosis of amebic liver abscess, amebic colitis, and *Entamoeba histolytica* cyst passage," *Journal of Clinical Microbiology*, vol. 43, no. 9, pp. 4801–4806, 2005.

[73] R. Haque, N. U. Mollah, I. K. M. Ali, et al., "Diagnosis of amebic liver abscess and intestinal infection with the TechLab *Entamoeba histolytica* II antigen detection and antibody tests," *Journal of Clinical Microbiology*, vol. 38, no. 9, pp. 3235–3239, 2000.

[74] R. Haque and W. A. Petri Jr., "Diagnosis of amebiasis in Bangladesh," *Archives of Medical Research*, vol. 37, no. 2, pp. 272–275, 2006.

[75] I. M. Krupp and S. J. Powell, "Comparative study of the antibody response in amebiasis. Persistence after successful treatment," *The American Journal of Tropical Medicine and Hygiene*, vol. 20, no. 3, pp. 421–424, 1971.

[76] S. L. Stanley Jr., T. F. H. G. Jackson, L. Foster, and S. Singh, "Longitudinal study of the antibody response to recombinant *Entamoeba histolytica* antigens in patients with amebic liver abscess," *The American Journal of Tropical Medicine and Hygiene*, vol. 58, no. 4, pp. 414–416, 1998.

[77] S. Buss, M. Kabir, W. A. Petri Jr., and R. Haque, "Comparison of two immunoassays for detection of *Entamoeba histolytica*," *Journal of Clinical Microbiology*, vol. 46, no. 8, pp. 2778–2779, 2008.

[78] L. G. Visser, J. J. Verweij, M. Van Esbroeck, W. M. Edeling, J. Clerinx, and A. M. Polderman, "Diagnostic methods for differentiation of *Entamoeba histolytica* and *Entamoeba dispar* in carriers: performance and clinical implications in a non-endemic setting," *International Journal of Medical Microbiology*, vol. 296, no. 6, pp. 397–403, 2006.

[79] S. J. Furrows, A. H. Moody, and P. L. Chiodini, "Comparison of PCR and antigen detection methods for diagnosis of *Entamoeba histolytica* infection," *Journal of Clinical Pathology*, vol. 57, no. 12, pp. 1264–1266, 2004.

[80] A. K. Sharma, S. Chibbar, G. Bansal, U. Kaur, and H. Vohra, "Evaluation of newer diagnostic methods for the detection and differentiation of *Entamoeba histolytica* in an endemic area," *Transactions of the Royal Society of Tropical Medicine and Hygiene*, vol. 97, no. 4, pp. 396–397, 2003.

[81] D. R. Pillai and K. C. Kain, "Recent developments in amoebiasis: the Gal/GalNAc lectins of *Entamoeba histolytica* and *Entamoeba dispar*," *Microbes and Infection*, vol. 2, no. 14, pp. 1775–1783, 2000.

[82] K. Khairnar and S. C. Parija, "Detection of *Entamoeba histolytica* DNA in the saliva of amoebic liver abscess patients who received prior treatment with metronidazole," *Journal of Health, Population and Nutrition*, vol. 26, no. 4, pp. 418–425, 2008.

[83] E. Tannich and G. D. Burchard, "Differentiation of pathogenic from nonpathogenic *Entamoeba histolytica* by restriction fragment analysis of a single gene amplified in vitro," *Journal of Clinical Microbiology*, vol. 29, no. 2, pp. 250–255, 1991.

[84] A. Calderaro, C. Gorrini, S. Bommezzadri, G. Piccolo, G. Dettori, and C. Chezzi, "*Entamoeba histolytica* and *Entamoeba dispar*: comparison of two PCR assays for diagnosis in a non-endemic setting," *Transactions of the Royal Society of Tropical Medicine and Hygiene*, vol. 100, no. 5, pp. 450–457, 2006.

[85] Z. Hamzah, S. Petmitr, M. Mungthin, S. Leelayoova, and P. Chavalitshewinkoon-Petmitr, "Differential detection of *Entamoeba histolytica*, *Entamoeba dispar*, and *Entamoeba moshkovskii* by a single-round PCR assay," *Journal of Clinical Microbiology*, vol. 44, no. 9, pp. 3196–3200, 2006.

[86] R. Haque, I. K. M. Ali, S. Akther, and W. A. Petri Jr., "Comparison of PCR, isoenzyme analysis, and antigen detection for diagnosis of *Entamoeba histolytica* infection," *Journal of Clinical Microbiology*, vol. 36, no. 2, pp. 449–452, 1998.

[87] M. Zaki, P. Meelu, W. Sun, and C. G. Clark, "Simultaneous differentiation and typing of *Entamoeba histolytica* and *Entamoeba dispar*," *Journal of Clinical Microbiology*, vol. 40, no. 4, pp. 1271–1276, 2002.

[88] D. Mirelman, Y. Nuchamowitz, and T. Stolarsky, "Comparison of use of enzyme-linked immunosorbent assay-based

kits and PCR amplification of rRNA genes for simultaneous detection of *Entamoeba histolytica* and *E. dispar*," *Journal of Clinical Microbiology*, vol. 35, no. 9, pp. 2405–2407, 1997.

[89] H. Troll, H. Marti, and N. Weiss, "Simple differential detection of *Entamoeba histolytica* and *Entamoeba dispar* in fresh stool specimens by sodium acetate-acetic acid-formalin concentration and PCR," *Journal of Clinical Microbiology*, vol. 35, no. 7, pp. 1701–1705, 1997.

[90] C. G. Clark and L. S. Diamond, "Ribosomal RNA genes of 'pathogenic' and 'nonpathogenic' *Entamoeba histolytica* are distinct," *Molecular and Biochemical Parasitology*, vol. 49, no. 2, pp. 297–302, 1991.

[91] C. G. Clark and L. S. Diamond, "Differentiation of pathogenic *Entamoeba histolytica* from other intestinal protozoa by riboprinting," *Archives of Medical Research*, vol. 23, no. 2, pp. 15–16, 1992.

[92] J. A. Cruz-Reyes, W. M. Spice, T. Rehman, E. Gisborne, and J. P. Ackers, "Ribosomal DNA sequences in the differentiation of pathogenic and non-pathogenic isolates of *Entamoeba histolytica*," *Parasitology*, vol. 104, no. 2, pp. 239–246, 1992.

[93] X. Que and S. L. Reed, "Nucleotide sequence of a small subunit ribosomal RNA (16S-like rRNA) gene from *Entamoeba histolytica*: differentiation of pathogenic from nonpathogenic isolates," *Nucleic Acids Research*, vol. 19, no. 19, p. 5438, 1991.

[94] C. G. Clark and L. S. Diamond, "*Entamoeba histolytica*: a method for isolate identification," *Experimental Parasitology*, vol. 77, no. 4, pp. 450–455, 1993.

[95] C. G. Clark and L. S. Diamond, "Intraspecific variation and phylogenetic relationships in the genus *Entamoeba* as revealed by riboprinting," *Journal of Eukaryotic Microbiology*, vol. 44, no. 2, pp. 142–154, 1997.

[96] P. Morán, F. Ramos, M. Ramiro, et al., "*Entamoeba histolytica* and/or *Entamoeba dispar*: infection frequency in HIV$^+$/AIDS patients in Mexico city," *Experimental Parasitology*, vol. 110, no. 3, pp. 331–334, 2005.

[97] P. Morán, F. Ramos, M. Ramiro, et al., "Infection by human immunodeficiency virus-1 is not a risk factor for amebiasis," *The American Journal of Tropical Medicine and Hygiene*, vol. 73, no. 2, pp. 296–300, 2005.

[98] F. Ramos, P. Morán, E. González, et al., "*Entamoeba histolytica* and *Entamoeba dispar*: prevalence infection in a rural mexican community," *Experimental Parasitology*, vol. 110, no. 3, pp. 327–330, 2005.

[99] F. Ramos, E. Valdez, P. Morán, et al., "Prevalence of *Entamoeba histolytica* and *Entamoeba dispar* in a highly endemic rural population," *Archives of Medical Research*, vol. 31, no. 4, supplement 1, pp. S34–S35, 2000.

[100] J. J. Verweij, J. Blotkamp, E. A. T. Brienen, A. Aguirre, and A. M. Polderman, "Differentiation of *Entamoeba histolytica* and *Entamoeba dispar* cysts using polymerase chain reaction on DNA isolated from faeces with spin columns," *European Journal of Clinical Microbiology & Infectious Diseases*, vol. 19, no. 5, pp. 358–361, 2000.

[101] J. J. Verweij, L. van Lieshout, C. Blotkamp, et al., "Differentiation of *Entamoeba histolytica* and *Entamoeba dispar* using PCR-SHELA and comparison of antibody response," *Archives of Medical Research*, vol. 31, no. 4, supplement 1, pp. S44–S46, 2000.

[102] S. Bhattacharya, A. Bhattacharya, L. S. Diamond, and A. T. Soldo, "Circular DNA of *Entamoeba histolytica* encodes ribosomal RNA," *Journal of Protozoology*, vol. 36, no. 5, pp. 455–458, 1989.

[103] H. Tachibana, S. Kobayashi, M. Takekoshi, and S. Ihara, "Distinguishing pathogenic isolates of *Entamoeba histolytica* by polymerase chain reaction," *The Journal of Infectious Diseases*, vol. 164, no. 4, pp. 825–826, 1991.

[104] Y. O. Núñez, M. A. Fernández, D. Torres-Núñez, et al., "Multiplex polymerase chain reaction amplification and differentiation of *Entamoeba histolytica* and *Entamoeba dispar* DNA from stool samples," *The American Journal of Tropical Medicine and Hygiene*, vol. 64, no. 5, pp. 293–297, 2001.

[105] M. G. Paglia and P. Visca, "An improved PCR-based method for detection and differentiation of *Entamoeba histolytica* and *Entamoeba dispar* in formalin-fixed stools," *Acta Tropica*, vol. 92, no. 3, pp. 273–277, 2004.

[106] I. K. M. Ali, M. B. Hossain, S. Roy, et al., "*Entamoeba moshkovskii* infections in children in Bangladesh," *Emerging Infectious Diseases*, vol. 9, no. 5, pp. 580–584, 2003.

[107] R. Fotedar, D. Stark, N. Beebe, D. Marriott, J. Ellis, and J. Harkness, "Laboratory diagnostic techniques for *Entamoeba* species," *Clinical Microbiology Reviews*, vol. 20, no. 3, pp. 511–532, 2007.

[108] D. Klein, "Quantification using real-time PCR technology: applications and limitations," *Trends in Molecular Medicine*, vol. 8, no. 6, pp. 257–260, 2002.

[109] S. Roy, M. Kabir, D. Mondal, I. K. M. Ali, W. A. Petri Jr., and R. Haque, "Real-time-PCR assay for diagnosis of *Entamoeba histolytica* infection," *Journal of Clinical Microbiology*, vol. 43, no. 5, pp. 2168–2172, 2005.

[110] Y. Qvarnstrom, C. James, M. Xayavong, et al., "Comparison of real-time PCR protocols for differential laboratory diagnosis of amebiasis," *Journal of Clinical Microbiology*, vol. 43, no. 11, pp. 5491–5497, 2005.

[111] M. Rosenstraus, Z. Wang, S.-Y. Chang, D. Debonville, and J. P. Spadoro, "An internal control for routine diagnostic PCR: design, properties, and effect on clinical performance," *Journal of Clinical Microbiology*, vol. 36, no. 1, pp. 191–197, 1998.

[112] J. J. Verweij, R. A. Blangé, K. Templeton, et al., "Simultaneous detection of *Entamoeba histolytica*, *Giardia lamblia*, and *Cryptosporidium parvum* in fecal samples by using multiplex real-time PCR," *Journal of Clinical Microbiology*, vol. 42, no. 3, pp. 1220–1223, 2004.

[113] S. E. Stroup, S. Roy, J. Mchele, et al., "Real-time PCR detection and speciation of *Cryptosporidium* infection using Scorpion probes," *Journal of Medical Microbiology*, vol. 55, no. 9, pp. 1217–1222, 2006.

[114] R.-J. ten Hove, L. van Lieshout, E. A. T. Brienen, M. A. Perez, and J. J. Verweij, "Real-time polymerase chain reaction for detection of *Isospora belli* in stool samples," *Diagnostic Microbiology and Infectious Disease*, vol. 61, no. 3, pp. 280–283, 2008.

Hindawi Publishing Corporation
Interdisciplinary Perspectives on Infectious Diseases
Volume 2009, Article ID 926521, 13 pages
doi:10.1155/2009/926521

Review Article

Molecular Diagnostic Tests for Microsporidia

Kaya Ghosh[1,2] and Louis M. Weiss[1,3]

[1] *Department of Pathology, Albert Einstein College of Medicine, Bronx, NY 10461, USA*
[2] *Department of Biological Sciences, Rutgers University, Newark, NY 07102, USA*
[3] *Department of Medicine, Albert Einstein College of Medicine, Bronx, NY 10461, USA*

Correspondence should be addressed to Louis M. Weiss, lmweiss@aecom.yu.edu

Received 31 March 2009; Accepted 12 May 2009

Recommended by Herbert B. Tanowitz

The Microsporidia are a ubiquitous group of eukaryotic obligate intracellular parasites which were recognized over 100 years ago with the description of *Nosema bombycis*, a parasite of silkworms. It is now appreciated that these organisms are related to the Fungi. Microsporidia infect all major animal groups most often as gastrointestinal pathogens; however they have been reported from every tissue and organ, and their spores are common in environmental sources such as ditch water. Several different genera of these organisms infect humans, but the majority of infections are due to either *Enterocytozoon bieneusi* or *Encephalitozoon* species. These pathogens can be difficult to diagnose, but significant progress has been made in the last decade in the development of molecular diagnostic reagents for these organisms. This report reviews the molecular diagnostic tests that have been described for the identification of the microsporidia that infect humans.

1. Introduction

The Microsporidia are a phylum of over 1200 species representing at least 150 genera [1, 2]. Since the mid-1980s, these organisms have increasingly been implicated as agents of human disease, especially in their capacity as opportunistic pathogens in patients with HIV infection [2, 3] and other immunosuppressed individuals, such as those with organ transplantation or chemotherapy recipients [4]. To date, fourteen species in eight genera have been found to infect humans [5]. In HIV-positive patients, the most common clinical manifestation is chronic diarrhea and wasting due to enteric infection, but the spectrum of disease due to these pathogens is broad and includes hepatitis, peritonitis, keratoconjunctivits, sinusitis, bronchitis, pneumonia, cystitis, nephritis, myositis, encephalitis, and other cerebral infections [4]. In addition, microsporidia have also been reported to be etiologic in isolated case reports of urethritis, prostatic abscess, tongue ulcer, bone infection, and cutaneous infection [4]. There is an increasing appreciation that these organisms can also cause gastrointestinal and ocular infections in apparently immunocompetent individuals. Serosurveys [6, 7] suggest that microsporidiosis is common, but usually self-limiting or asymptomatic in the general population. While transmission routes have not been specifically documented in epidemiologic studies, there is evidence that infections can occur by multiple routes (enumerated in [2]) including waterborne, respiratory, sexual, congenital, zoonotic transmission, and in ocular infection by traumatic inoculation into the cornea.

All microsporidia produce an environmentally resistant spore which is capable of extruding its coiled, internal polar filament (i.e., polar tube) thereby inoculating its contents into a nearby host cell. Unique in structure and function, identification of the polar filament is diagnostic for the phylum. Due to the small size of the organisms, for example, several of the human-infecting species measure 1–2 μm [4], diagnosis of microsporidiosis has traditionally relied on transmission electron microscopy (TEM) to identify the polar filament and other phylum- and species-specific ultrastructural characters. Although it remains the gold standard, TEM is labor-intensive and time-consuming, requiring expensive equipment, significant specialized expertise, and a dedicated histological staff working over the course of several days. It is also relatively insensitive, due to the small amount of tissue that can be examined and the lack of signal

amplification. Light microscopy-based methods have also been developed and are faster and typically more sensitive than TEM, but they still require experienced pathologists for successful interpretation. These methods include routine histological stains such as the modified trichrome stain which is used alone or in combination with other stains such as Gram or Warthin-Starry silver [1]. Although these methods are more convenient than TEM for detecting microsporidia in body fluids and tissues, the internal polar filament is not easily identified using these techniques. Rather, diagnosis hinges mostly on the detection of the thick spore wall which is birefringent and provides selective staining characteristics with the modified trichrome stain. Chemofluorescent brighteners (e.g., Calcofluor White, Uvitex 2B, Fungifluor) have been used to target the chitin within the spore wall. While sensitive, the potential for cross reactivity with Fungi and artifactual material exists, especially in stool specimens. Thus, it has been recommended that chemofluorescent brighteners should be used in combination with traditional histological stains, to provide better sensitivity and specificity when examining stool specimens. However, even the best possible tissue preparation and staining for light microscopy rarely enables a microsporidian species-specific diagnosis. This is a critical shortcoming in light of the need for different treatments for the various microsporidian species that infect humans [8].

While TEM evidence of the polar filament or other ultrastructural features unique to the phylum is considered incontrovertible proof of microsporidiosis, a more specific diagnosis is not always possible on the basis of morphology alone. Especially in the case of closely related species, distinguishing characteristics may arise in only certain developmental stages of the organism, all of which may not be present in a particular clinical sample. While in vitro culture is conceivable as a tool to aid in diagnosis for several human-infecting species, culture methods are laborious, subject to contamination, and usually impractical; moreover, for *Enterocytozoon bieneusi*, the most common microsporidium found in humans, no in vitro culture system exists [9]. Thus, there exists a need for faster, more specific, and more accessible approaches to diagnosis in both clinical specimens and environmental samples.

Over the past decade or so, molecular biology-based procedures have been increasingly used in clinical settings for the diagnosis and characterization of microbial pathogens. These procedures are designed to detect either a nucleic acid sequence or antigen specific to the pathogen. Compared to traditional microscopy- or culture-based methods, molecular methods can offer the following potential advantages: increased sensitivity, by virtue of amplification of signal; greater specificity, when appropriate detection probes are employed; faster time-to-result; and greater ease of interpretation by nonspecialists [10]. While clinical laboratories still primarily rely on microscopy-based methods for the diagnosis of microsporidia, over the past fifteen years significant effort has been directed to the development of molecular methods in research laboratories. This article will review the progress toward molecular diagnostics of these emerging pathogens.

2. Nucleic Acid-Based Detection Methods

Nucleic acid-based detection methods utilize synthetic DNA molecules that are specific and complementary to a sequence in the DNA of the pathogen. The earliest methods employed labeled probes which hybridized to pathogen DNA and emitted a detectable (e.g., fluorescent) signal. Such DNA probe technologies are still in use today, although they have been largely supplanted by methods that amplify the target sequence; of these methods the most commonly utilized is the polymerase chain reaction (PCR) (for a historical perspective, see [11]). In PCR, the target pathogen DNA is bound by a specifically designed set of primers and copied over and over again in the presence of free nucleotides by a themostable polymerase enzyme. The amplification of the target pathogen DNA (i.e., amplicon) confers two advantages: improved detection sensitivity relative to probe-based methods and facilitation of downstream analyses (e.g., restriction analysis, sequencing) of the amplicon.

Techniques for sample preparation for the molecular diagnosis of microsporidia have been reviewed in detail in Weiss and Vossbrinck [12]. The technique used to extract DNA for amplification can significantly affect the sensitivity of a PCR diagnostic technique. Nucleic acids may be extracted from clinical samples such as tissue biopsies, corneal scrapings, duodenal aspirations, and urine specimens as well as in vitro cultures with commercial DNA extraction kits (e.g., those manufactured by Qiagen, Santa Clara, Calif, Usa, or Promega, Madison, Wis, Usa) or by routine procedures such as proteinase K digestion followed by phenol-chloroform extraction and ethanol precipitation [13]. DNA may also be isolated from paraffin-embedded material by standard methods [14] or with commercial kits such as DexPAT (Takera Biochemical, Berkeley Calif, Usa). DNA has been successfully amplified from modified trichrome-stained [15] and decades-old Giemsa-stained [16] microscope slides by scraping the material off of the slides followed by mechanical disruption of the microsporidia (using glass beads) and subsequent DNA extraction using standard techniques.

The isolation and amplification of DNA from stool samples is more challenging, generally requiring mechanical disruption and/or harsh extraction conditions. Successful reported methods include subjection to 0.5% sodium hypochlorite [17], chitinase [17], lyticase [18], guanidine thiocyanate [19–21], 10% formalin or M potassium hydroxide [17, 22, 23], dithiothreitol [22], hexadecyltrimethylammoniuim bromide [24], or boiling the samples (Ombrouck et al. [25] . Stool samples frequently contain inhibitors of polymerase enzymes [26]. If they are not removed by the above methods, dilution of the samples (Ombrouck et al.,[27]) or guanidine thiocyanate treatment [19] may be warranted. An extraction-free template preparation method for stool samples has also been developed [28] using FTA filters impregnated with denaturants, chelating agents, and free-radical traps, which apparently causes most cells to lyse on contact and enables debris and other inhibitory factors to be washed away from the DNA trapped on the filter. In one study this FTA filter method allowed the detection of

800 microsporidian spores per milliliter of stool by a PCR technique (Subrungruang et al., [29]) .

In order to apply PCR-based diagnostics to a pathogen, some genetic sequence information must be known in advance. The human-infecting microsporidia are a diverse group of "emerging" pathogens, and the available genetic information on these organisms is limited but ever-increasing. For the majority of the microsporidia GenBank sequence data on their rRNA genes is the only genetic information available. The number of microsporidian genes deposited in GenBank has grown from less than 200 in 1999 (surveyed in [12]) to almost 6000 today. Approximately two-thousand of these are the genome sequence-related predicted genes proposed by Katinka et al. [30] in their landmark genomic sequencing of the human pathogen *Encephalitzoon cuniculi*, the first and to-date only microsporidium genome to be completely sequenced. For the closely related species *Encephalitozoon hellem*, there are 75 entries. Recently, a genomic survey of the essentially noncultivatable pathogen *Enterocytozoon bieneusi* resulted in the addition of another three-thousand hypothetical genes, some of which are homologs to the genes identified in *Enc. cuniculi* [31]. For the other eleven human-infecting species of microsporidia, between zero and a few dozen genes have been deposited in GenBank.

Due to the availability of sequence information as well as the presence of conserved and variable regions within the rRNA genes, PCR-based methods have typically utilized primers to this gene for the characterization of the microsporidia. The first such report of the use of conserved rRNA primers was of that of the cloning of the small subunit (SSU) rDNA of *Vairimorpha necatrix*, a pathogen of agricultural pests [32]. Primers complementary to conserved sequences within this gene were used to amplify and subsequently obtain sequence data on the rRNA gene of several human-infecting microsporidia, including *Enc. cuniculi*, *Enc. hellem*, *Enc. intestinalis*, *Ent. bieneusi*, and *Vittaforma corneae* (reviewed in [33, 34]). These rRNA genes have been reported by Katinka et al. [30] to be present in more than twenty copies in the *Enc. cuniculi* genome, and therefore, provide an increase in sensitivity (over single copy genes) for use in diagnostic PCR tests.

Diagnostic studies using primers to the various rRNA genes of microsporidia have been reviewed by Weiss and Vossbrinck [12] and Franzen and Muller [35]. The sequences of many of the primer pairs used for the amplification of various microsporidia, along with the recommended annealing temperatures for PCR and the expected amplicon size, are compiled in Table 1 (adapted from [12]). Some of these primers are species-specific whereas others are more general primer sets that amplify all of the Encephalitozoonidae. For some of these primer sets downstream restriction analysis, wherein the amplicon is digested into smaller pieces by specific restriction enzymes, is required for species specific diagnoses.

PCR has also been useful for the identification of the previously unknown microsporidia in human and veterinary infections. Using phylogenetically conserved primers amplifying the small subunit (SSU), large subunit (LSU), and intergenic spacer (IGS) regions, it has been possible to clone and then sequence portions of the rRNA gene of uncharacterized microsporidia from biopsy specimens (Table 2, adapted from [12]). These rRNA sequence data can then be used for phylogenetic analysis using BLAST and similar in silico programs comparing the unknown sequence to the rRNA sequences on various microsporidia available in GenBank. The primers in Table 2 form the basis of a "molecular toolbox" which allows the cloning of rRNA genes from novel species or strains of microsporidia. The primer pairs V1(18f)::1492r and 530f::580r are considered "universal" in that they are usually successful in amplifying unknown rRNA genes for novel species or strains of microsporidia ([36], also see [12]).

Several investigators have published diagnostic procedures for microsporidia which use real-time PCR [33, 34, 53, 54, 56]. Real-time PCR, which detects accumulating amplicons in real time via interacting either fluorescent dyes or fluorescence-labelled probes, has the advantage of being quantitative over a broad dynamic range. In addition, it typically employs a multiwell format and dispenses with postamplification processing of the sample, which increases throughput and reduces the risk of contamination inherent in PCR [57]. Hester et al. [53] used a probe specific for the small subunit rRNA of the genus *Encephalitozoon* and species-specific primers for *Enc. cuniculi, Enc. hellem,* and *Enc. intestinalis.* While their method was validated only for purified microsporidian DNA, it could be adapted for clinical samples. Another study utilized pan-*Encephalitozoon* primers specific to small subunit rRNA and a guanidine thiocyanate-based extraction system designed for an automated workstation to detect *Enc. cuniculi*, *Enc. hellem*, and *Enc. intestinalis* from stool specimens [56]. The assay was sensitive (detection limit between 10^2 to 10^3 spores/mL) and reflective of infection intensity (linear range was between 10^3 and 10^7 spores/mL). In addition, melting curve analyses of the amplicons readily allowed differentiation of the three *Enc.* species., which is useful for multiple or unknown infections. In 2003, a real-time PCR assay using primers for *Enc. intestinalis* small subunit rRNA was used to detect this pathogen from known clinical samples, including stools, urine, tissue biopsies, bronchopulmonary specimens, and blood [33, 34]. Using control reference spores, the detection limit was estimated to be 20 spores per milliliter, which was sufficient to detect a relatively low-intensity blood infection suggesting that an infection was disseminated [33, 34]. Finally, a multiplex real-time PCR assay has also been reported to simultaneously detect *Ent. bieneusi*, *Enc. cuniculi*, *Enc. hellem*, and *Enc. intestinalis* from both fresh and formalin-fixed stool with primers for the intergenic region and small subunit rRNA of *Ent. bieneusi* and *Encephalitozoon* species., respectively [54]. *Ent. bieneusi* was detected in 30 of 33 known microsporidia-positive samples. The study included a range of negative and positive controls to verify the assay specificity and guard against false negatives due to inhibitors potentially present in stool or to the presence of extraneous DNA, respectively.

A few studies have also utilized fluorescent *in situ* hybridization (FISH-) based methods to detect microsporidia.

Table 1: Diagnostic Primers for the Microsporidia.

Species amplified	Sequence (5′ to 3′)	Primer /*probe**name	Annealing temp. in PCR/*melting temp.#* (°C)	Amplicon size, base pairs	Reference(s); notes
		Primers used in PCR			
Anncaliia (Brachiola) algerae	ACTCCGGTAACGTGTGATGTG TACAAAGCATGATCCCAGTCT	NALGf2 NALGR1	55	180	[37]
Anncaliia (Brachiola) algerae	GCCGTTTCCGAAGTTGG ATATCGACGGGACTCTCACC	NAGf NAG178r	50	192	[38]
Encephalitozoonidae and *Ent. bieneusi*	CACCAGGTTGATTCTGCCTGAC CCTCTCCGGAACCAAACCTG	PMP1 (V1) PMP2	60	Eb 250 Ec 268 Ei 270 Eh 279**	[17]
Encephalitozoonidae and *Ent. bieneusi*	TGAATG(G/T)GTCCCTGT TCACTCGCCGCTACT GTTCATCGCACTACT GGAATTCACACCGCCCGTC(A/G)(C/T)TAT CCAAGCTTATGCTTAAGT(C/T)(A/C)AA(A/G)GGGT CCAAGCTTATGCTTAAGTCCAGGGAG	MSP1 MSP2A MSP2B MSP3 MSP4A MSP4B	58	Eb 508 Ec 289 Ei 305	[22]
Encephalitozoonidae and *Ent. bieneusi*	CCAGGUTGATUCTGCCUGACG TUACCGCGGCUGCUGGCAC AAGGAGCCTGAGAGATGGCT CAATTGCTTCACCCTAAGGTC GACCCCTTTGCACTCGCACAC TGCCCTCCAGTAAATCACAAC CCTCCAATCAATCTCGACTC	Mic3U Mic421U Mic266 Eb379 Ec378 Eh410 Ei395	65/62	Eb 132 Ec 113 Eh 134 Ei 128	[20]
Encephalitozoonidae and *Ent. bieneusi*	CACCAGGTTGATTCTGCC GTGACGGGCGGTGTCTAC	C1 (V1) C2	56	Eb 1170 Ec 1190 Eh 1205 Ei 1186***	[18]
Encephalitozoonidae	TGCAGTTAAAATGTCCGTAGT TTTCACTCGCCGCTACTCAG	int530f int580r	40	1000	Didier et al., [39]

Table 1: Continued.

Species amplified	Sequence (5′ to 3′)	Primer /*probe**name	Annealing temp. in PCR/*melting temp.*# (°C)	Amplicon size, base pairs	Reference(s); notes
Enc. intestinalis	CACCAGGTTGATTCTGCCTGAC CTCGCTCCTTTACACTCGAA	V1 Si500	58	375	[40]
Enc. intestinalis	GGGGGTAGGAGTGTTTTTG CAGCAGGCTCCCTCGCCATC	3 3	65	930	Schuitema et al., 1993 , [41]
Enc. intestinalis	TTTCGAGTGTAAGGAGTCGA CCGTCCTCGTTCTCCTGCCCG	SINTF1 SINTR	55	520	[42, 43]
Enc. cuniculi	ATGAGAAGTGATGTGTGTGCG TGCCATGCACTCACAGGCATC	ECUNF ECUNR	55	549	[43, 44]
Enc. hellem	TGAGAAGTAAGATGTTTAGCA GTAAAAAGACTCTCACACTCA	EHELF EHELR	55	547	[44]
Ent. bieneusi	GAAACTTGTCCACTCCTTACG CCATGCACCACTCCTGCCATT	EBIEF1 EBIER1	55	607	[42]
Ent. bieneusi	CACCAGGTTGATTCTGCCTGAC ACTCAGGTGTTATACTCACGTC	V1 EB450	48	353	[45, 46]
Ent. bieneusi	CACCAGGTTGATTCTGCCTGAC CAGCATCCACCATAGACAC	V1 Mic3	54	446	[24, 47]
Ent. bieneusi	TCAGTTTTGGGTGTGGTATCGG GCTACCCATACACACATCATTC	Eb.gc Eb.gt	49	210	[48]
[-8pt] *Ent. bieneusi*	GCCTGACGTAGATGCTAGTC ATGGTTCTCCAACTGAAACC	2 2	55	1265	[49]
Vittaforma corneae	TGAGACGTGAAGATGAGTATC TCCCTGCCCACTGTCTCCAAT	NCORF1 NCORR1	55	375	Pieniazek NJ and Visvesvara GS personal communication
Primers and probes used in hybridization					
Encephalitozoon spp.	CAGGTTGATTCTGCCTGACG ATCTCTCAGGCTCCCTCTCC	FP RP	63		Notermans et al., [50]
Enc. hellem	ACT CTCACA CTC ACT TCA G	*HEL878F*	54		[51]

Table 1: Continued.

Species amplified	Sequence (5′ to 3′)	Primer /*probe**name	Annealing temp. in PCR/*melting temp.*# (°C)	Amplicon size, base pairs	Reference(s); notes
Ent. bieneusi	CGGTGGTGTGTGTAGGCGTGAGAGTGTATC	*probe*	55 (hybridization)		[52]
		Primers and probes used in RT-PCR or fluorogenic PCR			
EncephP1	CCC TGT CCT TTG TAC ACA CCG CCC	*EncephP1*	68		[53]
EcunF1	TCC TAG TAA TAG CGG CTG ACG AA	EcunF1	59		
EcunR2	ACT CAG GAC TCA GAC CTT CCG A	EcunR2	59		
EhelF1	GAA TGA TTG AAC AAG TTA TTT TGA ATG TG	EhelF1	59		
EhelR2	AAC ACG AAA GAC TCA GAC CTC TCA	EhelR2	58		
EintF1	AAT TCC TAG TAA TAA CGA TTG AAC AAG TTG	EintF1	59		
EintR2	ACG AAG GAC TCA GAC CTT CCA A	EintR2	59		
Ent. bieneusi	CGCTGTAGTTCCTGCAGTAAACTATGCC	FEB1	65	102	[33, 34]
	CTTGCGAGCGTACTATCCCCAGAG	REB1			
	ACGTGGGCGGGAGAAATCTTTAGTGTTCGGG	*probe*			
Enc. intestinalis	GCAAGGGAGGAATGGAACAGAACAG	FEI1	65	127	[33]
	TTCAGAAGCCCATTACACAGC	REI1			
	CGGGCGGCACGCGCACTACGATA	*probe*			
Ent. bieneusi	TGTGTAGGCGTGAGAGTGTATCTG	EbITS-89F	60	103	[54]
	CATCCAACCATCACGTACCAATC	EbITS-191R			
	CACTGCACCCACATCCCTCACCCTT	*EbITS-114revT*			
Encephalitozoon spp.	CACCAGGTTGATTCTGCCTGAC	MSP1F	60		
	CTAGTTAGGCCATTACCCTAACTACCA	Eint227R			
	CTATCACTGAGCCGTCC	*Eint82Trev*			
Encephalitozoon	GTCCGT TAT GCC CTG AGA T		60	268	
	ACA GCA GCC ATG TTA CGACT				
	GCC CGT CGC TATCTA AGA TGA CGC A	*probe 1*			
	TGG ACG AAG ATT GGA AGGTCT GAG TC	*probe 2*			

Table 1: Continued.

Species amplified	Sequence (5′ to 3′)	Primer /*probe**name	Annealing temp. in PCR/*melting temp.*# (°C)	Amplicon size, base pairs	Reference(s); notes
Primers and probes used in oligonucleotide microarray					
microsporidia-generic	GATTCTGCCTGACGTGGATGCTATT	*Msp1*	58		[55]
	ATTCCGGAGAGGGAGCCTGAGAGAT	*Msp2*	61		
	ATTGACGGAAGGACACTACCAGGA	*Msp3*	57		
	GTGCGGCTTAATTTGACTCAACGCG	*Msp4*	58		
Ent. bieneusi	ACGGCTCAGTAATGTTGCGGTAATT	*Eb1*	56		
	CCTATCAGCTTGTTGGTAGTGTAAA	*Eb2*	54		
	TCATGAGACGTGAGTATAAGACCTG	*Eb3*	56		
	ATCGAATACGTGAGAATGGCAGGAGT	*Eb4*	58		
	CTAAAAGCGGAGAATAAGGCGCAAC	*Eb5*	58		
	CGTTGTTCAATAGCGATGAGTTTGC	*Eb6*	56		
	GGTGAAACTTAAAGCGAAATTGACGG	*Eb7*	56		
	AGCCTGTGTGTGAGAATACGTGG	*Eb8*	56		
Encephalitozoon	ACGGCTCAGTGATAGTACGATGATT	*Ence1*	56		
	TATCAGCTGGTAGTTAGGGTAATGG	*Ence2*	56		
	GAGTGAAACTTGAAGAGATTGACGG	*Ence3*	56		
Enc. cuniculi	TGTGGGGTTGGCAAGTAAGTTGTGG	*Ec1*	59		
	ATGAGAAGTGATGTGTGTGCGAGTG	*Ec2*	58		
	GCCTGTGAGTGCATGGCATGAG	*Ec3*	59		
	GGGAAACTGCAGATAGTGGTCTGC	*Ec4*	59		
	GGATGTAGTGATGTGTGTGGCAGAG	*Ec5*	59		
	CTGGACGGGACAGTGTGTGTTGT	*Ec6*	59		
Enc. hellem	TAAGTTCTGGGGGTGGTAGTTTGTA	*Eh1*	56		
	GCGGTTATGAGAAGTAAGATGTTTAGCA	*Eh2*	57		
	CTGAAGTGAGTGTGAGAGTGTTTTTAC	*Eh3*	57		
	ATTGGGAGCCTGGATGTAACTGTGG	*Eh4*	59		
	GGATGTAGTTTTATTGTAGCAGAGG	*Eh5*	54		
	TGGACGGGACTGTTTTAGTGTTGTC	*Eh6*	58		
Enc. intestinalis	TTGACACGAGCCAAGTAAGTTGTAG	*Ei1*	56		
	TTTCGAGTGTAAAGGAGTCGAGATTGA	*Ei2*	57		
	GGCAGGAGAACGAGGACGGGAT	*Ei3*	60		
	CAGGTAGGGGGCTAGGAGTGTTTTT	*Ei4*	59		
	TATGTCCTGATGTGGATGTAAGAGG	*Ei5*	56		
	TGGACGGGACTATATAGTGTTGTG	*Ei6*	56		
microsporidia-generic	TTTMMAACGGCCATGCACCAC	MspR3	52	var.	Used to label initial PCR products

* Italics indicate hybridization probe.
** PstI and HaeIII restriction analysis differentiates these amplicons.
*** HindIII and HinfI restriction analysis differentiates these amplicons.
# Italics indicate melting temperature.

Table 2: Primers for the identification and sequencing of microsporidian rRNA[1] Genes.

ss[2]18f[3]	CACCAGGTTGATTCTGCC
ss18sf	GTTGATTCTGCCTGACGT
ss350f	CCAAGGA(T/C)GGCAGCAGGCGCGAAA
ss350r	TTTCGCGCCTGCTGCC(G/A)TCCTTG
ss530f	GTGCCAGC(C/A)GCCGCGG
ss530r	CCGCGG(T/G)GCTGGCAC
ss1047r	AACGGCCATGCACCAC
ss1061f	GGTGGTGCATGGCCG
ss1492r	GGTTACCTTGTTACGACTT (Universal primer)
ss1537	TTATGATCCTGCTAATGGTTC
ls212r1	GTT(G/A)GTTTCTTTTCCTC
ls212r2	AATCC(G/A/T/C)(G/A)GTT(G/A)GTTTCTTTTCCTC
ls580r	GGTCCGTGTTTCAAGACGG

1- Primers 18f and 1492r amplify most of the small subunit rRNA of the microsporidia. Primes 530f and 212r1 or 212r2 are used to amplify the small subunit rRNA and the ITS region. The remaining primers are used to sequence, with overlap, the forward and reverse strands of the entire small subunit rRNA and ITS region. ls580r amplifies a variable region of the 5′ end of the large subunit rRNA gene of many microsporidia (e.g., Nosema and Vairimorpha) but it does not work on all microsporidia. ss1537 allows sequencing closer to the 3′ end of the small subunit rRNA of many but not all microsporidia. ss350f and ss350r may not be needed for sequencing reactions if 18f and 530r provide sufficient overlap to obtain clear sequence data.

2- ss: denotes primers in the small subunit rRNA gene,
ls: denotes primers in the large subunit rRNA gene,
f: forward primer (positive strand),
r: reverse primer (negative strand).

3- Similar to V1 primer.

Adapted from [12].

Essentially, FISH technology utilizes a fluorescence-labeled probe that binds to complementary nucleic acid (DNA or RNA) in the specimen [10]. In contrast to PCR, general morphological and spatial information regarding probe-binding in the specimen may be retained because the procedure is performed *in situ*. FISH has been used with probes against the small subunit or intergenic regions of microsporidia rRNA to detect *Ent. bieneusi* and *Enc. hellem* [24, 51, 52]. These methods were used successfully with archived formalin-fixed, paraffin-embedded (FFPE) clinical samples and detected either more microsporidia-positive samples or more infected cells within samples than traditional histochemical staining. In the case of *Ent. bieneusi*, characteristic staining of parasites in a supranuclear location within jejunal biopsy epithelial cells [24] and staining of developmental forms [52] contributed to the certainty of diagnosis. Although FISH is an attractive procedure due to the multifaceted information, it can provide two factors seriously hamper its potential for general use in clinical diagnostic settings. Firstly, it is rather laborious and technically challenging, requiring deparaffinization, dehydration, and rehydration (of FFPE samples), digestion by proteinases to make the nucleic acid accessible to the probe, labeling and overnight hybridization of the probe, blocking, counterstaining, and many wash steps prior to viewing with an epifluorescence-equipped microscope. Secondly, it is less sensitive than PCR by orders of magnitude due to the lack of amplification of original signal (i.e., the nucleic acid target). Nonetheless, it may prove particularly useful for environmental samples wherein discrimination of live versus dead organisms is important, which can be afforded by designing probes for the less-stable RNA rather than DNA (discussed in [51]).

Of interest is the report of the development of an oligonucleotide microarray to simultaneously detect *Ent. bieneusi*, *Enc. cuniculi*, *Enc. hellem*, and *Enc. intestinalis* from clinical samples [55]. Such microarrays were originally developed for genomewide expression analysis but have recently been applied to molecular diagnostics [10, 58]. Microarray technology commonly employs an array of target-complementary oligonucleotides printed on a "chip" to which fluorescence-labelled nucleic acid from the sample is hybridized; the degree of fluorescence correlates to the abundance of the sample DNA. Because of the array format and the analog nature of fluorescence intensity, this technology is intrinsically high-throughput and somewhat quantitative, respectively. Wang et al. [55] capitalized on these advantages and combined them with the sensitivity of PCR by first using conserved, family-specific primers to amplify 1.3-kb microsporidia rRNA fragments from unextracted, FTA-filtered clinical fecal samples before hybridization to a microsporidia microarray. Multiple specific probes were then used to confer genus- and species-level hybridization profiles to the assay and to increase sensitivity by decreasing amplicon size (i.e., in a "nested" fashion). The array was able to simultaneously detect all four species of microsporidia at a sensitivity of 10^2 spores per 100 μL of fecal sample. In a survey of 20 fecal samples from AIDS patients suffering from diarrhea of unknown etiology, 12 samples were microsporidia-positive, and all but one were apparently multiply-infected. No masking effect by the more abundant species was evident, and the probe hybridization profile for each species offers a tentative assessment of infection intensity. The printing of four individual microarrays per slide increases the potential throughput of this technique.

3. Antigen-Based Detection Methods

Antigen-based detection methods such as the immunofluorescence assays (IFAs), ELISA, and immunoblot use antibodies from experimentally immunized animals to recognize characteristic pathogen specific antigens. IFA can be used *in situ* on fixed specimens but needs to be examined using fluorescence microscopy. Immunoblot or ELISA tests examine an homogenate of the specimen. Antibodies may be either polyclonal (i.e., purified from animal sera and directed against various epitopes of the protein, and possibly containing other, nonspecific antibodies which can increase background signal) or monoclonal (purified from cell culture supernatants).

A number of monoclonal and polyclonal antibodies against human-infecting microsporidia including *Ent. bieneusi*, *Enc. cuniculi*, *Enc. hellem*, and *Enc. intestinalis* have been developed [59–65]. Most often these antibodies have been directed against the spore wall or polar tube of the

Microsporidia. Some of these antibodies have demonstrated cross-reactivity among various species of microsporidia by IFA or immunoblot. While some investigators have reported IFA tests that had an equal sensitivity to a reference PCR (e.g., [64]), the majority of investigators believe that IFA tests are less sensitive than PCR based methods. In any case, the specificity and sensitivity depend to a great extent on the antibody itself and the care with which the various steps (e.g. fixation, blocking, and washes) are executed. Antibody-based detection is best used as a supplement to conventional histological techniques, and in difficult cases nucleotide-based detection should be utilized as well.

4. Antibody-Based Detection Methods

Serologic tests such as the enzyme-linked immunosorbent assay (ELISA), immunoblot, and agglutination-based tests [66, 67] which can detect circulating antibody are not currently recommended for diagnostic purposes due to variable expression of antibodies in immunocompromised patients, the inability to discriminate between acute and past infections [68], the high prevalence of anti-microsporidian antibodies in apparently healthy, immunocompetent populations [6, 7], and cross-reactivity of antibodies between different species. However, these serologic analyses may be useful to diagnose subclinical infections in prospective transplant donors or patients who may be at risk for reactivation of infection due to impending immune compromise (discussed in [8]).

5. Detection of Microsporidia from Environmental Samples

Because many species of microsporidia are enteric pathogens in humans and animals and are transmitted as environmentally resistant spores [69], it is likely that waterborne transmission of these parasites occurs. Human-pathogenic microsporidia have been detected in surface water, groundwater, and tertiary agricultural effluent [23, 70–75], which poses a contamination risk to drinking, recreational, and agricultural water supplies. Indeed, in 1999 there was a confirmed waterborne outbreak of microsporidiosis that affected both immune-compromised and immune-competent individuals [76]. As a result of such studies, the U.S. Environmental Protection Agency included the microsporidia on its two most recent Candidate Contaminant Lists (CCL-1 and -2) in 1998 and 2005, respectively. The CCL-2 currently consists of eight other candidate microbiological agents and 42 chemical agents which are known or anticipated to be present in public water systems and which may require regulation under the Safe Drinking Water Act.

Waterborne protozoa are usually detected from large-volume water samples by filter-based or centrifugal concentration followed by purification and molecular or microscopic identification of the organism from the concentrated material [77]. Currently, methods for the enrichment of microsporidia in water samples have not been standardized, but relatively expedient concentration of spores has been achieved by continuous flow centrifugation (CFC) [78] or continuous separation channel centrifugation [79]. In the case of water samples, purification of spores by immunomagnetic separation (IMS), which utilizes pathogen-specific antibody-coated beads prior to detection by real-time PCR, was shown to be 78%–90% sensitive for seeded spores in ultrapure water [78], although the paucity of commercially available anti-microsporidia antibodies currently limits the accessibility of this approach. In all cases requiring detection of microsporidia from turbid samples such as feces-impacted or otherwise turbid environmental water, the small size of human-pathogenic microsporidia impedes detection sensitivity, as it necessitates a reduction in filter pore size which increases membrane-fouling, thus effectively decreasing the volume of water that can be filtered [78]. In the case of feces or heavily feces-impacted wastewater, a similar problem arises in that although smaller, filtered, or unfiltered volumes may be analyzed for the sake of convenience, and to minimize the effect of PCR inhibitors usually present therein [26], such small volumes may not be representative of the entire sample or may be inadequate for detection of low-intensity contaminations (discussed in [80]). Nonetheless, detection limits of 10^2 to 10^3 spores per milliliter of feces or wastewater were achieved by sucrose-flotation purification followed by DNA extraction using commercial kits and PCR [80], a significant improvement over previously reported methods even for less turbid samples [71, 81].

While waterborne microsporidia likely pose the greater environmental threat, nonaquatic dispersal of microsporidia is also a public health concern. Spores have been identified on fresh produce in Poland such as berries and other fruits, sprouts, and green-leaf vegetables [82], perhaps as a consequence of microsporidial contamination of agricultural irrigation waters [74] or sewage-sludge end products used as fertilizer [83, 84]. Three species of Encephalitozoonidae were detected by FISH at levels likely to be infective for humans. In urban settings in Europe and North America, human-infecting microsporidia have been identified from pigeon fecal droppings [83–86]. The genotype of one isolate was found to match that of a previously reported human-infecting isolate [86], and in one study, 11% of pigeon fecal samples were found to be *Ent. bieneusi*-positive [85]. Graczyk et al. [83, 84] estimated that a person could inhale 10^3 viable, aerosolized spores in 30 minutes of occupational or incidental exposure to heavily pigeon excrement-contaminated surfaces. In addition, Mathis et al. [87] demonstrated *Ent. bieneusi* in feces of farm dogs and cats; diagnostic PCR suggested that the strains are closely related to human isolates. These findings support the notion that human microsporidiosis is a zoonotic disease [69, 88, 89] and highlight the utility of molecular methods to identify new sources of risk to human health.

6. Conclusion

The potential of molecular diagnostics and particularly nucleic acid-based diagnostics to exceed traditional methods

in terms of sensitivity, specificity, speed, and reproducibility has already achieved proof-of-concept for other pathogens [10, 11]. Indeed, this has been demonstrated for the microsporidia in molecular detection studies that processed corresponding specimens for light microscopy (e.g., [24, 51]). Although a blinded, multicenter evaluation of detection methods for the microsporidia conducted in 1998 (Rinder et al. [90]) revealed only a modest sensitivity advantage of PCR (89%) over light microscopy (80%), the greatest differences were seen between individual laboratories. Thus it is likely that as the molecular diagnostic methods are perfected over time and clinical diagnostic technicians become accustomed to them, their advantages will become more apparent. While the costs of such technology and requisite training of staff may seem initially prohibitive, the embedded costs of delayed and nonspecific or incorrect diagnosis to both patients and health care systems should be considered (see [11]).

In summary, molecular detection methods for the microsporidia described herein are potentially more sensitive, specific, and depend less on the subjectivity of the observer than traditional microscopy-based methods. Additionally, sophisticated nucleotide-based methods such as real-time PCR and oligonucleotide microarrays are intrinsically higher-throughput and quantitative, enabling simultaneous analysis of specimens for multiple pathogens as well as a tentative assessment of infection intensity. Although the time-to-result and reproducibility in clinical diagnostic settings have yet to be evaluated, a modest learning curve should be expected considering the "emerging" nature of these pathogens (see [91]). Looking ahead as more physiological insight into these pathogens is afforded by recent genomic sequencing projects [30, 31], these technologies may even be adapted as necessary to applications such as strain-genotyping and drug sensitivity-profiling.

References

[1] L. S. Garcia, "Laboratory identification of the microsporidia," *Journal of Clinical Microbiology*, vol. 40, no. 6, pp. 1892–1901, 2002.

[2] L. M. Weiss, "Microsporidia: emerging pathogenic protists," *Acta Tropica*, vol. 78, no. 2, pp. 89–102, 2001.

[3] A. Cali, "General microsporidian features and recent findings on AIDS isolates," *Journal of Protozoology*, vol. 38, no. 6, pp. 625–630, 1991.

[4] C. Franzen and A. Müller, "Microsporidiosis: human diseases and diagnosis," *Microbes and Infection*, vol. 3, no. 5, pp. 389–400, 2001.

[5] E. S. Didier, "Microsporidiosis: an emerging and opportunistic infection in humans and animals," *Acta Tropica*, vol. 94, no. 1, pp. 61–76, 2005.

[6] N. R. Bergquist, G. Stintzing, L. Smedman, T. Waller, and T. Andersson, "Diagnosis of encephalitozoonosis in man by serological tests," *British Medical Journal*, vol. 288, no. 6421, p. 902, 1984.

[7] T. van Gool, J. C. M. Vetter, B. Weinmayr, A. Van Dam, F. Derouin, and J. Dankert, "High seroprevalence of Encephalitozoon species in immunocompetent subjects," *Journal of Infectious Diseases*, vol. 175, no. 4, pp. 1020–1024, 1997.

[8] E. S. Didier and L. M. Weiss, "Microsporidiosis: current status," *Current Opinion in Infectious Diseases*, vol. 19, no. 5, pp. 485–492, 2006.

[9] G. S. Visvesvara, "In vitro cultivation of microsporidia of clinical importance," *Clinical Microbiology Reviews*, vol. 15, no. 3, pp. 401–413, 2002.

[10] G. W. Procop, "Molecular diagnostics for the detection and characterization of microbial pathogens," *Clinical Infectious Diseases*, vol. 45, supplement 2, pp. S99–S111, 2007.

[11] S. Yang and R. E. Rothman, "PCR-based diagnostics for infectious diseases: uses, limitations, and future applications in acute-care settings," *Lancet Infectious Diseases*, vol. 4, no. 6, pp. 337–348, 2004.

[12] L. M. Weiss and C. R. Vossbrinck, "Molecular biology, molecular phylogeny, and molecular diagnostic approaches to the microsporidia," in *The Microsporidia and Microsporidiosis*, M. Wittner and L. M. Weiss, Eds., pp. 129–171, American Society for Microbiology, Washington, DC, USA, 1999.

[13] F. M. Ausubel, R. Brent, R. E. Kingston, et al., *Current Protocols in Molecular Biology*, John Wiley & Sons, New York, NY, USA, 1997.

[14] M. A. Innis, D. H. Gelfand, J. J. Sninsky, and T. J. White, *PCR Protocols: A Guide to Methods and Applications*, Academic Press, San Diego, Calif, USA, 1990.

[15] K. S. Chan and T. H. Koh, "Extraction of microsporidial DNA from modified trichrome-stained clinical slides and subsequent species identification using PCR sequencing," *Parasitology*, vol. 135, no. 6, pp. 701–703, 2008.

[16] M. Hylis, J. Weiser, M. Obornik, and J. Vavra, "DNA isolation from museum and type collection slides of microsporidia," *Journal of Invertebrate Pathology*, vol. 88, no. 3, pp. 257–260, 2005.

[17] D. P. Fedorko and Y. M. Hijazi, "Application of molecular techniques to the diagnosis of microsporidial infection," *Emerging Infectious Diseases*, vol. 2, no. 3, pp. 183–191, 1996.

[18] L. Raynaud, F. Delbac, V. Broussolle, et al., "Identification of Encephalitozoon intestinalis in travelers with chronic diarrhea by specific PCR amplification," *Journal of Clinical Microbiology*, vol. 36, no. 1, pp. 37–40, 1998.

[19] R. Boom, C. J. A. Sol, M. M. M. Salimans, C. L. Jansen, P. M. E. Wertheim-van Dillen, and J. van der Noordaa, "Rapid and simple method for purification of nucleic acids," *Journal of Clinical Microbiology*, vol. 28, no. 3, pp. 495–503, 1990.

[20] N. P. Kock, H. Petersen, T. Fenner, et al., "Species-specific identification of microsporidia in stool and intestinal biopsy specimens by the polymerase chain reaction," *European Journal of Clinical Microbiology and Infectious Diseases*, vol. 16, no. 5, pp. 369–376, 1997.

[21] A. H. Talal, D. P. Kotler, J. M. Orenstein, and L. M. Weiss, "Detection of *Enterocytozoon bieneusi* in fecal specimens by polymerase chain reaction analysis with primers to the small-subunit rRNA," *Clinical Infectious Diseases*, vol. 26, no. 3, pp. 673–675, 1998.

[22] S. Katzwinkel-Wladarsch, M. Lieb, W. Heise, T. Loscher, and H. Rinder, "Direct amplification and species determination of microsporidian DNA from stool specimens," *Tropical Medicine and International Health*, vol. 1, no. 3, pp. 373–378, 1996.

[23] J. M. Sparfel, C. Sarfati, O. Liguory, et al., "Detection of microsporidia and identification of *Enterocytozoon bieneusi* in surface water by filtration followed by specific PCR," *Journal of Eukaryotic Microbiology*, vol. 44, no. 6, p. 78S, 1997.

[24] A. Carville, K. Mansfield, G. Widmer, et al., "Development and application of genetic probes for detection of *Enterocytozoon*

bieneusi in formalin-fixed stools and in intestinal biopsy specimens from infected patients," *Clinical and Diagnostic Laboratory Immunology*, vol. 4, no. 4, pp. 405–408, 1997.

[25] C . Ombrouck, L. Ciceron, and I. Desportes-Livag, "Specific and rapid detection of Microsporidia in stool specimens from AIDS patients by PCR," *Parasite*, vol. 3, no. 1, pp. 85–6, 1996.

[26] L. Monteiro, D. Bonnemaison, A. Vekris, et al., "Complex polysaccharides as PCR inhibitors in feces: helicobacter pylori model," *Journal of Clinical Microbiology*, vol. 35, no. 4, pp. 995–998, 1997.

[27] C . Ombrouck, L. Ciceron, S. Biligui, et al., "Specific PCR assay for direct detection of intestinal microsporidia Enterocytozoon bieneusi and Encephalitozoon intestinalis in fecal specimens from human immunodeficiency virus-infected patient," *J Clin Microbiol.*, vol. 35, no. 3, pp. 652–5, 1997.

[28] P. A. Orlandi and K. A. Lampel, "Extraction-free, filter-based template preparation for rapid and sensitive PCR detection of pathogenic parasitic protozoa," *Journal of Clinical Microbiology*, vol. 38, no. 6, pp. 2271–2277, 2000.

[29] I. Subrungruan, M. Mungthi, P. Chavalitshewinkoon-Petmit, R. Rangsi, T. Naaglor, and S. Leelayoova, "Evaluation of DNA extraction and PCR methods for detection of Enterocytozoon bienuesi in stool specimens," *J Clin Microbiol.*, vol. 42, no. 8, pp. 3490–4, 2004.

[30] M. D. Katinka, S. Duprat, E. Cornillott, et al., "Genome sequence and gene compaction of the eukaryote parasite Encephalitozoon cuniculi," *Nature*, vol. 414, no. 6862, pp. 450–453, 2001.

[31] D. E. Akiyoshi, H. G. Morrison, S. Lei, et al., "Genomic survey of the non-cultivatable opportunistic human pathogen, *Enterocytozoon bieneusi*," *PLoS Pathogens*, vol. 5, no. 1, article e1000261, 2009.

[32] C. R. Vossbrinck, J. V. Maddox, S. Friedman, B. A. Debrunner-Vossbrinck, and C. R. Woese, "Ribosomal RNA sequence suggests microsporidia are extremely ancient eukaryotes," *Nature*, vol. 326, no. 6111, pp. 411–414, 1987.

[33] J. Menotti, B. Cassinat, R. Porcher, C. Sarfati, F. Derouin, and J.-M. Molina, "Development of a real-time polymerase-chain-reaction assay for quantitative detection of *Enterocytozoon bieneusi* DNA in stool specimens from immunocompromised patients with intestinal microsporidiosis," *Journal of Infectious Diseases*, vol. 187, no. 9, pp. 1469–1474, 2003.

[34] J. Menotti, B. Cassinat, C. Sarfati, O. Liguory, F. Derouin, and J.-M. Molina, "Development of a real-time PCR assay for quantitative detection of Encephalitozoon intestinalis DNA," *Journal of Clinical Microbiology*, vol. 41, no. 4, pp. 1410–1413, 2003.

[35] C. Franzen and A. Müller, "Molecular techniques for detection, species differentiation, and phylogenetic analysis of microsporidia," *Clinical Microbiology Reviews*, vol. 12, no. 2, pp. 243–285, 1999.

[36] C. R. Vossbrinck and B. A. Debrunner-Vossbrinck, "Molecular phylogeny of the Microsporidia: ecological, ultrastructural and taxonomic considerations," *Folia Parasitologica*, vol. 52, no. 1-2, pp. 131–142, 2005.

[37] G. S. Visvesvara, M. Belloso, H. Moura, et al., "Isolation of Nosema algerae from the cornea of an immunocompetent patient," *Journal of Eukaryotic Microbiology*, vol. 46, no. 5, p. 10S, 1999.

[38] A. Cali, P. M. Takvorian, S. Lewin, et al., "Brachiola vesicularum, n. g., n. sp., a new microsporidium associated with AIDS and myositis," *Journal of Eukaryotic Microbiology*, vol. 45, no. 3, pp. 240–251, 1998.

[39] ES. Didier, LB. Roger, AD. Brush, S. Wong, V. Traina-Dorge, and D. Bertucc, "Diagnosis of disseminated microsporidian Encephalitozoon hetlem infection bv PCR-Southern analvsis and successful treatment with albendazole and fumaqillin," *J Clin Microbiol.*, vol. 34, no. 4, pp. 947–52, 1996.

[40] L. M. Weiss, X. Zhu, A. Cali, H. B. Tanowitz, and M. Wittner, "Utility of microsporidian rRNA in diagnosis and phylogeny: a review," *Folia Parasitologica*, vol. 41, no. 2, pp. 81–90, 1994.

[41] A. R. J. Schuitema, R. A. Hartskeerl, T. van Gool, R. Laxminarayan, and W. J. Terpstra, "Application of the polymerase chain reaction for the diagnosis of microsporidiosis," *AIDS*, vol. 7, supplement 3, pp. S57–S61, 1993.

[42] A. J. da Silva, S. B. Slemenda, G. S. Visvesvara, et al., "Detection of septata intestinalis (microsporidia) cali et al. 1993 using polymerase chain reaction primers targeting the small subunit ribosomal RNA coding region," *Molecular Diagnosis*, vol. 2, no. 1, pp. 47–52, 1997.

[43] M. A. De Groote, G. Visvesvara, M. L. Wilson, et al., "Polymerase chain reaction and culture confirmation of disseminated Encephalitozoon cuniculi in a patient with AIDS: successful therapy with albendazole," *Journal of Infectious Diseases*, vol. 171, no. 5, pp. 1375–1378, 1995.

[44] G. S. Visvesvara, G. J. Leitch, A. J. da Silva, et al., "Polyclonal and monoclonal antibody and PCR-amplified small-subunit rRNA identification of a microsporidian, Encephalitozoon hellem, isolated from an AIDS patient with disseminated infection," *Journal of Clinical Microbiology*, vol. 32, no. 11, pp. 2760–2768, 1994.

[45] X. Zhu, M. Wittner, H. B. Tanowitz, D. Kotler, A. Cali, and L. M. Weiss, "Small subunit rRNA sequence of *Enterocytozoon bieneusi* and its potential diagnostic role with use of the polymerase chain reaction," *Journal of Infectious Diseases*, vol. 168, no. 6, pp. 1570–1575, 1993.

[46] C. M. Coyle, M. Wittner, D. P. Kotler, et al., "Prevalence of microsporidiosis due to *Enterocytozoon bieneusi* and Encephalitozoon (Septata) intestinalis among patients with AIDS-related diarrhea: determination by polymerase chain reaction to the microsporidian small-subunit rRNA gene," *Clinical Infectious Diseases*, vol. 23, no. 5, pp. 1002–1006, 1996.

[47] K. G. Mansfield, A. Carville, D. Shvetz, J. MacKey, S. Tzipori, and A. A. Lackner, "Identification of an *Enterocytozoon bieneusi*-like microsporidian parasite in simian-immunodeficiency-virus-inoculated macaques with hepatobiliary disease," *American Journal of Pathology*, vol. 150, no. 4, pp. 1395–1405, 1997.

[48] J. N. Velasquez, S. Carnevale, E. A. Guarnera, et al., "Detection of the microsporidian parasite *Enterocytozoon bieneusi* in specimens from patients with AIDS by PCR," *Journal of Clinical Microbiology*, vol. 34, no. 12, pp. 3230–3232, 1996.

[49] F. David, A. R. J. Schuitema, C. Sarfati, et al., "Detection and species identification of intestinal microsporidia by polymerase chain reaction in duodenal biopsies from human immunodeficiency virus-infected patients," *Journal of Infectious Diseases*, vol. 174, no. 4, pp. 874–877, 1996.

[50] DW. Notermans, R. Peek, MD. de Jong, EM. Wentink-Bonnema, R. Boom, and T. van Gool, "Detection and identification of Enterocytozoon bieneusi and Encephalitozoon species in stool and urine specimens by PCR and differential hybridization.," *J Clin Microbiol*, vol. 43, no. 2, pp. 610–4, 2005.

[51] J. D. Hester, H. D. A. Lindquist, A. M. Bobst, and F. W. Schaefer III, "Fluorescent in situ detection of Encephalitozoon

hellem spores with a 6-carboxyfluorescein-labeled ribosomal RNA-targeted oligonucleotide probe," *Journal of Eukaryotic Microbiology*, vol. 47, no. 3, pp. 299–308, 2000.

[52] J. N. Velásquez, S. Carnevale, J. H. Labbé, A. Chertcoff, M. G. Cabrera, and W. Oelemann, "In situ hybridization: a molecular approach for the diagnosis of the microsporidian parasite Enterocytozoon bieneusi," *Human Pathology*, vol. 30, no. 1, pp. 54–58, 1999.

[53] J. D. Hester, M. Varma, A. M. Bobst, M. W. Ware, H. D. A. Lindquist, and F. W. Schaefer III, "Species-specific detection of three human-pathogenic microsporidial species from the genus Encephalitozoon via fluorogenic 5′ nuclease PCR assays," *Molecular and Cellular Probes*, vol. 16, no. 6, pp. 435–444, 2002.

[54] J. J. Verweij, R. ten Hove, E. A. T. Brienen, and L. van Lieshout, "Multiplex detection of *Enterocytozoon bieneusi* and Encephalitozoon spp. in fecal samples using real-time PCR," *Diagnostic Microbiology and Infectious Disease*, vol. 57, no. 2, pp. 163–167, 2007.

[55] Z. Wang, P. A. Orlandi, and D. A. Stenger, "Simultaneous detection of four human pathogenic microsporidian species from clinical samples by oligonucleotide microarray," *Journal of Clinical Microbiology*, vol. 43, no. 8, pp. 4121–4128, 2005.

[56] D. M. Wolk, S. K. Schneider, N. L. Wengenack, L. M. Sloan, and J. E. Rosenblatt, "Real-time PCR method for detection of Encephalitozoon intestinalis from stool specimens," *Journal of Clinical Microbiology*, vol. 40, no. 11, pp. 3922–3928, 2002.

[57] P. T. Monis and S. Giglio, "Nucleic acid amplification-based techniques for pathogen detection and identification," *Infection, Genetics and Evolution*, vol. 6, no. 1, pp. 2–12, 2006.

[58] A. Loy and L. Bodrossy, "Highly parallel microbial diagnostics using oligonucleotide microarrays," *Clinica Chimica Acta*, vol. 363, no. 1-2, pp. 106–119, 2006.

[59] H. D. Luján, J. T. Conrad, C. G. Clark, et al., "Detection of microsporidia spore-specific antigens by monoclonal antibodies," *Hybridoma*, vol. 17, no. 3, pp. 237–243, 1998.

[60] L. Mo and M. Drancourt, "Monoclonal antibodies for specific detection of Encephalitozoon cuniculi," *Clinical and Diagnostic Laboratory Immunology*, vol. 11, no. 6, pp. 1060–1063, 2004.

[61] K. Furuya, S. Miwa, M. Omura, et al., "Mouse monoclonal immunoglobulin E antibodies specific for the microsporidian Encephalitozoon cuniculi polar tube protein 1," *Hybridoma*, vol. 27, no. 3, pp. 153–157, 2008.

[62] G. P. Croppo, G. S. Visvesvara, G. J. Leitch, S. Wallace, and D. A. Schwartz, "Identification of the microsporidian Encephalitozoon hellem using immunoglobulin G monoclonal antibodies," *Archives of Pathology and Laboratory Medicine*, vol. 122, no. 2, pp. 182–186, 1998.

[63] Q. Zhang, I. Singh, A. Sheoran, et al., "Production and characterization of monoclonal antibodies against *Enterocytozoon bieneusi* purified from rhesus macaques," *Infection and Immunity*, vol. 73, no. 8, pp. 5166–5172, 2005.

[64] I. Singh, A. S. Sheoran, Q. Zhang, A. Carville, and S. Tzipori, "Sensitivity and specificity of a monoclonal antibody-based fluorescence assay for detecting *Enterocytozoon bieneusi* spores in feces of simian immunodeficiency virus-infected macaques," *Clinical and Diagnostic Laboratory Immunology*, vol. 12, no. 10, pp. 1141–1144, 2005.

[65] A. S. Sheoran, X. Feng, I. Singh, et al., "Monoclonal antibodies against *Enterocytozoon bieneusi* of human origin," *Clinical and Diagnostic Laboratory Immunology*, vol. 12, no. 9, pp. 1109–1113, 2005.

[66] C. N. Jordan, A. M. Zajac, K. S. Snowden, and D. S. Lindsay, "Direct agglutination test for Encephalitozoon cuniculi," *Veterinary Parasitology*, vol. 135, no. 3-4, pp. 235–240, 2006.

[67] I. F. Abou El Naga, M. R. Gaafar, L. A. El-Zawawy, D. El-Said, and S. F. Mossallam, "The utility of direct agglutination (DAT) and fast agglutination screening (FAST) tests in serodiagnosis of experimental microsporidiosis," *Journal of the Egyptian Society of Parasitology*, vol. 38, no. 3, pp. 903–918, 2008.

[68] Z. Kucerova-Pospisilova and O. Ditrich, "The serological surveillance of several groups of patients using antigens of Encephalitozoon hellem and E. cuniculi antibodies to microsporidia in patients," *Folia Parasitologica*, vol. 45, no. 2, pp. 108–112, 1998.

[69] M. Wittner and L. M. Weiss, *The Microsporidia and Microsporidiosis*, American Society for Microbiology, Washington, DC, USA, 1999.

[70] S. W. Avery and A. H. Undeen, "The isolation of microsporidia and other pathogens from concentrated ditch water," *Journal of the American Mosquito Control Association*, vol. 3, no. 1, pp. 54–58, 1987.

[71] S. E. Dowd, C. P. Gerba, and I. L. Pepper, "Confirmation of the human-pathogenic microsporidia *Enterocytozoon bieneusi*, Encephalitozoon intestinalis, and Vittaforma corneae in water," *Applied and Environmental Microbiology*, vol. 64, no. 9, pp. 3332–3335, 1998.

[72] S. E. Dowd, D. John, J. Eliopolus, et al., "Confirmed detection of Cyclospora cayetanesis, Encephalitozoon intestinalis and Cryptosporidium parvum in water used for drinking," *Journal of Water Health*, vol. 1, no. 3, pp. 117–123, 2003.

[73] S. Fournier, O. Liguory, M. Santillana-Hayat, et al., "Detection of microsporidia in surface water: a one-year follow-up study," *FEMS Immunology and Medical Microbiology*, vol. 29, no. 2, pp. 95–100, 2000.

[74] J. A. Thurston-Enriquez, P. Watt, S. E. Dowd, R. Enriquez, I. L. Pepper, and C. P. Gerba, "Detection of protozoan parasites and microsporidia in irrigation waters used for crop production," *Journal of Food Protection*, vol. 65, no. 2, pp. 378–382, 2002.

[75] S. Coupe, K. Delabre, R. Pouillot, S. Houdart, M. Santillana-Hayat, and F. Derouin, "Detection of Cryptosporidium, Giardia and *Enterocytozoon bieneusi* in surface water, including recreational areas: a one-year prospective study," *FEMS Immunology and Medical Microbiology*, vol. 47, no. 3, pp. 351–359, 2006.

[76] L. Cotte, M. Rabodonirina, F. Chapuis, et al., "Waterborne outbreak of intestinal microsporidiosis in persons with and without human immunodeficiency virus infection," *Journal of Infectious Diseases*, vol. 180, no. 6, pp. 2003–2008, 1999.

[77] D. S. Zarlenga and J. M. Trout, "Concentrating, purifying and detecting waterborne parasites," *Veterinary Parasitology*, vol. 126, no. 1-2, pp. 195–217, 2004.

[78] R. M. Hoffman, D. M. Wolk, S. K. Spencer, and M. A. Borchardt, "Development of a method for the detection of waterborne microsporidia," *Journal of Microbiological Methods*, vol. 70, no. 2, pp. 312–318, 2007.

[79] M. A. Borchardt and S. K. Spencer, "Concentration of Cryptosporidium, microsporidia and other water-borne pathogens by continuous separation channel centrifugation," *Journal of Applied Microbiology*, vol. 92, no. 4, pp. 649–656, 2002.

[80] A. M. Kahler and J. A. Thurston-Enriquez, "Human pathogenic microsporidia detection in agricultural samples: method development and assessment," *Parasitology Research*, vol. 100, no. 3, pp. 529–538, 2007.

[81] X. Li, K. W. Tate, L. A. Dunbar, B. Huang, and E. R. Atwill, "Efficiency for recovering Encephalitozoon intestinalis spores from waters by centrifugation and immunofluorescence microscopy," *Journal of Eukaryotic Microbiology*, vol. 50, supplement, pp. 579–580, 2003.

[82] S. Jedrzejewski, T. K. Graczyk, A. Slodkowicz-Kowalska, L. Tamang, and A. C. Majewska, "Quantitative assessment of contamination of fresh food produce of various retail types by human-virulent microsporidian spores," *Applied and Environmental Microbiology*, vol. 73, no. 12, pp. 4071–4073, 2007.

[83] T. K. Graczyk, F. E. Lucy, L. Tamang, and A. Miraflor, "Human enteropathogen load in activated sewage sludge and corresponding sewage sludge end products," *Applied and Environmental Microbiology*, vol. 73, no. 6, pp. 2013–2015, 2007.

[84] T. K. Graczyk, D. Sunderland, A. M. Rule, et al., "Urban feral pigeons (Columba livia) as a source for air- and waterborne contamination with *Enterocytozoon bieneusi* spores," *Applied and Environmental Microbiology*, vol. 73, no. 13, pp. 4357–4358, 2007.

[85] A. Bart, E. M. Wentink-Bonnema, E. R. Heddema, J. Buijs, and T. van Gool, "Frequent occurrence of human-associated microsporidia in fecal droppings of urban pigeons in Amsterdam, The Netherlands," *Applied and Environmental Microbiology*, vol. 74, no. 22, pp. 7056–7058, 2008.

[86] M. Haro, F. Izquierdo, N. Henriques-Gil, et al., "First detection and genotyping of human-associated microsporidia in pigeons from urban parks," *Applied and Environmental Microbiology*, vol. 71, no. 6, pp. 3153–3157, 2005.

[87] A. Mathis, A. C. Breitenmoser, and P. Deplazes, "Detection of new Enterocytozoon genotypes in faecal samples of farm dogs and a cat," *Parasite*, vol. 6, no. 2, pp. 189–193, 1999.

[88] E. S. Didier, M. E. Stovall, L. C. Green, P. J. Brindley, K. Sestak, and P. J. Didier, "Epidemiology of microsporidiosis: sources and modes of transmission," *Veterinary Parasitology*, vol. 126, no. 1-2, pp. 145–166, 2004.

[89] A. Curry, "Human microsporidial infection and possible animal sources," *Current Opinion in Infectious Diseases*, vol. 12, no. 5, pp. 473–480, 1999.

[90] H. Rinder, K. Janitschke, H. Aspöock, et al., "Blinded, externally controlled multicenter evaluation of liaht microscoclv and PCR for detection of microsporidiain stool specimens. The Diaunostic Multicenter Study Group on Microsporidia.," *J Clin Microbiol*, vol. 36, no. 6, pp. 1814–8, 1998.

[91] J. Dong, J. P. Olano, J. W. McBride, and D. H. Walker, "Emerging pathogens: challenges and successes of molecular diagnostics," *Journal of Molecular Diagnostics*, vol. 10, no. 3, pp. 185–197, 2008.

Hindawi Publishing Corporation
Interdisciplinary Perspectives on Infectious Diseases
Volume 2009, Article ID 984568, 9 pages
doi:10.1155/2009/984568

Review Article

Update on Babesiosis

Edouard Vannier[1] and Peter J. Krause[2]

[1] *Division of Geographic Medicine and Infectious Diseases, Tufts Medical Center, 800 Washington Street, Box 041, Boston, MA 02111, USA*
[2] *Department of Epidemiology and Public Health, Yale School of Medicine, 60 College Street, Room 600, P.O. Box 208034, New Haven, CT 06520, USA*

Correspondence should be addressed to Peter J. Krause, peter.krause@yale.edu

Received 12 March 2009; Accepted 14 May 2009

Recommended by Louis M. Weiss

Human babesiosis is an emerging tick-borne infectious disease caused by intraerythrocytic protozoan species of the genus *Babesia* with many clinical features similar to those of malaria. Over the last 50 years, the epidemiology of human babesiosis has changed from a few isolated cases to the establishment of endemic areas in the northeastern and midwestern United States. Episodic cases are reported in Europe, Asia, Africa, and South America. The severity of infection ranges from asymptomatic infection to fulminant disease resulting in death, although the majority of healthy adults experience a mild-to-moderate illness. People over the age of 50 years and immunocompromised individuals are at the highest risk of severe disease, including those with malignancy, HIV, lacking a spleen, or receiving immunosuppressive drugs. Asymptomatic carriers present a blood safety risk when they donate blood. Definitive diagnosis of babesial infection generally is made by microscopic identification of the organism on thin blood smear, amplification of *Babesia* DNA using PCR, and detection of *Babesia* antibody in acute and convalescent sera. Specific antimicrobial therapy consists of atovaquone and azithromycin or clindamycin and quinine. Exchange transfusion is used in severe cases. The use of multiple prevention strategies is recommended and consists of personal, residential, and community approaches.

1. Introduction

Human babesiosis is an emerging tick-borne infectious disease caused by an intraerythrocytic protozoan and has many clinical features similar to those of malaria. The parasite was first described in cattle by Babes in 1888 [1]. The first human case was described in 1957 [2]. Over the past 50 years, the epidemiology of the disease has changed from a few isolated cases to the establishment of endemic areas in southern New England, New York, New Jersey, and the northern Midwest [3–8]. Isolated cases are reported over a wide geographic range in Europe, Asia, Africa, and South America [9–17]. We will review the epidemiology, clinical characteristics, diagnosis, and treatment of infections caused by the four *Babesia* species that most commonly infect people: *B. microti*, *B. duncani*, *B. divergens*, and *B. venatorum*.

2. Epidemiology

2.1. United States

2.1.1. B. microti Infection. The most common cause of human babesiosis is *Babesia microti*, a *Babesia* of mice and other small rodents that is endemic in the United States [5–8]. Most cases occur along the northeastern seaboard. The first confirmed case was a normosplenic individual on Nantucket Island off the coast of Massachusetts [18]. Additional cases were soon identified and the disease became known as Nantucket fever. Other islands off the coast of southern New England subsequently became recognized as endemic areas, including Martha's Vineyard, the Elizabeth Islands, Block Island, Shelter Island, the eastern part of Long Island, and Fire Island [19]. Endemic areas on the mainland include Cape Cod, the southwestern counties of Rhode Island, and southeastern Connecticut [6, 19, 20].

Babesiosis has been diagnosed in individuals from the Lower Hudson Valley (Westchester, Putnam, Dutchess, and Columbia counties) in New York State, and is endemic in New Jersey [21–23]. *B. microti* is also the etiologic agent of babesiosis in the northern midwestern region of the United States, particularly in Wisconsin and Minnesota [24–26]. A few isolated cases have been noted in Indiana [27, 28]. Human babesiosis due to *B. microti* recently has been reported from Europe while *B. microti*-like species have been described as the cause of infection in people living in Asia [13, 17, 29].

The distribution of *B. microti* overlaps with that of *Borrelia burgdorferi*, the agent of Lyme disease, as both organisms are transmitted by *Ixodes scapularis* in the United States [19, 30]. Although the geographic distribution of babesiosis appears to be restricted to certain foci within the areas of endemicity for *B. burgdorferi*, the endemic range is expanding. For this reason and because the number of reported cases has dramatically increased over the last two decades, babesiosis is recognized as an emerging infectious disease [8, 31, 32]. The increase in incidence has often been attributed to the expansion of the deer population because these vertebrates are the primary host for adult ticks, although they are not competent reservoirs for *B. microti*. Other factors include better awareness of the disease by local physicians, an encroachment of humans on wildlife habitat, and increasing travel of immunosuppressed individuals to endemic areas.

Although most *B. microti* infections are acquired by tick bites from May through October, at least 70 patients in the United States have acquired babesiosis by transfusion of contaminated blood products from asymptomatic donors [33–36]. Blood products typically are fresh or frozen packed red blood cells, although one case has been attributed to platelet transfusion. Several cases of neonatal babesiosis have been reported, and these were acquired by tick bite, transfusion, or transplacental transmission [37, 38].

2.1.2. B. duncani Infection. *B. duncani* is the name given to the previously designated WA1 *Babesia* [3]. All nine documented cases of *B. duncani* infection have occurred on the west coast of the United States. Two people acquired the babesial infection by transfusion of blood products while the remaining cases were attributed to tick bites [39, 40]. One blood donor was asymptomatic at time of donation whereas the other reported a 10-day episode of nausea. Both recipients were immunologically at risk; one was an elderly man and the other was a premature infant. Among the five other symptomatic cases, one was a young normosplenic adult living in Washington State (index case) whereas four were splenectomized and lived in California [41, 42]. One of these four men died. Sequence analysis of the entire 18S rRNA gene indicated that the organisms causing babesial illness in the index case from Washington State and in the two cases acquired by blood transfusion were phylogenetically indistinguishable whereas the organisms acquired by three of the four splenectomized cases in California formed a separate but closely related phylogenetic group [3, 43]. The seroprevalence of *B. duncani* infection has been found to vary from 4% to 17% [41].

2.1.3. B. divergens-Like Infection. *B. divergens*-like organisms have been identified in three cases, two from the Midwest (Missouri and Kentucky) and one from Washington State [4, 44, 45]. All three patients had risk factors for severe babesial disease, namely, age greater than 50 years and splenectomy. Sequence analysis of the entire 18S rRNA gene indicated that the Missouri isolate (MO1) and the Kentucky isolate (KY) were identical to each other and to piroplasms found in eastern cottontail rabbits on Nantucket Island [46]. These isolates differed by a few bp in their 18S rRNA gene from the isolate of the Washington State patient and from the *B. divergens* organisms of European cattle. Because the piroplasms isolated from eastern cottontail rabbits are not infectious to cattle, the isolates obtained from the three US patients are now referred to as *B. divergens*-like organisms.

2.2. Europe

2.2.1. B. divergens Infection. About 40 cases of *B. divergens* infection have been documented in Europe, mostly from countries with extensive cattle industry such as France, Ireland, and Great Britain [47–49]. Cases have sporadically been reported from Sweden, Switzerland, Spain, Portugal, and Croatia (index case). Nearly all patients were splenectomized prior to the onset of *Babesia* infection. Because cattle are the reservoir for *B. divergens*, persons at risk of contracting babesiosis are farmers or people vacationing in rural areas. Limited data suggest that infection with *B. divergens* can be asymptomatic in normosplenic individuals [47]. There are no reports of *B. divergens* infection acquired by blood transfusion [49].

2.2.2. B. venatorum (EU1) Infection. Because the advent of PCR allows for molecular characterization of babesial organisms, a new *Babesia* species has been identified in Europe. Originally referred to as EU1, the name "*B. venatorum*" was later proposed [12]. *B. venatorum*, together with *B. odocoilei* that infects white-tail deer in the United States, form a sister group to that of *B. divergens*. Three cases of infection with *B. venatorum* have been documented [12, 50]. All three were men beyond 50 years of age who had been splenectomized. Unlike *B. divergens* infections that are fulminant and often fatal, *B. venatorum* infections have varied from mild to severe but have not been fatal.

3. Clinical Characteristics

3.1. B. microti Infection. The severity of *B. microti* infection is variable, depending primarily on the immune status of the host. Several clinical syndromes have been described, including asymptomatic infection, mild-to-moderate viral-like illness, and severe disease with a fulminant course that sometimes results in death or a persistent relapsing illness. Concurrent infection with Lyme disease increases neither the number nor the duration of symptoms of babesiosis [30, 51].

It is unclear whether this is also true of concurrent babesiosis and human granulocytic anaplasmosis.

3.1.1. Asymptomatic Infection. Following transmission of the babesial parasite, the incubation period may last from 1 to 9 weeks [5, 8]. Many people who are infected with *B. microti* never experience symptoms, as suggested by the disparity between seroprevalence and the number of reported cases. The frequency of asymptomatic *B. microti* infection was derived from an epidemiologic study of babesiosis carried out on Block Island, Rhode Island [6]. About a third of babesial infections at this site were asymptomatic, including 19% (13 of 67) of adults and 40% (4 of 10) of children [6]. Asymptomatic infection may persist for months or years following resolution of symptomatic babesiosis [36]. It is uncertain whether patients experiencing asymptomatic babesial infection are at risk for any long-term complications. They may transmit the infection if they donate blood [33].

3.1.2. Mild-to-Moderate Illness. Most cases of *B. microti* infection consist of a mild to moderate viral-like illness. These cases typically begin with a gradual onset of malaise and fatigue followed by intermittent fever and one or more of the following: chills, sweats, headache, arthralgia, myalgia, anorexia, cough, and nausea (Table 1) [30, 52–54]. Less commonly noted are gastrointestinal symptoms, weight loss, conjunctival injection, and emotional lability [53–57]. On physical examination, fever is commonly observed and pallor, mild splenomegaly or hepatomegaly occasionally may be noted. The illness usually lasts for a week to months, occasionally with prolonged recovery that can last more than a year [30, 36, 53, 56, 57]. Parasitemia may continue even after the patient feels well and rarely may persist for more than two years after the initial episode [36].

3.1.3. Severe Disease. Severe disease generally occurs in people with underlying immunosuppressive conditions that include HIV, malignancy, immunosuppressive medication, and splenectomy [50, 56, 58–60]. On physical examination, jaundice, retinal infarcts, or ecchymoses and petechiae may be noted [55, 58, 61]. The most common complications of severe babesiosis include acute respiratory failure, congestive heart failure, DIC, liver and renal failure, and splenic rupture [52]. A mortality rate of 5% was noted in a retrospective study of 136 patients experiencing *B. microti* infection on Long Island, New York, only one of whom was known to be immunocompromised [7]. In another study, the mortality rate among patients hospitalized for babesiosis was 9% [52]. The mortality rate is even higher among immunocompromised hosts. In a recent case-control study of 14 patients who were highly immunocompromised, 21% died and the remainder experienced a prolonged, relapsing course of illness, sometimes lasting more than a year, despite multiple courses of standard antibabesial therapy [59]. People 50 years of age and older also are more likely to experience severe babesiosis [52, 54, 62].

3.2. B. duncani Infection. Although studies of infection in hamsters suggest that *B. duncani* is more pathogenic than *B. microti*, the small number of reported *B. duncani* cases does not allow firm conclusions [32]. Of the nine reported cases of *B. duncani*, one died, one experienced pulmonary edema and renal insufficiency, and the remainder had a relatively mild clinical course or were asymptomatic [3, 39, 40, 42, 63]. Parasitemia ranged from 1% to 54%. Symptoms of *B. duncani* are similar to those of *B. microti* and consist of fever, chills, headache, sweats, myalgia, nausea, vomiting, diarrhea, dark urine, and fatigue.

3.3. B. divergens Infection. Nearly all 40 cases of *B. divergens* infection reported in Europe had been splenectomized and suffered a severe form of babesiosis [47–49]. Signs and symptoms begin 1 to 3 weeks after tick transmission and consist of high fever (40-41°C) with severe intravascular hemolysis that results in hemoglobinemia, hemoglobinuria, and jaundice. Headache, shaking chills, intense sweating, myalgia, and abdominal pain are common. More than half the cases experienced a rapid onset of renal failure and pulmonary edema. Ecchymoses, petechiae, congestive heart failure, and coma also have been reported. The illness generally is fulminant, lasting about a week and ending in death in more than a third of patients or in a prolonged convalescence.

3.4. B. venatorum (EU1) Infection. All three reported cases of *B. venatorum* infection had a history of Hodgkin's disease and had been splenectomized [12, 50]. One experienced mild babesiosis, whereas two had moderate-to-severe illness. In these two patients, babesiosis was concurrent with a relapse of nodular lymphocyte-predominant Hodgkin's lymphoma or with stage IIIA diffuse large B cell lymphoma. All three patients were admitted to the hospital and recovered after antibabesial therapy. One had a prolonged relapsing illness that eventually cleared. Peak parasitemia ranged from 1% to 30%. Symptoms included fever, dark urine, fatigue, chills, headache, confusion, jaundice, sweats, and shortness of breath.

4. Diagnosis

The diagnosis of babesiosis should be considered in patients who live or travel in areas that are endemic for babesiosis and who experience a viral-like illness in the late spring, summer, or autumn (Table 2). As the symptoms and signs are relatively nonspecific, laboratory testing is required for diagnosis. In some cases, physicians may choose to obtain screening laboratory testing such as a CBC, platelet count, and liver enzymes before ordering specific diagnostic tests. Most cases of babesiosis are accompanied by some degree of hemolytic anemia with an elevated reticulocyte count. Thrombocytopenia is common. The leukocyte count usually is normal to slightly decreased. Elevated serum liver enzymes occur in about half the patients. Proteinuria and an elevated blood urea nitrogen and serum creatinine also may be noted. Specific laboratory tests that are used for

Table 1: The most common symptoms of babesiosis caused by *Babesia microti* infection.

Symptom	Percentage of outpatients ($n = 41$)	Percentage of inpatients ($n = 173$)	Percentage of all patients ($n = 214$)
Fever	68	89	85
Fatigue	78	79	79
Chills	39	68	63
Sweats	41	56	53
Headache	75	32	39
Myalgia	37	32	33
Anorexia	25	24	24
Cough	17	23	22
Arthralgia	31	17	18
Nausea	22	9	16

Outpatient cases are from Ruebush et al. [60] and Krause et al. [30]. Inpatient cases are from White et al. [54] and Hatcher et al. [52].

the diagnosis of babesiosis are described below. Specific tests for concurrent Lyme disease and human granulocytic anaplasmosis should be performed in patients presenting with clinical manifestations that suggest coinfection, such as an erythema migrans type rash or neutropenia.

4.1. Microscopic Identification. Specific diagnosis of babesiosis can be made by microscopic identification of the organism using Giemsa stains of thin blood smears [64, Figure 1]. Thick blood smears also may be performed but the babesial organisms are small and may be difficult to visualize. *B. microti* and other *Babesia* spp. are round, oval, or pear-shaped and have a blue cytoplasm with a red chromatin. The ring form is most common and can be mistaken for early stage ring forms of *Plasmodium falciparum*. Multiple thin blood smears should be examined when only a few erythrocytes are infected, particularly in the early stage of illness when most people seek medical attention. PCR and serology should be performed if only a few ring-like structures are observed. Parasitemia seldom exceeds 5% in normal hosts but may be as high as 85% in asplenic individuals [55]. *B. divergens* and related organisms often appear as paired piriforms in human red blood cells. Pairs of *B. divergens* and *B. divergens*-like organisms are located in a subcentral, central, or peripheral position [46]. *B. venatorum* are morphologically indistinguishable from *B. divergens* [12, 50]. The tetrad form, referred to as a Maltese cross, is pathognomonic of small *Babesia* spp. such as *B. microti* and *B. duncani* [3]. *B. duncani* display more tetrad forms than *B. microti*.

4.2. Polymerase Chain Reaction. The polymerase chain reaction (PCR) provides a highly sensitive and specific test for detecting *Babesia* DNA in blood and identifies the *Babesia* species [65, 66]. Rigorous precautions are required to avoid false positive results. PCR is recommended when parasites are not identified on blood smears but symptoms and history are suggestive of babesiosis. As with all *Babesia* specific tests, it should only be performed in laboratories that are experienced in such testing and meet the highest laboratory performance standards.

Table 2: Diagnosis of babesiosis.

Epidemiology
– Residence in or travel to an area endemic for babesiosis
– *Ixodes* tick bite
– History of recent blood transfusion from a donor living or traveling in a *Babesia* endemic area
Symptoms
– Fever, fatigue, chills, sweats, headache, myalgia, anorexia, cough, arthralgia, nausea
– Less common: emotional lability and depression, hyperesthesia, sore throat, abdominal pain, conjunctival injection, photophobia, weight loss
Signs on physical examination
– Fever
– Splenomegaly, hepatomegaly, pallor
Common laboratory diagnostic procedures
– Identification of *Babesia* on Giemsa stained peripheral blood smears
– Amplification of *Babesia* DNA in blood using polymerase chain reaction
– Four-fold rise in *Babesia* antibody in acute or convalescent sera or identification of serum *Babesia* IgM antibody

4.3. Serology. Babesial infection can be confirmed by serologic testing using the indirect immunofluorescent assay (IFA) [67, 68]. During the acute phase of *B. microti* illness, IgG titers usually exceed 1 : 1024 and decline to 1 : 64 or less within 8 to 12 months. Thus, IgG titers of 1 : 1024 or greater usually signify active or recent infection [69]. The detection of IgM is indicative of recent infection [67]. Although seroconversion occurs in virtually all immunocompetent individuals infected with *B. microti*, the diagnosis of active babesial infection based on serologic findings alone is suspect. Serology usually is not considered in cases attributed to *B. divergens* because the illness becomes fulminant before antibody can be detected. Sera from patients infected with *B. divergens*-like organisms or *B. venatorum* cross-react with antigen from *B. divergens* [41, 42, 63]. Sera from patients

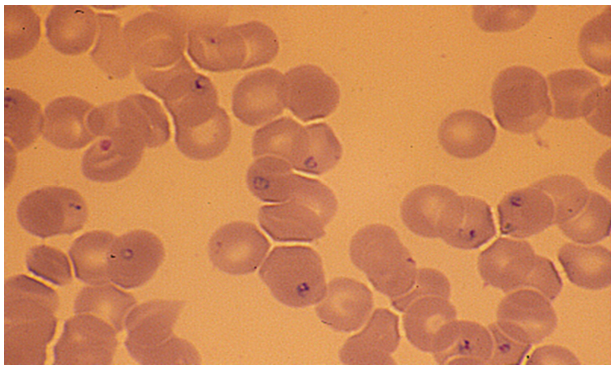

Figure 1: Ring forms of *B. microti* revealed by Giemsa staining of a human blood film (magnification 1000 x).

infected with *B. duncani* or related organisms do not cross-react with *B. microti* antigen [41, 42]. Sera from patients infected with one of several *Babesia* species may cross-react with antigen from *Plasmodium* species, but titers are almost always low (1 : 16 or lower).

4.4. Amplification of Babesia in Laboratory Animals. *Babesia* parasitemia can also be detected by injecting patient blood by the intravenous or intraperitoneal route into such laboratory animals as hamsters or gerbils [65]. This test is only available in a few research laboratories and is seldom useful for diagnosis. *B. microti* is easily detected in hamsters whereas *B. duncani* is often lethal in these animals [32]. This approach is not suited for rapid diagnosis, as *Babesia* usually do not appear in the blood of the laboratory animal until two to four weeks after inoculation.

5. Treatment

5.1. B. microti Infection

5.1.1. Mild-to-Moderate Disease. Most people infected with *B. microti* experience mild-to-moderate disease and can be successfully treated with a combination of atovaquone and azithromycin administered for 7 to 10 days [70, 71]. This combination was shown to be as effective as clindamycin and quinine, the first drug combination used in the treatment of babesiosis. The two regimens were directly compared in adults in a prospective, nonblinded randomized control trial [71]. While these drug combinations were similarly effective in clearing parasitemia and achieving resolution of symptoms, adverse effects were reported in 15% of subjects who received atovaquone and azithromycin compared with 72% of subjects who received clindamycin and quinine. The most common side effects associated with atovaquone and azithromycin were diarrhea and rash while those of clindamycin and quinine were tinnitus, hearing loss, and diarrhea. About a third of the subjects receiving clindamycin and quinine suffered from adverse reactions that were severe enough to require a decrease in dosage or discontinuing the medication. Only 2% of subjects taking atovaquone and azithromycin experienced such severe drug reactions. Although the atovaquone and azithromycin combination has not been studied in a controlled trial for pediatric use, cure has been achieved with use of this regimen in a child [72]. Clindamycin and quinine should be substituted for atovaquone and azithromycin when patients do not respond well to atovaquone and azithromycin.

5.1.2. Severe Disease. The combination of clindamycin (administered intravenously) and quinine given for 7 to 10 days is the treatment of choice for severe babesiosis. (Table 3) [70, 73]. Exchange red blood cell transfusion is indicated for all babesiosis patients experiencing heavy parasitemia (≥10%) or who have significant pulmonary, renal, or hepatic compromise [74–77]. Partial or complete exchange transfusion rapidly decreases parasite burden and removes toxic byproducts of *Babesia* infection.

5.1.3. Persistent Relapsing Disease. Babesial infection may persist and symptoms relapse in people with significant underlying immunosuppression despite standard combination antimicrobial therapy [59, 77]. Atovaquone-proguanil (250 mg–100 mg) was used to eradicate parasitemia in one such patient [77]. In a recent case-control study of chronic babesiosis in 14 highly immunocompromised patients, no single antimicrobial combination was uniformly superior to another in achieving resolution of infection [59]. Rather, cure was associated with duration of therapy for a minimum of six weeks and for at least two weeks after the last positive blood smear. Interestingly, the majority of case patients in the study had underlying B-cell lymphoma and had been treated with the anti-CD20 monoclonal antibody (Rituximab) prior to acute babesial infection, thereby dramatically impairing B-cell activity. It is important to recognize that a 7-to-10 day course of antibabesial therapy is sufficient for many immunocompromised patients. Thus, when acute babesiosis responds to a standard therapeutic course with resolution of symptoms and clearance of parasitemia on blood smear, no further treatment is required. Because immunosuppressed individuals are at increased risk for relapsing babesiosis, close clinical follow-up with repeat blood smears, *Babesia* PCR, and complete blood counts should be performed.

5.1.4. Asymptomatic Infection. In the unusual event that patients are identified with asymptomatic babesial infection, no treatment should be given unless parasitemia, as determined by blood smear or PCR, persists for longer than three months [70]. In this case, a one-week course of atovaquone and azithromycin should be considered. People who have positive serology, but negative blood smears and negative PCR should not be treated, as they likely have resolved the infection. Immunocompromised patients experiencing persistent asymptomatic parasitemia should have blood smears performed every month or two until they clear the infection.

5.2. B. duncani Infection. Recommended treatment consists of clindamycin and quinine [3, 39, 40, 42, 63]. Red cell

Table 3: Treatment of babesiosis.

Treatment	Dose	Frequency
Atovaquone and azithromycin		
Atovaquone	Adult: 750 mg	Every 12 hours
	Child: 20 mg/kg (maximum 750 mg/dose)	Every 12 hours
Azithromycin	Adult: 500 to 1000 mg	On day 1
	250 to 1000 mg	On subsequent days
	Child: 10 mg/kg (maximum 500 mg/dose)	On day 1
	5 mg/kg (maximum 250 mg/dose)	On subsequent days
Clindamycin and quinine		
Clindamycin	Adult: 600 mg	Every 8 hours
	Child: 7–10 mg/kg (maximum 600 mg/dose)	Every 6–8 hours
	Intravenous administration	
	Adult: 300–600 mg	Every 6 hours
	Child: 7–10 mg/kg (maximum 600 mg/dose)	Every 6–8 hours
Quinine	Adult: 650 mg	Every 6–8 hours
	Child: 8 mg/kg (maximum 650 mg/dose)	Every 8 hours

All antibiotics are administered by mouth unless otherwise specified. All doses are administered for 7 to 10 days except for persistent relapsing infection (see text). For immunocompromised patients experiencing babesiosis, successful outcome has been reported using atovaquone combined with higher doses of azithromycin (600–1000 mg per day) [78].
Complete or partial exchange transfusion should be considered for treatment of severe babesiosis.

exchange transfusion should be considered in the treatment of severe cases [41]. Renal insufficiency may require hemodialysis.

5.3. B. divergens and B. divergens-Like Infections. The morbidity and mortality rate of *Babesia divergens* infections are high and any such case should be considered a medical emergency [47, 49]. It is recommended that these infections be treated with exchange transfusion and clindamycin and quinine. One mild case of *B. divergens* infection was successfully treated with the combination of pentamidine and trimethoprim-sulfamethoxazole whereas another only required an abbreviated course of clindamycin and quinine (the quinine was stopped after 4 days) [79, 80]. In both cases, exchange transfusion was not needed. The *Babesia divergens*-like infections reported from Kentucky and Washington State were successfully treated with clindamycin and quinine or quinidine, but the case from Missouri died despite clindamycin and quinine therapy [4, 44, 45].

5.4. B. venatorum Infection. Of the three cases of *B. venatorum* infection, one cleared on clindamycin alone [12, 50]. The other two were given clindamycin and quinine. One of these patients was highly immunocompromised and relapsed after clindamycin and quinine was discontinued. He required a prolonged course of atovaquone and azithromycin followed by atovaquone alone for cure. In the third case, blood transfusion was given for massive hemolysis, and the infection eventually cleared following antimicrobial therapy.

6. Prevention

The use of multiple strategies is most likely to be effective for prevention of babesiosis. These include personal, residential, and community approaches [81–88]. One obvious personal protective measure is to avoid areas where ticks, mice, and deer are known to thrive, especially from May through October [84]. Immunocompromised people who are at increased risk of severe babesiosis need to avoid such areas. Anyone who may contact foliage in endemic sites should wear clothing that covers the lower part of the body, tuck cuffs of the trousers into stockings, and spray or impregnate clothing with permethrin (Permanone) [86]. DEET-containing products should be applied to the skin if legs remain uncovered. After travel through a high-risk area, a tick check should be performed and attached ticks should be removed as soon as possible by use of tweezers [84]. No data is available on the use of prophylactic antimicrobials after a tick bite to prevent babesiosis nor has a human babesiosis vaccine been developed.

Property modifications can help reduce tick exposure. These include keeping grass mowed, removing leaf litter

at the edge of lawns, sealing stonewalls to decrease the number of mice, using plantings that do not attract deer, and fencing to keep deer away [84]. Acaracides can be applied to property, rodents (Damminix or fipronil), or deer (four poster device) [82, 84, 88]. Elimination of the deer population may sharply reduce the risk of babesiosis and other tick-borne infections. Within 3–5 years after deer were eliminated on Great Island off Cape Cod, Massachusetts, the density of *I. scapularis* ticks fell precipitously [87]. Currently, the Red Cross and other blood donation agencies prohibit people with a history of babesiosis from donating blood in order to prevent transfusion-related cases. Additional measures such as screening blood donors for silent *Babesia* infection or inactivation of *Babesia* parasites in units of blood prior to transfusion have been considered but are not yet in use [89, 90].

Acknowledgement

This review has been made possible thanks to the generous support of The Gordon and Llura Gund Foundation.

References

[1] V. Babes, "Sur l'hemoglobinurie bacterienne du boeuf," *Comptes Rendus de l'Academie des Sciences*, vol. 107, pp. 692–694, 1888.

[2] Z. Skrabalo and Z. Deanovic, "Piroplasmosis in man; report of a case," *Documenta de Medicina Geographica et Tropica*, vol. 9, no. 1, pp. 11–16, 1957.

[3] P. A. Conrad, A. M. Kjemtrup, R. A. Carreno, et al., "Description of *Babesia duncani* n.sp. (Apicomplexa: Babesiidae) from humans and its differentiation from other piroplasms," *International Journal for Parasitology*, vol. 36, no. 7, pp. 779–789, 2006.

[4] B. L. Herwaldt, D. H. Persing, E. A. Précigout, et al., "A fatal case of babesiosis in Missouri: Identification of another piroplasm that infects humans," *Annals of Internal Medicine*, vol. 124, no. 7, pp. 643–650, 1996.

[5] K.-P. Hunfeld, A. Hildebrandt, and J. S. Gray, "Babesiosis: recent insights into an ancient disease," *International Journal for Parasitology*, vol. 38, no. 11, pp. 1219–1237, 2008.

[6] P. J. Krause, K. McKay, J. Gadbaw, et al., "Increasing health burden of human babesiosis in endemic sites," *American Journal of Tropical Medicine and Hygiene*, vol. 68, no. 4, pp. 431–436, 2003.

[7] S. C. Meldrum, G. S. Birkhead, D. J. White, J. L. Benach, and D. L. Morse, "Human babesiosis in New York state: an epidemiological description of 136 cases," *Clinical Infectious Diseases*, vol. 15, no. 6, pp. 1019–1023, 1992.

[8] E. Vannier, B. E. Gewurz, and P. J. Krause, "Human Babesiosis," *Infectious Disease Clinics of North America*, vol. 22, no. 3, pp. 469–488, 2008.

[9] J. B. Bush, M. Isaacson, A. S. Mohamed, F. T. Potgieter, and D. T. de Waal, "Human babesiosis—a preliminary report of 2 suspected cases in South Africa," *South African Medical Journal*, vol. 78, no. 11, p. 699, 1990.

[10] I. M. Foppa, P. J. Krause, A. Spielman, et al., "Entomologic and serologic evidence of zoonotic transmission of *Babesia microti*, eastern Switzerland," *Emerging Infectious Diseases*, vol. 8, no. 7, pp. 722–726, 2002.

[11] A. Gorenflot, C. Bazin, and P. Ambroise-Thomas, "Human babesiosis. Treatment of severe forms," *La Presse Médicale*, vol. 16, no. 22, p. 1099, 1987.

[12] B. L. Herwaldt, S. Cacciò, F. Gherlinzoni, et al., "Molecular characterization of a non-*Babesia divergens* organism causing zoonotic babesiosis in Europe," *Emerging Infectious Diseases*, vol. 9, no. 8, pp. 942–948, 2003.

[13] A. Hildebrandt, K.-P. Hunfeld, M. Baier, et al., "First confirmed autochthonous case of human *Babesia microti* infection in Europe," *European Journal of Clinical Microbiology and Infectious Diseases*, vol. 26, no. 8, pp. 595–601, 2007.

[14] J.-Y. Kim, S.-H. Cho, H.-N. Joo, et al., "First case of human babesiosis in Korea: detection and characterization of a novel type of *Babesia* sp. (KO1) similar to ovine Babesia," *Journal of Clinical Microbiology*, vol. 45, no. 6, pp. 2084–2087, 2007.

[15] A. Marathe, J. Tripathi, V. Handa, and V. Date, "Human babesiosis—a case report," *Indian Journal of Medical Microbiology*, vol. 23, no. 4, pp. 267–269, 2005.

[16] L. Rios, G. Alvarez, and S. Blair, "Serological and parasitological study and report of the first case of human babesiosis in Colombia," *Revista da Sociedade Brasileira de Medicina Tropical*, vol. 36, no. 4, pp. 493–498, 2003.

[17] C.-M. Shih, L.-P. Liu, W.-C. Chung, S.J. Ong, and C.-C. Wang, "Human babesiosis in Taiwan: asymptomatic infection with a *Babesia microti*-like organism in a Taiwanese woman," *Journal of Clinical Microbiology*, vol. 35, no. 2, pp. 450–454, 1997.

[18] K. A. Western, G. D. Benson, N. N. Gleason, G. R. Healy, and M. G. Schultz, "Babesiosis in a Massachusetts resident," *The New England Journal of Medicine*, vol. 283, no. 16, pp. 854–856, 1970.

[19] A. Spielman, M. L. Wilson, J. F. Levine, and J. Piesman, "Ecology of *Ixodes dammini*-borne human babesiosis and Lyme disease," *Annual Review of Entomology*, vol. 30, pp. 439–460, 1985.

[20] S. E. Rodgers and T. N. Mather, "Human *Babesia microti* incidence and *Ixodes scapularis* distribution, Rhode Island, 1998–2004," *Emerging Infectious Diseases*, vol. 13, no. 4, pp. 633–635, 2007.

[21] E. S. Eskow, P. J. Krause, A. Spielman, K. Freeman, and J. Aslanzadeh, "Southern extension of the range of human babesiosis in the Eastern United States," *Journal of Clinical Microbiology*, vol. 37, no. 6, pp. 2051–2052, 1999.

[22] S. J. Kogut, C. D. Thill, M. A. Prusinski, et al., "*Babesia microti*, upstate New York," *Emerging Infectious Diseases*, vol. 11, no. 3, pp. 476–478, 2005.

[23] B. L. Herwaldt, P. C. McGovern, M. P. Gerwel, R. M. Easton, and R. R. MacGregor, "Endemic babesiosis in another eastern state: New Jersey," *Emerging Infectious Diseases*, vol. 9, no. 2, pp. 184–188, 2003.

[24] M. K. Froberg, D. Dannen, N. Bernier, W.-J. Shieh, J. Guarner, and S. Zaki, "Case report: spontaneous splenic rupture during acute parasitemia of *Babesia microti*," *Annals of Clinical and Laboratory Science*, vol. 38, no. 4, pp. 390–392, 2008.

[25] R. K. Pruthi, W. F. Marshall, J. C. Wiltsie, and D. H. Persing, "Human babesiosis," *Mayo Clinic Proceedings*, vol. 70, no. 9, pp. 853–862, 1995.

[26] R. W. Steketee, M. R. Eckman, and E. C. Burgess, "Babesiosis in Wisconsin. A new focus of disease transmission," *Journal of the American Medical Association*, vol. 253, no. 18, pp. 2675–2678, 1985.

[27] K. H. Berman, D. E. Blue, D. S. Smith, P. Y. Kwo, and S. Liangpunsakul, "Fatal case of babesiosis in postliver transplant patient," *Transplantation*, vol. 87, no. 3, pp. 452–453, 2009.

[28] D. Blue, V. Graves, L. McCarthy, J. Cruz, S. Gregurek, and D. Smith, "Fatal transfusion-transmitted *Babesia microti* in the Midwest," *Transfusion*, vol. 49, no. 1, p. 8, 2009.

[29] Q. Wei, M. Tsuji, A. Zamoto, et al., "Human babesiosis in Japan: isolation of *Babesia microti*-like parasites from an asymptomatic transfusion donor and from a rodent from an area where babesiosis is endemic," *Journal of Clinical Microbiology*, vol. 39, no. 6, pp. 2178–2183, 2001.

[30] P. J. Krause, S. R. Telford III, A. Spielman, et al., "Concurrent Lyme disease and babesiosis: evidence for increased severity and duration of illness," *Journal of the American Medical Association*, vol. 275, no. 21, pp. 1657–1660, 1996.

[31] P. J. Krause, S. R. Telford III, R. Ryan, et al., "Geographical and temporal distribution of babesial infection in Connecticut," *Journal of Clinical Microbiology*, vol. 29, no. 1, pp. 1–4, 1991.

[32] A. M. Kjemtrup and P. A. Conrad, "Human babesiosis: an emerging tick-borne disease," *International Journal for Parasitology*, vol. 30, no. 12-13, pp. 1323–1337, 2000.

[33] D. A. Leiby, "Babesiosis and blood transfusion: flying under the radar," *Vox Sanguinis*, vol. 90, no. 3, pp. 157–165, 2006.

[34] D. M. Gubernot, C. T. Lucey, K. C. Lee, G. B. Conley, L. G. Holness, and R. P. Wise, "Babesia infection through blood transfusions: reports received by the US Food and Drug Administration, 1997–2007," *Clinical Infectious Diseases*, vol. 48, no. 1, pp. 25–30, 2009.

[35] J. V. Linden, S. J. Wong, F. K. Chu, G. B. Schmidt, and C. Bianco, "Transfusion-associated transmission of babesiosis in New York State," *Transfusion*, vol. 40, no. 3, pp. 285–289, 2000.

[36] P. J. Krause, A. Spielman, S. R. Telford III, et al., "Persistent parasitemia after acute babesiosis," *The New England Journal of Medicine*, vol. 339, no. 3, pp. 160–165, 1998.

[37] D. Esernio-Jenssen, P. G. Scimeca, J. L. Benach, and M. J. Tenenbaum, "Transplacental/perinatal babesiosis," *Journal of Pediatrics*, vol. 110, no. 4, pp. 570–572, 1987.

[38] L. M. Fox, S. Wingerter, A. Ahmed, et al., "Neonatal babesiosis: case report and review of the literature," *Pediatric Infectious Disease Journal*, vol. 25, no. 2, pp. 169–173, 2006.

[39] B. L. Herwaldt, A. M. Kjemtrup, P. A. Conrad, et al., "Transfusion-transmitted babesiosis in Washington state: first reported case caused by a WA1-type parasite," *Journal of Infectious Diseases*, vol. 175, no. 5, pp. 1259–1262, 1997.

[40] A. M. Kjemtrup, B. Lee, C. L. Fritz, C. Evans, M. Chervenak, and P. A. Conrad, "Investigation of transfusion transmission of a WA1-type babesial parasite to a premature infant in California," *Transfusion*, vol. 42, no. 11, pp. 1482–1487, 2002.

[41] D. H. Persing and P. A. Conrad, "Babesiosis: new insights from phylogenetic analysis," *Infectious Agents and Disease*, vol. 4, no. 4, pp. 182–195, 1995.

[42] R. E. Quick, B. L. Herwaldt, J. W. Thomford, et al., "Babesiosis in Washington State: a new species of Babesia?" *Annals of Internal Medicine*, vol. 119, no. 4, pp. 284–290, 1993.

[43] A. M. Kjemtrup, J. Thomford, T. Robinson, and P. A. Conrad, "Phylogenetic relationships of human and wildlife piroplasm isolates in the western United States inferred from the 18S nuclear small subunit RNA gene," *Parasitology*, vol. 120, no. 5, pp. 487–493, 2000.

[44] J. F. Beattie, M. L. Michelson, and P. J. Holman, "Acute babesiosis caused by *Babesia divergens* in a resident of Kentucky," *The New England Journal of Medicine*, vol. 347, no. 9, pp. 697–698, 2002.

[45] B. L. Herwaldt, G. de Bruyn, N. J. Pieniazek, et al., "*Babesia divergens*-like Infection, Washington State," *Emerging Infectious Diseases*, vol. 10, no. 4, pp. 622–629, 2004.

[46] P. J. Holman, "Phylogenetic and biologic evidence that *Babesia divergens* is not endemic in the United States," *Annals of the New York Academy of Sciences*, vol. 1081, pp. 518–525, 2006.

[47] A. Gorenflot, K. Moubri, E. Precigout, B. Carcy, and T. P. M. Schetters, "Human babesiosis," *Annals of Tropical Medicine and Parasitology*, vol. 92, no. 4, pp. 489–501, 1998.

[48] A. Zintl, J. S. Gray, H. E. Skerrett, and G. Mulcahy, "Possible mechanisms underlying age-related resistance to bovine babesiosis," *Parasite Immunology*, vol. 27, no. 4, pp. 115–120, 2005.

[49] A. Zintl, G. Mulcahy, H. E. Skerrett, S. M. Taylor, and J. S. Gray, "*Babesia divergens*, a bovine blood parasite of veterinary and zoonotic importance," *Clinical Microbiology Reviews*, vol. 16, no. 4, pp. 622–636, 2003.

[50] K. Haselbarth, A. M. Tenter, V. Brade, G. Krieger, and K.-P. Hunfeld, "First case of human babesiosis in Germany—clinical presentation and molecular characterisation of the pathogen," *International Journal of Medical Microbiology*, vol. 297, no. 3, pp. 197–204, 2007.

[51] P. J. Krause, K. McKay, C. A. Thompson, et al., "Disease-specific diagnosis of coinfecting tickborne zoonoses: babesiosis, human granulocytic ehrlichiosis, and Lyme disease," *Clinical Infectious Diseases*, vol. 34, no. 9, pp. 1184–1191, 2002.

[52] J. C. Hatcher, P. D. Greenberg, J. Antique, and V. E. Jimenez-Lucho, "Severe babesiosis in Long Island: review of 34 cases and their complications," *Clinical Infectious Diseases*, vol. 32, no. 8, pp. 1117–1125, 2001.

[53] T. K. Ruebush II, D. D. Juranek, and E. S. Chisholm, "Human babesiosis on Nantucket Island. Evidence for self-limited and subclinical infections," *The New England Journal of Medicine*, vol. 297, no. 15, pp. 825–827, 1977.

[54] D. J. White, J. Talarico, H.-G. Chang, G. S. Birkhead, T. Heimberger, and D. L. Morse, "Human babesiosis in New York State: review of 139 hospitalized cases and analysis of prognostic factors," *Archives of Internal Medicine*, vol. 158, no. 19, pp. 2149–2154, 1998.

[55] T. Sun, M. J. Tenenbaum, and J. Greenspan, "Morphologic and clinical observations in human infection with *Babesia microti*," *Journal of Infectious Diseases*, vol. 148, no. 2, pp. 239–248, 1983.

[56] H. O. Mathewson, A. E. Anderson, and G. W. Hazard, "Self-limited babesiosis in a splenectomized child," *Pediatric Infectious Disease*, vol. 3, no. 2, pp. 148–149, 1984.

[57] J. M. Ortiz and R. C. Eagle Jr., "Ocular findings in human babesiosis (Nantucket fever)," *American Journal of Ophthalmology*, vol. 93, no. 3, pp. 307–311, 1982.

[58] F. Rosner, M. H. Zarrabi, J. L. Benach, and G. S. Habicht, "Babesiosis in splenectomized adults. Review of 22 reported cases," *American Journal of Medicine*, vol. 76, no. 4, pp. 696–701, 1984.

[59] P. J. Krause, B. E. Gewurz, D. Hill, et al., "Persistent and relapsing babesiosis in immunocompromised patients," *Clinical Infectious Diseases*, vol. 46, no. 3, pp. 370–376, 2008.

[60] T. K. Ruebush II, P. B. Cassaday, and H. J. Marsh, "Human babesiosis on Nantucket Island: clinical features," *Annals of Internal Medicine*, vol. 86, no. 1, pp. 6–9, 1977.

[61] C. P. Stowell, J. A. Gelfand, J.-A. O. Shepard, and A. Kratz, "Case 17-2007: a 25-year-old woman with relapsing fevers and recent onset of dyspnea," *The New England Journal of Medicine*, vol. 356, no. 22, pp. 2313–2319, 2007.

[62] J. L. Benach and G. S. Habicht, "Clinical characteristics of human babesiosis," *Journal of Infectious Diseases*, vol. 144, no. 5, p. 481, 1981.

[63] D. H. Persing, B. L. Herwaldt, C. Glaser, et al., "Infection with a Babesia-like organism in Northern California," *The New England Journal of Medicine*, vol. 332, no. 5, pp. 298–303, 1995.

[64] G. R. Healy and T. K. Ruebush II, "Morphology of *Babesia microti* in human blood smears," *American Journal of Clinical Pathology*, vol. 73, no. 1, pp. 107–109, 1980.

[65] P. J. Krause, S. R. Telford III, A. Spielman, et al., "Comparison of PCR with blood smear and inoculation of small animals for diagnosis of *Babesia microti* parasitemia," *Journal of Clinical Microbiology*, vol. 34, no. 11, pp. 2791–2794, 1996.

[66] D. H. Persing, D. Mathiesen, W. F. Marshall, et al., "Detection of *Babesia microti* by polymerase chain reaction," *Journal of Clinical Microbiology*, vol. 30, no. 8, pp. 2097–2103, 1992.

[67] P. J. Krause, R. Ryan, S. R. Telford III, D. Persing, and A. Spielman, "Efficacy of immunoglobulin M serodiagnostic test for rapid diagnosis of acute babesiosis," *Journal of Clinical Microbiology*, vol. 34, no. 8, pp. 2014–2016, 1996.

[68] P. J. Krause, S. R. Telford III, R. Ryan, et al., "Diagnosis of babesiosis: evaluation of a serologic test for the detection of *Babesia microti* antibody," *Journal of Infectious Diseases*, vol. 169, no. 4, pp. 923–926, 1994.

[69] T. K. Ruebush II, A. J. Sulzer, and G. R. Healy, "Development and persistence of antibody in persons infected with *Babesia microti*," *American Journal of Tropical Medicine and Hygiene*, vol. 30, no. 1, pp. 291–292, 1981.

[70] G. P. Wormser, R. J. Dattwyler, E. D. Shapiro, et al., "The clinical assessments treatment, and prevention of lyme disease, human granulocytic anaplasmosis, and babesiosis: clinical practice guidelines by the Infectious Diseases Society of America," *Clinical Infectious Diseases*, vol. 43, no. 9, pp. 1089–1134, 2006.

[71] P. J. Krause, T. Lepore, V. K. Sikand, et al., "Atovaquone and azithromycin for the treatment of babesiosis," *The New England Journal of Medicine*, vol. 343, no. 20, pp. 1454–1458, 2000.

[72] M. Raju, J. C. Salazar, H. Leopold, and P. J. Krause, "Atovaquone and azithromycin treatment for babesiosis in an infant," *Pediatric Infectious Disease Journal*, vol. 26, no. 2, pp. 181–183, 2007.

[73] M. Wittner, K. S. Rowin, H. B. Tanowitz, et al., "Successful chemotherapy of transfusion babesiosis," *Annals of Internal Medicine*, vol. 96, no. 5, pp. 601–604, 1982.

[74] K. M. Cahill, J. L. Benach, L. M. Reich, et al., "Red cell exchange: treatment of babesiosis in a splenectomized patient," *Transfusion*, vol. 21, no. 2, pp. 193–198, 1981.

[75] G. A. Jacoby, J. V. Hunt, K. S. Kosinski, et al., "Treatment of transfusion-transmitted babesiosis by exchange transfusion," *The New England Journal of Medicine*, vol. 303, no. 19, pp. 1098–1100, 1980.

[76] V. I. Powell and K. Grima, "Exchange transfusion for malaria and babesia infection," *Transfusion Medicine Reviews*, vol. 16, no. 3, pp. 239–250, 2002.

[77] J. M. Vyas, S. R. Telford, and G. K. Robbins, "Treatment of refractory *Babesia microti* infection with atovaquone-proguanil in an HIV-infected patient: case report," *Clinical Infectious Diseases*, vol. 45, no. 12, pp. 1588–1590, 2007.

[78] L. M. Weiss, M. Wittner, and H. B. Tanowitz, "The treatment of babesiosis," *The New England Journal of Medicine*, vol. 344, no. 10, p. 773, 2001.

[79] D. Raoult, L. Soulayrol, B. Toga, H. Dumon, and P. Casanova, "Babesiosis, pentamidine, and cotrimoxazole," *Annals of Internal Medicine*, vol. 107, no. 6, p. 944, 1987.

[80] E. Denes, J. P. Rogez, M. L. Darde, and P. Weinbreck, "Management of *Babesia divergens* babesiosis without a complete course of quinine treatment," *European Journal of Clinical Microbiology and Infectious Diseases*, vol. 18, no. 9, pp. 672–673, 1999.

[81] E. B. Hayes and J. Piesman, "How can we prevent Lyme disease?" *The New England Journal of Medicine*, vol. 348, no. 24, pp. 2424–2430, 2003.

[82] T. N. Mather, J. M. C. Ribeiro, and A. Spielman, "Lyme disease and babesiosis: acaricide focused on potentially infected ticks," *American Journal of Tropical Medicine and Hygiene*, vol. 36, no. 3, pp. 609–614, 1987.

[83] G. R. Needham, "Evaluation of five popular methods for tick removal," *Pediatrics*, vol. 75, no. 6, pp. 997–1002, 1985.

[84] K. C. Stafford III, *Tick Management Handbook: An Integrated Guide for Homeowners, Pest Control Operators, and Public Health Officials for the Prevention of Tick-Associated Disease*, The Connecticut Agricultural Experimental Station, New Haven, Conn, USA, 2007.

[85] J. I. Tsao, J. T. Wootton, J. Bunikis, M. G. Luna, D. Fish, and A. G. Barbour, "An ecological approach to preventing human infection: vaccinating wild mouse reservoirs intervenes in the Lyme disease cycle," *Proceedings of the National Academy of Sciences of the United States of America*, vol. 101, no. 52, pp. 18159–18164, 2004.

[86] M. Vazquez, C. Muehlenbein, M. Cartter, E. B. Hayes, S. Ertel, and E. D. Shapiro, "Effectiveness of personal protective measures to prevent lyme disease," *Emerging Infectious Diseases*, vol. 14, no. 2, pp. 210–216, 2008.

[87] M. L. Wilson, S. R. Telford III, J. Piesman, and A. Spielman, "Reduced abundance of immature *Ixodes dammini* (Acari: Ixodidae) following elimination of deer," *Journal of Medical Entomology*, vol. 25, no. 4, pp. 224–228, 1988.

[88] D. Fish and J. E. Childs, "Community-Based Prevention of Lyme Disease and Other Tick-Borne Diseases Through Topical Application of Acaricide to White-Tailed Deer: Background and Rationale," *Vector-Borne and Zoonotic Diseases*, vol. 9, no. 4, pp. 357–364, 2009.

[89] P. Grellier, R. Santus, E. Mouray, et al., "Photosensitized inactivation of *Plasmodium falciparum*- and *Babesia divergens*-infected erythrocytes in whole blood by lipophilic pheophorbide derivatives," *Vox Sanguinis*, vol. 72, no. 4, pp. 211–220, 1997.

[90] B. Zavizion, M. Pereira, M. de Melo Jorge, et al., "Inactivation of protozoan parasites in red blood cells using INACTINE PEN110 chemistry," *Transfusion*, vol. 44, no. 5, pp. 731–738, 2004.

Hindawi Publishing Corporation
Interdisciplinary Perspectives on Infectious Diseases
Volume 2009, Article ID 251406, 14 pages
doi:10.1155/2009/251406

Review Article

Diagnosis of Infections Caused by Pathogenic Free-Living Amoebae

Bruno da Rocha-Azevedo,[1] Herbert B. Tanowitz,[2] and Francine Marciano-Cabral[1]

[1] *Department of Microbiology and Immunology, Virginia Commonwealth University School of Medicine, Richmond, VA 23298, USA*
[2] *Department of Pathology, Albert Einstein College of Medicine, Bronx, NY 10461, USA*

Correspondence should be addressed to Francine Marciano-Cabral, fmcabral@vcu.edu

Received 25 March 2009; Accepted 5 June 2009

Recommended by Louis M. Weiss

Naegleria fowleri, *Acanthamoeba spp.*, *Balamuthia mandrillaris*, and *Sappinia* sp. are pathogenic free-living amoebae. *N. fowleri* causes Primary Amoebic Meningoencephalitis, a rapidly fatal disease of the central nervous system, while *Acanthamoeba spp.* and *B. mandrillaris* cause chronic granulomatous encephalitis. *Acanthamoeba spp.* also can cause cutaneous lesions and Amoebic Keratitis, a sight-threatening infection of the cornea that is associated with contact lens use or corneal trauma. *Sappinia pedata* has been identified as the cause of a nonlethal case of amoebic encephalitis. In view of the potential health consequences due to infection with these amoebae, rapid diagnosis is critical for early treatment. Microscopic examination and culture of biopsy specimens, cerebral spinal fluid (CSF), and corneal scrapings have been used in the clinical laboratory. For amoebic keratitis, confocal microscopy has been used to successfully identify amoebae in corneal tissue. More recently, conventional and real-time PCR assays have been developed that are sensitive and specific for the amoebae. In addition, multiplex PCR assays are available for the rapid identification of these pathogens in biopsy tissue, CSF, and corneal specimens.

1. Introduction

Free-living amoebae (FLA) are found in soil and water habitats throughout the world. These amoebae ingest bacteria, yeast, and other organisms as a food source. Unlike "true" parasites, pathogenic FLA can complete their life cycles in the environment without entering a human or animal host. Of the many FLA that are found in the environment, four genera of FLA have been associated with human disease. One species of *Naegleria*, *N. fowleri,* one species of *Balamuthia, B. mandrillaris*, and several species of *Acanthamoeba* can cause fatal central nervous system (CNS) infections. In addition to a CNS infection, *Acanthamoeba* can cause cutaneous lesions and Amoebic Keratitis, a sight-threatening infection of the cornea [1–8]. Human infections with these amoebae have been reported from all over the world [3, 5]. More recently, a newly recognized pathogen was detected in brain tissue of a patient with CNS symptoms who survived the infection. Although the amoebae was not isolated from the patient, it was identified by light and electron microscopy as a species of *Sappinia*. *Sappinia* sp. has not been shown to be lethal in humans or experimental animals [9, 10]. Figure 1 shows the morphology of trophozoites of *N. fowleri* (A), *Acanthamoeba spp.* (B), and *B. mandrillaris* (C), by scanning electron microscopy.

Pathogenic FLA can be isolated from freshwater lakes, thermally polluted waters, sediment, thermal springs, swimming pools, soil, air conditioning vents, air, and the domestic water supply [3, 6, 11–14]. In addition to causing human disease, FLA also can harbor intracellular pathogenic bacteria such as *Legionella pneumophila* and may serve as vectors of bacterial infections in humans [15, 16]. A number of clinical FLA isolates from corneal and cutaneous lesions have been shown to harbor bacterial endosymbionts or pathogens [16–20]. Laboratory studies, also, have shown that a number of pathogenic bacteria including *Mycobacterium avium, Burkholderia spp.*, *Escherichia coli O157:H7*, and *Vibrio cholerae*, can survive and multiply in FLA [6, 21–26]. Intracellular growth of bacteria within amebae has been shown to increase bacterial resistance to antibiotics and to biocides, and to increase bacterial virulence [20, 23–26].

Since the majority of FLA infections are fatal and diagnosed postmortem, it is important to recognize the diseases and to develop more rapid diagnostic methods. The mode and pathogenesis of infection differ for each of the FLA that cause human infections.

2. *Naegleria fowleri* and Primary Amoebic Meningoencephalitis (PAM)

The amoeboflagellate, *N. fowleri,* has three morphological forms in its life cycle, an amoeba or trophozoite stage (Figure 1(a)) that feeds and divides, a swimming flagellate that seeks out a new food source, and a resistant cyst that protects the amoebae from adverse environmental conditions. *N. fowleri* causes Primary Amoebic Meningoencephalitis (PAM), an acute, fulminant, rapidly fatal disease that occurs generally in previously healthy children and young adults with a history of swimming and diving and other recreational activities in fresh water and contaminated swimming pools [1–3, 27–29]. Two other species of *Naegleria*, *N. australiensis* and *N. italica* can cause infections in mice but have never been identified from human infections [5]. Cases of PAM caused by *N. fowleri* have occurred also from contaminated domestic water used for bathing [11, 12]. Infection can occur when amebae enter the nasal passages, attach to the olfactory mucosa, and migrate through the cribriform plate alongside the olfactory nerves. Once in the olfactory bulbs of the brain, the amebae divide rapidly and death occurs within 7 to 10 days. *N. fowleri* causes a fulminating hemorrhagic necrosis of the brain. An inflammatory infiltrate consisting of neutrophils, eosinophils, and macrophages is histopathological characteristic of infected brain tissue. Only trophozoites are found in the brain [3–5, 29]. Survival from PAM is dependent on rapid diagnosis and treatment of the disease and has occurred when the disease was recognized early and treatment initiated promptly [30, 31]. Survival rate is improved when a combination of amphotericin B is used intravenously, with intrathecal administration of amphotericin B and oral rifampin and other antifungal agents [30–34]. Amphotericin B and fluconazole administered intravenously followed by oral rifampicin resulted in successful treatment of a child who developed PAM [35]. However, not all patients treated with Amphotericin B survive [36–38]. Others have suggested that a triple combination of low dose amphotericin B administered intravenously (IV) with oral rifampacin and oral ketoconazole would result in a more favorable outcome [39]. Azithromycin has been shown to be effective against *N. fowleri* in vitro (cell culture) and in vivo (mouse model of infection) [8]. However, optimal treatment remains to be developed.

2.1. Symptoms of PAM Infection. PAM is characterized by the sudden onset of severe frontal headache, fever, nausea, vomiting, and rhinitis. These are followed by stiff neck, diplopia, loss of the sense of smell, confusion, and occasional seizures, progressing rapidly to coma and death. An elevated white cell count is usual with a marked increase in neutrophils. CSF contains neutrophils, and thus a bacterial infection is often suspected [3–5, 7]. A history that describes contact with warm water (diving, wakeboarding, water skiing) is suggestive of PAM [40].

2.2. Laboratory Diagnosis. PAM is a rare disease but almost always fatal. Therefore, early diagnosis is important in order to start treatment. The disease is often misdiagnosed because no distinctive differences in diagnosis exist to distinguish PAM from bacterial meningoencephalitis.

2.2.1. Imaging Methods. Computed Tomography (CT) scans or Magnetic Resonance Imaging (MRI) shows lesions but these are nonspecific [41–43]. CT scans show obliteration of the cisterns surrounding the midbrain and the subarachnoid space [3].

2.2.2. Microscopic Methods. Premortem diagnosis is rare, but when CSF pressure is low, lumbar puncture can be performed. CSF is purulent, and when bacteria are not found, amoebic meningoencephalitis should be considered. The CSF is cloudy and slightly hemorrhagic with increased cellularity composed mainly of neutrophils. CSF is characterized by low glucose and elevated protein. Direct microscopic examination of CSF as a wet mount is the method of choice in the diagnosis of PAM because CSF contains motile amoebae which can be recognized by light microscopic observation [5, 44, 45]. *N. fowleri* can be distinguished from other FLA that cause CNS infections because amoebae can transform into swimming flagellates when amoebae are placed in water. If present in CSF, amoebae can be identified by staining fixed preparations with Wright's, Giemsa, or hematoxylin and eosin (H & E). Although Gram stain is used in clinical laboratories for detection of bacteria in CSF, Gram stain is not useful for diagnosis of amoebae because it does not depict the characteristic nuclear morphology of the amoebae. Amoebae can be mistaken as macrophages, but *N. fowleri* nucleus contains a large, central, round nucleolus which should distinguish it from host cells [3, 27, 44, 45].

Polyclonal antibodies produced in rabbits or monoclonal antibodies can be used to identify amoebae in tissue sections and CSF. Amoebae in CSF can be identified by specific indirect immunofluorescent antibody assays using a polyclonal or monoclonal antibody to the amoeba in conjunction with a flouresceinated secondary antibody [3, 45, 46].

Biopsy material should be fixed in 10% neutral buffered formalin for histological examination. Amoebae can be observed in biopsied brain tissue following H & E staining or by immunoperoxidase staining using antibodies to the amoebae. Only trophozoites are found in brain tissue; cysts are not observed [3].

A commercially available enzyme-linked immunosorbent assay (Indicia, Oulin, France) based on the use of a monoclonal antibody (5D12) that recognizes a glycosylated epitope on *N. fowleri* can be used to diagnose infections. This monoclonal antibody can be used to distinguish *N. fowleri* from other species of *Naegleria*, and from other FLA in tissue and in environmental samples [46, 47].

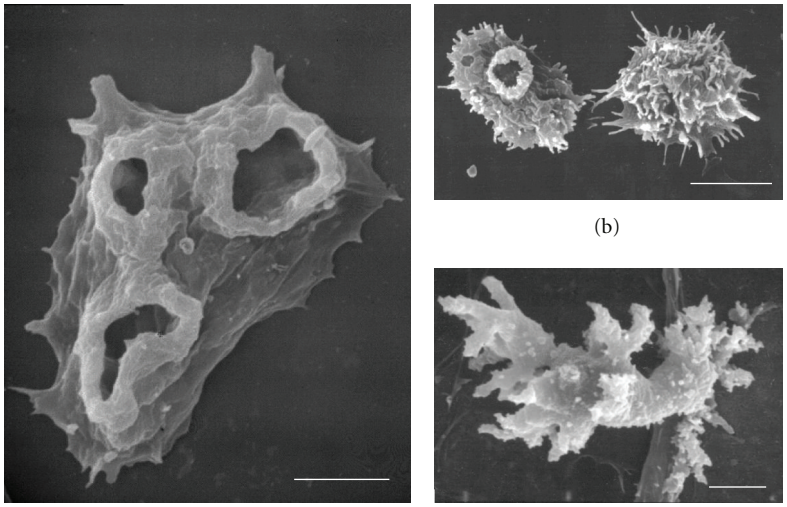

(a) (b) (c)

Figure 1: Fine morphology of trophozoites of *N. fowleri,* (a) *Acanthamoeba spp.*, (b) and *B. mandrillaris*, (c) by Scanning Electron Microscopy. Bars represent 5 μm.

2.2.3. Culture Methods. CSF or biopsied brain tissue should be kept and transported at room temperature to the diagnostic laboratory. This material can be inoculated onto tissue culture cells (Vero, fibroblasts) and incubated at 37°C in the presence of the antibiotics, penicillin-streptomycin. Fungicides are lethal to the amoebae. Amoebae that are present will multiply and destroy the monolayer in 24 to 48 hours. Biopsy tissue also can be placed on 1.5% nonnutrient agar coated with a layer of bacteria (*Escherichia coli*). The amoebae will emerge from the tissue, ingest the bacteria, and divide. The amoebae, then, can be observed on the agar using an inverted light microscope [3, 44, 45, 48].

2.2.4. Serology. Antibodies to *Naegleria spp*. have been identified in healthy individuals [49, 50]. Since PAM is a rapid disease, serological tests for an increase in antibody titer are not always helpful. Generally, there is not a rise in antibody titer although a rise in antibody has been observed in a patient that was successfully treated and survived the infection [30].

2.2.5. Polymerase Chain Reaction (PCR) Assays. More rapid molecular techniques are now available in research laboratories, but these methods generally are not available in most clinical laboratories. Highly specific and sensitive PCR and real-time PCR assays have been developed for the detection of *N. fowleri* in clinical and environmental samples [51–57]. A PCR assay using primers for the complete ribosomal internal transcribed spacer region (ITS) has been developed that allows for the discrimination of *Naegleria* species, and a species specific assay allows for detection of *N. fowleri* [51, 52]. A PCR assay that detects *N. fowleri* in fresh brain tissue as well as in formalin-fixed paraffin-embedded brain tissue also has been reported [56]. Recently, Qvarnstrom et al., [57] developed a fast and sensitive multiplex real-time PCR assay based on the use of probes targeting the partial or full length nuclear small subunit ribosomal genes (18S rRNA gene) for simultaneous detection of *Naegleria*, *Balamuthia,* and *Acanthamoeba* [57]. This PCR assay is species specific for *N. fowleri* and *B. mandrillaris* and genus specific for *Acanthamoeba.* Thus, this assay can identify which amoebae is present in a CSF sample or a brain biopsy specimen from an amoebic encephalitis patient. The detection limit for this assay was shown to be one amoebae per sample.

3. *Acanthamoeba spp.*

Acanthamoeba is one of the most commonly isolated amoebae in environmental samples. *Acanthamoeba* is ubiquitous and found in a variety of habitats including domestic water supplies, hospital water, dental water units, air, soil, and water. *Acanthamoeba* has two morphological forms in its life cycle, a trophozoite (Figure 1(b)) and a cyst stage. Both stages can be found in tissues of infected humans and in the environment. The trophozoite is the dividing form and is thought to be the infective stage. The cysts are dormant and protect the amoebae from harmful environments. The cysts are resistant to biocides, chlorination, and antibiotics. Several species of *Acanthamoeba* can cause Granulomatous Amoebic Encephalitis (GAE), cutaneous acanthamoebiasis, or Amoebic Keratitis (AK). AK is a sight-threatening infection of the cornea that occurs in immune competent individuals, mainly contact lens users. GAE, also known as *Acanthamoeba* Granulomatous Encephalitis (AGE), is a rare, chronic, progressive infection of the CNS that may involve the lungs [58]. GAE is usually associated with an underlying debilitating disease or immune suppressed individuals including HIV-AIDS patients, diabetics, individuals undergoing organ transplants or cancer chemotherapy, and drug abusers [6, 7, 58, 59]. Cutaneous lesions caused by *Acanthamoeba* also have been described. Cutaneous acanthamoebiasis has been reported more frequently in HIV

positive patients than in other conditions [60–66]. The manifestations of cutaneous infection include the presence of numerous hard erythematous nodules, papules, or ulcers along the patient's body [62–67]. The presence of both skin lesions and CNS symptoms occurring simultaneously can be suggestive of an *Acanthamoeba* infection [58].

3.1. Symptoms of GAE. GAE symptoms include headaches, slight fever, seizures, hemiparesis, cranial nerve palsies, personality changes, nausea, stiff neck, depressed level of consciousness and coma, typical clinical signs of a localized encephalopathy [5–8]. The clinical signs of GAE are not specific. Thus, the disease is often misdiagnosed as bacterial leptomeningitis, tuberculous meningitis, viral encephalitis, toxoplasmosis, fungal infections, neurocysticercosis, or a brain tumor [5, 6, 68–71].

3.2. Diagnostic Methods

3.2.1. Imaging Methods. Brain imaging methods, such as CT and MRI, have been used to visualize brain lesions caused by *Acanthamoeba*, but the lesions themselves are not specific for GAE [41–43]. Multifocal low-density lesions in both cortical and subcortical regions of the brain can be observed using CT scans. Enhanced CT normally shows the presence of progressive hydrocephalus, with meningeal thickening, pseudotumoral lesions, large isolated lesions, or multiple oval lesions. Multifocal lesions, edema, and multiple ring-enhancing lesions are commonly observed in GAE patients by MRI. Despite these characteristics, both CT and MRI have limited diagnostic value for GAE [5, 7, 41–43, 68–73].

3.2.2. Microscopic Methods. The definitive diagnosis of GAE is the detection of the amoeba in tissue or isolation of the amoeba. To achieve visual detection of both *Acanthamoeba* trophozoites and cysts in brain tissue, skin lesions, or cerebrospinal fluid (CSF), both light and electron microscopy can be used. *Acanthamoeba* trophozoites can be distinguished from host inflammatory cells such as macrophages mainly by their nuclear structure, since *Acanthamoeba* possesses a rounded nucleus and a large central nucleolus, forming a halo [3, 6, 59]. However, it is not possible to differentiate *Acanthamoeba* trophozoites from pathogenic *B. mandrillaris* trophozoites by light microscopy, since both amoebae possess the same nuclear structure [7]. Biopsy or autopsy specimens should be formalin-fixed, paraffin-embedded, and stained with H & E [74]. Other types of histological staining have been used, including Periodic Acid Shiff, Gomori's methenamine silver, or trichome. These stains appear to be effective in identifying cysts [75, 76]. Acridine orange and calcofluor white have been used successfully to observe *Acanthamoeba* cysts in tissues [6, 77, 78].

Brain granulomas, necrosis with the presence of multinucleated cells, inflammatory infiltrates, and amebas (both trophozoites and cysts) surrounding blood vessels [3–5] can be observed in biopsied tissue stained with H & E. Amoebae, also, can be detected in CSF in wet preparations or Giemsa stained slides of CSF sediments [29, 79, 80]. For the diagnosis of cutaneous acanthamoebiasis, light microscopic examination of H & E stained skin biopsies demonstrates the presence of granulomas, areas of necrosis, inflammatory infiltrates, and vasculitis containing both trophozoites and cysts of *Acanthamoeba* [62, 64, 67, 75, 81].

The use of both fluorescence microscopy and immunohistochemistry in brain and skin tissue sections is efficient methods to specifically detect *Acanthamoeba* [82–87]. Anti-*Acanthamoeba* antibodies generated in rabbits can be used to identify amoebae in tissue. Patient specimens are incubated with anti-*Acanthamoeba* antibodies followed by a secondary antirabbit IgG associated with a fluorescent marker to detect both trophozoites and cysts [74]. More recently, species-specific monoclonal antibodies were developed to use as an important diagnostic and epidemiological tool. These monoclonal antibodies recognize *A. castellanii, A. polyphaga, A. lenticulata*, and *A. culbertsoni*, react with formalin-fixed, paraffin-embedded infected tissues, and recognize both the trophozoite and cyst stages of the amoebae [88].

Transmission electron microscopy (TEM) also can be used as a tool to differentiate cysts and trophozoites of *Acanthamoeba* from host cells and from other amoebae, such as *B. mandrillaris* [63, 70, 89, 90]. However, this technique is expensive; sample preparation is time consuming and requires personnel with expertise.

3.2.3. Culture Methods. Isolation and culture of *Acanthamoeba* can be performed by placing brain or skin biopsy/autopsy samples on 1.5% nonnutrient agar plates covered with a layer of *Escherichia coli or Enterobacter aerogenes* [3, 7, 48, 58, 83, 91]. Depending on the density of amoebae, *Acanthamoeba* can be observed after 24 hours of inoculation. Samples, also, can be placed on tissue culture cells in the presence of antibiotics (penicillin-streptomycin and gentamicin) in which case the amoebae destroy the cell monolayer in 24 to 48 hours depending on the number of amoebae present [3, 6, 59].

3.2.4. Serology. To detect *Acanthamoeba* infections, an increase in antibody titer can be an indication of infection. For this evaluation, indirect immunofluorescence (IIF) is performed using serial dilutions of serum from an individual suspected of having Acanthamoebiasis, followed by incubation of the sera with slides containing fixed amoebae or amoebic extracts. The detection can be achieved by adding an anti-IgG antibody associated with a fluorescent label such as FITC, and antibody detection and titration can be determined by fluorescence microscopy [92]. *Acanthamoeba* infected individuals possess high antibody titers (between 1 : 256 and 1 : 1024) in serum while healthy individuals who have been exposed to *Acanthamoeba* in the environment have low antibody titers, usually not higher than 1 : 80 [82, 92–96]. Thus, IIF can be a useful tool to confirm infection in patients who are suspected of being infected with *Acanthamoeba* [96]. Western immunoblot analysis, also, has been used to demonstrate antibodies to *Acanthamoeba* in human serum [97]. An ELISA method utilizing whole fixed trophozoites rather than disrupted amoebic extracts

as the antigen source was developed and shown to be an effective tool for identifying antibodies to *Acanthamoeba* in the clinical laboratory setting [98].

3.2.5. PCR. Detection of *Acanthamoeba* can be rapidly achieved by using molecular methods. For diagnostic purposes, the detection of *Acanthamoeba* at the genus level is sufficient to recognize whether an individual is infected. Molecular identification of *Acanthamoeba* can be performed by polymerase chain reaction assays [99–101]. The complete DNA gene sequence of the 18S ribosomal RNA gene (18S rDNA) permitted the design of a reliable primer pair specific for *Acanthamoeba* genus, called JDP1 and JDP2. Use of the JDP1 (forward primer) 5′-GGCCCAGATCGTTTACCGTGAA and the JDP2 (reverse primer) 5′–TCTCACAAGCTGCTAGGGAGTCA, respectively, results in a specific amplimer of 500 bp, called ASA.S1. An advantage of this PCR assay is that it detects all known *Acanthamoeba* subgroups [100]. This PCR assay has been successfully used to detect *Acanthamoeba* in the environment as well as in patients with GAE and cutaneous acanthamoebiasis [83, 102–105]. However, DNA amplification from cysts is a troublesome task. Thus, treatment of cysts with proteinase K prior to DNA extraction has been suggested to increase the positive results by PCR assays [106].

Studies have shown that the majority of GAE and AK-causing amoebae have a specific PCR product (these amoebae are included in a subgroup called T4), when primers to amplify the small subunit rRNA genes (SSU rDNA) are used [107]. Mitochondrial DNA PCR, also, has been used successfully to detect *Acanthamoeba* from brain slices and CSF [108, 109]. Real-time PCR has been used as a fast tool to differentially identify free-living amoebae and to differentiate *Acanthamoeba* from *N. fowleri* and *B.mandrillaris* [57, 110]. A real time PCR assay developed by Rivière et al.,[110] utilizes Taqman technology to detect 18S ribosomal DNA (rDNA). This assay, based on the *Acanthamoeba* T4 genotype, does not detect other genotypes such as T10. The real time PCR assay developed by Qvarnstrom et al., [57] is a triplex assay to distinguish *Acanthamoeba* from other pathogenic FLA and is more complete in that it was designed to detect a broader range of *Acanthamoeba* genotypes. Both real time assays have been validated by testing a number of positive and negative clinical samples [111].

4. *Acanthamoeba spp.* and Amoebic Keratitis (AK)

In contrast to GAE, which is a chronic infection, AK is an acute, painful infection that can occur in immune competent individuals. This disease is related to the use of contact lenses or previous corneal trauma. When AK is not treated promptly, loss of visual acuity and blindness can occur [6, 7, 58, 59, 112–116].

4.1. Symptoms of AK. Initial symptoms of AK are not specific and include disproportional eye pain, photophobia, eye redness, and tearing, usually affecting one eye [116]. However, bilateral AK has been described, as a complication of the initial infection [116]. Using a slit-lamp, corneal inflammation leading to formation of a ring-like stromal infiltrate can be observed. Furthermore, corneal epithelial erosion, irregularities, and edema are present. The radial perineural distribution of the infiltrate (radial keratoneuritis) is characteristic for AK, similar to the type of infiltration observed in *Pseudomonas aeruginosa* keratitis [112–115, 117–120]. Later stages of infection can result in epithelial denudation and stromal necrosis. Contact lens usage and/or incidents of corneal trauma are strong indicators for AK [121–123]. Despite the clinical picture, AK is often misdiagnosed as herpes or bacterial keratitides which exhibit similar clinical symptomatology [114, 124, 125].

4.2. Diagnostic Methods

Diagnosis of AK can be undertaken by analysis of the clinical appearance of the cornea and by the demonstration of amoebae in the cornea [112, 125].

4.2.1. Microscopic Methods. The detection of *Acanthamoeba* can be achieved by analysis of a corneal biopsy. However, corneal scraping has been an efficient and noninvasive method used to isolate amoebae and to diagnose *Acanthamoeba* keratitis [126]. After scraping, samples can be smeared on glass slides. Light microscopy is an efficient means to detect *Acanthamoeba* in corneal scrapings, in biopsy samples, and in keratoplasty specimens. *Acanthamoeba* can be detected in wet-mount preparations of corneal scraping, using 10% KOH [126–132]. Moreover, impression cytology was able to remove amoebic specimens of an AK patient [132]. H & E and Giemsa stains have been used successfully to detect both trophozoites and cysts of *Acanthamoeba*. Cysts stained by Giemsa or H & E are clear, bright with polyhedric or stellate shaped cysts, while trophozoites, with the central nucleolus and vacuoles, are more difficult to detect, since they can resemble inflammatory cells [112, 115, 129, 130, 133–135]. PAS stain also has been used for detection of cysts [128, 136]. As described previously, IIF assays and immunofluorescence microscopy can be used to detect *Acanthamoeba* in brain and skin tissue, as well as in corneal specimens, contact lenses, and lens cases [134, 137, 138]. Immunoperoxidase technique is also efficient to detect *Acanthamoeba* in host tissue [121, 134]. Cysts and trophozoites are easily detected by transmission electron microscopy [133].

Fluorescent stains have been used to detect *Acanthamoeba* cysts in corneal samples. Calcofluor white is a fluorescent compound that is able to bind cellulose in the cell wall of *Acanthamoeba* cysts found in corneal scrapings and paraffin-embedded sections of corneal tissue [138, 139]. Furthermore, specimens previously stained with H & E, and other stains can be stained subsequently with calcofluor white, which is rapid and efficient but requires a fluorescence microscope. It is also important to note that in mixed fungi, *Acanthamoeba* infections, both pathogens will be stained,

since both amoebic cysts and fungi cell walls are possible targets for calcofluor white. Acridine orange, another fluorochromatic dye, has been used for rapid diagnosis of AK [78]. The use of fluorescent dyes may lead to false-positive staining patterns of cell debris [129, 130]; therefore, an experienced observer and a fluorescence microscope are necessary for a proper diagnosis.

The use of in vivo confocal microscopy to detect *Acanthamoeba* in corneal tissue at distinct depths, in real time, without any invasive procedure has been successfully used to diagnose AK [140–148]. In a recent Chicago-area outbreak, in conjunction with other methods, such as culturing or light microscopy, confocal microscopy was used to detect *Acanthamoeba* [148]. High-contrast rounded bodies, indicative of amoebic cysts, are commonly observed [143, 146, 147]. Limitations of confocal microscopy as a definitive diagnostic tool for AK have been presented [149]. However, studies have shown that when confocal microscopy was used by experienced operators, the technique is sensitive and specific for detection of *Acanthamoeba* in corneal tissue [148].

4.2.2. Culture Methods. As described previously for GAE, culture of amoebae from corneal biopsies or scrapings and washes from contact lenses or lens cases is still the most common, cheap, and efficient method to detect *Acanthamoeba*. Samples from the infected cornea are inoculated on 1.5% nonnutrient agar plates covered with *E. coli* or other nonmucoid bacteria. The plates can be incubated at 28–30 °C for days to weeks, which depends on the number of amoebae in the samples. The presence of amoebae can be checked by using an inverted microscope [48, 150].

4.3. PCR. As described previously for GAE and cutaneous lesions, PCR probes have been used, also, to confirm the presence of amoebae in corneal biopsies and scrapings, contact lenses, lens cases, lens solutions, and also in the environment [57, 100, 110, 151, 152]. Moreover, PCR is an efficient method to detect *Acanthamoeba* in tear samples [153], a completely noninvasive way to perform AK diagnostics. The sensitivity of PCR methods to diagnose AK was compared with direct microscopic examination and culture, and it was reported that PCR was more sensitive than morphological detection [154]. Two real time PCR assays have been validated to use as diagnostic tests for AK [57, 110]. However, it has been shown that a number of commonly used topical ophthalmic drugs have an inhibitory effect on PCR assays [155]. Thus, it is important that ophthalmologists rinse the eye surface extensively to remove any inhibitory substances to minimize the risk of misdiagnosis due to false negative PCR results.

5. *Balamuthia mandrillaris* and *Balamuthia* Amoebic Encephalitis (BAE)

B. mandrillaris is the only species of *Balamuthia* known to cause infection in humans or animals. *Balamuthia* was first isolated from the brain of a mandrill baboon that died at the San Diego Zoo from meningoencephalitis. The amoebae was first described as a leptomyxid amoebae but later identified and named *Balamuthia mandrillairs* [156–159]. The life cycle of *Balamuthia* consists of a trophozoite (Figure 1(c)) and a cyst state. The amoeba is found in soil, but its presence in water has been suggested based on cases of BAE occurring in animals and humans that had a history of swimming in stagnant water [160–163]. Although *Balamuthia* is considered an opportunistic pathogen, it can cause disease in both immune compromised and immune competent individuals. Infections can occur in children and adults. The incubation period of BAE is extended, and therefore the source and mode of infection have not been definitively determined. It has been suggested that the portal of entry may be via cutaneous lesions, nasal passages, or inhalation via the respiratory tract with subsequent hematogenous spread to the brain and other organs [159].

5.1. Symptoms of BAE. The encephalitis caused by *B. mandrillaris*, also, is a rare disease with nonspecific symptoms. Symptoms of BAE are chronic and include headaches, nausea, vomiting, fever, myalgia, seizures, weight loss, hemiparesis, and speech difficulties, usually associated with previous skin granulomatous lesions. The aforementioned symptoms are confusing, since they are similar to other brain infections, including tuberculosis, toxoplasmosis, cysticercosis, meningitis, and also brain tumors [7, 158, 164–169].

5.2. Diagnostic Methods

5.2.1. Imaging Methods. Brain lesions caused by *B. mandrillaris* can be detected by neuroimaging, such as CT scans and MRI [170–172]. Focal enhancing lesions, cystic lesions, edema, and hydrocephalus can be observed [172, 173]. The lesions can mimic other types of disease, such as gliomas, brain abscesses, and hematomas [7]. Thus, the lack of specificity makes the proper diagnosis by imaging methods difficult.

5.2.2. Microscopic Methods. Light microscopy can be used to detect the presence of *B. mandrillaris* in host tissue. *Balamuthia* has often been identified as *Acanthamoeba* in tissue because both amoebae cause granulomatous amoebic encephalitis. Amoebae can be observed from brain and skin biopsies and autopsies [174–176]. Unlike infection with *N. fowleri*, *B. mandrillaris* is generally not seen in CSF preparations, although it has been isolated from CSF of a 33-year-old patient that died of BAE [7, 177]. In the majority of cases described, *B. mandrillaris* was observed in brain biopsy specimens embedded in paraffin and processed for H&E [158, 170, 175, 178]. Areas of inflammation, granulomas, and the presence of trophozoites and cysts of *B. mandrillaris*, especially around blood vessels, are observed [165, 169, 179]. Trophozoites show an oval-to-round shape, with a single nucleus and a large nucleolus, while cysts are rounded with a thick wall. However, these morphological characteristics

are not adequate to differentiate *B. mandrillaris* from *Acanthamoeba spp.*, and also the ability to differentiate these amoebae from host macrophages requires expertise [7, 84].

Antibodies are crucial to the specific detection of *B. mandrillaris* in tissues. Studies have confirmed, both in biopsies and autopsies, the presence of *B. mandrillaris* in brain and skin tissue [84, 157, 170, 174, 178]. Usually, paraffin-embedded specimens are sectioned and incubated with rabbit anti-*Balamuthia* serum, and a FITC-conjugated secondary antibody against rabbit IgG is used to detect amoebae with high degree of specificity [159].

It is possible to identify *B. mandrillaris* in biopsies with the use of transmission electron microscopy (TEM). Unlike host cells, trophozoites contain a characteristic dense nucleolus, and the cytoplasm contains many vesicles. Furthermore, TEM can distinguish *B. mandrillaris* from *Acanthamoeba*, since *B. mandrillaris* possesses a tripled-walled cyst, a distinctive trait when compared to the doubled-walled cyst of *Acanthamoeba* [158, 159].

5.2.3. Culture Methods. Isolation of *B. mandrillaris* from biopsy specimens is possible; however amoebic growth is slow and also requires the use of tissue culture cells as a food source, since *B. mandrillaris* does not feed on bacteria [48, 157–159]. This is not a recommended method.

5.2.4. Serology. One of the characteristics of *B. mandrillaris* infection is the high concentration of antibodies to the amoebae in host serum [180–182]. It is possible to determine an infection in humans suspected of having BAE by the presence of antibodies against *B. mandrillaris* in their sera using enzyme-linked immunoassays (ELISAs). This methodology was used to screen a group of encephalitis patients in California, and it was shown that 7 individual samples from 290 were positive for *B. mandrillaris* [181]. Antibodies to *B. mandrillaris* do not cross-react with other amoebae [180]. Thus, ELISA technique can be useful for screening of samples containing large number of individuals. More recently, flow cytometry was successfully used to detect and quantify antibodies against *B. mandrillaris* in both healthy and diseased individuals [182].

5.2.5. PCR. Rapid and highly specific *B. mandrillaris* detection can be achieved by using polymerase chain reaction methodology. *B. mandrillaris* is a well-defined phylogenetic species, with no SSU rDNA sequence variation between isolates and low levels of mitochondrial DNA variation. Booton and coworkers [183, 184] developed specific primers from a portion of the mitochondrial rRNA gene (rns). The PCR reaction of these primers resulted in a 1075 bp product, where the product is specific for *B. mandrillaris* and not for *Acanthamoeba*. Detection of *B. mandrillaris* was performed successfully on clinical samples using these primers, both in brain tissue, and CSF [177, 185, 186]. The sensitivity of the PCR detection was tested, and it was observed that 0.2 amoebae were enough for amplification, since mitochondrial DNA had been used [186], indicating that the employment of PCR was an efficient diagnostic tool. The efficacy of PCR method was compared with IIF as a diagnostic tool on archival brain tissue and a high degree of agreement was reported [109]. By using distinct primers, a multiplex real time PCR to detect *B. mandrillaris* was developed, with rapid test completion time and high sensitivity, detecting one amoebae per sample [57]. This multiplex assay has been validated and is recommended for detection of FLA in clinical samples [111]. More recently, a real time PCR assay was developed for *B. mandrillaris*, targeting the RNAase P gene [187]. Sensitivity and specificity were observed, with the probes able to detect small amounts of amoebic DNA.

6. *Sappinia pedata* and *Sappinia* Amoebic Encephalitis (SAE)

The free-living amoeba, *Sappinia*, a newly discovered human pathogen of the central nervous system (CNS), can cause amoebic encephalitis in humans [9, 10]. There are two species of *Sappinia*, *S. pedata* and *S. diploidea*. *Sappinia* has a worldwide distribution and has been isolated from elk and buffalo feces, soil contaminated with bovine feces, decaying ground plant litter and fresh water [188, 189]. The life cycle of *Sappinia* consists of two stages, a trophozoite and a cyst [190]. The first and only case of amoebic encephalitis caused by *Sappinia sp.* occurred in a previously healthy immune competent adult male who survived the infection. The incubation period and the route of infection are unknown but thought to be by inhalation through the nasopharynx or by hematogenous spread to the brain [9]. The amoeba that caused this encephalitis was originally identified as *S. diploidea* but has now been identified as *S. pedata* using molecular techniques to identify the amoeba (191,192). It is not known whether the other species (*S. diploidea*) can cause infections in human or animal hosts.

6.1. Symptoms of SAE. In the single case of *Sappinia* amoebic encephalitis that has been reported, a sinus infection occurred prior to the onset of symptoms. The individual developed nausea, vomiting, bifrontal headache, photophobia, and blurry vision. A loss of consciousness occurred for a brief period [7, 9, 10, 191]. A successful outcome in this patient was reported after surgical excision of a tumor-like mass in the brain and treatment using azithromycin, intravenous pentamidine, itraconazole, and flucytosine [10].

6.2. Diagnosis. A solitary tumor-like mass without an abscess wall in the brain can be observed by MRI for *Sappinia* encephalitis. The excised mass or biopsy tissue can be fixed and embedded in paraffin. Brain sections stained with H & E may exhibit necrotizing hemorrhagic inflammation containing amoebae. Eosinophils and granuloma formation are lacking. *Sappinia* amoebae can be distinguished from other FLA by the presence of a distinctive double nucleus in which the 2 nuclei are closely apposed with a central flattening [188, 189]. Two nucleoli are found in the double nucleus. These structures can be observed in paraffin sections stained with H & E, Giemsa, or Periodic Acid Schiff. The amoebae are readily observed in cryostat sections stained with H & E

[7, 10, 191]. Brain tissue can be fixed in glutaraldehyde and prepared for transmission electron microscopy to visualize the amoebae in tissue.

6.3. PCR. *Sappinia pedata* and *S. diploidea* can be identified and distinguished by amplification of the SSU rDNA using universal eukaryotic SSU primers followed by an Internal Transcribed Spacer PCR assay. Primers used in the ITS PCR assay are ITS1–P1F5′-GTA ACA AGG TATCCG TAG GTG AAC C-3′ and ITS2–P4R: 5′TCC TCC GCT TAT TGA TAT GC—3′ [190]. The amoebae originally identified as *S. diploidea* in the single reported case of *Sappinia* amoebic encephalitis was later identified as *S. pedata* using newly developed real-time PCR assays based on 18S rRNA gene sequences [191]. The assay specific for *Sappinia* can be incorporated into the multiplex PCR assay described by Qvarnstrom et al., [57] that distinguish *Acanthamoeba, B. mandrillaris*, and *N. fowleri* for simultaneous detection of the four genera of FLA that cause infections in humans [191].

6.4. Culture. *Sappinia* can be cultured on nonnutrient agar coated with bacteria and on tissue culture cells [7].

7. Conclusion: The Importance of Early Diagnosis

Although infections with FLA are considered rare, there has been an increase in the number of reported cases in recent years. CNS infections caused by pathogenic free-living amoebae (FLA) are for the most part fatal. Corneal infection caused by *Acanthamoeba* can lead to blindness or vision impairment in AK. Recently, it has been shown that there is a greater chance of cure if these infections are detected early and treated timely. However, a fast and efficient diagnosis depends on two variables: the familiarity of practitioner with the symptomatology and treatment of FLA infections, and also the appropriate material to process for a fast and definitive diagnosis. At the present time, it is not known whether FLA infections are rare because they are underreported or due to misdiagnosis. Most infections have been diagnosed postmortem. It is not possible to determine the rarity of these infections, since these infections are relatively unknown, and in many cases autopsies are not performed.

The number of contact lenses users around the world has increased, and consequently AK outbreaks have been more frequent, which requires a faster public health response. GAE and cutaneous acanthamoebiasis can be one of the most frequent secondary diseases in AIDS-HIV patients and in other immunosupressed individuals, since *Acanthamoeba* is found throughout the world. The dramatic increase in BAE could reflect the potential of this infection to be a common worldwide disease. The increased incidence of PAM caused by *N. fowleri* in recent years may be due to greater recreational activity in warm water lakes and parks. PAM could be avoided with greater awareness of the disease, using public education programs, closing of swimming pools that are improperly chlorinated, and wearing nose clips while diving and engaging in water activities when the nose is submerged. The recent finding of *S. pedata* as a pathogen of the CNS in humans suggests that other free-living amoebae, not yet identified, may be causative of amoebic of amoebic encephalitis.

A more rapid clinical response could provide higher survival rates since treatment is available. Thus, fast and efficient diagnostic tests are pivotal for treatment success. The availability of PCR probes is a promising procedure to obtain fast and specific, confirmatory diagnosis of PAM, GAE, AK, BAE, and SAE in a timely fashion for efficient treatment. To this end, a multiplex PCR assay is available and has been validated as an important and specific tool to identify, *N. fowleri, Acanthamoeba spp.,* and *B. mandrillaris* in clinical specimens [57, 111] but only a few reference laboratories are capable of doing diagnostic detection of FLA [191]. Additionally, a PCR assay has been developed to detect *Sappinia* in clinical samples [191]. In conclusion, the recognition of these diseases and specific diagnostic tests could lead to earlier treatment and diminish the severity and lethality of these infections in the human host.

Acknowledgment

This review is dedicated to the memory of Dr. Frederick L. Schuster, a pioneer of the study of free-living amoebae, who published significant contributions in this field in the last 35 years.

References

[1] M. Fowler and R. Carter, "Acute pyogenic meningitis probably due to *Acanthamoeba sp.*: a preliminary report," *The British Medical Journal*, vol. 2, pp. 740–742, 1965.

[2] C. G. Butt, "Primary amebic meningoencephalitis," *The New England Journal of Medicine*, vol. 274, no. 26, pp. 1473–1476, 1966.

[3] A. J. Martinez, *Free-Living Amebas: Natural History, Prevevtion, Diagnosis, Pathology, and Treatment of Disease*, CRC Press, Boca Raton, Fla, USA, 1985.

[4] A. J. Martinez, "Free-living amebas: infection of the central nervous system," *Mount Sinai Journal of Medicine*, vol. 60, no. 4, pp. 271–278, 1993.

[5] A. J. Martinez and G. S. Visvesvara, "Free-living, amphizoic and opportunistic amebas," *Brain Pathology*, vol. 7, no. 1, pp. 583–598, 1997.

[6] F. Marciano-Cabral and G. Cabral, "*Acanthamoeba* spp. as agents of disease in humans," *Clinical Microbiology Reviews*, vol. 16, no. 2, pp. 273–307, 2003.

[7] G. S. Visvesvara, H. Moura, and F. L. Schuster, "Pathogenic and opportunistic free-living amoebae: *Acanthamoeba* spp., *Balamuthia mandrillaris, Naegleria fowleri*, and *Sappinia diploidea*," *FEMS Immunology and Medical Microbiology*, vol. 50, no. 1, pp. 1–26, 2007.

[8] F. L. Schuster and G. S. Visvesvara, "Free-living amoebae as opportunistic and non-opportunistic pathogens of humans and animals," *International Journal for Parasitology*, vol. 34, no. 9, pp. 1001–1027, 2004.

[9] B. B. Gelman, S. J. Rauf, R. Nader, et al., "Amoebic encephalitis due to *Sappinia diploidea*," *Journal of the American Medical Association*, vol. 285, no. 19, pp. 2450–2451, 2001.

[10] B. B. Gelman, V. Popov, G. Chaljub, et al., "Neuropathological and ultrastructural features of amebic encephalitis caused by *Sappinia diploidea*," *Journal of Neuropathology and Experimental Neurology*, vol. 62, no. 10, pp. 990–998, 2003.

[11] K. Anderson and A. Jamieson, "Primary amoebic meningoencephalitis," *The Lancet*, vol. 1, no. 7756, pp. 902–903, 1972.

[12] F. Marciano-Cabral, R. MacLean, A. Mensah, and L. LaPat-Polasko, "Identification of *Naegleria fowleri* in domestic water sources by nested PCR," *Applied and Environmental Microbiology*, vol. 69, no. 10, pp. 5864–5869, 2003.

[13] B. Blair, P. Sarkar, K. R. Bright, F. Marciano-Cabral, and C. P. Gerba, "*Naegleria fowleri* in well water," *Emerging Infectious Diseases*, vol. 14, no. 9, pp. 1499–1501, 2008.

[14] M. E. Shoff, A. Rogerson, K. Kessler, S. Schatz, and D. V. Seal, "Prevalence of *Acanthamoeba* and other naked amoebae in South Florida domestic water," *Journal of Water and Health*, vol. 6, no. 1, pp. 99–104, 2008.

[15] T. J. Rowbotham, "Current views on the relationships between amoebae, *Legionellae* and man," *Israel Journal of Medical Sciences*, vol. 22, no. 9, pp. 678–689, 1986.

[16] J. M. Barbaree, B. S. Fields, J. C. Feeley, G. W. Gorman, and W. T. Martin, "Isolation of protozoa from water associated with legionellosis outbreak and demonstration of intracellular multiplication of *Legionella pneumophila*," *Applied and Environmental Microbiology*, vol. 51, no. 2, pp. 422–424, 1986.

[17] T. R. Fritsche, R. K. Gautom, S. Seyedirashti, D. L. Bergeron, and T. D. Lindquist, "Occurrence of bacterial endosymbionts in *Acanthamoeba spp.* isolated from corneal and environmental specimens and contact lenses," *Journal of Clinical Microbiology*, vol. 31, no. 5, pp. 1122–1126, 1993.

[18] R. Michel, H. Burghardt, and H. Bergmann, "*Acanthamoeba*, naturally intracellularly infected with *Pseudomonas aeruginosa*, after their isolation from a microbiologically contaminated drinking water system in a hospital," *Zentralblatt für Hygiene und Umweltmedizin*, vol. 196, no. 6, pp. 532–544, 1995.

[19] T. J. Marrie, D. Raoult, B. La Scola, R. J. Birtles, and E. de Carolis, "*Legionella*-like and other amoebal pathogens as agents of community-acquired pneumonia," *Emerging Infectious Diseases*, vol. 7, no. 6, pp. 1026–1029, 2001.

[20] F. Marciano-Cabral, K. Han, E. Powell, T. Ferguson, and G. Cabral, "Interaction of an *Acanthamoeba* human isolate harboring bacteria with murine peritoneal macrophages," *Journal of Eukaryotic Microbiology*, vol. 50, pp. 516–519, 2003.

[21] J. Barker and M. R. W. Brown, "Trojan Horses of the microbial world: protozoa and the survival of bacterial pathogens in the environment," *Microbiology*, vol. 140, no. 6, pp. 1253–1259, 1994.

[22] F. Marciano-Cabral, "Introductory remarks: bacterial endosymbionts or pathogens of free-living amebae," *Journal of Eukaryotic Microbiology*, vol. 51, no. 5, pp. 497–501, 2004.

[23] C. H. King, E. B. Shotts Jr., R. E. Wooley, and K. G. Porter, "Survival of coliforms and bacterial pathogens within protozoa during chlorination," *Applied and Environmental Microbiology*, vol. 54, no. 12, pp. 3023–3033, 1988.

[24] J. D. Cirillo, S. Falkow, L. S. Tompkins, and L. E. Bermudez, "Interaction of *Mycobacterium avium* with environmental amoebae enhances virulence," *Infection and Immunity*, vol. 65, no. 9, pp. 3759–3767, 1997.

[25] E. C. Miltner and L. E. Bermudez, "*Mycobacterium avium* grown in *Acanthamoeba castellanii* is protected from the effects of antimicrobials," *Antimicrobial Agents and Chemotherapy*, vol. 44, no. 7, pp. 1990–1994, 2000.

[26] M. Molmeret, M. Horn, M. Wagner, M. Santic, and Y. Abu Kwaik, "Amoebae as training grounds for intracellular bacterial pathogens," *Applied and Environmental Microbiology*, vol. 71, no. 1, pp. 20–28, 2005.

[27] F. Marciano-Cabral and G. Cabral, "*Naegleria fowleri*," in *Emerging Protozoan Pathogens*, pp. 119–141, Taylor and Francis, New York, NY, USA, 2008.

[28] L. Cerva and K. Novak, "Amoebic meningoencephalitis: sixteen fatalities," *Science*, vol. 160, no. 3823, p. 92, 1968.

[29] P. Ma, G. S. Visvesvara, A. J. Martinez, F. H. Theodore, P.-M. Daggett, and T. K. Sawyer, "*Naegleria* and *Acanthamoeba* infections: review," *Reviews of Infectious Diseases*, vol. 12, no. 3, pp. 490–513, 1990.

[30] J. S. Seidel, P. Harmatz, G. S. Visvesvara, A. Cohen, J. Edwards, and J. Turner, "Successful treatment of primary amebic meningoencephalitis," *The New England Journal of Medicine*, vol. 306, no. 6, pp. 346–348, 1982.

[31] A. Wang, R. Kay, W. S. Poon, and H. K. Ng, "Successful treatment of amoebic meningoencephalitis in a Chinese living in Hong Kong," *Clinical Neurology and Neurosurgery*, vol. 95, no. 3, pp. 249–252, 1993.

[32] R. L. Brown, "Successful treatment of primary amebic meningoencephalitis," *Archives of Internal Medicine*, vol. 151, no. 6, pp. 1201–1202, 1991.

[33] S. C. Parija and S. R. Jayakeerthee, "*Naegleria fowleri*: a free living amoeba of emerging medical importance," *Journal of Communicable Diseases*, vol. 31, no. 3, pp. 153–159, 1999.

[34] S. N. Singh, A. K. Patwari, R. Dutta, N. Taneja, and V. K. Anand, "*Naegleria* meningitis," *Indian Journal of Pediatrics*, vol. 35, no. 10, pp. 1012–1015, 1998.

[35] J. Vargas-Zepeda, A. V. Gomez-Alcala, J. A. Vasquez-Morales, L. Licea-Amaya, J. F. de Jonckheere, and F. Lares-Villa, "Successful treatment of *Naegleria fowleri* meningoencephalitis by using intravenous amphotericin B, fluconazole and rifampicin," *Archives of Medical Research*, vol. 36, no. 1, pp. 83–86, 2005.

[36] S. Shenoy, G. Wilson, H. V. Prashanth, K. Vidyalakshmi, B. Dhanashree, and R. Bharath, "Primary meningoencephalitis by *Naegleria fowleri*: first reported case from Mangalore, South India," *Journal of Clinical Microbiology*, vol. 40, no. 1, pp. 309–310, 2002.

[37] R. T. Cursons, J. W. Sleigh, D. Hood, and D. Pullon, "A case of primary amoebic meningoencephalitis: North Island, New Zealand," *New Zealand Medical Journal*, vol. 116, no. 1187, p. U712, 2003.

[38] N. K. Shrestha, B. Khanal, S. K. Sharma, S. S. Dhakal, and R. Kanungo, "Primary amoebic meningoencephalitis in a patient with systemic lupus erythematosus," *Scandinavian Journal of Infectious Diseases*, vol. 35, no. 8, pp. 514–516, 2003.

[39] M. Poungvarin and P. Jariya, "The fifth nonlethal case of primary amoebic meningoencephalitis," *Journal of the Medical Association of Thailand*, vol. 74, no. 2, pp. 112–115, 1991.

[40] "Primary amebic meningoencephalitis—Arizona, Florida, and Texas, 2007," *Morbidity and Mortality Weekly Report*, vol. 57, no. 21, pp. 573–577, 2008.

[41] D. J. Schumacher, R. D. Tien, and K. Lane, "Neuroimaging findings in rare amebic infections of the central nervous system," *American Journal of Neuroradiology*, vol. 16, pp. 930–935, 1995.

[42] D. D. Kidney and S. H. Kim, "CNS infections with free-living amebas: neuroimaging findings," *American Journal of Roentgenology*, vol. 171, no. 3, pp. 809–812, 1998.

[43] P. Singh, R. Kochhar, R. K. Vashishta, et al., "Amebic meningoencephalitis: spectrum of imaging findings," *American Journal of Neuroradiology*, vol. 27, no. 6, pp. 1217–1221, 2006.

[44] A. J. Martinez, J. G. dos Santos, E. C. Nelson, W. P. Stamm, and E. Willaert, "Primary amebic meningoencephalitis," in *Pathology Annual*, S. C. Sommers and P. P. Rosen, Eds., vol. 12, p. 225, Appleton-Century-Crofts, New York, NY, USA, 1977.

[45] A. J. Martinez and G. S. Visvesvara, "Laboratory diagnosis of pathogenic free-living amoebas: *Naegleria, Acanthamoeba*, and *Leptomyxid*," *Clinics in Laboratory Medicine*, vol. 11, no. 4, pp. 861–872, 1991.

[46] O. Sparagano, E. Drouet, R. Brebant, E. Manet, G.-A. Denoyel, and P. Pernin, "Use of monoclonal antibodies to distinguish pathogenic *Naegleria fowleri* (cysts, trophozoites, or flagellate forms) from other *Naegleria* species," *Journal of Clinical Microbiology*, vol. 31, no. 10, pp. 2758–2763, 1993.

[47] F. L. Reveiller, M.-P. Varenne, C. Pougnard, et al., "An enzyme-linked immunosorbent assay (ELISA) for the identification of *Naegleria fowleri* in environmental water samples," *Journal of Eukaryotic Microbiology*, vol. 50, no. 2, pp. 109–113, 2003.

[48] F. L. Schuster, "Cultivation of pathogenic and opportunistic free-living amebas," *Clinical Microbiology Reviews*, vol. 15, no. 3, pp. 342–354, 2002.

[49] F. Marciano-Cabral, M. L. Cline, and S. G. Bradley, "Specificity of antibodies from human sera for *Naegleria* species," *Journal of Clinical Microbiology*, vol. 25, no. 4, pp. 692–697, 1987.

[50] F. Marciano-Cabral and G. A. Cabral, "The immune response to *Naegleria fowleri* amebae and pathogenesis of infection," *FEMS Immunology and Medical Microbiology*, vol. 51, no. 2, pp. 243–259, 2007.

[51] M. Pelandakis, S. Serre, and P. Pernin, "Analysis of the 5.8S rRNA gene and the internal transcribed spacers in *Naegleria spp.* and in *N. fowleri*," *Journal of Eukaryotic Microbiology*, vol. 47, no. 2, pp. 116–121, 2000.

[52] M. Pelandakis and P. Pernin, "Use of multiplex PCR and PCR restriction enzyme analysis for detection and exploration of the variability in the free-living amoeba *Naegleria* in the environment," *Applied and Environmental Microbiology*, vol. 68, no. 4, pp. 2061–2065, 2002.

[53] F. L. Reveiller, P.-A. Cabanes, and F. Marciano-Cabral, "Development of a nested PCR assay to detect the pathogenic free-living amoeba *Naegleria fowleri*," *Parasitology Research*, vol. 88, no. 5, pp. 443–450, 2002.

[54] B. S. Robinson, P. T. Monis, and P. J. Dobson, "Rapid, sensitive, and discriminating identification of *Naegleria spp.* by real-time PCR and melting-curve analysis," *Applied and Environmental Microbiology*, vol. 72, no. 9, pp. 5857–5863, 2006.

[55] J. Behets, P. Declerck, Y. Delaedt, L. Verelst, and F. Ollevier, "A duplex real-time PCR assay for the quantitative detection of *Naegleria fowleri* in water samples," *Water Research*, vol. 41, no. 1, pp. 118–126, 2007.

[56] M. Schild, C. Gianinazzi, B. Gottstein, and N. Muller, "PCR-based diagnosis of *Naegleria* sp. infection in formalin-fixed and paraffin-embedded brain sections," *Journal of Clinical Microbiology*, vol. 45, no. 2, pp. 564–567, 2007.

[57] Y. Qvarnstrom, G. S. Visvesvara, R. Sriram, and A. J. da Silva, "Multiplex real-time PCR assay for simultaneous detection of *Acanthamoeba* spp., *Balamuthia mandrillaris*, and *Naegleria fowleri*," *Journal of Clinical Microbiology*, vol. 44, no. 10, pp. 3589–3595, 2006.

[58] N. A. Khan, "*Acanthamoeba*: biology and increasing importance in human health," *FEMS Microbiology Reviews*, vol. 30, no. 4, pp. 564–595, 2006.

[59] F. Marciano-Cabral, R. Puffenbarger, and G. A. Cabral, "The increasing importance of *Acanthamoeba* infections," *Journal of Eukaryotic Microbiology*, vol. 47, no. 1, pp. 29–36, 2000.

[60] S. J. Hunt, S. L. Reed, W. C. Mathews, and B. Torian, "Cutaneous *Acanthamoeba* infection in the acquired immunodeficiency syndrome: response to multidrug therapy," *Cutis*, vol. 56, no. 5, pp. 285–287, 1995.

[61] G. J. Murakawa, T. McCalmont, J. Altman, et al., "Disseminated acanthamebiasis in patients with AIDS: a report of five cases and a review of the literature," *Archives of Dermatology*, vol. 131, no. 11, pp. 1291–1296, 1995.

[62] S. Levine, A. E. Goldstein, M. Dahdouh, P. Blank, C. Hoffman, and C. A. Gropper, "Cutaneous *Acanthamoeba* in a patient with AIDS: a case study with a review of new therapy; quiz 386," *Cutis*, vol. 67, no. 5, pp. 377–380, 2001.

[63] L. P. May, G. S. Sidhu, and M. R. Buchness, "Diagnosis of *Acanthamoeba* infection by cutaneous manifestations in a man seropositive to HIV," *Journal of the American Academy of Dermatology*, vol. 26, no. 2, pp. 352–355, 1992.

[64] J. Helton, M. Loveless, and C. R. White Jr., "Cutaneous *Acanthamoeba* infection associated with leukocytoclastic vasculitis in an AIDS patient," *American Journal of Dermatopathology*, vol. 15, no. 2, pp. 146–149, 1993.

[65] P. H. Chandrasekar, P. S. Nandi, M. R. Fairfax, and L. R. Crane, "Cutaneous infections due to *Acanthamoeba* in patients with acquired immunodeficiency syndrome," *Archives of Internal Medicine*, vol. 157, no. 5, pp. 569–572, 1997.

[66] M. S. Torno Jr., R. Babapour, A. Gurevitch, and M. D. Witt, "Cutaneous acanthamoebiasis in AIDS," *Journal of the American Academy of Dermatology*, vol. 42, no. 2, pp. 351–354, 2000.

[67] A. G. Duarte, F. Sattar, B. Granwehr, J. F. Aronson, Z. Wang, and S. Lick, "Disseminated acanthamoebiasis after lung transplantation," *Journal of Heart and Lung Transplantation*, vol. 25, no. 2, pp. 237–240, 2006.

[68] A. J. Martinez, C. A. García, M. Halks-Miller, and R. Arce-Vela, "Granulomatous amebic encephalitis presenting as a cerebral mass lesion," *Acta Neuropathologica*, vol. 51, no. 2, pp. 85–91, 1980.

[69] D. O. Matson, E. Rouah, R. T. Lee, D. Armstrong, J. T. Parke, and C. J. Baker, "Acanthameba meningoencephalitis masquerading as neurocysticercosis," *Pediatric Infectious Disease Journal*, vol. 7, no. 2, pp. 121–124, 1988.

[70] J. P. Sison, C. A. Kemper, M. Loveless, D. McShane, G. S. Visvesvara, and S. C. Deresinski, "Disseminated *Acanthamoeba* infection in patients with AIDS: case reports and review," *Clinical Infectious Diseases*, vol. 20, no. 5, pp. 1207–1216, 1995.

[71] S. K. Ofori-Kwakye, D. G. Sidebottom, J. Herbert, E. G. Fischer, and G. S. Visvesvara, "Granulomatous brain tumor caused by *Acanthamoeba*," *Journal of Neurosurgery*, vol. 64, no. 3, pp. 505–509, 1986.

[72] J. J. Sell, F. W. Rupp, and W. W. Orrison Jr., "Granulomatous amebic encephalitis caused by *Acanthamoeba*," *Neuroradiology*, vol. 39, no. 6, pp. 434–436, 1997.

[73] H. A. R. Gardner, A. J. Martinez, G. S. Visvesvara, and A. Sotrel, "Granulomatous amebic encephalitis in an AIDS patient," *Neurology*, vol. 41, no. 12, pp. 1993–1995, 1991.

[74] C. G. Culbertson and K. Harper, "Pathogenic free-living amebae. Immunocytologic demonstration and species identification," *American Journal of Tropical Medicine and Hygiene*, vol. 33, no. 5, pp. 851–856, 1984.

[75] B. Tan, C. M. Weldon-Linne, D. P. Rhone, C. L. Penning, and G. S. Visvesvara, "*Acanthamoeba* infection presenting as skin lesions in patients with the acquired immunodeficiency syndrome," *Archives of Pathology and Laboratory Medicine*, vol. 117, no. 10, pp. 1043–1046, 1993.

[76] M. S. Martinez, G. Gonzalez-Mediero, P. Santiago, et al., "Granulomatous amebic encephalitis in a patient with AIDS: isolation of *Acanthamoeba* sp. group II from brain tissue and successful treatment with sulfadiazine and fluconazole," *Journal of Clinical Microbiology*, vol. 38, no. 10, pp. 3892–3895, 2000.

[77] R. Cursons, "A simple staining method for the detection of amoebae," *New Zealand Medical Journal*, vol. 94, no. 698, p. 471, 1981.

[78] T.-W. Hahn, T. P. O'Brien, W.-J. Sah, and J.-H. Kim, "Acridine orange staining for rapid diagnosis of *Acanthamoeba* keratitis," *Japanese Journal of Ophthalmology*, vol. 42, no. 2, pp. 108–114, 1998.

[79] C. W. B. Walker, "*Acanthamoeba*: ecology, pathogenicity and laboratory detection," *British Journal of Biomedical Science*, vol. 53, no. 2, pp. 146–151, 1996.

[80] F. Petry, M. Torzewski, J. Bohl, et al., "Early diagnosis of *Acanthamoeba* infection during routine cytological examination of cerebrospinal fluid," *Journal of Clinical Microbiology*, vol. 44, no. 5, pp. 1903–1904, 2006.

[81] J. P. Steinberg, R. L. Galindo, E. S. Kraus, and K. G. Ghanem, "Disseminated acanthamebiasis in a renal transplant recipient with osteomyelitis and cutaneous lesions: case report and literature review," *Clinical Infectious Diseases*, vol. 35, no. 5, pp. e43–e49, 2002.

[82] E. Willaert, A. R. Stevens, and G. R. Healy, "Retrospective identification of *Acanthamoeba culbertsoni* in a case of amoebic meningoencephalitis," *Journal of Clinical Pathology*, vol. 31, no. 8, pp. 717–720, 1978.

[83] M. S. McKellar, L. R. Mehta, J. E. Greenlee, et al., "Fatal granulomatous *Acanthamoeba* encephalitis mimicking a stroke, diagnosed by correlation of results of sequential magnetic resonance imaging, biopsy, in vitro culture, immunofluorescence analysis, and molecular analysis," *Journal of Clinical Microbiology*, vol. 44, no. 11, pp. 4265–4269, 2006.

[84] J. Guarner, J. Bartlett, W.-J. Shieh, C. D. Paddock, G. S. Visvesvara, and S. R. Zaki, "Histopathologic spectrum and immunohistochemical diagnosis of amebic meningoencephalitis," *Modern Pathology*, vol. 20, no. 12, pp. 1230–1237, 2007.

[85] J. M. Feingold, J. Abraham, S. Bilgrami, et al., "*Acanthamoeba* meningoencephalitis following autologous peripheral stem cell transplantation," *Bone Marrow Transplantation*, vol. 22, no. 3, pp. 297–300, 1998.

[86] K. C. Bloch and F. L. Schuster, "Inability to make a premortem diagnosis of *Acanthamoeba* species infection in a patient with fatal granulomatous amebic encephalitis," *Journal of Clinical Microbiology*, vol. 43, no. 6, pp. 3003–3006, 2005.

[87] C. G. Shirwadkar, R. Samant, M. Sankhe, et al., "*Acanthamoeba* encephalitis in patient with systemic lupus, India," *Emerging Infectious Diseases*, vol. 12, no. 6, pp. 984–986, 2006.

[88] M. L. Turner, E. J. Cockerell, H. M. Brereton, et al., "Antigens of selected *Acanthamoeba* species detected with monoclonal antibodies," *International Journal for Parasitology*, vol. 35, no. 9, pp. 981–990, 2005.

[89] C. A. Wiley, R. E. Safrin, C. E. Davis, et al., "*Acanthamoeba* meningoencephalitis in a patient with AIDS," *Journal of Infectious Diseases*, vol. 155, no. 1, pp. 130–133, 1987.

[90] S. E. Vernon, B. C. Acar, S. M. Pham, and D. Fertel, "*Acanthamoeba* infection in lung transplantation: report of a case and review of the literature," *Transplant Infectious Disease*, vol. 7, no. 3-4, pp. 154–157, 2005.

[91] G. S. Visvesvara, D. B. Jones, and N. M. Robinson, "Isolation, identification, and biological characterization of *Acanthamoeba polyphaga* from a human eye," *American Journal of Tropical Medicine and Hygiene*, vol. 24, no. 5, pp. 784–790, 1975.

[92] L. Cerva, "*Acanthamoeba culbertsoni* and *Naegleria fowleri*: occurrence of antibodies in man," *Journal of Hygiene Epidemiology Microbiology and Immunology*, vol. 33, no. 1, pp. 99–103, 1989.

[93] R. T. M. Cursons, T. J. Brown, E. A. Keys, K. M. Moriarty, and D. Till, "Immunity to pathogenic free-living amoebae: role of humoral antibody," *Infection and Immunity*, vol. 29, no. 2, pp. 401–407, 1980.

[94] C. A. Slater, J. Z. Sickel, G. S. Visvesvara, R. C. Pabico, and A. A. Gaspari, "Brief report: successful treatment of disseminated *Acanthamoeba* infection in an immunocompromised patient," *The New England Journal of Medicine*, vol. 331, no. 2, pp. 85–87, 1994.

[95] N. Brindley, A. Matin, and N. A. Khan, "*Acanthamoeba castellanii*: high antibody prevalence in racially and ethnically diverse populations," *Experimental Parasitology*, vol. 121, no. 3, pp. 254–256, 2009.

[96] F. L. Schuster, S. Honarmand, G. S. Visvesvara, and C. A. Glaser, "Detection of antibodies against free-living amoebae *Balamuthia mandrillaris* and *Acanthamoeba* species in a population of patients with encephalitis," *Clinical Infectious Diseases*, vol. 42, no. 9, pp. 1260–1265, 2006.

[97] E. L. Powell, A. L. Newsome, S. D. Allen, and G. B. Knudson, "Identification of antigens of pathogenic free-living amoebae by protein immunoblotting with rabbit immune and human sera," *Clinical and Diagnostic Laboratory Immunology*, vol. 1, no. 5, pp. 493–499, 1994.

[98] C. L. Chappell, J. A. Wright, M. Coletta, and A. L. Newsome, "Standardized method of measuring *Acanthamoeba* antibodies in sera from healthy human subjects," *Clinical and Diagnostic Laboratory Immunology*, vol. 8, no. 4, pp. 724–730, 2001.

[99] M. H. Vodkin, D. K. Howe, G. S. Visvesvara, and G. L. McLaughlin, "Identification of *Acanthamoeba* at the generic and specific levels using the polymerase chain reaction," *Journal of Protozoology*, vol. 39, no. 3, pp. 378–385, 1992.

[100] J. M. Schroeder, G. C. Booton, J. Hay, et al., "Use of subgenic 18S ribosomal DNA PCR and sequencing for genus and genotype identification of *Acanthamoebae* from humans with keratitis and from sewage sludge," *Journal of Clinical Microbiology*, vol. 39, no. 5, pp. 1903–1911, 2001.

[101] N. A. Khan, E. L. Jarroll, and T. A. Paget, "*Acanthamoeba* can be differentiated by the polymerase chain reaction and simple plating assays," *Current Microbiology*, vol. 43, no. 3, pp. 204–208, 2001.

[102] J. Lorenzo-Morales, J. F. Lindo, E. Martinez, et al., "Pathogenic *Acanthamoeba* strains from water sources in

Jamaica, West Indies," *Annals of Tropical Medicine and Parasitology*, vol. 99, no. 8, pp. 751–758, 2005.

[103] R. C. MacLean, N. Hafez, S. Tripathi, C. G. Childress, N. R. Ghatak, and F. Marciano-Cabral, "Identification of *Acanthamoeba sp*. in paraffin-embedded CNS tissue from an HIV+ individual by PCR," *Diagnostic Microbiology and Infectious Disease*, vol. 57, no. 3, pp. 289–294, 2007.

[104] W. Meersseman, K. Lagrou, R. Sciot, et al., "Rapidly fatal *Acanthamoeba* encephalitis and treatment of cryoglobulinemia," *Emerging Infectious Diseases*, vol. 13, no. 3, pp. 469–471, 2007.

[105] J. Walochnik, A. Aichelburg, O. Assadian, et al., "Granulomatous amoebic encephalitis caused by *Acanthamoeba* amoebae of genotype T2 in a human immunodeficiency virus-negative patient," *Journal of Clinical Microbiology*, vol. 46, no. 1, pp. 338–340, 2008.

[106] P. Goldschmidt, S. Degorge, C. Saint-Jean, et al., "Resistance of *Acanthamoeba* to classic DNA extraction methods used for the diagnosis of corneal infections," *British Journal of Ophthalmology*, vol. 92, no. 1, pp. 112–115, 2008.

[107] G. C. Booton, G. S. Visvesvara, T. J. Byers, D. J. Kelly, and P. A. Fuerst, "Identification and distribution of *Acanthamoeba* species genotypes associated with nonkeratitis infections," *Journal of Clinical Microbiology*, vol. 43, no. 4, pp. 1689–1693, 2005.

[108] S. Yagi, F. L. Schuster, and K. Bloch, "Demonstration of presence of *Acanthamoeba* mitochondrial DNA in brain tissue and cerebrospinal fluid by PCR in samples from a patient who died of granulomatous amebic encephalitis," *Journal of Clinical Microbiology*, vol. 45, no. 6, pp. 2090–2091, 2007.

[109] S. Yagi, F. L. Schuster, and G. S. Visvesvara, "Demonstration of *Balamuthia* and *Acanthamoeba* mitochondrial DNA in sectioned archival brain and other tissues by the polymerase chain reaction," *Parasitology Research*, vol. 102, no. 3, pp. 491–497, 2008.

[110] D. Rivière, F. M. Szczebara, J.-M. Berjeaud, J. Frère, and Y. Héchard, "Development of a real-time PCR assay for quantification of *Acanthamoeba* trophozoites and cysts," *Journal of Microbiological Methods*, vol. 64, no. 1, pp. 78–83, 2006.

[111] P. P. Thompson, R. P. Kowalski, R. M. Q. Shanks, and Y. J. Gordon, "Validation of real-time PCR for laboratory diagnosis of *Acanthamoeba* keratitis," *Journal of Clinical Microbiology*, vol. 46, no. 10, pp. 3232–3236, 2008.

[112] C. D. Illingworth and S. D. Cook, "*Acanthamoeba* keratitis," *Survey of Ophthalmology*, vol. 42, no. 6, pp. 493–508, 1998.

[113] N. Thebpatiphat, K. M. Hammersmith, F. N. Rocha, et al., "*Acanthamoeba* keratitis: a parasite on the rise," *Cornea*, vol. 26, no. 6, pp. 701–706, 2007.

[114] D. W. Clarke and J. Y. Niederkorn, "The pathophysiology of Acanthamoeba keratitis," *Trends in Parasitology*, vol. 22, no. 4, pp. 175–180, 2006.

[115] S. T. Awwad, W. M. Petroll, J. P. McCulley, and H. D. Cavanagh, "Updates in *Acanthamoeba* keratitis," *Eye and Contact Lens*, vol. 33, no. 1, pp. 1–8, 2007.

[116] K. R. Wilhelmus, D. B. Jones, A. Y. Matoba, M. B. Hamill, S. C. Pflugfelder, and M. P. Weikert, "Bilateral *Acanthamoeba* keratitis," *American Journal of Ophthalmology*, vol. 145, no. 2, pp. 193–197, 2008.

[117] F. H. Theodore, F. A. Jakobiec, K. B. Juechter, et al., "The diagnostic value of a ring infiltrate in acanthamoebic keratitis," *Ophthalmology*, vol. 92, no. 11, pp. 1471–1479, 1985.

[118] M. B. Moore, J. P. McCulley, H. E. Kaufman, and J. B. Robin, "Radial keratoneuritis as a presenting sign in *Acanthamoeba* keratitis," *Ophthalmology*, vol. 93, no. 10, pp. 1310–1315, 1986.

[119] A. S. Bacon, J. K. G. Dart, L. A. Ficker, M. M. Matheson, and P. Wright, "*Acanthamoeba* keratitis: the value of early diagnosis," *Ophthalmology*, vol. 100, no. 8, pp. 1238–1243, 1993.

[120] I. Kremer, E. J. Cohen, R. C. Eagle Jr., I. Udell, and P. R. Laibson, "Histopathologic evaluation of stromal inflammation in *Acanthamoeba* keratitis," *CLAO Journal*, vol. 20, no. 1, pp. 45–48, 1994.

[121] S. Sharma, P. Garg, and G. N. Rao, "Patient characteristics, diagnosis, and treatment of non-contact lens related *Acanthamoeba* keratitis," *British Journal of Ophthalmology*, vol. 84, no. 10, pp. 1103–1108, 2000.

[122] D. V. Seal, "*Acanthamoeba* keratitis update-incidence, molecular epidemiology and new drugs for treatment," *Eye*, vol. 17, no. 8, pp. 893–905, 2003.

[123] C. E. Joslin, E. Y. Tu, M. E. Shoff, et al., "The association of contact lens solution use and *Acanthamoeba* keratitis," *American Journal of Ophthalmology*, vol. 144, no. 2, pp. 169–180.e2, 2007.

[124] K. J. Johns, D. M. O'Day, and W. S. Head, "Herpes simplex masquerade syndrome: *Acanthamoeba* keratitis," *Current Eye Research*, vol. 6, no. 1, pp. 207–212, 1987.

[125] J. P. McCulley, H. Alizadeh, and J. Y. Niederkorn, "The diagnosis and management of *Acanthamoeba* keratitis," *CLAO Journal*, vol. 26, no. 1, pp. 47–51, 2000.

[126] S. L. Karayianis, L. J. Genack, M. K. Lundergan, and G. B. Schumann, "Cytologic diagnosis of acanthamoebic keratitis," *Acta Cytologica*, vol. 32, no. 4, pp. 491–494, 1988.

[127] O. E. Lund, F. H. Stefani, and W. Dechant, "Amoebic keratitis: a clinicopathological case report," *British Journal of Ophthalmology*, vol. 62, no. 6, pp. 373–375, 1978.

[128] M. M. Qureshi and E. J. Bottone, "*Acanthamoeba* keratitis: a rational approach to microbiological diagnosis," *Medical Microbiology Letters*, vol. 2, pp. 117–124, 1993.

[129] H. E. Grossniklaus, G. O. Waring IV, C. Akor, A. A. Castellano-Sanchez, and K. Bennett, "Evaluation of hematoxylin and eosin and special stains for the detection of *Acanthamoeba* keratitis in penetrating keratoplasties," *American Journal of Ophthalmology*, vol. 136, no. 3, pp. 520–526, 2003.

[130] M. J. Bharathi, R. Ramakrishnan, R. Meenakshi, S. Mittal, C. Shivakumar, and M. Srinivasan, "Microbiological diagnosis of infective keratitis: comparative evaluation of direct microscopy and culture results," *British Journal of Ophthalmology*, vol. 90, no. 10, pp. 1271–1276, 2006.

[131] N. Gupta and R. Tandon, "Investigative modalities in infectious keratitis," *Indian Journal of Ophthalmology*, vol. 56, no. 3, pp. 209–213, 2008.

[132] J. de Nadai Barros, V. L. Degaspare-Mascaro, M. Lowen, M. C. Martins, and A. Foronda, "Diagnosis of *Acanthamoeba* corneal Infection by impression cytology: case report," *Arquivos Brasileiros de Oftalmologia*, vol. 70, no. 2, pp. 343–346, 2007.

[133] W. Mathers, G. Stevens Jr., and M. Rodrigues, "Immunopathology and electron microscopy of *Acanthamoeba* keratitis," *American Journal of Ophthalmology*, vol. 103, no. 5, part 3, pp. 626–635, 1987.

[134] K. M. Hammersmith, "Diagnosis and management of *Acanthamoeba* keratitis," *Current Opinion in Ophthalmology*, vol. 17, no. 4, pp. 327–331, 2006.

[135] H. Kaur, L. J. Maguire, D. R. Salomao, and J. D. Cameron, "Rapid progression of amebic keratitis 1 week after corneal trauma and 1 year after LASIK," *Cornea*, vol. 26, no. 2, pp. 212–214, 2007.

[136] R. J. Epstein, L. A. Wilson, G. S. Visvesvara, and E. G. Plourde Jr., "Rapid diagnosis of *Acanthamoeba* keratitis from corneal scrapings using indirect fluorescent antibody staining," *Archives of Ophthalmology*, vol. 104, no. 9, pp. 1318–1321, 1986.

[137] F. Rivasi, L. Longanesi, C. Casolari, et al., "Cytologic diagnosis of *Acanthamoeba* keratitis: report of a case with correlative study with indirect immunofluorescence and scanning electron microscopy," *Acta Cytologica*, vol. 39, no. 4, pp. 821–826, 1995.

[138] K. R. Wilhelmus, M. S. Osato, and R. L. Font, "Rapid diagnosis of *Acanthamoeba* keratitis using calcofluor white," *Archives of Ophthalmology*, vol. 104, no. 9, pp. 1309–1312, 1986.

[139] R. E. Silvany, M. W. Luckenbach, and M. B. Moore, "The rapid detection of *Acanthamoeba* in parafin-embedded secton of corneal tissue with calcofluor white," *Archives of Ophthalmology*, vol. 105, no. 10, pp. 1366–1367, 1987.

[140] D. N. Parmar, S. T. Awwad, W. M. Petroll, R. W. Bowman, J. P. McCulley, and H. D. Cavanagh, "Tandem scanning confocal corneal microscopy in the diagnosis of suspected *Acanthamoeba* keratitis," *Ophthalmology*, vol. 113, no. 4, pp. 538–547, 2006.

[141] H. D. Cavanagh, W. M. Petroll, H. Alizadeh, Y.-G. He, J. P. McCulley, and J. V. Jester, "Clinical and diagnostic use of in vivo confocal microscopy in patients with corneal disease," *Ophthalmology*, vol. 100, no. 10, pp. 1444–1454, 1993.

[142] K. Winchester, W. D. Mathers, J. E. Sutphin, and T. E. Daley, "Diagnosis of *Acanthamoeba* keratitis in vivo with confocal microscopy," *Cornea*, vol. 14, no. 1, pp. 10–17, 1995.

[143] D. R. Pfister, J. D. Cameron, J. H. Krachmer, and E. J. Holland, "Confocal microscopy findings of *Acanthamoeba* keratitis," *American Journal of Ophthalmology*, vol. 121, no. 2, pp. 119–128, 1996.

[144] B. J. Cho and E. J. Holland, "In vivo tandem scanning confocal microscopy in *Acanthamoeba* keratitis," *Korean Journal of Ophthalmology*, vol. 12, no. 2, pp. 112–117, 1998.

[145] S. C. Kaufman, D. C. Musch, M. W. Belin, et al., "Confocal microscopy: a report by the American Academy of Ophthalmology," *Ophthalmology*, vol. 111, no. 2, pp. 396–406, 2004.

[146] Y. Matsumoto, M. Dogru, E. A. Sato, et al., "The application of in vivo confocal scanning laser microscopy in the management of *Acanthamoeba* keratitis," *Molecular Vision*, vol. 13, pp. 1319–1326, 2007.

[147] A. Kobayashi, Y. Ishibashi, Y. Oikawa, H. Yokogawa, and K. Sugiyama, "In vivo and ex vivo laser confocal microscopy findings in patients with early-stage *Acanthamoeba* keratitis," *Cornea*, vol. 27, no. 4, pp. 439–445, 2008.

[148] E. Y. Tu, C. E. Joslin, J. Sugar, G. C. Booton, M. E. Shoff, and P. A. Fuerst, "The relative value of confocal microscopy and superficial corneal scrapings in the diagnosis of *Acanthamoeba* keratitis," *Cornea*, vol. 27, no. 7, pp. 764–772, 2008.

[149] J. A. Irvine and R. Ariyasu, "Limitations in tandem scanning confocal microscopy as a diagnostic tool for microbial keratitis," *Scanning*, vol. 16, no. 5, pp. 307–311, 1994.

[150] S. Kilvington, D. F. P. Larkin, D. G. White, and J. R. Beeching, "Laboratory investigation of *Acanthamoeba* keratitis," *Journal of Clinical Microbiology*, vol. 28, no. 12, pp. 2722–2725, 1990.

[151] S. M. Lee, Y. J. Choi, H. W. Ryu, H. H. Kong, and D. I. Chung, "Species identification and molecular characterization of *Acanthamoeba* isolated from contact lens paraphernalia," *Korean Journal of Ophthalmology*, vol. 11, no. 1, pp. 39–50, 1997.

[152] M. Boost, P. Cho, S. Lai, and W. M. Sun, "Detection of *Acanthamoeba* in tap water and contact lens cases using polymerase chain reaction," *Optometry and Vision Science*, vol. 85, no. 7, pp. 526–530, 2008.

[153] O. J. Lehmann, S. M. Green, N. Morlet, et al., "Polymerase chain reaction analysis of corneal epithelial and tear samples in the diagnosis of *Acanthamoeba* keratitis," *Investigative Ophthalmology and Visual Science*, vol. 39, no. 7, pp. 1261–1265, 1998.

[154] H. Yera, O. Zamfir, T. Bourcier, et al., "Comparison of PCR, microscopic examination and culture for the early diagnosis and characterization of *Acanthamoeba* isolates from ocular infections," *European Journal of Clinical Microbiology and Infectious Diseases*, vol. 26, no. 3, pp. 221–224, 2007.

[155] P. Goldschmidt, H. Rostane, C. Saint-Jean, et al., "Effects of topical anaesthetics and fluorescein on the real-time PCR used for the diagnosis of Herpesviruses and *Acanthamoeba* keratitis," *British Journal of Ophthalmology*, vol. 90, no. 11, pp. 1354–1356, 2006.

[156] G. S. Visvesvara, A. J. Martinez, F. L. Schuster, et al., "Leptomyxid ameba, a new agent of amebic meningoencephalitis in humans and animals," *Journal of Clinical Microbiology*, vol. 28, no. 12, pp. 2750–2756, 1990.

[157] G. S. Visvesvara, F. L. Schuster, and A. J. Martinez, "*Balamuthia mandrillaris*, N. G., N. Sp., agent of amebic meningoencephalitis in humans and other animals," *The Journal of Eukaryotic Microbiology*, vol. 40, no. 4, pp. 504–514, 1993.

[158] A. J. Martinez and G. S. Visvesvara, "Balamuthia mandrillaris infection," *Journal of Medical Microbiology*, vol. 50, no. 3, pp. 205–207, 2001.

[159] F. L. Schuster and G. S. Visvesvara, "Balamuthia mandrillaris," in *Emerging Protozoan Pathogens*, N. A. Khan, Ed., pp. 71–118, Taylor & Francis, New York, NY, USA, 2008.

[160] F. L. Schuster, T. H. Dunnebacke, G. C. Booton, et al., "Environmental isolation of *Balamuthia mandrillaris* associated with a case of amebic encephalitis," *Journal of Clinical Microbiology*, vol. 41, no. 7, pp. 3175–3180, 2003.

[161] T. H. Dunnebacke, F. L. Schuster, S. Yagi, and G. C. Booton, "Balamuthia mandrillaris from soil samples," *Microbiology*, vol. 150, no. 9, pp. 2837–2842, 2004.

[162] O. Foreman, J. Sykes, L. Ball, N. Yang, and H. De Cock, "Disseminated infection with *Balamuthia mandrillaris* in a dog," *Veterinary Pathology*, vol. 41, no. 5, pp. 506–510, 2004.

[163] P. Intalapaporn, C. Suankratay, S. Shuangshoti, K. Phantumchinda, S. Keelawat, and H. Wilde, "*Balamuthia mandrillaris* meningoencephalitis: the first case in Southeast Asia," *American Journal of Tropical Medicine and Hygiene*, vol. 70, no. 6, pp. 666–669, 2004.

[164] R. P. Reed, C. M. Cooke-Yarborough, A. L. Jaquiery, et al., "Fatal granulomatous amoebic encephalitis caused by *Balamuthia mandrillaris*," *Medical Journal of Australia*, vol. 167, no. 2, pp. 82–84, 1997.

[165] J. M. Riestra-Castaneda, R. Riestra-Castaneda, A. A. Gonzalez-Garrido, et al., "Granulomatous amebic encephalitis due to *Balamuthia mandrillaris* (Leptomyxiidae): report of four cases from Mexico," *American Journal of Tropical Medicine and Hygiene*, vol. 56, no. 6, pp. 603–607, 1997.

[166] T. R. Deetz, M. H. Sawyer, G. Billman, F. L. Schuster, and G. S. Visvesvara, "Successful treatment of *Balamuthia* amoebic encephalitis: presentation of 2 cases," *Clinical Infectious Diseases*, vol. 37, no. 10, pp. 1304–1312, 2003.

[167] F. Bravo and M. R. Sanchez, "New and re-emerging cutaneous infectious diseases in Latin America and other geographic areas," *Dermatologic Clinics*, vol. 21, no. 4, pp. 655–668, 2003.

[168] A. S. Pritzker, B. K. Kim, D. Agrawal, P. M. Southern Jr., and A. G. Pandya, "Fatal granulomatous amebic encephalitis caused by *Balamuthia mandrillaris* presenting as a skin lesion," *Journal of the American Academy of Dermatology*, vol. 50, no. 2, pp. S38–S41, 2004.

[169] A. Matin, R. Siddiqui, S. Jayasekera, and N. A. Khan, "Increasing importance of *Balamuthia mandrillaris*," *Clinical Microbiology Reviews*, vol. 21, no. 3, pp. 435–448, 2008.

[170] C. F. Denney, V. J. Iragui, L. D. Uber-Zak, et al., "Amebic meningoencephalitis caused by *Balamuthia mandrillaris*: case report and review," *Clinical Infectious Diseases*, vol. 25, no. 6, pp. 1354–1358, 1997.

[171] J. F. Healy, "*Balamuthia* amebic encephalitis: radiographic and pathologic findings," *American Journal of Neuroradiology*, vol. 23, no. 3, pp. 486–489, 2002.

[172] S. Jung, R. L. Schelper, G. S. Visvesvara, and H. T. Chang, "*Balamuthia mandrillaris* meningoencephalitis in an immunocompetent patient: an unusual clinical course and a favorable outcome," *Archives of Pathology and Laboratory Medicine*, vol. 128, no. 4, pp. 466–468, 2004.

[173] A. Bakardjiev, P. H. Azimi, N. Ashouri, et al., "Amebic encephalitis caused by *Balamuthia mandrillaris*: report of four cases," *Pediatric Infectious Disease Journal*, vol. 22, no. 5, pp. 447–452, 2003.

[174] D. A. Griesemer, L. L. Barton, C. M. Reese, et al., "Amebic meningoencephalitis caused by *Balamuthia mandrillaris*," *Pediatric Neurology*, vol. 10, no. 3, pp. 249–254, 1994.

[175] J. L. Rowen, C. A. Doerr, H. Vogel, and C. J. Baker, "*Balamuthia mandrillaris*: a newly recognized agent for amebic meningoencephalitis," *Pediatric Infectious Disease Journal*, vol. 14, no. 8, pp. 705–710, 1995.

[176] I. Bodi, N. Dutt, T. Hampton, and N. Akbar, "Fatal granulomatous amoebic meningoencephalitis due to *Balamuthia mandrillaris*," *Pathology Research and Practice*, vol. 204, no. 12, pp. 925–928, 2008.

[177] S. Jayasekera, J. Sissons, J. Tucker, et al., "Post-mortem culture of *Balamuthia mandrillaris* from the brain and cerebrospinal fluid of a case of granulomatous amoebic meningoencephalitis, using human brain microvascular endothelial cells," *Journal of Medical Microbiology*, vol. 53, no. 10, pp. 1007–1012, 2004.

[178] R. Kodet, E. Nohýnková, M. Tichý, J. Soukup, and G. S. Visvesvara, "Amebic encephalitis caused by *Balamuthia mandrillaris* in a Czech child: description of the first case from Europe," *Pathology Research and Practice*, vol. 194, no. 6, pp. 423–429, 1998.

[179] B. J. Duke, R. W. Tyson, R. DeBiasi, J. E. Freeman, and K. R. Winston, "*Balamuthia mandrillaris* meningoencephalitis presenting with acute hydrocephalus," *Pediatric Neurosurgery*, vol. 26, no. 2, pp. 107–111, 1997.

[180] Z. H. Huang, A. Ferrante, and R. F. Carter, "Serum antibodies to *Balamuthia mandrillaris*, a free-living amoeba recently demonstrated to cause granulomatous amoebic encephalitis," *Journal of Infectious Diseases*, vol. 179, no. 5, pp. 1305–1308, 1999.

[181] F. L. Schuster, S. Honarmand, G. S. Visvesvara, and C. A. Glaser, "Detection of antibodies against free-living amoebae *Balamuthia mandrillaris* and *Acanthamoeba* species in a population of patients with encephalitis," *Clinical Infectious Diseases*, vol. 42, no. 9, pp. 1260–1265, 2006.

[182] A. F. Kiderlen, E. Radam, and P. S. Tata, "Assessment of *Balamuthia mandrillaris*-specific serum antibody concentrations by flow cytometry," *Parasitology Research*, vol. 104, no. 3, pp. 663–670, 2009.

[183] G. C. Booton, J. R. Carmichael, G. S. Visvesvara, T. J. Byers, and P. A. Fuerst, "Genotyping of *Balamuthia mandrillaris* based on nuclear 18S and mitochondrial 16s rRNA genes," *American Journal of Tropical Medicine and Hygiene*, vol. 68, no. 1, pp. 65–69, 2003.

[184] G. C. Booton, J. R. Carmichael, G. S. Visvesvara, T. J. Byers, and P. A. Fuerst, "Identification of *Balamuthia mandrillaris* by PCR assay using the mitochondrial 16S rRNA gene as a target," *Journal of Clinical Microbiology*, vol. 41, no. 1, pp. 453–455, 2003.

[185] S. Yagi, G. C. Booton, G. S. Visvesvara, and F. L. Schuster, "Detection of *Balamuthia* mitochondrial 16S rRNA gene DNA in clinical specimens by PCR," *Journal of Clinical Microbiology*, vol. 43, no. 7, pp. 3192–3197, 2005.

[186] M. Tavares, J. M. C. da Costa, S. S. Carpenter, et al., "Diagnosis of first case of *Balamuthia* amoebic encephalitis in Portugal by immunofluorescence and PCR," *Journal of Clinical Microbiology*, vol. 44, no. 7, pp. 2660–2663, 2006.

[187] A. F. Kiderlen, E. Radam, and A. Lewin, "Detection of *Balamuthia mandrillaris* DNA by real-time PCR targeting the RNase P gene," *BMC Microbiology*, vol. 8, article 210, 2008.

[188] R. Michel, C. Wylezich, B. Hauroder, and A. V. Smirnov, "Phylogenetic position and notes on the ultrastructure of *Sappinia diploidea* (Thecamoebidae)," *Protistology*, vol. 4, pp. 319–325, 2006.

[189] L. P. Goodfellow, J. H. Belcher, and F. C. Page, "A light and electron microscopical study of *Sappinia diploidea*, a sexual amoeba," *Protistologica*, vol. 2, pp. 207–216, 1974.

[190] M. W. Brown, F. W. Spiegel, and J. D. Silberman, "Amoeba at attention: phylogenetic affinity of *Sappinia pedata*," *Journal of Eukaryotic Microbiology*, vol. 54, no. 6, pp. 511–519, 2007.

[191] Y. Qvarnstrom, A. J. da Silva, F. L. Schuster, B. B. Gelman, and G. S. Visvesvara, "Molecular confirmation of *Sappinia pedata* as a causative agent of amoebic encephalitis," *Journal of Infectious Diseases*, vol. 199, no. 8, pp. 1139–1142, 2009.

Hindawi Publishing Corporation
Interdisciplinary Perspectives on Infectious Diseases
Volume 2009, Article ID 180742, 9 pages
doi:10.1155/2009/180742

Review Article

Diagnosis and Treatment of Neurocysticercosis

Christina M. Coyle[1,2] and Herbert B. Tanowitz[1,2,3]

[1] *Department of Medicine, Division of Infectious Disease, Albert Einstein College of Medicine, Bronx, NY 10461, USA*
[2] *Parasitology and Tropical Disease Clinic and Laboratory, Jacobi Medical Center, Bronx, NY 10461, USA*
[3] *Department of Pathology, Division of Parasitology and Tropical Medicine, Albert Einstein College of Medicine, Bronx, NY 10461, USA*

Correspondence should be addressed to Christina M. Coyle, coyle@aecom.yu.edu

Received 6 April 2009; Accepted 25 June 2009

Recommended by Louis M. Weiss

Neurocysticercosis, the infection caused by the larval form of the tapeworm *Taenia solium*, is the most common parasitic disease of the central nervous system and the most common cause of acquired epilepsy worldwide. This has primarily been a disease that remains endemic in low-socioeconomic countries, but because of increased migration neurocysticercosis is being diagnosed more frequently in high-income countries. During the past three decades improved diagnostics, imaging, and treatment have led to more accurate diagnosis and improved prognosis for patients. This article reviews the current literature on neurocysticercosis, including newer diagnostics and treatment developments.

1. Introduction

Neurocysticercosis (NCC) is a neurologic infection caused by the larval stage of the tapeworm *Taenia solium*. In the developing world, NCC, infection of the central nervous system (CNS) with the *T. solium* larvae, is the most common cause of acquired epilepsy [1–3]. Because of globalization, many clinicians in industrialized countries who are unfamiliar with NCC are now faced with managing this disease. Humans are the definitive hosts for this parasite, and swine are the intermediate hosts. The adult tapeworm develops in human hosts after they ingest live cysticercus in undercook pork. NCC develops when humans accidentally ingest eggs. This occurs when feces of human carriers contaminates food, although the most important risk factor for the acquisition of cysticercosis is the proximity of a tapeworm carrier [4, 5]. Adult tapeworms shed proglottids, and each proglottid contains approximately 1000 to 2000 eggs. Once the hexacanth embryo reaches the parenchyma it forms cysticerci which undergo four stages of involution [6].

The first is the vesicular stage characterized by a cyst with a translucent vesicular wall, transparent fluid, and a viable invaginated scolex. During this stage there is little host inflammatory reaction. The cyst then develops a thick vesicular wall, the fluid becomes turbid, and the scolex degenerates during the next stage, which is termed the colloidal stage. An intense inflammatory host response is seen and is reflected in the pathology which reveals varying degrees of acute and chronic inflammation [1, 6]. Radiographic examination reveals cystic lesions with edema and enhancement and seizures are common [7]. The cyst continues to degenerate as it moves into the granular stage which is characterized by a thick vesicular wall, degenerated scolex, gliosis, and little inflammatory host response. Ultimately the parasite transforms into coarse calcified nodules; the calcific stage [1, 2, 6].

2. Clinical Manifestations of Neurocysticercosis (NCC)

The clinical manifestations of NCC range from asymptomatic to life threatening. Within the CNS it can affect the parenchyma, subarachnoid space, or intraventricular system. Ocular and spinal disease occurs, but is less common. Therefore, the clinical manifestations are pleomorphic and dependant on the location, number, and stage of the cysts at presentation. NCC is the leading cause of adult-onset

epilepsy in areas of the world where it is endemic, particularly in Latin America, Asia, and Africa [1]. Seizures are commonly generalized tonic-clonic or simple partial. Epilepsy occurs more frequent in patients with parenchymal disease, although it can occur in patients with cysts in the cortical sulci [1]. Seizures due to cysticercosis usually occur when the dying cyst incites an inflammatory reaction, but has been reported in the cystic stage. For many patients epilepsy may be the sole presentation of the disease with 50%–70% of patients experiencing recurrent seizures [8, 9].

There are multiple ways that cysticercosis can cause seizures. As noted, seizures can occur early in the disease in the setting of intense inflammation associated with viable or degenerating cysts. They can also occur secondary to vasculitis and infarction which occurs in the setting of subarachnoid disease [10]. Lastly, increasing evidence implicates calcified NCC in the development and maintenance of seizures and epilepsy [11]. Patients who present with seizures in regions where infection with *T. solium* is endemic commonly have calcified brain lesions observed on computerized axial tomography (CT) scan that are typical for NCC. In population-based studies calcified lesions on CT are much more common than viable cysts, and they are more prevalent in patients with epilepsy than they are in asymptomatic patients [11–13]. Strong evidence supports the role of calcified lesions in seizures; there is a high prevalence of cerebral calcifications in patients with seizures in the absence of other etiologies, and there is a positive correlation between endemic populations with increased proportions of calcification and seizure activity. In addition, individuals with calcified granulomas have increased risk of ongoing seizure [14–17].

There has been increasing evidence that perilesional edema, which occurs episodically, is associated with seizures [14, 15, 18–20]. Perilesional edema appears as a bright signal using magnetic resonance imaging (MRI) FLAIR or T2 imaging (Figure 1). It is almost always accompanied by enhancement around the calcified focus [11]. Previously calcified NCC has been classified as the inactive form of the disease, suggesting that it is less important than other forms of NCC [21]. Recently a growing literature is finding that perilesional edema related to calcifications seems to be a relatively frequent phenomenon, with reports ranging from 23%–35% in literature [8, 14, 22]. The natural history or pathophysiology of perilesional edema is not yet known, but it appears that it recurs, and repeated episodes tend to be associated with the same lesions in a patient. In a recent prospective nested case-control study, 110 patients with seizures or headaches and calcified lesions in an endemic region were followed for recurrent seizures. Of those with recurrent seizures, perilesional edema was noted on MRI in 50% as opposed to 9% of asymptomatic matched controls [23]. This study suggests that perilesional edema is a common and potentially preventable cause of seizure in endemic regions.

Although, seizures are the most common clinical manifestation of parenchymal NCC, focal neurologic signs have been reported and are usually related to the number, size, and location of the parasites in individuals with

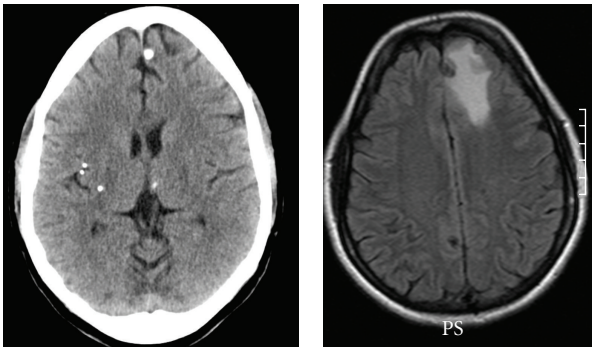

(a) (b)

Figure 1: (a) Baseline CT scan demonstrating a dense calcification in the left frontal lobe as well as other calcifications. (b) MRI images that used fluid attenuated recovery after the patient had a seizure revealing perilesional edema.

parenchymal disease. Intracranial hypertension can occur in patients with parenchymal NCC and is termed cysticercotic encephalitis [1, 24, 25]. This manifestation has been best described in children and young woman and is a result of the acute inflammatory response to massive cysticercal infection resulting in brain edema. Patients present with a syndrome characterized by clouding of consciousness, seizures, decreased visual acuity, headache, vomiting, and papilledema which can be subacute or acute in onset [1, 22]. These patients are treated with mannitol and corticosteroids in an attempt to control the inflammation and intracranial hypertension. Patients may even require decompressive temporal craniotomy. Those individuals with this form of NCC would not be candidates for antiparasitic agents, since treatment could exacerbate the inflammation and edema. Other causes of intracranial hypertension in patients with parenchymal NCC include the development of a large cyst that displaces midline structures or obstructs the flow of cerebrospinal fluid (CSF) in the cerebral aqueduct.

Psychiatric manifestations of NCC, such as depression and psychosis, have been described [26, 27]. A recent study found that patients admitted to a chronic inpatient psychiatric unit were more likely to have a positive serology for *T. solium* then healthy controls in the community. Of these inpatients, those with mental retardation were found to carry an increase risk of cysticercosis compared with patients with other psychiatric disorders. These patients were not carrying adult *Taenia spp.* in their stool and did not have CNS imaging, but the high prevalence of a positive cysticercosis serology in the inpatient psychiatric group suggests that there is a large proportion of cysticercosis in this group of patients [28]. Further studies are needed to explore the relationship between NCC and psychiatric disease.

Subarachnoid NCC is a common finding at autopsy, but when cysticerci find their way to the Sylvian fissure or the basilar cisterns the result can be devastating for the patient. The cysticercus larva (after embedding itself in the parenchyma) undergoes four stages of evolution: vesicular, vesicular colloid, granular nodular, and nodular calcified

[1]. This evolution does not occur in the intraventricular or the subarachnoid form of NCC. The cisternal NCC is also-called the racemose type of cysticerosis. Racemose NCC refers to "aberrant proliferating cestode larvae" that manifest as solitary or multiple unencapsulated bladders that bud exogenously to form a multilocular cyst resembling a bunch of grapes [29]. The multiple cysts of the racemose type occur in nonconfining areas in and around the brain such as the suprasellar, sylvian and quadrigeminal cisterns. These cysts are nonviable, degenerated interconnected bladders of different sizes that often lack scolices, and can reach large sizes producing local mass effect. Arachnoiditis can occur with resulting communicating hydrocephalus secondary to either chronic inflammation or fibrosis of the arachnoid villi causing obstruction to the reabsorption of CSF or extension of the subarachnoid inflammatory reaction to the meninges at the base of the brain occluding the forminal of Luschka and Magendie [1, 30]. Cysticercotic arachnoiditis can lead to entrapment of cranial nerves in the inflammatory exudates that occur on the ventral aspect of the brain. Extraocular muscle paralysis, diploplia and papillary abnormalities are the result of entrapment of the ocular motor nerves. The optic nerves and the optic chiasm can also be encased within the exudates with subsequent development of decreased visual acuity and visual field defects [31, 32]. Acute aseptic meningitis associated with subarachnoid disease has been reported, but is rarely associated with fever and signs of meningeal irritation [1].

Cerebrovascular complications of neurocysticercosis include cerebral infarction, transient ischemic attacks and brain hemorrhage [10, 33, 34]. The most common mechanisms by which NCC produces cerebrovascular disease are related to cerebral arteritis, mainly in those individuals with subarachnoid cysticercosis. Earlier clinical reports of cerebral infarction were secondary to small vessel involvement in NCC. In a recent study that examined 28 patients with subarachnoid disease 53% had angiographic evidence of cerebral arteritis with the middle cerebral and posterior cerebral arteries being the most commonly involved vessels associated with clinical stroke syndrome. The frequency of cerebral arteritis in subarachnoid cysticercosis seems to be higher than previously reported, and middle-size vessel involvement is a common finding [35].

Clinical manifestations of ventricular NCC vary according to the size of the parasites, their location inside the ventricular system, and the coexistence of granular ependymitis [1, 36]. Lateral ventricles usually induce a syndrome of increased intracranial pressure which may be associated with focal neurological signs due to compression of adjacent structures [37, 38]. Patients with third ventricle cysticerci complain of progressively worsening headaches and vomiting due to developing obstruction or may present with sudden loss of conscious from acute hydrocephalus [39, 40]. Paroxysmal headache and vomiting secondary to intermittent obstruction at the level of the cerebral aqueduct has been described [1]. Cysts in the fourth ventricle can also cause subacute hydrocephalus that may be associated with signs of brainstem dysfunction secondary to compression of the fourth ventricle [41]. A well-described clinical presentation of fourth ventricle cyst is the Bruns' syndrome which is characterized by episodic headache, papilledema, neck stiffness, sudden positional vertigo induced by rotatory movements of the head, nausea and vomiting, drop attacks and loss of consciousness with rapid recovery and long asymptomatic periods [1]. Cysts in the third and fourth are a well-described cause of sudden death due acute obstructive hydrocephalus [41–43].

A degenerating cyst in the ventricles can result in an inflammatory reaction throughout the ventricular system leading to granular ependymitis. When this occurs the cyst capsule can become fixed to the ventricular wall with strong adhesions and fibrosis [41]. Increased intracranial pressure due to hydrocephalus can occur if ependymitis occurs at the level of the cerebral aqueduct. These patients tend to have a more chronic course than those with cysts in the fourth ventricle [44].

Spinal cord involvement in NCC is rare, accounting for 1%–5% of all cases [1, 45]. Spinal cord involvement can be intramedullary or extramedullary with the latter being more common. Intramedullary cysts are most common in the thoracic spine and patients usually present with gradual onset of myelopathy similar to the presentation of intramedullary tumors [46–52]. Extramedullary cysts or leptomeningeal NCC is usually an extension of subarachnoid disease which has migrated from the basilar cisterns. Cysts may be single or may form clumps of multiple cysts extending along the entire spinal canal [46, 47]. The resulting clinical picture is characterized by a combination of radicular pain and motor deficits of subacute onset and progressive course [1].

Intraocular cysticerci may be located in the anterior chamber, the lens, the vitreous and the subretinal space, but the latter is the most common location. Cysts in the subretinal space can cause progressive decrease in visual acuity. Vitreous cysts can produce worsening vision with the perception of something moving within the eye. Cysts in the anterior chamber may induce a severe iridocyclitis, while retro-ocular intraorbital cysticerci may cause decreased visual acuity due to pressure on the optic nerve [1, 53, 54].

3. Radiological Manifestations

Neuroimaging of parenchymal NCC depends on the stage of the development of the parasites. In the vesicular stage the cysticerci appear as cystic lesions within the brain parenchyma [7]. CT and MRI reveal that the cyst wall is thin and well demarcated from the parenchyma. The cysts lack perilesional edema and do not enhance after administration of contrast medium. There may be a bright nodule in their interior giving the lesion a "hole with dot" appearance that represents the scolex (Figure 2(a)) [55]. As the cysts begin to degenerate they appear as ill-defined lesions surrounded by edema which enhance after contrast medium administration. This is the colloidal stage of the cyst and represents the so-called "acute encephalitic phase" of NCC which likely represents an intense host reaction to the parasite (Figure 2(b)). MRI reveals a thick and hypointense

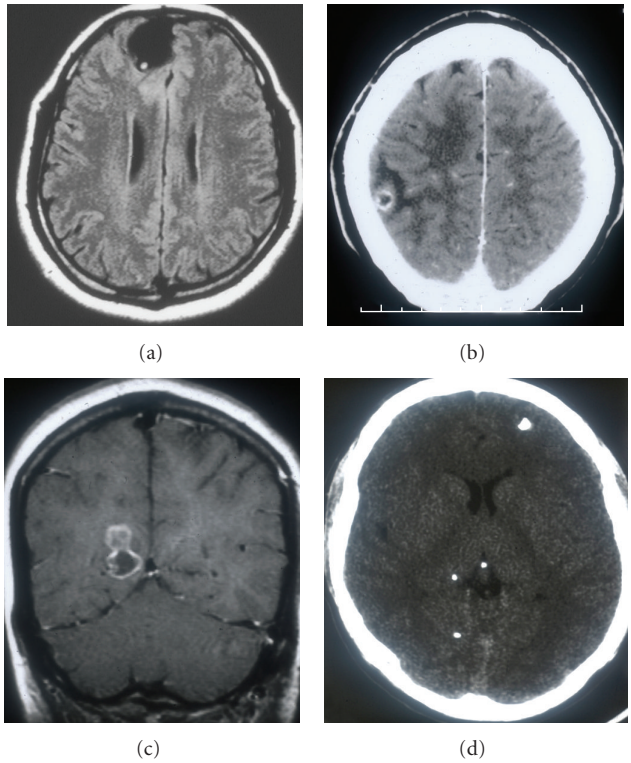

Figure 2: (a) MRI image revealing vesicular cysticerci (the central dot represents the scolex). (b) Cyst beginning to degenerate with perilesional edema and enhancement in the colloidal stage. (c) Cyst in the granular stage without perilesional edema. (d) CAT scan revealing multiple calcifications in the calcified stage.

wall with marked perilesional edema. The perilesional edema is best visualized on MRI with the fluid-attenuated inversion recovery (FLAIR) technique [7]. Granular cysticerci appear as nodular hyperdense lesions surrounded by edema or a rim of gliosis after contrast medium administration (Figure 2(c)) [55]. Calcified (dead) cysticerci appear on CT as small hyperdense nodules without perilesional edema (Figure 2(d)) or abnormal enhancement after contrast administration; these lesions are usually not visualized by MRI. Conversely, when calcified lesions are associated with perilesional edema and contrast enhancement, they are better seen by MRI [7, 55].

Cysticerci within the basilar cisterns are usually missed by CT scan and require MRI to adequately visualize them. While most subarachnoid cysts over the convexity of the cerebral hemispheres are small, lesions located in the Sylvian fissure may reach 50 mm or more in size; these parasites usually have a mulitlobulated appearance, displace neighboring structures, and behave as mass occupying lesions. Fibrous arachnoiditis commonly occurs in subarachnoid disease resulting in hydrocephalus which is the most common CT finding in subarachnoid NCC [7, 46]. Leptomeningeal enhancement at the base of the brain is observed best by MRI [56]. In general, the neuroimaging appearance of cerebrovascular complications is indistinguishable from cerebral infarcts from other causes [10].

Ventricular cysts appear on CT images as cystic lesions. They are initially isodense with the CSF and are therefore not well visualized. However, their presence can be inferred from distortions of the ventricular system causing asymmetric or obstructive hydrocephalus [57]. In contrast, most ventricular cysts are well visualized by MRI because their signal properties differ from those of the CSF, particularly using FLAIR techniques [7]. They may also move within the ventricular cavities in response to movements of the patients' head (ventricular migration sign), a phenomenon that is best observed with MRI than with CT [58]. Occasionally, this finding facilitates the diagnosis of ventricular cysticercosis.

In patients with spinal NCC, CT may reveal symmetrical enlargement of the cord (intramedullary cysts) or pseudoreticular formations within the spinal canal (leptomeningal cysts). MRI reveals intramedullary cysticerci to be ring-enhancing lesions that may have an eccentric hyperintense nodule representing the scolex. Myelography still has a role in the diagnosis of patients with spinal leptomeningeal cysticercosis because it shows multiple filling defects in the column of contrast material corresponding to each cyst [59]. Leptomeningeal cysts may be mobile (changing their position according to the movements of the patient) [7, 59, 60].

4. Serology

Only tests based on detection of antibodies specific for *T. solium* antigens are reliable for clinical diagnosis and epidemiologic studies. To date, these are limited to those based on the use of purified glycoprotein antigens derived from *T. solium* cysticerci. The current assay of choice is the electroimmunotransfer blot (ETIB) using partially purified antigenic extracts [61, 62]. This assay has a specificity approaching 100% and a sensitivity of 94%–98% for patients with two or more cystic or enhancing lesions. A major limitation of these tests are frequent false negative results in patients with single intracranial cysticerci, in which fewer than 50% test positive. Sensitivity of specific antibody assays is also relatively low in patients with only calcified cysticerci [63].

Detection of circulating parasite antigen reflects the presence of live parasites establishes the presence of ongoing viable infection and may permit quantitative verification of successful treatment [64–66]. Garcia and others have used Ag-ELISA based on the use of a monoclonal antibody (HP10) that reacts with a repetitive carbohydrate epitope found in excretory/secretory and surface antigens of living cysticerci [66, 67]. This assay had a sensitivity of 86% when tested on (CSF) samples from a series of 50 Peruvian patients with NCC [68]. The specificity of the assay is about 96% and it has been used to follow patients after treatment. Parasite antigen levels fell significantly by 3 months after treatment in patients with "cured" parenchymal disease after albendazole therapy [66]. This study found that the sensitivity is low in intraparenchymal NCC, especially in patients with only a few intraparenchymal cysts [66]. In

a study examining patients with hydrocephalus and NCC the assay was positive in 14 of 29 patients, but negative in patients with calcifications [69]. A drop in antigen levels (serum and CSF) after treatment in subarachnoid disease has been reported in a small number of patients [70]. The management of subarachnoid disease is particularly complicated and the appropriate endpoint for treatment has not been established. Further studies employing this assay to follow patients with subarachnoid disease are needed. Recently a monoclonal antibody-based ELISA to detect *T. solium* antigens in urine has been described. The overall sensitivity of urine antigen detection for viable parasites was 92%, which decreased to 62.5% in patients with a single cyst. Most individuals with only calcified cysticercosis were urine antigen negative. This assay could be useful in diagnosis of NCC and evaluating the efficacy of treatment.

5. Treatment

5.1. Parenchymal Disease. Praziquantel and albendazole are antiparasitic agents that are effective against *T. solium* cysticerci killing between 60% and 85% of parenchymal brain cysticerci [71]. Most trials show greater cyst reduction with albendazole administration. However, most of these studies have been uncontrolled, observational imaging studies. The majority of studies evaluated praziquantel at a dosage of 50 mg/kg/d for 2 weeks, although studies describing a single day regimen have also been described [8, 72–83]. Higher doses have been used, but there is limited experience in literature [71, 72]. A dose of 15 mg/kg of albendazole for four weeks was initially employed, but later reduced to 15 days and then to one week [74, 76, 80, 81, 83–88]. Between the second and fifth day of treatment with an antiparasitic agent there may be an exacerbation of neurologic symptoms which has been attributed to inflammation secondary to killing of the cysticerci. Because of this inflammation steroids are generally administered in conjunction with albendazole or praziquantel to control the resulting edema [71]. It should be noted that steroids decrease the plasma level of praziquantel, but not albendazole [89].

Randomized studies evaluating the clinical benefit of treatment have yielded conflicting data with some studies indicating a benefit and others failing to show a difference [90–94]. There has been much controversy whether cysticidal drugs modify the natural course of neurocysticercosis. In 2004 a randomized, placebo-controlled trial of treatment of adults with 20 or less viable parenchymal cysts and a history of seizures using albendazole demonstrated a reduction in seizures and enhanced resolution of cysts after treatment [95]. Although a landmark study, the treatment was not completely effective. The number of patients who became free of seizures was similar in the two groups, but the reduction in the number of the seizures among patients who received the treatment was significant in patients with generalized seizures, not in the group with partial seizures. Further studies are needed to determine whether longer or repeated courses of therapy will result in a decrease in seizures overall and leave patients with fewer remaining cysticerci. A recent meta-analysis confirmed that treatment of parenchymal NCC is clinically beneficial [96]. These authors concluded drug therapy results in better resolution of colloidal and vesicular cysticerci, lower risk for recurrence of seizures in patients with colloidal cysticerci, and a reduction in the rate of generalized seizures in patients with vesicular cysticerci. However, there were not sufficient data to determine conclusively the superiority of either albendazole or praziquantel as first-line treatment of NCC in this meta-analysis [96]. Despite the numerous studies, an optimal therapeutic regimen for neurocysticercosis has not been established. The evidence favors albendazole over praziquantel, but longer courses and repeated courses might be needed for patients with multiple cysts. Future trials should look to define the optimal therapeutic regimen. A recent prospective, randomized placebo, controlled trial examined combination therapy with albendazole and praziquantel versus albendazole alone in 110 children with seizsures and single enhancing lesions. There were no differences in recurrent seizures and resolution of the lesions. Larger studies are warranted with combination therapy in both parenchymal disease and extraparenchymal forms of neurocysticercosis [97].

Single enhancing lesions have a good prognosis. Studies examining this group of patients have shown variable clinical results, probably due to the heterogeneity of morphology of single enhancing lesions. The most rigorous double-blinded randomized treatment trial showed an initial increase in seizure occurrence, but in a follow-up evaluation at two years there was a significant benefit of treatment [87, 88]. The previously mentioned meta-analysis found that enhancing lesions benefited from treatment with antiparasitics [96]. Solid nodular cysts that are degenerating have shown resolution with antiparasitic treatment. Calcified cysts need not be treated with antiparasitic agents [4, 71].

Anticonvulsants are should be used to control seizures. Serum levels of phenytoin and carbamazepine may be lowered when given concomitantly with praziquantel [98].

There is no proven effective treatment for perilesional edema associated with calcified lesions. Steroids can control symptoms, but there are no data that treatment with steroids will prevent recurrent edema [4, 14]. Methotrexate has been used in patients with recurrent perilesional edema to control the host inflammatory response as a steroid sparing agent in patients requiring long-term steroids [99, 100]. Patients with cysticercotic encephalitis should not be treated with cysticidal drugs because this may exacerbate the intracranial hypertension. Treatment should be aimed at relieving edema with corticosteroids (up to 32 mg per day of dexamethasone) and mannitol at doses of 2 mg/kg per day [2].

5.2. Extraparenchymal NCC. There are no controlled trials on the management of subarachnoid disease. In a series of patients treated with only CSF diversion, 50% died at a median follow-up of 8 years and 11 months [101]. Cysticidal drugs with steroids and shunting for hydrocephalus have been used with success in subarachnoid disease [46, 102, 103]. The host inflammatory reaction around the cysts may

result in occlusion of leptomeningeal vessels resulting in stroke or hydrocephalus [9, 101]. Therefore, steroids must be used in conjunction with therapy [2, 4, 55]. Most experts consider subarachnoid NCC an indication for treatment with antiparasitic agents [71]. There is no consensus on the dose of antiparasitic agent or length of treatment for this form of NCC. A study of 33 patients with giant cysticerci in the Sylvian fissure treated with albendazole (15 mg/kg/d for 4 weeks) found only one single death from aplastic anemia at 59 months, with patients requiring several courses of therapy [102]. Therefore, a single course in patients with subarachnoid disease patients is probably inadequate and long-term therapy (months) might be required to treat some patients. Similarly, the optimal dose and duration of steroids has not been determined. Methotrexate has been used as a steroid sparing agent in subarachnoid disease in patients requiring long-term steroids and experiencing intolerable side effects [99].

Therapy for ventricular disease needs to be individualized. Anthelmintic treatment of the fourth, third, and lateral ventricle has been reported [41, 104–107]. If hydrocephalus is present patients, should have a shunt placed prior to medical therapy [106]. Surgery has been the mainstay in this form of NCC [39, 108]. There is a growing literature supporting flexible neuroendoscopy to remove approachable subarachnoid cysts and cysts lodged in the lateral, third, and fourth ventricles [109–112]. Cysts that enhance on MRI may not be suitable for endoscopic removal.

It is important to recognize that the management of NCC is complicated and involves antiinflammatory agents, antiparasitic drugs, and in some cases surgery. It should be managed by physicians knowledgeable in this field.

References

[1] O. H. Del Brutto, J. Sotelo, and G. Roman, *Neurocysticercosis: A Clinical Handbook*, Swets & Zeitlinger, Lisse, The Netherlands, 1998.

[2] O. H. Del Brutto, "Neurocysticercosis," *Seminars in Neurology*, vol. 25, no. 3, pp. 243–251, 2005.

[3] H. H. Garcia, A. E. Gonzalez, C. A. W. Evans, and R. H. Gilman, "Taenia solium cysticercosis," *The Lancet*, vol. 362, no. 9383, pp. 547–556, 2003.

[4] T. E. Nash, G. Singh, A. C. White, et al., "Treatment of neurocysticercosis: current status and future research needs," *Neurology*, vol. 67, no. 7, pp. 1120–1127, 2006.

[5] A. G. Lescano, H. H. Garcia, R. H. Gilman, et al., "Taenia solium cysticercosis hotspots surrounding tapeworm carriers: clustering on human seroprevalence but not on seizures," *PLoS Neglected Tropical Diseases*, vol. 3, article e371, 2009.

[6] A. Escobar, "The pathology of neurocysticercosis," in *Cysticercosis of the Central Nervous System*, E. Palacios, J. Rodriquez-Carbajal, and J. M. Taveras, Eds., pp. 27–54, Charles C. Thomas, Springfield, Ill, USA, 1983.

[7] H. H. Garcia and O. H. Del Brutto, "Imaging findings in neurocysticercosis," *Acta Tropica*, vol. 87, no. 1, pp. 71–78, 2003.

[8] O. H. Del Brutto, R. Santibanez, C. A. Noboa, R. Aguirre, E. Diaz, and T. A. Alarcon, "Epilepsy due to neurocysticercosis: analysis of 203 patients," *Neurology*, vol. 42, no. 2, pp. 389–392, 1992.

[9] G. F. McCormick, C. S. Zee, and J. Heiden, "Cysticercosis cerebri. Review of 127 cases," *Archives of Neurology*, vol. 39, no. 9, pp. 534–539, 1982.

[10] O. H. Del Brutto, "Cysticercosis and cerebrovascular disease: a review," *Journal of Neurology, Neurosurgery and Psychiatry*, vol. 55, no. 4, pp. 252–254, 1992.

[11] T. E. Nash, O. H. Del Brutto, J. A. Butman, et al., "Calcific neurocysticercosis and epileptogenesis," *Neurology*, vol. 62, no. 11, pp. 1934–1938, 2004.

[12] A. Fleury, T. Gomez, I. Alvarez, et al., "High prevalence of calcified silent neurocysticercosis in a rural village of Mexico," *Neuroepidemiology*, vol. 22, no. 2, pp. 139–145, 2003.

[13] J. Garcia-Noval, E. Moreno, F. de Mata, et al., "An epidemiological study of epilepsy and epileptic seizures in two rural Guatemalan communities," *Annals of Tropical Medicine and Parasitology*, vol. 95, no. 2, pp. 167–175, 2001.

[14] T. E. Nash, J. Pretell, and H. H. Garcia, "Calcified cysticerci provoke perilesional edema and seizures," *Clinical Infectious Diseases*, vol. 33, no. 10, pp. 1649–1653, 2001.

[15] S. A. Antoniuk, I. Bruck, L. H. Coutinho Dos Santos, et al., "Seizures associated with calcifications and edema in neurocysticercosis," *Pediatric Neurology*, vol. 25, no. 4, pp. 309–311, 2001.

[16] A. Thussu, A. Arora, S. Prabhakar, V. Lal, and I. M. S. Sawhney, "Acute symptomatic seizures due to single CT lesions: how long to treat with antiepileptic drugs?" *Neurology India*, vol. 50, no. 2, pp. 141–144, 2002.

[17] S. Rajadhyaksha, K. N. Shah, S. Kanhere, N. Naik, and R. Mehta, "Does treatment change the outcome of seizures and computerized tomographic lesions in intracranial granulomas?" *Journal of Tropical Pediatrics*, vol. 45, no. 3, pp. 161–165, 1999.

[18] T. E. Nash and N. J. Patronas, "Edema associated with calcified lesions in neurocysticercosis," *Neurology*, vol. 53, no. 4, pp. 777–781, 1999.

[19] T. N. Sheth, L. Pilon, J. Keystone, and W. Kucharczyk, "Persistent MR contrast enhancement of calcified neurocysticercosis lesions," *American Journal of Neuroradiology*, vol. 19, no. 1, pp. 79–82, 1998.

[20] S. Y. Park, A. J. Barkovich, and P. S. Weintrub, "Clinical implications of calcified lesions of neurocysticercosis," *Pediatric Infectious Disease Journal*, vol. 19, no. 6, pp. 581–583, 2000.

[21] J. Sotelo, V. Guerrero, and F. Rubio, "Neurocysticercosis: a new classification based on active and inactive forms. A study of 753 cases," *Archives of Internal Medicine*, vol. 145, no. 3, pp. 442–445, 1985.

[22] R. K. Garg, "Neurocysticercosis," *Postgraduate Medical Journal*, vol. 74, no. 872, pp. 321–326, 1998.

[23] T. E. Nash, E. J. Pretell, A. G. Lescano, et al., "Perilesional brain oedema and seizure activity in patients with calcified neurocysticercosis: a prospective cohort and nested case-control study," *The Lancet Neurology*, vol. 7, no. 12, pp. 1099–1105, 2008.

[24] R. Rangel, B. Torres, O. Del Bruto, and J. Sotelo, "Cysticercotic encephalitis: a severe form in young females," *American Journal of Tropical Medicine and Hygiene*, vol. 36, no. 2, pp. 387–392, 1987.

[25] N. Ignacio Madrazo, B. Olhagaray, M. Becerra, M. A. Sandoval, and L. Raúl Soto, "Acute cysticercosis encephalitis: description of a histologically confirmed case," *Neurosurgery*, vol. 13, no. 5, pp. 593–595, 1983.

[26] O. V. Forlenza, A. H. G. Filho, J. P. S. Nobrega, et al., "Psychiatric manifestations of neurocysticercosis: a study of 38 patients from a neurology clinic in Brazil," *Journal of*

Neurology, Neurosurgery and Psychiatry, vol. 62, no. 6, pp. 612–616, 1997.

[27] H. B. F. Dixon and F. M. Lipscomb, "Cysticercosis: an analysis and follow up of 450 cases," Special Report Series 299, Medical Research Council, Her Majesty's Stationery, London, UK, 1961.

[28] N. W. Meza, N. E. Rossi, T. N. Galeazzi, et al., "Cysticercosis in chronic psychiatric inpatients from a Venezuelan community," *American Journal of Tropical Medicine and Hygiene*, vol. 73, no. 3, pp. 504–509, 2005.

[29] E. R. Bickerstaff, P. C. Cloake, B. Hughes, and W. T. Smith, "The racemose form of cerebral cysticercosis," *Brain*, vol. 75, pp. 1–18, 1952.

[30] R. D. Lobato, E. Lamas, J. M. Portillo, et al., "Hydrocephalus in cerebral cysticercosis. Pathogenic and therapeutic considerations," *Journal of Neurosurgery*, vol. 55, no. 5, pp. 786–793, 1981.

[31] J. R. Keane, "Cysticercosis: unusual neuro-ophthalmologic signs," *Journal of Clinical Neuro-Ophthalmology*, vol. 13, no. 3, pp. 194–199, 1993.

[32] J. R. Keane, "Neuro-ophthalmologic signs and symptoms of cysticercosis," *Archives of Ophthalmology*, vol. 100, no. 9, pp. 1445–1448, 1982.

[33] F. Barinagarrementeria and O. H. Del Brutto, "Lacunar syndrome due to neurocysticercosis," *Archives of Neurology*, vol. 46, no. 4, pp. 415–417, 1989.

[34] J. L. Soto-Hernandez, S. G.-L. Andrade, L. A. Rojas-Echeverri, F. Texeira, and V. Romero, "Subarachnoid hemorrhage secondary to a ruptured inflammatory aneurysm: a possible manifestation of neurocysticercosis: case report," *Neurosurgery*, vol. 38, no. 1, pp. 197–200, 1996.

[35] F. Barinagarrementeria and C. Cantu, "Frequency of cerebral arteritis in subarachnoid cysticercosis: an angiographic study," *Stroke*, vol. 29, no. 1, pp. 123–125, 1998.

[36] O. H. Del Brutto and J. Sotelo, "Neurocysticercosis: an update," *Reviews of Infectious Diseases*, vol. 10, no. 6, pp. 1075–1087, 1988.

[37] R. Jankowski, R. D. Zimmerman, and N. E. Leeds, "Cysticercosis presenting as a mass lesion at foramen of Monro," *Journal of Computer Assisted Tomography*, vol. 3, no. 5, pp. 694–696, 1979.

[38] J. S. King and Y. Hosobuchi, "Cysticercus cyst of the lateral ventricle," *Surgical Neurology*, vol. 7, no. 3, pp. 125–129, 1977.

[39] M. L. J. Apuzzo, W. R. Dobkin, C. S. Zee, J. C. Chan, S. L. Giannotta, and M. H. Weiss, "Surgical considerations in treatment of intraventricular cysticercosis. An analysis of 45 cases," *Journal of Neurosurgery*, vol. 60, no. 2, pp. 400–407, 1984.

[40] W. T. Couldwell, C.-S. Zee, and M. L. J. Apuzzo, "Definition of the role of contemporary surgical management in cisternal and parenchymatous cysticercosis cerebri," *Neurosurgery*, vol. 28, no. 2, pp. 231–237, 1991.

[41] A. C. Cuetter and R. J. Andrews, "Intraventricular neurocysticercosis: 18 consecutive patients and review of the literature," *Neurosurgical Focus*, vol. 12, article e5, 2002.

[42] C. S. Zee, H. D. Segall, M. L. Apuzzo, J. Ahmadi, and W. R. Dobkin, "Intraventricular cysticercal cysts: further neuroradiologic observations and neurosurgical implications," *American Journal of Neuroradiology*, vol. 5, no. 6, pp. 727–730, 1984.

[43] J. R. Keane, "Death from cysticercosis. Seven patients with unrecognized obstructive hydrocephalus," *Western Journal of Medicine*, vol. 140, no. 5, pp. 787–789, 1984.

[44] A. Salazar, J. Sotelo, H. Martinez, and F. Escobedo, "Differential diagnosis between ventriculitis and fourth ventricle cyst in neurocysticercosis," *Journal of Neurosurgery*, vol. 59, no. 4, pp. 660–663, 1983.

[45] F. U. Ahmad and B. S. Sharma, "Treatment of intramedullary spinal cysticercosis: report of 2 cases and review of literature," *Surgical Neurology*, vol. 67, no. 1, pp. 74–77, 2007.

[46] J. C. Bandres, A. C. White Jr., T. Samo, E. C. Murphy, and R. L. Harris, "Extraparenchymal neurocysticercosis: report of five cases and review of management," *Clinical Infectious Diseases*, vol. 15, no. 5, pp. 799–811, 1992.

[47] L. De Souza Queiroz, A. Pellegrini Filho Jr., D. Callegaro, and L. Lopez De Faria, "Intramedullary cysticercosis. Case report, literature review and comments on pathogenesis," *Journal of the Neurological Sciences*, vol. 26, no. 1, pp. 61–70, 1975.

[48] R. Garza Mercado, "Intramedullary cysticercosis," *Surgical Neurology*, vol. 5, no. 6, pp. 331–332, 1976.

[49] M. Natarajan, K. R. Ramasubramanian, and A. K. Muthu, "Intramedullary cysticercosis of spinal cord," *Surgical Neurology*, vol. 6, no. 3, pp. 157–158, 1976.

[50] E. D. Rocca and B. Neira, "Cysticercosis of the spine," *Revista de Neuro-Psiquiatria*, vol. 42, no. 2, pp. 96–103, 1979.

[51] F. Cabieses, M. Vallenas, and R. Landa, "Cysticercosis of the spinal cord," *Journal of Neurosurgery*, vol. 16, pp. 337–341, 1959.

[52] I. Akiguchi, T. Fujiwara, H. Matsuyama, H. Muranaka, and M. Kameyama, "Intramedullary spinal cysticercosis," *Neurology*, vol. 29, no. 11, pp. 1531–1534, 1979.

[53] N. A. Sabrosa and M. Zajdenweber, "Nematode infections of the eye: toxocariasis, onchocerciasis, diffuse unilateral subacute neuroretinitis, and cysticercosis," *Ophthalmology Clinics of North America*, vol. 15, no. 3, pp. 351–356, 2002.

[54] N. A. Sabrosa and E. C. de Souza, "Nematode infections of the eye: toxocariasis and diffuse unilateral subacute neuroretinitis," *Current Opinion in Ophthalmology*, vol. 12, no. 6, pp. 450–454, 2001.

[55] H. H. Garcia, O. H. Del Brutto, T. E. Nash, A. C. White Jr., V. C. W. Tsang, and R. H. Gilman, "New concepts in the diagnosis and management of neurocysticercosis (Taenia solium)," *American Journal of Tropical Medicine and Hygiene*, vol. 72, no. 1, pp. 3–9, 2005.

[56] H. R. Martinez, R. Rangel-Guerra, G. Elizondo, et al., "MR imaging in neurocysticercosis: a study of 56 cases," *American Journal of Neuroradiology*, vol. 10, no. 5, pp. 1011–1019, 1989.

[57] I. Madrazo, J. A. Garcia-Renteria, M. Sandoval, and F. J. Lopez Vega, "Intraventricular cysticercosis," *Neurosurgery*, vol. 12, no. 2, pp. 148–152, 1983.

[58] R. A. Rangel-Guerra, J. Herrera, G. Elizondo, and J. Gonzalez-Morantes, "Neurocysticercosis," *Archives of Neurology*, vol. 45, p. 492, 1988.

[59] K. S. Kim and P. E. Weinberg, "Spinal cysticercosis," *Surgical Neurology*, vol. 24, no. 1, pp. 80–82, 1985.

[60] G. Santin and J. Vargas, "Roentgen study of cysticercosis of central nervous system," *Radiology*, vol. 86, no. 3, pp. 520–528, 1966.

[61] P. M. Schantz, V. C. Tsang, and S. E. Maddison, "Serodiagnosis of neurocysticercosis," *Reviews of Infectious Diseases*, vol. 10, no. 6, pp. 1231–1233, 1988.

[62] V. C. W. Tsang, J. A. Brand, and A. E. Boyer, "An enzyme-linked immunoelectrotransfer blot assay and glycoprotein antigens for diagnosing human cysticercosis (Taenia solium)," *Journal of Infectious Diseases*, vol. 159, no. 1, pp. 50–59, 1989.

[63] M. Wilson, R. T. Bryan, J. A. Fried, et al., "Clinical evaluation of the cysticercosis enzyme-linked immunoelectrotransfer blot in patients with neurocysticercosis," *Journal of Infectious Diseases*, vol. 164, no. 5, pp. 1007–1009, 1991.

[64] D. Correa, M. A. Sandoval, L. J. S. Harrison, et al., "Human neurocysticercosis: comparison of enzyme immunoassay capture technique based on monoclonal and polyclonal antibodies for the detection of parasite products in cerebrospinal fluid," *Transactions of the Royal Society of Tropical Medicine and Hygiene*, vol. 83, no. 6, pp. 814–816, 1989.

[65] Nguekam, A. P. Zoli, P. Ongolo-zogo, P. Dorny, J. Brandt, and S. Geerts, "Follow-up of neurocysticercosis patients after treatment using an antigen detection ELISA," *Parasite*, vol. 10, no. 1, pp. 65–68, 2003.

[66] H. H. Garcia, R. M. E. Parkhouse, R. H. Gilman, et al., "Serum antigen detection in the diagnosis, treatment, and follow-up of neurocysticercosis patients," *Transactions of the Royal Society of Tropical Medicine and Hygiene*, vol. 94, no. 6, pp. 673–676, 2000.

[67] L. J. S. Harrison, G. W. P. Joshua, S. H. Wright, and R. M. E. Parkhouse, "Specific detection of circulating surface/secreted glycoproteins of viable cysticerci in Taenia saginata cysticercosis," *Parasite Immunology*, vol. 11, no. 4, pp. 351–370, 1989.

[68] H. H. Garcia, L. J. S. Harrison, R. M. E. Parkhouse, et al., "A specific antigen-detection ELISA for the diagnosis of human neurocysticercosis," *Transactions of the Royal Society of Tropical Medicine and Hygiene*, vol. 92, no. 4, pp. 411–414, 1998.

[69] H. H. Garcia, A. E. Gonzalez, R. H. Gilman, et al., "Circulating parasite antigen in patients with hydrocephalus secondary to neurocysticercosis," *American Journal of Tropical Medicine and Hygiene*, vol. 66, no. 4, pp. 427–430, 2002.

[70] A. Fleury, M. Hernández, M. Avila, et al., "Detection of HP10 antigen in serum for diagnosis and follow-up of subarachnoidal and intraventricular human neurocysticercosis," *Journal of Neurology, Neurosurgery and Psychiatry*, vol. 78, no. 9, pp. 970–974, 2007.

[71] H. H. Garcia, C. A. W. Evans, T. E. Nash, et al., "Current consensus guidelines for treatment of neurocysticercosis," *Clinical Microbiology Reviews*, vol. 15, no. 4, pp. 747–756, 2002.

[72] P. R. M. Bittencourt, C. M. Gracia, A. M. Gorz, S. Mazer, and T. V. Oliveira, "High-dose praziquantel for neurocysticercosis: efficacy and tolerability," *European Neurology*, vol. 30, no. 4, pp. 229–234, 1990.

[73] D. Botero and S. Castano, "Treatment of cysticercosis with praziquantel in Colombia," *American Journal of Tropical Medicine and Hygiene*, vol. 31, no. 4, pp. 811–821, 1982.

[74] M. Cruz, I. Cruz, and J. Horton, "Albendazole versus praziquantel in the treatment of cerebral cysticercosis: clinical evaluation," *Transactions of the Royal Society of Tropical Medicine and Hygiene*, vol. 85, no. 2, pp. 244–247, 1991.

[75] L. D. deGhetaldi, R. M. Norman, and A. W. Douville Jr., "Cerebral cysticercosis treated biphasically with dexamethasone and praziquantel," *Annals of Internal Medicine*, vol. 99, no. 2, pp. 179–181, 1983.

[76] S.-K. Kim, K.-C. Wang, S.-H. Paek, K.-S. Hong, and B.-K. Cho, "Outcomes of medical treatment of neurocysticercosis: a study of 65 cases in Cheju Island, Korea," *Surgical Neurology*, vol. 52, no. 6, pp. 563–569, 1999.

[77] P. M. Lawner, "Medical management of neurocysticercosis with praziquantel," *Bulletin of Clinical Neurosciences*, vol. 48, pp. 102–105, 1983.

[78] R. Leblanc, K. F. Knowles, D. Melanson, J. D. MacLean, G. Rouleau, and J. P. Farmer, "Neurocysticercosis: surgical and medical management with praziquantel," *Neurosurgery*, vol. 18, no. 4, pp. 419–427, 1986.

[79] K. Markwalder, K. Hess, A. Valavanis, and F. Witassek, "Cerebral cysticercosis: treatment with praziquantel. Report of two cases," *American Journal of Tropical Medicine and Hygiene*, vol. 33, no. 2, pp. 273–280, 1984.

[80] J. Sotelo, O. H. del Brutto, P. Penagos, et al., "Comparison of therapeutic regimen of anticysticercal drugs for parenchymal brain cysticercosis," *Journal of Neurology*, vol. 237, no. 2, pp. 69–72, 1990.

[81] J. Sotelo, F. Escobedo, and P. Penagos, "Albendazole vs praziquantel for therapy for neurocysticercosis. A controlled trial," *Archives of Neurology*, vol. 45, no. 5, pp. 532–534, 1988.

[82] A. Spina-Franca, J. P. S. Nobrega, J. A. Livramento, and L. R. Machado, "Administration of praziquantel in neurocysticercosis," *Tropenmedizin und Parasitologie*, vol. 33, no. 1, pp. 1–4, 1982.

[83] O. M. Takayanagui and E. Jardim, "Therapy for neurocysticercosis: comparison between albendazole and praziquantel," *Archives of Neurology*, vol. 49, no. 3, pp. 290–294, 1992.

[84] S. Agapejev, D. A. Meira, B. Barraviera, et al., "Neurocysticercosis: treatment with albendazole and dextrochloropheniramine. (preliminary report)," *Revista do Instituto de Medicina Tropical de Sao Paulo*, vol. 30, no. 5, pp. 387–389, 1988.

[85] F. Alarcon and J. C. Maldonado, "Short course of albendazole therapy for neurocysticercosis," *Clinical Neurology and Neurosurgery*, vol. 108, no. 8, pp. 810–811, 2006.

[86] D. Botero, C. S. Uribe, J. L. Sanchez, et al., "Short course albendazole treatment for neurocysticercosis in Columbia," *Transactions of the Royal Society of Tropical Medicine and Hygiene*, vol. 87, no. 5, pp. 576–577, 1993.

[87] H. H. Garcia, R. H. Gilman, J. Horton, et al., "Albendazole therapy for neurocysticercosis: a prospective double-blind trial comparing 7 versus 14 days of treatment," *Neurology*, vol. 48, no. 5, pp. 1421–1427, 1997.

[88] P. C. Sanchetee, S. Venkataraman, R. M. Dhamija, and A. K. Roy, "Albendazole therapy for neurocysticercosis," *The Journal of the Association of Physicians of India*, vol. 42, no. 2, pp. 116–117, 1994.

[89] M. L. Vazquez, H. Jung, and J. Sotelo, "Plasma levels of praziquantel decrease when dexamethasone is given simultaneously," *Neurology*, vol. 37, no. 9, pp. 1561–1562, 1987.

[90] A. K. Baranwal, P. D. Singhi, N. Khandelwal, and S. C. Singhi, "Albendazole therapy in children with focal seizures and single small enhancing computerized tomographic lesions: a randomized, placebo-controlled, double blind trial," *Pediatric Infectious Disease Journal*, vol. 17, no. 8, pp. 696–700, 1998.

[91] A. K. Baranwal, P. D. Singhi, S. C. Singhi, and N. Khandelwal, "Seizure recurrence in children with focal seizures and single small enhancing computed tomographic lesions: prognostic factors on long-term follow-up," *Journal of Child Neurology*, vol. 16, no. 6, pp. 443–445, 2001.

[92] P. Singhi, M. Ray, S. Singhi, and N. Khandelwal, "Clinical spectrum of 500 children with neurocysticercosis and response to albendazole therapy," *Journal of Child Neurology*, vol. 15, no. 4, pp. 207–213, 2000.

[93] M. V. Padma, M. Behari, N. K. Misra, and G. K. Ahuja, "Albendazole in single CT ring lesions in epilepsy," *Neurology*, vol. 44, no. 7, pp. 1344–1346, 1994.

[94] A. Carpio, E. A. Kelvin, E. Bagiella, et al., "Effects of albendazole treatment on neurocysticercosis: a randomised controlled trial," *Journal of Neurology, Neurosurgery and Psychiatry*, vol. 79, no. 9, pp. 1050–1055, 2008.

[95] V. Vazquez and J. Sotelo, "The course of seizures after treatment for cerebral cysticercosis," *The New England Journal of Medicine*, vol. 327, no. 10, pp. 696–701, 1992.

[96] O. H. Del Brutto, K. L. Roos, C. S. Coffey, and H. H. Garcia, "Meta-analysis: cysticidal drugs for neurocysticercosis: albendazole and praziquantel," *Annals of Internal Medicine*, vol. 145, no. 1, pp. 43–51, 2006.

[97] S. Kaur, P. Singhi, and N. Khandelwal, "Combination therapy with albendazole and praziquantel versus albendazole alone in children with seizsures and single lesion neurocysticercosis: a randomized placebo-controlled double blind trial," *Pediatric Infectious Disease Journal*, vol. 28, no. 5, pp. 403–406, 2009.

[98] P. R. M. Bittencourt, C. M. Gracia, R. Martins, A. G. Fernandes, H. W. Diekmann, and W. Jung, "Phenytoin and carbamazepine decrease oral bioavailability of praziquantel," *Neurology*, vol. 42, no. 3, pp. 492–496, 1992.

[99] E. Mitre, K. R. Talaat, M. R. Sperling, and T. E. Nash, "Methotrexate as a corticosteroid-sparing agent in complicated neurocysticercosis," *Clinical Infectious Diseases*, vol. 44, no. 4, pp. 549–553, 2007.

[100] P. B. Keiser and T. E. Nash, "Prolonged perilesional edema after treatment of parenchymal neurocysticercosis: methotrexate as a corticosteroid-sparing agent," *Clinical Infectious Diseases*, vol. 36, no. 10, pp. e122–e126, 2003.

[101] J. Sotelo and C. Marin, "Hydrocephalus secondary to cysticercotic arachnoiditis. A long-term follow-up review of 92 cases," *Journal of Neurosurgery*, vol. 66, no. 5, pp. 686–689, 1987.

[102] J. V. Proano, I. Madrazo, F. Avelar, B. Lopez-Felix, G. Diaz, and I. Grijalva, "Medical treatment for neurocysticercosis characterized by giant subarachnoid cysts," *The New England Journal of Medicine*, vol. 345, no. 12, pp. 879–885, 2001.

[103] O. H. Del Brutto, "Albendazole therapy for subarachnoid cysticerci: clinical and neuroimaging analysis of 17 patients," *Journal of Neurology, Neurosurgery and Psychiatry*, vol. 62, no. 6, pp. 659–661, 1997.

[104] J. V. Proao, I. Madrazo, L. Garcia, E. Garcia-Torres, and D. Correa, "Albendazole and praziquantel treatment in neurocysticercosis of the fourth ventricle," *Journal of Neurosurgery*, vol. 87, no. 1, pp. 29–33, 1997.

[105] F. Góngora-Rivera, J. L. Soto-Hernández, D. González Esquivel, et al., "Albendazole trial at 15 or 30 mg/kg/day for subarachnoid and intraventricular cysticercosis," *Neurology*, vol. 66, no. 3, pp. 436–438, 2006.

[106] A. C. Cuetter, J. Garcia-Bobadilla, L. G. Guerra, F. M. Martinez, and B. Kaim, "Neurocysticercosis: focus on intraventricular disease," *Clinical Infectious Diseases*, vol. 24, no. 2, pp. 157–164, 1997.

[107] C. S. Zee, H. D. Segall, S. Destian, J. Ahmadi, and M. L. J. Apuzzo, "MRI of intraventricular cysticercosis: surgical implications," *Journal of Computer Assisted Tomography*, vol. 17, no. 6, pp. 932–939, 1993.

[108] B. O. Colli, N. Martelli, J. A. Assirati Jr., H. R. Machado, and S. de Vergueiro Forjaz, "Results of surgical treatment of neurocysticercosis in 69 cases," *Journal of Neurosurgery*, vol. 65, no. 3, pp. 309–315, 1986.

[109] M. Bergsneider, L. T. Holly, J. H. Lee, W. A. King, and J. G. Frazee, "Endoscopic management of cysticercal cysts within the lateral and third ventricles," *Journal of Neurosurgery*, vol. 92, no. 1, pp. 14–23, 2000.

[110] M. Bergsneider, "Endoscopic removal of cysticercal cysts within the fourth ventricle: technique and results," *Neurosurgical Focus*, vol. 6, article e8, 1999.

[111] T. Gravori, T. Steineke, and M. Bergsneider, "Endoscopic removal of cisternal neurocysticercal cysts. Technical note," *Neurosurgical Focus*, vol. 12, no. 6, article e7, 2002.

[112] B. Anandh, A. Mohanty, S. Sampath, S. S. Praharaj, and S. Kolluri, "Endoscopic approach to intraventricular cysticercal lesions," *Minimally Invasive Neurosurgery*, vol. 44, no. 4, pp. 194–196, 2001.

Hindawi Publishing Corporation
Interdisciplinary Perspectives on Infectious Diseases
Volume 2009, Article ID 474368, 7 pages
doi:10.1155/2009/474368

Review Article

Human Cystic Echinococcosis: Old Problems and New Perspectives

Alessandra Siracusano,[1] Antonella Teggi,[2] and Elena Ortona[1]

[1] *Dipartimento di Malattie Infettive, Parassitarie e Immunomediate, Istituto Superiore di Sanità, Viale Regina Elena 299, 00161 Roma, Italy*
[2] *Dipartimento di Malattie Infettive e Tropicali, Ospedale Sant'Andrea, Università di Roma, "Sapienza", 00189 Roma, Italy*

Correspondence should be addressed to Alessandra Siracusano, siracusano@iss.it

Received 4 March 2009; Revised 18 June 2009; Accepted 24 August 2009

Recommended by Louis M. Weiss

Cystic echinococcosis (CE) is a widespread chronic endemic helminthic disease caused by infection with metacestodes of the tapeworm *Echinococcus granulosus*. CE affects humans and has a worldwide prevalence of approximately six million. In this review, we discuss current findings in diagnosis and clinical management of CE and new concepts relating to *E. granulosus* molecules that directly modulate the host immune responses favouring a strong anti-inflammatory response and perpetuating parasite survival in the host. New insights into the molecular biology of *E. granulosus* will improve considerably our knowledge of the disease and will provide new potential therapeutic applications to treat or prevent inflammatory immune-mediated disease.

1. Introduction

Although effective preventive and therapeutic measures have been developed for most parasitic helminths, cystic echinococcosis (CE) infection is still very common in the developing world today. CE, a widely chronic endemic helminthic disease caused by infection with metacestodes (larval stage) of the tapeworm *Echinococcus granulosus*, is one of the most widespread Helminth zoonotic diseases in humans [1–5]. *E. granulosus* metacestode infections are characterized by the development of slowly growing hydatid cysts which may not be detected for months or years after the initial infection has occurred. The persistence of these cysts is of interest to immunologists since, once fully formed, they are apparently unaffected by the hosts immune response. The host parasite relationship is interactive and the outcome of infection depends on the balance achieved by the combination of the different variables involved with the host immunity and the parasite avoidance strategies. An understanding of the biological events occurring during infection is necessary to visualize the diverse immune stimuli to which the host is subjected and to define diagnostic and therapeutic tools. The evidence suggests that the intermediate hosts respond independently to antigenic stimuli of the invading oncosphere, the metacestode in transformation from the oncosphere, and finally, the mature metacestode (larvae) [6].

The oncospheres hatch and become activated in the small intestine when a suitable intermediate host ingests *Echinococcus* eggs. Lytic secretions of the oncosphere then facilitate its passage through the intestinal mucosa and into the host circulatory system (venous and lymphatic) through which they are distributed to the liver, lungs, and other sites where postoncospheral development continues. Within a few days after, oncospheres reach the preferred site, cystic development begins. This process involves degeneration of the oncospheral stage and emergence of the metacestode stage. In vitro 4–7 days are required for larvae to change into a typical "bladder" with a germinal layer. Subsequently, development time varies widely from one host species to another. In general, hydatid cysts increase in diameter from less than 1 to 5 cm each year. The mature hydatid cyst consists of an inner germinal layer of cells supported externally by an acellular-laminated membrane of variable thickness. Tegumental cells of the germinal layer unite to form a continuous syncytium which is differentiated into numerous microvilli that project peripherally into the laminar layer toward the host tissues surrounding the hydatid cyst. Small secondary

cysts called "brood capsules" bud internally from the germinative layer and, by asexual reproduction, produce multiple protoscoleces that can differentiate either into adult worms in the intestines of definitive hosts or into secondary hydatid cysts following rupture of a cyst in the intermediate hosts.

Because the oncosphere is known to be associated with the protective immune response, understanding the mechanisms, whereby protective antibodies against the oncoshere act, is of fundamental importance in developing highly effective vaccine against *E. granulosus* [6]. A vaccine based on the recombinant oncosphere protein, Eg95, has been produced for prevention of infection in the parasite's natural animal intermediate hosts [7, 8].

2. Clinical Aspects: Diagnosis and Therapy

Despite the advances in modern imaging and therapeutic strategies, problems associated with the diagnosis and treatments of human CE are still challenging and often difficult to resolve. Early diagnosis is important, because prompt intervention enables efficient management and treatment of the disease and results in reduced morbidity and mortality. Initially, cysts are small and patients are asymptomatic [9, 10]. Cysts in such instances are too small, too young, to pose clinical problems; usually they are single and localized in a neutral space in liver or lungs. The cysts may heal spontaneously by inconspicuous rupture and evacuation, or by degenerative and/or necrotic processes leading to a solidification and/or calcification of the cysts. Apart from lung cysts, which are more often symptomatic also if they are very small, symptomatic cases of CE are usually those with the cyst's diameter >5 cm. In most cases initially, the clinical diagnosis of CE is difficult and requires, beside the physical examination, imaging techniques and serology [11, 12]. As the cysts grow, however, they can exert mechanical pressure on surrounding organs and can cause several pathological changes mediated by compression or obstruction. Large amounts of hydatid fluid, after cyst rupture, can result in anaphylactic reaction that varies widely from benign urticaria and short episodes of shaking chills and/or fever, to a potentially fatal bronchial spasm, angioneurotic oedema, and anaphylactic shock. Cyst rupture can also result in a secondary hydatid infection caused by the release of many thousands of protoscoleces, which each have the potential to differentiate into another hydatid cyst.

Introduction of ultrasound (US) in the late 1970s has greatly improved the detection of liver and abdominal *Echinococcus* cysts and differential diagnosis from common nonparasitic true cysts and pseudocysts of traumatic, degenerative, inflammatory, and malignant origin. In particular, this noninvasive, low-risk, and low-cost examination can also have a positive educational effect in endemic communities [13]. The combination of US and confirmatory serology is now a standard approach for clinical and epidemiological surveys [14]. Whereas hepatic cysts can be preferentially diagnosed by US, hydatid cysts localized in lungs or in other organs than liver and abdomen can be successfully diagnosed by computerized tomography (CT) or Nuclear Magnetic Resonance imaging (NMR). In 2001, the WHO Informal Working group on Echinococcosis proposed an international classification of hepatic cysts based on US morphology correlated to the activity of the disease [10, 15]. Following the WHO classification, hepatic hydatid cysts are grouped into five major cyst types, CE1-CE5, characterized by the appearance of the cyst contents and wall. Using such classification has enabled clinicians to examine recommended clinical procedures for the different cyst types. If "Cystic Lesions" are defined as suspicious lesions, and if due to CE, then these cysts are usually at an early stage of development and are not fertile. Type CE1 (unilocular, simple cysts) and type CE2 (multivescicular, multiseptated cysts) are considered as active since they are likely to contain viable protoscoleces. Type CE3 (unilocular cysts with detachment of laminated membrane or multiseptated cysts with partial hyperechoic content) are considered as transitional and might represent the beginnings of cyst degeneration. Type CE4 (heterogeneous or hyperechoic degenerative contents) and type CE5 (calcified cysts) are considered inactive, as the parasite tissue is likely to be of low viability. Actually, we can consider the current WHO classification as a progressive natural history of cyst development from CE1 to CE5. It is of huge importance to understand the possible developmental fate of a cyst, but US imaging alone cannot predict the clinical fate of a cyst. Cysts classified by US as identical in clinical type may have distinctly differing fates: some will ultimately progress whereas others will regress (mainly, types CE3 and CE4). New interesting observation on the immunological mechanisms underlying these distinct outcomes indicate that the serologic profile associated with cysts of the same ultrasonographic type (type CE 3-4-5) correlates with the fate of the cyst: higher IgG1 and IgG3 in stable disease and higher IgG4 and IgE in progressive disease [16]. Because the advanced diagnostic techniques used today, for example, ultrasound scanning, detect even young (early stage) cysts (less than 2 cm in diameter) and calcified (late stage) cysts, providing more sensitive serological tests which are still a pressing research aim. In fact, a key problem for immunodiagnosis is the increasing numbers of seronegative patients or low responders, who still have too few antibodies detectable by serologic tests. To overcome problems of cross-reactions with other parasite antigens in countries with endemic disease, it is important to have new more antigens that are specific. The correct diagnosis of CE involves clinical, laboratory, and epidemiological information. As far as possible, alternative diagnostic methods are obligatory for suspected CE images in the US [10]. In fact, without confirmation of immunological tests, clinical and/or imaging technique diagnosis is not certain, unless for histological and/or cytological examination, being CE cysts hardly distinguished from "space occupying lesions" [5, 17]. Immunodiagnosis is useful not only for the primary diagnosis but also for the follow-up of patients after surgical or pharmacological treatment, or both [10, 17]. Hydatid serological testing has a long history and almost all serological tests that have been developed have been used in the diagnosis of human cases. The choice of a serodiagnostic technique depends primarily on its sensitivity and specificity. The first problem is that most conventional tests give a high percentage of

false-negative results (up to 25%). Secondly, false-positive reactions are present in areas where *E. granulosus* and *E. multilocularis* coexist and in areas where other parasitic diseases are endemic. An optimum test should be specific with high sensitivity. Immunodiagnostic techniques include initial screening tests, using crude antigens, such as latex agglutination, double diffusion, indirect hemagglutination, and enzyme-linked immunosorbent assay, followed by confirmatory tests using specific antigens, for example, arc-5 immunoelectrophoresis and immunoblotting [11, 12]. In particular, immunoblotting technique uses antibodies to identify specific target proteins and is now widely employed in routine laboratory applications for the analysis of immune responses [5]. Another diagnostic strategy for identifying active or current infections is to develop a technique for detecting circulating antigen in serum and urine [18, 19].

The history of immunodiagnosis represents the history of *Echinococcus* antigens because the choice of an appropriate source of antigenic material is a crucial point in the immunodiagnosis [5]. As the intermediate host of *E. granulosus,* humans are exposed to a variety of antigenic determinants on parasite-derived or parasite-modified molecules; each of these various sources of antigenic stimulation may be relevant to immunodiagnosis. The repertoire of antigens to which the host is exposed includes many factors, for example, the species or strain of parasite, host immunocompetence, organ parasitised, cyst fertility, cyst viability, and integrity of the cyst wall [20]. Antigens derived from *Echinococcus* oncospheres have not yet been successfully adapted to immunodiagnostic tests; however, such antigens provide theoretical advantages over metacestode stage antigens for a variety of purposes, including early detection of infection.

Extensive studies have focused on hydatid fluid antigens that still represent the main antigenic source for hydatid disease diagnosis. At the present time, the parasitic antigens present in hydatid fluid that have major immunodiagnostic value in detecting *E. granulosus* are antigen 5 (Ag5) and antigen B (AgB) [21]. Native Ag5, a 400 kDa thermolabile lipoprotein produces two subunits at 55 and 65 kDa in sodium-dodecyl sulphate-polyacrilamide gel electrophoresis (SDS-PAGE) under nonreducing conditions and two subunits at 38/39 and 20 kDa under reducing conditions [22, 23]. The 38/39 kDa component with phosphorylcholine epitopes may be responsible for a large proportion of cross-reactions with sera from patients infected with nematodes, cestodes, and trematodes [24–26]. Native AgB, a 160 kDa thermostable lipoprotein, produces three main subunits at 8/12, 16, and 20 kDa in SDS-PAGE under reducing and nonreducing conditions as well as other mass-subunits, probably polymers of the 8/12 kDa subunit [27]. The 8/12 kDa subunit induces a good humoral and cellular response [28]. Even though the 8/12 kDa subunit of AgB is cross-reactive in a high-percentage patients with alveolar echinococcosis sera and in a small percentage of patients with cysticercosis, native AgB is of high immunodiagnostic value [21, 24, 29].

To overcome some problems several recombinant antigens have been produced and used as molecular tools in the immunodiagnosis of CE [5, 30]. Although a few studies have assessed the diagnostic usefulness of recombinant Ag5 intense research has evaluated recombinant AgB and synthetic peptides that could be used in immunodiagnosis of CE [30–32]. To date, the only peptide that has proved diagnostic is that derives from the sequence of EgAgB1p176 [33]. Although native and recombinant antigens yield similar sensitivity, both have advantages and disadvantages [31]. Native antigens have to be extracted from the various sources, purified and prepared for use in each laboratory. They are, therefore, of limited availability, and nonstandardized in quality and composition. Recombinant antigens, usually commercially prepared and then distributed to the various diagnostic centres, have the advantage of being standardized in quality and composition.

For many years, surgery has been considered the only treatment available for CE because of the potential radical removing of the parasite. Nowadays, besides surgery, clinical management of CE may relies on several therapeutic approaches ranging from chemotherapy with benzoimidazole carbamates (mebendazole and albendazole) to percutaneous nonconventional treatment, like PAIR, or Radio-Frequency Thermoablation, or "wait and see" approach [9]. New guidelines on clinical management of liver CE suggest that there is not a single "golden rule" but it is very important to individualize the treatment of choice for each patient and for each hydatid cyst [9, 13, 34, 35]. A series of early articles have comprehensively reviewed the clinical management of CE [9, 13, 36, 37]. Here, we consider the more recent progress in the clinical management during hepatic involvement of CE. In the therapeutic approach to liver CE, it is advisable to distinguish the cases in which there is a concordance between clinical and serological data and imaging findings, and the cases in which these findings are discordant. In the first cases, and for no complicated small hepatic cysts (of diameter <5 cm, CE4-CE5 type), it is possible to take into account the "wait and see" approach because inactive cysts that do not compromise organ function or cause discomfort, seem to remain like this or stabilize even further. When clinical, immunological data and US findings are not concordant or when the cysts are complicated, surgery represents the first choice treatment [9, 13]. Surgery is indicated for large hepatic cysts with multiple daughter cysts; for single hepatic cysts, situated superficially, which may rupture spontaneously, or because of trauma; for cysts that are infected; for cysts communicating with biliary tree and/or exerting pressure on adjacent vital organs. Because curative surgery is not always possible, there is a 2–15% risk of relapse in hyperendemic areas and moderate ranges of morbidity in particular when the surgery is repeated. During surgery, the cyst can break spontaneously or the surgical damage of the cyst can lead to spillage and widespread dissemination [9, 36, 37].

Chemotherapy with benzoimidazole carbamates (mebendazole or albendazole), once reserved for inoperable cases of CE, is now more widely used [34, 37–41]. Benzamidazole carbamates inhibit tubulin and induce blockage of glucose absorption, glycogen depletion, and degenerative modifications in the endoplasmatic reticulum and in mitochondria of the germinal layer increasing lysosomes and producing

cellular autolysis [41]. Mebendazole and albendazole have the same mechanism of action; albendazole shows a better pharmacokinetic profile reaching higher plasmatic concentrations than mebendazole. At present, a cycle of albendazole treatment can be suggested as first choice treatment in patients with no complicated cysts and in patients without contraindications to chemotherapy (pregnancy, marked impairment of liver, renal or haemopoietic functionality). Most of the cysts treated with benzoimidazole carbamates show degenerative modifications (volumetric reduction and/or morphological alterations, such as solidification, detaching of membranes, and calcification) whose further evolution can hardly be predicted: in some cysts these degenerative modifications progressed until the parasite's death (biological recovery), while some cysts recurred after the end of treatment. Apart quantitative differences due to a more effectiveness of albendazole for hepatic cysts, albendazole, and mebendazole show similar effects. Treatment with benzoimidazole carbamates is effective and well tolerated but can be affected by many factors related both to the host and to the parasite. Both albendazole and mebendazole are more effective in cycles of continuous treatment, without intervals. It is relevant to note that young cysts and cysts of young people are more responsive, probably because these cysts present a higher metabolic activity and a greater susceptibility to the drugs. Benzoimidazole carbamates are more effective against cysts in the lung than against cysts in the liver that may be because of their thinner membranes. Regarding the type of hepatic cysts, CE1 cysts frequently show membrane detachment after treatment, while CE2 cysts frequently show matrix solidification. Sometimes cysts of the same patient with the same morphology and localized in the same organ may differently respond to therapy probably because have a different intrinsic sensitivity to drugs. Some treated patients' exhibit relapses, but these are usually sensitive to retreatment in high proportion of cases (up to 90%) [42]. Chemotherapy with benzoimidazole carbamates appears to be safe and well tolerated, the main adverse events are to changes in transaminases (<5-fold the normal range), observed in about 15% of the patients. To note, this side-effect is reversible, because transaminase value returned to normal without stopping treatment and it was mainly observed in patients with hepatic cysts and effectiveness of therapy [37, 43]. The increase in transaminases may be caused by the inflammatory immune response to the antigenic spillage from the hepatic cysts damaged by benzimidazole carbamates, and because correlates with the effectiveness of therapy could be considered as a prognostic marker. This finding further supports the importance of immune-mediate mechanisms in the clinical outcome of chemotherapy of CE, as observed for antibiotic treatment and innate and cell-mediated immunity. Because there is no doubt that, as an adjuvant therapy, chemotherapy can significantly contribute to the successful management of CE, the search for new drugs is ongoing [44].

In the last two decades, the percutaneous treatment by Puncture of the cyst, Aspiration of cyst fluid, Injection of a scolicidal agent, and reaspiration of the cyst content percutaneous (PAIR) under sonographic guidance has gained an important role in the treatment of CE; its efficacy has been confirmed both by short- and long-term follow-up. The aim of this treatment is to destroy the germinal layers with scolicidal agents or to evacuate the germinal and laminated layers, that is, the entire endocyst [45]. Percutaneous drainage of echinococcal cysts is effective and safe, as shown by the very low complication rate. Because neither imaging modalities nor serology is sufficient to assess directly the presence of parasites in the cyst, PAIR is the only method providing a direct diagnosis of the parasitic nature of the cysts. The major risks of percutaneous techniques are anaphylactic shock, secondary echinococcosis caused by spillage of cystic fluid, and chemical colangitis caused by contact of the scolicidal agent with the biliary tree.

Radiofrequency thermal ablation uses the same needle electrodes used for local treatments or hepatocellular carcinomas [46]. The experience with radiofrequency thermal ablation is still very limited; however, it does not seem to be very effective at long-term follow-up [13].

3. New Promising Perspectives from the Host-Parasite Relationship

Evidence from epidemiological studies indicates an inverse correlation between the incidence of certain immune-mediated diseases, including inflammatory bowel disease, and exposure to Helminth. Helminth parasites are the classic inducers of anti-inflammatory Th2 responses. Cross-regulatory suppression of the Th1 responses by a strong Th2 response has a role in modulating diseases characterized by a Th1 response. In particular, the Th2-polarized T cell response driven by Helminth infection correlates with the attenuation of some damaging Th1-driven inflammatory responses, preventing some Th1-mediated autoimmune diseases in the host [47–49].

Current evidence concerning antibody levels of IgG4 and IgE isotypes and frequent eosinophilia in CE suggests that the immune response to established *E. granulosus* infection is Th2 dominated and that *Echinococcus* antigens modulate polarized T-cells. These observations received confirmation from studies showing that the human immune response to *E. granulosus* infection is predominantly regulated by Th2 cell activation (in vitro production of IL-4, IL-5, IL-6, IL-10 by PBMC isolated from patients with CE) and also by the Th1 (or Th0) cell subset (IFN-γ production) [50]. Many findings indicated that in CE a strong Th2 response correlates with susceptibility to disease (active cyst), whereas a Th1 response correlates with protective immunity (inactive cyst) and that Th1 and Th2 responses coexist [6, 50, 51].

During CE, the distinguishing feature of the host-parasite relationship is that chronic infection coexists with detectable humoral and cellular responses against the parasite. *E. granulosus* could use two mechanisms to subvert the host immune response: passive escape, in which the parasite, by developing into a hydatid cyst, avoids the damaging effects of an immune response, and immunomodulation, through which the parasite actively interacts with the host immune system to reduce the impact of a host response

[12]. Recent studies demonstrated that *E. granulosus* secretes several molecules present in protoscoleces and in hydatid fluid that directly can modulate the immune responses thus altering the cytokine balance towards Th2 and favouring their evasion and perpetuating their survival in the host [52–54]. These molecules interfere with antigen presentation, cell proliferation and activation, antibody production, cause cell death, and stimulate regulatory responses.

The abundance of AgB in hydatid fluid suggests that this antigen has an important biological role in *E. granulosus* infection. AgB is involved in modulating the host immune response altering both innate and adaptative host immune responses. The 12-kDa subunit of AgB is a protease inhibitor that can inhibit neutrophil recruitment and that has a critical role in parasite escape mechanisms from early natural immunity [55]. Investigating further, the role of AgB in the host-parasite relationship has been confirmed that AgB impairs the inflammatory response and influences the Th1/Th2 balance towards a Th2 polarization [56]. To note, *E. granulosus* AgB acts to escape the host immune response by interfering directly with host dendritic cell function through two strategies [57]. First, it impairs monocyte precursor differentiation into immature dendritic cells rendering them unable to mature when stimulated with LPS; secondly, AgB modulates sentinel dendritic cells maturation, priming them to polarize lymphocytes into Th2 cells.

The possibility that IgG subclasses from patients with active or inactive CE might contain antibodies against molecules involved in the host-parasite interaction has been extensively examined [58]. In vitro AgB driven Th2 cytokine production corresponds in vivo to elevated specific IgE and IgG4 antibody binding to the 8 kDa subunit of AgB [16, 58, 59]. A new immunomodulating antigen has been obtained by screening an *E. granulosus* cDNA library with IgG4 from patients with active disease: a protein localized in the protoscolex tegument and on the germinal layer of cyst wall, named EgTeg. However, EgTeg, similarly to AgB, inhibits chemotaxis and induces IL-4-positive T lymphocytes and noncomplement-fixing antibodies (IgG4) [60].

CE shares with other helmintiases three responses typical of immediate hypersensitivity reactions such as elevated IgE/IgG4 antibodies production, eosinophilia, and mastocitosis, which contribute to trigger a Th2-type environment. By screening an *E. granulosus* cDNA library with IgE from patients with CE with acute cutaneous allergic manifestations have been identified three conserved constitutive proteins: EgEF-1 β/δ, EA21, and Eg2HSP70 associated with allergic disorders related to CE [61–63].

The hygiene hypothesis arose from attempts to explain differences in allergy prevalence related to socioeconomic and geographical factors. An inverse relationship between helminthiasis and allergy has been clearly established despite both conditions being accompanied by strong Th2 immune responses. [64]. The CE example stresses the ambiguous links that exist between parasitic and allergic diseases, and shows how studying these disease can help to understand how immune deviation leads to pathological events and to find new immunomodulatory or preventive drugs or both [64].

4. Concluding Remarks and Future Directions

Despite the large efforts that have been put into the research and control of echinococcosis, it still remains a disease of worldwide significance. In some areas of the world, CE caused by *E. granulosus* is a re-emerging disease in places where it was previously at low levels. Although ultrasound images and benzoimidazole carbamates are very useful in the clinical treatment of CE, achieving complete healing of the infection require defining more clearly the immunological events that accompany changes in cyst morphology.

Exposure to Helminths may protect from immune-mediated diseases and this evidence suggests that Helminths may have served as a lid on a "Pandora's box" of immune pathology. *E. granulosus* has evolved to live within its mammalian host, and in order to do so appear to express a diverse array of molecules that have immune-modulating effects. These observations suggest that *E. granulosus* molecules could be used therapeutically to treat or prevent immune-mediated disease.

Future studies understanding the mechanisms of *E. granulosus* immune regulation, will potentially uncover novel compounds that alter inflammatory responses, and will address the myriad of questions surrounding their potential for clinical application.

Acknowledgment

This work was supported by a research grant from the Italian Ministry of Health (Project no. 8ABF/8)

References

[1] D. P. McManus, W. Zhang, J. Li, and P. B. Bartley, "Echinococcosis," *The Lancet*, vol. 362, pp. 1295–1304, 2003.

[2] P. S. Craig, D. P. McManus, M. W. Lightowlers, et al., "Prevention and control of cystic echinococcosis," *The Lancet Infectious Diseases*, vol. 7, no. 6, pp. 385–394, 2007.

[3] R. C. A. Thompson, "The taxonomy, phylogeny and transmission of *Echinococcus*," *Experimental Parasitology*, vol. 119, no. 4, pp. 439–446, 2008.

[4] P. Moro and P. M. Schantz, "Echinococcosis: a review," *International Journal of Infectious Diseases*, vol. 13, no. 2, pp. 125–133, 2008.

[5] W. Zhang and D. P. McManus, "Recent advances in the immunology and diagnosis of echinococcosis," *FEMS Immunology & Medical Microbiology*, vol. 47, no. 1, pp. 24–41, 2006.

[6] W. Zhang, A. G. Ross, and D. P. McManus, "Mechanisms of immunity in hydatid disease: implications for vaccine development," *Journal of Immunology*, vol. 181, no. 10, pp. 6679–6685, 2008.

[7] M. W. Lightowlers, S. B. Lawrence, C. G. Gauci, et al., "Vaccination against hydatidosis using a defined recombinant antigen," *Parasite Immunology*, vol. 18, no. 9, pp. 457–462, 1996.

[8] C. Gauci, D. Heath, C. Chow, and M. W. Lightowlers, "Hydatid disease: vaccinology and development of the EG95 recombinant vaccine," *Expert Review of Vaccines*, vol. 4, no. 1, pp. 103–112, 2005.

[9] Z. S. Pawlowski, "Critical points in the clinical management of cystic echinococcosis: a revised review," in *Compendium on*

Cystic Echinococcosis in Africa and Middle Eastern Countries with Special Reference to Morocco, F. L. Anderson, H. Ouhelli, and M. Kachemi, Eds., pp. 119–135, Brigham Young University Print Services, Provo, Utah, USA, 1997.

[10] WHO/OIE, "Echinococcosis in humans: clinical aspects, diagnosis and treatment," in *Manual on Echinococcosis in Humans and Animals: A Public Health Problem of Global Concern*, J. Eckert, M. A. Gemmell, F. X. Meslin, and Z. S. Pawlowski, Eds., pp. 20–66, World Organisation for Animal Health, Paris, France, 2001.

[11] M. W. Lightowlers and B. Gottstein, "Echinococcosis/hydatidosis: antigens, immunological and molecular diagnosis," in *Echinococcus and Hydatid Disease*, R. C. A. Thompson and A. J. Lymbery, Eds., pp. 355–410, CAB International, Wallingford, UK, 1995.

[12] W. Zhang, J. Li, and D. P. McManus, "Concepts in immunology and diagnosis of hydatid disease," *Clinical Microbiology Reviews*, vol. 16, no. 1, pp. 18–36, 2003.

[13] T. Junghanss, A. M. da Silva, J. Horton, P. L. Chiodini, and E. Brunetti, "Clinical management of cystic echinococcosis: state of the art, problems, and perspectives," *The American Journal of Tropical Medicine and Hygiene*, vol. 79, no. 3, pp. 301–311, 2008.

[14] Y. Wang, X. Zhang, B. Bartholomot, et al., "Classification, follow-up and recurrence of hepatic cystic echinococcosis using ultrasound images," *Transactions of the Royal Society of Tropical Medicine and Hygiene*, vol. 97, no. 2, pp. 203–211, 2003.

[15] WHO Informal Working Group, "International classification of ultrasound images in cystic echinococcosis for application in clinical and field epidemiological settings," *Acta Tropica*, vol. 85, no. 2, pp. 253–261, 2003.

[16] R. Riganò, S. Ioppolo, E. Ortona, et al., "Long-term serological evaluation of patients with cystic echinococcosis treated with benzimidazole carbamates," *Clinical & Experimental Immunology*, vol. 129, no. 3, pp. 485–492, 2002.

[17] E. Ortona, R. Riganò, B. Buttari, et al., "An update on immunodiagnosis of cystic echinococcosis," *Acta Tropica*, vol. 85, no. 2, pp. 165–171, 2003.

[18] P. S. Craig, "Detection of specific circulating antigen, immune complexes and antibodies in human hydatidosis from Turkana (Kenya) and Great Britain, by enzyme-immunoassay," *Parasite Immunology*, vol. 8, no. 2, pp. 171–188, 1986.

[19] C. S. Devi and S. C. Parija, "A new serum hydatid antigen detection test for diagnosis of cystic echinococcosis," *The American Journal of Tropical Medicine and Hygiene*, vol. 69, no. 5, pp. 525–528, 2003.

[20] M. D. Rickard and J. F. Williams, "Hydatidosis/cysticercosis: immune mechanisms and immunization against infection," *Advances in Parasitology*, vol. 21, pp. 229–296, 1982.

[21] D. Carmena, A. Benito, and E. Eraso, "Antigens for the immunodiagnosis of *Echinococcus granulosus* infection: an update," *Acta Tropica*, vol. 98, no. 1, pp. 74–86, 2006.

[22] M. Piantelli, R. Pozzuoli, E. Arru, and P. Musiani, "*Echinococcus granulosus*: identification of subunits of the major antigens," *Journal of Immunology*, vol. 119, no. 4, pp. 1382–1386, 1977.

[23] C. Lorenzo, H. B. Ferreira, K. M. Monteiro, et al., "Comparative analysis of the diagnostic performance of six major *Echinococcus granulosus* antigens assessed in a double-blind, randomized multicenter study," *Journal of Clinical Microbiology*, vol. 43, no. 6, pp. 2764–2770, 2005.

[24] J. C. Shepherd and D. P. McManus, "Specific and cross-reactive antigens of *Echinococcus granulosus* hydatid cyst fluid," *Molecular and Biochemical Parasitology*, vol. 25, no. 2, pp. 143–154, 1987.

[25] S. E. Maddison, S. B. Slemenda, P. M. Schantz, J. A. Fried, M. Wilson, and V. C. W. Tsang, "A specific diagnostic antigen of *Echinococcus granulosus* with an apparent molecular weight of 8 kDa," *The American Journal of Tropical Medicine and Hygiene*, vol. 40, no. 4, pp. 377–383, 1989.

[26] M. W. Lightowlers, D. Liu, A. Haralambous, and M. D. Rickard, "Subunit composition and specificity of the major cyst fluid antigens of *Echinococcus granulosus*," *Molecular and Biochemical Parasitology*, vol. 37, no. 2, pp. 171–182, 1989.

[27] W. Mamuti, Y. Sako, M. Nakao, et al., "Recent advances in characterization of *Echinococcus* antigen B," *Parasitology International*, vol. 55, supplement 1, pp. S57–S62, 2006.

[28] A. Siracusano, P. Margutti, F. Delunardo, et al., "Molecular cross-talk in host-parasite relationships: the intriguing immunomodulatory role of *Echinococcus* antigen B in cystic echinococcosis," *International Journal for Parasitology*, vol. 38, no. 12, pp. 1371–1376, 2008.

[29] A. Ito, L. Ma, P. M. Schantz, et al., "Differential serodiagnosis for cystic and alveolar echinococcosis using fractions of *Echinococcus granulosus* cyst fluid (antigen B) and E. multilocularis protoscolex (Em18)," *The American Journal of Tropical Medicine and Hygiene*, vol. 60, no. 2, pp. 188–192, 1999.

[30] A. Siracusano, E. Ortona, and R. Riganò, "Molecular and cellular tools in human cystic echinococcosis," *Current Drug Targets, Immune, Endocrine & Metabolic Disorders*, vol. 2, no. 3, pp. 235–245, 2002.

[31] G. González-Sapienza, C. Lorenzo, and A. Nieto, "Improved immunodiagnosis of cystic hydatid disease by using a synthetic peptide with higher diagnostic value than that of its parent protein, *Echinococcus granulosus* antigen B," *Journal of Clinical Microbiology*, vol. 38, no. 11, pp. 3979–3983, 2000.

[32] E. Ortona, R. Riganò, P. Margutti, et al., "Native and recombinant antigens in the immunodiagnosis of human cystic echinococcosis," *Parasite Immunology*, vol. 22, no. 11, pp. 553–559, 2000.

[33] G. González-Sapienza and R. E. Cachau, "Identification of critical residues of an immunodominant region of *Echinococcus granulosus* antigen B," *Journal of Biological Chemistry*, vol. 278, no. 22, pp. 20179–20184, 2003.

[34] A. Teggi, "An up-to-date on clinical management of human cystic echinococcosis," *Parassitologia*, vol. 46, no. 4, pp. 405–407, 2004.

[35] H. H. Garcia, P. L. Moro, and P. M. Schantz, "Zoonotic helminth infections of humans: echinococcosis, cysticercosis and fascioliasis," *Current Opinion in Infectious Diseases*, vol. 20, no. 5, pp. 489–494, 2007.

[36] K. Buttenschoen and D. C. Buttenschoen, "*Echinococcus granulosus* infection: the challenge of surgical treatment," *Langenbeck's Archives of Surgery*, vol. 388, no. 4, pp. 218–230, 2003.

[37] A. G. Saimot, "Medical treatment of liver hydatidosis," *World Journal of Surgery*, vol. 25, no. 1, pp. 15–20, 2001.

[38] C. Franchi, B. Di Vico, and A. Teggi, "Long-term evaluation of patients with hydatidosis treated with benzimidazole carbamates," *Clinical Infectious Diseases*, vol. 29, no. 2, pp. 304–309, 1999.

[39] P. Kern, "*Echinococcus granulosus* infection: clinical presentation, medical treatment and outcome," *Langenbeck's Archives of Surgery*, vol. 388, no. 6, pp. 413–420, 2003.

[40] M. E. Falagas and I. A. Bliziotis, "Albendazole for the treatment of human echinococcosis: a review of comparative clinical

trials," *The American Journal of the Medical Sciences*, vol. 334, no. 3, pp. 171–179, 2007.

[41] A. Teggi, M. G. Lastilla, and F. De Rosa, "Therapy of human hydatid disease with mebendazole and albendazole," *Antimicrobial Agents and Chemotherapy*, vol. 37, no. 8, pp. 1679–1684, 1993.

[42] A. Teggi, M. G. Lasilla, G. Grossi, C. Franchi, and F. De Rosa, "Increase of serum glutamic-oxaloacetic and glutamic-pyrivic transaminases in patients with hydatid cysts treated with mebendazole and albendazole," *Mediterranean Journal of Infectious and Parasitic Diseases*, vol. 10, p. 85, 1995.

[43] R. M. Matossian, G. N. Awar, H. Radwan, P. S. Craig, and G. A. Meshefedjian, "Immune status during albendazole therapy for hydatidosis," *Annals of Tropical Medicine and Parasitology*, vol. 86, no. 1, pp. 67–75, 1992.

[44] M. Stamatakos, C. Sargedi, Ch. Stefanaki, C. Safioleas, I. Matthaiopoulou, and M. Safioleas, "Anthelminthic treatment: an adjuvant therapeutic strategy against *Echinococcus granulosus*," *Parasitology International*, vol. 58, no. 2, pp. 115–120, 2009.

[45] C. Filice and E. Brunetti, "Use of PAIR in human cystic echinococcosis," *Acta Tropica*, vol. 64, no. 1-2, pp. 95–107, 1997.

[46] E. Brunetti and C. Filice, "Radiofrequency thermal ablation of echinococcal liver cysts," *The Lancet*, vol. 358, no. 9291, p. 1464, 2001.

[47] R. M. Maizels, A. Balic, N. Gomez-Escobar, M. Nair, M. D. Taylor, and J. E. Allen, "Helminth parasites—masters of regulation," *Immunological Reviews*, vol. 201, pp. 89–116, 2004.

[48] R. M. Maizels, "Infections and allergy—helminths, hygiene and host immune regulation," *Current Opinion in Immunology*, vol. 17, no. 6, pp. 656–661, 2005.

[49] R. Maizels and M. Yazdanbakhsh, "T-cell regulation in helminth parasite infections: implications for inflammatory diseases," *Chemical Immunology and Allergy*, vol. 94, pp. 112–123, 2008.

[50] R. Riganò, E. Profumo, S. Ioppolo, et al., "Immunological markers indicating the effectiveness of pharmacological treatment in human hydatid disease," *Clinical & Experimental Immunology*, vol. 102, no. 2, pp. 281–285, 1995.

[51] R. Riganò, E. Profumo, B. Buttari, A. Teggi, and A. Siracusano, "Cytokine gene expression in peripheral blood mononuclear cells (PBMC) from patients with pharmacologically treated cystic echinococcosis," *Clinical & Experimental Immunology*, vol. 118, no. 1, pp. 95–101, 1999.

[52] R. Riganò, B. Buttari, E. de Falco, et al., "*Echinococcus granulosus*-specific T-cell lines derived from patients at various clinical stages of cystic echinococcosis," *Parasite Immunology*, vol. 26, no. 1, pp. 45–52, 2004.

[53] A. Siracusano, R. Riganò, E. Ortona, et al., "Immunomodulatory mechanisms during *Echinococcus granulosus* infection," *Experimental Parasitology*, vol. 119, no. 4, pp. 483–489, 2008.

[54] D. A. Vuitton, "The ambiguous role of immunity in echinococcosis: protection of the host or of the parasite?" *Acta Tropica*, vol. 85, no. 2, pp. 119–132, 2003.

[55] J. C. Shepherd, A. Aitken, and D. P. McManus, "A protein secreted in vivo by *Echinococcus granulosus* inhibits elastase activity and neutrophil chemotaxis," *Molecular and Biochemical Parasitology*, vol. 44, no. 1, pp. 81–90, 1991.

[56] R. Riganò, E. Profumo, F. Bruschi, et al., "Modulation of human immune response by *Echinococcus granulosus* antigen B and its possible role in evading host defenses," *Infection and Immunity*, vol. 69, no. 1, pp. 288–296, 2001.

[57] R. Riganò, B. Buttari, E. Profumo, et al., "*Echinococcus granulosus* antigen B impairs human dendritic cell differentiation and polarizes immature dendritic cell maturation towards a Th2 cell response," *Infection and Immunity*, vol. 75, no. 4, pp. 1667–1678, 2007.

[58] H. Wen and P. S. Craig, "Immunoglobulin G subclass responses in human cystic and alveolar echinococcosis," *The American Journal of Tropical Medicine and Hygiene*, vol. 51, no. 6, pp. 741–748, 1994.

[59] S. Ioppolo, S. Notargiacomo, E. Profumo, et al., "Immunological responses to antigen B from *Echinococcus granulosus* cyst fluid in hydatid patients," *Parasite Immunology*, vol. 18, no. 11, pp. 571–578, 1996.

[60] E. Ortona, P. Margutti, F. Delunardo, et al., "Screening of an *Echinococcus granulosus* cDNA library with IgG4 from patients with cystic echinococcosis identifies a new tegumental protein involved in the immune escape," *Clinical & Experimental Immunology*, vol. 142, no. 3, pp. 528–538, 2005.

[61] E. Ortona, S. Vaccari, P. Margutti, et al., "Immunological characterization of *Echinococcus granulosus* cyclophilin, an allergen reactive with IgE and IgG4 from patients with cystic echinococcosis," *Clinical & Experimental Immunology*, vol. 128, no. 1, pp. 124–130, 2002.

[62] E. Ortona, P. Margutti, S. Vaccari, et al., "Elongation factor 1 β/δ of *Echinococcus granulosus* and allergic manifestations in human cystic echinococcosis," *Clinical & Experimental Immunology*, vol. 125, no. 1, pp. 110–116, 2001.

[63] E. Ortona, P. Margutti, F. Delunardo, et al., "Molecular and immunological characterization of the C-terminal region of a new *Echinococcus granulosus* Heat Shock Protein 70," *Parasite Immunology*, vol. 25, no. 3, pp. 119–126, 2003.

[64] D. A. Vuitton, "Echinococcosis and allergy," *Clinical Reviews in Allergy & Immunology*, vol. 96, no. 2, pp. 93–104, 2004.

Hindawi Publishing Corporation
Interdisciplinary Perspectives on Infectious Diseases
Volume 2009, Article ID 195040, 5 pages
doi:10.1155/2009/195040

Review Article

Chemotherapy of Human African Trypanosomiasis

Cyrus J. Bacchi

Department of Biological and Health Sciences, Haskins Laboratory, Pace University, New York, NY 10038, USA

Correspondence should be addressed to Cyrus J. Bacchi, cbacchi@pace.edu

Received 27 March 2009; Accepted 28 April 2009

Recommended by Louis M. Weiss

Human Africa trypanosomiasis is a centuries-old disease which has disrupted sub-Saharan Africa in both physical suffering and economic loss. This article presents an update of classic chemotherapeutic agents, in use for >50 years and the recent development of promising non-toxic combination chemotherapy suitable for use in rural clinics.

1. Introduction

Human African Trypanosomiasis (HAT) or African trypanosomiasis has been endemic in sub-Saharan Africa for thousands of years. Currently approximately 50 million people are at risk for this disease in an area of 10 million square kilometers [1] HAT is caused by two hemoflagellates of the *Trypanosoma brucei* subgroup, *T. b. gambiense* (West African or Gambian form) and *T. b. rhodesiense* (East African or Rhodesian form). The parasites are transmitted by the tsetse fly between humans and reservoir domestic and wild animals. In the early-stage of the disease, the parasite is found in the bloodstream and lymphatic system. In the later, central nervous system stage, cerebrospinal fluid, and neural tissue become infected. Symptoms of early-stage include fever, chills, headache, and lymphadopathy. In the later CNS stage, severe headaches, insomnia, progressive mental deterioration, psychiatric manifestations, and tremors are common, finally culminating in coma and death [2]. The surface of the trypanosome is covered by variant surface glycoprotein (VSG) which is the main antigenic determinant to the human immune system [3]. The genome contains ~1 000 genes capable of coding for VSG genes which are randomly switched on and off at each generation [4]. This immune evasion mechanism makes it unlikely that a vaccine could be developed for HAT.

The attention paid to developing chemotherapy for HAT has lagged behind that for other tropical diseases [5]. The agents in routine clinical use have been available for >50 years and are not ideal drugs, some curing only early-stage disease (pentamidine, berenil or suramin), with the only routinely available drug for late-stage, CNS disease (Melarsprol, Mel B, Arsobal) having significant toxicity [6]. With the exception of suramin, resistance to these agents is growing. This is due in part to development of reduced uptake with melarsoprol and pentamidine [7].

Difluoromethylornithine (eflornithine, DFMO, Ornidyl®) is the only new useful addition to this list for treatment of late-stage since the early 1950s [7, 8]. A recent development has been the success in clinical trial of a DFMO-nifurtimox combination for CNS disease. This reduces the DFMO dosage and has no significant toxicity [9]. Parafuramidine maleate (DB289) is being developed as an orally administered alternative to intramuscular dosing with pentamidine in hope that it might facilitate treatment of early-stage, non-CNS disease [10].

2. Current Chemotherapy

Pentamidine is a water-soluble aromatic diamidine that has been in use since the 1930s. It is effective against early-stage *T. b. gambiense* infection, but is less effective against *T. b. rhodesiense* infection, and is ineffective against late-stage disease [10, 11]. Dosing for early-stage disease consists of a series of 7–10 intramuscular injections; however, shorter dose regimens are being explored [10]. African trypanosomes have a nucleoside (adenine/adenosine: P2) transporter that takes up pentamidine, resulting in the concentration of the agent at levels many times that in plasma [12, 13]. Recent

studies have found two other transporters, besides P2, that also transport pentamidine and may be responsible for 50% of its uptake [14]. Many studies have focused on the mechanism of pentamidine action; however, none appears to conclusively define the target. It is known to bind to the minor groove of kinetoplast (mitochondrial) DNA, and to promote the cleavage of kinetoplast minicircle DNA, eventually leading to the development of dyskinetoplastic cells. Despite its effects on kinetoplast DNA, pentamidine has no effect on nuclear DNA, and dyskinetoplastic forms can persist in the bloodstream of mammals [10, 11]. Pentamidine was also found to be a reversible inhibitor of S-adenosylmethionine (AdoMet) decarboxylase, an enzyme in the polyamine biosynthetic pathway, but this is unlikely as the primary mechanism of action [10]. Although Ki values were in the 200-μM range, we now know that this internal concentration is achievable via uptake through the P2 nucleoside–pentamidine transporter, and two other recently discovered transporters HAPT1 and LAPT1 [14, 15]. Other targets studied previously in trypanosomes include the inhibition of glycolysis and lipid metabolism, as well as effects on amino acid transport and ion exchange. The fact that pentamidine does not kill trypanosomes outright and bloodstream forms persist after treatment argue for a sustained effect more consistent with interference of parasite nucleic acid metabolism [10, 11].

Diminazene aceturate (Berenil) is an aromatic diamidine developed by Hoechst as treatment for bovine trypanosomiasis; however, its apparent low incidence of adverse reactions and significant therapeutic activity has led some physicians in endemic countries to use it extensively. It is effective against early-stage *T. b. gambiense* and *T. b. rhodesiense*. Berenil has also been used in combination with melarsoprol for the late-stage disease. Mechanistically, like pentamidine, berenil has also been linked to kinetoplast DNA binding at the minor groove and cleavage of minicircle DNA. As with pentamidine, berenil may also interfere with RNA editing and *trans*-splicing [11]. Berenil is also a more effective and noncompetitive inhibitor of AdoMet decarboxylase in trypanosomes, resulting in the reduction of spermidine content and elevating putrescine in the parasite. Berenil uptake, as with pentamidine, occurs via the P2 nucleoside transporter, which allows significant accumulation from the external environment. The other pentamidine transporters, HAPT1 and LAPT1 appear to play only a minor role in berenil uptake [14]. Although berenil has been used for many years on thousands of sleeping sickness patients, there is little published on its toxicity [10, 15]. This may in part be due to physicians who are unwilling to document human studies with an agent licensed for veterinary use. However, personal accounts of those using berenil in humans indicate it is well tolerated.

Suramin is a sulfonated naphthylamine, which has been used successfully against early-stage sleeping sickness caused chiefly by *T. b. rhodesiense*. Suramin does not penetrate the blood-brain barrier and is not used for CNS-stage disease. It was first used in 1922, developed from the closely related azo dyes, trypan red, and trypan blue [6, 10]. Suramin has an extremely long half-life in humans, 44–54 days, the result of avid binding to serum proteins. Suramin binds to many plasma proteins including LDL, which trypanosomes avidly bind and endocytose as a result of specific membrane receptors. LDL is a prime source of sterols for bloodstream trypanosomes [10, 16]. Suramin has been shown to inhibit all of the glycolytic enzymes in *T. b. brucei* and also other enzymes, including those of the pentose phosphate pathway [10]. This specificity for trypanosomal enzymes was attributed to higher (basic) isoelectric points for the parasite enzyme than the mammalian enzymes, allowing the negatively charged suramin to bind preferentially to the parasite enzymes. In practice, because most trypanosome glycolytic enzymes are contained in a membrane-bound cytosolic organelle, the glycosome, it is not likely that rapid massive binding occurs. This would rapidly induce lysis in bloodstream forms that depend on glycolysis as the sole energy-generating source. Rather, animals that are heavily infected with trypanosomes and given suramin show a slow decrease in parasite numbers, indicating that enzyme inhibition occurs slowly. Suramin may be affecting newly synthesized enzyme molecules in the cytosol before they are imported into the glycosome. Suramin has also been found to affect thymidine kinase and dihydrofolate reductase. It is likely that suramin's action may be attributable to the inhibition of several of these enzymes [11].

Melarsoprol is an arsenical resulting from the efforts of Ernst Freidheim in the late 1940s. His initial compound, melarsen oxide, *p*-(4,6-diamino-*s*-triazinyl-2-*yl*) aminophenylarsenoxide was complexed with dimercaptopropanol (British Anti-Lewisite) to form a less-toxic complex, merlarsoprol. Until 1990, this was the only agent available for treatment of late-stage CNS disease both of East African and West African origin. It is usually given as two to four series of three daily I.V. injections, or a single daily injection for 10 days [8]. It is insoluble in water and must be dissolved in propylene glycol, given intravenously. For this reason, it is painful to administer and destroys veins after several applications. Toxicity is an important concern with melarsoprol. This takes the form of reactive arsenical-induced encephalopathy in 10% of treated patients, which is often followed by pulmonary edema and death in more than half these cases within 48 hour. [8, 17]. Although the mechanism of melarsoprol action has been extensively studied, it still remains unclear. Parasites exposed to low (1–10 μM) levels rapidly lyse. Because the bloodstream forms are intensely glycolytic, any interruption of glycolysis or interference with redox metabolism should produce this effect. Thus a series of reports has detailed melarsoprol inhibition of trypanosome pyruvate kinase (Ki, 100 μM), phosphofructokinase (Ki, <1 μM), and fructose-2,6-bisphosphatase (Ki, 2 μM). It is likely that the rapid inhibition of fructose 2,6,bis-phosphate production is a key factor in halting glycolysis through downregulation of pyruvate kinase [11]. Other studies indicated that melarsoprol and melarsen oxide formed adducts with trypanothione (N1,N8-bisglutathionyl spermidine), a metabolite unique to trypanosomes and believed to be responsible for the redox balance of the cell and detoxification of peroxides [12, 18]. The melarsen–trypanothionine adduct (Mel T)

inhibits trypanothione reductase, which has been attributed to the mode of action [19, 20]. However, melarsoprol and related arsenicals may also bind to other sulfhydryl-containing agents in the cell, including dihydrolipoate and the closely adjacent cysteine residues of many proteins. Similar to pentamidine and diminazene, melarsoprol uptake into African trypanosomes has been attributed to the P2 purine nucleoside transporter; thus, significant levels can be concentrated in the cell from a low external (plasma) concentration [12, 13]. Although most laboratory-generated melarsoprol-resistant strains have lost or modified the P2 transporter, clinical isolates appear to have retained uptake capacity [14].

DFMO is the most recently developed agent for late-stage *T. b. gambiense* sleeping sickness. DFMO is an enzyme-activated irreversible inhibitor of ornithine decarboxylase (ODC), the initial enzyme in the polyamine synthetic pathway. This agent was initially developed as an antitumor agent by Merrell-Dow in the late 1970s and underwent extensive clinical trials before testing against trypanosomes, after initial testing in mouse model *T. b. brucei* infections [21]. DFMO was studied extensively in human trials in Africa [22, 23]. The standard treatment regimen resulting from the trials indicate that DFMO is <95% active when given intravenously 400 mg/kg I.V., given every 6 hours. for 14 days. DFMO cured children, adults, patients with melarsoprol-refractory strains, and patients with late-stage disease [17, 24] The short plasma half-life of DFMO necessitates constant dosing when given as an I.V. drip. The most frequent toxic reaction was reversible bone marrow suppression, which was alleviated upon reduction of the doses. The major drawbacks with respect to DFMO are its cost, the duration of treatment, and its availability [25]. DFMO rapidly and irreversibly binds to the catalytic site (cysteine 360) in mouse ODC, inactivating it. In culture, it blocks division of bloodstream trypanosomes, but it is not trypanocidal. In laboratory infections, DFMO cures when administered continuously in the drinking water as a 2% solution. Within 48 hours of administration, DFMO reduces putrescine levels to zero, and reduces spermidine levels by >75% [26]. Trypanothione levels are also significantly reduced [19]. As noted, DFMO is not trypanocidal and depends on a functional immune system to rid the host of non-dividing forms [27]. Morphologically, trypanosomes exposed to DFMO have multiple kinetoplasts and nuclei as well as forms resembling "stumpy" blood forms [26]. DFMO is curative for laboratory infections of *T. b. brucei* and *T. b. gambiense,* but not to all strains of *T. b. rhodesiense* [28].The reason for this selectivity is not completely evident, although it is not due to uptake of DFMO, because it enters by passive diffusion, not transport [27, 29]. Iten et al 1997 [30] have found that *T. b. rhodesiense* isolates have an ODC with a shorter half-life than *T. b. gambiense*, which could result in lowered susceptibility to DFMO. Also levels of AdoMet are highly elevated in DFMO-treated susceptible *T. b. rhodesiense* strains, but less so in refractory isolates [25]. This elevation is the result of the block in putrescine synthesis and the resulting inability to make spermidine. The elevated level of AdoMet is the result of an AdoMet synthase insensitive to its product. DFMO treatment leads to intracellular concentrations of >5 mM, an increase of >50-fold over untreated parasites [25]. Trypanosome ODC is missing the C-terminal PEST sequence in both procyclic and bloodstream trypanosomes, and this appears to be the major reason for the stability of the trypanosome enzyme. The remainder of the ODC molecule has ~60% sequence identity with the mammalian enzyme, including a cysteine 360 residue at the demonstrated DFMO-binding site for the mammalian enzyme [31, 32]. Beyond this, trypanosomes lack a polyamine oxidase, which in mammalian cells converts spermine to the biologically active spermidine. Trypanosomes are also limited in their ability to transport putrescine and spermidine [25].

3. DFMO Drug Combinations

Eflornithine is the only new agent developed in 58 years for clinical use of second stage HAT. With relatively minor and irreversible side effects as compared to melarsoprol, it is superior in efficacy to melarsoprol [33, 34]. In laboratory model infections of *T. b. brucei*, DFMO was curative in combination with many new agents as well as clinically-used trypanocides, including suramin and melarsoprol [35, 36]. In the laboratory, these combinations resulted in significant reduction in DFMO dosage and time of administration [37]. Recent clinical studies have investigated the use of DFMO in combination with other clinically used trypanocides [17, 34]. Because of the recent availability of DFMO as a result of advocacy campaigns by Medicines Sans Frontiers and other organizations, coupled with financial support by Sanofi-Aventis, DFMO has been increasingly available in the field since 2001 [8]. Initial clinical combination studies [17] showed that DFMO + nifurtimox was far superior to DFMO + melarsoprol and melarsoprol + nifurtimox. The DFMO + nifurtimox regimen (NECT regimen) allowed reduction in DFMO regimen from 14 to 7 days (56 versus 28 infusions) with a 94% cure rate. Nifurtimox was given orally for 10 days. The study has been confirmed in another clinical study with a DFMO-Nifurtimox cure rate of 100% [24]. In another related study, total doses of DFMO were reduced to 14 (two/day for 7 days) and a 94% cure rate resulted with a DFMO-nifurtimox regimen [34]. All of the DFMO-nifurtimox regimens were associated with significantly reduced adverse side effects as compared to melarsoprol-based therapy [8]. The biochemical basis for this therapy most likely lies in the ability of DFMO to reduce trypanothione levels and resistance to oxidative stress [19, 20] and the ability of nifurtimox to generate oxidative stress in trypanosomes [38]. In addition to MSF, Drugs for Neglected Diseases initiative (DNDi), the Swiss Tropical Institute, Epicenter, and The World Health Organization, have collaborated in making these combination clinical trials possible (HAT-NECT Phase III Study: [9]).

4. Prophylaxis and Prevention

Trypanosomiasis causes complex public health and epizootic problems in many developing countries in Africa. Control

programs concentrating on the eradication of vectors and drug treatment of infected people and animals have been in operation in some areas for decades. Considerable progress has been made in a number of regions, but the lack of agreement on the best approach to solving the problem of African trypanosomiasis, combined with a paucity of resources, stands in the way of effective control. Individuals can reduce their risk of becoming infected with trypanosomes by avoiding tsetse fly-infested areas, by wearing clothing that reduces the biting of the flies, and by using insect repellants. Chemoprophylaxis with suramin or pentamidine can be effective, but it is not clear which populations should use this as a preventive measure. No vaccine is available to prevent the transmission of the parasites.

References

[1] E. M. Fèvre, K. Picozzi, J. Fyfe, et al., "A burgeoning epidemic of sleeping sickness in Uganda," *The Lancet*, vol. 366, no. 9487, pp. 745–747, 2005.

[2] V. W. Pentreath, "Trypanosomiasis and the nervous system: pathology and immunology," *Transactions of the Royal Society of Tropical Medicine and Hygiene*, vol. 89, no. 1, pp. 9–15, 1995.

[3] J. M. Sternberg, "Immunobiology of African trypanosomiasis," *Chemical Immunology*, vol. 70, pp. 186–199, 1998.

[4] J. E. Donelson, K. L. Hill, and N. M. A. El-Sayed, "Multiple mechanisms of immune evasion by African trypanosomes," *Molecular and Biochemical Parasitology*, vol. 91, no. 1, pp. 51–66, 1998.

[5] "Drugs for parasitic infections," *The Medical Letter on Drugs and Therapeutics*, vol. 40, no. 1017, pp. 1–12, 1998.

[6] J. Pépin and F. Milord, "The treatment of human African trypanosomiasis," *Advances in Parasitology*, vol. 33, pp. 1–47, 1994.

[7] S. Gehrig and T. Efferth, "Development of drug resistance in *Trypanosoma brucei rhodesiense* and *Trypanosoma brucei gambiense*. Treatment of human Africa trypanosomiasis with natural products (review)," *International Journal of Molecular Medicine*, vol. 22, no. 4, pp. 411–419, 2008.

[8] F. Chappuis, "Melarsoprol-free drug combinations for second-stage gambian sleeping sickness: the way to go," *Clinical Infectious Diseases*, vol. 45, no. 11, pp. 1443–1445, 2007.

[9] G. Priotto and A.-M. Sevscik, "An improved treatment for sleeping sickness," *DNDi Newsletter*, no. 17, pp. 1–2, 2008.

[10] M. P. Barrett, D. W. Boykin, R. Brun, and R. R. Tidwell, "Human African trypanosomiasis: pharmacological re-engagement with a neglected disease," *British Journal of Pharmacology*, vol. 152, no. 8, pp. 1155–1171, 2007.

[11] C. C. Wang, "Molecular mechanisms and therapeutic approaches to the treatment of African trypanosomiasis," *Annual Review of Pharmacology and Toxicology*, vol. 35, no. 11, pp. 93–127, 1995.

[12] A. H. Fairlamb, N. S. Carter, M. Cunningham, and K. Smith, "Characterisation of melarsen-resistant *Trypanosoma brucei brucei* with respect to cross-resistance to other drugs and trypanothione metabolism," *Molecular and Biochemical Parasitology*, vol. 53, no. 1-2, pp. 213–222, 1992.

[13] N. S. Carter, B. J. Berger, and A. H. Fairlamb, "Uptake of diamidine drugs by the P2 nucleoside transporter in melarsen- sensitive and -resistant *Trypanosoma brucei brucei*," *The Journal of Biological Chemistry*, vol. 270, no. 47, pp. 28153–28157, 1995.

[14] H. P. de Koning, "Uptake of pentamidine in *Trypanosoma brucei brucei* is mediated by three distinct transporters: implications for cross-resistance with arsenicals," *Molecular Pharmacology*, vol. 59, no. 3, pp. 586–592, 2001.

[15] V. Delespaux and H. P. de Koning, "Drugs and drug resistance in African trypanosomiasis," *Drug Resistance Updates*, vol. 10, no. 1, pp. 30–50, 2007.

[16] E. L. M. Vansterkenburg, I. Coppens, J. Wilting, et al., "The uptake of the trypanocidal drug suramin in combination with low- density lipoproteins by *Trypanosoma brucei* and its possible mode of action," *Acta Tropica*, vol. 54, no. 3-4, pp. 237–250, 1993.

[17] G. Priotto, C. Fogg, M. Balasegaram, et al., "Three drug combinations for late-stage *Trypanosoma brucei gambiense* sleeping sickness: a randomized clinical trial in Uganda," *PLoS Clinical Trials*, vol. 1, no. 8, article e39, pp. 1–8, 2006.

[18] A. H. Fairlamb, P. Blackburn, P. Ulrich, B. T. Chait, and A. Cerami, "Trypanothione: a novel bis(glutathionyl)spermidine cofactor for glutathione reductase in trypanosomatids," *Science*, vol. 227, no. 4693, pp. 1485–1487, 1985.

[19] A. H. Fairlamb, G. B. Henderson, C. J. Bacchi, and A. Cerami, "In vivo effects of difluoromethylornithine on trypanothione and polyamine levels in bloodstream forms of *Trypanosoma brucei*," *Molecular and Biochemical Parasitology*, vol. 24, no. 2, pp. 185–191, 1987.

[20] A. H. Fairlamb, G. B. Henderson, and A. Cerami, "Trypanothione is the primary target for arsenical drugs against African trypanosomes," *Proceedings of the National Academy of Sciences of the United States of America*, vol. 86, no. 8, pp. 2607–2611, 1989.

[21] C. J. Bacchi, H. C. Nathan, S. H. Hutner, P. P. McCann, and A. Sjoerdsma, "Polyamine metabolism: a potential therapeutic target in trypanosomes," *Science*, vol. 210, no. 4467, pp. 332–334, 1980.

[22] S. Van Nieuwenhove, "Advances in sleeping sickness therapy," *Annales de la Société Belge de Médecine Tropicale*, vol. 72, supplement 1, pp. 39–51, 1992.

[23] G. Priotto, L. Pinoges, I. B. Fursa, et al., "Safety and effectiveness of first line eflornithine for *Trypanosoma brucei* gambiense sleeping sickness in Sudan: cohort study," *British Medical Journal*, vol. 336, no. 7646, pp. 705–708, 2008.

[24] F. Checchi, P. Piola, H. Ayikoru, F. Thomas, D. Legros, and G. Priotto, "Nifurtimox plus eflornithine for late-stage sleeping sickness in Uganda: a case series," *PLoS Neglected Tropical Diseases*, vol. 1, no. 2, article e64, pp. 1–6, 2007.

[25] C. J. Bacchi and N. Yarlett, "Polyamine metabolism," in *Biochemistry and Molecular Biology of Parasites*, J. J. Marr and M. Müller, Eds., pp. 119–131, Academic Press, New York, NY, USA, 1995.

[26] C. J. Bacchi, J. Garofalo, D. Mockenhaupt, et al., "In vivo effects of α-DL-difluoromethylornithine on the metabolism and morphology of *Trypanosoma brucei brucei*," *Molecular and Biochemical Parasitology*, vol. 7, no. 3, pp. 209–225, 1983.

[27] A. J. Bitonti, P. P. McCann, and A. Sjoerdsma, "Necessity of antibody response in the treatment of African trypanosomiasis with α-difluoromethylornithine," *Biochemical Pharmacology*, vol. 35, no. 2, pp. 331–334, 1986.

[28] C. J. Bacchi, H. C. Nathan, T. Livingston, et al., "Differential susceptibility to DL-α-difluoromethylornithine in clinical isolates of *Trypanosoma brucei rhodesiense*," *Antimicrobial Agents and Chemotherapy*, vol. 34, no. 6, pp. 1183–1188, 1990.

[29] A. J. Bitonti, C.J. Bacchi,, PP. McCann, and A. Sjoerdsma, "Uptake of a-difluoromethylornithine by Trypanosoma brucei

bruci," *Biochemical Pharmacology*, vol. 35, pp. 3541–3545, 1986.

[30] M. Iten, H. Mett, A. Evans, J. C. K. Enyaru, R. Brun, and R. Kaminsky, "Alterations in ornithine decarboxylase characteristics account for tolerance of *Trypanosoma brucei rhodesiense* to D,L-α- difluoromethylornithine," *Antimicrobial Agents and Chemotherapy*, vol. 41, no. 9, pp. 1922–1925, 1997.

[31] M. A. Phillips, P. Coffino, and C. C. Wang, "Cloning and sequencing of the ornithine decarboxylase gene from *Trypanosoma brucei*," *Molecular and Biochemical Parasitology*, vol. 22, no. 1, pp. 9–17, 1987.

[32] L. Ghoda, M. A. Phillips, K. E. Bass, C. C. Wang, and P. Coffino, "Trypanosome ornithine decarboxylase is stable because it lacks sequences found in the carboxyl terminus of the mouse enzyme which target the latter for intracellualr degradation," *The Journal of Biological Chemistry*, vol. 265, no. 20, pp. 11823–11826, 1990.

[33] F. Chappuis, N. Udayraj, K. Stietenroth, A. Meussen, and P. A. Bovier, "Eflornithine is safer than melarsoprol for the treatment of second-stage *Trypanosoma brucei gambiense* human African trypanosomiasis," *Clinical Infectious Diseases*, vol. 41, no. 5, pp. 748–751, 2005.

[34] G. Priotto, S. Kasparian, D. Ngouama, et al., "Nifurtimox-eflornithine combination therapy for second-stage *Trypanosoma brucei gambiense* sleeping sickness: a randomized clinical trial in Congo," *Clinical Infectious Diseases*, vol. 45, no. 11, pp. 1435–1442, 2007.

[35] A. B. Clarkson Jr., E. J. Bienen, C. J. Bacchi, P. P. McCann, S. H. Hutner, and A. Sjoerdsma, "New drug combination for experimental late-stage African trypanosomiasis: DL-α-difluoromethylornithine (DFMO) with suramin," *The American Journal of Tropical Medicine and Hygiene*, vol. 33, no. 6, pp. 1073–1077, 1984.

[36] C. J. Bacchi, H. C. Nathan, N. Yarlett, et al., "Combination chemotherapy of drug-resistant *Trypanosoma brucei rhodesiense* infections in mice using DL-α-difluoromethylornithine and standard trypanocides," *Antimicrobial Agents and Chemotherapy*, vol. 38, no. 3, pp. 563–569, 1994.

[37] C. J. Bacchi, H. C. Nathan, A. B. Clarkson Jr., et al., "Effects of the ornithine decarboxylase inhibitors DL-α-difluoromethylornithine and 3,4 dehydromonofluoromethylornithine alone and in combination with suramin against *Trypanosoma brucei brucei* central nervous system models," *The American Journal of Tropical Medicine and Hygiene*, vol. 35, pp. 46–52, 1987.

[38] M. O. Eze, "Towards more efficacious chemotherapy of trypanosomiasis: combination of α-difluoromethylornithine (DFMO) with reactive oxygen generating drugs," *Medical Hypotheses*, vol. 36, no. 3, pp. 246–249, 1991.

Hindawi Publishing Corporation
Interdisciplinary Perspectives on Infectious Diseases
Volume 2009, Article ID 642502, 19 pages
doi:10.1155/2009/642502

Review Article

Sterol Biosynthesis Pathway as Target for Anti-trypanosomatid Drugs

Wanderley de Souza[1,2] and Juliany Cola Fernandes Rodrigues[1]

[1] *Laboratório de Ultraestrutura Celular Hertha Meyer, Instituto de Biofísicia Carlos Chagas Filho, Universidade Federal do Rio de Janeiro, CCS-Bloco G, 21941-902, Rio de Janeiro, RJ, Brazil*
[2] *Diretoria de Programas, Instituto Nacional de Metrologia, Normalização e Qualidade Industrial, Rio de Janeiro, RJ, Brazil*

Correspondence should be addressed to Wanderley de Souza, wsouza@biof.ufrj.br

Received 30 March 2009; Accepted 27 April 2009

Recommended by Herbert B. Tanowitz

Sterols are constituents of the cellular membranes that are essential for their normal structure and function. In mammalian cells, cholesterol is the main sterol found in the various membranes. However, other sterols predominate in eukaryotic microorganisms such as fungi and protozoa. It is now well established that an important metabolic pathway in fungi and in members of the Trypanosomatidae family is one that produces a special class of sterols, including ergosterol, and other 24-methyl sterols, which are required for parasitic growth and viability, but are absent from mammalian host cells. Currently, there are several drugs that interfere with sterol biosynthesis (SB) that are in use to treat diseases such as high cholesterol in humans and fungal infections. In this review, we analyze the effects of drugs such as (a) statins, which act on the mevalonate pathway by inhibiting HMG-CoA reductase, (b) bisphosphonates, which interfere with the isoprenoid pathway in the step catalyzed by farnesyl diphosphate synthase, (c) zaragozic acids and quinuclidines, inhibitors of squalene synthase (SQS), which catalyzes the first committed step in sterol biosynthesis, (d) allylamines, inhibitors of squalene epoxidase, (e) azoles, which inhibit C14α-demethylase, and (f) azasterols, which inhibit $\Delta^{24(25)}$-sterol methyltransferase (SMT). Inhibition of this last step appears to have high selectivity for fungi and trypanosomatids, since this enzyme is not found in mammalian cells. We review here the IC50 values of these various inhibitors, their effects on the growth of trypanosomatids (both in axenic cultures and in cell cultures), and their effects on protozoan structural organization (as evaluted by light and electron microscopy) and lipid composition. The results show that the mitochondrial membrane as well as the membrane lining the protozoan cell body and flagellum are the main targets. Probably as a consequence of these primary effects, other important changes take place in the organization of the kinetoplast DNA network and on the protozoan cell cycle. In addition, apoptosis-like and autophagic processes induced by several of the inhibitors tested led to parasite death.

1. Introduction

Sterols are constituents of the cellular membranes that are essential for their normal structure and function. In mammalian cells, cholesterol is the main sterol found in the various membranes. However, other sterols predominate in eukaryotic microorganisms such as fungi and protozoa. In the case of trypanosomatids, for many years cholesterol was considered to be the major sterol. This was due to the fact that all biochemical analyses were undertaken in protozoa grown in complex media containing either brain, heart, or liver extracts and bovine serum. When the first biochemical analysis of lower trypanosomatids grown in chemically defined medium was carried out, it became clear that they synthesize ergosterol and not cholesterol [1]. Subsequently, it was shown that the trypanosomatids incorporate cholesterol from the culture medium or from the blood of infected animals through a typical endocytic process involving, in the case of epimastigotes of *Trypanosoma cruzi*, the formation of endocytic vesicles in the flagellar pocket and the cytostome [2, 3].

It is now well established that an important metabolic pathway in fungi and in members of the Trypanosomatidae family is the sterol biosynthesis (SB) pathway. In these

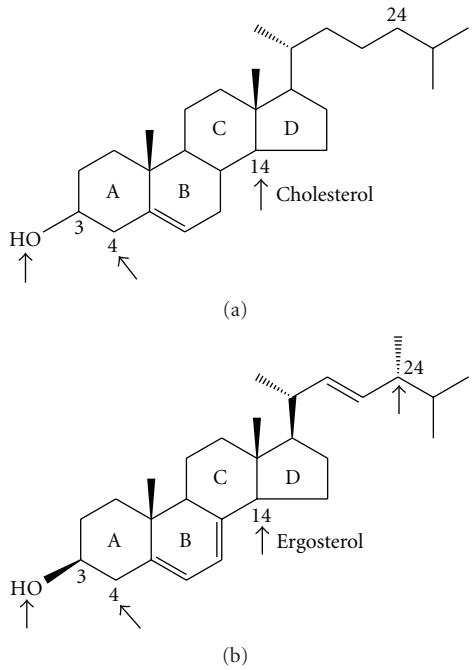

Figure 1: Molecular structures of cholesterol and ergosterol. The arrows indicate the parts of the molecules which have been shown to be essential for the growth of mammalian cells (cholesterol), fungi, and trypanosomatids (ergosterol and 24-methyl sterols).

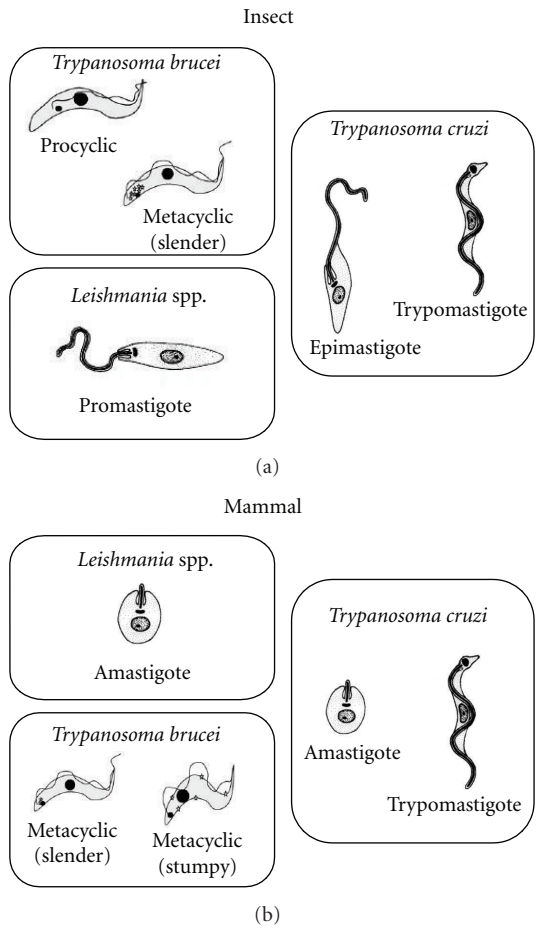

Figure 2: Schematic representation of main morphologies found during the life cycle of some members of the Trypanosomatidae family in the invertebrate host (insect) and vertebrate host (mammal).

organisms, this pathway produces a special class of sterols, including ergosterol and other 24-methyl sterols, that is, required for their growth and viability, but is absent from mammalian host cells [4, 5]. Cholesterol and ergosterol differ in a few minor ways, as shown in Figure 1; cholesterol has only one double bond ($\Delta 5(6)$) in the B ring and has a fully saturated side chain without a methyl group at C24. It has been shown that some parts of the sterol molecule are important for its activity in cellular membranes. In the tetracyclic nucleus, the 3β–OH is obligatory for growth, whereas the presence of methyl groups at C14 or C4 do not allow growth. These two characteristics are essential for both cholesterol and ergosterol to support growth. However, certain characteristics of ergosterol that are absent in the cholesterol molecule, such as the presence of two double bonds in the B ring of the steroid nucleus, the presence of a β methyl at position 24, and the double bond at C22 in the side chain are essential for the growth of fungi and trypanosomatids.

The main sterols of the trypanosomatids comprise $\Delta^{5,7}$-compounds belonging to the C_{28}-ergostane (24-methyl or methylene) or the C_{29}-stigmastane (24-ethyl or ethylidine) groups [6–9]. In *Leishmania* amastigotes and promastigotes, the predominant sterol includes ergosta-5,7,24(24^1)-trien-3β-ol (5-dehydroepisterol), although ergosta-118 7,24(24^1)-dien-3β-ol (episterol) and ergosta-5,7,22-trien-3β-ol (ergosterol, the major fungal sterol) are present in smaller amounts. Stigmastane-related sterols comprise 5% of the total sterols in promastigotes; which can go as high as 20% in amastigotes of some species [9–12]. In contrast, *T. cruzi* epimastigotes contain around 40% ergosterol and ergosta-5,7-dien-3β-ol, and an appreciable amount, around 30%, of stigmasta-5,7-dien-3β-ol, and stigmasta-5,7,22-trien-3β-ol [8, 13]. In the case of amastigote forms, the sterol content is completely different since *T. cruzi* apparently does not produce $\Delta^{5,7}$-sterols, which are replaced by ergosta-7-en-3β-ol and 24-ethylidinecholest-7-en-3β-ol, indicating the absence of Δ^5-desaturase activity [14]. The content of sterols in *Trypanosoma brucei* differs from other trypanosomatids, where the bloodstream form contains predominantly cholesterol incorporated from the medium through a receptor-mediated endocytic process, which apparently suppresses *de novo* synthesis of C_{28}-sterols [15], even though it has mRNA coding for enzymes involved in ergosterol biosynthesis [16]. In the procyclic form, the sterol content is different from the bloodstream form, with the major component in the total membranes being ergosterol, with some amount of cholesterol [16].

In the context of this review describing the effect of sterol biosynthesis inhibitors in members of the Trypasonomatidae family, it is important to show a schematic representation

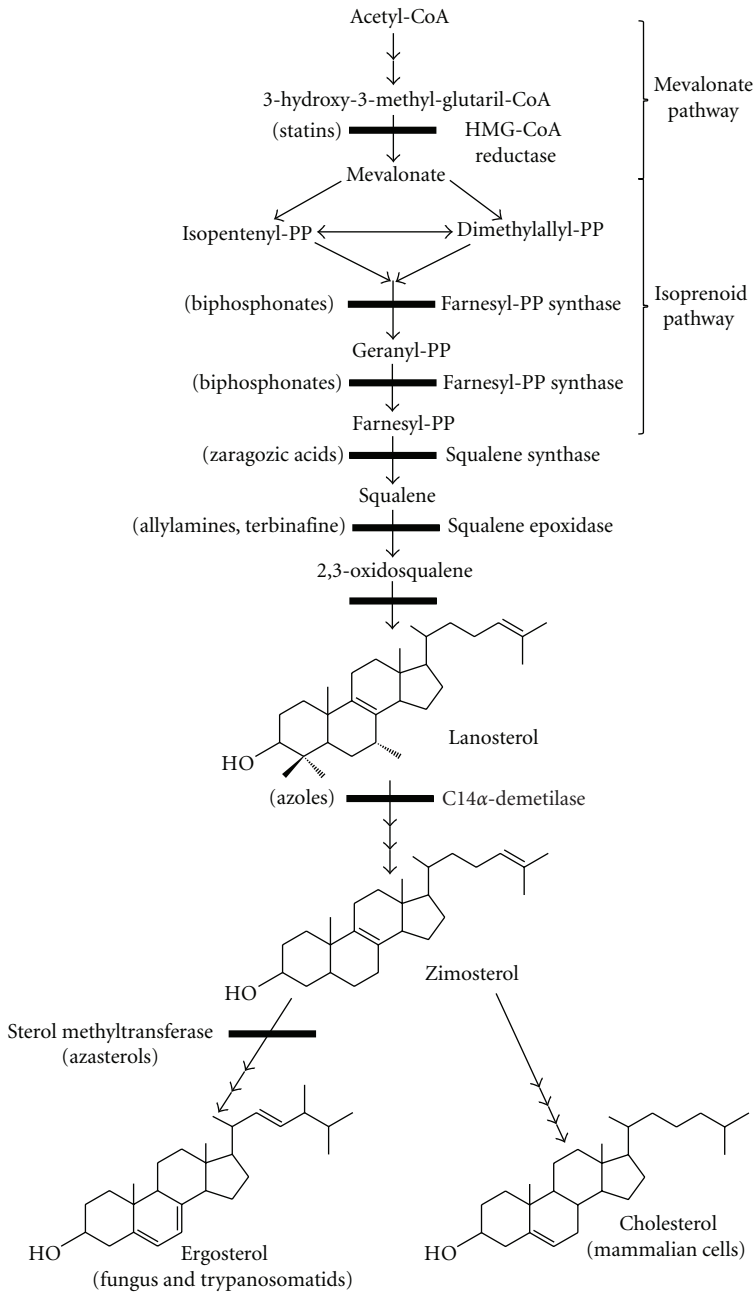

Figure 3: The biosynthesis of ergosterol and cholesterol showing the main steps, the enzymes involved, and the known inhibitors.

of the main developmental stages found in the invertebrate host (insect) and vertebrate host (mammal) for *Trypanosoma brucei*, *Trypanosoma cruzi*, and *Leishmania spp* (Figure 2) [17–20].

2. Comparison of the Sterol Biosynthesis Pathways in Mammals, Fungi, and Trypanosomatids

A comparative schematic diagram of the sterol biosynthesis pathway in eukaryotes is shown in Figure 3. At least 20 metabolic steps are necessary to synthesize such sterols as cholesterol and ergosterol, with some steps involving specific enzymes that differ between mammalian cells and microorganisms such as fungi and trypanosomatids. Some of these enzymes have been extensively studied, both as targets for the development of new drugs that interfere with parasite growth without severe effects on host cells and also as a means of reducing the high levels of endogenous cholesterol in mammalian cells.

The carbon skeleton of the sterol molecule is derived from acetyl-CoA, with the exception to the presence of the C24 methyl group in the ergosterol side chain. The first

reactions in the biosynthetic pathway involve condensation of two acetyl-CoA units to form acetoacetyl-CoA, followed by the addition of a third unit to form 3-hydroxy-3-methylglutaryl-CoA (HMG-CoA), which is then reduced by NADPH to give mevalonic acid. These three steps comprise the mevalonate pathway and are catalyzed by the cytosolic enzyme acetoacetyl-CoA thiolase, and two mitochondrial enzymes in yeasts and trypanosomatids, HMG-CoA synthase, and HMG-CoA reductase [21–23]. By contrast, the initial steps of cholesterol biosynthesis in mammalian cells occur mainly in the cytosol, with the later steps occurring in the endoplasmic reticulum (ER). On the other hand, several of the enzymes have been reported to exist in peroxisomes and in glycosomes [23–25].

After the mevalonate pathway, the next steps constitute the isoprenoid pathway. Isoprenoids are the most diverse and abundant compounds present in nature, and are essential components of all organisms due to a variety of roles in different biological processes. First, mevalonate is converted to isopentenyl diphosphate (IPP) by two phosphorylation reactions followed by one decarboxylation. Subsequently, isomerization of IPP by isopentenyl diphosphate isomerase produces dimethylallyl diphosphate (DMAPP). After that, longer isoprenoids are formed by a consecutive condensation of IPP with DMAPP and geranyl diphosphate (GPP) to produce the 15-carbon isoprenoid compound known as farnesyl diphosphate (FPP) in two reactions catalyzed by the enzyme farnesyl diphosphate synthase (FPPS). All these reactions together constitute the isoprenoid pathway, which is present in almost all organisms investigated so far [25]. FPP, which is the last product of isoprenoid biosynthesis, is the substrate for enzymes catalyzing the first committed step for the biosynthesis of sterols, ubiquinones, dolichols, heme A, and prenylated proteins. The enzymes involved in the isoprenoid pathway are located in different subcellular compartments such as the cytosol [26], mitochondria [27, 28], plastids in plant cells [26], and the peroxisome in animals [29]. For example, in *Leishmania major,* FPPS is located in the cytosol [30], while in *Toxoplasma gondii* it appears partially in the mitochondrion without any co-localization in rhoptries or apicoplast [31].

After the isoprenoid pathway, the next two reactions comprise the first committed step in sterol biosynthesis. These are catalyzed by the enzyme squalene synthase, which promotes a head-to-head condensation of two molecules of farnesyl diphosphate to produce squalene. In the first reaction, presqualene pyrophosphate (PPP) is produced by the loss of an inorganic pyrophosphate. This is converted to squalene in the second reaction in presence of NADPH, an essential cofactor required to drive this conversion [32]. In mammalian cells and in yeasts, squalene synthase is associated with the endoplasmic reticulum [33]. In *L. major*, its localization is still controversial. The presence of the signal sequences PTS1 and PTS2, typical of glycosomal proteins, indicates localization to the glycosome [34], while biochemical analysis of subcellular fractions of *T. cruzi* and *Leishmania spp.* showed that it could be found in the mitochondrion and microsomal fractions [35–37].

After production of squalene, sterol biosynthesis continues with the synthesis of 2,3-oxidosqualene (or squalene epoxide) in a reaction catalyzed by the enzyme squalene epoxidase. This is the first step in the conversion of the 30-carbon chain squalene to the tetracyclic sterol skeleton. Squalene epoxidase is the first enzyme in the pathway that requires molecular oxygen, and this reaction is performed by a microsomal complex consisting of a flavoprotein with NADPH cytochrome C reductase activity, and a terminal oxidase that is not of the cytochrome P-450 family [38].

In a reaction that is considered to be one of the most complex in the sterol pathway, 2,2-oxidosqualene cyclase cyclizes the intermediate 2,3-oxidosqualene to lanosterol, the initial precursor of all steroid structures formed by mammals, fungi, and trypanosomatids.

After the cyclization of 2,3-oxidosqualene to form lanosterol, several sequential transformations occur to form cholesterol in mammals and ergosterol in trypanosomatids and fungi. Some of these reactions are common to all eukaryotes, whereas others are exclusive to each organism, with differences also between trypanosomatids and fungi.

One of the earliest steps in the lanosterol pathway is the demethylation of the ring system at the C14 position in a two-stage oxidative reaction catalyzed by a cytochrome P-450-containing monooxygenase enzyme known as lanosterol-14α-methyl demethylase (C14α-demethylase) [38].

Removal of the 14α-methyl by C14α-demethylase generates a $\Delta^{8(14)}$ unsaturated sterol with a double bond at the C14 position. This unsaturation needs to be removed to produce Δ^5 sterols in two consecutive reactions catalyzed by the enzyme $\Delta^{8(14)}$-reductase with NADPH as cofactor. In several fungi, this removal is essential, because the subsequent enzymes in the pathway do not metabolize this unnatural sterol. However in some fungal species such as *Candida albicans* [38, 40], and also *L. amazonensis* [11] and *T. cruzi* [42–44], it is metabolized by the C4-demethylase enzymes and Δ^{24}-methenylase to form Δ^{14} fecosterol.

After removal of the C4 and C14 methyl groups and the methenylation of the side chain, the next reaction in the sequence is the isomerization of the double bonds in fecosterol in a reversible reaction catalyzed by the Δ^7-Δ^8 isomerase that does not require cofactors such as NADPH.

One of the most important stages of ergosterol biosynthesis that does not exist in the synthesis of cholesterol is the addition of a methyl group at the C24 position in the sterol side chain. Depending on the microorganism, this occurs early after the production of lanosterol, as observed in *L. amazonensis* [11], or at the level of zymosterol (which does not have the C4 and C14 methyl groups in the structure) as found in several fungi [45] and some *Leishmania spp.* [46]. The methyl group is transferred from S-adenosyl-L-methionine (SAM) to C-24 of Δ^{24} sterols to produce $\Delta^{24(28)}$-sterols in some reactions catalyzed by the S-Adenosyl-L-methionine:Δ^{24}-sterol methyltransferase (EC 2.1.1.43; 24-SMT). 24-SMT is a 150 000 dalton membrane-bound protein that is present in plants, fungi, and trypanosomatids, but is absent in mammalian sterol biosynthetic systems; thus it may constitute an interesting target for the development

of antifungal and antitrypanosomal agents. Cell fractionation studies have suggested that 24-SMT is located in the glycosomes and in the mitochondrion [35]. However, immunofluorescence and electron microscopic observations using antibodies generated against the recombinant protein showed that 24-SMT is located in the endoplasmic reticulum and in translucent vesicles that presumably belong to the endocytic pathway [47].

3. Available Drugs that Interfere with the Sterol Biosynthetic Pathway

Currently, there are several known drugs that interfere with sterol biosynthesis which are used to treat diseases such as high cholesterol in humans and fungal infections. Table 1 shows the representative compounds distributed in different classes, some of which are commercially available.

Statin is one of the main classes of the sterol biosynthesis inhibitors (SBIs), which act on the mevalonate pathway by the inhibition of HMG-CoA reductase. They have been widely used for cholesterol reduction in humans [38]. A drawback of the statins is their effect on the synthesis of isoprenoid compounds that are essential for several cellular events. Atorvastatin, widely used for treatment of hyperlipidemia, is one example of this class of drugs [48].

Bisphosphonate is another important class that interferes with the isoprenoid pathway inhibiting the step catalyzed by farnesyl diphosphate synthase (FPPS). They are used for the treatment of different bone resorption diseases, including osteoporosis, Paget's disease, hypercalcemia caused by malignancy, and tumor metastases in bone [49]. Alendronate and risedronate are two examples of bisphosphonates used for the treatment of osteoporosis and other bone resorption diseases [49].

Zaragozic acids and quinuclidines are known inhibitors of squalene synthase (SQS), which catalyzes the first committed step in sterol biosynthesis. This is a very attractive target because its inhibition does not interfere with isoprenoid production and intermediate metabolites that are formed can be readily metabolized and excreted [50]. SQS has been under intense scrutiny with the aim of developing new cholesterol-lowering agents for humans. Previous experimental studies with animals have demonstrated the effectiveness of quinuclidine-based SQS inhibitors such as 3-(biphenyl-4-yl)-3-hydroxyquinuclidine [BPQ-OH] as cholesterol- and triglyceride-lowering agents [51–53].

Allylamines are known inhibitors of squalene epoxidase. One good example is terbinafine, which has been shown to be a potent compound against fungi, showing both oral and topical efficacy. Terbinafine inhibits squalene epoxidase leading to a depletion of ergosterol. Importantly, it does not inhibit the mammalian enzyme [38].

Azoles are important inhibitors of C14α-demethylase, and since they are effective against most fungal diseases, they are presently considered to be the most important antifungal compounds in use. Ketoconazole, one of the first azoles developed, was intensely used for several years. More recently, however, four new commercially available triazoles have been shown to be much more effective: fluconazole, itraconazole, voriconazol, and posaconazole.

The last class of ergosterol biosynthesis inhibitors comprises the azasterols, which inhibit $\Delta^{24(25)}$-sterol methyltransferase (SMT). Inhibition of this step appears to have high selectivity for fungi and trypanosomatids since this enzyme is not found in mammalian cells. Antifungal activities of azasterols have been described for *Candida spp.* [38, 39], *Pneumocystis carinii* [54], and *Paracoccidioides brasiliensis* [55].

In conclusion, based on the comments made above it is clear that further exploration of the sterol biosynthesis pathway is highly relevant to the treatment of both chronic diseases, such as hypercholesterolemia, and infectious diseases caused by fungi and trypanosomatids. Therefore, drugs known to inhibit enzymes of the sterol biosynthesis pathway should be tested against all these diseases. Indeed, several drugs developed either to reduce cholesterol levels in humans or to treat fungal diseases have been tested with some success against trypanosomatids, as will be discussed below. We also believe that new drugs shown to be active against trypanosomatids should be tested on fungi as well as in mammals.

4. Effects of SB Inhibitors on Trypanosomatid Growth

In *T. cruzi,* inhibitors of HMG-CoA reductase such as mevinolin (lovastatin) have been tested *in vitro* and *in vivo*. Against the extracellular proliferative epimastigote forms, mevinolin produced a dose-dependent reduction of the growth rate up to 25 μM. In the intracellular proliferative amastigote forms only very modest effects were observed up to 0.75 μM, above which a significant effect was also observed in the mammalian host cells. In intracellular amastigotes, it has been shown that supplementation of mevinolin with ketoconazole gives a synergistic effect, so that lower concentrations of azoles become more effective. On the other hand, the combination of mevinolin with terbinafine produced an additive effect, whereas the combination of mevinolin, terbinafine, and ketoconazole showed again a synergistic effect on amastigotes [56]. These results together indicate that a combination of drugs acting in consecutive steps of the sterol biosynthesis pathway may be a promising approach for the treatment of diseases caused by some pathogenic protozoa.

Bisphosphonates have been tested *in vivo* and *in vitro* against different protozoan parasites, including *Leishmania spp.*, *T. cruzi, T. brucei, Plasmodium falciparum*, and *T. gondii* [57–59]. More than 50 new compounds were tested in different protozoan parasites, some of them presenting IC_{50} values lower than 1 μM [60, 61]. In addition, to confirm that the isoprenoid enzymes are involved in the inhibition, they were also tested on the isolated *L. major*, *T. cruzi*, and *T. gondii* farnesyl diphosphate synthase enzymes (LmFPPS, TcFPPS, and TgFPPS). A potent inhibition of the enzyme's activities indicated that some of them are specific for inhibition of the isoprenoid pathway, thus validating this pathway as an

Table 1: Representative compounds that interfere with sterol synthesis in eukaryotes, fungi and trypanosomatids.

Molecular structure	Name	Class	Mechanism of action
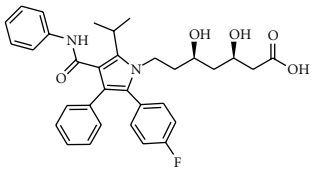	Atorvastatin	Statin	Inhibitor of the HMG-CoA Reductase. Used to treat hyperlipidemia in humans
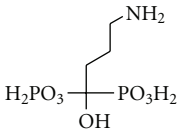	Alendronate	Bisphosphonate	Inhibitor of the farnesyl diphosphate synthase (FPPS). Used to treat osteoporosis and different bone resorption diseases
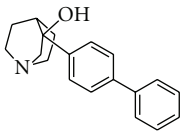	BPQ-OH	Quinuclidine	Inhibitor of the squalene synthase (SQS), acting in the cholesterol and ergosterol biosyntheses
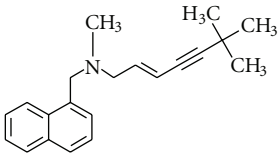	Terbinafine	Allylamine	Inhibitor of the squalene epoxidase. Used for a long time to treat fungal infections
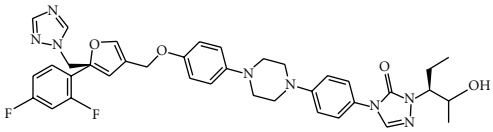	Posaconazole	Azole	Inhibitor of the C14α-demetilase. One of the triazole used to treat fungal infections
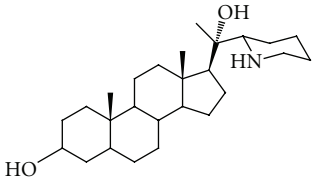	22,26-azasterol	Azasterol	Inhibitor of the $\Delta^{24(25)}$-sterol methyltransferase, one enzyme presents exclusively in the ergosterol biosynthesis

interesting and selective drug target for these parasites. Garzoni et al. [62] reported that risedronate showed a selective effect against *Trypanosoma cruzi*, leading to complete growth arrest and lysis at 150 μM for epimastigotes. Complete destruction of intracellular amastigotes was observed at 100 μM risedronate, thus preventing the development of *T. cruzi* infections in murine muscle heart or in Vero cells [62].

In trypanosomatids and fungi, there are several works describing the potent and selective activity of zaragozic acids and quinuclidines [35–37, 63–68]. For example, ER-119884 and E5700, two novel quinuclidine derivatives produced by Eisai Co. (Tokyo, Japan), have been shown to be potent anti-*Trypanosoma* and *Leishmania* agents *in vitro*, leading to a dramatic depletion of the parasite's endogenous sterols, that

is, associated with an intense antiproliferative activity [36, 37]. Figures 4(a)–4(d) shows the antiproliferative effect of E5700 (Figures 4(a) and 4(c)) and ER-119884 (Figures 4(b) and 4(d)) in promastigotes and intracellular amastigotes of *Leishmania amazonensis*. These compounds are very potent against both forms of the life cycle, presenting MIC values of 30 and 10 nM for promastigote, and 2.0 and 0.5 nM for intracellular amastigotes [37]. When compared with the minimal concentration that affects macrophages, these values are, respectively, 100 000 and 25 000 fold greater than the corresponding IC_{50}, indicating that they are selective against the parasite without any effect in the host cells.

In *Leishmania*, Vannier-Santos et al. [70] showed that terbinafine is able to interfere with the growth of promastigotes and intracellular amastigotes, inducing dramatic changes in their structural organization, especially in the mitochondrion. For terbinafine, the IC_{50} values were around 1 μM for promastigotes and 100 nM for intracellular amastigotes. However when in combination with ketoconazole, which also interferes with ergosterol biosynthesis, the values decreased to around 1 nM for intracellular amastigotes, indicating once more that the approach of inhibiting multiple steps of this pathway is a promising alternative for chemotherapy [70].

In trypanosomatids, azoles have been used *in vitro* against *T. cruzi* and *Leishmania*. Drugs such as D0870 and posaconazol were tested in vitro and *in vivo* with positive and interesting results, and also have a potent effect against acute and chronic experimental Chagas' disease [69, 71–75]. Ketoconazole was also tested alone or in combination with other sterol biosynthesis inhibitors [42, 44, 71, 76]. The IC_{50} of Posaconazole for *T. cruzi* epimastigotes and amastigotes was 3 and 0.25 nM, respectively. However when in combination with amiodarone, a K^+ and Ca^{2+} channel antagonist, they presented synergistic effects with a fractional inhibitory concentration (FIC) of 0.42 μM [73]. Amiodarone was also tested in *Leishmania mexicana*, having an IC_{50} similar to that found for *T. cruzi*, due to alterations in the physiology of the mitochondrion and acidocalcisomes [77].

The effects of azasterols on *T. cruzi* [4, 42–44, 78], *Leishmania* [5, 11, 47, 78, 79], and *T. brucei* [16] have been extensively studied. The antifungal activities of azasterols against *Candida spp.*, *P. carinii* [54], and *P. brasiliensis* [55] have also been described. We have shown that several azasterols are active against *L. amazonesis* with IC_{50}s in the submicromolar to nanomolar range, indicating that this step has potential as a chemotherapeutic target [11, 78, 80]. Furthermore, when in combination with azoles they are even more effective, and sometimes acting synergistically [43].

5. Effects of SB Inhibitors on the Ultrastructure of Trypanosomatids

It has been shown that ergosterol biosynthesis inhibitors induce dramatic alterations in the ultrastructure of several organelles [11, 37, 64, 66, 70, 74–76, 78–81]. These alterations occur mainly in the mitochondrion-kinetoplast complex, the endoplasmic reticulum, the Golgi complex, nucleus, multivesicular structures, lipidic inclusions, the contractile vacuole, and also in the plasma membrane covering the cell body, and the flagellum.

The mitochondrion-kinetoplast complex has been shown to constitute an important organelle target of drugs that inhibit sterol biosynthesis. It is important to point out that *T. cruzi* and *Leishmania* have only one highly ramified mitochondrion distributed throughout the protozoan body (Figure 5(a)) (reviewed in [82]). Treatment of *L. amazonensis* with different azasterols induced mitochondrion alterations such as a disorganization of the mitochondrial membranes (Figures 5(b)-5(c)) followed by an intense swelling and loss of the matrix contents (Figures 5(b)-5(d)) [11, 76]. These alterations in the mitochondrion were also observed after treatment of *T. cruzi* and *L. amazonensis* with terbinafine, ketoconazole, and ICI195,739 [70, 74–76]. The swelling is dramatic and the mitochondrion appears to occupy the whole cytosol in epimastigotes treated with ketoconazole (Figures 6(a)-6(b)). The mitochondrial alterations were confirmed by measuring the mitochondrial membrane potential in digitonin-permeabilized parasites [79]. On the other hand, the inhibitors did not affect the macrophage's mitochondria, which can be visualized using JC-1, a cationic mitochondrial vital dye [37]. Most probably all these morphological changes are due to modifications in the composition of the mitochondrial membranes due to interference with the synthesis of ergosterol and accumulation of intermediate metabolites [83]. Lipid analysis performed in epimastigotes of *T. cruzi* showed that the mitochondrion has a different lipid composition when compared with mammalian cells, including the presence of ergosterol, thus explaining the potent effect of SB inhibitors on its ultrastructure and physiology [84].

One characteristic feature of the unique mitochondrion of trypanosomatids is the presence of a complex network of DNA localized in a portion of the mitochondrion. This network is located just below the basal bodies from which the flagellum is formed, and is known as the kinetoplast (reviewed in [85]). The kinetoplast DNA is organized as thousands of concatenated minicircles and a few maxicircles. It was shown that after treatment with E5700, an SQS inhibitor, alterations were observed in the kinetoplast structure of *L. amazonensis*. In treated cells, the kinetoplast appeared completely disorganized relative to its normal structure (Figure 6(c)). These alterations probably result from changes that take place in the organization of the inner mitochondrial membrane, that is, connected to the kinetoplast DNA network.

Alterations in the nuclear membrane, Golgi complex and endoplasmic reticulum were also observed after treatment with different SB inhibitors (Figures 7(a)–7(c)). The presence of a multivesicular body associated with the trans-Golgi network can be seen in Figure 7(b) (star), thus suggesting alterations in the secretory pathway. Furthermore, Figure 7(c) (stars) also shows the presence of some vacuoles resembling autophagosomes, thus suggesting the occurrence of cell death by autophagy (reviewed in [86–88]). The presence of large vacuoles containing membrane profiles, endoplasmic reticulum forming myelin-like figures or engulfing a part of

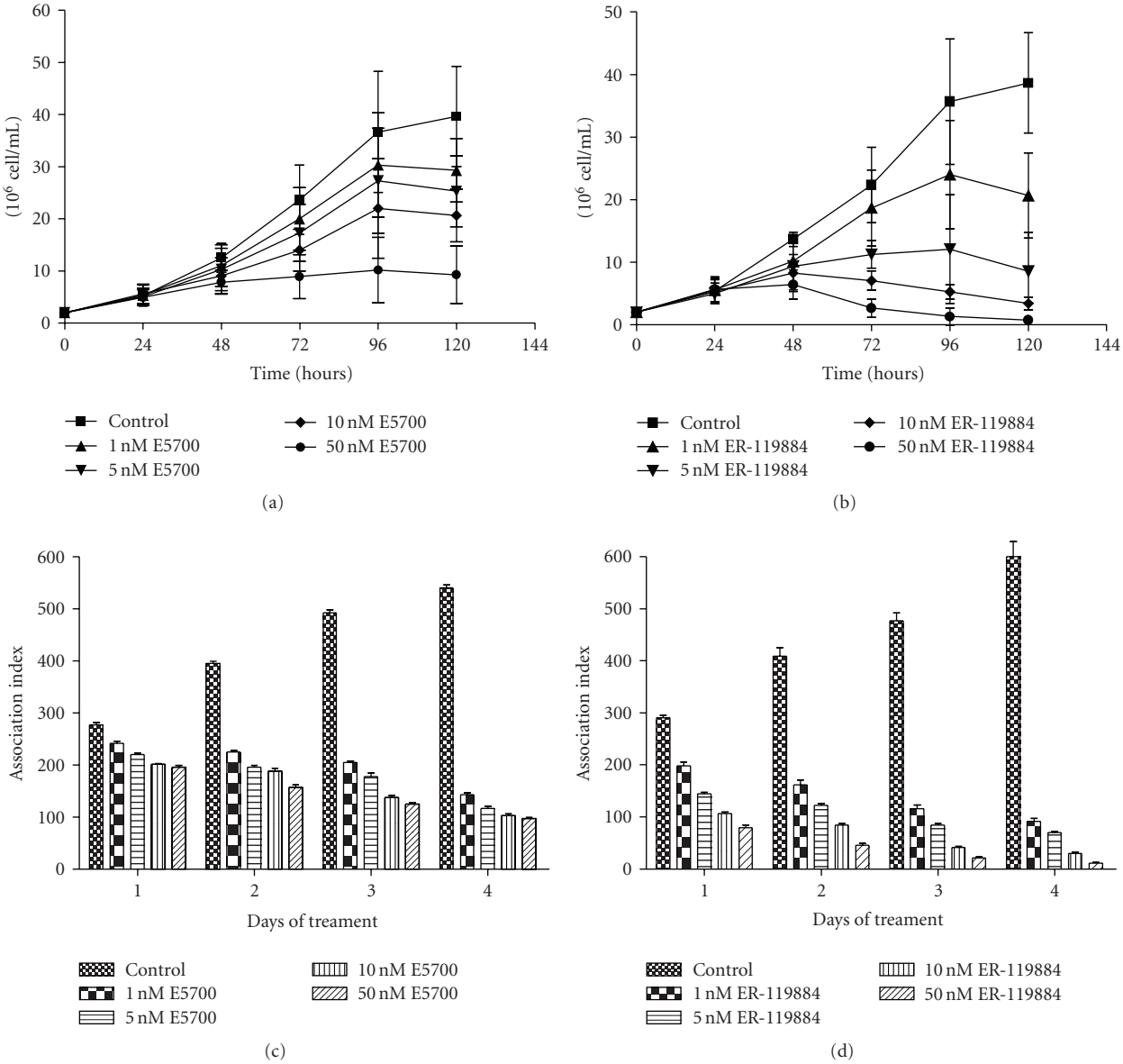

Figure 4: (a)-(b) Growth curves of promastigotes and (c)-(d) intracellular amastigotes of *Leishmania amazonensis* treated with two potent squalene synthase inhibitors, E5700 and ER-119884. The graphics are reproduced with permission from [37] American Society for Microbiology.

the cytoplasm, and damaged organelles supports the idea that an autophagy-like process takes place in these cells (Figures 8(a)-8(b)).

Recent studies using various microscopy techniques have shown that trypanosomatids possess a structure located close to the flagellar pocket identified as a contractile vacuole (reviewed in [89]). This structure became much more evident in *L. amazonensis* (Figures 9(a)-9(b)) and *T. cruzi* epimastigotes [64] treated with SB inhibitors. As observed by differential interference contrast microscopy, the treated cells appeared rounded and swollen (Figure 9(a)), suggesting osmotic changes, thus explaining the presence of a prominent contractile vacuole. These changes may be due to alterations in the plasma membrane's permeability to ions induced by the complete depletion of sterols and sterol-like molecules, which is likely to lead to significant changes of the physicochemical properties of the lipid bilayer [90].

Another important alteration observed after treatment with SB inhibitors is the presence of several lipid droplets displaying variable morphology, as shown in Figures 10(a)-10(b). The formation of these structures is probably due to accumulation of lipid precursors. The images showed a large variation in the electron density of the structures, suggesting that different types of lipids are accumulated. Some appeared very dense after postfixation with osmium tetroxide (Figure 10(a)). Others, however, appeared as electron-lucent structures (Figure 10(b), large arrows and stars). They are surrounded by a typical monolayer of phospholipids

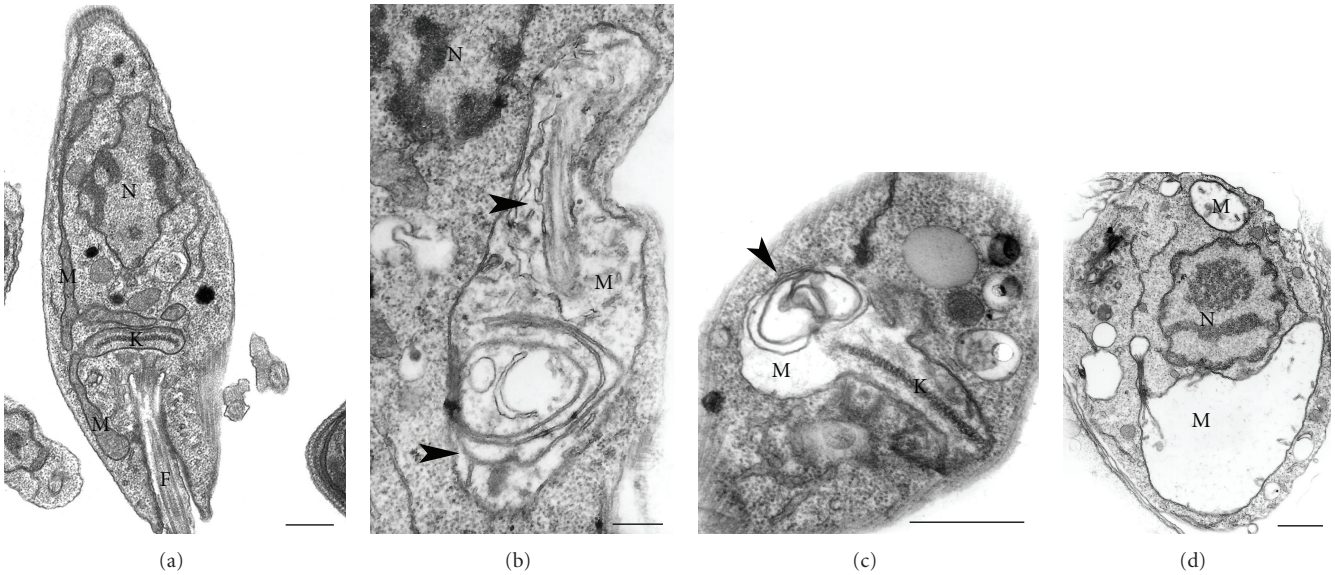

Figure 5: Ultrathin sections of *L. amazonensis* promastigotes control (a) and treated with azasterols, known inhibitors of the $\Delta^{24(25)}$-sterol methyltransferase (b)–(d). (a) General overview of an untreated-parasite showing a normal ultrastructure of the mitochondrion (M), kinetoplast (k), flagellum (F) and nucleus (N). (b)–(d) Treated-parasites presenting severe alterations in the mitochondrion structure such as a disorganization of the internal membranes ((b) and (c), *arrowheads*) and an intense and evident mitochondrial swelling with loss of the matrix content (b)–(d). Bars 0.5 μm.

(high magnification in Figure 10(b)). These lipid droplets could be also identified by fluorescence microscopy using the neutral lipid marker Nile Red [37]. Lipid droplets were also observed in *L. major* null mutants for important enzymes of the sphingolipid biosynthesis pathway [91, 92], and in *T. cruzi* after perturbation of the sphingolipid content [93]. On the other hand, they also accumulated when epimastigotes were treated with different classes of inhibitors, including cytoskeletal inhibitors [94], indicating that lipid body formation can occur as a consequence of perturbations in parasitic functions not related to lipid biosynthesis.

Alterations in the plasma membrane lining the cell body, flagellar pocket and flagellum were also observed, but the morphological changes varied according to the inhibitor (Figures 11(a)-11(b)). When the parasites where incubated with azasterols, alterations in the flagellar pocket were predominant (Figure 11(a)), while SQS inhibitors induced alterations mainly in the membrane lining the cell body (Figure 11(c)-11(d)) and sometimes in the flagellar membrane (Figure 11(b)) [64]. These different phenotypes suggest that the three domains of the plasma membrane have distinct lipid compositions. On the other hand, the presence of membrane blebs could be related to apoptosis-like death [86].

It is well known that in trypanosomatids there is a close connection between the plasma membrane lining the cell body and the subpellicular microtubules, and that the spatial distribution of these microtubules is responsible for the maintenance of the protozoan's shape (reviewed in [95]). Immunofluorescence microscopy of tubulin-stained trypanosomes treated with an SBI revealed changes in the shape of the cell and in the distribution of the subpellicular microtubules, probably due to alterations in the sterol composition of the plasma membrane [37]. Figures 12(a)–12(d) show the effect of ER-119884, an SQS inhibitor, on the cytoskeleton of *L. amazonensis* promastigotes. The changes were also seen by transmission electron microscopy (Figure 11(d)).

Recent observations show that SBIs also interfere with the protozoan cell cycle. Using fluorescence microscopy of cells stained with DAPI to label the nucleus and kinetoplast, as well as transmission electron microscopy, it was shown that ER-119884 and BPQ-OH interfere dramatically with the cell cycle, inducing several abnormal phenotypes, including cells with multiple nuclei, kinetoplasts, and flagella (Figures 13(a)–13(d)). The effect on the cell cycle was already evident after 24 hours of incubation in the presence of the inhibitors, and the number of cells containing abnormal numbers of flagella, kinetoplasts, and nuclei increased with time [37]. There are at least two possible explanations for these effects: (i) the cells do not complete cell division due to the depletion of essential endogenous sterols, which control the dynamics of the membrane but are also key regulators of the cell cycle [96, 97], or (ii) the organization of the cytoskeleton necessary for the completion of cytokinesis, which requires interactions with the nuclear membrane, is in some way affected by SQS inhibitors. In addition, SBI also induced significant alterations in the trypanosomatids' nuclei.

A significant number of treated cells showed abnormal chromatin condensation (Figure 14), indicating a process of cell death by apoptosis (reviewed in [86–88]).

All these alterations discussed here indicate that sterols play an essential role in a significant number of cellular processes, including the cell cycle, cell death, and the

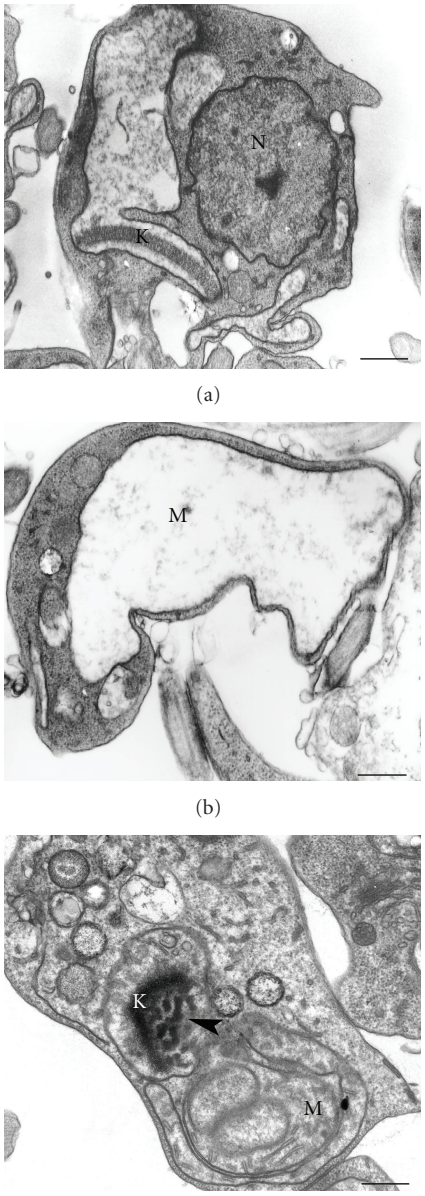

Figure 6: *Trypanosoma cruzi* epimastigotes treated with ketoconazole, an inhibitor of the C14α-demetilase (a)-(b), and *L. amazonensis* promastigotes treated with E5700, an inhibitor of the squalene synthase (c) showing an intense mitochondrial swelling (a)-(b) and alterations in the kinetoplast structure ((c), *arrowhead*). K, kinetoplast; M, mitochondrion. (a)-(b) Images are reproduced with permission from [74] American Society for Microbiology. Bars, 0.5 μm.

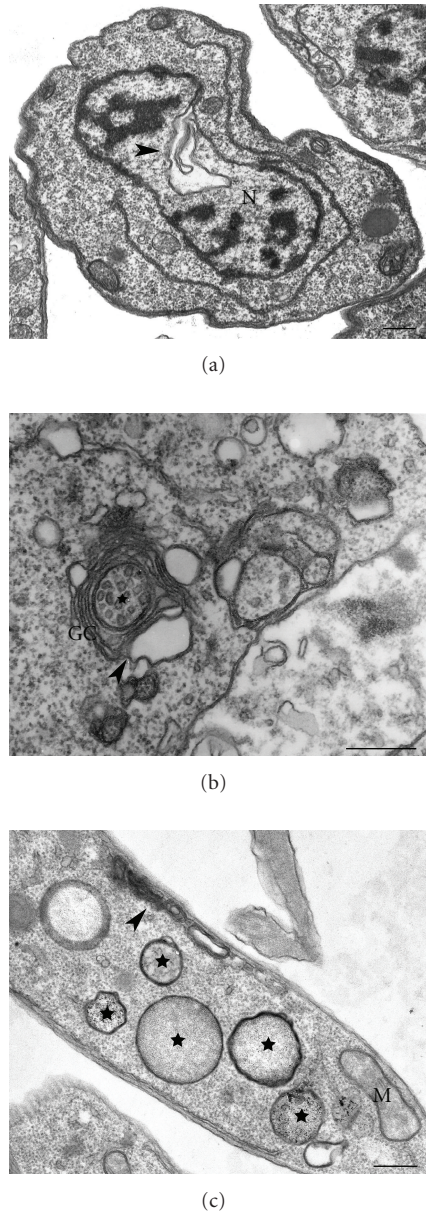

Figure 7: *L. amazonensis* promastigotes treated with azasterols (a)-(b), and ER-119884 (c) showing alterations in the nuclear membrane ((a), *arrowhead*), in the Golgi complex ((b), *arrowhead*), and in the endoplasmic reticulum ((c), *arrowhead*). In the Figures 6(b) and 6(c), the presence of a multivesicular bodies and autophagosome-like structures (*stars*) could be related with a remodeling process of damaged organelle by autophagy. GC, Golgi complex; M, mitochondrion; N, nucleus. Bars, 0.5 μm.

maintenance of the membrane's structure, stability, and function.

6. Effects of SB Inhibitors on Lipid Composition

It is now well established that SB inhibitors lead to the accumulation of intermediates of the ergosterol biosynthesis pathway (reviewed in [4]). Treatment of *T. cruzi* epimastigotes with mevinolin, an inhibitor of HMG-CoA reductase, led to a significant reduction in the presence of ergosterol-like molecules, with a concomitant increase in exogenous cholesterol [56].

Incubation of the parasites with bisphosphonates, inhibitors of the farnesyl diphosphate synthase (FPPS),

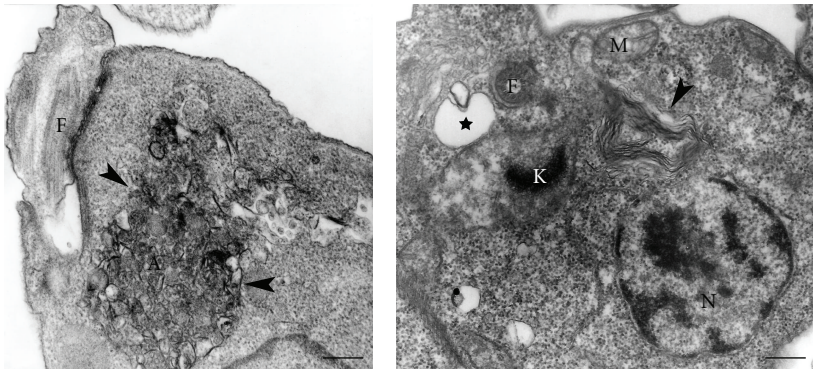

(a) (b)

Figure 8: Promastigotes treated with quinuclidine and azasterol, respectively, showing the presence of structures related with autophagy such as a large vacuole containing many membrane profiles ((a), *arrowheads*), and a myelin-like figures involving part of the cytosol ((b), *arrowhead*). Star indicates the presence of a possible contractile vacuole near the flagellar pocket. A, autophagosome; F, flagellum; K, kinetoplast; M, mitochondrion; N, nucleus. (a) This image is reproduced with permission from [66] Elsevier. Bars, 0.25 μm.

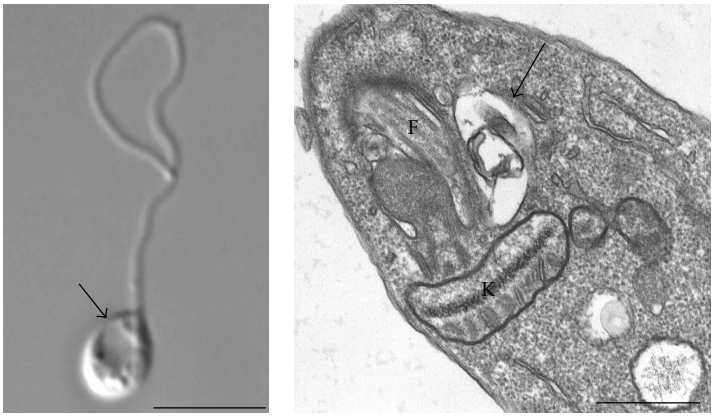

(a) (b)

Figure 9: (a) Diferential interference contrast (DIC) microscopy and (b) transmission electron microscopy showing the presence of a prominent contractile vacuole (arrows) near the flagellar pocket after treatment of *L. amazonensis* promastigotes with quinuclidine inhibitors. In the left panel it is possible to observe a rounded and swollen parasite that probably indicates osmotic changes due alterations in the plasma membrane's permeability. F, flagellum; K, kinetoplast. Bars, 5 μm and 0.5 μm, respectively.

induces an accumulation of isopentenyl diphosphate (IPP) and inhibits the formation of farnesyl diphosphate (FPP). Consequences of this inhibition include a decrease in the level of protein prenylation, and reduced production of molecules such as dolichols, ubiquinones, heme a, and sterols (reviewed in [58]).

The inhibition of squalene synthase (SQS) induces a total depletion of squalene, endogenous ergosterol, and other 24-methyl sterols, and these are completely replaced by exogenous cholesterol [35–37]. This potent effect in the sterol composition is consistent with the inhibition of SQS enzyme in concentrations near the nanomolar to subnanomolar range, in a reaction that is noncompetitive with the substrate [37].

Treatment of *L. mexicana* promastigotes with terbinafine, a potent inhibitor of squalene-2,3-epoxidase, results in the accumulation of squalene, and a reduction in the amount of endogenous C_{28}- and C_{29}-sterols [98]. In *T. cruzi* epimastigotes the same treatment led to the depletion of sterols and accumulation of phosphorylated hydrocarbons, with a lower amount of squalene when compared with *Leishmania* [99]. The K^+ and Ca^{+2} channel antagonist amiodarone also induces the inhibition of squalene epoxidase in *T. cruzi* and *L. mexicana*, leading to an accumulation of squalene and complete depletion of 24-methyl sterols such as ergosterol and 5-dehydroepisterol [73, 77].

Incubation of the parasites in the presence of azoles, which inhibit C14α-demethylase, led to the replacement of normal endogenous sterols by various 14α-methyl sterols. In this situation, the first sterol that accumulates in promastigotes of *Leishmania* is 4α,14α-dimethyl-dimethylzymosterol; however, after a long exposure this sterol molecule could be metabolized by 24-SMT, producing sterols alkylated at C-24, or demethylated at C-4 by C4α-demethylase to produce

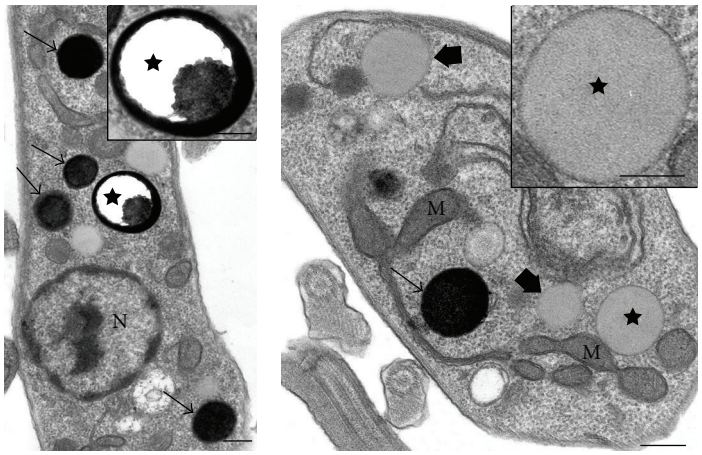

(a) (b)

Figure 10: Treatment of promastigotes with ER-119884 induces the accumulation of several lipid droplets in the cytosol, sometimes appearing as an electrondense structure due to osmium tetroxide concentration ((a)-(b), *small arrows*), and as a classic lipid body surrounded by a phospholipid monolayer ((b), *large arrows*). At high magnification (*stars*), it is evident that the structures are completely different, probably indicating a distintic nature of the lipids that accumulate in these inclusions. M, mitochondrion; N, nucleus. All images are reproduced with permission from [37] American Society for Microbiology. Bars, 0.5 μm.

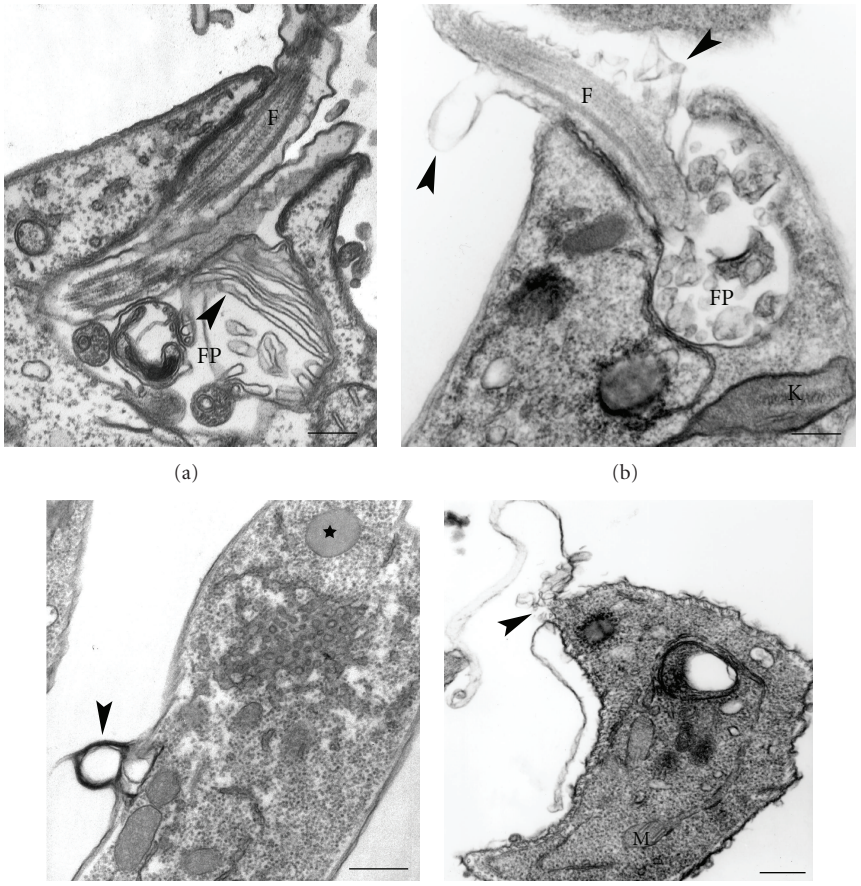

(a) (b)

(c) (d)

Figure 11: Ultrathin sections of *L. amazonensis* promastigotes treated with different sterol biosynthesis inhibitors showing severe alterations in the plasma membrane lining (a) the flagellar pocket, (b) the flagellum, and (c)-(d) the cell body. In (d) it is possible to observe a breakdown in the plasma membrane and release of the subpellicular microtubules (*arrowhead*). Star in (c) shows a classic lipid body. F, flagellum; FP, flagellar pocket; k, kinetoplast; M, mitochondrion. Images are reproduced with permission from [79] (a), and [66] (b), (d) Elsevier. Bars, 0.25 μm (a)–(c) and 0.5 μm (d).

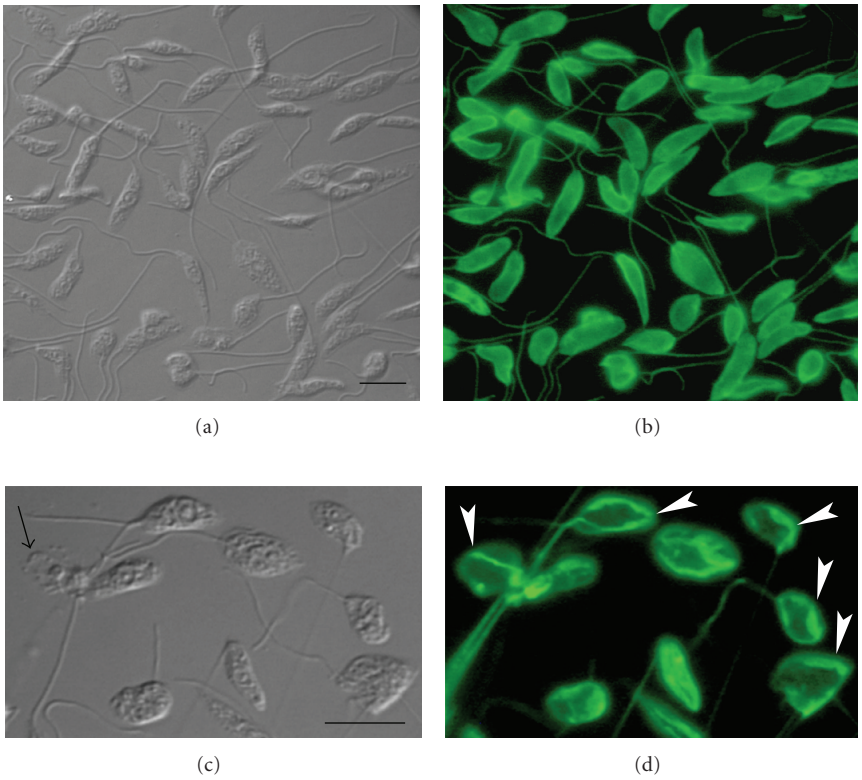

Figure 12: DIC microscopy (left panel) and immunofluorescence microcospy (right panel) of *L. amazonensis* promastigotes control (a)-(b) and treated with ER-119884 (c)-(d). The labeling corresponds to the cytoskeleton constituted mainly by tubulin, revelead here by using of an Alexa 488-labeled secondary antibody. The black arrow in DIC image corresponds to the cell body which sometimes appeared changed and rounded as compared to the control parasites, while the white arrows point to several tubulin clusters that accumulated in the cytosol after treatment. All images are reproduced with permission from [37] American Society for Microbiology. Bars, 5 μm.

4-desmethylsterol [11, 46, 100]. In *T. cruzi* epimastigotes and amastigotes, the accumulating 14α-methylsterol is lanosterol, particularly its C-24 alkylation product (24-methylenedihydrolanosterol) [5, 14, 69, 71–75, 99, 101]. Unlike *Leishmania*, demethylation at C4 seems to be very restricted in *T. cruzi,* and the C4α-demethylase has higher specificity for sterols after the removal of the 14α-methyl. On the other hand, treatment with SCH 56592 (posaconazole) also causes an accumulation of squalene, possibly indicating that some regulatory step involved in squalene cyclization is regulated by high amounts of lanosterol and its 24-methylene derivatives [72].

The C-24 transmethylation reaction catalyzed by 24-SMT in trypanosomatids is inhibited by various azasterols that have a nitrogen substitution in the side chain. This leads to a depletion of C_{28}-sterols such as ergosterol, episterol, and 5-dehydroepisterol, which are then replaced by large amounts of zimosterol and cholesterol ingested from the culture media [11, 42, 43, 102] through the endocytic pathway [3]. Furthermore, a simultaneous incubation with azasterol and ketoconazole induces an accumulation of lanosterol, 4,14-dimethyl-zymosterol, and 14-methyl-zymosterol [11, 42, 43], indicating that the mechanism of action of 24-SMT in trypanosomatids is similar to that observed in fungi, yeasts, and plants [32, 38, 44, 103–105]. These results also indicate that in some trypanosomatids, 24-SMT can use zymosterol or its 14-methyl or 4,14-dimethyl derivatives as substrates. In the case of fungi, the substrate for 24-SMT is restricted to zymosterol [32, 38]. On the other hand, experiments exposing *Leishmania spp.* to low concentration azasterol for a long time showed that they are able to survive by modulating biosynthesis to use C_{27}-sterols as substrates for 24-SMT [102]. Thus, these biochemical analyses indicate that in the case of sterol biosynthesis it is better to use combination therapy to inhibit more than one step in order to completely eliminate all the sterol substrates, particularly of the 24-SMT enzyme, which participates in essential reactions.

It is important to point out that in all biochemical analyses of the lipid composition of trypanosomatids after drug treatment, a significant accumulation of cholesterol is observed in both *T. cruzi* and *Leishmania spp.,* indicating that the parasites try to compensate for the absence of endogenous sterols. It is also clear that 24-methyl and/or 24-ethyl sterols are essential for the maintenance of membrane structure and function, as well as other vital cellular process like the cell cycle.

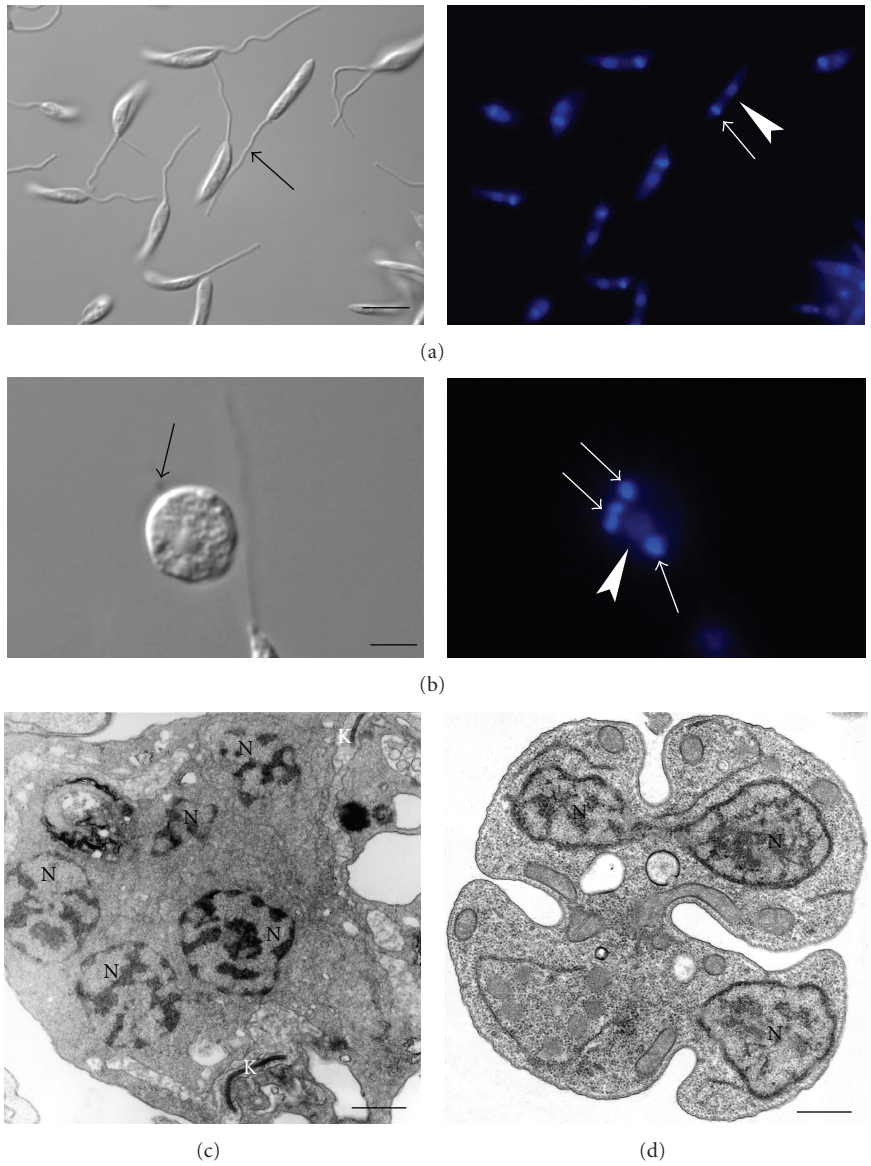

Figure 13: DIC microscopy ((a)-(b), *left panel*), fluorescence with DAPI ((a)-(b), *right panel*) and transmission electron microscopy (c)-(d) of treated-promastigotes to evidenciate the alterations in the cell cycle after treatment with BPQ-OH and ER-119884. (a) Control cells present a correct number of kinetoplast (white arrow), nucleus (arrowhead), and flagellum (black arrow), one of each for a unique cell. (b) After treatment, the number of these organelles is completely alterated and it is possible to find cells with one flagellum (black arrow), four kinetoplast (white arrows), and one nucleus (arrowhead). (c)-(d) Alterations in the cell cycle can also be evidenced by transmission electron microscopy with the appearance of cells with several nuclei and kinetoplasts. K, kinetoplast; N, nucleus. These images are reproduced with permission from [37] American Society for Microbiology (a), (b), (d), and from [66] Elsevier (c). Bars, 5 μm (a)-(b), and 0.5 μm (c)-(d).

7. Effects of SB Inhibitors in Experimentally Infected Animals and Perspectives for Human Therapy

Several of the SB inhibitors have been tested using murine models of Chagas' disease, leishmaniasis, and malaria. Treatment of acute Chagas' disease with mevinolin (lovastatin) in combination with ketoconazole led to the elimination of circulating parasites and complete protection against death in the murine model [56].

Bisphosphonates were also tested in acute Chagas' disease as well as in leishmaniasis experimental models. In *Leishmania* infections, recent studies showed that pamidronate is able to promote a radical cure of experimental cutaneous leishmaniasis in mice [105], and also that it is active *in vivo* against *L. donovani* by intravenous administration [106]. Furthermore, *in vivo* studies using the murine model of acute Chagas' disease showed that treatment with 1 mg/kg risedronate per day for 7 days induced a more than 90% reduction in parasitemia and significantly increased the animals' survival. On the other hand, at higher concentrations

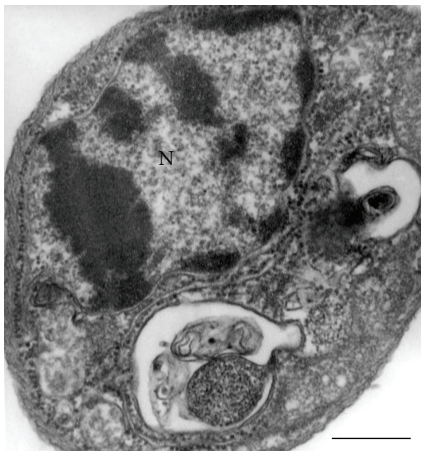

Figure 14: *Leishmania amazonensis* promastigote treated with sterol biosynthesis inhibitors showing a condensation of the nuclear chromatin, a characteristic feature of the apoptosis-like cell death process. N, nucleus. Bar, 0.5 μm.

(up to 10 mg/kg per day), risedronate led to a reduction of parasitemia and mortality with no toxic effects for the treated animals [107].

Inhibitors of squalene synthase such as ER-119884 and E5700 were also tested in a murine model of Chagas' disease, revealing that E5700 is able to provide full protection against death and to completely suppress parasitemia, with no toxicity to the host [36].

Some azoles were also tested against *T. cruzi* and *Leishmania spp.* with interesting results. D0870, a bis-triazole derivative, showed a potent effect, preventing death and inducing parasitological cure in 70 to 90% of animals in acute and chronic murine models of Chagas' disease [71, 108]. SCH 56592 (posaconazole), which is one of the new triazole derivatives, has been tested against Chagas' disease [72, 109] and leishmaniasis [110]. In the acute Chagas' disease model, 43 doses of $\geq$10 mg/kg of body weight/day promoted 85 to 100% survival, with 90 to 100% cure of the animals as verified by parasitological, serological and PCR-diagnostics. By contrast, ketoconazole at 30 mg/kg/day gave only a 60% survival rate and a 20% cure rate. [72]. In the chronic phase, the results were also positive, with 85% of the animals protected from death and 75% parasitologically cured. In addition, the combination of posaconazole with amiodarone produced a delay in the development of parasitemia after a high rate of infection mice, and in mice with a lower infection rate, the survival and cure were higher when compared with posaconazole alone [73]. Amiodarone alone also led to a decrease in parasitemia and a 40% increase in the survival of the infected animals [73]. On the other hand, in cutaneous leishmaniasis, treatment with 60 and 30 mg/kg/day, of SCH 56592 was highly efficacious, and the higher dose was superior to amphotericin B at a dose of 1 mg/kg/day [110]. In visceral leishmaniasis due to *L. donovani* infection, treated mice showed a significant reduction in parasite burden in the liver and spleen compared to untreated mice [110].

In vivo studies with 22,26-azasterol, one of the most potent inhibitors of 24-SMT, have shown that it has selective antiparasitic activity in a murine model of acute Chagas' disease [43].

8. Perspectives

It is clear that the sterol biosynthesis pathway plays a key role in the metabolism of eukaryotic cells. The observation that compounds found in several steps of this metabolic pathway plays essential roles in several basic physiological processes spurred several groups to further analyze this metabolic pathway. From the parasitological point of view, it will be important to test new drugs developed for other medical purposes, such as control of blood cholesterol levels in humans, against trypanosomatids. The same assumption is valid for drugs interfering with the SB pathway in fungal cells. On the other hand, since trypanosomatids, fungi and mammals share several steps of the SB pathway, the trypanosomatids may constitute a useful biological system for the screening of candidate SB inhibitors, and thereby facilitate the search for cholesterol-control drugs for humans. Finally, we expect that new studies will appear providing a better characterization of the last steps of the SB pathway, especially those involved in transformation of zimosterol into ergosterol.

Acknowledgments

The authors were supported by the Conselho Nacional de Desenvolvimento Científico e Tecnológico (CNPq), Programa de Núcleos de Excelência (PRONEX), Fundação Carlos Chagas Filho de Amparo à Pesquisa do Estado do Rio de Janeiro (FAPERJ), and Coordenação de Aperfeiçoamento de Pessoal de Nível Superior (CAPES). J. C. F. R. has a posdoctoral fellowship from the Coordenação de Aperfeiçoamento de Pessoal de Nível Superior (CAPES). This review is in celebration of the 100th anniversary of Chagas' disease discovery.

References

[1] L. J. M. Fagundes, *Estudo de esteróis e lipídeos totais em Leptomonas pessoai cultivada a 28°C e 37°C*, M.S. thesis, Instituto de Microbiologia da Universidade Federal do Rio de Janeiro, Rio de Janeiro, Brazil, 1974.

[2] W. de Souza, C. Sant'anna, and N. L. Cunha-e-Silva, "Electron microscopy and cytochemistry analysis of the endocytic pathway of pathogenic protozoa," *Progress in Histochemistry and Cytochemistry*, vol. 44, no. 2, pp. 67–124, 2009.

[3] M. J. Soares and W. de Souza, "Endocytosis of gold-labeled proteins and LDL by *Trypanosoma cruzi*," *Parasitology Research*, vol. 77, no. 6, pp. 461–468, 1991.

[4] J. A. Urbina, "Lipid biosynthesis pathways as chemotherapeutic targets in kinetoplastid parasites," *Parasitology*, vol. 114, supplement 1, pp. S91–S99, 1997.

[5] C. W. Roberts, R. McLeod, D. W. Rice, M. Ginger, M. L. Chance, and L. J. Goad, "Fatty acid and sterol metabolism:

potential antimicrobial targets in apicomplexan and trypanosomatid parasitic protozoa," *Molecular and Biochemical Parasitology*, vol. 126, no. 2, pp. 129–142, 2003.

[6] S. Halevy and L. Avivi, "Sterols of trypanosomidae," *Annals of Tropical Medicine and Parasitology*, vol. 60, pp. 439–444, 1966.

[7] H. Dixon, C. D. Ginger, and J. Williamson, "Trypanosome sterols and their metabolic origins," *Comparative Biochemistry and Physiology*, vol. 41, no. 1, pp. 1–18, 1972.

[8] E. D. Korn, T. von Brand, and E. J. Tobie, "The sterols of *Trypanosoma cruzi* and *Crithidia fasciculata*," *Comparative Biochemistry and Physiology*, vol. 30, no. 4, pp. 601–610, 1969.

[9] P. A. Haughan and L. J. Goad, "Lipid biochemistry of trypanosomatids," in *Biochemical Protozoology*, G. Coombs and M. North, Eds., pp. 312–328, Taylor & Francis, London, UK, 1991.

[10] L. J. Goad, G. G. Holz Jr., and D. H. Beach, "Sterols of *Leishmania* species. Implications for biosynthesis," *Molecular and Biochemical Parasitology*, vol. 10, no. 2, pp. 161–170, 1984.

[11] J. C. F. Rodrigues, M. Attias, C. Rodriguez, J. A. Urbina, and W. de Souza, "Ultrastructural and biochemical alterations induced by 22,26-azasterol, a $\Delta^{24(25)}$-sterol methyltransferase inhibitor, on promastigote and amastigote forms of *Leishmania amazonensis*," *Antimicrobial Agents and Chemotherapy*, vol. 46, no. 2, pp. 487–499, 2002.

[12] L. J. Goad, J. S. Keithley, J. D. Berman, D. H. Beach, and G. G. Holz, "The sterols of *Leishmania* promastigotes and amastigotes: possible implications for chemotherapy," in *Leishmaniasis*, D. T. Hart, Ed., pp. 495–501, Plenum, New York, NY, USA, 1989.

[13] D. H. Beach, L. J. Goad, and G. G. Holz Jr., "Effects of ketoconazole on sterol biosynthesis by *Trypanosoma cruzi* epimastigotes," *Biochemical and Biophysical Research Communications*, vol. 136, no. 3, pp. 851–856, 1986.

[14] A. Liendo, G. Visbal, M. M. Piras, R. Piras, and J. A. Urbina, "Sterol composition and biosynthesis in *Trypanosoma cruzi* amastigotes," *Molecular and Biochemical Parasitology*, vol. 104, no. 1, pp. 81–91, 1999.

[15] I. Coppens, P. Baudhuin, F. R. Opperdoes, and P. J. Courtoy, "Receptors for the host low density lipoproteins on the hemoflagellate *Trypanosoma brucei*: purification and involvement in the growth of the parasite," *Proceedings of the National Academy of Sciences of the United States of America*, vol. 85, no. 18, pp. 6753–6757, 1988.

[16] L. Gros, V. M. Castillo-Acosta, C. J. Jiménez, et al., "New azasterols against *Trypanosoma brucei*: role of 24-sterol methyltransferase in inhibitor action," *Antimicrobial Agents and Chemotherapy*, vol. 50, no. 8, pp. 2595–2601, 2006.

[17] K. R. Matthews, "The developmental cell biology of *Trypanosoma brucei*," *Journal of Cell Science*, vol. 118, no. 2, pp. 283–290, 2005.

[18] K. Fenn and K. R. Matthews, "The cell biology of *Trypanosoma brucei* differentiation," *Current Opinion in Microbiology*, vol. 10, no. 6, pp. 539–546, 2007.

[19] K. M. Tyler and D. M. Engman, "The life cycle of *Trypanosoma cruzi* revisited," *International Journal for Parasitology*, vol. 31, no. 5-6, pp. 472–481, 2001.

[20] M. A. Vannier-Santos, A. Martiny, and W. de Souza, "Cell biology of *Leishmania spp.*: invading and evading," *Current Pharmaceutical Design*, vol. 8, no. 4, pp. 297–318, 2002.

[21] P. J. Trocha and D. B. Sprinson, "Location and regulation of early enzymes of sterol biosynthesis in yeast," *Archives of Biochemistry and Biophysics*, vol. 174, no. 1, pp. 45–51, 1976.

[22] J. Peña-Diaz, A. Montalvetti, C.-L. Flores, et al., "Mitochondrial localization of the mevalonate pathway enzyme 3-hydroxy-3-methyl-glutaryl-CoA reductase in the Trypanosomatidae," *Molecular Biology of the Cell*, vol. 15, no. 3, pp. 1356–1363, 2004.

[23] J. Carrero-Lérida, G. Pérez-Moreno, V. M. Castillo-Acosta, L. M. Ruiz-Pérez, and D. González-Pacanowskda, "Intracellular location of the early steps of the isoprenoid biosynthetic pathway in the trypanosomatids *Leishmania major* and *Trypanosoma brucei*," *International Journal for Parasitology*, vol. 39, no. 3, pp. 307–314, 2009.

[24] G. A. Keller, M. Pazirandeh, and S. Krisans, "3-hydroxy-3-methylglutaryl coenzyme A reductase localization in rat liver peroxisomes and microsomes of control and cholestyramine-treated animals: quantitative biochemical and immunoelectron microscopical analyses," *Journal of Cell Biology*, vol. 103, no. 3, pp. 875–886, 1986.

[25] L. M. Olivier and S. K. Krisans, "Peroxisomal protein targeting and identification of peroxisomal targeting signals in cholesterol biosynthetic enzymes," *Biochimica et Biophysica Acta*, vol. 1529, no. 1–3, pp. 89–102, 2000.

[26] P. Hugueney, F. Bouvier, A. Badillo, J. Quennemet, A. d'Harlingue, and B. Camara, "Developmental and stress regulation of gene expression for plastid and cytosolic isoprenoid pathways in pepper fruits," *Plant Physiology*, vol. 111, no. 2, pp. 619–626, 1996.

[27] K. Okada, T. Saito, T. Nakagawa, M. Kawamukai, and Y. Kamiya, "Five geranylgeranyl diphosphate synthases expressed in different organs are localized into three subcellular compartments in *Arabidopsis*," *Plant Physiology*, vol. 122, no. 4, pp. 1045–1056, 2000.

[28] N. Cunillera, A. Boronat, and A. Ferrer, "The *Arabidopsis thaliana* FPS1 gene generates a novel mRNA that encodes a mitochondrial farnesyl-diphosphate synthase isoform," *The Journal of Biological Chemistry*, vol. 272, no. 24, pp. 15381–15388, 1997.

[29] L. M. Olivier, W. Kovacs, K. Masuda, G.-A. Keller, and S. K. Krisans, "Identification of peroxisomal targeting signals in cholesterol biosynthetic enzymes: AA-CoA thiolase, HMG-CoA synthase, MPPD, and FPP synthase," *Journal of Lipid Research*, vol. 41, no. 12, pp. 1921–1935, 2000.

[30] A. Ortiz-Gómez, C. Jiménez, A. M. Estévez, J. Carrero-Lérida, L. M. Ruiz-Pérez, and D. González-Pacanowska, "Farnesyl diphosphate synthase is a cytosolic enzyme in *Leishmania major* promastigotes and its overexpression confers resistance to risedronate," *Eukaryotic Cell*, vol. 5, no. 7, pp. 1057–1064, 2006.

[31] Y. Ling, Z.-H. Li, K. Miranda, E. Oldfield, and S. N. J. Moreno, "The farnesyl-diphosphate/geranylgeranyl-diphosphate synthase of *Toxoplasma gondii* is a bifunctional enzyme and a molecular target of bisphosphonates," *The Journal of Biological Chemistry*, vol. 282, no. 42, pp. 30804–30816, 2007.

[32] A. C. Oehlschlager and E. Czyzewska, "Rationally designed inhibitors of sterol biosynthesis," in *Emerging Targets in Antibacterial and Antifungal Chemotherapy*, J. Sutcliffe and N. H. Georgopapadakou, Eds., pp. 437–475, Chapman & Hall, New York, NY, USA, 1992.

[33] J. F. Thompson, D. E. Danley, S. Mazzalupo, P. M. Milos, M. E. Lira, and H. J. Harwood Jr., "Truncation of human squalene synthase yields active, crystallizable protein," *Archives of Biochemistry and Biophysics*, vol. 350, no. 2, pp. 283–290, 1998.

[34] F. R. Opperdoes and J.-P. Szikora, "In silico prediction of the glycosomal enzymes of *Leishmania major* and trypanosomes," *Molecular and Biochemical Parasitology*, vol. 147, no. 2, pp. 193–206, 2006.

[35] J. A. Urbina, J. L. Concepcion, S. Rangel, G. Visbal, and R. Lira, "Squalene synthase as a chemotherapeutic target in *Trypanosoma cruzi* and *Leishmania mexicana*," *Molecular and Biochemical Parasitology*, vol. 125, no. 1-2, pp. 35–45, 2002.

[36] J. A. Urbina, J. L. Concepcion, A. Caldera, et al., "In vitro and in vivo activities of E5700 and ER-119884, two novel orally active squalene synthase inhibitors, against *Trypanosoma cruzi*," *Antimicrobial Agents and Chemotherapy*, vol. 48, no. 7, pp. 2379–2387, 2004.

[37] J. C. F. Rodrigues, J. L. Concepcion, C. Rodrigues, A. Caldera, J. A. Urbina, and W. de Souza, "In vitro activities of ER-119884 and E5700, two potent squalene synthase inhibitors, against *Leishmania amazonensis*: antiproliferative, biochemical, and ultrastructural effects," *Antimicrobial Agents and Chemotherapy*, vol. 52, no. 11, pp. 4098–4114, 2008.

[38] K. Barrett-Bee and N. Ryder, "Biochemical aspects of ergosterol biosynthesis inhibition," in *Emerging Targets in Antibacterial and Antifungal Chemotherapy*, J. Sutcliffe and N. H. Georgopapadakou, Eds., pp. 410–436, Chapman & Hall, New York, NY, USA, 1992.

[39] K. Ishida, J. C. F. Rodrigues, M. D. Ribeiro, et al., "Growth inhibition and ultrastructural alterations induced by $\Delta^{24(25)}$-sterol methyltransferase inhibitors in *Candida spp*. isolates, including non-*albicans* organisms," *BMC Microbiology*, vol. 9, article 74, 2009.

[40] Y. Aoyama, Y. Yoshida, and R. Sato, "Yeast cytochrome P-450 catalyzing lanosterol 14α-demethylation. II. Lanosterol metabolism by purified P-450(14DM) and by intact microsomes," *The Journal of Biological Chemistry*, vol. 259, no. 3, pp. 1661–1666, 1984.

[41] N. S. Ryder, G. Seidl, and P. F. Troke, "Effect of the antimycotic drug naftifine on growth of and sterol biosynthesis in *Candida albicans*," *Antimicrobial Agents and Chemotherapy*, vol. 25, no. 4, pp. 483–487, 1984.

[42] J. A. Urbina, J. Vivas, G. Visbal, and L. M. Contreras, "Modification of the sterol composition of *Trypanosoma* (*Schizotrypanum*) *cruzi* epimastigotes by $\Delta^{24(25)}$-sterol methyl transferase inhibitors and their combinations with ketoconazole," *Molecular and Biochemical Parasitology*, vol. 73, no. 1-2, pp. 199–210, 1995.

[43] J. A. Urbina, J. Vivas, K. Lazardi, et al., "Antiproliferative effects of $\Delta^{24(25)}$ sterol methyl transferase inhibitors on *Trypanosoma* (*Schizotrypanum*) *cruzi*: in vitro and in vivo studies," *Chemotherapy*, vol. 42, no. 4, pp. 294–307, 1996.

[44] A. Liendo, G. Visbal, M. M. Piras, R. Piras, and J. A. Urbina, "Sterol composition and biosynthesis in *Trypanosoma cruzi* amastigotes," *Molecular and Biochemical Parasitology*, vol. 104, no. 1, pp. 81–91, 1999.

[45] K. Barrett-Bee, L. Newboult, and P. Pinder, "Biochemical changes associated with the antifungal action of the triazole ICI 153,066 on *Candida albicans* and *Trichophyton quinckeanum*," *FEMS Microbiology Letters*, vol. 79, no. 2-3, pp. 127–131, 1991.

[46] D. H. Beach, L. J. Goad, and G. G. Holz Jr., "Effects of antimycotic azoles on growth and sterol biosynthesis of *Leishmania* promastigotes," *Molecular and Biochemical Parasitology*, vol. 31, no. 2, pp. 149–162, 1988.

[47] C. Jiménez-Jiménez, J. Carrero-Lérida, M. Sealey-Cardona, L. M. Ruiz-Pérez, J. A. Urbina, and D. González-Pacanowska, "$\Delta^{24(25)}$-sterol methenyltransferase: intracellular localization and azasterol sensitivity in *Leishmania major* promastigotes overexpressing the enzyme," *Molecular and Biochemical Parasitology*, vol. 160, no. 1, pp. 52–59, 2008.

[48] S. A. Doggrell, "Is atorvastatin superior to other statins? Analysis of the clinical trials with atorvastatin having cardiovascular endpoints," *Reviews on Recent Clinical Trials*, vol. 1, no. 2, pp. 143–153, 2006.

[49] G. A. Rodan, "Mechanisms of action of bisphosphonates," *Annual Review of Pharmacology and Toxicology*, vol. 38, pp. 375–388, 1998.

[50] D. González-Pacanowska, B. Arison, C. M. Havel, and J. A. Watson, "Isopentenoid synthesis in isolated embryonic *Drosophila* cells. Farnesol catabolism and ω-oxidation," *The Journal of Biological Chemistry*, vol. 263, no. 3, pp. 1301–1306, 1988.

[51] G. R. Brown, D. S. Clarke, A. J. Foubister, et al., "Synthesis and activity of a novel series of 3-biarylquinuclidine squalene synthase inhibitors," *Journal of Medicinal Chemistry*, vol. 39, no. 15, pp. 2971–2979, 1996.

[52] F. McTaggart, G. R. Brown, R. G. Davidson, et al., "Inhibition of squalene synthase of rat liver by novel 3′ substituted quinuclidines," *Biochemical Pharmacology*, vol. 51, no. 11, pp. 1477–1487, 1996.

[53] V. Charlton-Menys and P. N. Durrington, "Squalene synthase inhibitors: clinical pharmacology and cholesterol-lowering potential," *Drugs*, vol. 67, no. 1, pp. 11–16, 2007.

[54] J. A. Urbina, G. Visbal, L. M. Contreras, G. McLaughlin, and R. Docampo, "Inhibitors of $\Delta^{24(25)}$ sterol methyltransferase block sterol synthesis and cell proliferation in *Pneumocystis carinii*," *Antimicrobial Agents and Chemotherapy*, vol. 41, no. 7, pp. 1428–1432, 1997.

[55] G. Visbal, A. Alvarez, B. Moreno, and G. San-Blas, "*S*-adenosyl-L-methionine inhibitors Δ^{24}-sterol methyltransferase and $\Delta^{24(28)}$-sterol methylreductase as possible agents against *Paracoccidioides brasiliensis*," *Antimicrobial Agents and Chemotherapy*, vol. 47, no. 9, pp. 2966–2970, 2003.

[56] J. A. Urbina, K. Lazardi, E. Marchan, et al., "Mevinolin (lovastatin) potentiates the antiproliferative effects of ketoconazole and terbinafine against *Trypanosoma* (*Schizotrypanum*) *cruzi*: in vitro and in vivo studies," *Antimicrobial Agents and Chemotherapy*, vol. 37, no. 3, pp. 580–591, 1993.

[57] R. Docampo and S. N. Moreno, "Bisphosphonates as chemotherapeutic agents against trypanosomatid and apicomplexan parasites," *Current Drug Targets—Infectious Disorders*, vol. 1, no. 1, pp. 51–61, 2001.

[58] R. Docampo and S. N. J. Moreno, "The acidocalcisome as a target for chemotherapeutic agents in protozoan parasites," *Current Pharmaceutical Design*, vol. 14, no. 9, pp. 882–888, 2008.

[59] M. B. Martin, J. S. Grimley, J. C. Lewis, et al., "Bisphosphonates inhibit the growth of *Trypanosoma brucei*, *Trypanosoma cruzi*, *Leishmania donovani*, *Toxoplasma gondii*, and *Plasmodium falciparum*: a potential route to chemotherapy," *Journal of Medicinal Chemistry*, vol. 44, no. 6, pp. 909–916, 2001.

[60] J. M. Sanders, Y. Song, J. M. W. Chan, et al., "Pyridinium-1-yl bisphosphonates are potent inhibitors of farnesyl diphosphate synthase and bone resorption," *Journal of Medicinal Chemistry*, vol. 48, no. 8, pp. 2957–2963, 2005.

[61] S. H. Szajnman, G. E. García Liñares, Z.-H. Li, et al., "Synthesis and biological evaluation of 2-alkylaminoethyl-1,1-bisphosphonic acids against *Trypanosoma cruzi* and *Toxoplasma gondii* targeting farnesyl diphosphate synthase," *Bioorganic and Medicinal Chemistry*, vol. 16, no. 6, pp. 3283–3290, 2008.

[62] L. R. Garzoni, A. Caldera, M. D. N. L. Meirelles, et al., "Selective in vitro effects of the farnesyl pyrophosphate synthase inhibitor risedronate on *Trypanosoma cruzi*," *International Journal of Antimicrobial Agents*, vol. 23, no. 3, pp. 273–285, 2004.

[63] J. D. Bergstrom, C. Dufresne, G. F. Bills, M. Nallin-Omstead, and K. Byrne, "Discovery, biosynthesis, and mechanism of action of the zaragozic acids: potent inhibitors of squalene synthase," *Annual Review of Microbiology*, vol. 49, pp. 607–639, 1995.

[64] M. V. Braga, J. A. Urbina, and W. de Souza, "Effects of squalene synthase inhibitors on the growth and ultrastructure of *Trypanosoma cruzi*," *International Journal of Antimicrobial Agents*, vol. 24, no. 1, pp. 72–78, 2004.

[65] S. O. Lorente, R. Gómez, C. Jiménez-Jiménez, et al., "Biphenylquinuclidines as inhibitors of squalene synthase and growth of parasitic protozoa," *Bioorganic and Medicinal Chemistry*, vol. 13, no. 10, pp. 3519–3529, 2005.

[66] J. C. F. Rodrigues, J. A. Urbina, and W. de Souza, "Antiproliferative and ultrastructural effects of BPQ-OH, a specific inhibitor of squalene synthase, on *Leishmania amazonensis*," *Experimental Parasitology*, vol. 111, no. 4, pp. 230–238, 2005.

[67] S. B. Cammerer, C. Jiménez-Jiménez, S. Jones, et al., "Quinuclidine derivatives as potential antiparasitics," *Antimicrobial Agents and Chemotherapy*, vol. 51, no. 11, pp. 4049–4061, 2007.

[68] M. Sealey-Cardona, S. Cammerer, S. Jones, et al., "Kinetic characterization of squalene synthase from *Trypanosoma cruzi*: selective inhibition by quinuclidine derivatives," *Antimicrobial Agents and Chemotherapy*, vol. 51, no. 6, pp. 2123–2129, 2007.

[69] D. H. Beach, L. J. Goad, and G. G. Holz Jr., "Effects of ketoconazole on sterol biosynthesis by *Trypanosoma cruzi* epimastigotes," *Biochemical and Biophysical Research Communications*, vol. 136, no. 3, pp. 851–856, 1986.

[70] M. A. Vannier-Santos, J. A. Urbina, A. Martiny, A. Neves, and W. de Souza, "Alterations induced by the antifungal compounds ketoconazole and terbinafine in *Leishmania*," *The Journal of Eukaryotic Microbiology*, vol. 42, no. 4, pp. 337–346, 1995.

[71] J. A. Urbina, G. Payares, J. Molina, et al., "Cure of short- and long-term experimental Chagas' disease using D0870," *Science*, vol. 273, no. 5277, pp. 969–971, 1996.

[72] J. A. Urbina, G. Payares, L. M. Contreras, et al., "Antiproliferative effects and mechanism of action of SCH 56592 against *Trypanosoma* (*Schizotrypanum*) *cruzi*: in vitro and in vivo studies," *Antimicrobial Agents and Chemotherapy*, vol. 42, no. 7, pp. 1771–1777, 1998.

[73] G. Benaim, J. M. Sanders, Y. Garcia-Marchán, et al., "Amiodarone has intrinsic anti-*Trypanosoma cruzi* activity and acts synergistically with posaconazole," *Journal of Medicinal Chemistry*, vol. 49, no. 3, pp. 892–899, 2006.

[74] K. Lazardi, J. A. Urbina, and W. de Souza, "Ultrastructural alterations induced by two ergosterol biosynthesis inhibitors, ketoconazole and terbinafine, on epimastigotes and amastigotes of *Trypanosoma* (*Schizotrypanum*) *cruzi*," *Antimicrobial Agents and Chemotherapy*, vol. 34, no. 11, pp. 2097–2105, 1990.

[75] K. Lazardi, J. A. Urbina, and W. de Souza, "Ultrastructural alterations induced by ICI 195,739, a bis-triazole derivative with strong antiproliferative action against *Trypanosoma* (*Schizotrypanum*) *cruzi*," *Antimicrobial Agents and Chemotherapy*, vol. 35, no. 4, pp. 736–740, 1991.

[76] J. Vivas, J. A. Urbina, and W. de Souza, "Ultrastructural alterations in *Trypanosoma* (*Schizotrypanum*) *cruzi* induced by $\Delta^{24(25)}$ sterol methyl transferase inhibitors and their combinations with ketoconazole," *International Journal of Antimicrobial Agents*, vol. 7, no. 4, pp. 235–240, 1996.

[77] X. Serrano-Martín, Y. García-Marchan, A. Fernandez, et al., "Amiodarone destabilizes intracellular Ca^{2+} homeostasis and biosynthesis of sterols in *Leishmania mexicana*," *Antimicrobial Agents and Chemotherapy*, vol. 53, no. 4, pp. 1403–1410, 2009.

[78] F. Magaraci, C. J. Jiménez, C. Rodrigues, et al., "Azasterols as inhibitors of sterol 24-methyltransferase in *Leishmania* species and *Trypanosoma cruzi*," *Journal of Medicinal Chemistry*, vol. 46, no. 22, pp. 4714–4727, 2003.

[79] J. C. F. Rodrigues, C. F. Bernardes, G. Visbal, J. A. Urbina, A. E. Vercesi, and W. de Souza, "Sterol methenyl transferase inhibitors alter the ultrastructure and function of the *Leishmania amazonensis* mitochondrion leading to potent growth inhibition," *Protist*, vol. 158, no. 4, pp. 447–456, 2007.

[80] S. O. Lorente, J. C. F. Rodrigues, C. J. Jiménez, et al., "Novel azasterols as potential agents for treatment of leishmaniasis and trypanosomiasis," *Antimicrobial Agents and Chemotherapy*, vol. 48, no. 8, pp. 2937–2950, 2004.

[81] A. C. Granthon, M. V. Braga, J. C. F. Rodrigues, et al., "Alterations on the growth and ultrastructure of *Leishmania chagasi* induced by squalene synthase inhibitors," *Veterinary Parasitology*, vol. 146, no. 1-2, pp. 25–34, 2007.

[82] W. de Souza, M. Attias, and J. C. F. Rodrigues, "Particularities of mitochondrial structure in parasitic protozoa (Apicomplexa and Kinetoplastida)," submitted to *The International Journal of Biochemistry & Cell Biology*.

[83] I. V. Palmié-Peixoto, M. R. Rocha, J. A. Urbina, W. de Souza, M. Einicker-Lamas, and M. C. M. Motta, "Effects of sterol biosynthesis inhibitors on endosymbiont-bearing try panosomatids," *FEMS Microbiology Letters*, vol. 255, no. 1, pp. 33–42, 2006.

[84] C. O. Rodrigues, R. Catisti, S. A. Uyemura, et al., "The sterol composition of *Trypanosoma cruzi* changes after growth in different culture media and results in different sensitivity to digitonin-permeabilization," *Journal of Eukaryotic Microbiology*, vol. 48, no. 5, pp. 588–594, 2001.

[85] W. de Souza and D. P. Cavalcanti, "DNA containing organelles in pathogenic protozoa," *Trends in Cell & Molecular Biology*, vol. 2, pp. 89–104, 2008.

[86] J. F. R. Kerr, "History of the events leading to the formulation of the apoptosis concept," *Toxicology*, vol. 181-182, pp. 471–474, 2002.

[87] J. C. F. Rodrigues and W. de Souza, "Ultrastructural alterations in organelles of parasitic protozoa induced by different classes of metabolic inhibitos," *Current Pharmaceutical Design*, vol. 14, no. 9, pp. 925–938, 2008.

[88] R. F. S. Menna-Barreto, K. Salomão, A. P. Dantas, et al., "Different cell death pathways induced by drugs in *Trypanosoma cruzi*: an ultrastructural study," *Micron*, vol. 40, no. 2, pp. 157–168, 2009.

[89] R. Docampo, W. de Souza, K. Miranda, P. Rohloff, and S. N. J. Moreno, "Acidocalcisomes—conserved from bacteria to man," *Nature Reviews Microbiology*, vol. 3, no. 3, pp. 251–261, 2005.

[90] J. A. Urbina, S. Pekerar, H.-B. Le, J. Patterson, B. Montez, and E. Oldfield, "Molecular order and dynamics of phosphatidylcholine bilayer membranes in the presence of cholesterol, ergosterol and lanosterol: a comparative study using 2H-,

13C- and 31P-NMR spectroscopy," *Biochimica et Biophysica Acta*, vol. 1238, no. 2, pp. 163–176, 1995.

[91] K. Zhang, M. Showalter, J. Revollo, F.-F. Hsu, J. Turk, and S. M. Beverley, "Sphingolipids are essential for differentiation but not growth in *Leishmania*," *The EMBO Journal*, vol. 22, no. 22, pp. 6016–6026, 2003.

[92] K. Zhang, F.-F. Hsu, D. A. Scott, R. Docampo, J. Turk, and S. M. Beverley, "*Leishmania* salvage and remodelling of host sphingolipids in amastigote survival and acidocalcisome biogenesis," *Molecular Microbiology*, vol. 55, no. 5, pp. 1566–1578, 2005.

[93] M. L. Salto, L. E. Bertello, M. Vieira, R. Docampo, S. N. J. Moreno, and R. M. de Lederkremer, "Formation and remodeling of inositolphosphoceramide during differentiation of *Trypanosoma cruzi* from trypomastigote to amastigote," *Eukaryotic Cell*, vol. 2, no. 4, pp. 756–768, 2003.

[94] A. P. Dantas, H. S. Barbosa, and S. L. de Castro, "Biological and ultrastructural effects of the anti-microtubule agent taxol against *Trypanosoma cruzi*," *Journal of Submicroscopic Cytology and Pathology*, vol. 35, no. 3, pp. 287–294, 2003.

[95] K. Gull, "The cytoskeleton of trypanosomatid parasites," *Annual Review of Microbiology*, vol. 53, pp. 629–655, 1999.

[96] C. Dahl, H.-P. Biemann, and J. Dahl, "A protein kinase antigenically related to $pp60^{v\text{-}src}$ possibly involved in yeast cell cycle control: positive in vivo regulation by sterol," *Proceedings of the National Academy of Sciences of the United States of America*, vol. 84, no. 12, pp. 4012–4016, 1987.

[97] R. F. Gaber, D. M. Copple, B. K. Kennedy, M. Vidal, and M. Bard, "The yeast gene ERG6 is required for normal membrane function but is not essential for biosynthesis of the cell-cycle-sparking sterol," *Molecular and Cellular Biology*, vol. 9, no. 8, pp. 3447–3456, 1989.

[98] L. J. Goad, G. G. Holz Jr., and D. H. Beach, "Effect of the allylamine antifungal drug SF 86-327 on the growth and sterol synthesis of *Leishmania mexicana mexicana* promastigotes," *Biochemical Pharmacology*, vol. 34, no. 20, pp. 3785–3788, 1985.

[99] J. A. Urbina, K. Lazardi, T. Aguirre, M. M. Piras, and R. Piras, "Antiproliferative synergism of the allylamine SF 86-327 and ketoconazole on epimastigotes and amastigotes of *Trypanosoma* (*Schizotrypanum*) *cruzi*," *Antimicrobial Agents and Chemotherapy*, vol. 32, no. 8, pp. 1237–1242, 1988.

[100] L. J. Goad, G. G. Holz Jr., and D. H. Beach, "Sterols of ketoconazole-inhibited *Leishmania mexicana mexicana* promastigotes," *Molecular and Biochemical Parasitology*, vol. 15, no. 3, pp. 257–279, 1985.

[101] L. J. Goad, R. L. Berens, J. J. Marr, D. H. Beach, and G. G. Holz Jr., "The activity of ketoconazole and other azoles against *Trypanosoma cruzi*: biochemistry and chemotherapeutic action in vitro," *Molecular and Biochemical Parasitology*, vol. 32, no. 2-3, pp. 179–190, 1989.

[102] P. A. Haughan, M. L. Chance, and L. J. Goad, "Effects of an azasterol inhibitor of sterol 24-transmethylation an sterol biosynthesis and growth of *Leishmania donovani* promastigotes," *Biochemical Journal*, vol. 308, no. 1, pp. 31–38, 1995.

[103] E. I. Mercer, "Inhibitors of sterol biosynthesis and their applications," *Progress in Lipid Research*, vol. 32, no. 4, pp. 357–416, 1993.

[104] A. Rahur, M. Taton, and P. Benveniste, "Inhibition of sterol biosynthesis in higher plants by analogues of high energy carbocationic intermediates," in *Biochemistry of Cell Walls and Membranes in Fungi*, P. J. Kuhn, A. P. J. Trinci, M. J. Jung, M. W. Goosey, and L. G. Copping, Eds., pp. 206–221, Springer, Berlin, Germany, 1990.

[105] N. Rodriguez, B. N. Bailey, M. B. Martin, E. Oldfield, J. A. Urbina, and R. Docampo, "Radical cure of experimental cutaneous leishmaniasis by the bisphosphonate pamidronate," *Journal of Infectious Diseases*, vol. 186, no. 1, pp. 138–140, 2002.

[106] V. Yardley, A. A. Khan, M. B. Martin, et al., "In vivo activities of farnesyl pyrophosphate synthase inhibitors against *Leishmania donovani* and *Toxoplasma gondii*," *Antimicrobial Agents and Chemotherapy*, vol. 46, no. 3, pp. 929–931, 2002.

[107] L. R. Garzoni, M. C. Waghabi, M. M. Baptista, et al., "Antiparasitic activity of risedronate in a murine model of acute Chagas' disease," *International Journal of Antimicrobial Agents*, vol. 23, no. 3, pp. 286–290, 2004.

[108] J. Molina, Z. Brener, A. J. Romanha, and J. A. Urbina, "In vivo activity of the bis-triazole D0870 against drug-susceptible and drug-resistant strains of the protozoan parasite *Trypanosoma cruzi*," *Journal of Antimicrobial Chemotherapy*, vol. 46, no. 1, pp. 137–140, 2000.

[109] J. Molina, O. Martins-Filho, Z. Brener, A. J. Romanha, D. Loebenberg, and J. A. Urbina, "Activities of the triazole derivative SCH 56592 (Posaconazole) against drug-resistant strains of the protozoan parasite *Trypanosoma* (*Schizotrypanum*) *cruzi* in immunocompetent and immunosuppressed murine hosts," *Antimicrobial Agents and Chemotherapy*, vol. 44, no. 1, pp. 150–155, 2000.

[110] H. M. Al-Abdely, J. R. Graybill, D. Loebenberg, and P. C. Melby, "Efficacy of the triazole SCH 56592 against *Leishmania amazonensis* and *Leishmania donovani* in experimental murine cutaneous and visceral leishmaniases," *Antimicrobial Agents and Chemotherapy*, vol. 43, no. 12, pp. 2910–2914, 1999.

Hindawi Publishing Corporation
Interdisciplinary Perspectives on Infectious Diseases
Volume 2009, Article ID 617954, 8 pages
doi:10.1155/2009/617954

Review Article

The Impact of HIV and Malaria Coinfection: What Is Known and Suggested Venues for Further Study

Sarah Hochman[1] and Kami Kim[2]

[1] *Department of Medicine, Division of Infectious Diseases, Montefiore Medical Center, Albert Einstein College of Medicine, Ullmann 1205, 1300 Morris Park Avenue, Bronx, NY 10461, USA*
[2] *Department of Microbiology and Immunology, Albert Einstein College of Medicine, Ullmann 1225, 1300 Morris Park Avenue, Bronx, NY 10461, USA*

Correspondence should be addressed to Sarah Hochman, shochman@montefiore.org

Received 17 March 2009; Accepted 1 June 2009

Recommended by Herbert B. Tanowitz

HIV and malaria have similar global distributions. Annually, 500 million are infected and 1 million die because of malaria. 33 million have HIV and 2 million die from it each year. Minor effects of one infection on the disease course or outcome for the other would significantly impact public health because of the sheer number of people at risk for coinfection. While early population-based studies showed no difference in outcomes between HIV-positive and HIV-negative individuals with malaria, more recent work suggests that those with HIV have more frequent episodes of symptomatic malaria and that malaria increases HIV plasma viral load and decreases CD4+ T cells. HIV and malaria each interact with the host's immune system, resulting in a complex activation of immune cells, and subsequent dysregulated production of cytokines and antibodies. Further investigation of these interactions is needed to better define effects of coinfection.

1. Introduction

HIV and malaria have similar global distributions, with the majority of those affected living in sub-Saharan Africa, the Indian subcontinent, and Southeast Asia. Given the overlap of their geographic distribution and resultant rates of coinfection, interactions between the two diseases pose major public health problems. Together they accounted for over 3 million deaths in 2007 [1, 2], and millions more are adversely affected each year. Malaria and HIV/AIDS are both diseases of poverty and contribute to poverty by affecting young people who would otherwise enter the workforce and contribute to the local economy.

Malaria is caused by the protozoan parasite *Plasmodium* and is transmitted by *Anopheles* mosquitoes. It is endemic in most tropical and subtropical regions of the world. Of the four *Plasmodium* species that infect humans, *P. falciparum* is the most virulent and is responsible for the majority of morbidity and mortality due to malaria. Worldwide, 1.2 billion people are at risk for malaria infection, resulting in 500 million infections and more than 1 million deaths each year. The majority of these deaths occur in young children in sub-Saharan Africa, where one in every five childhood deaths is due to malaria [1]. Aside from young children, pregnant women are also heavily affected [3], with resultant effects on maternal health and birth outcomes. While recent data indicates the number of malaria infections per year is decreasing (247 million malaria cases in 2006) the number of deaths attributable to malaria remains unchanged [4].

Areas of the world with high rates of malaria also carry a heavy burden of HIV. There are 33 million people living with HIV worldwide, with 22.5 million in sub-Saharan Africa alone. This results in an estimated overall prevalence of 5% in sub-Saharan Africa, with some countries reporting prevalence rates of greater than 25%. While new HIV infections in adults and children have decreased since 2005, there were an estimated 2.5 million children living with HIV in 2007, nearly 90% of whom are in sub-Saharan Africa. It is estimated that 2.1 million deaths in 2007 were due to HIV, of which 1.6 million occurred in sub-Saharan Africa, making HIV/AIDS the number one cause of mortality in that region [2].

2. Physiologic Impact of Malaria

Falciparum malaria has a spectrum of clinical presentations, ranging from asymptomatic parasitemia in patients with immunity to severe anemia, cerebral malaria, multiorgan failure, or death.

Anemia is most frequently seen in young children and pregnant women [5] and can be seen in acute infection as well as with chronic repeated malarial infections. The underlying causes of severe malarial anemia are likely multifactorial. Extravascular and/or intravascular hemolysis of both infected and uninfected erythrocytes plays a role: changes in surface proteins on infected erythrocytes lead to increased clearance of these cells [6], while noninfected red blood cells are destroyed in the spleen during acute infection [7]. This leads to hemolysis and depletion of iron stores. Bone marrow suppression also plays an important role in the pathogenesis of malarial anemia. The normal response to hemolytic anemia is enhanced secretion of erythropoietin, leading to stimulation of erythropoiesis, but this mechanism seems to be defective in patients with malaria. During acute infection, abnormalities are seen in erythroid progenitors [8], while dyserythropoiesis (abnormal production of red cells) is observed in chronic infection [9].

Cerebral malaria and other end-organ damage is mediated through interactions between infected red blood cells and host receptors on the blood vessel wall, resulting in adherence and sequestration of infected red blood cells in the postcapillary venules, obstruction of blood flow, and subsequent tissue damage [10]. Patients who survive cerebral malaria may suffer from long-term mental and psychological deficits [11]. Renal complications are common and may present as acute renal failure due to the effects of sequestrated infected red blood cells or with nephrotic syndrome, due to deposition of antigen-antibody complexes within glomeruli. *P. falciparum* can also result in severe anemia, low birth weight, and maternal death during pregnancy [3, 12].

3. Physiologic Impact of HIV

HIV infects and depletes CD4+ T lymphocytes, putting patients at risk for opportunistic infection and malignancy, the major causes of death due to HIV and AIDS. However, it also has effects on the systemic inflammatory response, causing activation and/or apoptosis in a variety of immune cells as well as elevated levels of proinflammatory cytokines and chemokines in plasma and lymph nodes. This immune activation, rather than being a reflection of antiviral immunity, is associated with HIV-1 disease progression [13]. It is also a potential means by which HIV affects disease course and outcome in other infections, such as malaria.

4. Impact of HIV and Malaria Coinfection

While no population-based studies are available to determine the number of patients affected by coinfection and the impact of coinfection on a population, a mathematical model applied to previously published data was used to estimate the impact of HIV-1 on malaria in sub-Saharan Africa. It estimated that an additional 3 million cases of malaria and 65 000 additional malaria-related deaths annually are due to the impact of HIV [14]. Rates were highest in countries with high HIV prevalence and unstable malaria transmission.

Cohort studies have shown that malaria infection causes an increase in plasma HIV viral load, even during asymptomatic parasitemia. HIV viral load returned to baseline eight weeks after acute malaria infection [15]. It has also been demonstrated that CD4+ T lymphocytes decline temporarily during clinical malaria episodes in HIV-infected and HIV-uninfected patients [16] and that repeated malaria infections are associated with a more rapid decline in CD4+ T lymphocytes over time [17], suggesting that malaria may lead to faster disease progression from HIV to AIDS.

While early studies found no association between HIV and malaria disease severity in either adults or children [18, 19] more recent research has shown that HIV infection predisposes to more frequent episodes of symptomatic malaria [20] and more episodes of severe or complicated malaria including death in both children and adults [21–24], see Table 1. An inverse relationship was found between incidence of severe malaria and CD4+ T lymphocyte counts. Generally, patients with HIV respond to standard malaria regimens. While infection with HIV has been associated with an increased rate of malaria treatment failure, this was due to re-infection with new malaria strains, rather than recrudescence of prior infection [20].

In HIV-uninfected women, risk for symptomatic or placental malaria decreases with each subsequent pregnancy. In HIV-infected women this gravidity-specific pattern is altered, such that multigravidae women carry the same risk of disease as primigravidae women [25]. Pregnancy-associated malaria is associated with increased risk of maternal anemia, intrauterine growth restriction, and delivery of preterm, and low-birth-weight infants [26]. Given the lack of gravidity-specific protection against malaria seen with HIV infection in pregnant women, HIV puts more pregnancies at risk for complications associated with malaria.

In a cohort study in Kenya, HIV-coinfected women had higher placental parasite densities and higher rates of antenatal malaria transmission than did HIV-uninfected women [26]. Maternal antibody to variant surface antigens (VSAs) on malaria-infected erythrocytes plays an important role in pregnancy-related immunity to malaria. Sera from HIV-infected mothers when analyzed by flow cytometry contained fewer antibodies to VSAs in both placental and pediatric isolates of malaria than did sera from HIV-uninfected mothers [27]. Additionally, assays using plasma or purified IgG from HIV-infected or HIV-uninfected primi- or multigravidae women found that HIV-uninfected multigravidae women had high levels of opsonic phagocytosis of infected erythrocytes, which was due to IgG1 and IgG3 specific for VSA. Opsonic phagocytosis was not seen with plasma or purified IgG from HIV-uninfected primigravidae women or HIV-uninfected men. HIV-infected multigravidae women had significantly lower plasma opsonizing activity than did their HIV-uninfected counterparts [28].

Table 1: Effects of coinfection with HIV and malaria.

Type of Interaction	Interactions		
	Pregnant women	Children	Adult men and nonpregnant women
Effect of HIV on malaria			
• ↑ Risk of infection	+	?	+
• ↑ Parasite density	+	?	+
Effect of malaria on HIV			
• ↑ Viral load	+	?	+
• ↑ Transmission	?	+	?
	(Data on vertical transmission to the fetus is contradictory)	(Through transfusion of unscreened blood for anemia)	(No definitive data, although ↑ viral load has previously been shown to correlate with ↑ sexual transmission)
Effects of dual infection			
• ↑ Severity of illness	+	+	+
• ↑ Frequency and severity of anemia	+	+	+
• ↑ Frequency of low birth weight	+	N/A	N/A

Cohort studies in Cameroon show that malaria infection during pregnancy may increase the risk of mother-to-child transmission of HIV [29, 30]. One potential mechanism for this was evaluated in vitro, where binding of recombinant *P. falciparum* adhesin to chondroitin sulfate A on human placental cells increased HIV-1 replication in those cells, possibly via TNF-alpha stimulation [31].

5. Immune Response to Malaria

Proinflammatory (Th1) cytokines such as TNF-alpha are thought to play an important role in malaria pathogenesis and in cerebral malaria in particular, as they increase surface expression of adhesion molecules on endothelial cells, promoting parasite attachment. Activated CD4+ T lymphocytes stimulate macrophages to produce TNF-alpha, which leads to cerebral malaria in mouse models [32].

In humans, clusters of cytokines may help discriminate between mild, severe, and cerebral malaria. In an adult population in a malaria-endemic region of India, high levels of IL-12, IL-5, and IL-6 discriminated severe forms of malaria from mild malaria. Levels of IL-1beta, IL-12, and IFN-gamma helped to discriminate cerebral malaria from severe malaria, with high IL-1beta levels being associated with cerebral malaria, and high IL-12 and IFN-gamma levels being associated with severe malaria [33]. In a pediatric population in Mali, high levels of IL-6 and IL-10 helped to discriminate both severe malaria from mild malaria and cerebral malaria from severe malaria, whereas IL-1beta and IL-12 did not differ significantly among groups [34]. While there are many studies that associate patterns of cytokines to disease, results may be different depending on the cohort population. Thus, there is an association between elevations in certain cytokines and disease outcomes, but it is hard to generalize these associations to different patient populations.

Adaptive immunity to malaria is thought to confer protection against febrile parasitemia but does not prevent parasitemia. This is due in part to the development of antibodies against proteins on the infected erythrocyte surface, notably VSA [35].

The effect of malaria on dendritic cells, key players in both the early stages of adaptive immunity and innate immunity, is not clear. Urban et al. found that *P. falciparum*-infected erythrocytes adhere to human dendritic cells, inhibit their maturation, and subsequently reduce their capacity to stimulate T cells [36]. However, mouse studies using *P. chabaudi* found that infected erythrocytes induce maturation of dendritic cells, stimulate IL-12 and IFN-gamma production, and cause CD4+ T lymphocyte proliferation [37]. While these two studies reported conflicting findings, one unifying explanation for both was seen in another mouse model, using *P. yoelii*. Overstimulation of dendritic cells by toll-like receptors makes them refractory to further activation in *P. yoelii*-infected mice [38]. As malaria infection progresses and parasitemia increases exponentially, dendritic cells will develop toll-like receptor resistance. This would result in dendritic cell dysfunction in later stages of infection, as was seen by Urban et al., while the findings of Ing et al. may be more consistent with the early stages of malaria.

6. Immune Response to HIV

Proinflammatory cytokines play an important role both in control and pathogenesis of HIV infection. During infection, viral particles are taken up by antigen presenting cells (APCs), which are then recognized by CD4+ T lymphocytes, causing activation and release of IL-2 and IFN-gamma. These proinflammatory cytokines in turn stimulate CD8+ T lymphocytes, which control viremia. It is not known if this inflammatory response seen in HIV has an effect on the adherence and sequestration seen in malaria. However, HIV upregulates adhesion molecules on endothelial cells, which may compound the adherence and sequestration seen in malaria [39].

HIV also dysregulates pathways of cytokine expression, such that production of the proinflammatory cytokines IL-12 and IFN-gamma is decreased and expression of the anti-inflammatory cytokine IL-10 is increased [40]. As HIV progresses clinically to AIDS there are effects on innate immunity, with progressive loss of T lymphocyte responses to common recall antigens [41]. Increased IL-10 has been shown to play a role in this impaired innate immune response in AIDS patients [42].

The impaired innate immune response in patients with AIDS may in part account for the increased rates of symptomatic malaria seen in cohort studies. However, the decreased production of IL-12 and IFN-gamma seen in HIV is confounding, as high levels of these proinflammatory cytokines are associated with severe malaria in clinical studies [33], and previously mentioned cohort studies have found higher rates of severe or symptomatic malaria in subjects with HIV.

Increased expression of IL-10 also appears to play a role in loss of adaptive immunity. IL-10 impairs T helper type 1 (Th1) responses [42]. Dendritic cells In HIV/AIDS are functionally impaired, producing less IL-12 and more IL-10, disrupting the IL-12/IFN-gamma signaling pathway and contributing to problems with adaptive immunity [40]. It is not clear if this impairment is due to direct HIV infection of dendritic cells, or that indirect effects of chronic antigenic stimulation or exposure to virally induced proteins cause dendritic cell dysfunction. Given the important role of dendritic cells in adaptive immunity to malaria, the effects of HIV on dendritic cell dysfunction may also contribute to the higher frequency of symptomatic parasitemia seen in cohort studies.

7. Effects of Malaria on the Endothelium and Blood-Brain Barrier

Cerebral malaria is a major cause of death due to *P. falciparum* in children under the age of five. Characterized by coma and/or seizures, it is associated with sequestration of parasitized red blood cells in the brain microvasculature. Occasionally brain edema and elevated intracranial pressure are seen.

Postmortem samples from children who died from cerebral malaria show activation of endothelial cells (with upregulation of ICAM-1) and macrophages (with increased macrophage scavenger receptor and sialoadhesin), and disruption of endothelial intercellular junctions (ZO-1, occludin, vinculin) in vessels containing sequestered parasitized red blood cells. No leakage of plasma proteins (fibrinogen, C5b-9, IgG) into brain parenchyma was seen, suggesting that the blood-brain barrier remains intact. However, there were elevations in cerebrospinal fluid albumin taken prior to death, which may indicate blood-brain barrier permeability [43].

In vitro studies have backed up some of these findings. Gillrie et al. showed that parasite sonicates but not intact malaria-infected red blood cells disrupt the endothelial (dermal and pulmonary, not brain) barrier, revealed by discontinuous immunofluorescent staining of endothelial junction proteins, formation of interendothelial gaps in monolayers, and loss in total protein content of claudin 5 and redistribution of ZO-1 [44].

Additionally it appears that severity of malaria infection is associated with differential expression of tight junction proteins. Quantitative PCR of human umbilical vascular endothelial cells (HUVECs) cultured with *P. falciparum* samples from patients with uncomplicated malaria showed increased mRNA levels of occludin, vinculin, and ZO-1. Those cultured with samples from severe malaria had no change in mRNA levels, and HUVECs cultured with *P. falciparum* from patients with cerebral malaria had decreased mRNA levels of occludin, vinculin, and ZO-1 [45]. This data suggests that infected erythrocytes can alter the expression of tight junction proteins in endothelial cells at the site of sequestration, influencing disease severity.

Not only are endothelial junction proteins affected, but also endothelial cells themselves seem to be influenced by infected erythrocytes, producing inflammatory mediators in response to malaria infection. Endothelial cells produce tissue factor when cultured with *P. falciparum*, and brain endothelial cells from patients dying of cerebral malaria and from those with malaria who died of other causes also showed increased levels of tissue factor [46]. Tissue factor plays a role in coagulation via thrombin formation, and plays a role in inflammation, as it is upregulated by proinflammatory cytokines such as TNF-alpha and also induces expression of such cytokines [47].

Endothelial cells also upregulate adhesion molecules in the setting of *falciparum* malaria. In *P. falciparum* isolates from patients with complicated malaria, binding of infected red blood cells to human lung microvascular endothelial cells was observed and was primarily mediated through ICAM-1 and chondroitin sulfate (CSA) [48]. Mouse models of cerebral malaria have supported the role of ICAM-1. ICAM-1-deficient C57BL/6 mice infected with *P. berghei* ANKA were protected from mortality compared with C57BL/6 controls [49]. Additionally, lack of TNF receptor 2 conferred resistance to cerebral malaria in mice, thought to be due to blocking the upregulatory effects of TNF on ICAM-1 expression in brain microvascular endothelial cells [50].

Another adhesion molecule that is likely involved in cerebral malaria pathogenesis is CD36, a receptor with a wide tissue distribution that is also found on endothelial cells. Monoclonal antibodies to CD36 and ICAM-1 partially inhibited the binding of *P. falciparum*-infected red blood cells to human brain endothelium, suggesting that both are important for cytoadherence [51]. The rodent malaria strain *P. chabaudi* has been used to study malaria sequestration in mice, and *P. chabaudi* AS-infected red blood cells adhered to purified CD36 in vitro [52]. This is of particular interest when considering the role of HIV coinfection in malarial sequestration and effects on the blood-brain barrier, as CD36 expression on circulating monocytes is significantly higher in HIV-1 infected patients compared with healthy controls [53].

8. Effects of HIV on the Endothelium and Blood-Brain Barrier

Unlike malaria, HIV is known to invade and infect the brain parenchyma, causing HIV-associated encephalitis and/or HIV-associated dementia. HIV may infect astrocytes at low levels, and it can activate endothelial cells, but it does not infect endothelial cells. HIV is thought to enter brain parenchyma through the regulated transmigration of HIV-infected mononuclear cells across the blood-brain barrier, mediated by surface receptors on endothelial cells such as ICAM-1. Once across the barrier, HIV-infected cells recruit microglia and astrocytes, allowing for subsequent infection of these cells and spread of HIV within the CNS.

As HIV replicates within the CNS, it produces inflammatory mediators, including the chemokine CCL2/MCP-1 [54]. This chemokine has been shown to enhance blood-brain barrier permeability, with increased transmigration of HIV-infected monocytes and a loss of tight junction proteins [55]. In addition to CCL2/MCP-1, cytokines including TNF-alpha, IFN-gamma, IL-1beta, and IL-6 are increased in brain tissue and CSF of people with NeuroAIDS [54].

9. Drug Effects

Aspartic proteases play key roles in HIV and are thus important therapeutic drug targets. Aspartic proteases are also important in malaria parasites (as plasmepsins), and antiretroviral protease inhibitors seem to have both direct effects on *Plasmodium* and indirect effects related to cytoadherence and phagocytosis.

The antiretroviral protease inhibitors saquinavir, ritonavir, indinavir, nelfinavir, amprenavir, lopinavir, and atazanavir directly inhibit erythrocytic stages of *P. falciparum* grown in vitro at concentrations achieved in vivo [56, 57], and mice infected with *P. chabaudi* AS had a delay in patency and attenuation of parasitemia when given oral ritonanvir/saquinavir or ritonavir/lopinavir [58]. Some antiretrovirals also seem to exert an effect on the pre-erythrocytic stages of malaria. Using *P. berghei*, a rodent strain of malaria, saquinavir and lopinavir inhibited development of extra-erythrocytic liver stages in vitro. In vivo mouse studies using the rodent strain *P. yoelii* showed a reduction in liver parasite burden when lopinavir/ritonavir was administered [59].

The antiretroviral protease inhibitors ritonavir and saquinavir affect CD36-mediated cytoadherence, thought to play a role in cerebral malaria and other end-organ damage in severe malaria. The drugs decrease CD36 surface concentrations on C32 epithelial cells in culture, which was associated with a decrease in cytoadherence of parasitized erythrocytes [60]. No effect on ICAM-1 expression on cells was seen. In addition, these protease inhibitors affect nonopsonic phagocytosis of parasitized erythrocytes. Human macrophages exposed to ritonavir or saquinavir also had reduced surface values of CD36, with an associated decrease in nonopsonic phagocytosis. The NNRTI nevirapine had no effect on CD36 concentrations on either C32 cells or macrophages and did not affect cytoadherence or phagocytosis.

The antimalarial drug chloroquine has effects on HIV, inhibiting the production of infectious viral particles by impairing virus glycosylation. Chloroquine also has synergistic effects on HIV suppression with the protease inhibitors indinavir, ritonavir, and saquinavir at concentrations achieved with prophylaxis dosing [61]. In vitro studies have also shown a synergistic effect on malaria growth between the protease inhibitors ritonavir and saquinavir and both chloroquine and mefloquine [62].

An additional drug-related interaction between malaria and HIV involves the use of trimethoprim-sulfamethoxazole prophylaxis in HIV-infected patients. In rural Uganda, HIV-infected participants given trimethoprim-sulfamethoxazole had a 76% decrease in rates of malaria compared with when they were not receiving trimethoprim-sulfamethoxazole, and participants who received antiretroviral therapy plus trimethoprim-sulfamethoxazole had a 92% decrease in malaria rates [63]. It is important to note that the antiretroviral regimen used did not include a protease inhibitor.

10. Conclusions

Malaria and HIV affect millions of people across overlapping geographic distributions, and risk of transmission of both malaria and HIV may be increased due to coinfection. It has been observed that HIV-infected people in areas of malaria transmission have more frequent episodes of symptomatic parasitemia [20] and higher parasitemias than those without HIV [64]. Thus, there is likely a higher risk for increased transmission of malaria in these areas. Additionally, HIV-infected people have an increase in viremia during episodes of parasitemia [15, 65], leading to a potential increase in risk of HIV transmission. Given the sheer numbers of people living with HIV in sub-Saharan Africa, an area where malaria transmission is common, there is concern for a significant public health threat.

While some interactions between malaria and HIV are known, these interactions have not been extensively studied from an epidemiological perspective. Many aspects of the relationship between malaria and HIV remain unanswered. While malaria is a major cause of morbidity and mortality in children in sub-Saharan Africa [1], little is known regarding the contribution of HIV to rates of severe malaria, cerebral malaria, and malaria deaths in these children. Additionally, the findings of increased rates of symptomatic malaria, higher parasite densities, and poorer responses to malaria treatment in adults have not been studied in children.

While it is known that pregnant women with HIV have higher rates of symptomatic malaria [25], placental malaria, and malaria transmission to their children [26], it is not known if mother-to-child transmission of HIV is affected by malaria infection. And while it has been shown that malaria infection increases HIV viral load [15], it has yet to be demonstrated if this translates to higher rates of

HIV transmission among populations. Additionally, it is not known if HIV increases rates of malaria transmission, even though it has been shown that HIV increases parasite density during malaria infection.

It is also unclear if HIV and malaria coinfection have an impact on treatment or clinical outcomes. Does HIV have an effect on resistance to antimalarial drugs, and are there more effective drugs to treat malaria in those who are also infected with HIV? Are there interactions between antiretrovirals used for HIV and antimalarial drugs currently in use, such as artemesin-derivatives? Also important to study are the effects of malaria on HIV prognosis: do the increases in viral load and decreases in CD4+ T lymphocytes seen during acute malaria infection have long term consequences on HIV progression to AIDS? These questions deserve investigative attention.

In addition to the need for population-based studies of coinfection, microbe-microbe interactions deserve further research efforts as well. It is likely that HIV and *P. falciparum* have a synergistic relationship, as both provoke an inflammatory response from immune cells, with subsequent effects on endothelial activation and blood-brain barrier permeability. Investigative methods that adequately mimic these pertinent clinical scenarios are needed. Thus, efforts to coculture malaria and HIV, and to observe the effects of each microbe during coculture, should be pursued. Examining the interactions between malaria and HIV in the setting of immune cells, endothelial models, and models of the blood-brain barrier would shed light on the effects on immune dysregulation, endothelial activation, and blood-brain barrier permeability.

Effective animal models of coinfection are also needed to look at systemic inflammatory responses and effects on end-organ damage, especially pertaining to cerebral malaria. While no animal model can fully mimic the effects of HIV and malaria coinfection in humans, it is impractical to invasively study dual infection in humans in a controlled, monitored setting. Established murine models of cerebral malaria rely on altered endothelial cell function and the immune response, both of which play a pivotal role in human disease [66]. A pertinent murine model of HIV infection and end-organ damage is the transgenic $HIV_{JR\text{-}CSF}$ model, which has been used to study blood-brain barrier integrity [67]. Integrating these two models would allow for the development of an effective mouse model for HIV and malaria coinfection. Pursuing this development will allow researchers to identify clinical findings, such as outcomes in cerebral malaria, which have yet to be elucidated in population-based studies.

As mentioned previously, 500 million cases of malaria occur each year, causing 1 million deaths [1]. Most of these cases occur in sub-Saharan Africa, where 22.5 million people are living with HIV. Thus, millions of people are likely coinfected with HIV and malaria. Investigating the effects of coinfection through in vitro coculture models, animal models, and through clinical studies focused on the pertinent epidemiological and clinical issues outlined above is needed to better understand the impact of HIV and malaria coinfection on public health.

References

[1] WHO, "World Malaria Report 2008," WHO Press, Geneva, Switzerland, 2008.

[2] UNAIDS, "AIDS epidemic update," UNAIDS and WHO, Geneva, Switzerland, 2007.

[3] WHO, "Malaria and HIV-AIDS interactions and implications: conclusions of a technical consultation convened by WHO," WHO, Geneva, Switzerland, June 2004.

[4] WHO, "Malaria Factsheet," January 2009, http://www.who.int/mediacentre/factsheets/fs094/en/index.html.

[5] C. Menendez, A. F. Fleming, and P. L. Alonso, "Malaria-related anaemia," *Parasitology Today*, vol. 16, no. 11, pp. 469–476, 2000.

[6] K. Mohan, M. L. Dubey, N. K. Ganguly, and R. C. Mahajan, "*Plasmodium falciparum*: role of activated blood monocytes in erythrocyte membrane damage and red cell loss during malaria," *Experimental Parasitology*, vol. 80, no. 1, pp. 54–63, 1995.

[7] A. M. Dondorp, B. J. Angus, K. Chotivanich, et al., "Red blood cell deformability as a predictor of anemia in severe falciparum malaria," *American Journal of Tropical Medicine and Hygiene*, vol. 60, no. 5, pp. 733–737, 1999.

[8] S. H. Abdalla and S. N. Wickramasinghe, "A study of erythroid progenitor cells in the bone marrow of Gambian children with falciparum malaria," *Clinical and Laboratory Haematology*, vol. 10, no. 1, pp. 33–40, 1988.

[9] S. Abdalla, D. J. Weatherall, S. N. Wickramasinghe, and M. Hughes, "The anaemia of *P. falciparum* malaria," *British Journal of Haematology*, vol. 46, no. 2, pp. 171–183, 1980.

[10] I. M. Medana and G. D. H. Turner, "Human cerebral malaria and the blood-brain barrier," *International Journal for Parasitology*, vol. 36, no. 5, pp. 555–568, 2006.

[11] M. J. Boivin, "Effects of early cerebral malaria on cognitive ability in Senegalese children," *Journal of Developmental and Behavioral Pediatrics*, vol. 23, no. 5, pp. 353–364, 2002.

[12] WHO, "Malaria and HIV interactions and their implications for public health policy," WHO, Geneva, Switzerland, 2005.

[13] V. Appay and D. Sauce, "Immune activation and inflammation in HIV-1 infection: causes and consequences," *Journal of Pathology*, vol. 214, no. 2, pp. 231–241, 2008.

[14] E. L. Korenromp, B. G. Williams, S. J. de Vlas, et al., "Malaria attributable to the HIV-1 epidemic, sub-Saharan Africa," *Emerging Infectious Diseases*, vol. 11, no. 9, pp. 1410–1419, 2005.

[15] J. G. Kublin, P. Patnaik, C. S. Jere, et al., "Effect of *Plasmodium falciparum* malaria on concentration of HIV-1-RNA in the blood of adults in rural Malawi: a prospective cohort study," *The Lancet*, vol. 365, no. 9455, pp. 233–240, 2005.

[16] J.-P. V. Geertruyden, M. Mulenga, W. Kasongo, et al., "CD4 T-cell count and HIV-1 infection in adults with uncomplicated malaria," *Journal of Acquired Immune Deficiency Syndromes*, vol. 43, no. 3, pp. 363–367, 2006.

[17] J. Mermin, J. R. Lule, and J. P. Ekwaru, "Association between malaria and CD4 cell count decline among persons with HIV," *Journal of Acquired Immune Deficiency Syndromes*, vol. 41, no. 1, pp. 129–130, 2006.

[18] D. Chandramohan and B. M. Greenwood, "Is there an interaction between human immunodeficiency virus and *Plasmodium falciparum*?" *International Journal of Epidemiology*, vol. 27, no. 2, pp. 296–301, 1998.

[19] I. Kalyesubula, P. Musoke-Mudido, L. Marum, et al., "Effects of malaria infection in human immunodeficiency virus type 1- infected Ugandan children," *Pediatric Infectious Disease Journal*, vol. 16, no. 9, pp. 876–881, 1997.

[20] M. R. Kamya, A. F. Gasasira, A. Yeka, et al., "Effect of HIV-1 infection on antimalarial treatment outcomes in Uganda: a population-based study," *Journal of Infectious Diseases*, vol. 193, no. 1, pp. 9–15, 2006.

[21] K. Grimwade, N. French, D. D. Mbatha, D. D. Zungu, M. Dedicoat, and C. F. Gilks, "Childhood malaria in a region of unstable transmission and high human immunodeficiency virus prevalence," *Pediatric Infectious Disease Journal*, vol. 22, no. 12, pp. 1057–1063, 2003.

[22] K. Grimwade, N. French, D. D. Mbatha, D. D. Zungu, M. Dedicoat, and C. F. Gilks, "HIV infection as a cofactor for severe falciparum malaria in adults living in a region of unstable malaria transmission in South Africa," *AIDS*, vol. 18, no. 3, pp. 547–554, 2004.

[23] C. Cohen, A. Karstaedt, J. Frean, et al., "Increased prevalence of severe malaria in HIV-infected adults in South Africa," *Clinical Infectious Diseases*, vol. 41, no. 11, pp. 1631–1637, 2005.

[24] R. O. Otieno, C. Ouma, J. M. Ong'echa, et al., "Increased severe anemia in HIV-1-exposed and HIV-1-positive infants and children during acute malaria," *AIDS*, vol. 20, no. 2, pp. 275–280, 2006.

[25] A. M. van Eijk, J. G. Ayisi, F. O. ter Kuile, et al., "HIV increases the risk of malaria in women of all gravidities in Kisumu, Kenya," *AIDS*, vol. 17, no. 4, pp. 595–603, 2003.

[26] S. D. Perrault, J. Hajek, K. Zhong, et al., "Human immunodeficiency virus co-infection increases placental parasite density and transplacental malaria transmission in western Kenya," *American Journal of Tropical Medicine and Hygiene*, vol. 80, no. 1, pp. 119–125, 2009.

[27] E. G. Dembo, V. Mwapasa, J. Montgomery, et al., "Impact of human immunodeficiency virus infection in pregnant women on variant-specific immunity to malaria," *Clinical and Vaccine Immunology*, vol. 15, no. 4, pp. 617–621, 2008.

[28] J. Keen, L. Serghides, K. Ayi, et al., "HIV impairs opsonic phagocytic clearance of pregnancy-associated malaria parasites," *PLoS Medicine*, vol. 4, no. 5, article e181, 2007.

[29] A. Ayouba, E. Nerrienet, E. Menu, et al., "Mother-to-child transmission of human immunodeficiency virus type 1 in relation to the season in Yaounde, Cameroon," *American Journal of Tropical Medicine and Hygiene*, vol. 69, no. 4, pp. 447–449, 2003.

[30] J. G. Ayisi, A. M. van Eijk, R. D. Newman, et al., "Maternal malaria and perinatal HIV transmission, Western Kenya," *Emerging Infectious Diseases*, vol. 10, no. 4, pp. 643–652, 2004.

[31] A. Ayouba, C. Badaut, A. Kfutwah, et al., "Specific stimulation of HIV-1 replication in human placental trophoblasts by an antigen of *Plasmodium falciparum*," *AIDS*, vol. 22, no. 6, pp. 785–787, 2008.

[32] S. de Kossodo and G. E. Grau, "Profiles of cytokine production in relation with susceptibility to cerebral malaria," *The Journal of Immunology*, vol. 151, no. 9, pp. 4811–4820, 1993.

[33] D. Prakash, C. Fesel, R. Jain, P.-A. Cazenave, G. C. Mishra, and S. Pied, "Clusters of cytokines determine malaria severity in *Plasmodium falciparum*-infected patients from endemic areas of central India," *Journal of Infectious Diseases*, vol. 194, no. 2, pp. 198–207, 2006.

[34] K. E. Lyke, R. Burges, Y. Cissoko, et al., "Serum levels of the proinflammatory cytokines interleukin-1 β (IL-1β), IL-6, IL-8, IL-10, tumor necrosis factor alpha, and IL-12(p70) in Malian children with severe *Plasmodium falciparum* malaria and matched uncomplicated malaria or healthy controls," *Infection and Immunity*, vol. 72, no. 10, pp. 5630–5637, 2004.

[35] P. Bejon, G. Warimwe, C. L. Mackintosh, et al., "Analysis of immunity to febrile malaria in children that distinguishes immunity from lack of exposure," *Infection and Immunity*, vol. 77, no. 5, pp. 1917–1923, 2009.

[36] B. C. Urban, D. J. P. Ferguson, A. Pain, et al., "*Plasmodium falciparum*infected erythrocytes modulate the maturation of dendritic cells," *Nature*, vol. 400, no. 6739, pp. 73–77, 1999.

[37] R. Ing, M. Segura, N. Thawani, M. Tam, and M. M. Stevenson, "Interaction of mouse dendritic cells and malaria-infected erythrocytes: uptake, maturation, and antigen presentation," *The Journal of Immunology*, vol. 176, no. 1, pp. 441–450, 2006.

[38] J. A. Perry, C. S. Olver, R. C. Burnett, and A. C. Avery, "Cutting edge: the acquisition of TLR tolerance during malaria infection impacts T cell activation," *The Journal of Immunology*, vol. 174, no. 10, pp. 5921–5925, 2005.

[39] H. E. Gendelman, I. Grant, I. P. Everall, and S. A. Lipton, Eds., *The Neurology of AIDS*, Oxford University Press, London, UK, 2005.

[40] A. Yadav, P. Fitzgerald, M. M. Sajadi, et al., "Increased expression of suppressor of cytokine signaling-1 (SOCS-1): a mechanism for dysregulated T helper-1 responses in HIV-1 disease," *Virology*, vol. 385, no. 1, pp. 126–133, 2009.

[41] M. Clerici and G. M. Shearer, "A TH1 $\rightarrow$ TH2 switch is a critical step in the etiology of HIV infection," *Trends in Immunology*, vol. 14, no. 3, pp. 107–111, 1993.

[42] X. Ma and L. J. Montaner, "Proinflammatory response and IL-12 expression in HIV-1 infection," *Journal of Leukocyte Biology*, vol. 68, no. 3, pp. 383–390, 2000.

[43] H. Brown, S. Rogerson, T. Taylor, et al., "Blood-brain barrier function in cerebral malaria in Malawian children," *American Journal of Tropical Medicine and Hygiene*, vol. 64, no. 3-4, pp. 207–213, 2001.

[44] M. R. Gillrie, G. Krishnegowda, K. Lee, et al., "Src-family kinase-dependent disruption of endothelial barrier function by *Plasmodium falciparum* merozoite proteins," *Blood*, vol. 110, no. 9, pp. 3426–3435, 2007.

[45] P. Susomboon, Y. Maneerat, P. Dekumyoy, et al., "Down-regulation of tight junction mRNAs in human endothelial cells co-cultured with *Plasmodium falciparum*-infected erythrocytes," *Parasitology International*, vol. 55, no. 2, pp. 107–112, 2006.

[46] I. M. B. Francischetti, K. B. Seydel, R. Q. Monteiro, et al., "*Plasmodium falciparum*-infected erythrocytes induce tissue factor expression in endothelial cells and support the assembly of multimolecular coagulation complexes," *Journal of Thrombosis and Haemostasis*, vol. 5, no. 1, pp. 155–165, 2007.

[47] I. M. B. Francischetti, K. Seydel, and R. Monteiro, "Blood coagulation, inflammation, and malaria," *Microcirculation*, vol. 15, no. 2, pp. 81–107, 2008.

[48] B. Traoré, K. Muanza, S. Looareesuwan, et al., "Cytoadherence characteristics of *Plasmodium falciparum* isolates in Thailand using an in vitro human lung endothelial cells model," *American Journal of Tropical Medicine and Hygiene*, vol. 62, no. 1, pp. 38–44, 2000.

[49] J. Li, W.-L. Chang, G. Sun, et al., "Intercellular adhesion molecule 1 is important for the development of severe experimental malaria but is not required for leukocyte adhesion in

the brain," *Journal of Investigative Medicine*, vol. 51, no. 3, pp. 128–140, 2003.

[50] R. Lucas, P. Juillard, E. Decoster, et al., "Crucial role of tumor necrosis factor (TNF) receptor 2 and membrane-bound TNF in experimental cerebral malaria," *European Journal of Immunology*, vol. 27, no. 7, pp. 1719–1725, 1997.

[51] J. G. Prudhomme, I. W. Sherman, K. M. Land, A. V. Moses, S. Stenglein, and J. A. Nelson, "Studies of *Plasmodium falciparum* cytoadherence using immortalized human brain capillary endothelial cells," *International Journal for Parasitology*, vol. 26, no. 6, pp. 647–655, 1996.

[52] M. M. Mota, W. Jarra, E. Hirst, P. K. Patnaik, and A. A. Holder, "Plasmodium chabaudi-infected erythrocytes adhere to CD36 and bind to microvascular endothelial cells in an organ-specific way," *Infection and Immunity*, vol. 68, no. 7, pp. 4135–4144, 2000.

[53] L. Meroni, A. Riva, P. Morelli, et al., "Increased CD36 expression on circulating monocytes during HIV infection," *Journal of Acquired Immune Deficiency Syndromes*, vol. 38, no. 3, pp. 310–313, 2005.

[54] C. M. Buckner, A. J. Luers, T. M. Calderon, E. A. Eugenin, and J. W. Berman, "Neuroimmunity and the blood-brain barrier: molecular regulation of leukocyte transmigration and viral entry into the nervous system with a focus on neuroAIDS," *Journal of Neuroimmune Pharmacology*, vol. 1, no. 2, pp. 160–181, 2006.

[55] E. A. Eugenin, K. Osiecki, L. Lopez, H. Goldstein, T. M. Calderon, and J. W. Berman, "CCL2/monocyte chemoattractant protein-1 mediates enhanced transmigration of human immunodeficiency virus (HIV)-infected leukocytes across the blood-brain barrier: a potential mechanism of HIV-CNS invasion and NeuroAIDS," *Journal of Neuroscience*, vol. 26, no. 4, pp. 1098–1106, 2006.

[56] T. S. Skinner-Adams, J. S. McCarthy, D. L. Gardiner, P. M. Hilton, and K. T. Andrews, "Antiretrovirals as antimalarial agents," *Journal of Infectious Diseases*, vol. 190, no. 11, pp. 1998–2000, 2004.

[57] S. Parikh, J. Gut, E. Istvan, D. E. Goldberg, D. V. Havlir, and P. J. Rosenthal, "Antimalarial activity of human immunodeficiency virus type 1 protease inhibitors," *Antimicrobial Agents and Chemotherapy*, vol. 49, no. 7, pp. 2983–2985, 2005.

[58] K. T. Andrews, D. P. Fairlie, P. K. Madala, et al., "Potencies of human immunodeficiency virus protease inhibitors in vitro against *Plasmodium falciparum* and in vivo against murine malaria," *Antimicrobial Agents and Chemotherapy*, vol. 50, no. 2, pp. 639–648, 2006.

[59] C. V. Hobbs, T. Voza, A. Coppi, et al., "HIV protease inhibitors inhibit the development of preerythrocytic-stage Plasmodium parasites," *Journal of Infectious Diseases*, vol. 199, no. 1, pp. 134–141, 2009.

[60] S. Nathoo, L. Serghides, and K. C. Kain, "Effect of HIV-1 antiretroviral drugs on cytoadherence and phagocytic clearance of *Plasmodium falciparum*-parasitised erythrocytes," *The Lancet*, vol. 362, no. 9389, pp. 1039–1041, 2003.

[61] A. Savarino, M. B. Lucia, E. Rastrelli, et al., "Anti-HIV effects of chloroquine: inhibition of viral particle glycosylation and synergism with protease inhibitors," *Journal of Acquired Immune Deficiency Syndromes*, vol. 35, no. 3, pp. 223–232, 2004.

[62] T. S. Skinner-Adams, K. T. Andrews, L. Melville, J. McCarthy, and D. L. Gardiner, "Synergistic interactions of the antiretroviral protease inhibitors saquinavir and ritonavir with chloroquine and mefloquine against *Plasmodium falciparum* in vitro," *Antimicrobial Agents and Chemotherapy*, vol. 51, no. 2, pp. 759–762, 2007.

[63] J. Mermin, J. P. Ekwaru, C. A. Liechty, et al., "Effect of co-trimoxazole prophylaxis, antiretroviral therapy, and insecticide-treated bednets on the frequency of malaria in HIV-1-infected adults in Uganda: a prospective cohort study," *The Lancet*, vol. 367, no. 9518, pp. 1256–1261, 2006.

[64] J. Whitworth, D. Morgan, M. Quigley, et al., "Effect of HIV-1 and increasing immunosuppression on malaria parasitaemia and clinical episodes in adults in rural Uganda: a cohort study," *The Lancet*, vol. 356, no. 9235, pp. 1051–1056, 2000.

[65] I. F. Hoffman, C. S. Jere, T. E. Taylor, et al., "The effect of *Plasmodium falciparum* malaria on HIV-1 RNA blood plasma concentration," *AIDS*, vol. 13, no. 4, pp. 487–494, 1999.

[66] N. H. Hunt and G. E. Grau, "Cytokines: accelerators and brakes in the pathogenesis of cerebral malaria," *Trends in Immunology*, vol. 24, no. 9, pp. 491–499, 2003.

[67] H. Wang, J. Sun, and H. Goldstein, "Human immunodeficiency virus type 1 infection increases the in vivo capacity of peripheral monocytes to cross the blood-brain barrier into the brain and the in vivo sensitivity of the blood-brain barrier to disruption by lipopolysaccharide," *Journal of Virology*, vol. 82, no. 15, pp. 7591–7600, 2008.

Hindawi Publishing Corporation
Interdisciplinary Perspectives on Infectious Diseases
Volume 2009, Article ID 802712, 5 pages
doi:10.1155/2009/802712

Review Article

New Means of Canine Leishmaniasis Transmission in North America: The Possibility of Transmission to Humans Still Unknown

Christine A. Petersen

2764 Veterinary Medicine, Department of Veterinary Pathology, Iowa State University, Ames, IA 50011, USA

Correspondence should be addressed to Christine A. Petersen, kalicat@iastate.edu

Received 6 March 2009; Accepted 27 April 2009

Recommended by Herbert B. Tanowitz

At present it is not possible to determine in advance the outcome of *Leishmania infantum* infection. Canine Visceral Leishmaniasis (VL), caused by *Le. infantum*, is a natural disease process which offers a insight into the interaction of the host and resultant disease outcome. Canine VL results in the same altered pathophysiology and immunodysregulation seen in humans. VL in US dogs is likely to be transmitted primarily via nontraditional, nonvector means. VL mediated by *Le. infantum* is endemic in U.S. Foxhound dogs, with vertical transmission likely to be the novel primary means of transmission. This population of dogs offers an opportunity to identify host factors of natural disease. Prevention of human clinical visceral leishmaniasis can occur only by better understanding the disease ecology of the primary reservoir host: the dog.

1. Introduction

Leishmania infantum is the causative agent of visceral leishmaniasis (VL) in the Mediterranean Basin and more recently North America. Natural hosts include dogs and humans [1], and transmission is usually via a sand fly vector. Infected dogs are the primary reservoir for zoonotic visceral leishmaniasis in endemic regions and are the most significant risk factor predisposing humans to infection [2]. Both dogs and humans have a wide range of clinical presentation due to infection with *Le. infantum*, ranging from asymptomatic to fatal visceralizing disease (Figure 1). Host factors which determine clinical outcome are poorly understood. When clinical symptoms (signs) in both humans and dogs occur, they include enlarged lymph nodes and hepato- and splenomegaly due to parasitic invasion of the reticulo-endothelial system of phagocytic lymphocytes [3]. Visceral leishmaniasis symptoms persist in both humans and canine patients for several weeks to months before patients seek medical care. In the meanwhile these patients are at risk of death from bacterial coinfections, massive bleeding, severe anemia [3], or renal failure in veterinary patients. A better understanding of this neglected disease, particularly the host and vector factors which lead to disease transmission and/or predict clinical outcome, is needed to optimally prevent clinical disease outright but otherwise bring these patients to medical attention faster, have them diagnosed correctly, and treated successfully.

2. Transmission of *Le. infantum*

Dogs are the primary mammalian reservoir for *Le. infantum* infection in endemic regions and are the most significant risk factor predisposing humans to infection [2]. In endemic areas, the primary means of transmission is vector-borne via the sand fly. Canine infection in the US suggests a possible human health threat if domestic sand fly species are capable of *Leishmania* transmission. Vector-borne transmission has not been shown in the US to date [4, 5]. Vertical transmission appears to be a major means of transmission in Foxhounds in the US [4]. The frequency of vertical transmission in endemic areas is unknown due to the overwhelming likelihood of vector contact [6].

(a) (b)

Figure 1: Both humans and dogs have a wide clinical presentation with *Le. infantum*. These presentations vary from (a) no clinical signs and robust healthy behavior in a young healthy Foxhound to (b) multiple clinical signs (polysymptomatic) including poor hair coat, enlarged liver and spleen, and crusty cutaneous lesions seen on the rump in an older hound.

A potential sand fly vector of *Le. infantum*, *Lutzomyia shannoni,* is present within Southern and Southeastern United States [4]. *Lu. shannoni* is known to bite dogs and other mammals and has been incriminated in the transmission of *Le. brasiliensis* in South and Central America [7]. Anecdotal data indicate that US species of *Lu. shannoni* can become infected with *Le. infantum*, but it is not known whether these flies permit *Le. infantum* development into infectious metacyclic parasites. Vector feeding preferences can importantly influence disease transmission. In the US, *Lu. shannoni* has also been shown to bite dogs (Rowton personal communication). Although vector feeding preferences can significantly influence disease transmission, host preference for *Lu. shannoni* in the US is currently not known.

3. Sand Fly Preference for Canines as Food Source

In South and Central America, several investigators have demonstrated that dogs are an important blood source to the principal vector of visceral leishmaniasis: *Lu. longipalpis* [8, 9]. Data from a study of the emergence of visceral leishmaniasis in Central Israel in the mid 1990's [10] suggested that a high prevalence of infected dogs (11.5%) contributed to the onset of the disease in humans. In Brazil, *Lu. longipalpis* is frequently found in houses with dogs [11]. A recent study detected high levels of antisand fly saliva antibodies in dogs from an endemic area of transmission of *Le. infantum* in Brazil compared to dogs from nonendemic areas [12], suggesting high exposure to the visceral leishmaniasis vector *Lu. longipalpis*. Dogs play a significant role in the spread and maintenance of *Le. infantum* in endemic areas, although it is not completely clear why dogs are more attractive as a blood source to sand flies. Using the *host selectivity index*, defined as the number of sand flies that feed on a given host relative to the available biomass of the host [13], *Lu. pseudolongipalpis*, a vector of visceral leishmaniasis in Colombia, preferred dogs as blood source. In contrast, *Lu. longipalpis* was shown to have no particular preference for specific vertebrate hosts and to be opportunistic feeders [14–17]. There has only been one substantial study looking at the feeding preferences of *Lu. shannoni* in the US [18]. This study was performed on a largely uninhabited barrier island off Georgia and did not find dogs to be a primary food source, but this was most likely because there were very few dogs present on the island. In many settings dogs have been shown to be a link between sylvatic and domestic cycles of visceral leishmaniasis. Dogs often cross forest-edge boundaries, thereby potentially bringing parasites to, or from, sylvatic systems and to and from other potential mammal hosts (such as foxes and opossums). In the US, due to frequent exchange of Foxhounds between kennels and these dogs' penchant for spending time in the woods, Foxhounds may be a primary focal point for transmission of *Le. infantum* to sand flies. Thus, if *Lu. shannoni* indeed prefers to feed on dogs in comparison to other mammals, infected dogs are more likely than other mammals to serve as a source of *Le. infantum* to an uninfected fly. It is important to determine whether *Lu. shannoni* feeds on dogs and further if US sand flies are permissive to parasite development into infectious metacyclic promastigotes.

4. Visceral Leishmaniasis in Foxhounds

Visceral Leishmaniasis is classically transmitted to a suitable mammalian host by the bite of an infected sand fly after which the promastigote form of the parasite is phagocytosed by macrophages [1]. Although endemic in many parts of the world, this disease has only recently been described as transmitted solely within the US [19]. Previously, sporadic cases have been reported in the United States, in human and canine travelers returning to the US from endemic areas [5]. However, in 2000, a kennel in New York State reported four Foxhounds with no travel history to be infected with *Le. Infantum*[19]. By 2005, 60 kennels in 22 states and two Canadian provinces had reported seropositive Foxhounds [20]. Nonvector-based mechanisms postulated for transmission of canine visceral leishmaniasis in the US include vertical transmission (transplacental or transmammary) and horizontal transmission by direct contact with infected cells in blood [4, 5, 21]. Transmission has been documented via packed red blood cell transfusion from infected Foxhounds [22]. It is not known how frequently vertical transmission occurs naturally in endemic areas. There are reports of

congenital transmission of visceral leishmaniasis in humans and during experimental *Leishmania* infection of beagles [20]. Pathology of visceral leishmaniasis of US Foxhounds was equivalent to that seen in dogs and humans infected in endemic areas through sand fly transmission [21]. Whether vertical transmission itself is solely responsible for the focus of disease in this breed of dogs or whether there are genetic factors predisposing particular lineages of Foxhounds should be further investigated.

5. Diagnosis of Visceral Leishmaniasis

In both humans and dogs, infection with *Leishmania infantum* frequently does not equate with clinical illness. The ratio of incident asymptomatic infection to incident clinical cases varies with location, vector and parasite. Ratios of 18:1 in Brazil and 50:1 in Spain have been observed in human populations [3] and is estimated to be 2:1 in high-risk US Foxhounds. Different means of transmission, as observed in US Foxhounds, will also alter this ratio. At present, diagnosis and control of visceral leishmaniasis is difficult as both humans and dogs can be infected but seronegative for years [23]. Various means of serology are the primary diagnostic tests used for surveillance of visceral leishmaniasis. For public health surveillance in the US where this disease is not endemic in humans, testing is performed via an indirect fluorescent antibody assay (IFA) by the Centers for Disease Control and Prevention (CDC). IFA is sufficient for screening purposes, but is found to cross react with antibodies to the kinetoplastid *Trypanosoma cruzi*. *T. cruzi* infects dogs in the Southeastern US, thus further testing is required to determine parasite specificity unless clinical signs are much more consistent with one infection over the other; for example, cardiomyopathy in the case of Chagas' disease. Other serologic tests are available in the US for detection of canine leishmaniasis including a highly sensitive and specifc kELISA available through the Cornell University diagnostic laboratory and a K39-antigen based assay available through Heska. Positive serology in Foxhounds appears to more closely correlate with the appearance of clinical disease than incidence of infection. Reports have shown that qPCR performed by a well-regulated and stringently tested laboratory can be a more sensitive test for *Le. infantum* infection in dogs and can detect asymptomatic dogs and/or dogs that have not yet to seroconvert [21]. qPCR is available through Iowa State University and the CDC.

6. IL-10 and Pathogenesis of VL

Mechanisms underlying systemic spread of *Leishmania infantum* during VL are not well understood. Mammalian host responses which prevent progression to clinical VL has been shown to be dependent on promoting T helper-1 IFN-γ production-based immunity and parasiticidal activity within infected macrophages [3]. A key immunological feature of late stage clinical VL in either humans or dogs is an inability to proliferate or to produce IFN-γ in response to *Leishmania* antigen ([24] and Petersen preliminary data). Pharmacologically-cured individuals are resistant to re-infection and mount antigen-specific IFN-γ responses in vitro, indicating that there is not an inherent defect in host CD4+ T cell responses of clinical patients once they have reached this stage. The actual factors which influence clinically-observed infection with *Le. infantum* are still mainly speculative [25]. One study of genetic factors predisposing to clinical VL identified a TNF-α allele associated with high serum levels of this cytokine [26]. High levels of TNF-α have been proposed to stimulate production of regulatory cytokines, specifically IL-10, as a homeostatic response to prevent further inflammation-mediated pathology. High leisonal IL-10 mRNA production is frequently found in human patients with VL [25, 27], and produced by polysymptomatic Foxhounds (Petersen preliminary data). IL-10 can be produced by many cell types including T cells, B cells and macrophages. One of the proposed mechanisms of IL-10 promotion of VL is by conditioning macrophages for parasite growth and survival versus killing. The best means of determining how leisonal IL-10 contributes to disease outcome would *ex vivo* study of splenic cells [27], which is not possible in human patients.

7. Genetic Factors Related to Visceral Leishmaniasis Disease Susceptibility

Although several genetic polymorphisms, including alterations in TNF-α and solute carrier family 11A1 (SLC11A1, formerly NRAMP1) allelic expression, have been indicated to predispose to disease [26, 28], causative factors of disease susceptibility in both humans and dogs, specifically those associated with heritability, remain elusive. Breed type has also been shown to alter the response to therapy, suggesting that canine breed-related genetic factors modulate disease progression and are therefore prognostically significant [29].

Numerous Foxhounds have tested positive for visceral leishmaniasis in the US and infection appears to be endemic only within this breed in the US If vertical transmission is indeed the primary route of transmission in these dogs, a particular genetic susceptibility is not absolutely necessary for widespread infection to occur in the Foxhound population. Both the observance of visceral leishmaniasis within specific families of Foxhounds and finding hounds that are *Leishmania* disease-resistant suggests that it is highly likely that particular genetic traits of dogs at least in part determine which dogs develop visceral leishmaniasis versus remain clinically disease-free.

8. Treatment/Prognosis

Treatment of visceral leishmaniasis (VL) is rarely 100% curative. Prognosis for emaciated chronically infected dogs is very poor and in these cases euthanasia should be considered. Due to difficulty obtaining certain drugs in the United States, treatment in dogs is recommended to begin with allopurinol (Zyloric). This drug is efficacious and relatively nontoxic when used as a maintenance drug. Clinical remission is often achieved when used alone. Relapses are common

when treatment ceases, complete cures are rare but survival occurs in 80% of cases over 4 years if renal insufficiency is not present when treatment is initiated. This drug is sometimes used in combination both in dogs and humans with pentavalent antimony (Glucantime), as drug resistance is seen for pentavalent antimony alone in endemic areas (France, Spain, and Italy). Pentavalent antimonials are not licensed for use in the United States and can only be obtained via an investigational drug use protocol from the CDC [30, 31]. The two main drugs in this class are (1) sodium stibogluconate (Pentostam, Wellcome Foundation Ltd, UK), which requires daily injection and has severe side effects, and (2) meglutamine antimoniate (Glucantime, Pfizer/Merial, France), which has less side effects. Amphotericin B in the lipid emulsion or liposomal form is relatively nonnephrotoxic and is effective against the organism, although it is not thought to be superior to allopurinol as it is still both more costly and more toxic. Renal insufficiency must be treated prior to giving antimonial drugs or amphotericin B as prognosis is dependent on renal function at the onset of treatment. Treatment efficacy is best monitored by clinical improvement and presence of organisms in biopsy or as measured by rigorously controlled qPCR. Relapses occur a few months to a year after therapy, so dogs should be rechecked at least every 2 months after the end of treatment. Prognosis for a cure is very guarded, but therapy does provide infected dogs improved quality of life.

Second-line drugs, which require further clinical studies to understand their efficacy in both dogs and humans, include miltefosine (Impavido or Miltex) and paromomycin (Humantin). Paromymycin has been shown to have fewer side effects than other drugs in humans. Use of this drug has been primarily targeted to the cutaneous versions of *Leishmania*, less is known about its ability to remove organ-based infection. There is no effective vaccine against CVL available in the United States. A secreted parasite antigen-based vaccine has recently been licensed for use in dogs in Brazil. Sand fly vector control measures, including deltamethrin or permethrin-impregnated collars are useful to date to prevent disease [32]. In many countries, due to the tie of canine infection to human disease, culling of dogs is still used as a means to prevent human disease [33, 34].

9. Summary

Factors which contribute to clinical VL are poorly understood. Canine VL mimics both immunology and pathophysiology of human disease. *Leishmania infantum* infection is endemic in the US Foxhound population. Study of these naturally infected dogs allows insight into the mechanism of lesional IL-10 and other host factors in promoting clinical disease. A cohort population of domestic dogs, specifically American Foxhounds, provides a unique and valuable model system to define vector and host factors that mediate presentation with clinical visceral leishmaniasis. Current evidence indicates that nontraditional means of transmission, particularly vertical transmission, may be a primary route of transmission of the parasite in US dogs, although *Lutzomyia* species in the US may be involved in transmission. Further study is necessary to better understand the impact of vertical transmission of leishmaniasis on the persistence of this disease and determine the likelihood of vector-borne transmission in the US.

Acknowledgments

The authors would like to thank their many canine breed collaborators for providing information and samples to better understand this fatal disease. Dr. Petersen is currently funded by AKC CHF Grants 1159 and 1220 and NIH R21AI074711.

References

[1] L. J. Roberts, E. Handman, and S. J. Foote, "Science, medicine, and the future: leishmaniasis," *British Medical Journal*, vol. 321, no. 7264, pp. 801–804, 2000.

[2] A. S. Mazloumi Gavgani, M. H. Hodjati, H. Mohite, and C. R. Davies, "Effect of insecticide-impregnated dog collars on incidence of zoonotic visceral leishmaniasis in Iranian children: a matched-cluster randomised trial," *The Lancet*, vol. 360, no. 9330, pp. 374–379, 2002.

[3] F. Chappuis, S. Sundar, A. Hailu, et al., "Visceral leishmaniasis: what are the needs for diagnosis, treatment and control?" *Nature Reviews Microbiology*, vol. 5, no. 11, pp. 873–882, 2007.

[4] Z. H. Duprey, F. J. Steurer, J. A. Rooney, et al., "Canine visceral leishmaniasis, United States and Canada, 2000–2003," *Emerging Infectious Diseases*, vol. 12, no. 3, pp. 440–446, 2006.

[5] P. M. Schantz, F. J. Steurer, Z. H. Duprey, et al., "Autochthonous visceral leishmaniasis in dogs in North America," *Journal of the American Veterinary Medical Association*, vol. 226, no. 8, pp. 1316–1322, 2005.

[6] F. Mancianti, M. Gramiccia, L. Gradoni, and S. Pieri, "Studies on canine leishmaniasis control. 1. Evolution of infection of different clinical forms of canine leishmaniasis following antimonial treatment," *Transactions of the Royal Society of Tropical Medicine and Hygiene*, vol. 82, no. 4, pp. 566–567, 1988.

[7] B. L. Travi, C. Ferro, H. Cadena, J. Montoya-Lerma, and G. H. Adler, "Canine visceral leishmaniasis: dog infectivity to sand flies from non-endemic areas," *Research in Veterinary Science*, vol. 72, no. 1, pp. 83–86, 2002.

[8] J. Alvar, C. Cañavate, R. Molina, J. Moreno, and J. Nieto, "Canine leishmaniasis," *Advances in Parasitology*, vol. 57, pp. 1–88, 2004.

[9] M. Gramiccia and L. Gradoni, "The current status of zoonotic leishmaniases and approaches to disease control," *International Journal for Parasitology*, vol. 35, no. 11-12, pp. 1169–1180, 2005.

[10] G. Baneth, G. Dank, E. Keren-Kornblatt, et al., "Emergence of visceral leishmaniasis in central Israel," *American Journal of Tropical Medicine and Hygiene*, vol. 59, no. 5, pp. 722–725, 1998.

[11] R. J. Quinnell and C. Dye, "Correlates of the peridomestic abundance of *Lutzomyia longipalpis* (Diptera: Psychodidae) in Amazonian Brazil," *Medical and Veterinary Entomology*, vol. 8, no. 3, pp. 219–224, 1994.

[12] R. B. Gomes, I. L. Mendonça, V. C. Silva, et al., "Antibodies against *Lutzomyia longipalpis* saliva in the fox *Cerdocyon thous* and the sylvatic cycle of *Leishmania chagasi*," *Transactions of*

the Royal Society of Tropical Medicine and Hygiene, vol. 101, no. 2, pp. 127–133, 2007.

[13] I. Agrela, E. Sanchez, B. Gomez, and M. D. Feliciangeli, "Feeding behavior of *Lutzomyia pseudolongipalpis* (Diptera: Psychodidae), a putative vector of visceral leishmaniasis in Venezuela," *Journal of Medical Entomology*, vol. 39, no. 3, pp. 440–445, 2002.

[14] A. C. Morrison, C. Ferro, and R. B. Tesh, "Host preferences of the sand fly *Lutzomyia longipalpis* at an endemic focus of American visceral leishmaniasis in Colombia," *American Journal of Tropical Medicine and Hygiene*, vol. 49, no. 1, pp. 68–75, 1993.

[15] M. F. F. M. Ximenes, M. F. Souza, and E. G. Castellón, "Density of sand flies (Diptera: Psychodidae) in domestic and wild animal shelters in an area of visceral leishmaniasis in the state of Rio Grande do Norte, Brazil," *Memorias do Instituto Oswaldo Cruz*, vol. 94, no. 4, pp. 427–432, 1999.

[16] R. A. Barata, J. C. França-Silva, W. Mayrink, et al., "Aspects of the ecology and behaviour of phlebotomines in endemic area for visceral leishmaniasis in state of Minas Gerais," *Revista da Sociedade Brasileira de Medicina Tropical*, vol. 38, no. 5, pp. 421–425, 2005.

[17] F. O. Dias, E. S. Lorosa, and J. M. Rebêlo, "Blood feeding sources and peridomiciliation of *Lutzomyia longipalpis* (Lutz & Neiva, 1912) (Psychodidae, Phlebotominae)," *Cadernos de Saúde Pública*, vol. 19, no. 5, pp. 1373–1380, 2003.

[18] J. A. Comer, W. S. Irby, and D. M. Kavanaugh, "Hosts of *Lutzomyia shannoni* (Diptera: Psychodidae) in relation to vesicular stomatitis virus on Ossabaw Island, Georgia, U.S.A," *Medical and Veterinary Entomology*, vol. 8, no. 4, pp. 325–330, 1994.

[19] A. A. Gaskin, P. Schantz, J. Jackson, et al., "Visceral leishmaniasis in a New York foxhound kennel," *Journal of Veterinary Internal Medicine*, vol. 16, no. 1, pp. 34–44, 2002.

[20] A. C. Rosypal, G. C. Troy, R. B. Duncan, A. M. Zajac, and D. S. Lindsay, "Utility of diagnostic tests used in diagnosis of infection in dogs experimentally inoculated with a North American isolate of *Leishmania infantum* infantum," *Journal of Veterinary Internal Medicine*, vol. 19, no. 6, pp. 802–809, 2005.

[21] K. N. Gibson-Corley, J. M. Hostetter, S. J. Hostetter, et al., "Disseminated *Leishmania infantum* infection in two sibling foxhounds due to possible vertical transmission," *Canadian Veterinary Journal*, vol. 49, no. 10, pp. 1005–1008, 2008.

[22] S. D. Owens, D. A. Oakley, K. Marryott, et al., "Transmission of visceral leishmaniasis through blood transfusions from infected English foxhounds to anemic dogs," *Journal of the American Veterinary Medical Association*, vol. 219, no. 8, pp. 1076–1083, 2001.

[23] R. J. Quinnell, O. Courtenay, L. M. Garcez, et al., "IgG subclass responses in a longitudinal study of canine visceral leishmaniasis," *Veterinary Immunology and Immunopathology*, vol. 91, no. 3-4, pp. 161–168, 2003.

[24] D. L. Sacks, S. L. Lal, S. N. Shrivastava, J. Blackwell, and F. A. Neva, "An analysis of T cell responsiveness in Indian kala-azar," *Journal of Immunology*, vol. 138, no. 3, pp. 908–913, 1987.

[25] S. Nylén and D. Sacks, "Interleukin-10 and the pathogenesis of human visceral leishmaniasis," *Trends in Immunology*, vol. 28, no. 9, pp. 378–384, 2007.

[26] T. M. Karplus, S. M. B. Jeronimo, H. Chang, et al., "Association between the tumor necrosis factor locus and the clinical outcome of *Leishmania chagasi* infection," *Infection and Immunity*, vol. 70, no. 12, pp. 6919–6925, 2002.

[27] S. Nylén, R. Maurya, L. Eidsmo, K. Das Manandhar, S. Sundar, and D. Sacks, "Splenic accumulation of IL-10 mRNA in T cells distinct from $CD4^+CD25^+$ (Foxp3) regulatory T cells in human visceral leishmaniasis," *The Journal of Experimental Medicine*, vol. 204, no. 4, pp. 805–817, 2007.

[28] J. M. Blackwell, H. S. Mohamed, and M. E. Ibrahim, "Genetics and visceral leishmaniasis in the Sudan: seeking a link," *Trends in Parasitology*, vol. 20, no. 6, pp. 268–274, 2004.

[29] J. F. Modiano, M. Breen, R. C. Burnett, et al., "Distinct B-cell and T-cell lymphoproliferative disease prevalence among dog breeds indicates heritable risk," *Cancer Research*, vol. 65, no. 13, pp. 5654–5661, 2005.

[30] G. Miró, L. Cardoso, M. G. Pennisi, G. Oliva, and G. Baneth, "Canine leishmaniosis—new concepts and insights on an expanding zoonosis: part two," *Trends in Parasitology*, vol. 24, no. 8, pp. 371–377, 2008.

[31] S. L. Croft, S. Sundar, and A. H. Fairlamb, "Drug resistance in leishmaniasis," *Clinical Microbiology Reviews*, vol. 19, no. 1, pp. 111–126, 2006.

[32] V. Foglia Manzillo, G. Oliva, A. Pagano, L. Manna, M. Maroli, and L. Gradoni, "Deltamethrin-impregnated collars for the control of canine leishmaniasis: evaluation of the protective effect and influence on the clinical outcome of *Leishmania* infection in kennelled stray dogs," *Veterinary Parasitology*, vol. 142, no. 1-2, pp. 142–145, 2006.

[33] D. A. Ashford, J. R. David, M. Freire, et al., "Studies on control of visceral leishmaniasis: impact of dog control on canine and human visceral leishmaniasis in Jacobina, Bahia, Brazil," *American Journal of Tropical Medicine and Hygiene*, vol. 59, no. 1, pp. 53–57, 1998.

[34] E. D. Moreira Jr., V. M. Mendes de Souza, M. Sreenivasan, E. G. Nascimento, and L. Pontes de Carvalho, "Assessment of an optimized dog-culling program in the dynamics of canine *Leishmania* transmission," *Veterinary Parasitology*, vol. 122, no. 4, pp. 245–252, 2004.

Hindawi Publishing Corporation
Interdisciplinary Perspectives on Infectious Diseases
Volume 2009, Article ID 824324, 6 pages
doi:10.1155/2009/824324

Review Article

Perspectives on Adipose Tissue, Chagas Disease and Implications for the Metabolic Syndrome

Fnu Nagajyothi,[1] Mahalia S. Desruisseaux,[1,2] Linda A. Jelicks,[3] Fabiana S. Machado,[4] Streamson Chua,[2] Philipp E. Scherer,[5] and Herbert B. Tanowitz[1,2]

[1] *Department of Pathology, Albert Einstein College of Medicine, 1300 Morris Park Avenue, Bronx, NY 10461, USA*
[2] *Department of Medicine, Albert Einstein College of Medicine, 1300 Morris Park Avenue, Bronx, NY 10461, USA*
[3] *Department of Physiology & Biophysics, Albert Einstein College of Medicine, 1300 Morris Park Avenue, Bronx, NY 10461, USA*
[4] *Department of Biochemistry and Immunology, Institute of Biological Sciences, Federal University of Minas Gerais, Pampula, Belo Horizonte 3127-901, Brazil*
[5] *Touchstone Diabetes Center, Departments of Internal Medicine and Cell Biology, University of Texas Southwestern, Dallas, TX 75390, USA*

Correspondence should be addressed to Herbert B. Tanowitz, tanowitz@aecom.yu.edu

Received 27 March 2009; Accepted 27 May 2009

Recommended by Louis M. Weiss

The contribution of adipose tissue an autocrine and endocrine organ in the pathogenesis of infectious disease and metabolic syndrome is gaining attention. Adipose tissue and adipocytes are one of the major targets of *T. cruzi* infection. Parasites are detected 300 days postinfection in adipose tissue. Infection of adipose tissue and cultured adipocytes triggered local expression of inflammatory mediators resulting in the upregulation of cytokine and chemokine levels. Adipose tissue obtained from infected mice display an increased infiltration of inflammatory cells. Adiponectin, an adipocyte specific protein, which exerts antiinflammatory effects, is reduced during the acute phase of infection. The antiinflammatory regulator peroxisome proliferator activated receptor-γ (PPAR-γ) is downregulated in infected cultured adipocytes and adipose tissue. *T. cruzi* infection is associated with an upregulation of signaling pathways such as MAPKs, Notch and cyclin D, and reduced caveolin-1 expression. Adiponectin null mice have a cardiomyopathy and thus we speculate that the *T. cruzi*-induced reduction in adiponectin contributes to the *T. cruzi*-induced cardiomyopathy. While *T. cruzi* infection causes hypoglycemia which correlates with mortality, hyperglycemia is associated with increased parasitemia and mortality. The *T. cruzi*-induced increase in macrophages in adipose tissue taken together with the reduction in adiponectin and the associated cardiomyopathy is reminiscent of the metabolic syndrome.

1. Introduction

Diseases caused by nematodes and protozoa have been reported to be associated with nutritional deficiencies, wasting, and diabetes. An association between human *Trypanosoma cruzi* infection (Chagas disease) and obesity and diabetes has been suspected.

Chagas disease is an important cause of morbidity and mortality in Latin America where 10% to 30% of infected individuals eventually succumb to the chronic manifestations such as cardiomyopathy and/or mega syndromes. This infection is also an opportunistic infection in those individuals who are immunosuppressed including those with HIV/AIDS. Although the pathogenesis of Chagas disease has been investigated by many laboratories the role of the adipocyte and of adipose tissue has been ignored.

2. The Adipocyte and Adipose Tissue: General Considerations

The contribution of the adipocyte or fat cell to the pathogenesis of diabetes, obesity and the metabolic syndrome is well recognized [1–5]. Adipose tissue is not a mere storage compartment for triglycerides. Adipocytes or fat cells are active endocrine cells that play an important

role in energy homeostasis and the immune system [6]. Adipocytes influence systemic lipid homeostasis through the production and release of adipocyte-specific and adipocyte-enriched hormonal factors, inflammatory mediators such as cytokines, chemokines, and extracellular matrix components also known as adipokines. The strong proinflammatory potential of adipose tissue suggests an important role in the systemic innate immune response.

Although the most prominent cell type in adipose tissue is the adipocyte, there are other cell types such as fibroblasts, endothelial cells, smooth muscle cells and inflammatory cells. Different adipose tissue depots display distinct gene expression patterns and vary widely in size and proximity to neighboring organs. Although differences exist between the different fat pads, the depots share similarity with respect to their ability to store lipids and secrete adipose tissue-derived hormones. Adipose tissue stores lipid in the form of triglycerides and also stores mostly nonesterified cholesterol on the surface of the lipid droplets that represent specialized organelles inside the adipocyte.

The potential endocrine function of adipose tissue was first appreciated with the report that the serine protease adipsin was secreted by the cultured 3T3-L1 adipocytes [7]. Subsequently, several additional adipokines have been discovered [8, 9]. These adipokines contribute to the regulation of energy homeostasis through effects on both central and peripheral tissues. Several of these adipokines also contribute to nonmetabolic processes in the body emphasizing the fact that adipokines participate in the coordination of multiple physiological functions in a variety of tissues. The most adipocyte-specific adipokine is adiponectin. Other adipokines can also be synthesized by tissues other than adipose tissue and/or by cells other than adipocytes.

Systemic energy homeostasis is maintained by competing effects of a number of different hormonal factors, some of which originate in adipose tissue. These adipocyte-derived factors (adipokines), influence processes such as food intake, energy expenditure and insulin sensitivity in a variety of tissues. Two adipokines, resistin and adiponectin have opposite effects on whole-body glucose homeostasis [1, 10]. Pharmacological doses of recombinant resistin hyperactivate gluconeogenesis through decreased hepatic insulin sensitivity.

Adiponectin, a hormone exclusively produced by the adipocytes, is a 30-kDa molecule with three defined domains. Both intracellular and extracellular adiponectin exists in three different higher order complexes: high molecular weight form (HMW; 12 to 36 mer), and low molecular weight form (hexamer and trimeric). The different complexes exert distinct functions, and the ratio of HMW to the other forms serves as an independent predicting factor for metabolic disorders. The total level and HMW ratio are decreased in obese patients and obese mouse models. This suggests that adiponectin, especially the HMW form, may be involved in obesity-related disorders. It has been demonstrated that adiponectin increases insulin sensitivity by inhibiting hepatic glucose output. Lower levels of circulating adiponectin are associated with increased susceptibility to a variety of diseases of metabolic dysfunction including diabetes, hypertension and obesity.

There is an association between circulating adiponectin levels and various metabolic parameters regulating insulin sensitivity in many different patient populations. For example, there is a decrease in plasma adiponectin concentration in obese humans [11]. Other studies showed that this finding could be extended to obese rodents and other animal models. The pattern of decreased adiponectin secretion with increasing adiposity has been well recognized. There is a reduction in the levels of adiponectin in diabetics with coronary artery disease compared with diabetics without coronary artery disease and the adiponectin levels in serum are negatively correlated with basal metabolic rate, plasma glucose and insulin and serum triglycerides [12]. Interestingly, even a relatively moderate weight loss led to a significant increase in circulating adiponectin levels in both diabetics and nondiabetics. In morbidly obese individuals [13] undergoing gastric partition surgery, a decrease in basic metabolic rate was noted and fasting glucose and insulin levels were associated with a similar increase in circulating levels of adiponectin together with an increase in insulin sensitivity.

Adiponectin expression and/or secretion may be directly or indirectly regulated by plasma insulin levels. Previous studies have demonstrated that insulin treatment of 3T3-L1 adipocytes results in significantly decreased adiponectin expression [14], and serum adiponectin levels are inversely proportional to fasting insulin levels. A corollary is that a feedback inhibitory pathway must exist that downregulates expression and secretion of adiponectin in obesity. Intra-abdominal and mesenteric fat pads (central fat pads) are predominant sources of systemic adiponectin in the lean state and the production of adiponectin in the obese state is reduced.

3. Adiponectin, Inflammation, and Heart Disease

Individuals with the highest levels of adiponectin had a reduced risk of myocardial infarction compared with those with the lowest adiponectin levels. Animal models have corroborated these observations, demonstrating the importance of adiponectin for preventing diet-induced progression of atherosclerosis. It should be noted, however, that the mechanism of the antiatherosclerotic activity of adiponectin has not been entirely elucidated. It has been hypothesized that adiponectin has inflammatory-modulating activities, and clinical studies have demonstrated an inverse relationship between adiponectin levels and serum markers of inflammation [15, 16]. It is reported that antiinflammatory effects on both endothelium and macrophages with the physiologically relevant full-length form exist [4, 9]. It is unclear whether adiponectin itself has antiinflammatory properties. However, adiponectin production by adipose tissue can be inhibited by systemic inflammation, at least under some circumstances.

Adiponectin production by adipocytes in culture is inhibited by inflammatory cytokines such as TNF-α [9, 17] and

this inhibition may be mediated in part by NFκB signaling. IκB Kinase inhibition leads to increased plasma adiponectin levels and an improvement in systemic insulin sensitivity [18]. The antiinflammatory activity of adiponectin may be mediated by its principal signaling target, the AMP-activated protein kinase (AMPK).

Chemokines positively control the secretion of leptin suggesting a role for chemokines in the regulation of adipose tissue and suggest a novel therapeutic basis for the treatment of obesity, diabetes and cachexia [19]. A high-fat diet increases the expression of inflammatory genes including early induction of MCP-1 and MCP-3 [20]. The antiatheromatous effects of adiponectin may be mediated by antiinflammatory activities acting directly on the vasculature. For example, Okamoto et al. [21] recently reported that adiponectin inhibits the production of CXCR-3 chemokine ligands in macrophages and causes a reduction in T-lymphocyte recruitment.

Adiponectin contributes toward protection against cardiac hypertrophy in cardiac overload states including hypertension, hypertrophic cardiomyopathy, and ischemic heart disease. In mice, adiponectin protects against myocardial ischemia-reperfusion injury and overload as well as adrenergically-induced cardiac myocyte hypertrophy, by inhibiting hypertrophic signals via AMPK [22–24]. Notably, adiponectin null mice have a cardiomyopathic phenotype [22, 25]. Thus, the current information is consistent with the idea that adiponectin is antiinflammatory and reduced levels of adiponectin are proinflammatory.

4. Adipose Tissue Adipocytes and Infection

The relationship between adipocytes and infectious agents has only recently received attention. For example, there have been investigations into the infectious etiologies of obesity [26]. A role for adipose tissue in infection was also underscored by the work of the Scherer laboratory who demonstrated that injection of LPS into mice that were rendered fatless by manipulation of the apoptosis pathway did not cause immediate death of mice as they did in control mice with a normal component of adipose tissue [27]. These observations suggested that the inflammatory mediators resulting from adipose tissue play an important role in the inflammatory response to infection. One of the most intensively investigated areas in the interface between infection and adipose tissue has been in HIV/AIDS [28–31].

5. Trypanosoma cruzi Infection

The relationship between blood sugar and *T. cruzi* infection has undergone limited investigation. Studies from our laboratory demonstrated that when mice with chemical-induced diabetes were infected with *T. cruzi*, they had a higher parasitemia and mortality and this was reversed by treatment with insulin [32]. *T. cruzi*-infected obese diabetic *db/db* mice also displayed a high parasitemia and increased mortality [32]. The underlying pathophysiological mechanisms of these observations remain unknown. Recently,we infected mice and observed hypoglycemia which generally correlated with mortality [33]. Interestingly, the metabolic response to bacterial sepsis is hyperglycemia, insulin resistance, profound negative nitrogen balance, and diversion of protein from skeletal muscle to splanchnic tissues. Thus, the response to *T. cruzi* infection differs from that generally observed in bacterial sepsis. It is possible that there is an effect on glucose metabolism due to invasion of the liver by the parasite. During acute infection, glucose levels in all the *T. cruzi*-infected mice were below the levels measured for the control mice. Even though the baseline glucose levels in the infected animals were lower, the oral glucose tolerance test indicated relatively normal ability to clear the ingested glucose despite the high degree of inflammation associated with this infection.

Infection of mice with *T. cruzi* results in hypoglycemia. This may be a result of increased uptake of glucose by the parasite [34]. Another explanation is an effect on glucose metabolism due to invasion of the liver by the parasite. The precise mechanism(s) for hypoglycemia during the acute *infection* is not known.

Adiponectin levels were significantly reduced during *T. cruzi* infection of several different strains of mice (see [10] and unpublished observations). Reduced levels of adiponectin are usually associated with insulin resistance, hyperglycemia, and obesity, that is, the metabolic syndrome. Decreased levels of adiponectin are observed in the setting of some types of inflammation and cardiovascular disease. Acute inflammation induced by endotoxemia does not affect adiponectin levels [18]. The infection-induced hypoglycemia cannot be readily explained by changes in adiponectin. Thus, this is an interesting example of a physiologically relevant condition that combines hypoglycemia and normal glucose tolerance with significantly reduced adiponectin levels. The decreased insulin levels observed during infection in the mouse model of *T. cruzi* infection are consistent with a physiological response to the very low glucose levels. Leptin levels were also significantly reduced in infected mice compared to controls [33]. Resistin levels, another fat cell-specific secretory factor with insulin-desensitizing properties, were not affected by infection [33]. Levels of plasminogen activator inhibitor-1, which is also prominently expressed in adipocytes, were completely unaffected by infection. Proinflammatory markers such as cytokines and chemokines were markedly elevated in the adipose tissue of acutely infected mice and persisted into the chronic phase.

Initially, the significant decrease in leptin levels was surprising since the infected mice gained more weight than the control mice. Magnetic resonance imaging studies as well as the body composition studies using an ECHO magnetic resonance spectrometry (MRS) body composition instrument revealed a decrease in abdominal adipose tissue. Mice that had marked right ventricular dilation had a greater loss of fat depots. The weight gain in infected mice appeared to be related to edema, which may have been the consequence of right-sided heart failure [33].

CD-1 and FVB mice infected with the Brazil strain of *T. cruzi* displayed a reduction in plasma levels of adiponectin suggesting that infection of adipocytes may also

have consequences on other proteins synthesized in adipose tissue. The level of adiponectin in adipose tissue was also reduced during acute infection in a number of fat pads known to be important sources of adiponectin. During acute infection, the acute-phase reactants α-1 acid glycoprotein and SAA3, which are expressed in adipocytes, were upregulated. Consistent with the infection-induced increase in inflammatory mediators (cytokines and chemokines) there was a concomitant reduction in adiponectin and peroxisome proliferator-activated receptor-γ (PPAR-γ). Both of these proteins are negative regulators of the inflammatory pathway.

We also demonstrated by qPCR that *T. cruzi* DNA in adipose tissue 300 days post infection was at the same levels as in the heart [33]. This observation suggests that the adipocyte may serve as an important target for *T. cruzi* and in chronic Chagas disease adipocytes may represent an important long-term reservoir for parasites from which relapse of infection can occur.

Next our laboratory performed in vitro studies to evaluate the role of the adipocyte in *T. cruzi* infection in a model system devoid of many other cell types ordinarily found in adipose tissue. We were not the first group to observe *T. cruzi* in adipocytes [35] but we were the first group to investigate this relationship in detail [33, 36]. Adipocytes infected for 96 hours maintain their integrity and intracellular amastigotes are observed as monitored by electron microscopy (Figure 1). *T. cruzi* infection of cultured adipocytes displays an inflammatory phenotype. For example, there was increased expression of chemokines such as CCL2, CCL3, CCL5, and CXCL10 and the cytokines TNF-α, IL-10, and interferon-γ. The expression of SAT3, an important downstream mediator of cytokine signaling, was increased as well. Toll-like receptors (TLRs) TLR-2 and -9 reported to be activated during *T. cruzi* infection of other cell types were also upregulated in adipocytes *T. cruzi* infection also activated ERK and p38 MAPK.

T. cruzi infection of cultured adipocytes resulted in increased expression of cyclin D1. Cyclin D1 is generally associated with cell proliferation but cultured adipocytes are usually terminally differentiated. The increased expression of cyclin D1 is important because it is upregulated by ERK and inversely regulated by caveolin-1 [37]. In infected cultured adipocytes, we demonstrated that infection resulted in a reduction in the expression of caveolin-1 and activation of ERK; both of these events increase the expression of cyclin D1. The reduction in caveolin-1 expression has also been demonstrated to be associated with an increased proinflammatory cytokine response [38, 39]. Interestingly, infection activates the Notch pathway which regulates the expression of cyclin D1 [40].

PPAR-γ is expressed in adipose tissue and similar to adiponectin is antiinflammatory [41, 42]. As noted, the reduction in the level of adiponectin is associated with an increase in inflammation [9]. In addition, there is an inverse relationship between PPAR-γ and inflammation as well as between PPAR-γ and cyclin D1 [43]. It has been demonstrated that increased expression of cyclin D1 is associated with a reduction in PPAR-γ. Recent evidence suggests a similar relationship between adiponectin and PPAR-γ [41, 42]. Our observations clearly demonstrated that *T. cruzi* infection resulted in a reduction in the expression of adiponectin and PPAR-γ and an increase in the expression of cyclin D1 and inflammatory mediators.

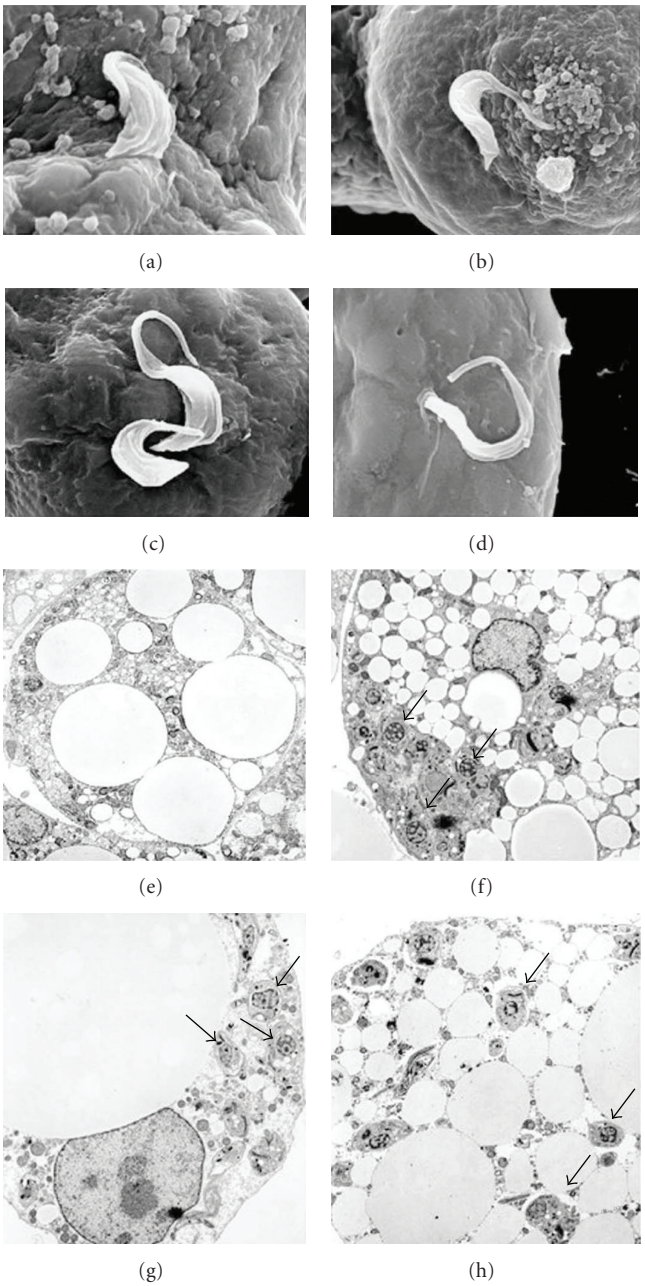

Figure 1: (a)–(d) Scanning electron micrograph of trypomastigotes of *T. cruzi* invading adipocyte. (e) A transmission electron micrograph of an uninfected adipocyte. (f)–(h) Electron micrographs of infected adipocytes. The parasites (arrows) are in close proximity to the lipid droplets (with permission of the Journal of Biological Chemistry).

Infection also results in increased expression of PI-3 kinase and activation of AKT, suggesting that this infection may induce components of the insulin/IGF-1 receptor

cascade. The upregulation of proinflammatory pathways is generally associated with a downregulation of the insulin signal transduction pathway [44, 45]. It is not clear what is responsible for this phenomenon, but it can be observed with a high degree of reproducibility in these cells. *T. cruzi* invasion is facilitated through the activation of host cell PI-3 kinases in mammalian cells [46]. Human Schwann cells infected with *T. cruzi* suppressed host-cell apoptosis through trans sialidase activity via the PI3k/AKT pathway, suggesting a role for PI3K/AKT in the pathogenesis of Chagas disease [47]. Despite the upregulation of some of the components of the pathway, there were no differences with respect to a dose response to insulin in infected cells (unpublished observations). It remains to be determined whether other pathways influenced by insulin may be affected, such as events leading to differences in the rate of lipid accumulation or lipolysis. *T. cruzi* is likely to have an impact on lipid pathways in vivo, yet these issues have not been examined to date.

Our findings are significant since there is a positive correlation between inflammation and insulin resistance. However, the infection of adipocytes with a parasite that resides intracellularly is different from exposing adipocytes to conventional proinflammatory stimuli such as endotoxin. The continued intracellular presence of the parasites clearly has a differential effect on insulin sensitivity, perhaps by lowering the levels of one of the critical lipid mediators of insulin resistance.

Fat and glucose metabolism are interrelated and dysregulated in *T. cruzi* infection. Adipocytes and adipose tissue represent an important target of and reservoir for infection. This is a reservoir from which parasites can be reactivated during periods of immunosuppression. In addition, infection of the adipocyte and adipose tissue creates an inflammatory phenotype that affects a variety of metabolic processes. Furthermore, the reduction in the expression of adiponectin and persistent inflammation and PPAR-γ perpetuate the inflammatory phenotype. Since adiponectin null mice have a cardiomyopathic phenotype it is tempting to suggest that the reduction in adiponectin and PPAR-γ contributes to the cardiomyopathy of Chagas disease.

Acknowledgment

This work was supported in part by NIH Grants HL-73732, AI-076248 and 06538 and AI-052739 (HBT), R01-DK55758 (PES) and R01-CA112023 (PES) and P60DK020541 (SC).

References

[1] M. W. Rajala, S. Obici, P. E. Scherer, and L. Rossetti, "Adipose-derived resistin and gut-derived resistin-like molecule-β selectively impair insulin action on glucose production," *Journal of Clinical Investigation*, vol. 111, no. 2, pp. 225–230, 2003.

[2] M. W. Rajala and P. E. Scherer, "Minireview: the adipocyte—at the crossroads of energy homeostasis, inflammation, and atherosclerosis," *Endocrinology*, vol. 144, no. 9, pp. 3765–3773, 2003.

[3] I. W. Asterholm, N. Halberg, and P. E. Scherer, "Mouse models of lipodystrophy: key reagents for the understanding of the metabolic syndrome," *Drug Discovery Today: Disease Models*, vol. 4, no. 1, pp. 17–24, 2007.

[4] A. R. Nawrocki and P. E. Scherer, "Keynote review: the adipocyte as a drug discovery target," *Drug Discovery Today*, vol. 10, no. 18, pp. 1219–1230, 2005.

[5] A. D. Attie and P. E. Scherer, "Adipocyte metabolism and obesity," *Journal of Lipid Research*, vol. 50, supplement, pp. S395–S399, 2009.

[6] N. Halberg, I. Wernstedt-Asterholm, and P. E. Scherer, "The adipocyte as an endocrine cell," *Endocrinology and Metabolism Clinics of North America*, vol. 37, no. 3, pp. 753–768, 2008.

[7] K. S. Cook, H. Y. Min, D. Johnson, et al., "Adipsin: a circulating serine protease homolog secreted by adipose tissue and sciatic nerve," *Science*, vol. 237, no. 4813, pp. 402–405, 1987.

[8] P. E. Scherer, S. Williams, M. Fogliano, G. Baldini, and H. F. Lodish, "A novel serum protein similar to C1q, produced exclusively in adipocytes," *The Journal of Biological Chemistry*, vol. 270, no. 45, pp. 26746–26749, 1995.

[9] M. S. Desruisseaux, Nagajyothi, M. E. Trujillo, H. B. Tanowitz, and P. E. Scherer, "Adipocyte, adipose tissue, and infectious disease," *Infection and Immunity*, vol. 75, no. 3, pp. 1066–1078, 2007.

[10] T. P. Combs, A. H. Berg, S. Obici, P. E. Scherer, and L. Rossetti, "Endogenous glucose production is inhibited by the adipose-derived protein Acrp30," *Journal of Clinical Investigation*, vol. 108, no. 12, pp. 1875–1881, 2001.

[11] Y. Arita, S. Kihara, N. Ouchi, et al., "Paradoxical decrease of an adipose-specific protein, adiponectin, in obesity," *Biochemical and Biophysical Research Communications*, vol. 257, no. 1, pp. 79–83, 1999.

[12] K. Hotta, T. Funahashi, Y. Arita, et al., "Plasma concentrations of a novel, adipose-specific protein, adiponectin, in type 2 diabetic patients," *Arteriosclerosis, Thrombosis, and Vascular Biology*, vol. 20, no. 6, pp. 1595–1599, 2000.

[13] W.-S. Yang, W.-J. Lee, T. Funahashi, et al., "Weight reduction increases plasma levels of an adipose-derived anti-inflammatory protein, adiponectin," *Journal of Clinical Endocrinology and Metabolism*, vol. 86, no. 8, pp. 3815–3819, 2001.

[14] M. Fasshauer, J. Klein, S. Neumann, M. Eszlinger, and R. Paschke, "Hormonal regulation of adiponectin gene expression in 3T3-L1 adipocytes," *Biochemical and Biophysical Research Communications*, vol. 290, no. 3, pp. 1084–1089, 2002.

[15] B. J. Goldstein and R. Scalia, "Adiponectin: a novel adipokine linking adipocytes and vascular function," *Journal of Clinical Endocrinology and Metabolism*, vol. 89, no. 6, pp. 2563–2568, 2004.

[16] N. Ouchi, S. Kihara, T. Funahashi, Y. Matsuzawa, and K. Walsh, "Obesity, adiponectin and vascular inflammatory disease," *Current Opinion in Lipidology*, vol. 14, no. 6, pp. 561–566, 2003.

[17] H. Ruan and H. F. Lodish, "Insulin resistance in adipose tissue: direct and indirect effects of tumor necrosis factor-α," *Cytokine and Growth Factor Reviews*, vol. 14, pp. 447–455, 2003.

[18] P. Keller, K. Moller, K. S. Krabbe, and B. K. Pedersen, "Circulating adiponectin levels during human endotoxaemia," *Clinical and Experimental Immunology*, vol. 134, no. 1, pp. 107–110, 2003.

[19] C. C. Gerhardt, I. A. Romero, R. Cancello, L. Camoin, and A. D. Strosberg, "Chemokines control fat accumulation and

leptin secretion by cultured human adipocytes," *Molecular and Cellular Endocrinology*, vol. 175, no. 1-2, pp. 81–92, 2001.

[20] A. Chen, S. Mumick, C. Zhang, et al., "Diet induction of monocyte chemoattractant protein-1 and its impact on obesity," *Obesity Research*, vol. 13, no. 8, pp. 1311–1320, 2005.

[21] Y. Okamoto, E. J. Folco, M. Minami, et al., "Adiponectin inhibits the production of CXC receptor 3 chemokine ligands in macrophages and reduces T-lymphocyte recruitment in atherogenesis," *Circulation Research*, vol. 102, no. 2, pp. 218–225, 2008.

[22] N. Ouchi, R. Shibata, and K. Walsh, "Cardioprotection by Adiponectin," *Trends in Cardiovascular Medicine*, vol. 16, no. 5, pp. 141–146, 2006.

[23] R. Shibata, N. Ouchi, M. Ito, et al., "Adiponectin-mediated modulation of hypertrophic signals in the heart," *Nature Medicine*, vol. 10, no. 12, pp. 1384–1389, 2004.

[24] R. Shibata, K. Sato, D. R. Pimentel, et al., "Adiponectin protects against myocardial ischemia-reperfusion injury through AMPK- and COX-2-dependent mechanisms," *Nature Medicine*, vol. 11, no. 10, pp. 1096–1103, 2005.

[25] R. Shibata, N. Ouchi, and T. Murohara, "Adiponectin and cardiovascular disease," *Circulation Journal*, vol. 73, no. 4, pp. 608–614, 2009.

[26] M. Pasarica and N. V. Dhurandhar, "Infectobesity: obesity of infectious origin," *Advances in Food and Nutrition Research*, vol. 52, pp. 61–102, 2007.

[27] U. B. Pajvani, M. E. Trujillo, T. P. Combs, et al., "Fat apoptosis through targeted activation of caspase 8: a new mouse model of inducible and reversible lipoatrophy," *Nature Medicine*, vol. 11, no. 7, pp. 797–803, 2005.

[28] U. Hazan, I. A. Romero, R. Cancello, et al., "Human adipose cells express CD4, CXCR4, and CCR5 [corrected] receptors: a new target cell type for the immunodeficiency virus-1?" *The FASEB Journal*, vol. 16, no. 10, pp. 1254–1256, 2002.

[29] P. W. G. Mallon, R. Sedwell, G. Rogers, et al., "Effect of rosiglitazone on peroxisome proliferator-activated receptor γ gene expression in human adipose tissue is limited by antiretroviral drug-induced mitochondrial dysfunction," *Journal of Infectious Diseases*, vol. 198, no. 12, pp. 1794–1803, 2008.

[30] T. Maurin, C. Saillan-Barreau, B. Cousin, L. Casteilla, A. Doglio, and L. Pénicaud, "Tumor necrosis factor-α stimulates HIV-1 production in primary culture of human adipocytes," *Experimental Cell Research*, vol. 304, no. 2, pp. 544–551, 2005.

[31] D. C. Mynarcik, T. Combs, M. A. McNurlan, P. E. Scherer, E. Komaroff, and M. C. Gelato, "Adiponectin and leptin levels in HIV-infected subjects with insulin resistance and body fat redistribution," *Journal of Acquired Immune Deficiency Syndromes*, vol. 31, no. 5, pp. 514–520, 2002.

[32] H. B. Tanowitz, B. Amole, D. Hewlett, and M. Wittner, "Trypanosoma cruzi infection in diabetic mice," *Transactions of the Royal Society of Tropical Medicine and Hygiene*, vol. 82, no. 1, pp. 90–93, 1988.

[33] T. P. Combs, Nagajyothi, S. Mukherjee, et al., "The adipocyte as an important target cell for Trypanosoma cruzi infection," *The Journal of Biological Chemistry*, vol. 280, no. 25, pp. 24085–24094, 2005.

[34] J. J. B. Cannata and J. J. Cazzulo, "The aerobic fermentation of glucose by Trypanosoma cruzi," *Comparative Biochemistry and Physiology Part B*, vol. 79, no. 3, pp. 297–308, 1984.

[35] Z. A. Andrade and H. R. Silva, "Parasitism of adipocytes by Trypanosoma cruzi," *Memórias do Instituto Oswaldo Cruz*, vol. 90, no. 4, pp. 521–522, 1995.

[36] F. Nagajyothi, M. S. Desruisseaux, N. Thiruvur, et al., "Trypanosoma cruzi Infection of cultured adipocytes results in an inflammatory phenotype," *Obesity*, vol. 16, no. 9, pp. 1992–1997, 2008.

[37] J. Hulit, T. Bash, M. Fu, et al., "The cyclin D1 gene is transcriptionally repressed by caveolin-1," *The Journal of Biological Chemistry*, vol. 275, no. 28, pp. 21203–21209, 2000.

[38] A. W. Cohen, D. S. Park, S. E. Woodman, et al., "Caveolin-1 null mice develop cardiac hypertrophy with hyperactivation of p42/44 MAP kinase in cardiac fibroblasts," *American Journal of Physiology*, vol. 284, no. 2, pp. C457–C474, 2003.

[39] A. W. Cohen, R. Hnasko, W. Schubert, and M. P. Lisanti, "Role of caveolae and caveolins in health and disease," *Physiological Reviews*, vol. 84, no. 4, pp. 1341–1379, 2004.

[40] M. Stahl, C. Ge, S. Shi, R. G. Pestell, and P. Stanley, "Notch1-induced transformation of RKE-1 cells requires up-regulation of cyclin D1," *Cancer Research*, vol. 66, no. 15, pp. 7562–7570, 2006.

[41] J.-Y. Kim, E. van de Wall, M. Laplante, et al., "Obesity-associated improvements in metabolic profile through expansion of adipose tissue," *The Journal of Clinical Investigation*, vol. 117, no. 9, pp. 2621–2637, 2007.

[42] A. R. Nawrocki, M. W. Rajala, E. Tomas, et al., "Mice lacking adiponectin show decreased hepatic insulin sensitivity and reduced responsiveness to peroxisome proliferator-activated receptor γ agonists," *The Journal of Biological Chemistry*, vol. 281, no. 5, pp. 2654–2660, 2006.

[43] A. W. Ferrante Jr., "Obesity-induced inflammation: a metabolic dialogue in the language of inflammation," *Journal of Internal Medicine*, vol. 262, no. 4, pp. 408–414, 2007.

[44] C. Wang, N. Pattabiraman, J. N. Zhou, et al., "Cyclin D1 repression of peroxisome proliferator-activated receptor γ expression and transactivation," *Molecular and Cellular Biology*, vol. 23, no. 17, pp. 6159–6173, 2003.

[45] G. S. Hotamisligil, "Inflammation and metabolic disorders," *Nature*, vol. 444, no. 7121, pp. 860–867, 2006.

[46] A. M. Woolsey, L. Sunwoo, C. A. Petersen, S. M. Brachmann, L. C. Cantley, and B. A. Burleigh, "Novel Pl 3-kinase-dependent mechanisms of trypanosome invasion and vacuole maturation," *Journal of Cell Science*, vol. 116, no. 17, pp. 3611–3622, 2003.

[47] M. V. Chuenkova, F. B. Furnari, W. K. Cavenee, and M. A. Pereira, "Trypanosoma cruzi trans-sialidase: a potent and specific survival factor for human Schwann cells by means of phosphatidylinositol 3-kinase/Akt signaling," *Proceedings of the National Academy of Sciences of the United States of America*, vol. 98, no. 17, pp. 9936–9941, 2001.

Hindawi Publishing Corporation
Interdisciplinary Perspectives on Infectious Diseases
Volume 2009, Article ID 190354, 8 pages
doi:10.1155/2009/190354

Review Article

Oxidative Stress in Chagas Disease

Shivali Gupta,[1] Jian-Jun Wen,[1] and Nisha Jain Garg[1,2,3,4]

[1] *Department of Microbiology and Immunology, University of Texas Medical Branch, Galveston, TX 77555, USA*
[2] *Department of Pathology, University of Texas Medical Branch, Galveston, TX 77555, USA*
[3] *Sealy Center for Vaccine Development, Institute for Human Infections and Immunity, University of Texas Medical Branch, Galveston, TX 77555, USA*
[4] *3.142C Medical Research Building, University of Texas Medical Branch, 301 University Boulevard, Galveston, TX 77555-1070, USA*

Correspondence should be addressed to Nisha Jain Garg, nigarg@utmb.edu

Received 19 March 2009; Accepted 23 April 2009

Recommended by Herbert B. Tanowitz

There is growing evidence to suggest that chagasic myocardia are exposed to sustained oxidative stress induced injuries that may contribute to disease progression. Trypanosoma cruzi invasion- and replication-mediated cellular injuries and immune-mediated cytotoxic reactions are the common source of reactive oxygen species (ROS) during acute infection. Mitochondria are proposed to be the major source of ROS in chronic chagasic hearts. However, it has not been established yet, whether mitochondrial dysfunction is a causative factor in chagasic cardiomyopathy or a consequence of other pathological events. A better understanding of oxidative stress in relation to cardiac tissue damage would be useful in the evaluation of its true role in the pathogenesis of Chagas disease and other heart diseases. In this review, we discuss the evidence for increased oxidative stress in chagasic disease, with emphasis on mitochondrial abnormalities, and its role in sustaining oxidative stress in myocardium.

1. Chagas Disease

Chagas disease continues to pose a serious threat to health in Latin America and Mexico, and is the most important emerging parasitic disease in developed countries. According to the World Health Organization, the overall prevalence of human *Trypanosoma cruzi* infection is at ∼16–18 million cases, and ∼120 million people are at risk of infection in Latin America [1]. In most patients, the early period of *T. cruzi* infection goes virtually unnoticed whereas others develop an acute phase that lasts several weeks and is accompanied by such nonspecific symptoms, fever, tachycardia, weakness, and lymphadenopathy [2, 3]. After acute control of *T. cruzi*, infected patients enter an indeterminate phase, defined by the absence of clinical symptoms although subclinical pathology may be present. Unfortunately, 15–30 years after the initial infection, 30–40% of the infected patients develop life threatening dilated cardiomyopathy associated with clinical symptoms of ventricular dilation, arrhythmia, and cardiac arrest [4]. The pathological developments and clinical symptoms vary widely among chagasic patients [2, 5–7]. Not every individual infected with *T. cruzi* experiences the abnormalities characteristic of the three phases of Chagas disease: acute, indeterminate, and chronic. These facts make Chagas disease a complex disease and difficult to understand.

Over the years, a number of mechanisms have been proposed to explain the pathogenesis of Chagas disease (reviewed in [8, 9]). There is growing evidence to suggest that chagasic myocardia are exposed to sustained oxidative stress-induced injuries that may contribute to disease progression. In this review, we discuss the evidence for increased oxidative stress in chagasic disease, with emphasis on mitochondrial abnormalities, as well as electron transport chain dysfunction, and its role in sustaining oxidative stress in myocardium.

2. Sources of Oxidants

2.1. Overview. Broadly defined, reactive oxygen species (ROS, e.g., $O_2^{\bullet -}$, $^{\bullet}OH$, and H_2O_2) are derivatives of molecular oxygen. ROS are unstable and react rapidly with other free radicals and macromolecules in chain reactions to generate increasingly harmful oxidants. ROS are produced

through the action of specific oxidases and oxygenases (e.g., xanthine oxidase, and NADPH oxidase), peroxidases (e.g., myeloperoxidase), the Fenton reaction, and are also by-products of the electron transport chain of mitochondria [10]. Nitric oxide ($^{\bullet}$NO) is produced by the enzymatic activity of nitric oxide synthases (NOS), which oxidize L-arginine, transferring electrons from NADPH. Different NOS isoforms have been identified, for example, inducible NOS (iNOS) in phagocytic cells, mtNOS in mitochondria, (eNOS) in endothelial cells, and neuronal nNOS [11].

2.2. ROS in Chagasic Hosts. During the course of *T. cruzi* infection and disease development, ROS can be produced as a consequence of tissue destruction caused by toxic secretions of parasite, immune-mediated cytotoxic reactions, and secondary damage to mitochondria.

In experimental studies, *T. cruzi* infection has been suggested to initiate ROS formation via the stimulation of inflammatory mediators, for example, cytokines and chemokines, which lead to an oxidative burst of phagocytic cells. Several investigators have used in vitro assay systems or animal models and demonstrated that *T. cruzi*-mediated macrophage activation results in increased levels of $O_2^{\bullet-}$ formation, likely by the NADPH oxidase-dependent oxidative burst [12–14]. In addition to ROS, activated macrophages can produce large amounts of $^{\bullet}$NO by iNOS. Accordingly, TNF-α- and IFN-γ-dependent increased iNOS expression and $^{\bullet}$NO production is noted in splenocytes of *T. cruzi*-infected mice [15] and in macrophages infected in vitro with *T. cruzi* [16]. We have found increased levels of myeloperoxidase and nitrite in the plasma of *T. cruzi*-infected mice [17] that are markers of neutrophil and macrophage activation, respectively. Relatively few studies have been performed to elucidate inflammatory oxidative stress in human patients. In humans, the severity of cardiac disease was correlated with high plasma levels of TNF-α and $^{\bullet}$NO [18]. The $^{\bullet}$NO level was also increased in indeterminate individuals in comparison to healthy controls [19]. These reactive oxidants are important for the control of *T. cruzi*, and may elicit toxicity to host cellular components.

Recent studies provide evidence for enhanced mitochondrial ROS generation (H_2O_2 and $O_2^{\bullet-}$) in chagasic myocardium. Mitochondria are the prime source of energy and many of the body's functions, including those of cardiac metabolic and contractile activities, require mitochondrial generation of ATP. Electron microscopic analysis of heart biopsies from chagasic patients and experimental animals have shown that with disease development, mitochondrial degenerative changes, that is, swelling, irregular membranes, and loss of cristae, accrue in the heart with disease development [20–23]. Global microarray profiling of gene expression has identified alterations in several of the mitochondrial function related transcripts in the myocardium of infected humans [24] and experimental animals [25, 26]. The biochemical evidence for the mitochondrial dysfunction was provided by documentation of a decline in the activities of respiratory complexes, NADH-ubiquinone reductase (CI) and ubiquinol-cytochrome c reductase (CIII) [27] and ATP synthase (CV) complex [28] in chagasic murine hearts. The functional effect of these perturbations was shown by decreased mitochondrial respiration [29], and reduction in myocardial and mitochondrial ATP levels [30] in chagasic experimental models.

Imperatively, mitochondrial dysfunction also contributes to increased oxidative stress. A low, but constant, production of superoxide $O_2^{\bullet-}$ occurs in mitochondria. The rate of electron leakage and $O_2^{\bullet-}$ formation in mitochondria is closely related to the coupling efficiency between the respiratory chain and oxidative phosphorylation [31]. The CI and CIII complexes are the main sites for electron leakage to O_2 and $O_2^{\bullet-}$ generation in mitochondria [32, 33]. We have shown a decline in complex I and complex III activities in the myocardium was associated with excessive leakage of electrons to molecular oxygen and sustained ROS production in chagasic mice [27]. Further studies identified that CI was not the main source of increased ROS in chagasic hearts. Instead, defects of the myxothiazol-binding site in CIII complex resulted in enhanced electron leakage towards the Q_o-center, and contributed to increased ROS generation in chagasic cardiac mitochondria [34]. Thus, conditions conducive to oxidative stress are presented in the Chagasic heart.

3. Antioxidants

3.1. Overview. The overall level of cellular ROS and its biological effects are determined by the relative rates of ROS generation and the rate of reduction by antioxidants. The principal enzymatic antioxidants are superoxide dismutase (SOD), catalase (CAT), peroxiredoxin (Prx), and glutathione peroxidase (GPx). These enzymes work in tandem to scavenge ROS. SOD exists in different isoforms, for example, manganese SOD (MnSOD) in the mitochondrial matrix and Cu- or Zn-SOD in the cytoplasm, mitochondria intermembrane space, and endothelial cell surface [35]. SOD converts $O_2^{\bullet-}$ to H_2O_2 [36]. CAT, located in peroxisomes, converts H_2O_2 to H_2O and O_2 [37]. Prx reduces peroxides, including H_2O_2 and alkyl hydroperoxides [38]. The five isoforms of GPx utilize glutathione (GSH), and reduce H_2O_2 or lipid peroxides (ROOH) to H_2O or alcohols (ROH), respectively. The byproduct of this reaction, GSSG is recycled by glutathione S reductase [38]. The nonenzymatic antioxidants, for example, vitamin E (α-tocopherol) and vitamin C (ascorbate), are abundant in aerobic organisms. Vitamin E, active in membranes, functions to reduce peroxy radicals. Vitamin C, a highly soluble antioxidant in plasma, functions by reducing α-tocopherol-lipid peroxide radicals, particularly formed in reaction with the low-density lipoproteins (LDL) [37].

3.2. Antioxidant Status in Chagasic Host. The myocardium contains high concentrations of various nonenzymatic antioxidants such as reduced glutathione (GSH) and vitamins A, C, and E, and enzymatic scavengers of ROS, including GPx and Mn- and CuZn-SOD. GSH, GPx, and MnSOD are shown to be most critical in cardiac antioxidant

defenses, particularly in protecting the cardiomyocytes from oxidative injury [39, 40]. We and others have evaluated the antioxidant/oxidant balance in experimental models of chagasic disease and human patients. Our experimental studies showed that the host responds to acute *T. cruzi* infection by upregulating glutathione antioxidant defense constituted by GPx, GSR, and GSH. However, after the initial burst, the glutathione defense was unresponsive to chronic oxidative stress, and the cardiac levels of GSH and MnSOD were significantly diminished in chagasic mice [41]. A decline in plasma levels of GSH, the GSH/GSSG ratio [42, 43], and GPx activity [18], along with decreased MnSOD activity in PBMCs of seropositive chagasic patients [42, 43] is also noted. Decreased antioxidant levels (GPx and SOD) were correlated with an increase in TNF-α and $^{\bullet}$NO levels in human patients [18]. All of these observations suggest an antioxidant response is not sufficiently activated to scavenge the ROS during progressive chagasic disease.

4. Cytotoxicity of Oxidative Stress

4.1. Overview. ROS and $^{\bullet}$NO, when produced in physiological quantities, play critical roles in normal developmental processes, and control signal transduction mechanisms that regulate cell proliferation, differentiation, and death [44, 45]. However, when ROS are produced in excess or for sustained periods, they may exert toxic effects that damage cells and tissues, thereby resulting in dysfunction of physiological processes. ROS can rapidly oxidize proteins, lipids, and DNA. Lipid peroxidation causes damage to membrane integrity and loss of membrane protein function. Specifically, 4-hydroxynonenal (HNE) and malonyldialdehyde (MDA) are products of the peroxidation of membrane phospholipids [46–48]. These oxidized lipids are also toxic because they are highly reactive species that result in oxidative modification of proteins [37]. For example, HNE reacts with Cys, His, or Lys residues via a Michael addition that results in irreversible alkylation and introduction of carbonyl groups into proteins [49]. The direct oxidative attack by ROS on Arg, Lys, Pro, and Thr residues can also derivatize the proteins and lead to the formation of protein carbonyls [50, 51]. $^{\bullet}$NO reacts with $O_2^{\bullet -}$, to form peroxynitrite ($ONOO^-$). Myeloperoxidase-dependent oxidation of nitrite (NO_2^-) results in formation of nitrogen dioxide (NO_2) and nitryl chloride (NO_2Cl). These reactive nitrogen species (RNS) result in protein tyrosine nitration that is widely recognized as a hallmark of nitrosative stress and inflammation [52]. Because of oxidation or nitration, a functional impairment of proteins occurs, and furthermore leads to protein turnover, for example, degradation by proteases via the proteosome [53]. DNA can be oxidized by a variety of mechanisms, resulting in nucleotide damage, for example, formation of 8-oxoguanine lesions. As a result, DNA replication may be inaccurate leading to mutations and transcription errors. While mechanisms exist to repair these DNA lesions, the level of DNA damage may exceed the capacity of the cellular repair mechanisms. Furthermore, mtDNA is believed to be particularly susceptible to sustained damage, since mitochondria may lack appropriate DNA repair mechanisms [54].

4.2. Oxidative Damage in Chagas Disease. Oxidative stress-induced injuries are a common finding in chagasic myocardium. *T. cruzi* has the potential to infect a wide range of host tissues [55]. As discussed above, the inflammatory infiltrate in acutely infected host is mainly constituted of phagocytic cells (e.g., macrophages) and neutrophils that produce ROS/RNS through oxidative burst [56], iNOS-dependent $^{\bullet}$NO release [15], and myeloperoxidase-dependent HOCl production [57]. Oxidative damage is a consequence of the extent of oxidative stress and the antioxidant capacity. A *T. cruzi*-infected host does respond to inflammatory oxidative stress by an upregulation of antioxidant response constituted of GPx, GSH, and GST [41]. Yet, oxidative cellular damage, evidenced by increased protein carbonyls, MDA, and GSSG levels, is widespread, and associated with the presence of parasite foci and inflammatory infiltrate in the heart, as well as in other muscle tissues in acutely infected mice [58]. The acute oxidative damage, thus, appears to be a bystander effect of inflammatory responses elicited by *T. cruzi*, and occurs in all muscle tissues.

The immune control of acute parasitemia fails to provide sterile immunity. The evolution of a chronic phase is associated with mild-to-moderate diffused inflammation in different tissues and organs. It would be an oversimplification to suggest that cardiac pathology is merely an outcome of infection and inflammation, or parasite persistence that is sufficient to drive an ongoing host immune response targeted against *T. cruzi*. An unvarying high degree of oxidative damage persists mainly in the myocardium of chronically infected mice, as evidenced by high levels of MDA, protein carbonyl, and GSSG contents in the heart compared to findings in the skeletal muscle and colon tissue [58]. We propose the persistent activation of oxidative injurious processes plays an important role in heart-specific tissue damage in Chagas disease.

Several observations led us to consider that ROS in chronic chagasic heart are primarily produced by dysfunctional mitochondria. It is well known that ROS are generated at several subcellular sites [59] and particularly in mitochondria [60]. In effect, ~2% of the O_2 consumed by mitochondria is converted to $O_2^{\bullet -}$ due to spontaneous electron leaks from the respiratory chain [61]. Activated skeletal and intestinal muscles intermittently require mitochondria as an energy source, while cardiomyocytes are constantly dependent upon mitochondrial functions for their energy requirement for maintaining the contractile and other metabolic activities. According to energy demand, a ~30% cell volume of cardiomyocytes is provided by mitochondria, while in other tissues mitochondria constitute only 3–6% of cell volume [62]. Thus, maximal O_2 consumption, as would be expected based upon the number of mitochondria in the heart, would produce substantial $O_2^{\bullet -}$ in the heart through electron leakage from the respiratory chain. Thus, it can be inferred that even in normal conditions, heart tissue is maximally exposed to ROS of mitochondrial origin. Besides

this, inefficient functioning of the respiratory complexes, as documented in chagasic hearts [27], would result in an inadequate coupling of the respiratory chain with oxidative phosphorylation and an excessive release of electrons to molecular oxygen, leading to an increased mitochondrial ROS production. We have recently found that the rate of mitochondrial $O_2^{\bullet-}$ generation was substantially increased in cardiac tissue of infected mice [34], and associated with the oxidation of several subunits of the respiratory complexes [41]. The active-site thiol and heme proteins within respiratory complexes are particularly vulnerable to ROS [63]. The oxidative modification/degradation of heme proteins of the complexes release iron, the catalyst of the Fenton reaction, resulting in the formation/release of $^{\bullet}$OH radicals [64–66]. Taken together, these observations suggest that, under disease conditions, mitochondria are vulnerable to oxidative stress, as well as to becoming the site of an increasing order of ROS production. We, thus, propose that the acute inflammatory oxidative stress-induced mitochondrial injuries initiate a feedback cycle of ROS production and oxidative overload that causes sustained oxidative damage in the myocardium. A compromise in mitochondrial antioxidant enzyme activity (MnSOD) in chagasic myocardium would further exacerbate the mitochondrial ROS toxicity. The foregoing studies have pointed to the pathologic significance of oxidative responses in Chagasic cardiomyopathy.

It is important to note that a high degree of oxidative stress is detected in the peripheral blood of chagasic mice [58]. The demonstration of a strong positive correlation in the heart-versus-blood levels of oxidative stress markers (MDA and GSSG), and antioxidants (SOD, MnSOD, and catalase), and the mitochondrial inhibition of respiratory complexes in chronically infected mice have made it apparent that peripheral blood will be useful for understanding the role of mitochondrial decay and oxidative stress in the initiation and progression of human chagasic disease.

Subsequently, observations of increased plasma levels of GSSG and MDA and a decline in GPx activity in seropositive humans [18, 42] have led to the suggestion that chagasic patients are indeed exposed to an antioxidant/oxidant imbalance. As in experimental studies, multiple mechanisms are likely to contribute to increased oxidative stress-induced damage in chagasic patients. Plasma levels of inflammatory cytokines, $^{\bullet}$NO [18] and myeloperoxidase activity [17] are increased in seropositive subjects which seems to imply that the cytotoxic effects of free radicals released by immune cells would contribute to oxidative pathology in chagasic patients. The increase in plasma MDA levels in chagasic patients may also be due to oxidatively modified lipids released as a consequence of cellular injuries, most likely, that are incurred in the cardiac tissue. This notion is supported by the observation of intense myocardial oxidative modifications [41] associated with the detection of oxidatively modified lipids and proteins in the serum [58] of mice infected by *T. cruzi*. Additionally, SOD and glutathione (GPx-GSH-GR) antioxidant defenses, utilized by mammalian cells to cope with free radicals [67], are found to be compromised in chagasic patients [18, 42]. These observations support the idea that glutathione antioxidant defenses, despite being active, may only be partially effective in balancing the oxidant level in chagasic patients.

5. Antioxidant Adjunct Therapy

Interventions that reduce the generation or the effects of ROS may exert beneficial effects in preventing or arresting oxidative damage. Several therapeutic interventions, for example, a vitamin E-like antioxidant, an SOD mimetic [68, 69], and an $ONOO^-$ decomposition catalyst [70] have been examined for their beneficial effects against ROS in different systems. Phenyl-*N*-*tert*-butylnitrone (PBN), a nitrone-based compound, is a potent antioxidant. PBN has been shown to trap or scavenge a wide variety of free radical species, including biologically relevant $O_2^{\bullet-}$ and hydroxyl $^{\bullet}$OH radicals; to increase endogenous antioxidant levels; and to inhibit free radical generation [71]. In addition, PBN has been shown to inhibit the expression of a variety of inflammation-associated gene products [72].

In a recent study, we have shown that PBN treatment of infected mice prevented an oxidative stress-mediated loss in mitochondrial membrane integrity; preserved redox potential coupled with mitochondrial gene expression, and improved respiratory complex activities in infected myocardium [30]. Importantly, the PBN-mediated normalization of respiratory complex activities led to the inhibition of a feedback cycle of electron transport chain inefficiency, increased ROS production, and energy homeostasis in acute chagasic hearts [30]. Others have shown a decline in oxidative stress in human chagasic patients given Vitamin A [73]. We propose that antioxidants capable of modulating or delaying the onset of oxidative insult and mitochondrial deficiencies in the myocardium would prove to be useful in preserving cardiac functions in Chagas disease.

6. Ischemic Injury and ROS

Approximately 10% of chronic chagasic patients exhibit signs of ischemic disease [74, 75]. The abnormalities during isovolemic contraction and the early relaxation phase, in general ascribed to asynchronous onset of contraction, are noted in chagasic patients, and are similar to that seen in patients with conventional ischemic heart disease of other etiologies [76]. Others have suggested the alterations in the coronary microcirculation contribute to ischemic tissue damage in chronic chagasic patients [75, 77–80]. Myocardial hypoperfusion owing to an affected microvasculature has also been noted in chagasic heart regions with normal or mildly impaired wall motion [75, 80].

Hypoxia is a critical outcome of ischemia. In hypoxic tissues, low availability of oxygen results in electron accumulation in highly reduced respiratory complexes that lead to severely compromised respiration and ATP synthesis [81–83]. Ischemia also influences mitochondrial function via change in calcium flux [84], cyt c depletion (reviewed in [85]), and decline in intrinsic level of MnSOD—the mtROS scavenger [86]. The inefficient scavenging of mtROS during hypoxia is complemented by increased production

of ROS at reperfusion [87]. Mitochondrial loss of cyt c is considered to potentate ROS production at reperfusion because (a) cyt c is a catalytic scavenger for mitochondrial $O_2^{\bullet -}$, and (b) loss of cyt c results in highly reduced state of respiratory complexes I, II, and III, thus, favoring electron release to molecular oxygen and $O_2^{\bullet -}$ production [88, 89]. These observations suggest that mitochondrial inhibition of respiration and ATP synthesis resulting from hypoxia, coupled with an increase in $O_2^{\bullet -}$ formation and ROS-induced injurious effects during reperfusion, potentially contribute to the contractile dysfunction and cell death in Chagasic hearts, to be confirmed in future studies.

7. Summary

Sustained ROS generation of inflammatory and mitochondrial origin, coupled with an inadequate antioxidant response, result in the inefficient scavenging of ROS in the heart, and lead to long-term oxidative stress, and subsequently, to oxidative damage of the cardiac cellular components during chagasic disease. The alterations in biomarkers of oxidant and antioxidant status and in respiratory complex activities in the heart and blood/plasma of infected host appear to have same pathologic tendencies, which led to the suggestion that peripheral blood would be a useful tissue for investigating the pathologic importance of impaired mitochondrial function and oxidant/antioxidant status in chagasic disease development. Further studies should examine the pathological relevance of oxidative stress in clinical severity of chronic heart disease in Chagasic patients.

Abbreviations

CI: NADH ubiquinone oxidoreductase
CII: Succinate decylubiquinone 2, 6 dichlorophenolindophenolreductase
CIII: Ubiquinol cytochrome c oxidoreductase
CIV: Cytochrome c oxidase
cyt c: Cytochrome c
GSH: Glutathione
GPx: Glutathione peroxidase
HNE: 4-hydroxynonenal
MDA: Malonyldialdehyde
MPO: Myeloperoxidase
NADH: Nicotinamide adenine dinucleotide (reduced form)
NOS: Nitric oxide synthase
PBN: Phenyl-*N*-*tert*-butylnitrone
ROS: Reactive oxygen species
SOD: Superoxide dismutase
T. cruzi: *Trypanosoma cruzi.*

Acknowledgments

The work discussed in this review was supported by Grants from the National Heart, Lung, and Blood Institute (HL088320 and HL094802) and the National Institutes of Allergy and Infectious Diseases (AI053098 and AI054578) of the National Institutes of Health, John Sealy Memorial Endowment Fund for Biomedical Research, and the American Health Assistance Foundation. The authors also would like to thank Ms. Mardelle Susman for editing the manuscript.

References

[1] World Health Organization, "Report of the scientific working group on chagas disease," Tech. Rep., UNDP/World Bank/WHO, Buenos Aires, Argentina, 2006.
[2] Z. Brener, "Present status of chemotherapy and chemoprophylaxis of human trypanosomiasis in the Western Hemisphere," *Pharmacology & Therapeutics*, vol. 7, no. 1, pp. 71–90, 1979.
[3] J. Milei and R. Storino, "Early myocardial infarction. A feasible histologic diagnostic procedure," *Japanese Heart Journal*, vol. 27, no. 3, pp. 307–319, 1986.
[4] C. A. Santos-Buch and A. M. Acosta, "Pathology of Chagas' disease," in *Immunology and Pathology of Trypanosomiasis*, I. Tizard, Ed., pp. 145–183, CRC Press, Boca Raton, Fla, USA, 1985.
[5] Z. A. Andrade, S. G. Andrade, R. Correa, M. Sadigursky, and V. J. Ferrans, "Myocardial changes in acute *Trypanosoma cruzi* infection. Ultrastructural evidence of immune damage and the role of microangiopathy," *The American Journal of Pathology*, vol. 144, no. 6, pp. 1403–1411, 1994.
[6] A. Rassi Jr., A. Rassi, and W. C. Little, "Chagas' heart disease," *Clinical Cardiology*, vol. 23, no. 12, pp. 883–889, 2000.
[7] M. de Lourdes Higuchi, L. A. Benvenuti, M. M. Reis, and M. Metzger, "Pathophysiology of the heart in Chagas' disease: current status and new developments," *Cardiovascular Research*, vol. 60, no. 1, pp. 96–107, 2003.
[8] M. B. P. Scares, L. Pontes-De-Carvalho, and R. Ribeiro-Dos-Santos, "The pathogenesis of Chagas' disease: when autoimmune and parasite-specific immune responses meet," *Anais da Academia Brasileira de Ciências*, vol. 73, no. 4, pp. 547–559, 2001.
[9] F. Kierszenbaum, "Mechanisms of pathogenesis in Chagas disease," *Acta Parasitologica*, vol. 52, no. 1, pp. 1–12, 2007.
[10] J. F. Turrens, "Mitochondrial formation of reactive oxygen species," *The Journal of Physiology*, vol. 552, no. 2, pp. 335–344, 2003.
[11] P. J. Andrew and B. Mayer, "Enzymatic function of nitric oxide synthases," *Cardiovascular Research*, vol. 43, no. 3, pp. 521–531, 1999.
[12] M. N. Alvarez, L. Piacenza, F. Irigoín, G. Peluffo, and R. Radi, "Macrophage-derived peroxynitrite diffusion and toxicity to *Trypanosoma cruzi*," *Archives of Biochemistry and Biophysics*, vol. 432, no. 2, pp. 222–232, 2004.
[13] M. A. Muñoz-Fernández, M. A. Fernández, and M. Fresno, "Activation of human macrophages for the killing of intracellular *Trypanosoma cruzi* by TNF-α and IFN-γ through a nitric oxide-dependent mechanism," *Immunology Letters*, vol. 33, no. 1, pp. 35–40, 1992.
[14] R. C. Melo, D. L. Fabrino, H. D'Avila, H. C. Teixeira, and A. P. Ferreira, "Production of hydrogen peroxide by peripheral blood monocytes and specific macrophages during experimental infection with *Trypanosoma cruzi* in vivo," *Cell Biology International*, vol. 27, no. 10, pp. 853–861, 2003.
[15] G. A. Martins, M. A. G. Cardoso, J. C. S. Aliberti, and J. S. Silva, "Nitric oxide-induced apoptotic cell death in the acute phase

of *Trypanosoma cruzi* infection in mice," *Immunology Letters*, vol. 63, no. 2, pp. 113–120, 1998.

[16] M. Bergeron and M. Olivier, "*Trypanosoma cruzi*-mediated IFN-γ-inducible nitric oxide output in macrophages is regulated by *iNOS* mRNA stability," *The Journal of Immunology*, vol. 177, no. 9, pp. 6271–6280, 2006.

[17] M. Dhiman, J. G. Estrada-Franco, J. M. Pando, et al., "Increased myeloperoxidase activity and protein nitration are indicators of inflammation in patients with Chagas' disease," *Clinical and Vaccine Immunology*, vol. 16, no. 5, pp. 660–666, 2009.

[18] R. Pérez-Fuentes, J.-F. Guégan, C. Barnabé, et al., "Severity of chronic Chagas disease is associated with cytokine/antioxidant imbalance in chronically individuals," *International Journal for Parasitology*, vol. 33, no. 3, pp. 293–299, 2003.

[19] R. Pérez-Fuentes, M. D. C. Sánchez-Guillén, C. González-Alvarez, V. M. Monteón, P. A. Reyes, and J. L. Rosales-Encina, "Humoral nitric oxide levels and antibody immune response of symptomatic and indeterminate Chagas' disease patients to commercial and autochthonous *Trypanosoma cruzi* antigen," *The American Journal of Tropical Medicine and Hygiene*, vol. 58, no. 6, pp. 715–720, 1998.

[20] H. A. Carrasco Guerra, E. Palacios-Prü, C. Dagert de Scorza, C. Molina, G. Inglessis, and R. V. Mendoza, "Clinical, histochemical, and ultrastructural correlation in septal endomyocardial biopsies from chronic chagasic patients: detection of early myocardial damage," *American Heart Journal*, vol. 113, no. 3, pp. 716–724, 1987.

[21] E. Palacios-Pru, H. Carrasco, C. Scorza, and R. Espinoza, "Ultrastructural characteristics of different stages of human chagasic myocarditis," *The American Journal of Tropical Medicine and Hygiene*, vol. 41, no. 1, pp. 29–40, 1989.

[22] H. Parada, H. A Carrasco, N. Añez, C. Fuenmayor, and I. Inglessis, "Cardiac involvement is a constant finding in acute Chagas' disease: a clinical, parasitological and histopathological study," *International Journal of Cardiology*, vol. 60, no. 1, pp. 49–54, 1997.

[23] N. Garg, V. L. Popov, and J. Papaconstantinou, "Profiling gene transcription reveals a deficiency of mitochondrial oxidative phosphorylation in *Trypanosoma cruzi*-infected murine hearts: implications in chagasic myocarditis development," *Biochimica et Biophysica Acta*, vol. 1638, no. 2, pp. 106–120, 2003.

[24] E. Cunha-Neto, V. J. Dzau, P. D. Allen, et al., "Cardiac gene expression profiling provides evidence for cytokinopathy as a molecular mechanism in Chagas' disease cardiomyopathy," *American Journal of Pathology*, vol. 167, no. 2, pp. 305–313, 2005.

[25] S. Mukherjee, T. J. Belbin, D. C. Spray, et al., "Microarray analysis of changes in gene expression in a murine model of chronic chagasic cardiomyopathy," *Parasitology Research*, vol. 91, no. 3, pp. 187–196, 2003.

[26] N. Garg, A. Gerstner, V. Bhatia, J. DeFord, and J. Papaconstantinou, "Gene expression analysis in mitochondria from chagasic mice: alterations in specific metabolic pathways," *Biochemical Journal*, vol. 381, no. 3, pp. 743–752, 2004.

[27] G. Vyatkina, V. Bhatia, A. Gerstner, J. Papaconstantinou, and N. Garg, "Impaired mitochondrial respiratory chain and bioenergetics during chagasic cardiomyopathy development," *Biochimica et Biophysica Acta*, vol. 1689, no. 2, pp. 162–173, 2004.

[28] S. A. Uyemura, M. C. Jordani, A. C. M. Polizello, and C. Curti, "Heart FoF1-ATPase changes during the acute phase of *Trypanosoma cruzi* infection in rats," *Molecular and Cellular Biochemistry*, vol. 165, no. 2, pp. 127–133, 1996.

[29] S. A. Uyemura, S. Albuquerque, and C. Curti, "Energetics of heart mitochondria during acute phase of *Trypanosoma cruzi* infection in rats," *The International Journal of Biochemistry & Cell Biology*, vol. 27, no. 11, pp. 1183–1189, 1995.

[30] J.-J. Wen, V. Bhatia, V. L. Popov, and N. J. Garg, "Phenyl-α-*tert*-butyl nitrone reverses mitochondrial decay in acute Chagas' disease," *American Journal of Pathology*, vol. 169, no. 6, pp. 1953–1964, 2006.

[31] A. Boveris, N. Oshino, and B. Chance, "The cellular production of hydrogen peroxide," *Biochemical Journal*, vol. 128, no. 3, pp. 617–630, 1972.

[32] T. Ide, H. Tsutsui, S. Kinugawa, et al., "Mitochondrial electron transport complex I is a potential source of oxygen free radicals in the failing myocardium," *Circulation Research*, vol. 85, no. 4, pp. 357–363, 1999.

[33] Q. Chen, E. J. Vazquez, S. Moghaddas, C. L. Hoppel, and E. J. Lesnefsky, "Production of reactive oxygen species by mitochondria: central role of complex III," *The Journal of Biological Chemistry*, vol. 278, no. 38, pp. 36027–36031, 2003.

[34] J. J. Wen and N. J. Garg, "Mitochondrial generation of reactive oxygen species is enhanced at the Q_o site of the complex III in the myocardium of *Trypanosoma cruzi*-infected mice: beneficial effects of an antioxidant," *Journal of Bioenergetics and Biomembranes*, vol. 40, no. 6, pp. 587–598, 2008.

[35] I. Fridovich, "Superoxide radical and superoxide dismutases," *Annual Review of Biochemistry*, vol. 64, pp. 97–112, 1995.

[36] I. Fridovich, "Superoxide dismutases," in *Advances in Enzymology and Related Areas of Molecular Biology, Vol. 41*, pp. 35–97, John Wiley & Sons, New York, NY, USA, 1974.

[37] J. Nordberg and E. S. J. Arnér, "Reactive oxygen species, antioxidants, and the mammalian thioredoxin system," *Free Radical Biology and Medicine*, vol. 31, no. 11, pp. 1287–1312, 2001.

[38] H. Z. Chae, S. W. Kang, and S. G. Rhee, "Isoforms of mammalian peroxiredoxin that reduce peroxides in presence of thioredoxin," *Methods in Enzymology*, vol. 300, pp. 219–226, 1999.

[39] N. S. Dhalla, A. B. Elmoselhi, T. Hata, and N. Makino, "Status of myocardial antioxidants in ischemia-reperfusion injury," *Cardiovascular Research*, vol. 47, no. 3, pp. 446–456, 2000.

[40] N. Marczin, N. El-Habashi, G. S. Hoare, R. E. Bundy, and M. Yacoub, "Antioxidants in myocardial ischemia-reperfusion injury: therapeutic potential and basic mechanisms," *Archives of Biochemistry and Biophysics*, vol. 420, no. 2, pp. 222–236, 2003.

[41] J.-J. Wen and N. Garg, "Oxidative modification of mitochondrial respiratory complexes in response to the stress of *Trypanosoma cruzi* infection," *Free Radical Biology and Medicine*, vol. 37, no. 12, pp. 2072–2081, 2004.

[42] J.-J. Wen, P. C. Yachelini, A. Sembaj, R. E. Manzur, and N. J. Garg, "Increased oxidative stress is correlated with mitochondrial dysfunction in chagasic patients," *Free Radical Biology and Medicine*, vol. 41, no. 2, pp. 270–276, 2006.

[43] T. B. de Oliveira, R. C. Pedrosa, and D. W. Filho, "Oxidative stress in chronic cardiopathy associated with Chagas disease," *International Journal of Cardiology*, vol. 116, no. 3, pp. 357–363, 2007.

[44] T. Finkel, "Oxidant signals and oxidative stress," *Currnet Opinion in Cell Biology*, vol. 15, no. 2, pp. 247–254, 2003.

[45] W. Dröge, "Free radicals in the physiological control of cell function," *Physiological Reviews*, vol. 82, no. 1, pp. 47–95, 2002.

[46] A. Valenzuela, "The biological significance of malondialdehyde determination in the assessment of tissue oxidative stress," *Life Sciences*, vol. 48, no. 4, pp. 301–309, 1991.

[47] H. Ohkawa, N. Ohishi, and K. Yagi, "Assay for lipid peroxides in animal tissues by thiobarbituric acid reaction," *Analytical Biochemistry*, vol. 95, no. 2, pp. 351–358, 1979.

[48] N. Zarkovic, "4-hydroxynonenal as a bioactive marker of pathophysiological processes," *Molecular Aspects of Medicine*, vol. 24, no. 4-5, pp. 281–291, 2003.

[49] K. Uchida and E. R. Stadtman, "Modification of histidine residues in proteins by reaction with 4-hydroxynonenal," *Proceedings of the National Academy of Sciences of the United States of America*, vol. 89, no. 10, pp. 4544–4548, 1992.

[50] D. A. Butterfield, T. Koppal, B. Howard, et al., "Structural and functional changes in proteins induced by free radical-mediated oxidative stress and protective action of the antioxidants *N*-*tert*-butyl-α-phenylnitrone and vitamin E," *Annals of the New York Academy of Sciences*, vol. 854, pp. 448–462, 1998.

[51] M. Chevion, E. Berenshtein, and E. R. Stadtman, "Human studies related to protein oxidation: protein carbonyl content as a marker of damage," *Free Radical Research*, vol. 33, supplement, pp. S99–S108, 2000.

[52] F. J. Schopfer, P. R. S. Baker, and B. A. Freeman, "NO-dependent protein nitration: a cell signaling event or an oxidative inflammatory response?" *Trends in Biochemical Sciences*, vol. 28, no. 12, pp. 646–654, 2003.

[53] R. A. Floyd, M. West, and K. Hensley, "Oxidative biochemical markers; clues to understanding aging in long-lived species," *Experimental Gerontology*, vol. 36, no. 4–6, pp. 619–640, 2001.

[54] M. D. Evans and M. S. Cooke, "Factors contributing to the outcome of oxidative damage to nucleic acids," *BioEssays*, vol. 26, no. 5, pp. 533–542, 2004.

[55] A. B. Younés-Chennoufi, M. Hontebeyrie-Joskowicz, V. Tricottet, H. Eisen, M. Reynes, and G. Said, "Persistence of *Trypanosoma cruzi* antigens in the inflammatory lesions of chronically infected mice," *Transactions of the Royal Society of Tropical Medicine and Hygiene*, vol. 82, no. 1, pp. 77–83, 1988.

[56] R. L. Cardoni, M. I. Antunez, C. Morales, and I. Rodriguez Nantes, "Release of reactive oxygen species by phagocytic cells in response to live parasites in mice infected with *Trypanosoma cruzi*," *The American Journal of Tropical Medicine and Hygiene*, vol. 56, no. 3, pp. 329–334, 1997.

[57] F. Villalta and F. Kierszenbaum, "Role of polymorphonuclear cells in Chagas' disease. I. Uptake and mechanisms of destruction of intracellular (amastigote) forms of *Trypanosoma cruzi* by human neutrophils," *The Journal of Immunology*, vol. 131, no. 3, pp. 1504–1510, 1983.

[58] J.-J. Wen, M. Dhiman, E. B. Whorton, and N. J. Garg, "Tissue-specific oxidative imbalance and mitochondrial dysfunction during *Trypanosoma cruzi* infection in mice," *Microbes and Infection*, vol. 10, no. 10-11, pp. 1201–1209, 2008.

[59] B. Chance, H. Sies, and A. Boveris, "Hydroperoxide metabolism in mammalian organs," *Physiological Reviews*, vol. 59, no. 3, pp. 527–605, 1979.

[60] A. Boveris, E. Cadenas, and A. O. M. Stoppani, "Role of ubiquinone in the mitochondrial generation of hydrogen peroxide," *Biochemical Journal*, vol. 156, no. 2, pp. 435–444, 1976.

[61] J. F. Turrens, "The potential of antioxidant enzymes as pharmacological agents in vivo," *Xenobiotica*, vol. 21, no. 8, pp. 1033–1040, 1991.

[62] K. Carvajal and R. Moreno-Sánchez, "Heart metabolic disturbances in cardiovascular diseases," *Archives of Medical Research*, vol. 34, no. 2, pp. 89–99, 2003.

[63] D. Han, R. Canali, D. Rettori, and N. Kaplowitz, "Effect of gutathione depletion on sites and topology of superoxide and hydrogen peroxide production in mitochondria," *Molecular Pharmacology*, vol. 64, no. 5, pp. 1136–1144, 2003.

[64] B. Halliwell and J. M. C. Gutteridge, "Oxygen toxicity, oxygen radicals, transition metals and disease," *Biochemical Journal*, vol. 219, no. 1, pp. 1–14, 1984.

[65] L. Y. Brovko, N. A. Romanova, and N. N. Ugarova, "Bioluminescent assay of bacterial intracellular AMP, ADP, and ATP with the use of a coimmobilized three-enzyme reagent (adenylate kinase, pyruvate kinase, and firefly luciferase)," *Analytical Biochemistry*, vol. 220, no. 2, pp. 410–414, 1994.

[66] J. D. Rush and W. H. Koppenol, "Oxidizing intermediates in the reaction of ferrous EDTA with hydrogen peroxide. Reactions with organic molecules and ferrocytochrome *C*," *The Journal of Biological Chemistry*, vol. 261, no. 15, pp. 6730–6733, 1986.

[67] D. A. Dickinson and H. J. Forman, "Glutathione in defense and signaling: lessons from a small thiol," *Annals of the New York Academy of Sciences*, vol. 973, pp. 488–504, 2002.

[68] J. Wang, H. Chen, T. Wang, Y. Diao, and K. Tian, "Oxygen-derived free radicals induced cellular injury in superior mesenteric artery occlusion shock: protective effect of superoxide dismutase," *Circulatory Shock*, vol. 32, no. 1, pp. 31–41, 1990.

[69] S. Cuzzocrea, G. Costantino, E. Mazzon, A. De Sarro, and A. P. Caputi, "Beneficial effects of Mn(III)tetrakis (4-benzoic acid) porphyrin (MnTBAP), a superoxide dismutase mimetic, in zymosan-induced shock," *British Journal of Pharmacology*, vol. 128, no. 6, pp. 1241–1251, 1999.

[70] D. Salvemini, Z.-Q. Wang, J. L. Zweier, et al., "A nonpeptidyl mimic of superoxide dismutase with therapeutic activity in rats," *Science*, vol. 286, no. 5438, pp. 304–306, 1999.

[71] R. A. Floyd, K. Hensley, M. J. Forster, J. A. Kelleher-Anderson, and P. L. Wood, "Nitrones as neuroprotectants and antiaging drugs," *Annals of the New York Academy of Sciences*, vol. 959, pp. 321–329, 2002.

[72] Y. Kotake, "Pharmacologic properties of phenyl *N*-*tert*-butylnitrone," *Antioxidants & Redox Signaling*, vol. 1, no. 4, pp. 481–499, 1999.

[73] L. B. Maçao, D. W. Filho, R. C. Pedrosa, et al., "Antioxidant therapy attenuates oxidative stress in chronic cardiopathy associated with Chagas' disease," *International Journal of Cardiology*, vol. 123, no. 1, pp. 43–49, 2007.

[74] J. S. M. Oliveira, "A natural human model of intrinsic heart nervous system denervation: Chagas' cardiopathy," *American Heart Journal*, vol. 110, no. 5, pp. 1092–1098, 1985.

[75] J. A. Marin-Neto, M. V. Simões, E. M. Ayres-Neto, et al., "Studies of the coronary circulation in Chagas' heart disease," *São Paulo Medical Journal*, vol. 113, no. 2, pp. 826–834, 1995.

[76] H. Acquatella and N. B. Schiller, "Echocardiographic recognition of Chagas' disease and endomyocardial fibrosis," *Journal of the American Society of Echocardiography*, vol. 1, no. 1, pp. 60–68, 1988.

[77] M. A. Rossi, "Microvascular changes as a cause of chronic cardiomyopathy in Chagas' disease," *American Heart Journal*, vol. 120, no. 1, pp. 233–236, 1990.

[78] M. A. Rossi, "Aortic endothelial cell changes in the acute septicemic phase of experimental Trypanosoma cruzi infection in rats: scanning and transmission electron microscopic study," *The American Journal of Tropical Medicine and Hygiene*, vol. 57, no. 3, pp. 321–327, 1997.

[79] H. B. Tanowitz, D. K. Kaul, B. Chen, et al., "Compromised microcirculation in acute murine Trypanosoma cruzi infection," *Journal of Parasitology*, vol. 82, no. 1, pp. 124–130, 1996.

[80] S. G. Ramos and M. A. Rossi, "Microcirculation and Chagas' disease: hypothesis and recent results," *Revista do Instituto de Medicina Tropical de Sao Paulo*, vol. 41, no. 2, pp. 123–129, 1999.

[81] H. M. Piper, T. Noll, and B. Siegmund, "Mitochondrial function in the oxygen depleted and reoxygenated myocardial cell," *Cardiovascular Research*, vol. 28, no. 1, pp. 1–15, 1994.

[82] V. Borutaite, R. Morkuniene, A. Budriunaite, et al., "Kinetic analysis of changes in activity of heart mitochondrial oxidative phosphorylation system induced by ischemia," *Journal of Molecular and Cellular Cardiology*, vol. 28, no. 10, pp. 2195–2201, 1996.

[83] R. B. Jennings and C. E. Ganote, "Mitochondrial structure and function in acute myocardial ischemic injury," *Circulation Research*, vol. 38, no. 5, supplement 1, pp. 80–91, 1976.

[84] K. Ataka, D. Chen, S. Levitsky, E. Jimenez, and H. Feinberg, "Effect of aging on intracellular Ca^{2+}, pHi, and contractility during ischemia and reperfusion," *Circulation*, vol. 86, no. 5, supplement 2, pp. 371–376, 1992.

[85] V. Borutaite and G. C. Brown, "Mitochondria in apoptosis of ischemic heart," *FEBS Letters*, vol. 541, no. 3, pp. 1–5, 2003.

[86] M. Shlafer, C. L. Myers, and S. Adkins, "Mitochondrial hydrogen peroxide generation and activities of glutathione peroxidase and superoxide dismutase following global ischemia," *Journal of Molecular and Cellular Cardiology*, vol. 19, no. 12, pp. 1195–1206, 1987.

[87] E. J. Lesnefsky, S. Moghaddas, B. Tandler, J. Kerner, and C. L. Hoppel, "Mitochondrial dysfunction in cardiac disease: ischemia-reperfusion, aging, and heart failure," *Journal of Molecular and Cellular Cardiology*, vol. 33, no. 6, pp. 1065–1089, 2001.

[88] R. A. Simonyan and V. P. Skulachev, "Thermoregulatory uncoupling in heart muscle mitochondria: involvement of the ATP/ADP antiporter and uncoupling protein," *FEBS Letters*, vol. 436, no. 1, pp. 81–84, 1998.

[89] S. S. Korshunov, B. F. Krasnikov, M. O. Pereverzev, and V. P. Skulachev, "The antioxidant functions of cytochrome *c*," *FEBS Letters*, vol. 462, no. 1, pp. 192–198, 1999.

Hindawi Publishing Corporation
Interdisciplinary Perspectives on Infectious Diseases
Volume 2009, Article ID 484358, 6 pages
doi:10.1155/2009/484358

Review Article

Cell Therapy in Chagas Disease

Antonio C. Campos de Carvalho,[1,2,3] Regina C. S. Goldenberg,[3] Linda A. Jelicks,[4] Milena B. P. Soares,[5] Ricardo Ribeiro dos Santos,[5] David C. Spray,[2] and Herbert B. Tanowitz[6]

[1] *Instituto Nacional de Cardiologia, 22240-006 Rio de Janeiro, RJ, Brazil*
[2] *Dominick P. Purpura, Department of Neuroscience, Albert Einstein College of Medicine, Bronx, NY 10461, USA*
[3] *Instituto de Biofísica Carlos Chagas Filho, Universidade Federal do Rio de Janeiro, 21941-590 Rio de Janeiro, RJ, Brazil*
[4] *Department of Physiology & Biophysics, Albert Einstein College of Medicine, Bronx, NY 10461, USA*
[5] *Centro de Pesquisas Gonçalo Moniz, Fundação Oswaldo Cruz, 40296-70 Salvador, BA, Brazil*
[6] *Department of Pathology, Albert Einstein College of Medicine, Bronx, NY 10461, USA*

Correspondence should be addressed to Herbert B. Tanowitz, tanowitz@aecom.yu.edu

Received 5 April 2009; Accepted 11 May 2009

Recommended by Louis M. Weiss

Chagas disease which is caused by the parasite *Trypanosoma cruzi* is an important cause of cardiomyopathy in Latin America. In later stages chagasic cardiomyopathy is associated with congestive heart failure which is often refractory to medical therapy. In these individuals heart transplantation has been attempted. However, this procedure is fraught with many problems attributable to the surgery and the postsurgical administration of immunosuppressive drugs. Studies in mice suggest that the transplantation of bone-marrow-derived cells ameliorates the inflammation and fibrosis in the heart associated with this infection. Cardiac magnetic resonance imaging reveals that bone marrow transplantation ameliorates the infection induced right ventricular enlargement. On the basis of these animal studies the safety of autologous bone marrow transplantation has been assessed in patients with chagasic end-stage heart disease. The initial results are encouraging and more studies need to be performed.

1. Introduction

This year we celebrate the 100th anniversary of the discovery by the Brazilian physician-scientist Carlos Chagas of the disease that bears his name (Chagas disease). This represents a rare instance in the history of medicine where a researcher described the disease, identified the transmission method and isolated the causal agent [1, 2]. Since 1909, many studies have been performed to unravel disease mechanisms and to find a cure for Chagas disease. Unfortunately, although much progress has been achieved, until now there is no consensus on the exact mechanisms that lead to the different manifestations of the disease, nor is there an effective treatment for this infection.

Chagas disease is caused by the hemoflagellate parasite, *Trypanosoma cruzi*. The parasite has a complex life cycle consisting of different life forms that are distinguished by morphological and biochemical criteria. Blood form trypomastigotes are found in infected mammalian hosts. After the insect vector, from the *Reduvidae* family, ingests blood containing blood form trypomastigotes they transform into dividing epimastigotes in the midgut of the insect vector. After 3–4 weeks epimastigotes become infective, nondividing metacyclic trypomastigotes. These forms are present in the hindgut of the vector and are deposited with the feces during blood meals. Transmission to a new host takes place when the parasite-laden feces contaminate oral or nasal mucous membranes, the conjunctivas, or other vulnerable surfaces such as the skin. In the mammalian host the metacyclic trypomastigotes invade the cells of the host and once inside the parasites transform into intracellular amastigotes that multiply by binary fission. As the amastigotes accumulate inside the host cells, signaling mechanisms that have not been fully identified lead to their transformation into blood form trypomastigotes. They are then released as the host cell ruptures and disseminate through the lymphatics and the bloodstream to invade new cells or, while in circulating blood, may be ingested in meals taken by the insect vectors.

Although any nucleated mammalian cell can be parasitized by *T. cruzi,* cells of the reticuloendothelial, nervous and muscle systems, including the heart, appear to be favored. Chagas disease is characterized by three phases, acute, indeterminate and chronic. In the acute infection, which usually lasts for approximately two months, there are nonspecific signs and symptoms such as fever and myalgias associated with tissue parasitism, inflammation and high peripheral blood parasitemia. The indeterminate phase may last for months to a lifetime during which individuals are relatively asymptomatic. In the chronic phase parasitemia is low or nonexistent but there is an intense inflammatory process in the affected organs. The gastrointestinal tract and heart are the main targets of the chronic stage of the disease and in these organs dilatation is present, constituting the so-called mega syndromes.

The disease is endemic in all Latin America countries with the exception of the Caribbean nations. In these countries it is estimated that 16–18 million individuals are infected with the parasite, with many new cases reported each year. In the past transmission of *T. cruzi* to humans has essentially been vector-borne. Presently this situation has changed drastically due to the successful implementation of vector control programs in many of the endemic countries. The Southern Cone Initiative (SCI), which began in 1991 in Argentina, Bolivia, Brazil, Chile, Paraguay, and Uruguay, was instrumental for the success of the control program. The transmission of *T. cruzi* by blood transfusion has been essentially eliminated throughout much of the endemic range by obligatory testing of donated blood for evidence of *T. cruzi* infection. In recent decades the rate of emigration from Chagas-endemic countries to the United States, Canada, and the European Union has increased markedly. Currently an estimated 100 000 immigrants from these areas are chronically infected with *T. cruzi*. Although these regions are free of the vector transmission, transmission by blood transfusion and by organ transplantation have been reported in Canada and the United States.

During the chronic phase, cardiomyopathy is the most important clinical manifestation of Chagas disease. It is estimated that 10%–30% of all infected individuals will acquire chronic chagasic cardiomyopathy. This represents anywhere between 1.6 to 5.4 million patients with chronic chagasic cardiomyopathy in Latin America, making Chagas disease one of the most important causes of heart disease in this region. Additionally, the chronic cardiac manifestations of Chagas disease have created an immense social and economic burden in endemic areas because of unemployment and increased health care costs. It has been estimated that 20 000 deaths occur annually in endemic countries due to complications of chronic chagasic cardiomyopathy [3].

Dilated congestive cardiomyopathy is an important manifestation of chronic chagasic cardiomyopathy that typically occurs years or even decades after a person first becomes infected. Apical aneurysm of the left ventricle is one of the hallmarks of chronic chagasic cardiomyopathy. Chronic chagasic cardiomyopathy is characterized by focal or disseminated inflammatory infiltrates, myocytolysis, myonecrosis and progressive fibrosis [4, 5]. Remodeling of the myocardium and vasculature is the result of damage to the extracellular matrix and the replacement of cardiac myocytes and/or vascular cells by fibrous tissue. This results in thinning of the myocardium and hypertrophy of the remaining cardiac myocytes and also leads to thromboembolic events. In that regard chronic chagasic cardiomyopathy is similar to other dilated cardiomyopathies that lead to congestive heart failure. The clinical correlation between intensity of the myocarditis varies considerably from mild cardiac symptoms to intense chronic cardiomyopathy, leading to heart failure and death [6]. Patients with chronic chagasic cardiomyopathy may have a variety of arrhythmias causing heart malfunction. The ECG abnormalities include right bundle-branch block, left anterior fascicular block, ventricular premature beats and A-V block [7, 8].

The virtual absence of parasites, both circulating and within the heart and the presence of a focal and widespread inflammatory process in the myocardium have generated multiple hypotheses to explain the etiology of chronic chagasic cardiomyopathy. However, the general opinion is that the etiology of chronic chagasic cardiomyopathy is multifactorial involving parasite persistence, vascular impairment, destruction of ganglia of the autonomic nervous system and autoimmunity [9]. With such complex disease mechanisms it is not surprising that once the cardiomyopathy is established, the prognosis for the chagasic patient is rather bleak. In fact, chronic chagasic cardiomyopathy has been reported to be the main prognostic mortality factor among patients with heart failure of various etiologies [10]. Therapies for chronic chagasic cardiomyopathy are identical to those for congestive heart failure and often include β-blockers, diuretics, angiotensin-enzyme inhibitors angiotensin receptor blockers and amiodarone. There is no consensus about the use of anti-trypanosomal agents such as benznidazole. In fact, a large trial designed to address the efficacy of benznidazole in chronic chagasic cardiomyopathy is under way; the BENEFIT Multicenter Trial. As the disease progresses few therapeutic options are left for the chronic chagasic cardiomyopathy patient other than heart transplantation. Although survival in chagasic heart transplant patients has been reported to be longer than that of persons transplanted for heart disease resulting from other etiologies [11], the limited number of donors and the complications of immunosuppressive therapy, including parasite reactivation, make this therapeutic option a very limited one for the majority of chronic chagasic cardiomyopathy patients. In that scenario, cell transplantation appears as an alternative to standard therapies in the setting of chronic chagasic cardiomyopathy.

2. Cell Therapy for Chagasic Cardiomyopathy

The use of cell therapy for chagasic cardiomyopathy followed closely the development of research on the use of this therapy in patients with myocardial infarction. The pioneering work of Soonpaa et al. [12] demonstrated conclusively that exogenous cells could be integrated into the host myocardium. Although initially most of the studies in this area of research focused on transplantation of fetal cardiac

myocytes, embryonic stem cells, or skeletal myoblasts into hearts that were damaged cryogenically or by myocardial infarction, more recently bone marrow derived cells have become an important cell source. A major development in the use of cell therapies to improve cardiac function was based on the observations that stromal bone marrow cells could be induced to differentiate into cardiac myocytes in vitro [13] and that when they were transplanted into cryo-injured rat hearts, myocardial function improved and angiogenesis was promoted [14]. Another significant development was the report by Orlic et al. [15] that hematopoietic stem cells from transgenic mice expressing enhanced green fluorescent protein (EGFP) transplanted into myocardial infarction-damaged hearts of syngeneic mice differentiated into cardiac muscle and vascular cells. Importantly, they demonstrated complete integration of the transplanted c-Kit$^+$ bone marrow derived cells, including formation of connexin 43 gap junctions between the newly formed myocardium and the surviving tissue. Many others have reported that hematopoietic and mesenchymal stem cells derived from bone marrow improve myocardial function in animal models of both cryo-injured and ischemic heart lesions [16–19].

Cardiac regeneration by bone marrow-derived cells has been questioned [20–22] and remains controversial [23]. However, even in cases where cardiac regeneration by bone marrow-derived cells has not been demonstrated, functional measurements have detected improvements in heart function after cell transplantation [22]. More recently, the beneficial effects of cell therapies using bone marrow-derived cells in heart disease have been increasingly attributed to paracrine effects [24, 25].

In most of the reported studies the damage to the heart is circumscribed to a specific area since the lesions are ischemic in nature. Accordingly, cell delivery has been mostly intramyocardial, especially in small animals. Due to the global nature of chronic chagasic cardiomyopathy, systemic delivery of cells was chosen for studies in a mouse model of Chagas disease. Our reasoning was that direct myocardial injections would have to be performed in various areas of the left and right ventricle, creating the possibility of myocardial damage due to the multiple injections. Thus, to validate the therapy it was necessary to demonstrate that cells injected intravenously established themselves in the chagasic hearts. In initial experiments bone marrow mononuclear cells were preincubated with Hoechst 33258 stain prior to injection into tail veins of normal and chagasic mice, and cell-treated mice were sacrificed at various time points thereafter. In chagasic mice Hoechst$^+$ cells were observed in the heart 1–7 days after BM cell injection, but were not found in heart sections of normal mice injected with Hoechst 33258-stained cells (see Figure 1). Hoechst$^+$ cells were also found in the spleen and liver of chagasic and control bone marrow cell-treated mice 1-2 days after transplant. Heart sections of mononuclear cell-treated mice were also stained for stem cell markers by immunofluorescence, and Sca-1$^+$ and c-Kit$^+$ cell clusters were found in hearts of mononuclear cell-treated mice after cell injection [26]. As a result of these and other experiments in which bone marrow cells from EGFP positive mice were used, it was concluded that bone marrow stem cells home to the chagasic heart, validating systemic injection as a viable approach for cell therapy in this context.

Once the homing of the cells to the diseased myocardium was established, Soares et al. [26] demonstrated that bone marrow mononuclear cells from normal syngeneic donors significantly reduced cardiac inflammation and fibrosis in mice with chronic *T. cruzi* infections. Importantly, the improvement was long lasting, being observed up to six months after cell therapy. The reduction in inflammation likely resulted from increased apoptosis of the infiltrating inflammatory cells as determined by TUNEL staining. The decrease in fibrosis may result from activation of metalloproteases, since MMP9 expression is increased in the chagasic hearts after cell therapy. Cell dosing experiments demonstrated that 10^5 cells were necessary for a significant reduction in the number of inflammatory cells and injection of 10^6 or 10^7 cells induced similar effects [26].

The mechanisms of action of the mononuclear cells in chagasic mouse hearts have not yet been fully elucidated. Trans differentiation/fusion appears to occur at an extremely low frequency and paracrine effects may be the major cause of improvement in myocardial function. In clinical human trials autologous bone marrow cells would be employed. Therefore, bone marrow cells from chronically infected mice were used to ameliorate the pathology of infected mice [26]. These experiments highlight the translational aspects of these animal studies.

Recently, using cardiac MRI, it was demonstrated that tail vein injection of 10^7 bone marrow mononuclear cells prevented and reversed the right ventricular dilatation induced by *T. cruzi*-infection [27] which correlates with the pathologic improvement reported by Soares et al. [26]. Furthermore it was determined that repeated injections of Granulocyte-colony stimulating factor (G-CSF), which mobilizes stem cells from the bone marrow, decrease inflammation and fibrosis in the hearts of chagasic mice Garcia et al. personal communication. This finding is consistent with observations of Harada et al. [28] that demonstrated improvement in heart function in an ischemic mouse model. The combination of mononuclear cells and G-CSF enhances the effect of the cell therapy in the reduction of the inflammatory infiltrate.

In a rat model of chagasic cardiomyopathy Guarita et al. [29] reported that direct left ventricular injection of cocultured skeletal myoblasts and mesenchymal bone marrow derived cells improved heart function in chronically infected rats as determined by echocardiography. Injection of the cocultured cells increased ejection fraction and decreased end-systolic and diastolic volumes. These findings demonstrated that local injection of stem cells is also effective and suggest that cells are able to diffuse from the injection site to reach other regions of the heart. This is an important observation, given the widespread involvement of the myocardium in chagasic cardiomyopathy.

Based on the encouraging results in animal models, investigators in Brazil initiated a clinical trial to examine the feasibility and safety of autologous bone marrow cell transplantation in patients with congestive heart failure due

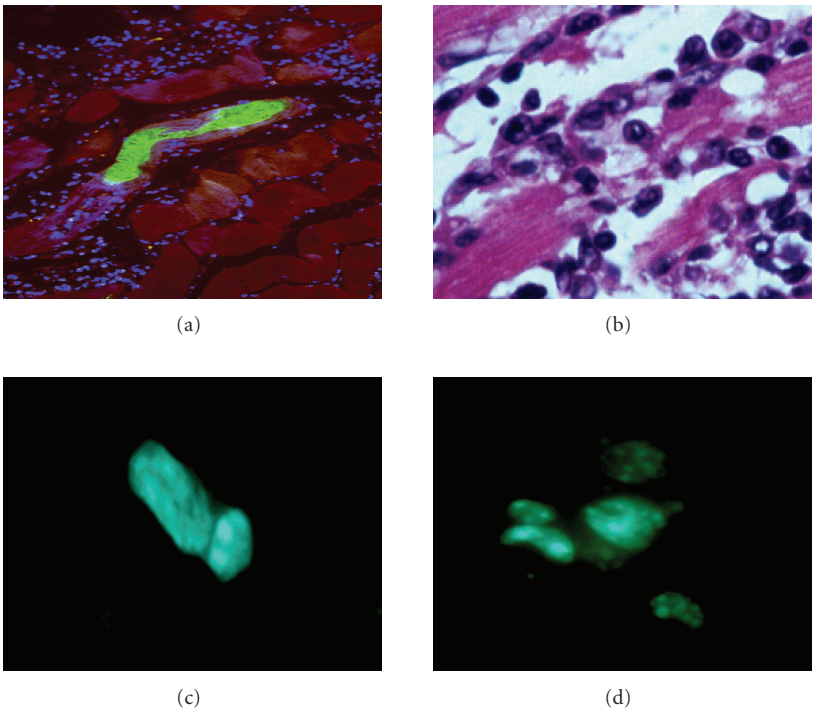

Figure 1: Heart sections of *T. cruzi*-infected mice. (a) BALB/c mouse during the acute phase of infection with Colombian strain *T. cruzi*, showing a parasite nest (green), DAPI-stained nuclei (blue) and myofibers (red). The majority of the DAPI nuclei belong to inflammatory cells that infiltrate the heart in areas infected with parasites. (b) Inflammation of chronic chagasic BALB/c mouse, showing inflammatory cells adhered to myofibers causing myocytolysis. (c) and (d), Detection of bone marrow stem cells (BMC) in the myocardium of chronic chagasic mice. BMC obtained from normal BALB/c mice were injected i.v. into chronic chagasic mice (18 months of infection). BMC were incubated with the fluorescent DNA stain Hoechst 33258 prior to injection into chagasic mice. Sections of frozen heart fragments were prepared 7 (c) and 15 (d) days after BMC injection and fixed with cold acetone. Sections were observed in an Olympus spectral confocal microscope FV1000 observed by fluorescence microscopy. In chagasic mice Hoechst$^+$ cells could be observed 1–7 days after BMC injection, some of which were already beginning cell division cycles (c). Hoechst$^+$ cells proliferated and formed clusters of cells bearing a dotted nuclear fluorescent pattern that could be observed up to 30 days after BMC transplant (d).

to chronic chagasic cardiomyopathy. These patients generally have a poor prognosis, with mortality rates reaching 40% within two years of onset [30]. At the most advanced stage of congestive heart failure the only therapy possible is heart transplantation, but this procedure is feasible in only a very small number of patients. Due to uncertainties regarding the mechanisms of action of the mononuclear cells, the trial was designed for patients with end-stage congestive heart failure whose only therapeutic option would be heart transplantation. This was an open label, uncontrolled, single center clinical trial that enrolled 30 patients. Inclusion criteria required patients to be 18–70 years old, of either gender, with congestive heart failure due to Chagas' disease, in New York Heart Association (NYHA) class III or IV, with an ejection fraction of less than 40% while on optimized pharmacologic therapy for at least 4 weeks before enrollment [31]. Bone marrow cell aspiration was performed on the day of the injection and the mononuclear fraction was obtained through Ficoll density gradient centrifugation. The cell suspension was diluted in 20 mL of saline with 5% autologous serum and injected in the coronary arteries using an angioplasty catheter with the following distribution: 10 mL in the left descending coronary artery, 5 mL in the circumflex and 5 mL in the right coronary artery. Mean number of injected cells was 2.7×10^8. At the 25th day after cell injection patients received 5 μg/kg of G-CSF for 5 days. Patients were followed for six months. Importantly there was no detectable increase in arrhythmias after cell therapy nor were troponin I levels increased during or after the procedure. Results indicated that cell therapy induced a small but significant increase in ejection fraction. Quality of life improved as determined by the Minnesota Questionnaire and by NYHA class. The six minute walking test also showed significant improvement. These results were observed 1 month after therapy and persisted for the 6 month follow-up period. However, since the trial was not designed to test for efficacy the only conclusion possible is that bone marrow mononuclear cell therapy by intracoronary delivery is feasible and safe in chronic chagasic cardiomyopathy patients.

In a patient with chagasic cardiomyopathy, bone marrow mononuclear cells delivered by the intracoronary route were

preferentially retained in diseased, hypoperfused areas of the myocardium [32]. Further studies using labeled cells confirmed these results (Barbosa, personal communication).

Given the promising results of the phase II trial, a larger, multicenter, randomized, double-blind and placebo controlled trial was designed to test for efficacy of the intracoronary delivery of bone marrow-derived mononuclear cells in chronic chagasic cardiomyopathy. Inclusion criteria included diagnosis of heart failure by the Framingham criteria, regular visits to a cardiology service with at least two independent serological diagnoses of Chagas disease, ages between 18–75 years, NYHA class III or IV, ejection fraction below 35% by echocardiography according to Simpson's rule, and optimized pharmacologic therapy. Main exclusion criteria were valvular diseases (except for functional mitral or tricuspid regurgitation), coronary angiography with significant lesions (more than 50% of obstruction), sustained ventricular tachycardia, abusive use of drugs or alcohol, serum creatinine >2.5 mg/dl, neoplasia and other diseases that might impact life expectancy within two years. Primary endpoint for the trial is the difference in ejection fraction between the cell therapy and the placebo group as determined by Simpson's rule in echocardiography. The trial was powered to detect an absolute 5% difference as significant. Secondary endpoints include difference in ejection fraction, life quality assessment by Minnesota Quality of Life Questionnaire, six minute walking distance, NYHA class and brain natriuretic peptide levels at baseline and 6 and 12 months after therapy, among others. The trial is still recruiting patients, but initial 6 month follow-up results are expected to be published by July 2009.

Transplantation of bone marrow derived-cells may prove to be an important therapeutic modality in the management of end-stage chagasic heart disease. Undoubtedly, identifying which cell type(s) is(are) responsible for the effects observed in the animal and the preliminary human experiments will be an important step toward improvement of this therapy. Since the percentage of stem cells, either hematopoietic or mesenchymal, is minimal in the mononuclear fraction, use of purified stem cell populations has the potential to significantly increase the therapeutic potential of cell therapy in chagasic cardiomyopathy.

Acknowledgments

This work was supported in part by grants from the NIH HL-73732 (ACC) CA123334 (LAJ) and AI076248 (HBT), from FINEP (ACC) and from the Brazilian Ministry of Health (ACC). Regina Goldenberg was supported by Fogarty International Grant - D43TW007129 (HBT).

References

[1] C. Chagas, "Nova tripanosomíase humana: estudos sobre a morfologia e o ciclo evolutivo do *Schizotrypanum cruzi* n. gen., n.sp., agente etiológico de nova entidade mórbida no homem," *Memórias do Instituto Oswaldo Cruz*, vol. 1, pp. 159–218, 1909.

[2] C. Chagas, "Nova entidade mórbida do homem: resumo geral de estudos etiológicos e clínicos," *Memórias do Instituto Oswaldo Cruz*, vol. 3, pp. 219–257, 1911.

[3] R. Salvatella, *Current Status of Chagas Disease*, Pan American Health Organization, Washington, DC, USA, 2006.

[4] Z. A. Andrade and S. G. Andrade, "Pathogenesis of Chagas' chronic myocarditis; importance of ischemic lesions," *Arquivos Brasileiros de Medicina*, vol. 45, no. 7-8, pp. 279–288, 1955.

[5] Z. A. Andrade and E. A. Lopes, "A histochemical study of experimental study of experimental Chagas' disease," *Revista do Instituto de Medicina Tropical de São Paulo*, vol. 19, pp. 236–242, 1963.

[6] M. B. Rosenbaum, "Chagasic myocardiopathy," *Progress in Cardiovascular Diseases*, vol. 7, no. 3, pp. 199–225, 1964.

[7] M. B. Rosenbaum and A. J. Alvarez, "The electrocardiogram in chronic chagasic myocarditis," *American Heart Journal*, vol. 50, no. 4, pp. 492–527, 1955.

[8] B. Moia and M. B. Rosenbaum, "The electrocardiogram in chronic Chagas' myocarditis," *Arquivos Brasileiros de Cardiologia*, vol. 13, pp. 236–243, 1960.

[9] F. Kierszenbaum, "Where do we stand on the autoimmunity hypothesis of Chagas disease?" *Trends in Parasitology*, vol. 21, no. 11, pp. 513–516, 2005.

[10] H. F. G. Freitas, P. R. Chizzola, Â. T. Paes, A. C. P. Lima, and A. J. Mansur, "Risk stratification in a Brazilian hospital-based cohort of 1220 outpatients with heart failure: role of Chagas' heart disease," *International Journal of Cardiology*, vol. 102, no. 2, pp. 239–247, 2005.

[11] E. A. Bocchi and A. Fiorelli, "The paradox of survival results after heart transplantation for cardiomyopathy caused by *Trypanosoma cruzi*," *The Annals of Thoracic Surgery*, vol. 71, no. 6, pp. 1833–1838, 2001.

[12] M. H. Soonpaa, A. I. Daud, G. Y. Koh, et al., "Potential approaches for myocardial regeneration," *Annals of the New York Academy of Sciences*, vol. 752, pp. 446–454, 1995.

[13] S. Makino, K. Fukuda, S. Miyoshi, et al., "Cardiomyocytes can be generated from marrow stromal cells in vitro," *The Journal of Clinical Investigation*, vol. 103, no. 5, pp. 697–705, 1999.

[14] S. Tomita, R.-K. Li, R. D. Weisel, et al., "Autologous transplantation of bone marrow cells improves damaged heart function," *Circulation*, vol. 100, supplement 19, pp. II247–II256, 1999.

[15] D. Orlic, J. Kajstura, S. Chimenti, et al., "Bone marrow cells regenerate infarcted myocardium," *Nature*, vol. 410, no. 6829, pp. 701–705, 2001.

[16] A. A. Kocher, M. D. Schuster, M. J. Szabolcs, et al., "Neovascularization of ischemic myocardium by human bone-marrow-derived angioblasts prevents cardiomyocyte apoptosis, reduces remodeling and improves cardiac function," *Nature Medicine*, vol. 7, no. 4, pp. 430–436, 2001.

[17] J. M. Nygren, S. Jovinge, M. Breitbach, et al., "Bone marrow-derived hematopoietic cells generate cardiomyocytes at a low frequency through cell fusion, but not transdifferentiation," *Nature Medicine*, vol. 10, no. 5, pp. 494–501, 2004.

[18] E. L. Olivares, V. P. Ribeiro, J. P. S. Werneck de Castro, et al., "Bone marrow stromal cells improve cardiac performance in healed infarcted rat hearts," *American Journal of Physiology*, vol. 287, no. 2, pp. H464–H470, 2004.

[19] C. Toma, M. F. Pittenger, K. S. Cahill, B. J. Byrne, and P. D. Kessler, "Human mesenchymal stem cells differentiate to a cardiomyocyte phenotype in the adult murine heart," *Circulation*, vol. 105, no. 1, pp. 93–98, 2002.

[20] C. E. Murry, M. H. Soonpaa, H. Reinecke, et al., "Haematopoietic stem cells do not transdifferentiate into cardiac myocytes

in myocardial infarcts," *Nature*, vol. 428, no. 6983, pp. 664–668, 2004.

[21] J. M. Nygren, S. Jovinge, M. Breitbach, et al., "Bone marrow-derived hematopoietic cells generate cardiomyocytes at a low frequency through cell fusion, but not transdifferentiation," *Nature Medicine*, vol. 10, no. 5, pp. 494–501, 2004.

[22] L. B. Balsam, A. J. Wagers, J. L. Christensen, T. Kofidis, I. L. Weissmann, and R. C. Robbins, "Haematopoietic stem cells adopt mature haematopoietic fates in ischaemic myocardium," *Nature*, vol. 428, no. 6983, pp. 668–673, 2004.

[23] D. Orlic, J. A. N. Kajstura, S. Chimenti, D. M. Bodine, A. Leri, and P. Anversa, "Transplanted adult bone marrow cells repair myocardial infarcts in mice," *Annals of the New York Academy of Sciences*, vol. 938, pp. 221–230, 2001.

[24] M. Gnecchi, H. He, O. D. Liang, et al., "Paracrine action accounts for marked protection of ischemic heart by Akt-modified mesenchymal stem cells," *Nature Medicine*, vol. 11, no. 4, pp. 367–368, 2005.

[25] A. A. Mangi, N. Noiseux, D. Kong, et al., "Mesenchymal stem cells modified with Akt prevent remodeling and restore performance of infarcted hearts," *Nature Medicine*, vol. 9, no. 9, pp. 1195–1201, 2003.

[26] M. B. P. Soares, R. S. Lima, L. L. Rocha, et al., "Transplanted bone marrow cells repair heart tissue and reduce myocarditis in chronic chagasic mice," *American Journal of Pathology*, vol. 164, no. 2, pp. 441–447, 2004.

[27] R. C. S. Goldenberg, L. A. Jelicks, F. S. A. Fortes, et al., "Bone marrow cell therapy ameliorates and reverses chagasic cardiomyopathy in a mouse model," *The Journal of Infectious Diseases*, vol. 197, no. 4, pp. 544–547, 2008.

[28] M. Harada, Y. Qin, H. Takano, et al., "G-CSF prevents cardiac remodeling after myocardial infarction by activating the Jak-Stat pathway in cardiomyocytes," *Nature Medicine*, vol. 11, no. 3, pp. 305–311, 2005.

[29] L. C. Guarita-Souza, K. A. T. Carvalho, V. Woitowicz, et al., "Simultaneous autologous transplantation of cocultured mesenchymal stem cells and skeletal myoblasts improves ventricular function in a murine model of Chagas disease," *Circulation*, vol. 114, supplement 1, pp. I120–I124, 2006.

[30] F. Vilas-Boas, G. S. Feitosa, M. B. P. Soares, et al., "Early results of bone marrow cell transplantation to the myocardium of patients with heart failure due to Chagas disease," *Arquivos Brasileiros de Cardiologia*, vol. 87, no. 2, pp. 159–166, 2006.

[31] B. R. Tura, H. F. Martino, L. H. Gowdak, et al., "Multicenter randomized trial of cell therapy in cardiopathies—MiHeart study," *Trials*, vol. 8, article 2, pp. 1–4, 2007.

[32] J. L. B. Jacob, F. V. Salis, M. A. Ruiz, and O. T. Greco, "Labeled stem cells transplantation to the myocardium of a patient with Chagas' disease," *Arquivos Brasileiros de Cardiologia*, vol. 89, no. 2, pp. e10–e11, 2007.