Journal of Thyroid Research

Thyroid Oncology

Guest Editors: Maria João M. Bugalho, Nelson Wohllk,
Ana O. Hoff, and Maria E. Cabanillas

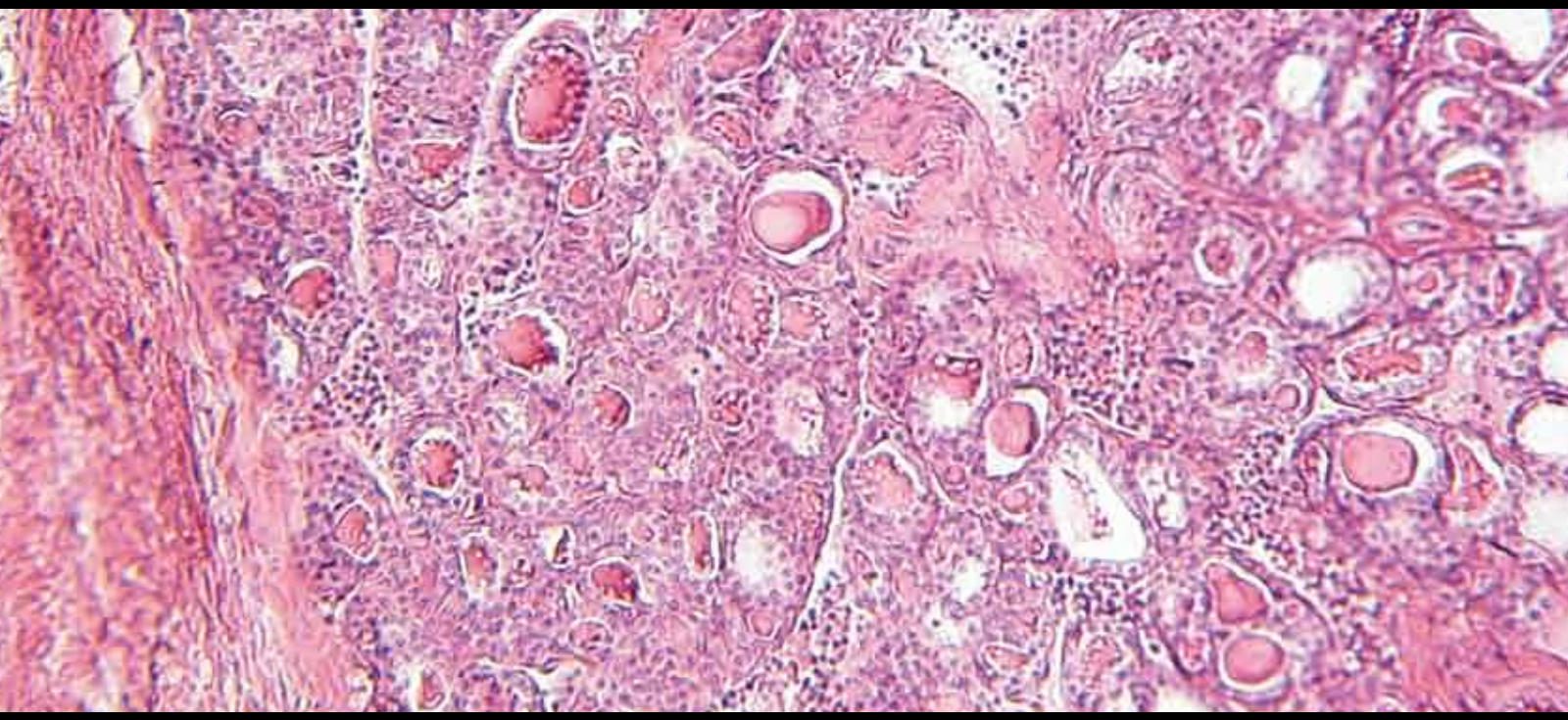

Thyroid Oncology

Journal of Thyroid Research

Thyroid Oncology

Guest Editors: Maria João M. Bugalho, Nelson Wohllk, Ana O. Hoff, and Maria E. Cabanillas

Editorial Board

Contents

SAGE-Hindawi Access to Research
Journal of Thyroid Research
Volume 2011, Article ID 467570, 3 pages
doi:10.4061/2011/467570

Editorial

Thyroid Oncology

Maria João M. Bugalho,[1,2] Nelson Wohllk,[3] Ana O. Hoff,[4] and Maria E. Cabanillas[5]

[1] *Serviço de Endocrinologia, Instituto Português de Oncologia, 1099-023 Lisboa, Portugal*
[2] *Faculdade de Ciências Médicas, Universidade Nova de Lisboa, 1169-056 Lisboa, Portugal*
[3] *Seccion Endocrinologia, Hospital del Salvador, Santiago de Chile, Universidad de Chile, Chile*
[4] *Departamento de Endocrinologia, Instituto do Cancer do Estado de São Paulo, Faculdade de Medicina da Universidade de São paulo, São Paulo, Brazil*
[5] *Department of Endocrine Neoplasia and Hormonal Disorders, University of Texas M.D. Anderson Cancer Center, Houston, TX 77030, USA*

Correspondence should be addressed to Maria João M. Bugalho, mjbugalho@ipolisboa.min-saude.pt

Received 20 July 2011; Accepted 20 July 2011

We are pleased to bring you the Special Issue of the Journal Thyroid Research dedicated to Thyroid Oncology.

The incidence of thyroid cancer has been increasing in recent decades mainly due to an increase in papillary thyroid carcinomas (PTCs). Among these, tumors ≤ 1 cm increased the most. Whether this represents a higher sensitivity to detect smaller tumors or depends on other factors such as environmental factors remains unclear [1–3].

According to the World Health Organization (WHO), papillary thyroid carcinomas measuring 1 cm or less are designated as papillary thyroid microcarcinomas (PTMCs).

Incidentally diagnosed PTMCs are generally indolent tumors. However, PTMCs detected due to clinically suspected and histological confirmed lymph node metastases or associated with extra thyroidal extension may have a more aggressive behavior [4, 5]. Thus, it is inaccurate and misleading to regard all PTMCs patients as having the same level of risk. Most studies based their conclusions on clinicopathological factors. Recently, Kim et al. [6] showed that the gene expression profiles of PTMCs were not different from those of larger PTCs and suggested that PTMCs may represent an earlier stage of the same disease.

Differences in the form of presentation between papillary microcarcinomas and papillary carcinomas of larger size are discussed in this issue by C. Zafon et al., who concluded that patients with a low aggressive profile were significantly older than the remaining patients. This interesting finding awaits confirmation by other studies and larger series.

Fine-needle aspiration cytology (FNAC) of thyroid nodules is highly sensitive in the diagnosis of papillary, medullary, and anaplastic carcinomas. Distinction between benign lesions, such as follicular adenoma or nodular adenomatous goiter, and follicular carcinoma or follicular variant of papillary carcinoma remains a problem. The final diagnosis depends on histological evaluation.

The study by M. Bonzanini et al. addresses practical issues related to the existence of different FNAC classifications [7, 8] and was designed to retrospectively analyze the benefits of subclassifying the "undetermined" cytologic reports into two categories: "follicular lesion" (FL) and "atypia of undetermined significance" (AUS). Data obtained on this basis indicate that AUS is associated with higher malignancy rate than FL. Moreover, the authors provide data in favor of an integrated analysis of clinical, cytological, biochemical, and ecographic findings to improve diagnostic accuracy.

Young patients with differentiated thyroid carcinoma (DTC) represent a particular group. Childhood DTC is more frequently multicentric and is associated with a more locally aggressive and more frequent distant disease than its adult counterpart. Nonetheless, recent series [9], with long followup, have shown that fewer than 2% of children die from DTC contrasting to a much higher number of patients dying from nonthyroid malignancy. Further more, seventy-three percent of those who died from nonthyroid malignancy had received adjuvant radioactive iodine (^{131}I) therapy.

In children, the lungs are almost the sole distant metastatic site, and pulmonary metastases are nearly always functional [10].

A risk-stratified approach is probably the best choice to optimize treatment and reduce risks associated with therapy [11]. To choose among the classical risk stratification systems, the most adequate one for young patients is still a matter of debate. F. Vaisman et al. discuss these and other points.

Medullary thyroid carcinoma (MTC) is a neuroendocrine tumor derived from parafollicular cells of the thyroid that occurs in both sporadic and hereditary forms. MTC spreads early to lymph nodes and is both chemo- and radioresistant. Early surgery is the only therapeutic approach potentially curative thus explaining the importance of an early detection.

Activating mutations of the rearranged during transfection (*RET*) proto-oncogene were first described in patients with familial forms in 1993 [12, 13]. Additionally, somatic *RET* mutations were identified in up to 65% of patients with sporadic MTC [14, 15]. The *RET* gene is located in chromosome 10q11.2 and codes for a tyrosine kinase (TK) receptor. These molecular advances made possible to define genotype-phenotype correlations; the International RET Mutation Consortium and the American Thyroid Association provided guidelines for the timing of prophylactic surgery based on genetic analysis [16, 17]. Moreover, promising targeted therapies have been developed for progressive and advanced MTC.

Genetic screening became a routine, worldwide, in the management of MTC patients at a preclinical stage. Results presented by M. Hedayati et al. in the current issue, in addition to those previously presented by Alvandi et al. [18], are illustrative of the mutational profile observed among Iranian patients with MTC.

Based on the understanding of the altered molecular pathways underlying MTC, a number of "targeted" therapies have been developed. K. Gómez et al. present a comprehensive review of the most promising TK inhibitors for the treatment of MTC and draw attention to possible adverse effects and drug resistance.

Standard treatment of DTC includes surgery, ^{131}I and thyroid hormone suppressive therapy. ^{131}I, selectively targeting thyroid cells, was probably the first targeted therapy for cancer. For those cases refractory to^{131}I and for patients with local aggressive or metastatic disease, until recently, there were no effective treatments.

During the last decades, a large body of information has been generated on the molecular alterations, particularly on the role of oncogenic kinases involved in thyroid carcinomas. Based on this information, thyroid became, once more, a model for the use of new targeted therapies specially the kinase inhibitors. Interest in this field grew, and future holds promise. The role for combinatory treatments is still not defined.

Papers by H. Prazeres et al. and S. B. Bales et al. review genomic changes in thyroid cancer (DTC and MTC) and discuss how this information might be used to improve targeted therapies.

Epigenetic mechanisms are likely to play an important role in thyroid cancers particularly by modulating tumor progression. Whereas mutations generally alter intracellular signaling pathways, the epigenetic mechanisms may interfere with tumor environment as recently shown [19]. In this issue, O. P. Eze et al. present a thorough revision of this theme and discuss implications for future therapies designed to attain different pathways.

Clinical trials of TK inhibitors in patients with advanced thyroid cancer have shown promising preliminary results, justifying enthusiasm among physicians and expectation among patients. The Food and Drug Administration recently approved Vandetanib for local advanced or metastatic MTC.

Despite the promising results, TK inhibitors have a broad spectrum of adverse effects. Considering that this class of therapeutic agents is to be used as chronic treatment, clinicians responsible for their use need to be familiar with adverse effects associated with TK inhibitors and prepared to manage them. M. E. Cabanillas et al. provide us with a comprehensive revision and practical tips to optimize treatment and minimize toxicity.

We are grateful to all contributors, reviewers, and the editorial staff.

Maria João M. Bugalho
Nelson Wohllk
Ana O. Hoff
Maria E. Cabanillas

References

[1] L. Davies and H. G. Welch, "Increasing incidence of thyroid cancer in the United States, 1973–2002," *Journal of the American Medical Association*, vol. 295, no. 18, pp. 2164–2167, 2006.

[2] J. D. Cramer, P. Fu, K. C. Harth, S. Margevicius, and S. M. Wilhelm, "Analysis of the rising incidence of thyroid cancer using the Surveillance, Epidemiology and End Results national cancer data registry," *Surgery*, vol. 148, no. 6, pp. 1147–1152, 2010.

[3] G. P. Yu, J. C. L. Li, D. Branovan, S. McCormick, and S. P. Schantz, "Thyroid cancer incidence and survival in the national cancer institute surveillance, epidemiology, and end results race/ethnicity groups," *Thyroid*, vol. 20, no. 5, pp. 465–473, 2010.

[4] C. Durante, M. Attard, M. Torlontano et al., "Identification and optimal postsurgical follow-up of patients with very low-risk papillary thyroid microcarcinomas," *Journal of Clinical Endocrinology and Metabolism*, vol. 95, no. 11, pp. 4882–4888, 2010.

[5] S. Agarwal, A. Agarwal, and G. Chand, "Incidental papillary microcarcinoma of the thyroid-further evidence of a very low malignant potential: a retrospective clinicopathologic study with up to 30 years of follow-up," *Annals of Surgical Oncology*. In press.

[6] H. Y. Kim, W.-Y. Park, K. E. Lee et al., "Comparative analysis of gene expression profiles of papillary thyroid microcarcinoma and papillary thyroid carcinoma," *Journal of Cancer Research and Therapeutics*, vol. 6, no. 4, pp. 452–457, 2010.

[7] R. G. Gheri, E. Romoli, V. Vezzosi et al., "Follicular nodules (THY3) of the thyroid: we recommend surgery," *Journal of Endocrinological Investigation*. In press.

[8] R. Paschke, L. Hegedüs, E. Alexander, R. Valcavi, E. Papini, and H. Gharib, "Thyroid nodule guidelines: agreement, disagreement and need for future research," *Nature Reviews Endocrinology*, vol. 7, no. 6, pp. 354–361, 2011.

[9] I. D. Hay, T. Gonzalez-Losada, M. S. Reinalda, J. A. Honetschlager, M. L. Richards, and G. B. Thompson, "Long-term outcome in 215 children and adolescents with papillary thyroid cancer treated during 1940 through 2008," *World Journal of Surgery*, vol. 34, no. 6, pp. 1192–1202, 2010.

[10] B. Jarząb, D. Handkiewicz-Junak, and J. Włoch, "Juvenile differentiated thyroid carcinoma and the role of radioiodine in its treatment: a qualitative review," *Endocrine-Related Cancer*, vol. 12, no. 4, pp. 773–803, 2005.

[11] G. Francis and S. G. Waguespack, "An individualized approach to the child with thyroid cancer," *Expert Review of Endocrinology and Metabolism*, vol. 6, no. 1, pp. 85–92, 2011.

[12] H. Donis-Keller, S. Dou, D. Chi et al., "Mutations in the RET proto-oncogene are associated with MEN 2A and FMTC," *Human Molecular Genetics*, vol. 2, no. 7, pp. 851–856, 1993.

[13] L. M. Mulligan, J. B. J. Kwok, C. S. Healey et al., "Germ-line mutations of the RET proto-oncogene in multiple endocrine neoplasia type 2A," *Nature*, vol. 363, no. 6428, pp. 458–460, 1993.

[14] N. Wohllk, G. J. Cote, M. M. J. Bugalho et al., "Relevance of RET proto-oncogene mutations in sporadic medullary thyroid carcinoma," *Journal of Clinical Endocrinology and Metabolism*, vol. 81, no. 10, pp. 3740–3745, 1996.

[15] M. M. Moura, B. M. Cavaco, A. E. Pinto et al., "Correlation of RET somatic mutations with clinicopathological features in sporadic medullary thyroid carcinomas," *British Journal of Cancer*, vol. 100, no. 11, pp. 1777–1783, 2009.

[16] M. L. Brandi, R. F. Gagel, A. Angeli et al., "Consensus: Guidelines for diagnosis and therapy of MEN type 1 and type 2," *Journal of Clinical Endocrinology and Metabolism*, vol. 86, no. 12, pp. 5658–5671, 2001.

[17] American Thyroid Association Guidelines Task Force, R. T. Kloos, C. Eng et al., "Medullary thyroid cancer: management guidelines of the American Thyroid Association," *Thyroid*, vol. 19, no. 6, pp. 565–612, 2009.

[18] E. Alvandi, S. M. Akrami, M. Chiani et al., "Molecular analysis of the RET proto-oncogene key exons in patients with medullary thyroid carcinoma: a comprehensive study of the iranian population," *Thyroid*, vol. 21, no. 4, pp. 373–382, 2011.

[19] H. Prazeres, J. Torres, F. Rodrigues et al., "Chromosomal, epigenetic and microRNA-mediated inactivation of LRP1B, a modulator of the extracellular environment of thyroid cancer cells," *Oncogene*, vol. 30, no. 11, pp. 1302–1317, 2011.

SAGE-Hindawi Access to Research
Journal of Thyroid Research
Volume 2011, Article ID 639156, 5 pages
doi:10.4061/2011/639156

Clinical Study

Differences in the Form of Presentation between Papillary Microcarcinomas and Papillary Carcinomas of Larger Size

Carles Zafon,[1] Juan Antonio Baena,[2] Josep Castellví,[3] Gabriel Obiols,[1] Gabriela Monroy,[1] and Jordi Mesa[1]

[1] *Department of Endocrinology, Hospital General Universitari Vall d'Hebron, Pg. Vall d'Hebron 119-129, 08035 Barcelona, Spain*
[2] *Department of Surgery, Unit of endocrinological surgery, Hospital General Universitari Vall d'Hebron, 08035 Barcelona, Spain*
[3] *Department of Pathology, Hospital General Universitari Vall d'Hebron, 08035 Barcelona, Spain*

Correspondence should be addressed to Carles Zafon, 26276czl@comb.cat

Received 12 August 2010; Revised 20 October 2010; Accepted 18 November 2010

Academic Editor: Maria João M. Bugalho

Papillary thyroid carcinomas (PTCs) with a diameter ≤1 cm are referred to as papillary microcarcinomas (PTMCs). The prognostic factors for PTMCs have not been defined. Different clinical and histopathologic variables were studied in 152 PTCs, including 74 PTMCs and 78 PTCs of larger size. We found that PTMCs are associated with less multifocality ($P = .046$) and bilaterality ($P = .003$), fewer lymphadenectomies ($P < .001$), and a higher rate of incidental tumours ($P < .001$). Moreover, patients with a low aggressive profile were significantly older than the remaining patients (54 ± 13.7 years versus 45.8 ± 13.1 years; $P = .001$). In conclusion PTMCs show significant differences compared to PTCs of larger size in the form of presentation. Furthermore, it is possible that the classic risk factors, which are well validated in PTCs, such as age, must be cautiously interpreted in the current increasing subgroup of PTMCs.

1. Introduction

It has been clearly demonstrated that there is an increasing worldwide incidence of papillary thyroid carcinomas (PTCs). It is uncertain whether this is a real phenomenon, or whether it is due to an increased rate of detection [1]. Practices for management of thyroid diseases have changed over the past few decades. The wide availability of ultrasound (US) and fine needle aspiration biopsy (FNAB) and the improved accuracy of histopathologic examination of surgical specimens have been suggested to be reasons for the increased rate of detection. Moreover, among the new cases, the highest incidence has been observed in the smallest tumors [2]. In the USA, 49% of the increased incidence of PTCs consisted of cancers measuring ≤1 cm [3]. In Europe, Leenhardt et al. [4] reported that the proportion of tumors of this size increased from 18.4% between 1983 and 1987 to 43.1% between 1998 and 2001 [4]. Similar results have been confirmed by other authors worldwide [2, 5–8].

PTCs measuring ≤1 cm are referred to as papillary thyroid microcarcinomas (PTMCs) [9]. Although PTMCs are not recognized as a specific entity in the tumour, node, and metastasis (TNM) classification, PTMCs are considered a subset of PTCs that exhibit a more benign behavior. PTMCs usually follow an indolent course and carry an excellent prognosis. Distant metastases and mortality rates are reported to be <0.5% for PTMCs [10]. Two large series have recently confirmed the excellent prognosis for PTMCs in long-term followup [5, 11]. Nevertheless, some authors suggest that there exist a subgroup of PTMCs that can be aggressive, requiring therapeutic management similar to larger tumors [12]. Thus, no agreement has been reached about the optimal treatment of PTMCs. In recent years, several clinical and histologic risk factors for aggressiveness have been identified in PTMCs, such as size ≤5 mm, multifocality, capsular invasion, tumor extension beyond the parenchyma, lymph node involvement, and the extent of primary surgery [12–17]. In contrast, some studies have failed to identify independent prognostic factors, arguing that to distinguish PTCs on the basis of size alone may be clinically irrelevant [18, 19]. Because PTMCs are being diagnosed with increasing frequency, identification of specific prognostic factors is of outmost importance.

In the present study, we describe the clinical and pathologic presentation of PTMCs, compared with papillary thyroid carcinomas of larger size (LPTCs). We have analyzed the classic risk factors and studied the clinical and histologic characteristics present at the time of diagnosis which were associated with a higher risk of recurrence in PTMCs, such as multifocality, lymph node metastases, and mode of detection (incidental versus nonincidental tumors).

2. Methods

PTMCs were defined as PTCs measuring ≤1 cm in greatest diameter. Mode of detection refers to incidental (IPTMCs) or nonincidental tumors (NIPTMCs). IPTMCs were identified in patients undergoing surgery for reasons unrelated to a thyroid malignancy, whereas patients with NIPTMCs underwent thyroidectomy for suspected malignancies. Multifocal disease was defined when >1 focus of PTCs was found in the thyroidectomy specimen. The following clinical variables were considered in the analysis: patient age, mode of detection, and extent of disease. The histopathologic variables after postoperative pathologic examination included the maximum diameter of the primary tumour, multifocality, bilaterality, extrathyroid extension, and lymph node metastases. Patients with PTMCs discovered incidentally, without multifocality, and without lymph node involvement were considered at low risk for developing recurrences. The confidentiality of patient information was absolutely maintained. Data are presented as the mean ± SD. Statistical analysis was performed by Fisher's exact test for univariate analysis and by Student's t-test to compare continuous variables between groups. All tests were two-tailed. The levels of statistical significance are presented as p values. It was assumed that the observed differences were statistically significant at a $P < .05$ level.

3. Results

Between 2000 and 2009, 152 patients with PTCs were treated in our institution. Among these cases, there were 74 (48.7%) PTMCs and 78 (51.3%) LPTCs.

3.1. Microcarcinoma. The PTMC series included 59 females and 15 males (the female-to-male ratio was approximately 3.9). The mean age at the time of diagnosis was 50.1 ± 13.2 years. Of the 74 cases, 67 (90.5%) underwent total or near-total thyroidectomy, and only 7 (9.5%) underwent lobectomies. The mean tumour size was 5.7 ± 2.6 mm. The pathology reports showed classic variant PTMCs in 64 patients (86%), and follicular variants in 10 patients (14%). Multifocal disease was documented in 26 patients (35.1%). The patients with multifocal disease were younger than patients with a unique focus (45.9 ± 10.2 years versus 52.5 ± 14.2 years; $P = .039$). Contralateral involvement was observed in 7 of 26 patients (27%) with multifocal tumors. Regional lymph nodes were removed in 24 patients (32.4%); of these, 12 (50%) had nodal tumor involvement.

Overall, 72.2% of tumors (52 of 72) presented as IPTMCs (no information was available in 2 cases). In the other 20 cases (27.8%), PTMCs were diagnosed by preoperative US-guided FNABs. In patients with IPTMCs, the indications for surgery were as follows: 29 nontoxic multinodular goiters, 7 toxic multinodular goiters, and 16 solitary nodules. The difference in mean tumour size was statistically significant among the IPTMCs (5 ± 2.3 mm) and NIPTMCs (7.6 ± 2.6 mm; $P < .001$). Multifocality was present in 13 (65%) of 20 patients classified as NIPTMCs, whereas multifocality was present in only 11 (21%) of 52 patients with IPTMCs ($P < .001$).

3.2. Larger Tumours. Tumors >1 cm occurred in 62 females and 16 males (the female-to-male ratio was approximately 3.9). The mean age at the time of diagnosis was 46.2 ± 14.1 years. The primary surgical treatment consisted of total or near-total thyroidectomies in 76 patients and lobectomies in 2 patients. The mean tumor size was 25.21 ± 11.8 mm. The pathology reports showed classic variant LPTCS in 54 patients (69.2%), follicular variant LPTCs in 21 patients (26.9%), and one case each of columnar cell, cribiform-morular variant, and clear cell LPTCs. In this group, multifocality was found in 39 (50%) samples. The age at presentation was not different in patients with and without multifocality. Contralateral involvement occurred in 25 of 39 patients (64%) with multifocal tumours. Lymph node dissection was performed in 60 patients (77%); of these, 36 patients (60%) had nodal tumor involvement.

Only 11 (15.5%) of 71 cases were classified as incidental tumors (no information was available in 7 cases). Of the indications for surgery were as follows: 7 nontoxic multinodular goiters, 3 solitary nodules, and 1 toxic multinodular goiter. Neither tumor size nor multifocality was significantly different among the incidental and nonincidental LPTCs.

3.3. PTMCs versus LPTCs. Table 1 shows the characteristics of both groups. Age and gender were not statistically different between the two groups of patients. However, based on the mode of presentation, patients with IPTMCs were significantly older than patients with incidental LPTCs (51.9 ± 13.5 years versus 41.4 ± 7.95 years; $P = .016$). Moreover, apart from size ($P < .0001$), patients with PTMCs presented with multifocality ($P = .046$) and bilaterality ($P = .003$) less often, fewer lymphadenectomies ($P < .001$), and a higher rate of incidental tumours ($P < .001$). In contrast, in patients in whom the lymph nodes were removed, there were no differences in the frequency of nodal metastases.

3.4. Aggressive Cases. Among all the 152 patients with PTCs, 40 patients (26.3%) in whom PTMCs were discovered incidentally, without multifocality, and without lymph node involvement, were considered at a low risk for developing recurrences. These patients with a low aggressive profile were significantly older than the rest of the patients (54 ± 13.7 years versus 45.8 ± 13.1 years; $P = .001$). Moreover, the low aggressive profile was observed in 28 (36.8%) of 76 patients >45 years of age and in 12 (17.9%) of 67 patients <45 years

Table 1: Differences between cases with papillary thyroid microcarcinomas (PTMCs) from those with papillary thyroid carcinomas of larger size (LPTCs).

	PTMC (n = 74)	LPTC (n = 78)	P
Gender (female/male)	15/59 (79.7%/20.3%)	16/62 (79.5%/20.5%)	ns
Age (y)	50.17 ± 13.22	46.29 ± 14.12	ns
Size (mm)	5.7 ± 2.6	25.2 ± 11.8	<.001
Multifocality	26/74 (35.1%)	39/78 (50%)	.046
Lymphadenectomies	24/74 (32.4%)	60/78 (77%)	<.001
Lymph M1	12/24 (50%)	36/60 (60%)	ns
Incidental	52/72 (72.2%)	11/72 (15.2%)	<.001

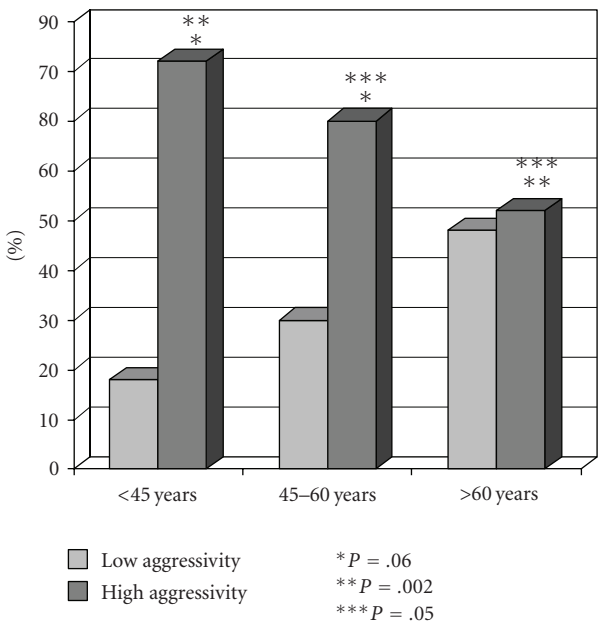

Figure 1: Patients with a low aggressive profile are significantly older than patients with a high aggressive profile.

of age (P = .006). Finally, patients ≥60 years of age had more cases with low aggressiveness compared to patients <45 years of age (P = .002), and to patients between 45 and 60 years of age (P = .05). This data is shown in Figure 1.

4. Discussion

PTMC is defined as PTC measuring ≤1 cm in size [9]. This variant is also known as occult papillary carcinoma, latent papillary carcinoma, small papillary carcinoma, and papillary microtumor [20]. The current increase in incidence of PTC worldwide is mainly attributed to the corresponding increase in the diagnosis of PTMCs. In most recent series, especially the series that have analyzed cases from the last decade, PTMCs comprise nearly one-half of all the cases of PTCs [2, 3, 8, 21, 22]. Our series confirms this data. PTMCs are considered a subset of PTCs that exhibit a more benign behavior. Distant metastases and mortality rates are reported to be <0.5% in patients with PTMCs [10]. Hay et al. [5] reported no difference between the observed number of deaths and the expected number of deaths in a cohort of 900 cases. Appetecchia et al. [23] reported that the outcome of PTMCs was favorable, even in the presence of lymph node metastases and local invasion. In contrast, some authors have suggested that there exist a subset of PTMCs that can be aggressive, requiring therapeutic management similar to larger PTCs [6, 12]. Thus, no agreement has been reached about the optimal treatment of PTMCs. Some authors recommend an aggressive approach to PTMCs, while other authors suggest that no further treatment is needed after lobectomy or thyroidectomy. Moreover, it has even been proposed that observation without surgical treatment is appropriate [24].

Because the number of deaths is very small in patients with PTMCs, in the majority of series authors use the rate of recurrence as a marker of poor clinical outcome. Local and regional lymph node recurrences have been observed with a prevalence rate between 2% and 5.7% [5, 25–27].

In recent years, some specific markers for aggressiveness have been identified [12–17]. Three of the most accepted factors are multifocality, lymph node metastasis, and the mode of diagnosis.

PTMCs frequently present as a multifocal process. Multiple foci are reported in approximately 7%–56% of cases [5, 6, 10, 28]. A number of clinical studies have shown that patients with ≥ two foci had a higher recurrence rate and cancer mortality than those with unifocal PTMCs [5, 29]. Baudin et al. [30] reported that only two parameters influenced PTMC recurrences, one of which was multifocality. Moreover, multifocality has been associated with a high incidence of contralateral lobe involvement [31] and is an independent risk factor for metastases [32]. Hence, multifocal PTMCs have been considered to have a poor prognosis. In our series, we have detected a significantly higher rate of multifocality in LPTCs than in PTMCs.

PTMCs also show a high incidence of regional lymph node metastasis, occurring in 12%–64% of patients [6, 25, 33–36]. Wada et al. [37] reported that 64.1% and 44.5% of patients have central and ipsilateral node involvement, respectively, and two-thirds of patients have lymph node metastasis in at least one of the two compartments. It has been described that cases with positive lymph nodes have a higher risk of recurrence [38]. Kim et al. [26] found that lateral cervical node metastasis was the most powerful independent predictor of clinical recurrence. However, other authors have reported that the outcome of PTMCs is favorable, even in the presence of lymph node metastases [5, 23, 37, 39]. Prophylactic neck dissection is not routine in our hospital; node resection was not performed in the incidentally discovered cases. Therefore, the true number of positive lymph nodes is unknown; however, it is interesting to note that among patients in whom lymphadenectomy was performed, the rate of metastasis was not different between PTMCs and LPTCs.

Three circumstances may lead to the detection of a PTMC, as follows, PTMC found at autopsy, PTMC found incidentally in specimens of the thyroid removed for benign thyroid disease, and clinical PTMCs diagnosed before

surgery [40]. Although the prevalence is highly variable, >70% of PTMCs correspond to IPTMCs [10]. It has been suggested that clinical and biological behaviours may differ between IPTMCs and NIPTMCs [41, 42]. Some authors have found that overt tumors are associated with a higher incidence of multicentricity, extrathyroidal involvement, lymphovascular invasion, higher stage, risk of relapse, and death [11, 42–45]. Hence, IPTMCs are associated with a better prognosis, whereas NIPTMCs may have more aggressive behavior. In like manner, we have found significant differences between both modes of presentation in relation to tumor size, multifocality, and age in the group of patients with PTMCs, whereas there were no such differences in tumors >1 cm in size.

Age is considered to be the most important prognostic factor in PTCs and is included in all of the prognostic scoring systems. However, some investigators have failed to show that age affects the outcome of patients with PTMCs [15, 32, 34, 38, 43, 46, 47]. It is interesting to note that in our series, younger age is associated with a higher frequency of specific markers for aggressiveness. Thus, older patients have more IPTMCs without adverse markers, such as multifocality or lymph node metastases. Moreover, the group of patients >60 years of age has a higher incidence of cases with a lower risk of developing later recurrences than the rest of the patients.

In recent years, some of the molecules involved in neoplastic transformation have been explored as markers to assess the biological aggressiveness of PTMC [22, 48]. However, their use is at present not relevant to clinical decision making.

In summary, PTMCs exhibit significant differences in presentation from LPTCs. It is possible that the classic risk factors, which are well validated for PTCs, such as age, must be cautiously interpreted in the current increasing subgroup of PTMCs.

Conflict of Interests

The authors declare that they have no conflict of interests.

References

[1] S. Grodski and L. Delbridge, "An update on papillary microcarcinoma," *Current Opinion in Oncology*, vol. 21, no. 1, pp. 1–4, 2009.

[2] M. I. C. V. Cordioli, M. H. B. S. Canalli, and M. H. C. Coral, "Increase incidence of thyroid cancer in Florianopolis, Brazil: comparative study of diagnosed cases in 2000 and 2005," *Arquivos Brasileiros de Endocrinologia e Metabologia*, vol. 53, no. 4, pp. 453–460, 2009.

[3] L. Davies and H. G. Welch, "Increasing incidence of thyroid cancer in the United States, 1973–2002," *Journal of the American Medical Association*, vol. 295, no. 18, pp. 2164–2167, 2006.

[4] L. Leenhardt, P. Grosclaude, and L. Chérié-Challine, "Increased incidence of thyroid carcinoma in france: a true epidemic or thyroid nodule management effects? Report from the french thyroid cancer committee," *Thyroid*, vol. 14, no. 12, pp. 1056–1060, 2004.

[5] I. D. Hay, M. E. Hutchinson, T. Gonzalez-Losada et al., "Papillary thyroid microcarcinoma: a study of 900 cases observed in a 60-year period," *Surgery*, vol. 144, no. 6, pp. 980–988, 2008.

[6] J. Lee, Y. Rhee, S. Lee et al., "Frequent, aggressive behaviors of thyroid microcarcinomas in Korean patients," *Endocrine Journal*, vol. 53, no. 5, pp. 627–632, 2006.

[7] H. W. Lin and N. Bhattacharyya, "Survival impact of treatment options for papillary microcarcinoma of the thyroid," *Laryngoscope*, vol. 119, no. 10, pp. 1983–1987, 2009.

[8] A. Zengi, M. Karadeniz, M. Erdogan et al., "Does chernobyl accident have any effect on thyroid cancers in Turkey? A retrospective review of thyroid cancers from 1982 to 2006," *Endocrine Journal*, vol. 55, no. 2, pp. 325–330, 2008.

[9] R. Lloyd, R. De Lellis, P. Heitz et al., *World Health Organization Classification of Tumors: Pathology and Genetics of Tumors of the Endocrine Organs*, IARC Press, Lyon, France, 2004.

[10] E. Roti, E. C. degli Uberti, M. Bondanelli, and L. E. Braverman, "Thyroid papillary microcarcinoma: a descriptive and meta-analysis study," *European Journal of Endocrinology*, vol. 159, no. 6, pp. 659–673, 2008.

[11] S. Noguchi, H. Yamashita, S. Uchino, and S. Watanabe, "Papillary microcarcinoma," *World Journal of Surgery*, vol. 32, no. 5, pp. 747–753, 2008.

[12] C. Page, A. Biet, P. Boute, P. Cuvelier, and V. Strunski, "'Aggressive papillary' thyroid microcarcinoma," *European Archives of Oto-Rhino-Laryngology*, vol. 266, no. 12, pp. 1959–1963, 2009.

[13] N. Ö. Küçük, P. Tari, E. Tokmak, and G. Aras, "Treatment for microcarcinoma of the thyroid—clinical experience," *Clinical Nuclear Medicine*, vol. 32, no. 4, pp. 279–281, 2007.

[14] S. H. Lee, S. S. Lee, S. M. Jin, J. H. Kim, and Y. S. Rho, "Predictive factors for central compartment lymph node metastasis in thyroid papillary microcarcinoma," *Laryngoscope*, vol. 118, no. 4, pp. 659–662, 2008.

[15] G. Mercante, A. Frasoldati, C. Pedroni et al., "Prognostic factors affecting neck lymph node recurrence and distant metastasis in papillary microcarcinoma of the thyroid: results of a study in 445 patients," *Thyroid*, vol. 19, no. 7, pp. 707–716, 2009.

[16] M. R. Pelizzo, I. M. Boschin, A. Toniato et al., "Papillary thyroid microcarcinoma (PTMC): prognostic factors, management and outcome in 403 patients," *European Journal of Surgical Oncology*, vol. 32, no. 10, pp. 1144–1148, 2006.

[17] E. Roti, R. Rossi, G. Trasforini et al., "Clinical and histological characteristics of papillary thyroid microcarcinoma: results of a retrospective study in 243 patients," *Journal of Clinical Endocrinology and Metabolism*, vol. 91, no. 6, pp. 2171–2178, 2006.

[18] N. Arora, H. K. Turbendian, M. A. Kato, T. A. Moo, R. Zarnegar, and T. J. Fahey, "Papillary thyroid carcinoma and microcarcinoma: is there a need to distinguish the two?" *Thyroid*, vol. 19, no. 5, pp. 473–477, 2009.

[19] C. Cappelli, M. Castellano, M. Braga et al., "Aggressiveness and outcome of papillary thyroid carcinoma (PTC) versus microcarcinoma (PMC): a mono-institutional experience," *Journal of Surgical Oncology*, vol. 95, no. 7, pp. 555–560, 2007.

[20] J. Rosai, V. A. LiVolsi, M. Sobrinho-Simoes, and E. D. Williams, "Renaming papillary microcarcinoma of the thyroid gland: the Porto proposal," *International Journal of Surgical Pathology*, vol. 11, no. 4, pp. 249–251, 2003.

[21] M. Colonna, A. V. Guizard, C. Schvartz et al., "A time trend analysis of papillary and follicular cancers as a function of tumour size: a study of data from six cancer registries in France

(1983–2000)," *European Journal of Cancer*, vol. 43, no. 5, pp. 891–900, 2007.

[22] D. J. Lim, K. H. Baek, Y. S. Lee et al., "Clinical, histopathological, and molecular characteristics of papillary thyroid microcarcinoma," *Thyroid*, vol. 17, no. 9, pp. 883–888, 2007.

[23] M. Appetecchia, G. Scarcello, E. Pucci, and A. Procaccini, "Outcome after treatment of papillary thyroid microcarcinoma," *Journal of Experimental and Clinical Cancer Research*, vol. 21, no. 2, pp. 159–164, 2002.

[24] Y. Ito, T. Uruno, K. Nakano et al., "An observation trial without surgical treatment in patients with papillary microcarcinoma of the thyroid," *Thyroid*, vol. 13, no. 4, pp. 381–387, 2003.

[25] N. Besic, G. Pilko, R. Petric, M. Hocevar, and J. Zgajnar, "Papillary thyroid microcarcinoma: prognostic factors and treatment," *Journal of Surgical Oncology*, vol. 97, no. 3, pp. 221–225, 2008.

[26] T. Y. Kim, S. J. Hong, J. M. Kim et al., "Prognostic parameters for recurrence of papillary thyroid microcarcinoma," *BMC Cancer*, vol. 8, article 296, 2008.

[27] M. R. Pelizzo, I. M. Boschin, A. Toniato et al., "Natural history, diagnosis, treatment and outcome of papillary thyroid microcarcinoma (PTMC): a mono-institutional 12-year experience," *Nuclear Medicine Communications*, vol. 25, no. 6, pp. 547–552, 2004.

[28] M. Dietlein, W. A. Luyken, H. Schicha, and A. Larena-Avellaneda, "Incidental multifocal papillary microcarcinomas of the thyroid: is subtotal thyroidectomy combined with radioiodine ablation enough?" *Nuclear Medicine Communications*, vol. 26, no. 1, pp. 3–8, 2005.

[29] J. D. Lin, T. C. Chao, C. Hsueh, and S. F. Kuo, "High recurrent rate of multicentric papillary thyroid carcinoma," *Annals of Surgical Oncology*, vol. 16, no. 9, pp. 2609–2616, 2009.

[30] E. Baudin, J. P. Travagli, J. Ropers et al., "Microcarcinoma of the thyroid gland the Gustave-Roussy Institute experience," *Cancer*, vol. 83, no. 3, pp. 553–559, 1998.

[31] E. Kim, T. Kim, J. Koh et al., "Completion thyroidectomy in patients with thyroid cancer who initially underwent unilateral operation," *Clinical Endocrinology*, vol. 61, no. 1, pp. 145–148, 2004.

[32] K. Gülben, U. Berberoğlu, O. Çelen, and H. H. Mersin, "Incidental papillary microcarcinoma of the thyroid—factors affecting lymph node metastasis," *Langenbeck's Archives of Surgery*, vol. 393, no. 1, pp. 25–29, 2008.

[33] S. Choi, T. Kim, J. Lee et al., "Is routine central neck dissection necessary for the treatment of papillary thyroid microcarcinoma?" *Clinical and Experimental Otorhinolaryngology*, vol. 1, pp. 41–45, 2008.

[34] Y. S. Chung, J. Y. Kim, JA. S. Bae et al., "Lateral lymph node metastasis in papillary thyroid carcinoma: results of therapeutic lymph node dissection," *Thyroid*, vol. 19, no. 3, pp. 241–246, 2009.

[35] Y. C. Lim, E. C. Choi, Y. H. Yoon, E. H. Kim, and B. S. Koo, "Central lymph node metastases in unilateral papillary thyroid microcarcinoma," *British Journal of Surgery*, vol. 96, no. 3, pp. 253–257, 2009.

[36] J. L. Roh, J. M. Kim, and C. I. Park, "Central cervical nodal metastasis from papillary thyroid microcarcinoma: pattern and factors predictive of nodal metastasis," *Annals of Surgical Oncology*, vol. 15, no. 9, pp. 2482–2486, 2008.

[37] N. Wada, Q. Y. Duh, K. Sugino et al., "Lymph node metastasis from 259 papillary thyroid microcarcinomas," *Annals of Surgery*, vol. 237, no. 3, pp. 399–407, 2003.

[38] S. M. Chow, S. C. K. Law, J. K. C. Chan, S. K. Au, S. Yau, and W. H. Lau, "Papillary microcarcinoma of the thyroid—prognostic significance of lymph node metastasis and multifocality," *Cancer*, vol. 98, no. 1, pp. 31–40, 2003.

[39] Y. Ito, C. Tomoda, T. Uruno et al., "Clinical significance of metastasis to the central compartment from papillary microcarcinoma of the thyroid," *World Journal of Surgery*, vol. 30, no. 1, pp. 91–99, 2006.

[40] K. Pazaitou-Panayiotou, M. Capezzone, and F. Pacini, "Clinical features and therapeutic implication of papillary thyroid microcarcinoma," *Thyroid*, vol. 17, no. 11, pp. 1085–1092, 2007.

[41] D. Barbaro, U. Simit, G. Meucci, P. Lapi, P. Orsini, and C. Pasquini, "Thyroid papillary cancers: microcarcinoma and carcinoma, incidental cancers and non-incidental cancers—are they different diseases?" *Clinical Endocrinology*, vol. 63, no. 5, pp. 577–581, 2005.

[42] J. D. Lin, S. F. Kuo, T. C. Chao, and C. Hsueh, "Incidental and nonincidental papillary thyroid microcarcinoma," *Annals of Surgical Oncology*, vol. 15, no. 8, pp. 2287–2292, 2008.

[43] N. Besic, J. Zgajnar, M. Hocevar, and R. Petric, "Extent of thyroidectomy and lymphadenectomy in 254 patients with papillary thyroid microcarcinoma: a single-institution experience," *Annals of Surgical Oncology*, vol. 16, no. 4, pp. 920–928, 2009.

[44] C. Y. Lo, W. F. Chan, B. H. H. Lang, K. Y. Lam, and K. Y. Wan, "Papillary microcarcinoma: is there any difference between clinically overt and occult tumors?" *World Journal of Surgery*, vol. 30, no. 5, pp. 759–766, 2006.

[45] A. Pisanu, I. Reccia, O. Nardello, and A. Uccheddu, "Risk factors for nodal metastasis and recurrence among patients with papillary thyroid microcarcinoma: differences in clinical relevance between nonincidental and incidental tumors," *World Journal of Surgery*, vol. 33, no. 3, pp. 460–468, 2009.

[46] M. N. Pakdaman, L. Rochon, O. Gologan et al., "Incidence and histopathological behavior of papillary microcarcinomas: study of 429 cases," *Otolaryngology—Head and Neck Surgery*, vol. 139, no. 5, pp. 718–722, 2008.

[47] G. Tzvetov, D. Hirsch, I. Shraga-Slutzky et al., "Well-differentiated thyroid carcinoma: comparison of microscopic and macroscopic disease," *Thyroid*, vol. 19, no. 5, pp. 487–494, 2009.

[48] D. Cvejic, S. Selemetjev, S. Savin, I. Paunovic, I. Petrovic, and S. Tatic, "Apoptosis and proliferation related molecules (Bcl-2, Bax, p53, PCNA) in papillary microcarcinoma versus papillary carcinoma of the thyroid," *Pathology*, vol. 40, no. 5, pp. 475–480, 2008.

SAGE-Hindawi Access to Research
Journal of Thyroid Research
Volume 2011, Article ID 251680, 8 pages
doi:10.4061/2011/251680

Research Article

Subclassification of the "Grey Zone" of Thyroid Cytology; A Retrospective Descriptive Study with Clinical, Cytological, and Histological Correlation

Mariella Bonzanini,[1] Pierluigi Amadori,[2] Luca Morelli,[1] Silvia Fasanella,[1] Riccardo Pertile,[3] Angela Mattiuzzi,[4] Giorgio Marini,[4] Mauro Niccolini,[5] Giuseppe Tirone,[6] Marco Rigamonti,[7] and Paolo Dalla Palma[1]

[1] *Department of Surgical Pathology, S. Chiara Hospital, 38100 Trento, Italy*
[2] *Outpatient Endocrine Surgery, Local Public Health Service, 38100 Trento, Italy*
[3] *Epidemiological Survey, Local Public Health Service, Trento, Italy*
[4] *Department of Radiology, S. Chiara Hospital, 38100 Trento, Italy*
[5] *Department of Radiology, Villa Bianca Hospital, 38100 Trento, Italy*
[6] *Department of Surgery, S. Chiara Hospital, 38100 Trento, Italy*
[7] *Department of Surgery, Cles Hospital, 38100 Trento, Italy*

Correspondence should be addressed to Mariella Bonzanini, mariella.bonzanini@apss.tn.it

Received 15 January 2011; Revised 14 March 2011; Accepted 29 March 2011

Academic Editor: Nelson Wohllk

Undetermined thyroid cytology precludes any definitive distinction between malignant and benign lesions. Recently several classifications have been proposed to split this category into two or more cytological subcategories related to different malignancy risk rates. The current study was performed retrospectively to investigate the results obtained separating "undetermined" cytologic reports into two categories: "follicular lesion" (FL) and "atypia of undetermined significance" (AUS). Biochemical, clinical, and echographic features of each category were also retrospectively analyzed. Altogether, 316 undetermined fine-needle aspirated cytologies (FNACs) were reclassified as 74 FL and 242 AUS. Histological control leads to a diagnosis of carcinomas, adenomas, and nonneoplastic lesions, respectively, in 42.2%, 20%, and 37.8% of AUS and in 8.3%, 69.4%, and 22.2% of FL. Among biochemical, clinical, cytological, and echographic outcomes, altered thyroid autoantibodies, multiple versus single nodule, AUS versus FL, and presence of intranodular vascular flow were statistically significant to differentiate adenoma from carcinoma and from nonneoplastic lesions, whereas no significant differences were found between carcinomas and nonneoplastic lesions for these parameters. The results of this retrospective study show that undetermined FNAC category can further be subclassified in AUS and FL, the former showing higher malignancy rate. Further prospective studies are needed to confirm our results.

1. Introduction

Fine-needle aspiration cytology (FNAC) has become the dominant method in the evaluation of thyroid nodules, being fast, reliable, safe, minimally invasive, cost-effective, and reaching high sensitivity and specificity [1].

FNAC has allowed a dramatic decrease in surgical treatment of patients with thyroid nodular disease [2], enhancing the percentage of malignant operated nodules over 50% [3].

However, even in adequate cellular specimens, the method shows certain limitations and leads to an "undetermined" result in 4–15% of all cases [4, 5], precluding any definitive distinction between malignant and benign lesions.

To assess terminology, description, and interpretation of cytological appearances and transmit them to the clinicians in a clear and reproducible way, several classifications for thyroid cytology report have been proposed [6–10].

All are based on a risk of malignancy scale for adequate specimens."Undetermined" results are mostly composed of atypia of undetermined significance (AUS) and follicular patterned lesions (FL).

According to the recent Bethesda System for Reporting Thyroid Cytopathology (BSRTC), "atypia of undetermined significance/follicular lesion of undetermined significance" (AUS/FLUS) is a heterogeneous category that includes cases with ambiguous cytological findings that appear to be greater than what would be expected of a nonneoplastic process, yet the degree of cellular or architectural atypia is insufficient for an interpretation of "follicular neoplasm" or "suspicious for malignancy" [8].

Therefore, undetermined cytology is a sort of "grey zone" also for the clinicians, whose main goal is a correct therapeutic approach to thyroid lesions, that is, surgery, with its extension, or medical followup. Practically, most of these lesions are surgically removed, in total or subtotal thyroidectomy, although only a minority of them are malignant.

However, true malignancy incidence in undetermined lesions is not definitely known, because not all of them are histologically checked, and the literature reports largely heterogeneous data.

In AUS, malignancy is reported in 25% of operated patients, but it is thought to be closer to 5–10% of the total [8]. Papillary carcinoma is by far the commonest tumour [3, 11, 12].

Malignancy incidence in FL is even more variously reported than in AUS.

Cancer ratio in all FL lesions (operated and nonoperated) is about 20% in several surveys [3, 11–13], but other authors reported much lesser incidences of 0–7% [14–16].

In this study we have retrospectively split "undetermined" thyroid FNAC into two categories: "follicular lesion" (FL) and "atypia of undetermined significance" (AUS) in order to evaluate

(i) the relative incidences of AUS and FL in thyroid FNA specimens in our district,

(ii) the incidence of malignant lesions in AUS and FL,

(iii) the presence of biochemical, clinical, and echographic features possibly predictive of malignancy related to AUS and FL.

2. Materials and Methods

We reviewed the thyroid FNAC data of our institution from June 2004 to December 2007.

For each FNAC, a specific module was performed, including patient data, clinical and biochemical thyroid status (hypo-, hyper, or euthyroidism), thyroid autoantibodies, and thyroid medication. Moreover, detailed ultrasound features such as size, echogenicity, microcalcifications, boundaries, and color Doppler vascular flow pattern (intra/perinodular) were described for each nodule.

FNACs were mainly performed by four radiologists and one endocrinologist with ultrasound guide, using 25 or 27 gauge needles.

Two-three samplings were performed for each nodule. Papanicolaou and May-Grünwald-Giemsa stains were both used for FNA smears preparations.

2.1. Cytological Classification Criteria. Cytological specimens were evaluated by 3 pathologists, and careful cytological description was reported for each case.

Original cytologic reports were reclassified into 5 categories: inadequate, benign, undetermined, suspicious, and malignant, not knowing the followup.

The undetermined results were divided into two further categories.

(1) FL for samples suggesting follicular neoplasms. In this category were included FNACs with high to moderate cellularity, predominantly or partially microfollicular pattern, scanty or absent colloid, and mild or absent nuclear atypia. Samples consisting almost exclusively/exclusively of Hurthle cells were also included here.

Follicular patterned lesions or Hurthle cells lesions with overt cytological architectural or nuclear atypical features (that is irregular or variably sized follicle, crowding of cells, many single cells, pleomorphic, enlarged nuclei, nuclear grooves, coarse and irregular chromatin, prominent and multiple nucleoli, atypical or numerous mitosis) [17] were reported as suspicious and were not included in this study.

(2) AUS for samples exhibiting cytological atypia or other features raising the possibility of neoplasia, but which were insufficient to enable confident placing into any other category.

This is intended as a broad category encompassing focal features suggestive of papillary carcinoma, cellular atypia hindered by sample preparation artifact, cellular atypia engendered by cystic alteration, repair, and therapy. Atypical lymphoid infiltrate was included [8, 10].

2.2. Histological, Cytological, and Clinical Followup. Corresponding histologic and clinical-cytological followup was reviewed.

The histological diagnosis was made according to the World Health Organization guidelines [18].

The patients who did not undergo thyroid surgery, with benign repeated FNAC, were followed by clinical and periodic thyroid sonographic evaluation, at least once within 2 years from the last FNA. If the thyroid nodule did not undergo any modifications it was considered "bona fide" benign.

2.3. Statistical Analysis. The descriptive analyses included the observed frequencies calculation with the respective percentages for each categorical variable, while median and range were computed for patients' age and diameter of nodules (continuous variables).

Multivariate stepwise logistic regression analysis was performed in order to identify clinical, echographic, and

cytological categories associated with the lesion type (carcinomas versus adenomas, carcinomas versus nonneoplastic lesions, adenomas versus nonneoplastic lesions). In stepwise selection analysis, any significant variables (P value $\leq$ .05) are inserted in the model as covariates, but an attempt is made to remove any insignificant variables from the model before adding a new significant variable to the model. Each addition or deletion of a variable to or from a model is listed as a separate step and at each step, a new model is fitted. In this study only the final model is presented. Results are given in terms of odds ratio (OR).

Multivariate analyses were performed with SAS software, version 9.1.3 (SAS Institute Inc., SAS 9.1.3, Cary, NC, USA, 2003).

3. Results

Between June 2004 and December 2007, 2422 FNAs were performed in 1883 patients with thyroid nodule(s). There were 348 men and 1535 women, aged 13–88 years (median 54 years).

Reclassification of the cytological reports yielded 397 (16.4%) nondiagnostic samples, 1554 (64.2%) benign cytology, 84 (3.5%) diagnoses of suspect malignant neoplasia, 71 (2.9%) diagnoses of malignant cytology, and 316 (13%) undetermined cytologic reports. 74 (3%) reports corresponding to follicular lesion were reclassified as FL, and 242 (10%) reports were reclassified as AUS (Figure 1).

3.1. Histological Followup. The histological diagnosis was available for 81 nodules of the undetermined category: 36 of 74 (48.6%) nodules classified as FL, and 45 of 242 (18.6%) nodules classified as AUS.

There were 22 malignant tumors, 34 follicular adenomas, and 25 nonneoplastic lesions.

Among malignant tumors, 19 were PTC, 15 classic and 4 follicular variant, and 3 were follicular carcinomas.

Follicular adenomas were Hurtle cells type in 13 cases and follicular in 21 cases.

Nonneoplastic lesions have been shown to be nodular hyperplasia in 18 cases, Hashimoto's thyroiditis in 5, granulomatous thyroiditis in 1, and spindled, probably reactive, lesion in 1. Among histologically proven carcinomas, 19 (42.2%) were observed in nodules with preoperative AUS reclassification, whereas 3 (8.3%) were observed in nodules with preoperative FL reclassification.

Adenomas were observed in 25 (69.4%) nodules classified as FL and in 9 (20%) classified as AUS.

Seventeen benign lesions (nodular hyperplasia and thyroiditis) corresponded to cytological reclassification of AUS (37.8%) and 8 to FL (22.2%) (Table 1).

3.2. Clinical Followup. Repetition of FNAC was performed in 73 AUS lesions. Nine resulted inadequate, 46 benign, 10 AUS, 1 FL, 5 suspicious, and 2 malignant.

Repetition of FNAC was performed in 8 FL. In 5 cases the same cytological category was confirmed, whereas in 3 cases the cytological diagnosis was benign.

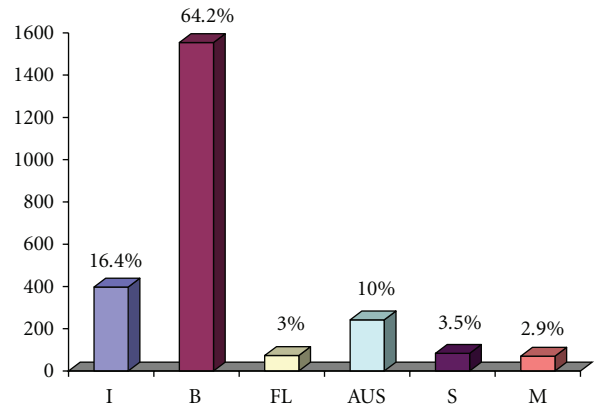

Figure 1: I: inadequate; B: benign; FL: follicular lesion; AUS: atypia of undetermined significance; S: suspicious for malignant neoplasia; M: malignant neoplasia. Distribution of cytological categories after reclassification.

For 49 lesions with repeated benign FNA (46 AUS and 3 FL), in which the patients did not undergo thyroid surgery, clinical and echographic followup supported the benign nature of the lesion.

3.3. Clinical and Echographic Features. Clinical, echographic features and cytological diagnosis of histologically proven carcinomas and adenomas and of nonneoplastic lesions with histological or clinical followup are reported in Table 2.

No significant statistical differences were found according to age, gender, and thyroid function between carcinomas, adenomas, and nonneoplastic lesions. Moreover, there were no significant differences for clinical, echographic, and cytological reclassification between carcinomas and nonneoplastic lesions. However, altered autoantibodies, multiple nodules versus single nodule, and AUS versus FL cytological category showed a statistically significant difference between carcinomas and adenomas (Table 3). In detail, after conditioning on the other variables entered in the model, the probability of observing a carcinoma was more than 15 times higher when thyroid autoantibodies were altered (OR = 15.43 with a P value = .046), multiple nodules increased the probability of identifying a carcinoma by almost 79 times (OR = 78.94 with a P value = .003), and the presence of AUS cytological category increased the probability of recognizing a carcinoma by more than 21 times (OR = 21.49 with a P value = .023). Total variance explained by these three variables entered in the final model is 56% (R^2 = 0.56) and concordance percentage is 92.9% which means that 93 of every 100 nodules will be well classified using alteration in thyroid autoantibodies, multiple/single nodules, and cytological category as predictors.

Concerning the comparison between nonneoplastic lesions and adenomas, single nodule (versus multiple nodules), follicular lesion (versus AUS), higher diameter, and no vascular flow are all statistically significant features in adenomas compared to nonneoplastic lesions (Table 4). Keeping the other variables constant in the model, the

Table 1: Histologic followup of cases.

	AUS (242 cases)		FL (74 cases)	
	45	18.6%	36	48.6%
Benign	26	57.8%	33	91.6%
Follicular adenoma	5	19.2%	16	48.5%
Hurtle cell adenoma	4	15.4%	9	27.3%
Nodular hyperplasia	11	43.3%	7	21.2%
Hashimoto thyroiditis	4	15.4%	1	3%
De Quervain thyroiditis	1	3.8%	—	—
Reactive nodule	1	3.8%	—	—
Malignant	19	42.2%	3	8,4%
Papillary carcinoma classic type	14	73.7%	1	33.3%
Follicular variant of papillary carcinoma	3	15.8%	1	33.3%
Follicular carcinoma	2	10.5%	1	33.3%

AUS: atypia of undetermined significance; FL: follicular lesion.

Table 2: Clinical, biochemical, and echographic features of 130 thyroid nodules with histological (81 cases) or benign repeated cytology with clinical-echographic followup (49 cases).

	Carcinoma		Adenoma		Nodular hyperplasia/thyroiditis	
	22	16.9%	33	25.4%	75	57.7%
Clinical and biochemical features						
Age (years)	Range 25–75 Median 53		Range 18–81 Median 49		Range 27–72 Median 51	
Female	18	80.8%	26	78.8%	68	90.7%
Male	4	19.2%	7	21.2%	7	9.3%
AbHTG and/or AbTPO	7	31.8%	4	12.1%	27	36.0%
Hypothyroidism	1	4.5%	—	—	3	4.0%
Hyperthyroidism	1	4.5%	1	3.0%	2	2.7%
Single nodule	8	36.4%	25	75.8%	24	32.0%
Unknown	—		1	3.0%	3	4.0%
Diameter (mm)	Range 6–48 Median 18		Range 7–54 Median 23		Range 8–50 Median 15	
Palpable	14	63.6%	22	66.7%	35	46.7%
Echographic features						
Solid	20	90.9%	26	78.8%	54	72.0%
Hypoechoic	14	70.0%	20	76.9%	37	68.5%
Hyperechoic	2	10%	1	3.8%	10	18.5%
Isoechoic	4	20%	5	19.2%	7	13.0%
Microcalcifications	5	25%	5	19.2%	3	5.6%
Vascular flow	4	20%	14	53.8	11	20.4%
Irregular margins	3	15%	2	7.7%	3	5.6%
Unknown	—		2	6.1%	3	4.0%
Mixed	2	9.1%	5	15.1%	16	21.3%
Cystic	—	—	—	—	2	2.7%
Cytologic category						
AUS	19	86.4%	9	27.3%	65	86.7%
FL	3	13.6%	24	72.7%	10	13.3%

AUS: atypia of undetermined significance; FL: follicular lesion.

Table 3: Multivariate logistic analysis of the probability of identifying a carcinoma versus an adenoma by clinical, echographic features and cytologic category.

	Parameters entered in the model	OR	*P* value	Concordance percentage	*R*2
All nodules ($n = 54$)	Ab altered (yes versus no)	15.43	**.046**	92.9%	0.56
	Multiple versus single nodule	78.94	**.003**		
	Cytologic Category (AUS versus FL)	21.49	**.023**		
Only solid nodules ($n = 45$)	Multiple versus single nodule	29.53	**.005**	85.9%	0.48
	Cytologic Category (AUS versus FL)	12.50	**.044**		

AUS: atypia of undetermined significance; FL: follicular lesion.

Table 4: Multivariate logistic analysis of the probability of identifying a benign nodule (NH and thyroiditis) versus an adenoma by clinical, echographic features and cytologic category.

	Parameters entered in the model	OR	*P* value	Concordance percentage	R^2
All nodules ($n = 108$)	Multiple versus single nodule	14.47	**.002**	81.3%	0.38
	Cytologic Category (AUS versus FL)	11.96	**.000**		
	Diameter (mm)	0.94	**.043**		
Only solid nodules ($n = 80$)	Multiple versus single nodule	10.93	**.006**	80.8%	0.37
	Cytologic Category (AUS versus FL)	8.48	**.005**		
	Vascular flow (yes versus No)	0.14	**.035**		

AUS: atypia of undetermined significance; FL: follicular lesion.

probability of identifying a benign lesion increased by 14.5 times in case of multiple nodules (OR = 14.47 with a *P* value = .002) and by 12 times with an AUS cytological category (OR = 11.96 with a *P* value $\leq$ .0001). Finally, for each mm. of increase in the nodule diameter, the logistic regression model predicted a 6% decrease in the probability of observing a nonneoplastic lesion rather than an adenoma (OR = 0.94 and *P* value = .043). Concordance percentage of the model is 81.3% and R^2 is 0.38.

Taking into account only solid nodules ($n = 80$), the diameter was no more statistically significant, but another variable entered in the model, that is, vascular flow: the presence of vascular flow decreased the probability of observing a nonneoplastic lesion by 86% (OR = 0.14 and *P* value = .035).

4. Conclusions

Although FNAC has been used with success in the diagnosis of papillary, medullary, and anaplastic thyroid carcinomas, it is difficult to assess its value in follicular lesions. The main problem is the distinction between benign lesions, such as follicular adenoma or nodular adenomatous goiter, and follicular carcinoma or follicular variant of papillary carcinoma (FVPTC).

Therefore, histological evaluation is necessary to demonstrate capsular/vascular invasion for follicular carcinoma and the subtle nuclear aspects in FVPTC [11].

Classifications, practically overlapping as for benign and malignant definitions, show some substantial differences managing undetermined lesions.

Follicular lesions are managed in two main different ways depending on the classification.

The Bethesda System distinguishes 3 subcategories: "follicular neoplasm or suspicious for a follicular neoplasm" refers to a cellular aspirate comprised of follicular cells, most of which are arranged in an altered architectural pattern characterized by significant cell crowding and/or microfollicle formation; "follicular neoplasm, Hurthle cell type/suspicious for follicular neoplasm, Hurthle cell type" refers to a cellular aspirate consisting exclusively (or nearly exclusively) of Hurthle cells.

Follicular patterned aspirates that do not otherwise fulfil the aforementioned criteria are set together with AUS (AUS/FLUS).

However, a significant difference in malignancy incidence seems not to appear from the document [8].

The recently published "Guidance on the reporting of thyroid cytology specimens" of English Royal College of Pathologist (RCP) names "neoplasm possible" (Thy3) the undetermined category and separates samples suggesting follicular neoplasms (Thy3f-f for follicular) from samples which exhibit cytological atypia or other features which raise the possibility of neoplasia but which are insufficient to enable confident placing into any other category (Thy3a-a for atypia).

Operative indications emerging from BSRTC recommend FNAC repetition for AUS/FLUS (with subsequent surgery if AUS/FLUS, or worse category, are found) [8], whereas RCP recommends an individualized and multidisciplinary assessment for each patient [10].

As for AUS, its incidence among thyroid cytological specimens is variably reported, ranging from 2% to 6%, although some heterogeneity in its definition makes it difficult to draw consistent conclusions [3, 5, 11, 12]. The Bethesda System for Reporting Thyroid Cytopathology recommends to use this

category as a last resort and limit its use to approximately 7% [8].

In our institution, thyroid FNAC classification similar to that of The Royal College of Pathologists [9, 10] has been actually chosen, where the presence/absence of nuclear atypia is the key of the undetermined lesions subclassification in AUS and FL.

In the present study, data obtained on this basis indicate that AUS is associated with higher malignancy rates than FL.

Low malignancy incidence in FL emerging from our study contradicts the usually accepted rates of about 20% reported by some studies [3, 5, 13, 14, 19, 20] but it is in agreement with others.

Two Italian studies found no cancers in all operated nodules with cytological diagnosis of FL [15, 21].

DeMay, at histological examination, found only 2 cancers (none follicular) among 138 FL [16].

Such a discrepancy may reflect inconsistent patterns in cytological criteria of classification.

One of the heaviest factors influencing this discrepancy is cellular atypia, particularly its definition and association with follicular patterned lesions.

The role of atypia as an independent risk factor for malignancy has been matter of interest and debate. Although some authors report no correlation between atypia and malignancy [5, 22, 23], other studies show, conversely, that atypia alone or in association with a follicular patterned FNAC can be linked to a higher risk of malignancy [12, 14, 16, 20, 24, 25].

Interestingly, most literature showing high malignancy rates in FL, actually reports substantial reduction when lesions with atypia are excluded [12, 14, 19].

Moreover, among the malignancies histologically proven in FL, FVPTC appears to be the commonest one, whereas follicular carcinoma and Hurthle cell carcinomas seem to be much rarer than usually reported both in FL and, generally, among all thyroid cancers [13–16].

It is well known that the cytological diagnosis of FVPTC is challenging, due to a paucity or lack of well-defined nuclear features of papillary carcinoma, leading, in samples containing few cellular groups, to a diagnosis of AUS or FL [13].

However, an accurate evaluation of focal cytological features and the architectural pattern has been shown to allow a correct diagnosis of malignancy or suspect for malignancy [26, 27], but adequate smears and skilled pathologists are necessary, and this could play some role in outcome differences.

Multivariate analysis of our data allows to draw some other relevant conclusions.

Among the cytological undetermined lesions of thyroid, adenomas seem to be the more correctly classifiable on the basis of cytological, immunological, and ultrasound data.

Firstly, most of FL specimens lead to a histological diagnosis of adenoma.

Secondly, thyroid autoantibodies appear to be more common in non-neoplastic lesions and in carcinomas than in adenomas. As for carcinomas, this is not surprising. Coexistence of chronic lymphocytic thyroiditis and PTC has been reported, at variable frequencies, although it remains unclear whether these two thyroid disorders share a common aetiology or thyroiditis represents a host tumor immune response [28–30].

Moreover, Kim et al. recently reported positive serum antithyroglobulin antibodies as an independent predictor for thyroid malignancy in thyroid nodules, regardless of the presence of autoimmune thyroiditis [31].

Our results, although limited to thyroid cancers discovered in undetermined cytology, seem to be in agreement with this observation.

Conversely, the overlapping incidences of thyroid autoantibodies in carcinomas and in non-neoplastic lesions in the present study could almost partially be due to the fact that, in the latter, both autoimmune thyroiditis and nodular hyperplasia were enclosed.

In conclusion, our outcomes suggest higher malignancy risk in cytological undetermined thyroid lesions with atypia than without atypia.

The very low incidence of thyroid cancer found in FL refers to the same perplexity about an unavoidable surgical treatment, arisen by other authors with similar results [15, 16, 21].

Although all patients with FL should be considered for surgical resection, they should be also informed about the low malignancy risk of their condition and other aspects, such as underlying medical conditions and age of the patients, presence/absence of thyroid autoantibodies, growth rate of the nodule, which could be taken in account for the decision.

Conversely, a more relevant indication to surgery could be advisable for AUS.

In this lesion, FNAC repetition seems also appropriate. Our data confirm that about half of these aspirates are reclassified as benign, as already reported in the literature [3, 12].

Being based on the review of previous cytological data, our study shares the same limitations of the retrospective studies, not allowing a prospective, two-arm followup of operated versus nonoperated cases. Therefore our findings should be evaluated in this light. Anyway, we clearly documented clinical and cytological findings in subclassified undetermined cytologic category in 81 nodules histologically checked and in 49 nodules with repeated FNAC and clinical and echographic followup.

Two years ago our results led to the employment, in our department, of a cytological classification similar to that of the RCP. A larger, prospective study design has been planned for the risk assessment in each cytological category.

In recent years, molecular tests have been shown to be useful in the diagnosis of thyroid neoplasms. Point mutations in BRAF and RAS genes and gene rearrangements involving PAX8/PPARγ and RET/PTC have been found in approximately 70% of thyroid neoplasia [32].

The B-RAF V600E mutation has been shown as diagnostic marker for PTC, and there have been many reports on its diagnostic usefulness in refining the cytological diagnosis of

this tumor [33–37]. But, unfortunately BRAF analysis is of limited value in preoperative diagnosis of FVPTC [38].

Moreover, several studies indicate that molecular testing of thyroid nodules for a panel of mutations can enhance the accuracy of undetermined FNAC [39, 40], but at present no single marker seems to be accurate enough to distinguish thyroid carcinoma from its benign mimics to be introduced in the routine [41].

Finally, our results support the indication to distinguish undetermined thyroid cytological samples with follicular patterned feature without atypia from the undetermined samples with atypical cells and to relate the FNAC results with clinical and echographic findings.

Conflict of Interests

There is no financial interest in or arrangement with a company whose product was used in a study. In addition, there is no financial interest in or arrangement with a competing company, and there are no other direct or indirect financial connections or other situations that might raise the question of bias in the work reported or the conclusions, implications, or opinions stated—including pertinent commercial or other sources of funding for the individual author(s) or for the associated department(s) or organization(s), personal relationships, or direct academic competition.

References

[1] M. W. Ashcraft and A. J. Van Herle, "Management of thyroid nodules. I: history and physical examination, blood tests, X-ray tests, and ultrasonography," *Head and Neck Surgery*, vol. 3, no. 3, pp. 216–230, 1981.

[2] H. Gharib and J. R. Goellner, "Fine-needle aspiration biopsy of the thyroid: an appraisal," *Annals of Internal Medicine*, vol. 118, no. 4, pp. 282–289, 1993.

[3] L. Yassa, E. S. Cibas, C. B. Benson et al., "Long-term assessment of a multidisciplinary approach to thyroid nodule diagnostic evaluation," *Cancer*, vol. 111, no. 6, pp. 508–516, 2007.

[4] Z. W. Baloch, M. J. Sack, G. H. Hu, V. A. Livolsi, and P. K. Gupta, "Fine-needle aspiration of thyroid: an institutional experience," *Thyroid*, vol. 8, no. 7, pp. 565–569, 1998.

[5] J. Yang, V. Schnadig, R. Logrono, and P. G. Wasserman, "Fine-needle aspiration of thyroid nodules: a study of 4703 patients with histologic and clinical correlations," *Cancer*, vol. 111, no. 5, pp. 306–315, 2007.

[6] H. H. Wang, "Reporting thyroid fine-needle aspiration: literature review and a proposal," *Diagnostic Cytopathology*, vol. 34, no. 1, pp. 67–76, 2006.

[7] "Papanicolau Society of cytopathology recommandetionsfor thyroid fine-needle aspiration," 2010, http://www.pathology.org/guidelines.html.

[8] S. Z. Ali and E. S. Cibas, *The Bethesda System for Reporting Thyroid Cytopathology. Definitions, Criteria and Explanatory Notes*, Springer, New York, NY, USA, 2010.

[9] British Thyroid Association Royal College of Physicians, "Guidelines for the management of thyroid cancer," in *Report of the Thyroid Cancer Guidelines Update Group*, P. Perros, Ed., Royal College of Physicians, London, UK, 2nd edition, 2007.

[10] The Royal College of Pathologists, "Guidance on the reporting of thyroid cytology specimens," London: RCP 2009, http://www.rcpath.org/resources/pdf/g089guidanceonthereportingofthyroidcytologyfinal.pdf.

[11] Y. Shi, X. Ding, M. Klein et al., "Thyroid fine-needle aspiration with atypia of undetermined significance: a necessary or optional category?" *Cancer Cytopathology*, vol. 117, no. 5, pp. 298–304, 2009.

[12] R. E. Goldstein, J. L. Netterville, B. Burkey, and J. E. Johnson, "Implications of follicular neoplasms, atypia, and lesions suspicious for malignancy diagnosed by fine-needle aspiration of thyroid nodules," *Annals of Surgery*, vol. 235, no. 5, pp. 656–664, 2002.

[13] W. C. Faquin and Z. W. Baloch, "Fine-Needle aspiration of follicular patterned lesions of the thyroid: diagnosis, management, and follow-up according to National Cancer Institute (NCI) recommendations," *Diagnostic Cytopathology*, vol. 38, pp. 731–739, 2010.

[14] N. Dabelić, N. Matesa, D. Matesa-Anić, and Z. Kusić, "Malignancy risk assessment in adenomatoid nodules and suspicious follicular lesions of the thyroid obtained by fine needle aspiration cytology," *Collegium Antropologicum*, vol. 34, pp. 349–354, 2010.

[15] L. Foppiani, M. Tancredi, G. L. Ansaldo et al., "Absence of histological malignancy in a patient cohort with follicular lesions on fine-needle aspiration," *Journal of Endocrinological Investigation*, vol. 26, no. 1, pp. 29–34, 2003.

[16] R. M. DeMay, "Follicular lesions of the thyroid: W(h)ither follicular carcinoma?" *American Journal of Clinical Pathology*, vol. 114, no. 5, pp. 681–683, 2000.

[17] R. M. De May, "Thyroid," in *The Art and Science of Cytopathology*, pp. 724–729, ASCP Press, Chigago, Ill, USA, 1996.

[18] C. Hedinger, *Histological Typing of Thyroid Tumours*, Springer, Berlin, Germany, 2nd edition, 1988.

[19] R. Mihai, A. J. C. Parker, D. Roskell, and G. P. Sadler, "One in four patients with follicular thyroid cytology (THY3) has a thyroid carcinoma," *Thyroid*, vol. 19, no. 1, pp. 33–37, 2009.

[20] G. Bahar, D. Braslavsky, T. Shpitzer et al., "The cytological and clinical value of the thyroid "follicular lesion"," *American Journal of Otolaryngology*, vol. 24, no. 4, pp. 217–220, 2003.

[21] D. Piromalli, G. Martelli, I. Del Prato, P. Collini, and S. Pilotti, "The role of fine needle aspiration in the diagnosis of thyroid nodules: analysis of 795 consecutive cases," *Journal of Surgical Oncology*, vol. 50, no. 4, pp. 247–250, 1992.

[22] T. S. Greaves, M. Olvera, B. D. Florentine et al., "Follicular lesions of thyroid: a 5-year fine-needle aspiration experience," *Cancer*, vol. 90, no. 6, pp. 335–341, 2000.

[23] C. R. McHenry, S. R. Thomas, S. J. Slusarczyk, and A. Khiyami, "Follicular or Hurthle cell neoplasm of the thyroid: can clinical factors be used to predict carcinoma and determine extent of thyroidectomy?" *Surgery*, vol. 126, no. 4, pp. 798–804, 1999.

[24] A. Carpi, E. Ferrari, M. G. Toni, A. Sagripanti, A. Nicolini, and G. Di Coscio, "Needle aspiration techniques in preoperative selection of patients with thyroid nodules: a long-term study," *Journal of Clinical Oncology*, vol. 14, no. 5, pp. 1704–1712, 1996.

[25] A. S. Kelman, A. Rathan, J. Leibowitz, D. E. Burstein, and R. S. Haber, "Thyroid cytology and the risk of malignancy in thyroid nodules: importance of nuclear atypia in indeterminate specimens," *Thyroid*, vol. 11, no. 3, pp. 271–277, 2001.

[26] S. Logani, P. K. Gupta, V. A. LiVolsi, S. Mandel, and Z. W. Baloch, "Thyroid nodules with FNA cytology suspicious for follicular variant of papillary thyroid carcinoma: follow-up

and management," *Diagnostic Cytopathology*, vol. 23, no. 6, pp. 380–385, 2000.

[27] I. A. El Hag and S. M. Kollur, "Benign follicular thyroid lesions versus follicular variant of papillary carcinoma: differentiation by architectural pattern," *Cytopathology*, vol. 15, no. 4, pp. 200–205, 2004.

[28] K. C. Loh, F. S. Greenspan, F. Dong, T. R. Miller, and P. P. B. Yeo, "Influence of lymphocytic thyroiditis on the prognostic outcome of patients with papillary thyroid carcinoma," *Journal of Clinical Endocrinology and Metabolism*, vol. 84, no. 2, pp. 458–463, 1999.

[29] E. Kebebew, P. A. Treseler, P. H. G. Ituarte, and O. H. Clark, "Coexisting chronic lymphocytic thyroiditis and papillary thyroid cancer revisited," *World Journal of Surgery*, vol. 25, no. 5, pp. 632–637, 2001.

[30] S. Arif, A. Blanes, and S. J. Diaz-Cano, "Hashimoto's thyroiditis shares features with early papillary thyroid carcinoma," *Histopathology*, vol. 41, no. 4, pp. 357–362, 2002.

[31] E. S. Kim, D. J. Lim, K. H. Baek et al., "Thyroglobulin antibody is associated with increased cancer risk in thyroid nodules," *Thyroid*, vol. 20, pp. 885–891, 2010.

[32] Y. E. Nikiforov, "Thyroid carcinoma: molecular pathways and therapeutic targets," *Modern Pathology*, vol. 21, supplement 2, pp. S37–S43, 2008.

[33] G. Salvatore, R. Giannini, P. Faviana et al., "Analysis of BRAF point mutation and RET/PTC rearrangement refines the fine-needle aspiration diagnosis of papillary thyroid carcinoma," *Journal of Clinical Endocrinology and Metabolism*, vol. 89, no. 10, pp. 5175–5180, 2004.

[34] K. W. Chung, S. K. Yang, G. K. Lee et al., "Detection of BRAF mutation on fine needle aspiration specimens of thyroid nodule refines cyto-pathology diagnosis, especially in BRAF mutation-prevalent area," *Clinical Endocrinology*, vol. 65, no. 5, pp. 660–666, 2006.

[35] M. R. Sapio, D. Posca, A. Raggioli et al., "Detection of RET/PTC, TRK and BRAF mutations in preoperative diagnosis of thyroid nodules with indeterminate cytological findings," *Clinical Endocrinology*, vol. 66, no. 5, pp. 678–683, 2007.

[36] G. Troncone, I. Cozzolino, M. Fedele, U. Malapelle, and L. Palombini, "Preparation of thyroid FNA material for routine cytology and BRAF testing: a validation study," *Diagnostic Cytopathology*, vol. 38, no. 3, pp. 172–176, 2010.

[37] S. Girlando, L. V. Cuorvo, M. Bonzanini et al., "High prevalence of B-RAF mutation in papillary carcinoma of the thyroid in North-East Italy," *International Journal of Surgical Pathology*, vol. 18, no. 3, pp. 173–176, 2010.

[38] A. Proietti, R. Giannini, C. Ugolini et al., "BRAF status of follicular variant of papillary thyroid carcinoma and its relationship to its clinical and cytological features," *Thyroid*, vol. 20, pp. 1263–1270, 2010.

[39] Y. E. Nikiforov, D. L. Steward, T. M. Robinson-Smith et al., "Molecular testing for mutations in improving the fine-needle aspiration diagnosis of thyroid nodules," *Journal of Clinical Endocrinology and Metabolism*, vol. 94, no. 6, pp. 2092–2098, 2009.

[40] N. P. Ohori, M. N. Nikiforova, K. E. Schoedel et al., "Contribution of molecular testing to thyroid fine-needle aspiration cytology of "follicular lesion of undetermined significance/atypia of undetermined significance"," *Cancer Cytopathology*, vol. 118, no. 1, pp. 17–23, 2010.

[41] B. C. G. Freitas and J. M. Cerutti, "Genetic markers differentiating follicular thyroid carcinoma from benign lesions," *Molecular and Cellular Endocrinology*, vol. 321, no. 1, pp. 77–85, 2010.

SAGE-Hindawi Access to Research
Journal of Thyroid Research
Volume 2011, Article ID 845362, 7 pages
doi:10.4061/2011/845362

Review Article

Thyroid Carcinoma in Children and Adolescents—Systematic Review of the Literature

Fernanda Vaisman,[1,2] Rossana Corbo,[1,2] and Mario Vaisman[1]

[1] *Endocrinology Service, Universidade Federal do Rio de Janeiro, Rio de Janiro, RJ, Brazil*
[2] *Endocrinology Service, Instituto Nacional do Cancer, Rio de Janeiro, Rio de Janiro, RJ, Brazil*

Correspondence should be addressed to Fernanda Vaisman, fevaisman@globo.com

Received 21 December 2010; Revised 8 April 2011; Accepted 9 May 2011

Academic Editor: Ana O. Hoff

Thyroid cancer in children and adolescents is usually a major concern for physicians, patients, and parents. Controversies regarding the aggressiveness of the clinical presentation and the ideal therapeutic approach remain among the scientific community. The current recommendations and staging systems are based on data generated by studies in adults, and this might lead to overtreating in some cases as well as undertreating in others. Understanding the differences in the biology, clinical course, and outcomes in this population is crucial for therapeutic decisions. This paper evaluates the biology, clinical presentation, recurrences, and overall survival as well as the staging systems in children and adolescents with differentiated thyroid cancer.

1. Introduction

Palpable thyroid nodules can be diagnosed in 4 to 7% of the adult population. The high-resolution ultrasounds are able to detect nodules around 19% of the adult population, reaching up to 67% in populations at higher risk such as women and elderly individuals [1]. Considering autopsy series, this prevalence can reach 50%. Although common, only 5% are malignant [2].

Thyroid cancer is a rare pathology in childhood and adolescence being responsible for 1.5–3% of all carcinomas in this age group in the USA and Europe [3]. Such as the adults, the differentiated thyroid carcinoma is the most commonly found, especially the papillary carcinoma. In this population, age, family history of thyroid disease and radiation exposure are very important factors as already shown in various ser-ies [4–6], especially after the Chernobyl accident, when a substantial increase in the incidence of thyroid carcinoma in children exposed to radiation was documented [7].

Staging thyroid carcinoma in children and adolescents is still a controversial issue. To avoid overtreating, a risk classification system, with the highest accuracy as possible, should be used to identify patients who should be treated in a more conservative or more aggressive way.

The current treatment recommendation is the total thyroidectomy followed by radioiodine therapy, based on good response and high disease-free survival rate for this age group. However, many authors question the aggressiveness of this treatment given the long lifespan of these patients and long-term complications of high doses of radioiodine.

This revision aims to evaluate the initial therapeutic approach for children and adolescents with DTC regarding surgery, adjuvant therapy, and staging.

2. Epidemiology of the Disease

The incidence of clinically palpable thyroid nodules in children is estimated to be around 1–1.5%. However, in teenagers, this prevalence may reach 13% [8]. When compared to adults, children have four times greater risk of malignancy when a thyroid nodule is diagnosed. In the US, around 350 individuals aged less than 20 years receive the diagnosis of thyroid carcinoma annually [9]. In Brazil, the incidence can reach 2% of all pediatric cancers according to the National Cancer Institute database [10].

Besides being a rare disease, the differentiated thyroid carcinoma accounts for about 0.5–3% of all malignancies in the pediatric population [8]. In addition, the thyroid is one of the most common sites of a second primary tumor in children who received external beam radiotherapy to the neck for the treatment of other neoplasms.

The occurrence of thyroid carcinoma in early childhood is very rare. In the literature, there are isolated cases of differentiated thyroid carcinoma in neonates and infants aged less than 1 year old [11, 12].

Furthermore, the incidence of thyroid cancer seems to increase with age. In a series with 235 children and adolescents who followed Maria Skłodowska Memorial Cancer Center and Institute of Oncology for thyroid cancer, 5% were diagnosed under 6 years old, 10% with 7–9 years, increasing substantially after 10 years old. The difference between boys and girls was seen more clearly after 13-14 years old [13]. Also the latest records of SEER cohort (Surveillance, Epidemiology and End Results) from a group of 1753 patients aged less than 20 years confirm the greater incidence in girls (0.89 cases/100,000 for girls versus 0.2 cases/100,000 for boys) [14].

3. Risk Factors

In the past 60 years, the incidence of thyroid carcinoma in the pediatric age group presented two distinct peaks. The first occurred around 1950 due to the use of radiation for the treatment of common childhood conditions such as *Tinea capitis*, acne, chronic tonsillitis, and thymus hyperplasia [15, 16]. In these cases, the thyroid carcinoma was diagnosed on average 10–20 years after exposure, but with risk persisting until 40 years later. When the causal relationship between neck irradiation and thyroid carcinoma was established, such practices were abandoned leading to a decreasing incidence in this population [11]. These data led to acceptance of ionizing radiation, a risk factor for the development of thyroid cancer [17]. Similarly, external beam radiotherapy for the treatment of other childhood malignancies would also be associated with an increased incidence of thyroid carcinoma in this population [18–20].

A second peak incidence occurred in the mid-1990s in some regions of Eastern Europe on behalf of the nuclear accident that occurred in Chernobyl in 1986 [4–6]. The first cases were diagnosed approximately 4-5 years later, especially in children under 5 years old at the time of exposure [4, 21]. About 75% of these cases were exposed to the radioactive fallout between birth and 14 years of age, with most of the other 25% being from 14 to 17 years old at the time of exposure [21]. The Chernobyl accident confirmed the high-er sensitivity of the pediatric population, to the effects of radiation when compared to adults [22].

The effects of ionizing radiation on thyroid remain of great interest of the scientific community. The British Childhood Cancer Survivor Study (BCCSS) is a cohort of 17,980 patients who were followed on average for 17.4 years, so far, whose main objective is to determine the occurrence of a second primary tumor. Eighty-eight percent of thyroid carcinomas were found in patients undergoing radiotherapy covering the cervical region. The risk of thyroid carcinoma was higher in patients treated for Hodgkin's disease (RR 3.3—IC: 1.1–10.1) and non-Hodgkin Lymphoma (RR 3.4—IC: 1.1–10.7) [23].

4. Presentation in Childhood

Regarding the clinical presentation, some characteristics are markedly different in pediatric population.

First, the tumor volume tends to be larger in patients with less than 20 years old when compared to patients diagnosed between 20 and 50 years [24]. Zimmerman et al. already showed, in 1988 [25], that newly diagnosed tumors were greater than 4 cm in 36% of children as opposed to 15% of adults and had less than 1 cm in 9% of children as opposed to 22% of adults. In series contemplating only patients with papillary carcinoma, only 1.5–3% of tumors had less than 1 cm size at diagnosis [26, 27].

Furthermore, probably due to the fact that thyroid volume is smaller in children, an early involvement of thyroid capule and surrounding tissue is seen [28]. Thus, the category of microcarcinoma (including tumors with less than 1 cm), commonly used in adults, should be avoided in children, since a 1 cm tumor constitutes a very important finding in this age group.

Secondly, the multicentricity also occurs more frequently in the pediatric age group, especially in the subtype papillary carcinoma [29, 30]. Such outbreaks have been considered as polyclonal in most cases [31]. This becomes especially important as it can be used as an argument in favor of total thyroidectomy as primary surgical approach for these patients.

Third, pediatric patients have a higher probability of cervical lymph node metastasis as well as distant metastasis [21, 32]. In a series done at the Mayo Clinic with 1039 patients with papillary thyroid carcinoma, cervical lymph node invol-vement was detected in 90% and metastasis distance in approximately 7% of children versus 35% of cervical lymph node involvement and 2% of distance metastasis in adults [25]. In a study performed by our group with 65 children and adolescents, the occurrence lymph node metastasis at diagnosis was 61.5%, local invasion 39.5%, and distant metastases 29.2%, all of them being in the lungs [33]. As the diagnostic methods improved, clinical presentation of differentiated thyroid carcinoma in the pediatric age group has changed over time. A review held at the University of Michigan comparing patients diagnosed between 1936–1970 with those diagnosed between 1971 and 1990 showed that the patients diagnosed more recently had a lower in-cidence of lymph node involvement (36% versus 63%), less local invasion (6% versus 31%), and lower incidence of lung metastases (6% versus 19%), reflecting a precocity in diagnosis over the decades, with a consequent better pro-gnosis, particularly if older than 10 years of age [34].

The most common site of distant metastasis in children is the lung with just a few cases described of bone metastases [12, 35] and of central nervous system metastases [12, 36].

The histological subtype follows a distribution similar to adults: 90–95% papillary carcinomas and 5% follicular [9, 37, 38]. Poorly differentiated tumors as insular and anaplastic are extremely rare [38].

5. Prevalence of Mutations and Expression of NIS

An important difference between thyroid carcinoma in pediatric and adult age is related to the high prevalence of expression of sodium-iodide transporter (NIS) in metastatic focus found in children [39–41]. In the absence of stimulation of TSH, the expression of NIS is undetectable in 65% of papillary tumors and 56% of follicular in patients with less than 20 years [39]. In contrast, the expression of NIS is absent or negligible in 90% of differentiated carcinomas in adults, either when searched by PCR with reverse transcription [40] or by Immunohistochemistry [42].

The greater expression of NIS in the pediatric population results in greater responsiveness to radioiodine treatment and better prognosis. In young patients, the recurrence risk increases in those who do not express the protein NIS when compared to those who have it [39]. Thus, the degree of NIS expression correlates with radioiodine avidity by metastases [43] and lower clinical recurrence rates [44].

Regarding the molecular biology of these tumors, apparently RET-PTC rearrangements occur in childhood more frequently than in adults, especially in the radiation-related tumors. Initial studies of Chernobyl-associated PTC identified RET/PTC-3 as the most common form of RET rearrangement in radiation-induced childhood PTC [45–49]. However, Pisarchik et al. found that 29% of adult and childhood PTC in Belarus actually contained RET/PTC-1 rearrangements [45]. It was hypothesized that the increase in frequency of the RET/PTC-1 rearrangements in those adults could be related to a longer latency period in those cases. In addition, patients who had RET/PTC-3 rearrangements were diagnosed much earlier after the Chernobyl incident [45]. Motomura et al. reported that 71% of sporadic PTC from children in the United States and 87% of PTC from children living in radiation-contaminated areas of Belarus contain rearrangements of the RET oncogene [50, 51].

Besides RET/PTC rearrangements, other groups suggested the immunohistochemical overexpression of MET associated with high recurrence rate in children and adolescents [51], in addition to the immunohistochemical overexpression of growth factors of vascular endothelium [52] and telomerase, however, without definitive findings [53].

In the case of follicular carcinomas, the two most frequently involved genes would be RAS and PPAR gamma, and their rearrangement might serve as a trigger to the transformation from adenoma to carcinoma [54]. However, little is known about its role in the prognosis of such neoplasms.

6. Prognosis

The prognosis of these tumors in childhood is a very interesting issue. Despite having a greater recurrence rate when compared to adults, survival seems to be better [55]. Mazzaferri and Kloos in a series with 16.6 years of followup, found a recurrence rate, in patients with less than 20 years old, around 40%, while those with more than 20 years of age had 20% recurrence rates [24]. In contrast, survival is greater than in adults. In a study done in Minsk with a large cohort of 741 patients, the survival rate was 99.3% in 5 years and 98.5% in 10 years in a pediatric population [56].

Age seems to be a very important prognostic factor in thyroid cancer. Children and adolescents are usually classified as having a better prognosis and they are classified together with all patients under 45 years old. However, Lazar et al. showed that patients with less than 10 years, mainly prepubertal, had a worse prognosis than the older and more advanced pubertal stages patients [34].

7. Treatment

Regardless, the biology of papillary and follicular tumors, the therapeutic approach is very similar for both subtypes of tumors [12, 55]. As well as in adults, the treatment of differentiated thyroid carcinoma is based on the combination of three therapeutic modalities: surgery, hormone replacement with levothyroxine, and radioiodine treatment. The surgery can vary from lobectomy to total thyroidectomy accompanied by cervical lymphadenectomy in various ways. Latest guidelines recommend total thyroidectomy, mainly for larger tumors, 1 cm [24, 57, 58] associated with cervical dissection of central or lateral compartment block if lymph node metastases are seen in preoperative imaging or during the surgery. The main surgical complications include persistent hypoparathyroidism and laryngeal nerve damage that may cause a wide spectrum of clinical consequences: from hoarseness to total vocal cord paralysis, with need for definitive tracheotomy [59].

After a total or near-total thyroidectomy, the volume of remaining gland should be less than 2 g seen in the cervical ultrasound performed around one month after surgery [55].

Even after total thyroidectomy, some radioiodine uptake is seen in the thyroid bed. Generally, this phenomenon is assigned to the remaining normal thyroid cells left by the surgeon to protect the nerve and around Berry's ligament. However, because multicentricity and metastatic disease are more common in the pediatric age group, the possibility of such outbreaks being malignant cells cannot be ruled out. Thus, most societies recommend radioiodine ablation in the vast majority of patients under 45 years old but none of them make specific recommendations for children and adolescents [55, 58–60]. However, the radioiodine treatment should be used to complement, not replace, the total thyroidectomy. The success of ablation is significantly lower in patients who have undergone less extensive surgery, such as near-total thyroidectomy [24, 61]. In most cases, one dose of radioiodine treatment is capable of achieving complete ablation; however, the procedure may have to be repeated usually 6–12 months after the first [62]. Some variables seem to influence the success of thyroid remnant ablation and the most important one seems to be the presence of lymph node metastases in low risk patients [33]. However, little is known

about the prognostic significance of achieving a successful ablation with the first dosage of I-131 in patients with differentiated thyroid cancer. Mazzaferri and Jhiang have shown that adult patients with a successful ablation had a better prognosis than those who failed: disease-free survival was 87% versus 49% after 10 years; additionally, thyroid-cancer related survival was 93% versus 78% [63]. On the other hand, the Mayo Clinic studies did not show a major impact in the overall survival and in the recurrence rates [25, 64].

The third treatment modality is thyroid hormone replacement. This suppressive therapy with thyroid hormone is believed to reduce the risk of growth or tumor proliferation induced by TSH [65]. In children and adolescents still undergoing growth, there are several studies that guarantee the efficacy and safety of this approach, particularly with regard to their final height, as long as they are carefully controlled [55].

Possible side effects of long-term suppressive therapy include osteoporosis and cardiovascular disease, especially of left ventricular hypertrophy [65, 66]; such are effects documented in adults.

8. Radioiodine in Childhood and Its Side Effects

The radioiodine treatment in pediatric age should be preferably administered in capsule form, in association with an antiemetic medication, in an attempt to ensure that the activity administered has been fully ingested.

Iodine 131 therapy can lead to a temporary loss of salivary flow and change of taste in up to 30% of the cases [59]. However, permanent xerostomia is rare. The most serious side effect from radioiodine treatment is radiation-induced leukemia that happen in 1 out of 26 treated patients in a study held in Netherlands with children and adolescents [59]. Another concern is pulmonary fibrosis that may occur in up to 1% of cases, mostly in those with diffuse lung metastases. Both effects are dose dependent and usually are seen in patients that underwent multiple treatments with a total dose above 600 mCi [59].

The actinic sialoadenitis is common but usually is reversible [67]. This complication is more frequent in the absence of iodine-avid metastases and discrete thyroid remnant, situations with greater availability of radioiodine to the salivary glands [34, 67]. A transitional impairment of spermatogenesis [34, 67, 68] is observed after ablation thera-py with high doses of iodine 131. Permanent infertility is possible with accumulated high doses [69]. Usually the production of testosterone is preserved [68, 69], although an elevation of LH can occur [69]. In women, an increment of FSH and reversible menstrual changes [68, 69] and even infertility and early menopause [69] may occur after high doses of radioiodine.

Whereas the maximum dose absorbed by the gonads is 5 mGy/mCi, Maxon inferred that permanent infertility does not occur in women with doses up to 300 mCi iodine-131 and happen in less than 10% of men with this same dose. With doses of 800 mCi or more, infertility would go up to 60% of women and more than 90% of men [69, 70].

In adolescent boys, radioiodine can also cause a decrease in quantity and affect sperm quality leading to infertility that may be transient or permanent [71].

9. Controversies

Even with all knowledge acquired today, the controversies on the ideal approach of these patients remain. The lack of studies demonstrating real benefit in overall survival of these patients comparing the different therapeutic modalities contributes to this discussion. Groups like the Mayo Clinic advocate a conservative treatment (considering the possibility of partial thyroidectomy without adjuvant radioiodine therapy) using as argument the observation of 1.7% mortality after 28 years of monitoring and 3.4% recurrence in 30 years in 58 patients under 17 years at diagnosis, in which only 38% underwent total thyroidectomy and 17% radioiodine treatment adjuvant, that is, a good evolution even without the traditionally recommended intensive treatment [25].

The main arguments of those who prefer a more aggressive approach are based on studies with long follow-up period analyzing disease-free survival and recurrence rate. For example, Chow et al., in this univariate analysis, showed that the local recurrence rate in children was reduced from 42% to 6.3% when radioiodine adjuvant treatment was per-formed ($P = .0001$) [72].

The application of the current staging system created by the International Union against Cancer (AJCC/UICC) based on the TNM and age is recommended for all types of tumors including thyroid [73], in an attempt to standardize the tumoral extension description [73]. However, in thyroid carcinoma, TNM staging does not take into consideration several additional factors that influence the evolution and prognosis and so has a limited capacity of predicting outcome in some cases. Thus, several other staging systems are being proposed in the attempt to achieve a better accuracy, among them: CAEORTC, AGES, AMES, MACE, and ATA. [58, 74–77]. These systems take into account factors identified as predictor of outcomes in retrospective studies, usually taking into consideration the presence of metastases, the age of the patient, and the extent of the tumor site. However, most of them were developed to predict cancer-specific mortality not to predict recurrence [76]. Because the mortality is low, there is not an ideal standing system for thyroid cancer yet, especially when it comes to the pediatric population. These patients are usually grouped with minors 45 years which may be responsible for the low accuracy of all existing systems for patients under 20 years of age, that clearly have a different clinical presentations and biology when compared to older patients. In a recent study performed with 65 patients under 20 years old, the staging system proposed by ATA in 2009 seems to be better than the others for predicting disease-free survival [33]. More studies with this specific population are needed to develop a specific risk assessment for this age group.

10. Conclusion

Although children with DTC typically present with locoregional metastases and a high rate of distant metastatic

disease, overall survival is very good. Treatment should be based on their increased risk for recurrence instead of overall mortality, and lifelong followup is required because recurrence and death may not occur for decades after diagnosis. Initial treatment will generally include total thyroidectomy and central compartment lymph node dissection especially if lymph node disease is found in the preoperative evaluation. Radioiodine ablation should be individualized and given to those with a higher risk of recurrence.

Large multicenter studies are needed to better understand optimal treatment approaches to this unique population. All care of pediatric DTC should be delivered by multidisciplinary specialized teams which include both pediatricians and thyroid cancer specialists to minimize possible complications and ensure competent followup.

References

[1] G. H. Tan and H. Gharib, "Thyroid incidentalomas: management approaches to nonpalpable nodules discovered incidentally on thyroid imaging," *Annals of Internal Medicine*, vol. 126, no. 3, pp. 226–231, 1997.

[2] L. Hegedus, "Clinical practice. The thyroid nodule," *The New England Journal of Medicine*, vol. 351, pp. 1764–1771, 2004.

[3] R. T. Greenlee, M. B. Hill-Harmon, T. Murray, and M. Thun, "Cancer statistics, 2001," *Cancer Journal for Clinicians*, vol. 51, no. 1, pp. 15–36, 2001.

[4] M. C. Mahoney, S. Lawvere, K. L. Falkner et al., "Thyroid cancer incidence trends in Belarus: examining the impact of Chernobyl," *International Journal of Epidemiology*, vol. 33, no. 5, pp. 1025–1033, 2004.

[5] S. Murbeth, M. Rousarova, H. Scherb, and E. Lengfelder, "Thyroid cancer has increased in the adult populations of countries moderately affected by Chernobyl fallout," *Medical Science Monitor*, vol. 10, no. 7, pp. CR300–CR306, 2004.

[6] T. Parfitt, "Chernobyl's legacy. 20 years after the power station exploded, new cases of thyroid cancer are still rising, say experts," *The Lancet*, vol. 363, no. 9420, p. 1534, 2004.

[7] E. D. Williams, "Cancer after nuclear fallout: lessons from Chernobyl accident," *Nature Reviews*, vol. 2, no. 7, pp. 543–549, 2002.

[8] J. Josefson and D. Zimmerman, "Thyroid nodules and cancers in children," *Pediatric Endocrinology Reviews*, vol. 6, no. 1, pp. 14–23, 2008.

[9] L. Bernstein and J. Gurney, "Carcinomas and other malignant epithelial neoplasms," in *Cancer Incidence and Survival among Children and Adolescents: United States SEER Program 1975–1995*, pp. 139–148, Cancer Statistics Branch, National Cancer Institute, Bethesda, Md, USA, 1999.

[10] *Childhood and Adolescent Cancer inBrazil: Data from Mortality and Population- Based Registries*, National Cancer Institute, Brazilian Society of Pediatric Oncology, Rio de Janeiro, Brazil, 2009, http://www.inca.gov.br.

[11] J. K. Harness, N. W. Thompson, M. K. McLeod, J. L. Pasieka, A. Fukuuchi, and P. L. Gerfo, "Differentiated thyroid carcinoma in children and adolescents," *World Journal of Surgery*, vol. 16, no. 4, pp. 547–554, 1992.

[12] K. D. Newman, T. Black, G. Heller et al., "Differentiated thyroid cancer: determinants of disease progression in patients <21 years of age at diagnosis: a report from the surgical discipline committee of the children's cancer group," *Annals of Surgery*, vol. 227, no. 4, pp. 533–541, 1998.

[13] M. Niedziela, E. Korman, D. Breborowicz et al., "A prospective study of thyroid nodular disease in children and adolescents in western Poland from 1996 to 2000 and the incidence of thyroid carcinoma relative to iodine deficiency and the Chernobyl disaster," *Pediatric Blood and Cancer*, vol. 42, no. 1, pp. 84–92, 2004.

[14] A. R. Hogan, Y. Zhuge, E. A. Perez, L. G. Koniaris, J. I. Lew, and J. E. Sola, "The incidence of pediatric thyroid cancer is increasing and is higher in girls than in boys and may have an adverse outcome," *Journal of Surgery Research*, vol. 156, pp. 167–172, 2009.

[15] E. Ron, J. H. Lubin, R. E. Shore et al., "Thyroid cancer after exposure to external radiation: a pooled analysis of seven studies," *Radiation Research*, vol. 141, pp. 259–277, 1995.

[16] J. H. Lubin, D. W. Schafer, E. Ron, M. Stovall, and R. J. Carroll, "A reanalysis of thyroid neoplasms in the Israeli tinea capitis study accounting for dose uncertainties," *Radiation Research*, vol. 161, no. 3, pp. 359–368, 2004.

[17] O. Catelinois, P. Verger, M. Colonna, A. Rogel, D. Hemon, and M. Tirmarche, "Projecting the time trend of thyroid cancers: its impact on assessment of radiation-induced cancer risks," *Health Physics*, vol. 87, no. 6, pp. 606–614, 2004.

[18] J. Blatt, A. Olshan, M. J. Gula, P. S. Dickman, and B. Zaranek, "Second malignancies in very-long-term survivors of childhood cancer," *American Journal of Medicine*, vol. 93, no. 1, pp. 57–60, 1992.

[19] P. Black, A. Straaten, and P. Gutjahr, "Secondary thyroid carcinoma after treatment for childhood cancer," *Medical and Pediatric Oncology*, vol. 31, pp. 91–95, 1998.

[20] S. Acharya, K. Sarafoglou, M. LaQuaglia et al., "Thyroid neoplasms after therapeutic radiation for malignancies during childhood or adolescence," *Cancer*, vol. 97, no. 10, pp. 2397–2403, 2003.

[21] R. M. Tuttle, F. Vaisman, and M. D. Tronko, "Clinical presentation and clinical outcomes in chernobyl-related paediatric thyroid cancers: what do we know now? What can we expect in the future?" *Clinical Oncology (Royal College of Radiologists)*, vol. 23, no. 4, pp. 268–275, 2011.

[22] L. A. Michel and J. E. Donckier, "Thyroid cancer 15 years after Chernobyl," *The Lancet*, vol. 359, no. 9321, p. 1947, 2002.

[23] A. J. Taylor, A. P. Croft, A. M. Palace et al., "Risk of thyroid cancer in survivors of childhood cancer: results from the British childhood cancer survivor study," *International Journal of Cancer*, vol. 125, no. 10, pp. 2400–2405, 2009.

[24] E. L. Mazzaferri and R. T. Kloos, "Clinical review 128: current approaches to primary therapy for papillary and follicular thyroid cancer," *Journal of Clinical Endocrinology and Metabolism*, vol. 86, pp. 1447–1463, 2001.

[25] D. Zimmerman, I. D. Hay, I. R. Gough et al., "Papillary thyroid carcinoma in children and adults: long-term follow-up of 1039 patients conservatively treated at one institution during three decades," *Surgery*, vol. 104, no. 6, pp. 1157–1166, 1988.

[26] M. E. Dottorini, A. Vignati, L. Mazzucchelli, G. Lomuscio, and L. Colombo, "Differentiated thyroid carcinoma in children and adolescents: a 37-year experience in 85 patients," *Journal of Nuclear Medicine*, vol. 38, pp. 669–675, 1997.

[27] S. M. Chow, S. C. Law, W. M. Mendenhall et al., "Differentiated thyroid carcinoma in childhood and adolescence—clinical course and role of radioiodine," *Pediatric Blood and Cancer*, vol. 42, no. 2, pp. 176–183, 2004.

[28] J. Farahati, E. P. Demidchik, J. Biko, and C. Reiners, "Inverse association between age at the time of radiation exposure and extent of disease in cases of radiation-induced childhood thyroid carcinoma in Belarus," *Cancer*, vol. 88, no. 6, pp. 1470–1476, 2000.

[29] R. Katoh, J. Sasaki, H. Kurihara, K. Suzuki, Y. Iida, and A. Kawaoi, "Multiple thyroid involvement (intraglandular metastasis) in papillary thyroid carcinoma. A clinicopathologic study of 105 consecutive patients," *Cancer*, vol. 70, no. 6, pp. 1585–1590, 1992.

[30] J. L. Pasieka, N. W. Thompson, M. K. McLeod, R. E. Burney, M. Macha, and T. S. Reeve, "The incidence of bilateral well differentiated thyroid cancer found at completion thyroidectomy," *World Journal of Surgery*, vol. 16, no. 4, pp. 711–716, 1992.

[31] S. L. Sugg, L. Zheng, I. B. Rosen, J. L. Freeman, S. Ezzat, and S. L. Asa, "ret/PTC-1, -2, and -3 oncogene rearrangements in human thyroid carcinomas: implications for metastatic potential?" *Journal of Clinical Endocrinology and Metabolism*, vol. 81, no. 9, pp. 3360–3365, 1996.

[32] D. K. Robie, C. W. Dinauer, R. M. Tuttle et al., "The impact of initial surgical management on outcome in young patients with differentiated thyroid cancer," *Journal of Pediatric Surgery*, vol. 33, no. 7, pp. 1134–1140, 1998.

[33] F. Visman, D. A. Bulzico, C. H. C. N. Pessoa et al., "Prognostic factors of a good response to initial therapy in children and adolescents with differentiated thyroid cancer," *Clinics*, vol. 66, no. 2, pp. 1–6, 2011.

[34] L. Lazar, Y. Lebenthal, A. Steinmetz, M. Yackobovitch-Gavan, and M. Phillip, "Differentiated thyroid carcinoma in pediatric patients: comparison of presentation and course between prepubertal children and adolescents," *Journal of Pediatrics*, vol. 154, no. 5, pp. 708–714, 2009.

[35] M. Schlumberger, F. De Vathaire, J. P. Travagli et al., "Differentiated thyroid carcinoma in childhood: long term follow-up of 72 patients," *Journal of Clinical Endocrinology and Metabolism*, vol. 65, no. 6, pp. 1088–1094, 1987.

[36] I. D. Hay, "Brain metastases from papillary thyroid carcinoma," *Archives of Internal Medicine*, vol. 147, no. 3, pp. 607–611, 1987.

[37] H. R. Harach and E. D. Williams, "Childhood thyroid cancer in England and Wales," *British Journal of Cancer*, vol. 72, no. 3, pp. 777–783, 1995.

[38] A. A. Hassoun, I. D. Hay, J. R. Goellner, and D. Zimmerman, "Insular thyroid carcinoma in adolescents: a potentially lethal endocrine malignancy," *Cancer*, vol. 79, no. 5, pp. 1044–1048, 1997.

[39] A. Patel, S. Jhiang, S. Dogra et al., "Differentiated thyroid carcinoma that express sodium-iodide symporter have a lower risk of recurrence for children and adolescents," *Pediatric Research*, vol. 52, no. 5, pp. 737–744, 2002.

[40] M. D. Ringel, J. Anderson, S. L. Souza et al., "Expression of the sodium iodide symporter and thyroglobulin genes are reduced in papillary thyroid cancer," *Modern Pathology*, vol. 14, no. 4, pp. 289–296, 2001.

[41] A. Faggiano, J. Coulot, N. Bellon et al., "Age dependent variation of follicular size and expression of iodine transporters in human thyroid tissue," *Journal of Nuclear Medicine*, vol. 45, no. 2, pp. 232–237, 2004.

[42] C. Mian, L. Lacroix, L. Alzieu et al., "Sodium iodide symporter and pendrin expression in human thyroid tissues," *Thyroid*, vol. 11, no. 9, pp. 825–830, 2001.

[43] M. R. Castro, E. R. Bergert, J. R. Goellner, I. D. Hay, and J. C. Morris, "Immunohistochemical analysis of sodium iodide symporter expression in metastatic differentiated thyroid cancer: correlation with radioiodine uptake," *Journal of Clinical Endocrinology and Metabolism*, vol. 86, no. 11, pp. 5627–5632, 2001.

[44] J. J. Min, J. K. Chung, Y. Lee et al., "Relationship between expression of the sodium/iodide symporter and 131I uptake in recurrent lesions of differentiated thyroid carcinoma," *European Journal of Nuclear Medicine*, vol. 28, no. 5, pp. 639–645, 2001.

[45] A. V. Pisarchik, G. Ermak, E. P. Demidchik, L. S. Mikhalevich, N. A. Kartel, and J. Figge, "Low prevalence of the ret/PTC3r1 rearrangement in a series of papillary thyroid carcinomas presenting in Belarus ten years post-chernobyl," *Thyroid*, vol. 8, no. 11, pp. 1003–1008, 1998.

[46] C. A. W. Welch Dinauer, R. M. Tuttle, D. K. Robie et al., "Clinical features associated with metastasis and recurrence of differentiated thyroid cancer in children," *Clinical Endocrinology*, vol. 49, no. 5, pp. 619–628, 1998.

[47] S. Klugbauer, E. Lengfelder, E. P. Demidchik, and H. M. Rabes, "High prevalence of RET rearrangement in thyroid tumors of children after the Chernobyl reactor accident," *Oncogene*, vol. 11, no. 12, pp. 2459–2467, 1995.

[48] L. DeGroot, E. Kaplan, M. McCormick, and F. Strauss, "Natural history, treatment, and course of papillary thyroid carcinoma," *Journal of Clinical Endocrinology and Metabolism*, vol. 71, pp. 414–424, 1990.

[49] I. Bongarzone, L. Fugazzola, P. Vigneri et al., "Age-related activation of the tyrosine kinase receptor protooncogenes RET and NTRK1 in papillary thyroid carcinoma," *Journal of Clinical Endocrinology and Metabolism*, vol. 81, no. 5, pp. 2006–2009, 1996.

[50] T. Motomura, Y. E. Nikiforov, H. Namba et al., "ret rearrangements in Japanese pediatric and adult papillary thyroid cancers," *Thyroid*, vol. 8, no. 6, pp. 485–489, 1998.

[51] R. Ramirez, D. Hsu, A. Patel et al., "Over-expression of hepatocyte growth factor/scatter factor (HGF/SF) and the HGF/SFreceptor (cMET) are associated with a high risk of metastasis and recurrence for children and young adults with papillary thyroid carcinoma," *Clinical Endocrinology*, vol. 53, no. 5, pp. 635–644, 2000.

[52] C. Fenton, A. Patel, C. Dinauer, D. K. Robie, R. M. Tuttle, and G. L. Francis, "The expression of vascular endothelial growth factor and the type 1 vascular endothelial growth factor receptor correlate with the size of papillary thyroid carcinoma in children and young adults," *Thyroid*, vol. 10, no. 4, pp. 349–357, 2000.

[53] A. M. Straight, A. Patel, C. Fenton, C. Dinauer, R. M. Tuttle, and G. L. Francis, "Thyroid carcinomas that express telomerase follow a more aggressive clinical course in children and adolescents," *Journal of Endocrinological Investigation*, vol. 25, no. 4, pp. 302–308, 2002.

[54] M. N. Nikiforova, R. A. Lynch, P. W. Biddinger et al., "RAS point mutations and PAX8-PPAR gamma rearrangement in thyroid tumors: evidence for distinct molecular pathways in thyroid follicular carcinoma," *Journal of Clinical Endocrinology and Metabolism*, vol. 88, no. 5, pp. 2318–2326, 2003.

[55] E. L. Mazzaferri and N. Massoll, "Management of papillary and follicular (differentiated) thyroid cancer: new paradigms using recombinant human thyrotropin," *Endocrine Related Cancer*, vol. 9, no. 4, pp. 227–247, 2002.

[56] Y. E. Demidchik, E. P. Demidchik, and C. Reiners, "Comprehensive clinical assessment of 741 operated pediatric thyroid cancer cases in Belarus," *Annals of Surgery*, vol. 243, pp. 525–532, 2006.

[57] A. L. Maia, L. S. Ward, G. A. Carvalho et al., "Nódulos de tireóide e câncer diferenciado de tireóide: consenso Brasileiro," *Arquivos Brasileiros de Endocrinologia e Metabologia*, vol. 51, no. 5, pp. 867–893, 2007.

[58] D. S. Cooper, G. M. Doherty, B. R. Haugen et al., "Revised American thyroid association management guidelines for patients with thyroid nodules and differentiated thyroid cancer," *Thyroid*, vol. 19, no. 11, pp. 1167–1214, 2009.

[59] H. M. van Santen, D. C. Aronson, T. Vulsma et al., "Frequent adverse events after treatment for childhood onset differentiated thyroid carcinoma: a single institute experience," *European Journal of Cancer*, vol. 40, no. 11, pp. 1743–1751, 2004.

[60] B. Jarzab, D. Handkiewicz-Junak, and J. Włoch, "Juvenile differentiated thyroid carcinoma and the role of radioiodine in its treatment: a qualitative review," *Endocrine Related Cancer*, vol. 12, no. 4, pp. 773–803, 2005.

[61] F. Pacini, M. Schlumberger, H. Dralle et al., "European consensus for the management of patients with differentiated thyroid carcinoma of the follicular epithelium," *European Journal of Endocrinology*, vol. 154, no. 6, pp. 787–803, 2006.

[62] F. A. Verburg, B. Keizer, C. J. M Lips et al., "Prognostic significance of good response to initial therapy with radioiodine of differentiated thyroid cancer patients," *European Journal of Endocrinology*, vol. 152, pp. 33–37, 2005.

[63] E. L. Mazzaferri and S. M. Jhiang, "Long-term impact of initial surgical and medical therapy on papillary and follicular thyroid cancer," *American Journal of Medicine*, vol. 97, no. 5, pp. 418–428, 1994.

[64] I. D. Hay, T. Gonzalez-Lousada, M. S. Reunalda, J. A. Honetschalger, and M. L. Richards, "Thompson GB. Long-term outcome in 215 children and adolescents with papillary thyroid cancer treated during 1940 though 2008," *World Journal of Surgery*, vol. 34, pp. 1192–202, 2010.

[65] G. Matuszewska, J. Roskosz, J. Włoch et al., "Evaluation of effects of L-thyroxine therapy in differentiated thyroid carcinoma on the cardiovascular system—prospective study," *Wiadomosci Lekarskie*, vol. 54, supplement 1, pp. 373–377, 2001.

[66] B. Biondi, S. Fazio, C. Carella et al., "Cardiac effects of long term thyrotropin-suppressive therapy with levothyroxine," *Journal of Clinical Endocrinology and Metabolism*, vol. 77, no. 2, pp. 334–338, 1993.

[67] C. Dinauer and G. L. Francis, "Thyroid cancer in children," *Endocrinology and Metabolism Clinics of North America*, vol. 36, no. 3, pp. 779–806, 2007.

[68] F. Pacini, M. Gasperi, L. Fugazzola et al., "Testicular function in patients with differentiated thyroid carcinoma treated with radioiodine," *Journal of Nuclear Medicine*, vol. 35, no. 9, pp. 1418–1422, 1994.

[69] J. P. Raymond, M. Izembart, V. Marliac et al., "Temporary ovarian failure in thyroid cancer patients after thyroid remnant ablation with radioactive iodine," *Journal of Clinical Endocrinology and Metabolism*, vol. 69, no. 1, pp. 186–190, 1989.

[70] L. Vini, S. Hyer, A. Al-Saadi, B. Pratt, and C. Harmer, "Prognostic for fertility and ovarian function after treatment with radioiodine for thyroid cancer," *Postgraduate Medical Journal*, vol. 78, no. 916, pp. 92–93, 2002.

[71] G. E. Krassas and N. Pontikides, "Gonadal effect of radiation from 131I in male patients with thyroid carcinoma," *Archives of Andrology*, vol. 51, no. 3, pp. 171–175, 2005.

[72] S. M. Chow, S. Yau, S. H. Lee, W. M. Leung, and S. C. K. Law, "Pregnancy outcome after diagnosis of differentiated thyroid carcinoma: no deleterious effect after radioactive iodine treatment," *International Journal of Radiation Oncology Biology Physics*, vol. 59, no. 4, pp. 992–1000, 2004.

[73] International Union Against Cancer (UICC), *TNM Classification of Malignant Tumors*, Wiley, New York, NY, USA, 7th edition, 2009.

[74] C. Wittekind, C. C. Compton, F. L. Greene, and L. H. Sobin, "TNM residual tumor classification revisited," *Cancer*, vol. 94, no. 9, pp. 2511–2516, 2002.

[75] A. R. Shaha, T. R. Loree, J. P. Shah et al., "Prognostic factors and risk group analysis in follicular carcinoma of the thyroid," *Surgery*, vol. 118, no. 6, pp. 1131–1138, 1995.

[76] I. D. Hay, E. J. Bergstralh, J. R. Goellner et al., "Predicting outcome in papillary thyroid carcinoma: development of a reliable prognostic scoring system in a cohort of 1779 patients surgically treated at one institution during 1940 through 1989," *Surgery*, vol. 114, no. 6, pp. 1050–1058, 1993.

[77] S. I. Sherman, J. D. Brierley, M. Sperling et al., "Prospective multicenter study of thyroid carcinoma treatment: initial analysis of staging and outcome. National thyroid cancer treatment cooperative study registry group," *Cancer*, vol. 83, pp. 1012–1021, 1998.

SAGE-Hindawi Access to Research
Journal of Thyroid Research
Volume 2011, Article ID 264248, 6 pages
doi:10.4061/2011/264248

Research Article

Predominant RET Germline Mutations in Exons 10, 11, and 16 in Iranian Patients with Hereditary Medullary Thyroid Carcinoma

Mehdi Hedayati,[1] Marjan Zarif Yeganeh,[1] Sara Sheikhol Eslami,[2] Shekoofe Rezghi Barez,[2] Laleh Hoghooghi Rad,[1] and Fereidoun Azizi[3]

[1] *Obesity Research Center, Research Institute for Endocrine Sciences, Shahid Beheshti University of Medical Sciences, Tehran 1985717413, Iran*
[2] *Department of Biology, Science and Research Branch, Islamic Azad University, Tehran, Iran*
[3] *Endocrine Research Center, Research Institute for Endocrine Sciences, Shahid Beheshti University of Medical Sciences, Tehran 1985717413, Iran*

Correspondence should be addressed to Mehdi Hedayati, hedayati@endocrine.ac.ir

Received 17 February 2011; Revised 17 March 2011; Accepted 14 April 2011

Academic Editor: Nelson Wohllk

Medullary thyroid carcinoma occurs in both sporadic (75%) and hereditary (25%) forms. The missense mutations of RET proto-oncogene in MTC development have been well demonstrated. To investigate the spectrum of predominant RET germline mutations in exons 10, 11, and 16 in hereditary MTC in Iranian population, 217 participants were included. Genomic DNAs were extracted from the leukocytes using the standard Salting Out/Proteinase K method. Mutation detection was performed through PCR-RFLP and DNA sequencing. In 217 participants, 43 missense mutations were identified in exons 10 (6%), 11 (13%), and 16 (0.9%). Moreover, a novel germline mutation was detected in exon 11 (S686N). Also four different polymorphisms were found in intron 16 in eight patients. The obtained data showed the frequency profile of RET mutations in Iranian individuals with MTC (19.8%). The most frequent mutation in our population was C634G whereas in most population it was C634R. Altogether, these results underline the importance of the genetic background of family members of any patient with MTC.

1. Introduction

Thyroid carcinoma is the most frequent malignant tumor of the endocrine system and accounts for nearly 1% of total human cancers [1]. Medullary thyroid carcinoma (MTC) is a malignancy of the parafollicular C cells derived from neural crest. MTC represents 5–10% of all types of thyroid cancers [2–4] and occurs in both sporadic (75%) and hereditary (25%) forms. The latter has an autosomal dominant mode of inheritance with variable expressivity and an age-related penetrance [5, 6]. This form of MTC is divided into 3 subtypes: isolated Familial MTC (FMTC) and multiple endocrine neoplasia type 2A and 2B (MEN2A, 2B). Affected individuals in FMTC develop MTC without any other abnormalities. MEN2A is characterized by MTC, pheochromocytoma, and parathyroid hyperplasia (75% of hereditary MTC) and MEN2B is characterized by MTC, pheochromocytoma, mucosal neuromas, ganglioneuromatosis of the gut, and a Marfanoid habitus (MEN2B) [5–8]. The gene(s) responsible for FMTC, MEN2A, and MEN2B were mapped on chromosome 10q11.2 by genetic linkage analysis [9]. Rearranged during transfection (RET) proto-oncogene is located on 10q11.21 chromosome [10] within the candidate region and has 21 exons and its point mutations have been identified in FMTC, MEN2A, and MEN2B. This proto-oncogene encodes a single-pass transmembrane receptor with a tyrosine kinase activity that is crucial in signal transduction during cell growth and differentiation [11]. The RET receptor in cell membrane is composed of one cystein rich residue, four cadherin-like repeats, and one calcium binding site in extracellular portion and contains tyrosine kinase domain in intracellular portion [12–14]. Upon ligand binding, RET dimerization is induced and mutual transphosphorylation of tyrosine residues occurs [15].

RET proto-oncogene loss of function results in Hirchsprung disease and its gain of function is implicated in a number of cancer syndromes such as MTC [13, 15]. As RET is a proto-oncogene, a single activating mutation in its one allele is sufficient to cause neoplastic changes [16]. Hereditary MTC is caused by germline mutations in the RET proto-oncogene and its somatic mutations is implicated in the sporadic MTC [2, 17]. The most frequent mutations in the RET proto-oncogene have been found in five cysteine codons 609, 611, 618, and 620 of exon 10 and codon 634 of exon 11. In addition, some other mutations have also been identified in noncystein codons such as 804 in exon 14, 883 in exon 15, and 918 in exon 16 [18, 19]. A germline mutation in this proto-oncogene has been observed in more than 95% of MEN2 patients [3] and several studies have found that point mutations are the extracellular domain in more than 96% MEN2A and 86% FMTC patients [13, 20]. These mutations induce RET proto-oncogene catalytic activity through disulfide homodimerization even in ligand absence [21–24]. Germline mutations also occur in the RET intracellular domain in codons 768, 790, and 791 (exon 13), codons 804, 844 (exon 14), and codon 891 (exon 15) in the FMTC [25] and codon 918 (exon 16) in MEN2B patients [16].

The early diagnosis of carrier RET mutation individuals, which are susceptible to develop MTC later in life, is possible. Genetic screening especially is useful for first-degree kindred of MTC patients. The aim of this study was to determine the allele frequency of predominant RET germline mutations in exons 10, 11, and 16 among Iranian hereditary MTC patients.

2. Materials and Methods

2.1. Patients. The study population consisted of 217 individuals, including 151 patients and 66 their first-degree relatives diagnosed for MTC between 2002 and 2010. They were referred to Research Institute for Endocrine Sciences, Shahid Beheshti University of Medical Science and the volunteer individuals were included in the survey after obtaining an informed consent. The diagnosis of MTC was confirmed by histopathologic documents. After germline RET mutation analysis, the first-degree relatives of MTC patients with positive mutations were also examined for RET mutations. This study has been approved by the Institutional Review Board and Ethics Committee of Obesity Research Center, Research Institute for Endocrine Sciences, Shahid Beheshti University of Medical Sciences.

2.2. RET Genetic Analysis. Blood samples were collected in EDTA from all 217 subjects. Genomic DNA was extracted from peripheral leucocytes samples according to a Standard Salting-out/Proteinase K method. An aliquot of DNA for each individual was stored at -20°C.

The RET gene exons 10, 11, and 16 were analyzed in all subjects using PCR-RFLP methods [22, 23]. For positive patients, sequencing was carried out in both sense and antisense direction.

For amplification of the DNA segment containing RET exon 10, the following primers were used: (10F 5′GCGCCCCAGGAGGCTGATGC3′) and (10R 5′CGTGGTGGTCCCGGCCGCC3′). The RET exon 11 was amplified using following primers: (11AF 5′CCTCTGCGGTGCCAAGCCTC3′) and (11AR 5′CACCGGAAGAGGAGTAGCTG3′) [23, 24, 26]. Amplification was carried out in a volume of 50 μL containing 1.5 μL of 10×buffer, 50 ng DNA, 0.3 μL of each dNTPs (10 mM) (Boehringer Mannheim Co.), 1 μL of each exons 10 and 11 primers (10 μM) (TIB MOLBIOL Synthesalabor Co.), 0.25 μL $MgCl_2$ (50 mM), and one U Taq polymerase (Boehringer Mannheim Co.). PCR reaction for both exons 10 and 11 was 30 cycles and performed in an automatic thermocycler (Omnigene & Hybaid Co.) under the following conditions: denaturation at 93°C for 45 seconds, annealing at 67°C for 30 seconds and extension at 72°C for another 45 seconds, and final extension at 72°C for 10 minutes [18, 27].

For amplification of the DNA segment containing RET exon 16, the following primers were used: (16F 5′GTGCCCAGGAGTGTCTACCA3′) and (16R 5′CAGGACCACAGGAGGGTAAC3′). A PCR reaction of exon 16 was performed in a 15 μL mixture containing 50 ng DNA, 0.35 μL of $MgCl_2$ (50 mM), 0.5 μL of each dNTPs (10 mM) (Boehringer Mannheim Co.), 0.6 μL of each exon 16 primers (10 μM) (TIB MOLBIOL Synthesalabor Co.), 1.5 μL of 10 × buffer, and one U Taq polymerase (Boehringer Mannheim Co.). PCR reaction for exon 16 was 30 cycles and performed in an automatic thermocycler (Omnigene & Hybaid Co.) under the following conditions: denaturation at 92°C for 10 minutes and 93°C for 45 seconds, annealing at 59.5°C for 30 seconds, extension at 72°C for 55 seconds, and final extension at 72°C for 10 minutes [27–29].

The amplified PCR products were digested by each of Taq I, BstU I, Mbo II, Rsa I, Nla IV (England Biolabs), and Cfo I (Roehe Molecular Biochemicals) restriction enzymes for exon 10. The products were digested with the following restriction enzymes Cfo I, Rsa I, Hae III, and Dde I for exon 11, and FokI for exon 16 (England Biolabs) in the restriction buffer according to the manufacturer's instructions [10, 27, 28]. The RFLP-produced patterns by these restriction enzymes in the presence and absence of each RET exon 10, 11, and 16 mutations have been shown in Table 1. The digested samples were separated by electrophoresis through a 10% nondenaturing polyacrylamide gel electrophoresis and then detected by silver staining method. The positive samples for RET mutation then were sequences.

3. Results

Altogether, 217 individuals, including 126 females and 91 males, participated in this study and the overall female-to-male ratio was 1.4 : 1. Among these, 151 individuals were diagnosed with MTC (88 females and 63 males) and 66 individuals were their first-degree relatives. The mean age of individuals was 33.4 ± 15.8 years. Genetic analyses revealed a germline RET missense mutation in 43 out of 217 (19.8%) individuals that 24 mutations occurred in female and 19 mutations were in male. From RET positive individuals, 36 mutations were in patients and seven mutations were in their

Table 1: Characterization and distribution of RET proto-oncogene germ-line mutations in exons 10, 11, 16, and intron 16 among patients with MTC and their families.

RET mutation	Exon	Changed bp		
		Normal (Mutant)	Frequency	Families
C611W	10	TGC (TGG)	0	0
C618Y	10	TGC (TAC)	5	2
C618R	10	TGC (CGC)	1	1
C618F	10	TGC (TTC)	4	4
C618S	10	TGC (AGC)	1	1
C620R	10	TGC (CGC)	1	1
C620F	10	TGC (TTC)	1	1
C634R	11	TGC (CGC)	1	1
C634Y	11	TGC (TAC)	5	3
C634G	11	TGC (GGC)	11	9
C634W	11	TGC (TGG)	1	1
C634S	11	TGC (AGC)	9	2
S686N	11	AGC>AAC	1	1
M918T	16	ATG (ACG)	2	2
Intron 16		A>T (rs3026772)	2	2
		45044G>A	1	1
		45095C>A	4	1
		45190C>A	1	1

first-degree relatives. Moreover, the mutations found in this study are belonging to the independent families.

In this study the majority of RET mutations (28 of 43, 65.1%) were located in exon 11 (11 C634G, nine C634S, five C634Y, one C634R, one C634W, and one S686N) (Figure 1). Interestingly, one of the positive RET patients had a new restriction site in exon 11 for CfoI restriction enzyme, but its cut fragments on a poly acryl amid gel were differed from another positive patients who had this restriction site (C634R). With direct DNA sequencing of exon 11 of this patient, a new missense mutation was detected at codon 686 (Ser686Asn, AGC>AAC) that has been not reported yet. This patient was an 18-year-old girl who had underwent thyroidectomy for thyroid nodules about 2 years ago, and her father suffered from very aggressive MTC.

The other 15 mutations were found in exons 10 and 16. In particular, 13 of 43 mutations (30.2%) were in exon 10 (five C618Y, four C618F, one C618S, one C618R, one C620F, and one C620R). In addition, two of 43 mutations (4.6%) were identified at codon 918 of exon 16 (M918T). One of these patients was a 14-year-old girl with early-diagnosed MTC. This mutation was found only in this patient although her parents were normal suggesting that it may be a de novo mutation. The other patient with M918T mutation was a boy that had been thyroidectomized when he was 10-year-old and he was diagnosed for early MTC. Unfortunately, he died when he was 19-year-old, because of distant metastasis to lung and brain.

Additionally, in the present study four sequence variations were detected in intron 16 of the RET proto-oncogene in seven patients and one their relatives, which three of those were new variations. These polymorphisms include A>T (rs3026772), 45044G>A, 45095C>A, and 45190C>A. A first variant, A>T (rs3026772), was identified in intron 16 in 2 patients affected to MTC. A second variant, 45044G>A, was detected in a patient that had a mutation in codon 634 (C634S). A third variant, 45095C>A, was identified in a family (4 individuals) with MEN2B where all of them carried a mutation in codon 611 (C611Y). The last variant, 45190C>A, was in a patient diagnosed for MTC with additional mutation in codon 620 (C620R).

4. Discussion

In present study, by mutational screening of the RET proto-oncogene we found 43 germline mutations in the predominant codons of exons 10, 11, and 16 among 217 individuals with MTCs. All of these encode cysteine codon 618 or 620 in exon 10 (30.2%) and cysteine codon 634 in exon 11 (65.1%), except of two (4.6%) mutations that occurred in codon 918 in exon 16 (M918T) and one new mutation that found in codon 686 in exon 11 (S686N). In this investigation, overall frequency profile of RET proto-oncogene germline mutation in Iranian MTC patients was estimated 19.8%.

Mutations of the extracellular RET cysteine-rich domain at codons 634, 609, 611, 618, and 620 resulted in ligand-independent dimerization of receptor molecules, enhanced phosphorylation of intracellular substrates, and cell transformation. Germline mutations in codons 609, 611, 618, 620, 634, and 768 have been discovered predominantly in MEN

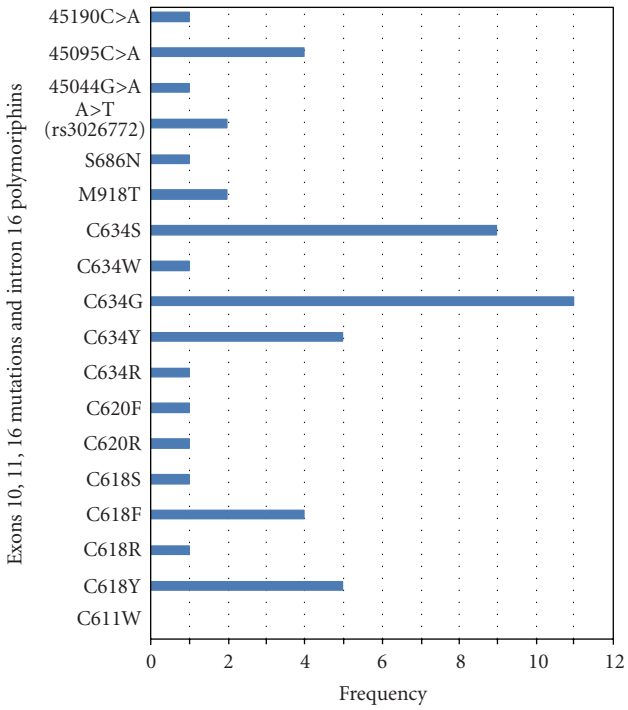

Figure 1: The allele frequency of the RET proto-oncogene mutations in Iranian patients with MTC.

2A and FMTC [27–29]. Mutation of the intracellular tyrosine kinase (codon 918) has no effect on receptor dimerization but causes constitutive activation of intracellular signaling pathways and also results in cellular transformation. It is demonstrated that patients with codon 918 mutations and MEN2B have a high risk of aggressive MTC occurring at a young age [29].

The mutations at codon 634, known as a common mutation in Caucasians [26], accounted for 65.1% of all mutations found in Iranian patients with MTC, in our study. Among five different types of nucleotide substitution found in this codon, changes from Cys to Gly (11 of 43) were the most common, followed by Cys to Ser (9 of 43), Cys to Tyr (5 of 43), Cys to Arg (one of 43), and Cys to Trp (one of 43). A comparison of our data with those available in the literature on other Caucasians indicates that the common alteration from Cys634Gly in this study may represent a founder effect. Indeed it has been reported that Cys634Arg mutation-that is the most common mutation in MTC patients in many population—is related to parathyroid diseases [30]. However, this mutation is rare in our population (identified in one patient, only). However, in the very recent study that carried out by Alvandi et al. in Iran, the most frequent mutation was Cys634Arg (five mutations in 55 patients). This different result in comparison with our study may be related to different genetic background of those studied population [31].

Fernández et al. in a study showed that the most frequent RET mutation in MEN 2A Spanish families is C634Y [32]. The RET proto-oncogene mutation analyses in French hereditary MEN2A and their first-degree relatives revealed that the most frequent mutation in this population was C634R and C634Y [29, 33]. In contrast, more prevalent mutation in FMTC in Sardinia was observed in codon 804 (V804M) and the less frequent mutant allele was present in codon 634 [34]. Also, high prevalence of RET mutations in the hereditary type of MTC has been found in codons 634 (C634R), 918 (M918T), 768, and 804 in American population [19]. Another study in China showed that the highest frequency of the RET mutation in patients with hereditary MTC was in codon 634 (C634Y) and 918 (M918T) in MEN2A and MEN2B, respectively. However, the most frequent RET proto-oncogene mutations in Saudi's families with MEN2A and FMTC [35] and in the Netherlands population with FMTC were at codon 618 [19]. A mutation rate in codon 918 (M918T) was high in sporadic type of MTC in Portugal, Czech Republic, and Italy population [2–4, 33, 36]. However, we identified only two M918T germline mutations in studied population, which in comparison with other population is low.

In general, it is apparent that the prevalence of RET proto-oncogene mutations in most Caucasian population may be related to codon 634 and codon 918. The present study also is in agreement with these reports, except for codon 918.

We showed the frequency profile of RET proto-oncogene mutations in a sample of 151 Iranian MTCs and 66 their relatives. These results underline the importance of the genetic background in the distribution of RET mutations and should be taken into account in genetic evaluation of MTC patients.

Finally, it is suggested that other RET exons especially those with high frequency of mutations such as exons 13, 14, and 15 should be examined. Direct sequencing analysis is also an accurate method to detect unknown RET mutations. Furthermore, a transforming activity and functional effect(s) of a new RET mutants such as S686N and intronic polymorphisms remain to be elucidated.

Acknowledgments

This study was supported by a research grant from the Endocrine Research Center, Shahid Beheshti University of Medical Sciences. The authors are indebted to kind collaboration of several endocrinology specialists. They express their gratitude to the staff of molecular genetic laboratory at the Endocrine Research Center, for their skillful technical assistance.

References

[1] M. N. Nikiforova and Y. E. Nikiforov, "Molecular genetics of thyroid cancer: implications for diagnosis, treatment and prognosis," *Expert Review of Molecular Diagnostics*, vol. 8, no. 1, pp. 83–95, 2008.

[2] S. Dvoráká, E. Václavíková, V. Sýkorová et al., "New multiple somatic mutations in the RET proto-oncogene associated with a sporadic medullary thyroid carcinoma," *Thyroid*, vol. 16, no. 3, pp. 311–316, 2006.

[3] M. M. Moura, B. M. Cavaco, A. E. Pinto et al., "Correlation of RET somatic mutations with clinicopathological features in sporadic medullary thyroid carcinomas," *British Journal of Cancer*, vol. 100, no. 11, pp. 1777–1783, 2009.

[4] D. J. Marsh, D. L. Learoyd, and B. G. Robinson, "Medullary thyroid carcinoma: recent advances and management update," *Thyroid*, vol. 5, no. 5, pp. 407–424, 1995.

[5] R. Elisei, B. Cosci, C. Romei et al., "Prognostic significance of somatic RET oncogene mutations in sporadic medullary thyroid cancer: a 10-year follow-up study," *Journal of Clinical Endocrinology & Metabolism*, vol. 93, no. 3, pp. 682–687, 2008.

[6] R. S. Sippel, M. Kunnimalaiyaan, and H. Chen, "Current management of medullary thyroid cancer," *Oncologist*, vol. 13, no. 5, pp. 539–547, 2008.

[7] R. V. Thakker, "Multiple endocrine neoplasia—syndromes of the twentieth century," *Journal of Clinical Endocrinology & Metabolism*, vol. 83, no. 8, pp. 2617–2620, 1998.

[8] H. Donis-Keller, S. Dou, D. Chi et al., "Mutations in the RET proto-oncogene are associated with MEN 2A and FMTC," *Human Molecular Genetics*, vol. 2, no. 7, pp. 851–856, 1993.

[9] C. G. P. Mathew, K. S. Chin, D. F. Easton et al., "A linked genetic marker for multiple endocrine neoplasia type 2A on chromosome 10," *Nature*, vol. 328, no. 6130, pp. 527–528, 1987.

[10] S. Shirahama, K. Ogura, H. Takami et al., "Mutational analysis of the RET proto-oncogene in 71 Japanese patients with medullary thyroid carcinoma," *Journal of Human Genetics*, vol. 43, no. 2, pp. 101–106, 1998.

[11] S. Manié, M. Santoro, A. Fusco, and M. Billaud, "The RET receptor: function in development and dysfunction in congenital malformation," *Trends in Genetics*, vol. 17, no. 10, pp. 580–589, 2001.

[12] M. P. Cosma, M. Cardone, F. Carlomagno, and V. Colantuoni, "Mutations in the extracellular domain cause RET loss of function by a dominant negative mechanism," *Molecular and Cellular Biology*, vol. 18, no. 6, pp. 3321–3329, 1998.

[13] S. Bethanis, G. Koutsodontis, T. Palouka et al., "A newly detected mutation of the RET protooncogene in exon 8 as a cause of multiple endocrine neoplasia type 2A," *Hormones*, vol. 6, no. 2, pp. 152–156, 2007.

[14] J. Grimm, M. Sachs, S. Britsch et al., "Novel p62dok family members, dok-4 and dok-5, are substrates of the c-Ret receptor tyrosine kinase and mediate neuronal differentiation," *Journal of Cell Biology*, vol. 154, no. 2, pp. 345–354, 2001.

[15] C. J. M. Lips, J. W. M. Höppener, and J. H. H. Thijssen, "Medullary thyroid carcinoma: role of genetic testing and calcitonin measurement," *Annals of Clinical Biochemistry*, vol. 38, part 3, no. 3, pp. 168–179, 2001.

[16] R. Elisei, C. Romei, B. Cosci, L. Agate, V. Bottici, E. Molinaro et al., "RET genetic screening in patients with medullary thyroid cancer and their relatives: experience with 807 individuals at one center," *Journal of Clinical Endocrinology & Metabolism*, vol. 92, no. 12, pp. 4725–4729, 2007.

[17] N. Wohllk, G. J. Cote, M. M. J. Bugalho et al., "Relevance of RET proto-oncogene mutations in sporadic medullary thyroid carcinoma," *Journal of Clinical Endocrinology & Metabolism*, vol. 81, no. 10, pp. 3740–3745, 1996.

[18] M. Lallier, D. St-Vil, M. Giroux et al., "Prophylactic thyroidectomy for medullary thyroid carcinoma in gene carriers of MEN2 syndrome," *Journal of Pediatric Surgery*, vol. 33, no. 6, pp. 846–848, 1998.

[19] C. Eng, D. Clayton, I. Schuffenecker, G. Lenoir, G. Cote, R. F. Gagel et al., "The relationship between specific RET proto-oncogene mutations and disease phenotype in multiple endocrine neoplasia type 2. International RET mutation consortium analysis," *Journal of the American Medical Association*, vol. 276, no. 19, pp. 1575–1579, 1996.

[20] S. Chappuis-Flament, A. Pasini, G. de Vita et al., "Dual effect on the RET receptor of MEN 2 mutations affecting specific extracytoplasmic cysteines," *Oncogene*, vol. 17, no. 22, pp. 2851–2861, 1998, Laboratoire de Génétique, CNRS UMR 5641, Domaine Rockefeller, Lyon, France.

[21] M. Santoro, F. Carlomagno, A. Romano et al., "Activation of RET as a dominant transforming gene by germline mutations of MEN2A and MEN2B," *Science*, vol. 267, no. 5196, pp. 381–383, 1995.

[22] C. Eng, P. A. Crossey, L. M. Mulligan et al., "Mutations in the RET proto-oncogene and the von Hippel-Lindau disease tumour suppressor gene in sporadic and syndromic phaeochromocytomas," *Journal of Medical Genetics*, vol. 32, no. 12, pp. 934–937, 1995.

[23] M. Hedayati, I. Nabipour, N. Rezaei-Ghaleh, and F. Azizi, "Germline RET mutations in exons 10 and 11: an Iranian survey of 57 medullary thyroid carcinoma cases," *Medical Journal of Malaysia*, vol. 61, no. 5, pp. 564–569, 2006.

[24] M. Hedayati, M. Zarif Yeganeh, M. Daneshpour, M. Ahmadi, and F. Azizi, "Frequent germline mutation in RET proto-oncogene exons 10 and 11 in hereditary MTC of Iranian patients," *Kowsar Medical Journal*, vol. 15, no. 1, pp. 17–21, 2010.

[25] Y. Zhou, Y. Zhao, B. Cui et al., "RET proto-oncogene mutations are restricted to codons 634 and 918 in mainland chinese families with MEN2A and MEN2B," *Clinical Endocrinology*, vol. 67, no. 4, pp. 570–576, 2007.

[26] L. M. Mulligan, C. Eng, C. S. Healey et al., "Specific mutations of the RET proto-oncogene are related to disease phenotype in MEN 2A and FMTC," *Nature Genetics*, vol. 6, no. 1, pp. 70–74, 1994.

[27] A. Machens, P. Niccoli-Sire, J. Hoegel et al., "Early malignant progression of hereditary medullary thyroid cancer," *The New England Journal of Medicine*, vol. 349, no. 16, pp. 1517–1525, 2003.

[28] K. Frank-Raue, A. Machens, C. Scheuba, B. Niederle, H. Dralle, and F. Raue, "Difference in development of medullary thyroid carcinoma among carriers of RET mutations in codons 790 and 791," *Clinical Endocrinology*, vol. 69, no. 2, pp. 259–263, 2008.

[29] I. Schuffenecker, M. Virally-Monod, R. Brohet et al., "Risk and penetrance of primary hyperparathyroidism in multiple endocrine neoplasia type 2A families with mutations at codon 634 of the RET proto-oncogene. Groupe d'etude des tumeurs à calcitonine," *Journal of Clinical Endocrinology & Metabolism*, vol. 83, no. 2, pp. 487–491, 1998.

[30] E. Saggiorato, I. Rapa, F. Garino et al., "Absence of RET gene point mutations in sporadic thyroid C-cell hyperplasia," *Journal of Molecular Diagnostics*, vol. 9, no. 2, pp. 214–219, 2007.

[31] E. Alvandi, S. M. Akrami, M. Chiani et al., "Molecular analysis of the RET proto-oncogene key exons in patients with medullary thyroid carcinoma: a comprehensive study of the Iranian population," *Thyroid*, vol. 2, no. 4, pp. 373–382, 2011.

[32] R. M. Fernández, E. Navarro, G. Antiñolo, M. Ruiz-Ferrer, and S. Borrego, "Evaluation of the role of RET polymorphisms/haplotypes as modifier loci for MEN 2, and analysis of the correlation with the type of RET mutation in a series of Spanish patients," *International Journal of Molecular Medicine*, vol. 17, no. 4, pp. 575–581, 2006.

[33] I. Berard, J. L. Kraimps, F. Savagner et al., "Germline-sequence variants S836S and L769L in the RE arranged during transfection (RET) proto-oncogene are not associated with predisposition to sporadic medullary carcinoma in the french population," *Clinical Genetics*, vol. 65, no. 2, pp. 150–152, 2004.

[34] G. Pinna, G. Orgiana, A. Riola et al., "RET proto-oncogene in Sardinia: V804M is the most frequent mutation and may be associated with FMTC/MEN-2A phenotype," *Thyroid*, vol. 17, no. 2, pp. 101–104, 2007.

[35] T Nasser, F. Qari, A Karawgh, and J. Al Aama, "RET codon 618 mutations is the most frequent phenotype in Saudi families with multiple endocrine neoplasia type 2A," in *Proceedings of the European Congress of Endocrinology*, vol. 22, p. 380, European Society of Endocrinology, Prague, Czech Republic, April 2010.

[36] M. Robledo, L. Gil, M. Pollán et al., "Polymorphisms G691S/S904S of RET as genetic modifiers of MEN 2A," *Cancer Research*, vol. 63, no. 8, pp. 1814–1817, 2003.

SAGE-Hindawi Access to Research
Journal of Thyroid Research
Volume 2011, Article ID 815826, 10 pages
doi:10.4061/2011/815826

Review Article

Medullary Thyroid Carcinoma: Molecular Signaling Pathways and Emerging Therapies

Karen Gómez,[1] Jeena Varghese,[2] and Camilo Jiménez[2]

[1] *Department of Endocrinology, Hospital San Juan de Dios, Avenida 14, Calles 6 Y 7 Paseo Colon, 1475-1000 San José, Costa Rica*
[2] *Department of Endocrine Neoplasia and Hormonal Disorders, Unit 1461, The University of Texas MD Anderson Cancer Center, 1515 Holcombe Boulevard, Houston, TX 77030, USA*

Correspondence should be addressed to Camilo Jiménez, cjimenez@mdanderson.org

Received 16 January 2011; Accepted 10 March 2011

Academic Editor: Ana O. Hoff

Research on medullary thyroid carcinoma (MTC) over the last 55 years has led to a good understanding of the genetic defects and altered molecular pathways associated with its development. Currently, with the use of genetic testing, patients at high risk for MTC can be identified before the disease develops and offered prophylactic treatment. In cases of localized neck disease, surgery can be curative. However, once MTC has spread beyond the neck, systemic therapy may be necessary. Conventional chemotherapy has been shown to be ineffective; however, multikinase inhibitors have shown promise in stabilizing disease, and this year will probably see the approval of a drug (Vandetanib) for advanced unresectable or metastatic disease, which represents a new chapter in the history of MTC. In this paper, we explore newly understood molecular pathways and the most promising emerging therapies that may change the management of MTC.

1. Introduction

Medullary thyroid carcinoma (MTC) is a neuroendocrine tumor derived from parafollicular cells of the thyroid gland [1]. MTC represents less than 3% of thyroid carcinomas in the United States [2]. The first description of its major histological features and characterization as a separate entity was done in 1959 by Hazard et al. [3]. It was then rapidly recognized that this carcinoma had distinctive clinical features, in that MTC was found to be associated with pheochromocytomas and other tumors, an association now known as multiple endocrine neoplasia type 2 (MEN2) [4]. The identification of familial cases led to the conclusion that many MTCs were probably hereditary [5]. In 1966, MTC was found to arise from the calcitonin-secreting parafollicular cells [6]. Subsequently, calcitonin provocation tests with calcium and/or pentagastrin were used to identify individuals susceptible to familial MTC, and those individuals were offered prophylactic thyroidectomy [7].

Activating mutations of the *Rearranged during Transfection* (*RET*) proto-oncogene were described for the first time in patients with familial forms of MTC in 1993 [8, 9]. Since then, several germline *RET* proto-oncogene mutations have been found in almost 100% of hereditary MTCs. Additionally, somatic *RET* proto-oncogene mutations have been found in approximately 40% of patients with sporadic MTC [10, 11]. These discoveries created new paradigms for the management of MTC: (1) the identification of germline *RET* proto-oncogene mutation carriers would allow the removal of the thyroid cells at risk for transformation early in life (this paradigm is perhaps the most perfect example of primary cancer prevention in humans to date), (2) the identification of several hidden familial medullary thyroid cancers [12], and (3) the abnormally activated *RET* gene might become a target to treat patients with advanced sporadic and hereditary MTC. Our goal in this paper is to describe the molecular pathways associated with MTC tumorigenesis and emerging therapies against this disease (Figure 1).

2. MTC and the *RET* Proto-Oncogene

Autonomous cell growth is the defining feature of all benign or malignant tumors. Malignant neoplasms have

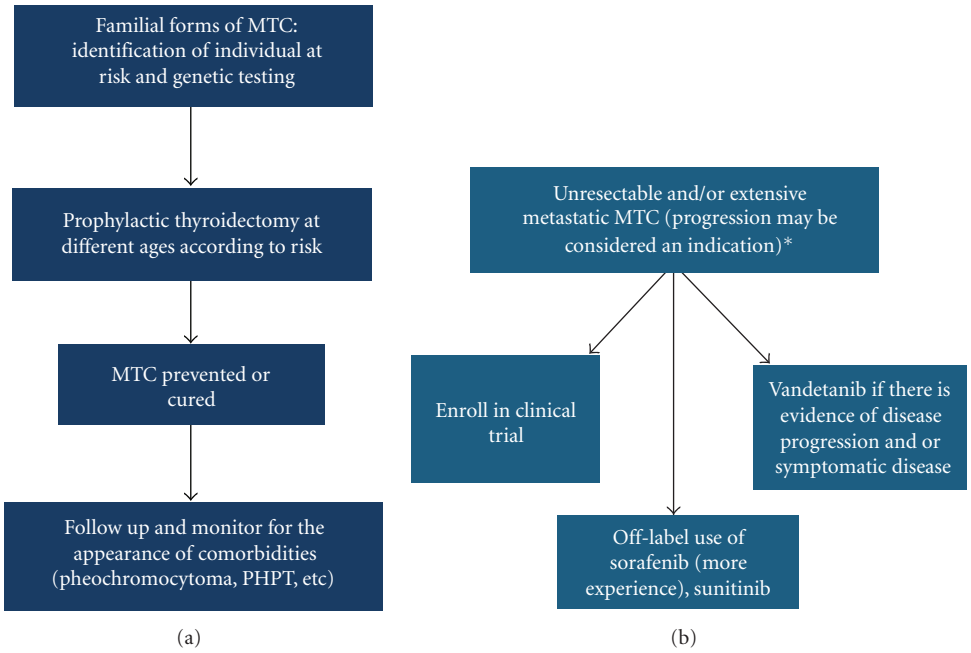

Figure 1: From prevention of MTC to treatment of incurable disease. Ideal approach to familial forms of MTC (a) versus treatment options in unresectable and/or extensive metastatic disease and/or progression. (b) *Every patient should be evaluated in an individual basis, and the decision to treat as well as the indication is not always clear cut as one must take into consideration quality of life issues and adverse events associated with treatment.

the capacity to invade the surrounding normal tissue and metastasize to distant sites. Molecules that are responsible for growth and other fundamental cell functions are frequently mutated in cancers. An example of such molecules is the tyrosine kinase (TK) receptors (Figure 2). TK receptors are membrane-spanning proteins with large N-terminal extracellular domains that act as ligand-binding sites and intracellular domains that catalyze the transfer of the γ phosphate of adenosine-5′-triphosphate (ATP) to hydroxyl groups of tyrosines of target proteins. TKs control a wide range of fundamental processes of cells such as the cell cycle, proliferation, angiogenesis, differentiation, motility, apoptosis, and survival.

The *RET* proto-oncogene is located in chromosome 10q11.2 [13]. The gene has 21 exons [14] and codes for a receptor TK [15]. The RET receptor is a transmembrane protein constituted by extracellular, transmembrane, and cytoplasmatic domains. The extracellular domain has a stretch of approximately 100 amino acids that are similar to members of the cadherin family of $Ca2^{+}$dependent cell adhesion molecules [16]. The binding of calcium to this cadherin-like domain is needed for conformational changes necessary for the interaction with different glial cell line-derived neurotrophic factor ligand family members (GDNF, neurturin, artemin, and persephin) [17]. These ligands in conjunction with a ligand-specific coreceptor (GFRα 1–4) activate RET [18]. These ligands or coreceptors are not always needed for RET activation [19]. Following RET activation, specific tyrosine residues are phosphorylated. These residues serve as docking sites for adaptor proteins that link the receptor to the main signal transduction pathways. Different activated sites trigger the activation of different pathways. For instance, tyrosine 1015 is a binding site for phospholipase C that activates protein kinase C (PKC). Other examples are given by the phosphorylated γ tyrosine 981 which is responsible for Src activation upon RET engagement [20] and the phosphorylation of tyrosine 1062, several adaptor or effector proteins are recruited including Shc, FRS2, Dok family proteins, insulin receptor substrate 2, and Enigma [21]. Then, various pathways that regulate cell survival, differentiation, proliferation, and chemotaxis [20] are activated, including RAS-extracellular signal-regulated kinase (ERK), phosphatidylinositol 3-kinase (PI3K)-Akt, p58 mitogen-activated protein kinase (MAPK), and Jun N-terminal kinase (JNK) [22] (Figure 3).

Mutated *RET* is expressed in derivatives of neural crest cells, including hereditary and sporadic MTC and pheochromocytoma [23]. These mutations are referred to as gain-of-function, because they lead to either a constitutively active TK or decreased specificity of the TK for its substrate [24].

3. *RET* Genotype-Phenotype Correlations

3.1. Sporadic MTC. Sporadic MTC constitutes 65% to 75% of MTC cases [25]. The most frequent clinical presentation is that of a thyroid nodule. Up to 75% of patients with palpable MTC have nodal metastases in the central and ipsilateral neck compartments, and 47% of patients with palpable MTC have nodal metastases in the contralateral neck [26]. Distant metastases frequently occur in the liver, lungs, and bones.

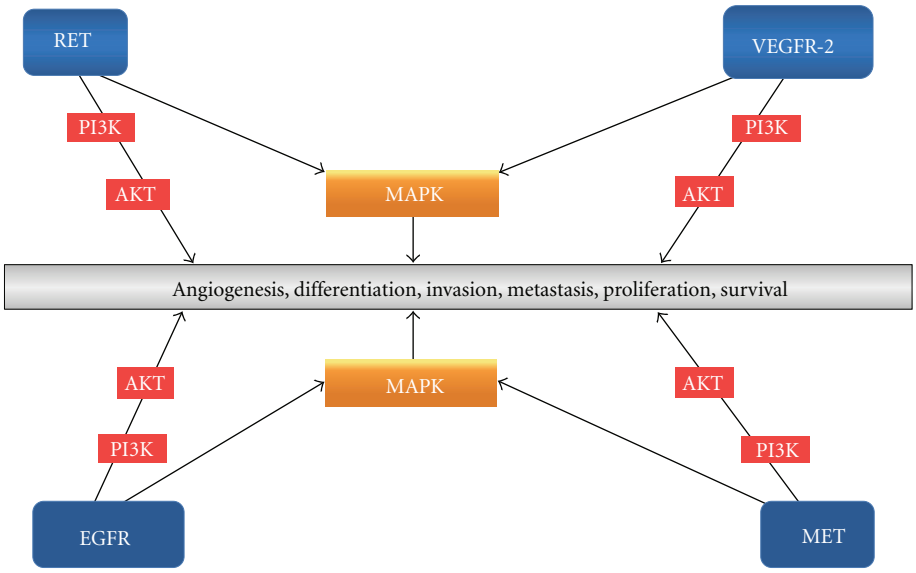

Figure 2: Simplified schematic representation of some of the TKs and pathways involved in MTC carcinogenesis as well normal physiology. These TKs represent important targets of TKIs. Written in the gray box are the consequences of the activation of multiple pathways and not of any one in particular.

Somatic mutations occur in 30% to 40% of cases [10, 11]. Exon 16, codon 918 ATG → ACG mutation is the most common somatic mutation in sporadic MTC [27]. This mutation is associated with larger tumors and a more advanced disease stage at diagnosis [11].

3.2. Hereditary MTC. Hereditary MTC constitutes 25% to 35% of MTC cases [25]. Hereditary MTC is preceded by C-cell hyperplasia and is usually bilateral and multicentric [28]. Hereditary forms of MTC are caused by germline *RET* proto-oncogene mutations and occurs as part of the MEN2 syndromes. MEN2A is characterized by MTC in almost 100% of gene carriers, pheochromocytomas, and parathyroid tumors. The most common mutations in MEN2A occur in one of six cysteine residues (codons 609, 611, 618, 620, 630, and 634) in the RET extracellular domain. The most frequently mutated residue found in patients with MEN2A is cysteine 634, in which removal of one-half of an intramolecular disulfide bond allows formation of an intermolecular disulfide bond with a second mutant molecule, thus leading to constitutive receptor dimerization [29]. PI3K-Akt and MAPK pathways have been implicated in MEN2A [30].

There are three variants of the syndrome: (1) MEN2A with Hirschsprung disease, (2) MEN2A associated with cutaneous lichen amyloidosis, and (3) familial MTC, in which MTC is the only manifestation. Familial MTC *RET*-mutation affects the extracellular cysteine-rich region and the TK domain. This variant tends to be the least aggressive form of hereditary MTC.

MEN2B is the most distinctive and aggressive MEN2 syndrome. The most common mutations associated with MEN2B are M918T and A883F. These mutations, unlike MEN2A, are in the TK domain and lead to an activated monomeric form, thus altering substrate specificity [29]. The PI3K/Akt cascade has been shown to be important in the pathogenesis of MEN2B in cell lines [31].

4. TK Receptors Other Than RET Involved in MTC Tumorigenesis

4.1. Epidermal Growth Factor Receptor. The epidermal growth factor receptor (EGFR/HER-1/erbB1) is a TK receptor. It is one of four homologous transmembrane receptors (the others are HER-2/erbB-2, HER-3/erbB-3, and HER-4/erbB-4) that mediate the actions of different growth factors, such as epidermal growth factor, transforming growth factor-α, and neuregulins [32]. The binding of ligands to these receptors induces EGFR homo- and/heterodimer formation, kinase domain activation, and phosphorylation of specific tyrosine residue that serve as docking sites for molecules that lead to the activation of several cascades, including the MAPK and PI3K pathways [33].

EGFR oncogenic activation can occur due to several mechanisms: excess ligand or receptor expression, activating mutations, failure of inactivation, or transactivation through receptor dimerization [34]. To date, two major types of EGFR-targeting agents exists monoclonal antibodies and small-molecule ATP-competitive TK inhibitors (TKIs) [35, 36]. PKI166, a potent EGFR kinase inhibitor, also decreases RET autophosphorylation and signaling in cell extracts despite lacking an effect on RET kinase activity. PKI166 was tested in clinical trial in patients with MTC amongst others. However, due to liver toxicities the development of this drug was halted [37]. AEE788, another EGFR kinase inhibitor, inhibits RET-induced growth at concentrations below its half maximal inhibitory concentration (IC50) [38]. However, AEE788 does not have any active clinical trials

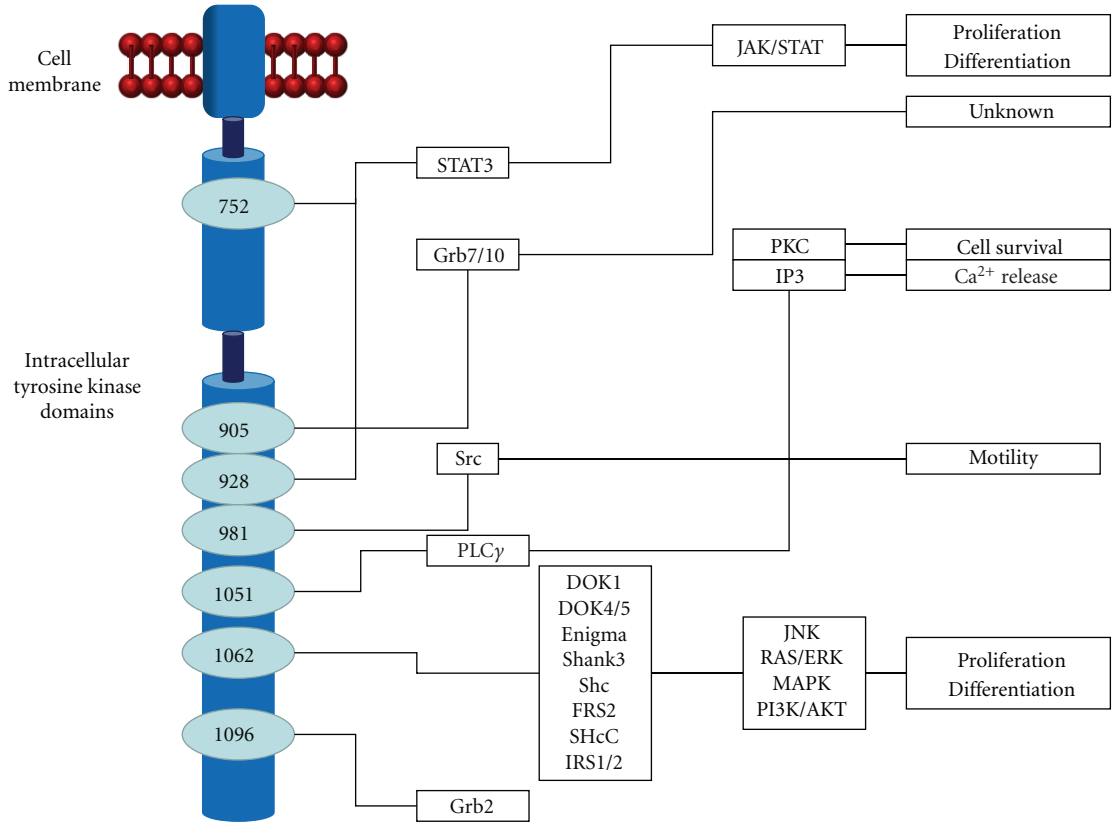

Figure 3: A summary of the signaling pathway mediated by RET.

in MTC patients. A study of 153 primary and metastatic MTC samples revealed that although *EGFR* mutations were rare, EGFR expression was higher in metastatic sites than in primary tumor sites [39]. MTC samples associated with *RET* 883 and 918 mutations had a significantly lower number of EGFR polysomes and a tendency toward less EGFR immunopositivity compared with samples associated with other *RET* mutations. Therefore, it is speculated that the most aggressive *RET* mutations are less dependent on EGFR activation, thereby explaining why EGFR inhibitors are less effective in codon 918-mutated cell lines than in codon 634-mutated cell lines.

4.2. Vascular Endothelial Growth Factor. The vascular endothelial growth factor (VEGF) family of growth factors stimulates angiogenesis, endothelial cell proliferation, migration, survival, and vascular permeability by various TK receptors: VEGFR-1, VEGFR-2, and VEGFR-3 [40]. There are several ligands for VEGFRs: VEGF-A (VEGF) binds to both VEGFR-1 and VEGFR-2; VEGF-B and placenta growth factor bind to only VEGFR-1; and VEGF-C and VEGF-D are specific ligands for VEGFR-3 [41].

Angiogenesis is one of the essential alterations in cell physiology that predispose to malignancy in many tumors, and it is fundamental in tumor growth and metastasis. Many molecules have been implicated as positive regulators of angiogenesis, including VEGF, hepatocyte growth factor, interleukin-8, and platelet-derived growth factor (PDGF). The major mediator of tumor angiogenesis is VEGF, which signals mainly through VEGFR-2. Activation of this receptor leads to a cascade of different pathways, including PLC γ-PKC-Raf-MEK-MAPK and PI3K-Akt [42]. Lymphangiogenesis is also involved in tumor biology, and since lymphatic vessels arise from blood vessels, some of the angiogenic mechanisms are also used in this process. VEGF-C and VEGF-D stimulate both angiogenesis and lymphangiogenesis and link both processes [43]. VEGFR-3 is expressed mainly in lymphatic endothelial cells and is thought to be primarily involved in lymphangiogenesis.

MTC has at least twofold expression when compared with normal thyroid tissue of VEGF and VEGF-R2 [44]. There is also an up to 20-fold increased expression of VEGF-C and VEGF-R3 in metastatic MTC [45]. Overexpression and activation of VEGFR-2 in MTC correlate with metastasis [39].

4.3. c-MET. The *c-met (MET)* proto-oncogene codes for the TK receptor of the hepatocyte growth factor [46]. *MET* is an important factor in tumorigenesis. Deregulated activation of MET confers unrestricted proliferative, antiapoptotic, cell motility/migration, invasive, metastatic, and angiogenenic properties to cancer cells [47]. Silencing the endogenous *MET* proto-oncogene, which is overexpressed in tumor cells, has been proven to impair the invasive growth in vitro, to decrease the generation of metastases in vivo, and to promote the regression of already established metastases [48].

Table 1: Some of the TKIs currently used for the treatment of MTC in clinical trials and off-label.

Drug	Oral daily dose	Major targets
Vandetanib	100–300 mg	VEGFR-1, VEGFR-2, VEGFR-3, RET, EGFR
Sorafenib	400–800 mg	RET, VEGFR-2, VEGFR-3, Flt-3, PDGFRβ, KIT, RAF-1
Sunitinib	37.5 mg every day 50 mg daily 4 weeks on 2 weeks off	VEGFR-2, PDGFRβ, KIT, RET
Cabozantinib (XL184)	125–175 mg/day	MET, VEGFR-2, RET, KIT, Flt-3, Tie-2
E7080	24 mg	VEGFR-2, VEGFR-3, VEGFR-1, KIT, FGFR1, PDGFR, EGFR

MET and hepatocyte growth factor coexpression has been seen in a subset of MTC tumors and is associated with multifocality in MTC [49].

5. Targeted Therapy

Different TKs and pathways are abnormally activated in MTC cells. Inhibiting only one receptor may induce other TKs compensatory activation [50]. Therefore, simultaneous inhibition of different activated TKs may be the best way to approach MTC (Table 1) [51]. To date, systemic targeted therapy for MTC has been administered in the context of clinical trials or has consisted of off-label use of drugs approved for other solid tumors. In this section, we review the most promising TK inhibitors against MTC.

5.1. Vandetanib. Vandetanib is a 4-anilinoquinazoline that is available as an oral daily agent. It inhibits VEGFR-2, VEGFR-3, RET, and to a lesser extent EGFR and VEGFR-1 [52]. The 4-anilinoquinazoline docks to the ATP binding pocket of RET kinase, inhibiting it [53].

At pharmacologically relevant doses, vandetanib inhibits tumor cell proliferation, survival, and angiogenesis without leading to direct cytotoxic effects on tumor or endothelial cells [52]. In 2002, vandetanib was shown to inhibit the kinase activity of NIH-RET/C634R (MEN2A) and NIH-RET/M918T (MEN2B) oncoproteins in vitro and to inhibit RET/MEN2B phosphorylation and RET/MEN2B-dependent MAPK activation in vivo in NIH-RET/MEN2B [54]. Two years later, a panel of point mutations targeting the RET kinase domain in MEN2 and sporadic MTC was screened for susceptibility to vandetanib. Most of the mutant oncoproteins (RET/E768D, RET/L790F, RET/Y791F, RET/S891A, and RET/A883F) were sensitive to vandetanib, while mutations substituting valine 804 either to leucine or to methionine (as occur in some cases of MEN2A) rendered the RET kinase significantly resistant. This is probably due to steric hindrance, because the Val804Gly mutation increased the sensitivity of RET to vandetanib [55]. Mice carrying a *RET* C634R mutation from a sporadic human MTC treated with vandetanib had inhibition of tumor growth [56].

Inhibition of other kinases seems to be very important, too. MTC metastases express more EGFR and VEGFR-2 than primary tumor sites. Both EGFR and VEGFR-2 have been shown to be phosphorylated in TT and MZ-CRC-1 cells and inhibited by vandetanib. Yet, in the presence of active RET, neither plays a prominent role in TT cell proliferation. However, when RET activity is inhibited, overstimulation of EGFR is able to partially replace RET through a partial rescue of the MAPK pathway. In such scenario, the inhibition of EGFR by vandetanib was shown to prevent this rescue of the MAPK pathway. These data support the idea that dual inhibition of RET and EGFR is important, as it may overcome the risk of MTC cells' escaping from RET blockade through compensatory overstimulation of EGFR [50].

In phase I clinical studies of patients with solid tumors (not including MTC) [57], doses of vandetanib up to 300 mg/day were well tolerated, and adverse effects were generally mild and controlled with either dose adjustments or symptomatic therapy. The most common adverse events were rash, diarrhea, fatigue, asymptomatic QTc prolongation, proteinuria, and hypertension. Since QT prolongation was note as an adverse event, patients should have EKG and electrolytes at baseline and at regular intervals during the course of treatment.

In a phase II study, 30 adult patients with unresectable, locally advanced, or metastatic hereditary MTC received 300 mg/day of vandetanib [58]. The primary endpoint was the objective response rate (ORR) according to the 2000 Response Evaluation Criteria in Solid Tumors (RECIST) guidelines [59]. Objective partial responses (PRs) were observed in 20% of patients, and the median duration of PR was 10.2 months. Additionally, 53% of patients had stable disease (SD) for a median of 24 weeks. In another trial of vandetanib at 100 mg/day (or up to 300 mg/day in cases with disease progression), patients with similar disease characteristics achieved similar results (ORR 68%) [60]. Both trials showed a $\geq$50% reduction in calcitonin and carcinoembryonic antigen levels from baseline. However, the reduction in calcitonin levels did not correlate with the degree of tumor growth inhibition. It seems that RET activity is required for ligand-induced calcitonin gene expression [61]. In that sense, carcinoembryonic antigen levels may be a better marker of tumor response to vandetanib. Of interest, there was no apparent association between specific *RET* germline mutations and response to treatment (no patients with 804 *RET* mutation were included). Other phase I and II studies are ongoing to determine the effectiveness of vandetanib in sporadic MTC and its safety and efficacy in children and adolescents. (http://www.ClinicalTrials.gov/).

Data on vandetanib have been presented to the United States Food and Drug Administration (FDA), including results from the largest randomized, double-blind, placebo-controlled trial, which was conducted in 331 patients with advanced unresectable or metastatic MTC, "Study D4200C00058". This trial showed that median progression-free survival (PFS) was 11 months longer in the group randomly assigned to vandetanib and 45% had an ORR. As the drug seems to be effective in stabilizing symptomatic and/or progressive disease, it will likely become the first FDA-approved drug for MTC.

Nuclear factor κB (NF-κB) activation can block cell-death pathways and contribute to the oncogenic state by driving proliferation, enhancing cell survival, and promoting angiogenesis and metastasis. NF-κB has a high baseline activity in MTC cell lines through RET-induced phosphorylation, ubiquitination, and proteosomal degradation of inhibitors of NF-kB (IkB), which allows NF-κB to enter the nucleus and bind to the DNA [62]. Bortezomib inhibits proteosome-mediated IkB degradation in MTC cells, resulting in its accumulation and thus preventing NF-κB translocation to the nucleus [63], thereby leading to apoptosis. A phase I/II trial of the combination of vandetanib plus bortezomib is currently recruiting patients (http://www.ClinicalTrials.gov/). Patients with MTC will participate in the phase II study.

5.2. Sorafenib. Sorafenib is a small TKI that targets RET, VEGFR-2, VEGFR-3, Flt3, PDGFR-β, KIT, and the RAF family serine/threonine kinases RAF-1 and BRAF. It inhibits the growth of RET-driven tumors by a combination of activities that target RET-dependent thyroid cancer cell proliferation and VEGF-dependent tumor angiogenesis. In vitro, sorafenib inhibits RET signaling and the growth of *RET*-transfected fibroblasts and human thyroid cancer cells that harbor *RET/PTC* and *RET/MEN2* oncogenes. Sorafenib action is mainly cytostatic, but the drug also exerts a proapoptotic effect. Sorafenib has been shown to significantly reduce tumor growth in nude mice with xenograft tumors derived from MTC cell lines [64]. Sorafenib has been investigated in four phase I trials with different doses and administration schedules. A dose of 400 mg orally twice daily was found to be safe and generally well tolerated, and the most frequently reported drug-related adverse events were fatigue, anorexia, diarrhea, rash/desquamation, and hand-foot syndrome. Hand-foot syndrome is characterized by painful erythematous lesions that affect the palmo-plantar surface. It is the most common reported adverse effect in patients taking the multikinase inhibitors like sorafenib and sunitinib. The lesions are pronounced on the pressure points on the palms and the soles but can also affect the margins of the feet and skin between fingers and toes. These lesions are not life threatening but significantly impair the quality of life requiring dose reduction or even discontinuation of the drug [65].Severe hematological, cardiovascular, hepatic, and renal toxic effects were not reported. Treatment-related hypertension was reported in 5% to 11% of patients in all four phase I trials. Sorafenib demonstrated evidence of antitumor activity by inducing disease stabilization in patients with refractory tumors, a finding that was consistent with the results of preclinical studies [66]. No patients with thyroid cancer were included in the phase I study. Because of the role of *RET* signaling in MTC and the antitumor activity exhibited by sorafenib in preclinical and in vitro studies, MTC was recognized as a potential target for sorafenib. In a small 2007 pilot study that included five patients with metastatic MTC with excessive calcitonin secretion, calcitonin secretion was decreased by >50% in all patients after 3 months of treatment, and all patients were free of calcitonin-related symptoms. After 6 months of therapy, one patient had a complete response (CR), and patient had a PR [67]. Sorafenib was administered orally at a dose of 400 mg twice daily continuously in a larger, open-label phase II study in patients with histologically confirmed metastatic or locally advanced MTC. Patients were monitored regularly with physical examination and biochemical and radiologic testing. In the event of any significant drug-related adverse event, the drug was withheld and restarted at a lower dose of 400 to 600 mg/day with dose re-escalation as tolerated. The median duration of therapy with sorafenib was 15 months. ORR was assessed using RECIST version 1.0. Of the 15 evaluable patients in this study, all showed some degree of tumor shrinkage. One patient achieved PR; 14 patients had SD, eight of whom had SD $\geq$15 months; and one patient had clinically progressive disease. Most patients had decreased calcitonin levels 2 months after treatment initiation, but they did not correlate with the degree or duration of response as assessed using RECIST [68]. Sorafenib has been approved by the FDA for treatment of renal cell and hepatocellular carcinoma. Therefore, sorafenib is an option for patients with advanced MTC who are not eligible for clinical trials [69].

5.3. Tipifarnib. Tipifarnib inhibits farnesylation of RAS and other proteins. Farnesylation is a type of lipid modification that is critical for the biological functionality including several signal transduction proteins. Farnesyltransferase inhibitors target multiple pathways, including the RAS pathway, and are among the first systematically investigated drugs in oncogene-targeted therapy. *RAS* genes encode proteins involved in cell proliferation, differentiation, and adhesion and apoptosis regulation. At least three associated genes (*H-RAS*, *K-RAS*, and *N-RAS*) are present in mammalian cells. Of all human tumors, 30% might have a mutated *RAS* isoform. Thyroid cancer has mutations in all three *RAS* genes. In in vitro studies, tipifarnib inhibited the growth of several human tumor cell lines, and in in vivo studies, tipifarnib was shown to inhibit colon and pancreatic cancer xenografts in a dose-dependent manner. The antitumor effects were mainly due to decreased cell proliferation, antiangiogenesis, and apoptosis. A phase I trial of tipifarnib in combination with sorafenib in patients with advanced malignancies included 15 patients with thyroid cancer, eight of whom had MTC. Three of the six patients who reached first restaging had PRs, whereas the others had some minor regressions and hence SD lasting from 12 to 16 months. The most common side effects reported were rash, hyperglycemia, and diarrhea. *RET* mutational analysis in these six patients revealed *RET* mutations; thus, it is unclear whether the response to

sorafenib and tipifarnib was entirely due to *RET* inhibition by sorafenib [70]. In a previously reported case, the rate of response rate to combination therapy was higher than that reported for sorafenib alone. It should be noted that the *RET* pathway is complex and the RET kinase can activate a cascade of signaling pathways. Tipifarnib can also affect various other pathways, including Akt and MAP/ERK, and may have acted synergistically to produce the clinical response [71]. The FDA has not approved tipifarnib because of its inferior outcomes in phase III trials in patients with other malignancies [72]. However, the data from trials of thyroid cancer so far seem encouraging, and studies combining various oncogene-targeted therapies are needed.

Preclinical studies have shown that activating *RET* mutations in V804 (V804L and V804M) causes resistance to various structural classes, including vandetanib. Mutations in V804 slightly affect RET susceptibility to sorafenib, thus indicating that a structurally different inhibitor may be used to overcome the mutational resistance to a particular TKI [73]. This might be clinically significant as a recent study showed RET V804M (19.6%) is a prevalent cause of hereditary MTC [74].

5.4. Sunitinib. Sunitinib is a derivative of indolinone and inhibits the activity of many TKs, including VEGFR, PDGFR, KIT, and RET. Sunitinib exerts antitumor activity by affecting cell proliferation and survival in cancers in which these receptors are involved [75]. Its inhibitory effect on VEGF and RET makes this drug a rational choice for treating MTC. In a phase II study of sunitinib in patients with progressive thyroid cancer that included six patients with MTC, disease stabilization was seen in five of the six patients (83%) [76]. Results from another phase II study that included only patients with progressive MTC also showed responses. Among the 23 patients evaluated, eight (35%) achieved PR, with a median response duration of 37 weeks, and 13 (57%) had SD, with a median response duration of 32 weeks [77]. A trial using a lower dose of 37.5 mg/day in a continuous manner included six patients with MTC. Three of the six patients had an objective response [78]. The most common drug-related adverse events were fatigue, diarrhea, palmar-plantar erythrodysesthesia, neutropenia, and hypertension. Sunitinib has been approved by the FDA as the treatment of renal cell carcinoma and is therefore available for use in selected patients with MTC not enrolled in a clinical trial [69].

5.5. Cabozantinib (XL184). Cabozantinib (XL184) is a small molecule that inhibits MET, VEGFR-2, RET, KIT, Flt-3, and Tie-2 [79]. In the context of MTC, preclinical data have demonstrated that XL184 can inhibit the proliferation of cells harboring activated *RET*. In 2009, results of a phase I trial that included 37 patients with MTC revealed that 44% of patients achieved at least 30% reduction in tumor size, and 29% of patients confirmed PR. There was no correlation between *RET* mutation status (either germline or somatic) and tumor response [80]. Side effects included fatigue, diarrhea, appetite loss, weight loss, hair hypopigmentation, and hypertension. Other effects, such as elevated aspartate aminotransferase, alanine aminotransferase, lipase elevations, palmar/plantar erythema, and mucositis, were dose dependent. Because of the noted antitumor effects of XL184, a phase III clinical trial called the "Efficacy of XL184 in Advanced Medullary Thyroid Cancer (EXAM)" is recruiting patients (http://www.ClinicalTrials.gov/). The purpose of the study is to evaluate PFS with XL184 compared to PFS with placebo in subjects with unresectable, locally advanced, or metastatic MTC.

Recently, in addition to giving XL184 a generic drug name, FDA had granted XL184 an orphan drug designation for treatment of follicular, medullary, and anaplastic thyroid carcinoma, and metastatic or locally advanced papillary thyroid cancer.

5.6. E7080. E7080 inhibits VEGFR-1, VEGFR-2, VEGFR-3, KIT, FGFR1, PDGFR, and to a lesser extent EGFR. This drug has been shown to be a potent inhibitor of in vitro angiogenesis in human small cell lung cancer via inhibition of VEGF/VEGF-2 and the stem cell factor/KIT signaling pathways. Via dual inhibition of VEGFR-2 and VEGFR-3, E7080 has also been shown to decrease lymphatic vessel density in the primary tumors of VEGFC-overexpressing MDA-MB-231 mammary fat pad xenograft models as well as within the metastatic nodules in the lymph nodes of nude mice [81].

In phase I trials, E7080 caused hypertension and proteinuria, which were the major dose-limiting toxic effects [82]. Other observed adverse events included thrombosis, tachycardia, febrile neutropenia, and thrombocytopenia.

A phase II trial to evaluate the safety and efficacy of oral E7080 in medullary and iodine-131-refractory, unresectable differentiated thyroid cancers is ongoing (http://www.clinicaltrials.gov/). The primary purpose of the trial is to determine the effect of E7080 on the objective tumor response rate according to RECIST.

5.7. Pazopanib. Pazopanib is an oral multikinase inhibitor. In vitro studies have shown that it is a potent inhibitor of VEGFR-1, VEGFR-2, VEGFR-3, PDGFR-α and $-\beta$, and KIT [83]. The antineoplastic activity of pazopanib is primarily due to its effect on the angiogenic pathways. Phase II studies of pazopanib for MTC are ongoing [84].

6. Conclusion

Research on MTC over the last 55 years has led to a good understanding of the genetic defects and altered molecular pathways associated with its development. Subsequently, promising targeted therapies have been developed for progressive and advanced MTC. Multikinase inhibitors have shown good results in terms of stabilizing disease, and this year will probably see the approval of a drug for advanced unresectable or metastatic MTC, which would represent a new chapter in the history of this disease. The challenge for the years to come is to discover more effective ways to target multiple key pathological pathways as well as the identification of the individuals who will benefit the most.

Conflict of Interests

The authors do not have any conflict of interest to disclose.

Acknowledgments

This research is supported in part by the National Institutes of Health through MD Anderson's Cancer Center Support Grant CA016672. K. Gómez and J. Varghese equally contributed to this work and should be rewarded as joint first authors.

References

[1] R. A. DeLellis, R. Lloyd, P. U. Heitz, and C. Eng, *WHO Classification of Tumours, Pathology and Genetics of Tumours of Endocrine Organs*, IARC Press, Lyon, France, 2004.

[2] L. Davies and H. G. Welch, "Increasing incidence of thyroid cancer in the United States, 1973–2002," *Journal of the American Medical Association*, vol. 295, no. 18, pp. 2164–2167, 2006.

[3] J. B. Hazard, W. A. Hawk, and G. Crile Jr., "Medullary (solid) carcinoma of the thyroid: a clinicopathologic entity," *Journal of Clinical Endocrinology & Metabolism*, vol. 19, no. 1, pp. 152–161, 1959.

[4] J. H. Sipple, "The association of pheochromocytoma with carcinoma of the thyroid gland," *The American Journal of Medicine*, vol. 31, no. 1, pp. 163–166, 1961.

[5] E. D. Williams, C. L. Brown, and I. Doniach, "Pathological and clinical findings in a series of 67 cases of medullary carcinoma of the thyroid," *Journal of Clinical Pathology*, vol. 19, no. 2, pp. 103–113, 1966.

[6] E. D. Williams, "Histogenesis of medullary carcinoma of the thyroid," *Journal of Clinical Pathology*, vol. 19, no. 2, pp. 114–118, 1966.

[7] K. Graze, I. J. Spiler, A. H. Tashjian Jr. et al., "Natural history of familial medullary thyroid carcinoma. Effect of a program for early diagnosis," *New England Journal of Medicine*, vol. 299, no. 18, pp. 980–985, 1978.

[8] H. Donis-Keller, S. Dou, D. Chi et al., "Mutations in the RET proto-oncogene are associated with MEN 2A and FMTC," *Human Molecular Genetics*, vol. 2, no. 7, pp. 851–856, 1993.

[9] L. M. Mulligan, J. B. J. Kwok, C. S. Healey et al., "Germ-line mutations of the RET proto-oncogene in multiple endocrine neoplasia type 2A," *Nature*, vol. 363, no. 6428, pp. 458–460, 1993.

[10] S. Dvorăká, E. Václavíková, V. Sýkorová et al., "New multiple somatic mutations in the RET proto-oncogene associated with a sporadic medullary thyroid carcinoma," *Thyroid*, vol. 16, no. 3, pp. 311–316, 2006.

[11] R. Elisei, B. Cosci, C. Romei et al., "Prognostic significance of somatic RET oncogene mutations in sporadic medullary thyroid cancer: a 10-year follow-up study," *Journal of Clinical Endocrinology and Metabolism*, vol. 93, no. 3, pp. 682–687, 2008.

[12] C. Romei, B. Cosci, G. Renzini et al., "RET genetic screening of sporadic medullary thyroid cancer (MTC) allows the preclinical diagnosis of unsuspected gene carriers and the identification of a relevant percentage of hidden familial MTC (FMTC)," *Clinical Endocrinology*, vol. 74, no. 2, pp. 241–247, 2011.

[13] E. Gardner, L. Papi, D. F. Easton et al., "Genetic linkage studies map the multiple endocrine neoplasia type 2 loci to a small interval on chromosome 10q11.2," *Human Molecular Genetics*, vol. 2, no. 3, pp. 241–246, 1993.

[14] B. Pasini, R. M. W. Hofstra, L. Yin et al., "The physical map of the human RET proto-oncogene," *Oncogene*, vol. 11, no. 9, pp. 1737–1743, 1995.

[15] M. Takahashi, Y. Buma, T. Iwamoto, Y. Inaguma, H. Ikeda, and H. Hiai, "Cloning and expression of the ret proto-oncogene encoding a tyrosine kinase with two potential transmembrane domains," *Oncogene*, vol. 3, no. 5, pp. 571–578, 1988.

[16] T. Iwamoto, M. Taniguchi, N. Asai, K. Ohkusu, I. Nakashima, and M. Takahashi, "cDNA cloning of mouse ret proto-oncogene and its sequence similarity to the cadherin superfamily," *Oncogene*, vol. 8, no. 4, pp. 1087–1091, 1993.

[17] J. Anders, S. Kjær, and C. F. Ibáñez, "Molecular modeling of the extracellular domain of the RET receptor tyrosine kinase reveals multiple cadherin-like domains and a calcium-binding site," *Journal of Biological Chemistry*, vol. 276, no. 38, pp. 35808–35817, 2001.

[18] M. S. Airaksinen and M. Saarma, "The GDNF family: signalling, biological functions and therapeutic value," *Nature Reviews Neuroscience*, vol. 3, no. 5, pp. 383–394, 2002.

[19] B. A. Tsui-Pierchala, J. Milbrandt, and E. M. Johnson Jr., "NGF utilizes c-Ret via a novel GFL-independent, inter-RTK signaling mechanism to maintain the trophic status of mature sympathetic neurons," *Neuron*, vol. 33, no. 2, pp. 261–273, 2002.

[20] J. W. B. De Groot, T. P. Links, J. T. M. Plukker, C. J. M. Lips, and R. M. W. Hofstra, "RET as a diagnostic and therapeutic target in sporadic and hereditary endocrine tumors," *Endocrine Reviews*, vol. 27, no. 5, pp. 535–560, 2006.

[21] M. Takahashi, "The GDNF/RET signaling pathway and human diseases," *Cytokine and Growth Factor Reviews*, vol. 12, no. 4, pp. 361–373, 2001.

[22] M. Ichihara, Y. Murakumo, and M. Takahashi, "RET and neuroendocrine tumors," *Cancer Letters*, vol. 204, no. 2, pp. 197–211, 2004.

[23] C. Eng, "Seminars in medicine of the Beth Israel Hospital, Boston: the RET proto- oncogene in multiple endocrine neoplasia type 2 and Hirschsprung's disease," *New England Journal of Medicine*, vol. 335, no. 13, pp. 943–951, 1996.

[24] K. M. Zbuk and C. Eng, "Cancer phenomics: RET and PTEN as illustrative models," *Nature Reviews Cancer*, vol. 7, no. 1, pp. 35–45, 2007.

[25] C. Jiménez, M. I.-N. Hu, and R. F. Gagel, "Management of medullary thyroid carcinoma," *Endocrinology and Metabolism Clinics of North America*, vol. 37, no. 2, pp. 481–496, 2008.

[26] J. F. Moley and M. K. DeBenedetti, "Patterns of nodal metastases in palpable medullary thyroid carcinoma: recommendations for extent of node dissection," *Annals of Surgery*, vol. 229, no. 6, pp. 880–888, 1999.

[27] D. J. Marsh, D. L. Learoyd, S. D. Andrew et al., "Somatic mutations in the RET proto-oncogene in sporadic medullary thyroid carcinoma," *Clinical Endocrinology*, vol. 44, no. 3, pp. 249–257, 1996.

[28] H. J. Wolfe, K. E. Melvin, S. J. Cervi-Skinner et al., "C-cell hyperplasia preceding medullary thyroid carcinoma," *New England Journal of Medicine*, vol. 289, no. 9, pp. 437–441, 1973.

[29] M. Drosten and B. M. Pützer, "Mechanisms of disease: cancer targeting and the impact of oncogenic RET for medullary thyroid carcinoma therapy," *Nature Clinical Practice Oncology*, vol. 3, no. 10, pp. 564–574, 2006.

[30] A. M. Hennige, R. Lammers, D. Arlt et al., "Ret oncogene signal transduction via a IRS-2/PI 3-kinase/PKB and a SHC/Grb-2 dependent pathway: possible implication for transforming activity in NIH3T3 cells," *Molecular and Cellular Endocrinology*, vol. 167, no. 1-2, pp. 69–76, 2000.

[31] H. Murakami, T. Iwashita, N. Asai et al., "Enhanced phosphatidylinositol 3-kinase activity and high phosphorylation state of its downstream signalling molecules mediated by Ret with the MEN 2B mutation," *Biochemical and Biophysical Research Communications*, vol. 262, no. 1, pp. 68–75, 1999.

[32] R. N. Jorissen, F. Walker, N. Pouliot, T. P.J. Garrett, C. W. Ward, and A. W. Burgess, "Epidermal growth factor receptor: mechanisms of activation and signalling," *Experimental Cell Research*, vol. 284, no. 1, pp. 31–53, 2003.

[33] T. Holbro, G. Civenni, and N. E. Hynes, "The ErbB receptors and their role in cancer progression," *Experimental Cell Research*, vol. 284, no. 1, pp. 99–110, 2003.

[34] G. Vlahovic and J. Crawford, "Activation of tyrosine kinases in cancer," *Oncologist*, vol. 8, no. 6, pp. 531–538, 2003.

[35] C. L. Arteaga, "ErbB-targeted therapeutic approaches in human cancer," *Experimental Cell Research*, vol. 284, no. 1, pp. 122–130, 2003.

[36] I. Vivanco and I. K. Mellinghoff, "Epidermal growth factor receptor inhibitors in oncology," *Current Opinion in Oncology*, vol. 22, no. 6, pp. 573–578, 2010.

[37] P. Traxler, "Tyrosine kinases as targets in cancer therapy—successes and failures," *Expert Opinion on Therapeutic Targets*, vol. 7, no. 2, pp. 215–234, 2003.

[38] M. Croyle, N. Akeno, J. A. Knauf et al., "RET/PTC-induced cell growth is mediated in part by epidermal growth factor receptor (EGFR) activation: evidence for molecular and functional interactions between RET and EGFR," *Cancer Research*, vol. 68, no. 11, pp. 4183–4191, 2008.

[39] C. Rodríguez-Antona, J. Pallares, C. Montero-Conde et al., "Overexpression and activation of EGFR and VEGFR2 in medullary thyroid carcinomas is related to metastasis," *Endocrine-Related Cancer*, vol. 17, no. 1, pp. 7–16, 2010.

[40] B. I. Terman, M. Dougher-Vermazen, M. E. Carrion et al., "Identification of the KDR tyrosine kinase as a receptor for vascular endothelial cell growth factor," *Biochemical and Biophysical Research Communications*, vol. 187, no. 3, pp. 1579–1586, 1992.

[41] M. Shibuya and L. Claesson-Welsh, "Signal transduction by VEGF receptors in regulation of angiogenesis and lymphangiogenesis," *Experimental Cell Research*, vol. 312, no. 5, pp. 549–560, 2006.

[42] R. S. Kerbel, "Tumor angiogenesis," *New England Journal of Medicine*, vol. 358, no. 19, pp. 2039–2049, 2008.

[43] K. Alitalo and P. Carmeliet, "Molecular mechanisms of lymphangiogenesis in health and disease," *Cancer Cell*, vol. 1, no. 3, pp. 219–227, 2002.

[44] C. Capp, S. M. Wajner, D. R. Siqueira, B. A. Brasil, L. Meurer, and A. L. Maia, "Increased expression of vascular endothelial growth factor and its receptors, VEGFR-1 and VEGFR-2, in medullary thyroid carcinoma," *Thyroid*, vol. 20, no. 8, pp. 863–871, 2010.

[45] G. Bunone, P. Vigneri, L. Mariani et al., "Expression of angiogenesis stimulators and inhibitors in human thyroid tumors and correlation with clinical pathological features," *American Journal of Pathology*, vol. 155, no. 6, pp. 1967–1976, 1999.

[46] D. P. Bottaro, J. S. Rubin, D. L. Faletto et al., "Identification of the hepatocyte growth factor receptor as the c-met proto-oncogene product," *Science*, vol. 251, no. 4995, pp. 802–804, 1991.

[47] M. Sattler and R. Salgia, "The MET axis as a therapeutic target," *Update on Cancer Therapeutics*, vol. 3, no. 3, pp. 109–118, 2009.

[48] S. Corso, C. Migliore, E. Ghiso, G. De Rosa, P. M. Comoglio, and S. Giordano, "Silencing the MET oncogene leads to regression of experimental tumors and metastases," *Oncogene*, vol. 27, no. 5, pp. 684–693, 2008.

[49] M. Papotti, M. Olivero, M. Volante et al., "Expression of hepatocyte growth factor (HGF) and its receptor (MET) in medullary carcinoma of the thyroid," *Endocrine Pathology*, vol. 11, no. 1, pp. 19–30, 2000.

[50] D. Vitagliano, V. De Falco, A. Tamburrino et al., "The tyrosine kinase inhibitor ZD6474 blocks proliferation of RET mutant medullary thyroid carcinoma cells," *Endocrine-Related Cancer*, vol. 18, no. 1, pp. 1–11, 2011.

[51] A. Ocana, E. Amir, B. Seruga, and A. Pandiella, "Do we have to change the way targeted drugs are developed?" *Journal of Clinical Oncology*, vol. 28, no. 24, pp. e420–e421, 2010.

[52] R. S. Herbst, J. V. Heymach, M. S. O'Reilly, A. Onn, and A. J. Ryan, "Vandetanib (ZD6474): an orally available receptor tyrosine kinase inhibitor that selectively targets pathways critical for tumor growth and angiogenesis," *Expert Opinion on Investigational Drugs*, vol. 16, no. 2, pp. 239–249, 2007.

[53] P. P. Knowles, J. Murray-Rust, S. Kjær et al., "Structure and chemical inhibition of the RET tyrosine kinase domain," *Journal of Biological Chemistry*, vol. 281, no. 44, pp. 33577–33587, 2006.

[54] F. Carlomagno, D. Vitagliano, T. Guida et al., "ZD6474, an orally available inhibitor of KDR tyrosine kinase activity, efficiently blocks oncogenic RET kinases," *Cancer Research*, vol. 62, no. 24, pp. 7284–7290, 2002.

[55] F. Carlomagno, T. Guida, S. Anaganti et al., "Disease associated mutations at valine 804 in the RET receptor tyrosine kinase confer resistance to selective kinase inhibitors," *Oncogene*, vol. 23, no. 36, pp. 6056–6063, 2004.

[56] V. Johanson, H. Ahlman, P. Bernhardt et al., "A transplantable human medullary thyroid carcinoma as a model for RET tyrosine kinase-driven tumorigenesis," *Endocrine-Related Cancer*, vol. 14, no. 2, pp. 433–444, 2007.

[57] S. N. Holden, S. G. Eckhardt, R. Basser et al., "Clinical evaluation of ZD6474, an orally active inhibitor of VEGF and EGF receptor signaling, in patients with solid, malignant tumors," *Annals of Oncology*, vol. 16, no. 8, pp. 1391–1397, 2005.

[58] S. A. Wells Jr., J. E. Gosnell, R. F. Gagel et al., "Vandetanib for the treatment of patients with locally advanced or metastatic hereditary medullary thyroid cancer," *Journal of Clinical Oncology*, vol. 28, no. 5, pp. 767–772, 2010.

[59] P. Therasse, S. G. Arbuck, E. A. Eisenhauer et al., "New guidelines to evaluate the response to treatment in solid tumors," *Journal of the National Cancer Institute*, vol. 92, no. 3, pp. 205–216, 2000.

[60] B. G. Robinson, L. Paz-Ares, A. Krebs, J. Vasselli, and R. Haddad, "Vandetanib (100 mg) in patients with locally advanced or metastatic hereditary medullary thyroid cancer," *Journal of Clinical Endocrinology and Metabolism*, vol. 95, no. 6, pp. 2664–2671, 2010.

[61] N. Akeno-Stuart, M. Croyle, J. A. Knauf et al., "The RET kinase inhibitor NVP-AST487 blocks growth and calcitonin gene expression through distinct mechanisms in medullary thyroid cancer cells," *Cancer Research*, vol. 67, no. 14, pp. 6956–6964, 2007.

[62] L. Ludwig, H. Kessler, M. Wagner et al., "Nuclear factor-κB is constitutively active in C-cell carcinoma and required for RET-induced transformation," *Cancer Research*, vol. 61, no. 11, pp. 4526–4535, 2001.

[63] C. S. Mitsiades, D. McMillin, V. Kotoula et al., "Antitumor effects of the proteasome inhibitor bortezomib in medullary and anaplastic thyroid carcinoma cells in vitro," *Journal of Clinical Endocrinology and Metabolism*, vol. 91, no. 10, pp. 4013–4021, 2006.

[64] F. Carlomagno, S. Anaganti, T. Guida et al., "BAY 43-9006 inhibition of oncogenic RET mutants," *Journal of the National Cancer Institute*, vol. 98, no. 5, pp. 326–334, 2006.

[65] A. Degen, M. Alter, F. Schenck et al., "The hand-foot-syndrome associated with medical tumor therapy—classification and management," *Journal of the German Society of Dermatology*, vol. 8, no. 9, pp. 652–662, 2010.

[66] D. Strumberg, J. W. Clark, A. Awada et al., "Safety, pharmacokinetics, and preliminary antitumor activity of sorafenib: a review of four phase I trials in patients with advanced refractory solid tumors," *Oncologist*, vol. 12, no. 4, pp. 426–437, 2007.

[67] F. Kober, M. Hermann, A. Handler, and G. Krotla, "Effect of sorafenib in symptomatic metastatic medullary thyroid cancer," *Journal of Clinical Oncology*, vol. 25, abstract 14065, 2007.

[68] E. T. Lam, M. D. Ringel, R. T. Kloos et al., "Phase II clinical trial of sorafenib in metastatic medullary thyroid cancer," *Journal of Clinical Oncology*, vol. 28, no. 14, pp. 2323–2330, 2010.

[69] S. I. Sherman, "NCCN Practice guidelines for thyroid cancer," Version 1.2011. 2011.

[70] D. S. Hong, S. M. Sebti, R. A. Newman et al., "Phase I trial of a combination of the multikinase inhibitor sorafenib and the farnesyltransferase inhibitor tipifarnib in advanced malignancies," *Clinical Cancer Research*, vol. 15, no. 22, pp. 7061–7068, 2009.

[71] D. Hong, L. Ye, R. Gagel et al., "Medullary thyroid cancer: targeting the RET kinase pathway with sorafenib/tipifarnib," *Molecular Cancer Therapeutics*, vol. 7, no. 5, pp. 1001–1006, 2008.

[72] A. M. Tsimberidou, C. Chandhasin, and R. Kurzrock, "Farnesyltransferase inhibitors: where are we now?" *Expert Opinion on Investigational Drugs*, vol. 19, no. 12, pp. 1569–1580, 2010.

[73] C. Lanzi, G. Cassinelli, V. Nicolini, and F. Zunino, "Targeting RET for thyroid cancer therapy," *Biochemical Pharmacology*, vol. 77, no. 3, pp. 297–309, 2009.

[74] C. Romei, S. Mariotti, L. Fugazzola et al., "Multiple endocrine neoplasia type 2 syndromes (MEN 2): results from the ItaMEN network analysis on the prevalence of different genotypes and phenotypes," *European Journal of Endocrinology*, vol. 163, no. 2, pp. 301–308, 2010.

[75] D. B. Mendel, A. D. Laird, X. Xin et al., "In vivo antitumor activity of SU11248, a novel tyrosine kinase inhibitor targeting vascular endothelial growth factor and platelet-derived growth factor receptors: determination of a pharmacokinetic/pharmacodynamic relationship," *Clinical Cancer Research*, vol. 9, no. 1, pp. 327–337, 2003.

[76] E. E. Cohen, B. M. Needles, K. J. Cullen et al., "Phase 2 study of sunitinib in refractory thyroid cancer," *Journal of Clinical Oncology*, vol. 26, abstract 6025, 2008.

[77] J. A. De Souza, N. Busaidy, A. Zimrin et al., "Phase II trial of sunitinib in medullary thyroid cancer (MTC)," *Journal of Clinical Oncology*, vol. 28, abstract 5504, 2010.

[78] L. L. Carr, D. A. Mankoff, B. H. Goulart et al., "Phase II study of daily sunitinib in FDG-PET-positive, iodine-refractory differentiated thyroid cancer and metastatic medullary carcinoma of the thyroid with functional imaging correlation," *Clinical Cancer Research*, vol. 16, no. 21, pp. 5260–5268, 2010.

[79] J. P. Eder, G. F. Vande Woude, S. A. Boerner, and P. M. Lorusso, "Novel therapeutic inhibitors of the c-Met signaling pathway in cancer," *Clinical Cancer Research*, vol. 15, no. 7, pp. 2207–2214, 2009.

[80] S. I. Sherman, "Targeted therapy of thyroid cancer," *Biochemical Pharmacology*, vol. 80, no. 5, pp. 592–601, 2010.

[81] J. Matsui, Y. Yamamoto, Y. Funahashi et al., "E7080, a novel inhibitor that targets multiple kinases, has potent antitumor activities against stem cell factor producing human small cell lung cancer H146, based on angiogenesis inhibition," *International Journal of Cancer*, vol. 122, no. 3, pp. 664–671, 2008.

[82] R. J. Keizer, A. Gupta, M. R. Mac Gillavry et al., "A model of hypertension and proteinuria in cancer patients treated with the anti-angiogenic drug E7080," *Journal of Pharmacokinetics and Pharmacodynamics*, vol. 37, no. 4, pp. 347–363, 2010.

[83] G. Sonpavde, T. E. Hutson, and C. N. Sternberg, "Pazopanib, a potent orally administered small-molecule multitargeted tyrosine kinase inhibitor for renal cell carcinoma," *Expert Opinion on Investigational Drugs*, vol. 17, no. 2, pp. 253–261, 2008.

[84] K. C. Bible, V. J. Suman, J. R. Molina et al., "Efficacy of pazopanib in progressive, radioiodine-refractory, metastatic differentiated thyroid cancers: results of a phase 2 consortium study," *The Lancet Oncology*, vol. 11, no. 10, pp. 962–972, 2010.

SAGE-Hindawi Access to Research
Journal of Thyroid Research
Volume 2011, Article ID 678357, 10 pages
doi:10.4061/2011/678357

Review Article

How to Treat a Signal? Current Basis for RET-Genotype-Oriented Choice of Kinase Inhibitors for the Treatment of Medullary Thyroid Cancer

Hugo Prazeres,[1,2,3] Joana Torres,[1] Fernando Rodrigues,[4] Joana P. Couto,[1,3] João Vinagre,[1,3,5] Manuel Sobrinho-Simões,[1,3,6] and Paula Soares[1,3]

[1] *Cancer Biology Group, Institute of Molecular Pathology and Immunology of the University of Porto (IPATIMUP), Rua Dr. Roberto Frias, s/n, 4200-465 Porto, Portugal*
[2] *Molecular Pathology Service, Portuguese Institute of Oncology of Coimbra FG, EPE, Avenida Bissaya Barreto, 98, 3000-075 Coimbra, Portugal*
[3] *Department of Pathology, Faculty of Medicine of Porto University, Al. Prof. Hernâni Monteiro, 4200-319 Porto, Portugal*
[4] *Endocrinology Service, Portuguese Institute of Oncology of Coimbra FG, EPE, Avenida Bissaya Barreto, 98, 3000-075 Coimbra, Portugal*
[5] *Abel Salazar Biomedical Sciences Institute (ICBAS), Lg. Prof. Abel Salazar, 4099-003 Porto, Portugal*
[6] *Department of Pathology, Hospital São João, Al. Prof. Hernâni Monteiro, 4200-319 Porto, Portugal*

Correspondence should be addressed to Paula Soares, psoares@ipatimup.pt

Received 11 February 2011; Accepted 10 April 2011

Academic Editor: Maria João M. Bugalho

The significance of *RET* in thyroid cancer comes from solid evidence that, when inherited, an *RET* activating mutation primes C-cells to transform into medullary carcinomas. Moreover, environmental exposure to radiation also induces rearranged transforming RET "isoforms" that are found in papillary thyroid cancer. The *RET* gene codes for a tyrosine kinase receptor that targets a diverse set of intracellular signaling pathways. The nature of *RET* point mutations predicts differences in the mechanisms by which the receptor becomes activated and correlates with different forms of clinical presentation, age of onset, and biological aggressiveness. A number of RET-targeting Tyrosine Kinase Inhibitors (TKIs) are currently undergoing clinical trials to evaluate their effectiveness in the treatment of thyroid cancer, and it is conceivable that the RET genotype may also influence response to these compounds. The question that now emerges is whether, in the future, the rational for treatment of refractory thyroid cancer will be based on the management of an abnormal RET signal. In this paper we address the RET-targeting TKIs and review studies about the signaling properties of distinct RET mutants as a means to predict response and design combinatorial therapies for the soon to be available TKIs.

1. The RET Tyrosine Kinase Receptor Targets a Diverse Spectrum of Intracellular Signaling Pathways

RET (Rearranged during Transfection) encodes a membrane receptor tyrosine kinase (RTK) composed of four extracellular cadherin-like motifs and a cysteine-rich region, a transmembrane portion, and an intracellular domain with tyrosine kinase activity [1]. The RET signaling pathways are outlined in (Figure 1). RET signals through a ligand/coreceptor/RET multiprotein complex instead of the usual receptor/ligand binding. To date, several ligands of the glial-derived neurotrophic factor (GDNF) family, which include GDNF, artemin, neurturin, and persephin and a family of GPI-linked RET coreceptors (GFR1-4), have been identified [2]. The formation of ligand/coreceptor and RET complexes results in RET dimerization and triggers autophosphorylation at intracellular tyrosine residues. Phosphorylated tyrosine 687 (Y687), serine 696 (S696), Y752, Y791, Y806, Y809, Y826, Y864, Y900, Y905, Y928, Y952, Y981, Y1015, Y1029, Y1062, Y1090, and Y1096 constitute docking sites for numerous intracellular adaptor proteins

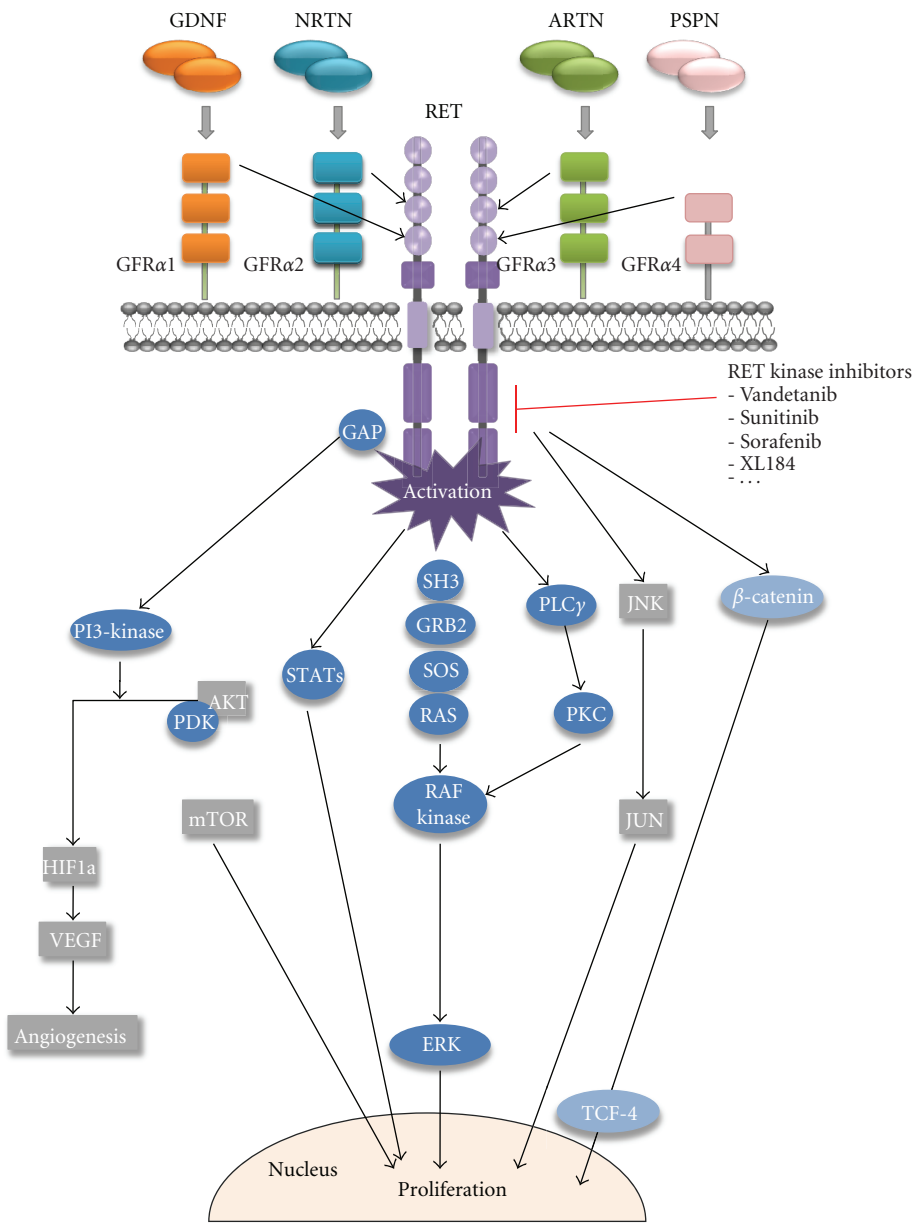

Figure 1: Outline of RET signalling pathways.

such as RAC1-guanine exchange factor (GEF) [3], growth factor receptor-bound (GRB) docking proteins GRB7/10 [4], chicken Rous sarcoma virus oncogene (c-Src), focal adhesion kinase (FAK) [5], phospholipase C-γ (PLC-γ) and Src homologue collagen (Shc), insulin receptor substrate 1/2 (IRS1/2), fibroblast growth factor substrate 2 (FRS2), or downstream of kinase 1/4/5 (DOK1/4/5) (reviewed by De Groot et al. [6]).

Phosphorylation of intracellular target proteins activates several downstream pathways which include mitogen-activated protein kinase cascade: rat sarcoma oncogene/rapidly accelerated fibrosarcoma/extracellular regulated kinase 1/2 (RAS/RAF/ERK1/2), the phosphatidylinositol 3-kinase/protein kinase B pathway (PI3K/AKT) [7, 8], the c-Jun N-terminal kinase pathway (JNK) [9], p38, enigma extracellular regulated kinase 5 (ERK5), the cAMP-responsive element-binding protein, and the signal transducer and activator of transcription 3 (STAT3) (for a review see Arighi et al. [10] and De Groot et al. [6]. More recently, Gujral et al. [11] have shown that RET mediates direct tyrosine phosphorylation of beta-catenin, which associated with an induction of the WNT pathway, that accounts for a part of RET tumorigenic ability *in vivo* [11].

Many of the above-mentioned intracellular signalling pathways are otherwise known to be general signal transducing pathways targeted not only by RET, but by other RTKs as well. Yet, RET is the main RTK targeted for genetic lesions in thyroid cancer. The transforming ability of activated RET,

which was actually on the basis of its isolation as an oncogene [12], could be attributable to the diversity of its signalling which covers several hallmarks of cancer [13].

Increased growth signals and proliferation result from the activation of the RAS/RAF/ERK1/2 cascade and phosphorylation of STAT3 [14, 15].

Cell migration is dependent on RET-mediated activation of RAC1 and JNK [3, 16], and FAK [5] is also reported to play a role in cell migration and to be required for invasion and metastatic behaviour [5, 17].

Inflammation (regarded as the 7th hallmark of cancer [18]) has also been shown to operate as a major component downstream of oncogenic RET mutations. In freshly isolated human thyrocytes, the activation of RET generates a transcriptional program that is similar to that which occurs during inflammation [19] inducing the expression of various inflammatory factors [19–21]. Furthermore, key protein components of the RET-activated "inflammatory" program were found in tumor specimens taken by biopsy, and larger amounts of these inflammatory molecules were found in the primary tumors of patients with lymph-node metastasis than in primary tumors in the absence of lymph-node metastasis (reviewed in [22]). These and other results ([23, 24]; [25]) connect the activation of RET to inflammation.

2. Hereditary MTC-Associated Activating Mutations Cluster at Specific Functional Domains of the RET Receptor Kinase

Overall, as stated before, varied signalling properties, covering multiple hallmarks of cancer, might afford explanation for the ability of RET to transform certain cell types. Nonetheless, the most solid grounds for the significance of RET as a cancer gene come from the fact that, when inherited, an RET germline point mutation alone primes a specific spectrum of tissues to develop endocrine tumors [26, 27]. Carriers of RET germline mutations develop hereditary medullary thyroid carcinoma (hMTC) as the first and most common clinical presentation. Along with hMTC, patients present with pheochromocytoma (tumor of the adrenal medulla) and parathyroid adenomas. This syndromic condition is referred to as Multiple Endocrine Neoplasia type 2 (MEN2) [28]. Penetrance for hMTC is near complete, which highlights the critical role of RET activation in the development of MTC and can be further taken to pinpoint RET as a relevant therapeutic target for MTC.

In hMTC, *RET* mutations occur in a specific spectrum of codons and result in gain of function, increased kinase activity, and receptor activation [29]. Mutational hotspots are located at the cysteine-rich region of the extracellular domain and in the intracellular tyrosine kinase domain [28]. The clustering of mutations in hotspots might be explained by the fact that proto-oncogene activation requires changes at residues that specifically interact in specific ways with receptor function, and thus mutations cannot occur in a widespread manner. A comprehensive description of all known germline *RET* variations can be found at the MEN2 RET database (http://www.arup.utah.edu/database/MEN2/MEN2_Welcome). The most common *RET* germline mutations are missense substitutions of extracellular cysteine residues, occurring at cysteine codon 634 in 80% of cases. Cysteine codons 609, 611, 618, 620, and 630 are less frequently affected. Other noncysteine extracellular domain mutations, located at exons 5 and 8, have been detected [30]. Tyrosine kinase domain mutations affect a more varied spectrum of amino acids, and most frequently recurring mutations replace Met918, Val804, Leu790, Tyr791, and Ala883. Less frequently, residues 768, 876, 891, 886, and 912 are affected. Rare mutations found in isolated families have been reported, comprising homozygous mutations [31], duplications [32], and double mutations [33].

Besides the point mutations found in MTC, an alternative somatic genetic event that causes RET activation is found in the papillary type of thyroid carcinoma (PTC). This involves chromosomal translocations between RET and a number of other loci, referred in general as RET/PTC rearrangements, which interestingly occur as alternative events to the V600E somatic BRAF mutation [34].

3. Distinct RET Mutations Determine Different Clinical Presentations of MEN2 and Predict Age of Onset of hMTC

In MEN2 there are consistent genotype/phenotype correlations that underlie aspects such as clinical manifestation, RET activation mechanisms, and disease penetrance, allowing for a mutation-specific classification of MEN2 [28]. In clinical terms, three disease phenotypes can be recognized: MEN2A, MEN2B, and a familial form of medullary thyroid carcinoma (FMTC). MEN2A was found to be associated with substitutions at one of six specific cysteine residues in exons 10 (609, 611, 618, 620) and 11 (630 and 634). MEN2A cysteine mutations give rise to MTC at young age (onset at 5 to 25 years), along with variable expression of pheochromocytoma (50%) and hyperparathyroidism (15–30%) [28]. MEN2B, on the other hand, is mainly caused by a specific missense mutation located at the RET tyrosine kinase domain (Met918Thr), which accounts for 95% of cases [35]. A second tyrosine kinase domain substitution (Ala883Phe) has been detected in a small proportion of MEN2B patients [36]. Additionally, double mutations affecting codons 804 and 805 and 804 and 806 were described in individual MEN2B cases [33, 37]. MEN2B kinase domain mutations give rise to a more complex clinical phenotype characterized by an early onset (sometimes <1 year old) and very aggressive form of MTC, concomitant with pheochromocytoma in 50% of cases and accompanied by other nonneoplastic features, such as mucosal neuromas of the tongue, lips, and eyelids, ganglioneuromatosis of the gastrointestinal tract, thickening of corneal nerves, and Marfanoid habitus [38]. In FMTC the only disease manifestation is MTC, which usually occurs in adult age, with no additional endocrinopathies. *RET* mutations with low clinical expression, involving codons 321, 533, 768, 790, 791, 804, and 891, may be found in these

families [28]. Occasionally, patients with these mutations may also develop the MEN2A phenotype, showing that FMTC and MEN2A represent a continuum of clinical expression in a common genetically related disorder [39–42]. Age-dependent penetrance for MTC in MEN2 is also codon specific, and classification of the risk of developing MTC can be done based on the genotype (reviewed by Raue and Frank-Raue in [43]). This is of clinical relevance because the ideal timing of prophylactic thyroidectomy should take into consideration the balance between the adverse effects of thyroidectomy at early ages and the individual risk of developing MTC. Comprehensive guidelines have been issued by the American Thyroid Association concerning this aspect [44]. In general, RET mutations with a very high risk of producing MTC (risk level D), comprising all the MEN2B mutations, require surgery before 1 year of age. RET mutations at codon Cys634 constitute risk level C and are managed by thyroidectomy before 5 years old. Level B mutations encompass the changes in the remaining extracellular cysteine codons 609, 611, 618, 620, and 630. In these cases, surgery is advised before 5 years old; however it can be postponed until calcitonin level rise. Risk level A accounts for the FMTC mutations, for which surgery before 5 years old is not required and can be delayed until calcitonin levels rise.

4. The Nature of Somatic RET Mutations Influences the Prognosis of Sporadic MTC

Aside from germline mutations, a somewhat similar spectrum of somatic mutations is observed in about 50 to 60% of the cases with sporadic MTC. A catalogue of somatic mutations can be found at the COSMIC database (http://www.sanger.ac.uk/genetics/CGP/cosmic/). The most frequent somatic lesion is the prototypic MEN2B Met918Thr mutation at exon 16, which comprises up to 60% of the mutation positive cases. Moreover, patients in which tumors harbor MEN2B mutations have a higher prevalence and number of lymph node metastases, present more often with multifocal tumors and with persistent disease at advanced stage, indicating that among the sporadic MTCs, cases with somatic MEN2B mutations are associated with the worst prognosis [45, 46]. Interestingly, cases with RET mutations at the cysteine cluster have the most indolent course, and those with no RET mutations have an intermediate risk [46].

5. Mutations Activate RET by Distinct Mechanisms and Confer Somewhat Different Oncogenic Signaling Properties

The functional basis for the differences in clinical expression of distinct RET genotypes might be explained by the recognition of mutation-specific mechanisms of activating the *RET* proto-oncogene. Mutations in the extracellular cysteine-rich region result in the replacement of a cysteine residue by another amino acid, subsequently leading to loss of an intramolecular disulfide bond. As a consequence, one cysteine residue becomes available for the formation of an intermolecular disulfide bond, which results in covalently bound receptors that are constitutively active because of ligand-independent receptor dimerization [29]. These mutations commonly associate with MEN2A and FMTC. In contrast, the intracellular MEN2B-specific mutations and other tyrosine kinase domain mutations affect receptor activation in a totally different way. By altering the conformation of the catalytic core of the tyrosine kinase domain they increase catalytic activity and alter the spectrum of intracellular substrates, resulting in remarkable changes of the signalling properties of the receptor [29].

These observations highlight that distinct clinical presentations can arise from differences in the RET activation mechanism and the corresponding output in terms of oncogenic signalling. However, not much is known about the specific differences in signalling properties of the different RET mutants. Studies have shown that wild-type and mutated RET display differences in the autophosphorylation levels of docking sites, which are likely to lead to differential activation of downstream cascades [47]. Support for this paradigm comes from evidence that there are marked differences between MEN2A and MEN2B mutations in terms of their capacity for downstream PI3K/AKT activation. This pathway seems to be more active in MEN2B than in MEN2A [7], and this difference might be attributed to an enhanced autophosphorylation of Y1062 caused by the MEN2B mutation [48].

Another example concerns RET-induced activation of STAT3. The MEN2A mutation Cys634Arg activates STAT3 independently of Janus tyrosine kinases (JAKs) [15]. However, the FMTC mutants, Tyr791Phe and Ser891Ala, seem to do so through a different route and need the involvement of Src and JAKs in order to constitutively activate STAT3 [49].

Thus, on the basis of the above-mentioned evidence that distinct signalling properties are displayed by RET mutants, it is conceivable that different sensitivity to the action of tyrosine kinase inhibitors can occur due to the potentially different conformations of the receptor in each of the RET mutants.

6. RET-Targeting Tyrosine Kinase Inhibitors

The small molecule tyrosine kinase inhibitors (TKIs) mechanism of action is based on the principle that sterically blocking the ATP-binding pocket results in impaired phosphorylation activity, inhibits signal transduction, and prevents activation of intracellular signalling pathways relevant to tumor growth and angiogenesis.

The finding of various compounds (Table 1) capable of inhibiting oncogenic RET (mutated or rearranged), such as PP1 and PP2 [50], ZD6474 (Vandetanib) [51], RPI-1 [52], CEP-701, CEP-751 [66], Imatinib [67], Sunitinib (SU5416, SU11248) [53], Gefitinib [55], Sorafenib (BAY 43-9006) [57], Motesanib (AMG706) [59], Axitinib (AG013736) [61] and XL 184, has brought further clinical relevance to the classification of the pharmacological sensitivity of RET mutants, as metastatic MTC is the most common cause of death in patients with MEN2 [68]. In addition, these

Table 1: Molecules used in preclinical and clinical trials as RET tyrosine kinase inhibitors.

Compound	Trade name	Structure	Targets	Clinical trials	Refs
PP1 PP2	Zaleplon	Pyrazolopyrimidine	RET	—	[50]
ZD6474	Vandetanib	Anilinoquinazoline	RET; VEGFR; EGFR	Phase II	[51]
RPI-1	—	Indolinone	RET; MET	—	[52]
SU5416 SU11248	Sunitinib	Butanedioic acid	VEGFR-2; PDGFR; c-KIT; RET; CSF-1R	Phase II	[53, 54]
ZD1839	Gefitinib	Anilinoquinazoline	EGFR	Phase II	[55, 56]
BAY43-9006	Sorafenib	Bis-aryl urea	RAF-1; BRAF; VEGFR-2/-3; PDGFR-B; Flt-3; c-KIT; RET	Phase II	[57, 58]
AMG706	Motesanib diphosphate	Diphosphate salt	VEGFR; PDGFR; KIT; RET	Phase II	[59, 60]
AG-013736	Axitinib	Benzamide	RET; VEGFR; PDGFR; c-KIT	Phase II	[61]
XL184/XL880			VEGFR2; RET and MET	Phase III	[***]

[***] Eder et al. [62]. LoRusso et al. [63]. Ross et al. [64]. Salgia et al. [65].

compounds could find application in radioactive iodine-refractory PTC with RET/PTC rearrangements.

The pyrazolopyrimidines PP1 and PP2 and the 4-anilinoquinazoline Vandetanib inhibit RET-rearrangement-derived oncoproteins with a half maximal inhibitor concentration (IC50) below 100 nM. These molecules were shown to inhibit RET enzymatic activity and phosphorylation of downstream targets, such as ERK1/2. Vandetanib has also been found to inhibit RET signalling in two human PTC cell lines and to reduce tumorigenicity of *RET/PTC*-transformed fibroblasts injected into nude mice [50]. Vandetanib blocks *in vivo* phosphorylation and signalling mediated by RET/PTC3 oncoprotein and of an epidermal growth factor- (EGF-) activated EGF-receptor/RET chimeric receptor. Finally, it blocks anchorage-independent growth of *RET/PTC3*-transformed NIH3T3 fibroblasts and the formation of tumors after injection of NIH-*RET/PTC3* cells into nude mice [51].

Sorafenib (BAY 43-9006) was designed originally as a RAF inhibitor [69]. Nonetheless, preclinical studies have shown that Sorafenib can inhibit the kinase activity and signalling of wild-type and oncogenic RET. Sorafenib inhibited oncogenic RET kinase activity at an IC50 of 50 nM or less in NIH3T3 cells. It arrested the growth of NIH3T3 and RAT1 fibroblasts transformed by oncogenic RET and of thyroid carcinoma cells that harbour rearranged RET alleles. These inhibitory effects paralleled a decrease in RET phosphorylation [57]. Finally, PTC cells carrying the *RET/PTC1* rearrangement were found to be more sensitive to Sorafenib than PTC cells carrying a *BRAF* mutation [70]. There is an ongoing phase II clinical trial using Sorafenib in patients with advanced thyroid cancer [58].

RPI-1 is a 2-indolinone derivative initially shown to inhibit RET/PTC1 activity in an immunokinase assay with an IC50 of 27–42 μM. It selectively inhibited the anchorage-independent growth of NIH3T3-transformed cells expressing the *RET/PTC1* gene, and the transformed phenotype of NIH3T3ptc1 cells was reverted to a normal fibroblast-like morphology. In these cells, the constitutive tyrosine phosphorylation of RET/PTC1, of the transducing adaptor protein Shc, and of a series of co-immunoprecipitated peptides was substantially reduced [52]. Activation of JNK2 and AKT was abolished, thus supporting the drug inhibitory efficacy on downstream pathways. In addition, cell growth inhibition was associated with a reduction in telomerase activity by nearly 85% [71].

Sunitinib was initially described as a TKI targeting VEGF and PDGFR receptors [72] and also found to inhibit c-KIT [73]. It is now approved for the treatment of GIST and renal cell carcinoma. *In vitro* kinase assays showed that Sunitinib inhibited the phosphorylation by RET/PTC3 of a synthetic tyrosine kinase substrate peptide in a dose-dependent manner. RET/PTC-mediated Y705 phosphorylation of STAT3 was inhibited by addition of Sunitinib, and the inhibitory effects of Sunitinib on tyrosine phosphorylation and transcriptional activation of STAT3 very closely correlated with decreased autophosphorylation of RET/PTC. Sunitinib caused a complete morphological reversion of transformed NIH-*RET/PTC3* cells and inhibited the growth of TPC-1 cells that have an endogenous *RET/PTC1* [53]. Treatment of two patients with progressive metastatic thyroid carcinoma (1 PTC and 1 FTC) demonstrated sustained clinical responses to Sunitinib over a period of four years [54].

Gefitinib was initially approved for nonsmall cell lung cancer since it targets oncogenic EGFR. *In vitro* data suggests that EGFR contributes to RET kinase activation, signalling, and growth stimulation. Conditional activation of RET/PTC oncoproteins in thyroid PCCL3 cells markedly induced expression and phosphorylation of EGFR, which was mediated in part through mitogen-activated protein (MAP) kinase signalling. RET and EGFR were found to co-immunoprecipitate. Ligand-induced activation of EGFR resulted in phosphorylation of a kinase-dead RET, and this effect was entirely blocked by EGFR kinase inhibitor. Gefitinib also inhibited cell growth induced by various constitutively active mutants of *RET* in thyroid cancer cells as well as in NIH3T3 cells [55]. These pieces of evidence have

provided a biological basis for clinical evaluation of Gefitinib in thyroid cancer. The results obtained in a phase II trial showed no objective responses among the 25 thyroid cancer patients treated with Gefitinib [56].

CEP-701 and CEP-751 are indolocarbazole derivatives that also inhibit RET in MTC cells. Effective inhibition of RET phosphorylation in a dose-dependent manner is achieved at concentrations <100 nM. These compounds also block the growth of MTC cells in culture. CEP-751 and its prodrug, CEP-2563 inhibit tumor growth in MTC cell xenografts [66]. These drugs also potentiate the effects of irinotecan treatment in TT cell culture and xenografts and result in durable complete remission in 100% of the mice. CEP-751 inhibited the induction of the DNA repair program (marked by phospho-H2AX) as well as the checkpoint pathway (marked by the activated Chk1) [74]. Since preclinical models have demonstrated that both CEP-751 and CEP-2563 have antitumor activity in a variety of tumors, phase I trials were undertaken [75].

Several other TKI molecules are being evaluated with regard to their efficacy in metastatic MTC treatment with limited published data. *Axitinib* (AG-013736) [76] was assessed in a phase II study with 60 MTC patients. Eighteen cases (30%) presented partial responses, and 23 (38%) had stable disease [61]. *Motesanib* (AMG706) [77] was evaluated in differentiated thyroid cancer [59] and in a phase I study in 91 patients with either hereditary (16 cases) or sporadic MTC (75 cases), 2% of the patients showed partial response, and 81% had stable disease [60]. *XL184/XL880* is a compound that is rapidly going through the clinical evaluation process. It is a TKI that targets VEGFR2, RET, and also MET and whose efficacy has been demonstrated for several solid tumors, especially thyroid cancer [***]. In patients with hereditary and sporadic MTC very interesting response rates were obtained with 9/17 patients (53%) showing partial remission. Based on these findings, a phase III registration trial of XL184 as a potential treatment for medullary thyroid cancer (MTC) has been initiated.

7. The Influence of Genotype on the Sensitivity to RET-Targeting TkIs and Challenges Ahead

Although a number of patients with refractory MTC have been undergoing treatment with several TKIs in the last few years, it is not yet clear whether clinical response to these drugs is actually influenced by the *RET* genotype of the tumor cells. At this point, the only reliable source for this type of information comes from *in vitro* studies. Indeed, some compounds used against RET seem to confirm the paradigm that certain mutations can render RET resistant to inhibition. This was first illustrated by PP1, PP2, and ZD6474 (Vandetanib) which, despite being efficient in inhibiting phosphorylation of most of the MEN2-associated *RET* mutants (at codons 768, 790, 883, 918, and 634 [50]), were incapable of inhibiting MEN2-associated swap of Valine 804 for bulky hydrophobic Leucine or Methionine within the RET kinase domain. Thus Valine 804 emerged as a structural determinant amino acid mediating resistance to pyrazolopyrimidines and 4-anilinoquinazolines [78, 79]. This was also found to be the case for the V804M/E805K tandem lesion, detected in non-Met918/Ala883 MEN2B, which was shown to also confer resistance to PP1, suggesting a mode of action different from the classical MEN2B mutations [33].

However, inhibition of RET phosphorylation and signaling by mutation of the Val804 gatekeeper residue was not impaired in cells subjected to Sorafenib treatment [80], indicating that this drug could be a potential therapeutic tool for *RET* Val804 positive thyroid tumors [80].

The fact that using another compound can overcome a mutation-specific primary resistance renders further support to the idea that sensitivity of *RET* mutants will, in the end, result from mutation-dependent structural determinants of the RET ATP-binding site. However, to support the paradigm of an *RET* pharmacogenetics, much more needs to be evaluated before we can confirm that this concept is useful for the clinical practice. To start, it would be imperative that the mutation status of the tumors from patients included in clinical trials is ascertained and correlated with clinical response. Until now, none of the clinical studies have published the mutation status of the patients. On the other hand, we must not forget that despite the *in vitro* data has proven highly informative for genotype/phenotype correlations, it cannot be taken directly to indicate differences in terms of clinical response. In addition, many of these small molecule inhibitors act upon several target RTKs, rendering it difficult to ascertain which of the effects over different RTKs actually accounts for the observed clinical response.

We should also be aware that some of the effects of these compounds may go beyond interference with the ATP-binding pocket and may affect RET expression. For instance, Sorafenib suppresses RET tyrosine kinase activity by direct enzymatic inhibition and also by promoting RET lysosomal degradation independent of proteasomal targeting [80].

At this point, given that a number of molecules are starting to become available, it would be worth to compare these drugs against each other in their efficacy to inhibit the activity of the most frequent *RET* genotypes. This may come as a means to define and stratify drugs for use as first-line and second-line treatments on the basis of the *RET* genotype.

As we highlighted before, specific *RET* mutations may lead stronger induction of specific intracellular signalling targets, many of which have their own dedicated inhibitors under development. In this respect, the information about the specificities in oncogenic signalling of different genotypes might be valuable to design combinatorial therapies employing mutation-specific combinations of inhibitors for treatment.

At present, the clinical use of tyrosine kinase inhibitors in patients with thyroid cancer still does not rely in the genetic background of each tumor [58, 61, 81]. Nonetheless, results from clinical trials suggest that these compounds have a more cytostatic than cytolytic effect, and thus are just adding another step of selective pressure to the progressing tumor (which buys time), but eventually secondary resistance can develop. In models such as *ABL/CML* (imatinib), *EGFR*/lung cancer (Gefitinib), or *KIT*/GIST (imatinib), prolonged

therapy with TKIs leads to the acquisition of resistance mutations in the receptors targeted by these drugs, rendering them insensitive to therapy. Although no secondary *RET* mutations have been described thus far, the experience with patients undergoing clinical trials taught that some patients suddenly fail to respond while on treatment. Most probably, the same underlying resistance mechanisms are at play. This implies that, in order to translate the use of these inhibitors into increased long-term survival, we may need to perform molecular followup of the progressing lesions, in order to predict resistance and eventually change from one inhibitor to another.

Finally, to reduce the biology of MTC to *RET* activation and signaling boosting is almost certainly a simplistic view. RET mutations do not only determine MTC development (even in hMTC). Likely these tumours also carry mutations in other genes, and possibly one should also know these to think about combinatory therapies. Indeed, data is accumulating regarding alternative pathways that contribute to MTC development from precursor C-cell hyperplasia. This is the case of the WNT pathway activation by RET-mediated tyrosine phosphorylation of β-Catenin [11] and the synergistic effects of p18 and p27, two members of the RB pathway [82, 83]. This may provide additional targets for combination of RET inhibitors with other compounds targeting these pathways. Also relevant to this is the recent recognition of mechanisms of cross-talk between different RTKs. For instance, EGFR may cooperate with RET in activating intracellular signaling pathways [55]. This provides biological basis for combining different RTK inhibitors.

The challenge for the years to come is to use the pools of knowledge generated in RET signaling pathways and MTC progression steps to rationalize combinatory therapies, targeting different molecules and different signaling pathways that are relevant in MTC.

Conflict of Interests

The authors declare that they have no proprietary, financial, professional, or other personal interest of any nature and kind in any product, service, and/or company that could be construed as influencing the position presented in this paper.

Authors' Contribution

H. Prazeres wrote the paper, J. Torres reviewed bibliography on RET signalling pathways, F. Rodrigues provided insight into clinical aspects of MTC management, J. P. Couto reviewed bibliography concerning the tyrosine kinase inhibitors, J. Vinagre composed the figures of the paper, and M. Sobrinho-Simões and P. Soares performed critical reviews of the paper.

Acknowledgments

This study was supported by the Portuguese Foundation for Science and Technology (FCT) through a Project Grant (PTDC/SAU-OBD/101242/2008), the Portuguese Society of Endocrinology and Metabolism (Edward Limber Prize), and the Portuguese Ministry of Health (project 13/2007). The authors would like also to acknowledge FCT for grants to H. Prazeres (Refs. SFRH/BD30041/2006 and SFRH/BPD/72004/2010), Ph.D. grant to J. P. Couto (SFRH/BD/40260/2007), and a BI to J. Torres. IPATIMUP is an associated Laboratory of the Portuguese Ministry of Science, Technology and Higher Education and is partially supported by the Portuguese Foundation for Science and Technology.

References

[1] M. Takahashi and G. M. Cooper, "ret Transforming gene encodes a fusion protein homologous to tyrosine kinases," *Molecular and Cellular Biology*, vol. 7, no. 4, pp. 1378–1385, 1987.

[2] M. S. Airaksinen, A. Titievsky, and M. Saarma, "GDNF family neurotrophic factor signaling: four masters, one servant," *Molecular and Cellular Neurosciences*, vol. 13, no. 5, pp. 313–325, 1999.

[3] T. Fukuda, K. Kiuchi, and M. Takahashi, "Novel mechanism of regulation of Rac activity and lamellipodia formation by RET tyrosine kinase," *Journal of Biological Chemistry*, vol. 277, no. 21, pp. 19114–19121, 2002.

[4] A. Pandey, X. Liu, J. E. Dixon, P. P. Di Fiore, and V. M. Dixit, "Direct association between the Ret receptor tyrosine kinase and the Src homology 2-containing adapter protein Grb7," *Journal of Biological Chemistry*, vol. 271, no. 18, pp. 10607–10610, 1996.

[5] G. R. Panta, F. Nwariaku, and L. T. Kim, "RET signals through focal adhesion kinase in medullary thyroid cancer cells," *Surgery*, vol. 136, no. 6, pp. 1212–1217, 2004.

[6] J. W. B. De Groot, T. P. Links, J. T. M. Plukker, C. J. M. Lips, and R. M. W. Hofstra, "RET as a diagnostic and therapeutic target in sporadic and hereditary endocrine tumors," *Endocrine Reviews*, vol. 27, no. 5, pp. 535–560, 2006.

[7] H. Murakami, T. Iwashita, N. Asai et al., "Enhanced phosphatidylinositol 3-kinase activity and high phosphorylation state of its downstream signalling molecules mediated by Ret with the MEN 2B mutation," *Biochemical and Biophysical Research Communications*, vol. 262, no. 1, pp. 68–75, 1999.

[8] C. Segouffin-Cariou and M. Billaud, "Transforming ability of MEN2A-RET requires activation of the phosphatidylinositol 3-kinase/AKT signaling pathway," *Journal of Biological Chemistry*, vol. 275, no. 5, pp. 3568–3576, 2000.

[9] M. Chiariello, R. Visconti, F. Carlomagno et al., "Signalling of the Ret receptor tyrosine kinase through the c-Jun NH-terminal protein kinases (JNKs): evidence for a divergence of the ERKs and JNKs pathways induced by Ret," *Oncogene*, vol. 16, no. 19, pp. 2435–2445, 1998.

[10] E. Arighi, M. G. Borrello, and H. Sariola, "RET tyrosine kinase signaling in development and cancer," *Cytokine and Growth Factor Reviews*, vol. 16, no. 4-5, pp. 441–467, 2005.

[11] T. S. Gujral, W. Van Veelen, D. S. Richardson et al., "A novel RET kinase-β-catenin signaling pathway contributes to tumorigenesis in thyroid carcinoma," *Cancer Research*, vol. 68, no. 5, pp. 1338–1346, 2008.

[12] M. Takahashi, J. Ritz, and G. M. Cooper, "Activation of a novel human transforming gene, ret, by DNA rearrangement," *Cell*, vol. 42, no. 2, pp. 581–588, 1985.

[13] D. Hanahan and R. A. Weinberg, "The hallmarks of cancer," *Cell*, vol. 100, no. 1, pp. 57–70, 2000.

[14] T. Watanabe, M. Ichihara, M. Hashimoto et al., "Characterization of gene expression induced by RET with MEN2A or MEN2B mutation," *American Journal of Pathology*, vol. 161, no. 1, pp. 249–256, 2002.

[15] J. J. Schuringa, K. Wojtachnio, W. Hagens et al., "MEN2A-RET-induced cellular transformation by activation of STAT3," *Oncogene*, vol. 20, no. 38, pp. 5350–5358, 2001.

[16] N. Asai, T. Fukuda, Z. Wu et al., "Targeted mutation of serine 697 in the Ret tyrosine kinase causes migration defect of enteric neural crest cells," *Development*, vol. 133, no. 22, pp. 4507–4516, 2006.

[17] G. W. McLean, N. O. Carragher, E. Avizienyte, J. Evans, V. G. Brunton, and M. C. Frame, "The role of focal-adhesion kinase in cancer—a new therapeutic opportunity," *Nature Reviews Cancer*, vol. 5, no. 7, pp. 505–515, 2005.

[18] F. Colotta, P. Allavena, A. Sica, C. Garlanda, and A. Mantovani, "Cancer-related inflammation, the seventh hallmark of cancer: links to genetic instability," *Carcinogenesis*, vol. 30, no. 7, pp. 1073–1081, 2009.

[19] M. G. Borrello, L. Alberti, A. Fischer et al., "Induction of a proinflammatory program in normal human thyrocytes by the RET/PTC1 oncogene," *Proceedings of the National Academy of Sciences of the United States of America*, vol. 102, no. 41, pp. 14825–14830, 2005.

[20] N. Iwahashi, H. Murakami, Y. Nimura, and M. Takahashi, "Activation of RET tyrosine kinase regulates interleukin-8 production by multiple signaling pathways," *Biochemical and Biophysical Research Communications*, vol. 294, no. 3, pp. 642–649, 2002.

[21] S. Shinohara and J. L. Rothstein, "Interleukin 24 is induced by the RET/PTC3 oncoprotein and is an autocrine growth factor for epithelial cells," *Oncogene*, vol. 23, no. 45, pp. 7571–7579, 2004.

[22] V. Guarino, M. D. Castellone, E. Avilla, and R. M. Melillo, "Thyroid cancer and inflammation," *Molecular and Cellular Endocrinology*, vol. 321, no. 1, pp. 94–102, 2010.

[23] E. Puxeddu, J. A. Knauf, M. A. Sartor et al., "RET/PTC-induced gene expression in thyroid PCCL3 cells reveals early activation of genes involved in regulation of the immune response," *Endocrine-Related Cancer*, vol. 12, no. 2, pp. 319–334, 2005.

[24] M. Muzza, D. Degl'Innocenti, C. Colombo et al., "The tight relationship between papillary thyroid cancer, autoimmunity and inflammation: clinical and molecular studies," *Clinical Endocrinology*, vol. 72, no. 5, pp. 702–708, 2010.

[25] M. G. Borrello, D. Degl'Innocenti, and M. A. Pierotti, "Inflammation and cancer: the oncogene-driven connection," *Cancer Letters*, vol. 267, no. 2, pp. 262–270, 2008.

[26] L. M. Mulligan, J. B. J. Kwok, C. S. Healey et al., "Germ-line mutations of the RET proto-oncogene in multiple endocrine neoplasia type 2A," *Nature*, vol. 363, no. 6428, pp. 458–460, 1993.

[27] H. Donis-Keller, S. Dou, D. Chi et al., "Mutations in the RET proto-oncogene are associated with MEN 2A and FMTC," *Human Molecular Genetics*, vol. 2, no. 7, pp. 851–856, 1993.

[28] C. Eng, D. Clayton, I. Schuffenecker et al., "The relationship between specific ret proto-oncogene mutations and disease phenotype in multiple endocrine neoplasia type 2: international RET mutation consortium analysis," *Journal of the American Medical Association*, vol. 276, no. 19, pp. 1575–1579, 1996.

[29] M. Santoro, F. Carlomagno, A. Romano et al., "Activation of RET as a dominant transforming gene by germline mutations of MEN2A and MEN2B," *Science*, vol. 267, no. 5196, pp. 381–383, 1995.

[30] M. D. Castellone, A. Verrienti, D. Magendra Rao et al., "A novel de novo germ-line V292M mutation in the extracellular region of RET in a patient with phaeochromocytoma and medullary thyroid carcinoma: functional characterization," *Clinical Endocrinology*, vol. 73, no. 4, pp. 529–534, 2010.

[31] F. Lesueur, A. Cebrian, A. Cranston et al., "Germline homozygous mutations at codon 804 in the RET protooncogene in medullary thyroid carcinoma/multiple endocrine neoplasia type 2A patients," *Journal of Clinical Endocrinology and Metabolism*, vol. 90, no. 6, pp. 3454–3457, 2005.

[32] P. Pigny, C. Bauters, J. L. Wemeau et al., "A novel 9-base pair duplication in RET exon 8 in familial medullary thyroid carcinoma," *Journal of Clinical Endocrinology and Metabolism*, vol. 84, no. 5, pp. 1700–1704, 1999.

[33] A. N. Cranston, C. Carniti, K. Oakhill et al., "RET is constitutively activated by novel tandem mutations that alter the active site resulting in multiple endocrine neoplasia type 2B," *Cancer Research*, vol. 66, no. 20, pp. 10179–10187, 2006.

[34] P. Soares, V. Trovisco, A. S. Rocha et al., "BRAF mutations and RET/PTC rearrangements are alternative events in the etiopathogenesis of PTC," *Oncogene*, vol. 22, no. 29, pp. 4578–4580, 2003.

[35] R. M. W. Hofstra, R. M. Landsvater, I. Ceccherini et al., "A mutation in the RET proto-oncogene associated with multiple endocrine neoplasia type 2B and sporadic medullary thyroid carcinoma," *Nature*, vol. 367, no. 6461, pp. 375–376, 1994.

[36] O. Gimm, D. J. Marsh, S. D. Andrew et al., "Germline dinucleotide mutation in codon 883 of the RET proto-oncogene in multiple endocrine neoplasia type 2B without codon 918 mutation," *Journal of Clinical Endocrinology and Metabolism*, vol. 82, no. 11, pp. 3902–3904, 1997.

[37] A. Miyauchi, H. Futami, N. Hai et al., "Two germline missense mutations at codons 804 and 806 of the RET proto-oncogene in the same allele in a patient with multiple endocrine neoplasia type 2B without codon 918 mutation," *Japanese Journal of Cancer Research*, vol. 90, no. 1, pp. 1–5, 1999.

[38] P. J. Morrison and N. C. Nevin, "Multiple endocrine neoplasia type 2B (mucosal neuroma syndrome, Wagenmann-Froboese syndrome)," *Journal of Medical Genetics*, vol. 33, no. 9, pp. 779–782, 1996.

[39] S. Bethanis, G. Koutsodontis, T. Palouka et al., "A newly detected mutation of the RET protooncogene in exon 8 as a cause of multiple endocrine neoplasia type 2A," *Hormones*, vol. 6, no. 2, pp. 152–156, 2007.

[40] I. Berndt, M. Reuter, B. Saller et al., "A new hot spot for mutations in the ret protooncogene causing familial medullary thyroid carcinoma and multiple endocrine neoplasia type 2A," *Journal of Clinical Endocrinology and Metabolism*, vol. 83, no. 3, pp. 770–774, 1998.

[41] G. Pinna, G. Orgiana, A. Riola et al., "RET proto-oncogene in Sardinia: V804M is the most frequent mutation and may be associated with FMTC/MEN-2A phenotype," *Thyroid*, vol. 17, no. 2, pp. 101–104, 2007.

[42] C. Jimenez, M. A. Habra, S. C. E. Huang et al., "Pheochromocytoma and medullary thyroid carcinoma: a new genotype-phenotype correlation of the RET protooncogene 891 germline mutation," *Journal of Clinical Endocrinology and Metabolism*, vol. 89, no. 8, pp. 4142–4145, 2004.

[43] F. Raue and K. Frank-Raue, "Multiple endocrine neoplasia type 2: 2007 update," *Hormone Research*, vol. 68, supplement 5, pp. 101–104, 2007.

[44] R. T. Kloos, C. Eng, D. B. Evans et al., "Medullary thyroid cancer: management guidelines of the American Thyroid Association," *Thyroid*, vol. 19, no. 6, pp. 565–612, 2009.

[45] S. Dvorakova, E. Vaclavikova, V. Sykorova et al., "Somatic mutations in the RET proto-oncogene in sporadic medullary thyroid carcinomas," *Molecular and Cellular Endocrinology*, vol. 284, no. 1-2, pp. 21–27, 2008.

[46] M. M. Moura, B. M. Cavaco, A. E. Pinto et al., "Correlation of RET somatic mutations with clinicopathological features in sporadic medullary thyroid carcinomas," *British Journal of Cancer*, vol. 100, no. 11, pp. 1777–1783, 2009.

[47] X. Liu, Q. C. Vega, R. A. Decker, A. Pandey, C. A. Worby, and J. E. Dixon, "Oncogenic RET receptors display different autophosphorylation sites and substrate binding specificities," *Journal of Biological Chemistry*, vol. 271, no. 10, pp. 5309–5312, 1996.

[48] D. Salvatore, R. M. Melillo, C. Monaco et al., "Increased in vivo phosphorylation of ret tyrosine 1062 is a potential pathogenetic mechanism of multiple endocrine neoplasia type 2B," *Cancer Research*, vol. 61, no. 4, pp. 1426–1431, 2001.

[49] I. P. Menacho, R. Koster, A. M. Van Der Sloot et al., "RET-familial medullary thyroid carcinoma mutants Y791F and S891A activate a Src/JAK/STAT3 pathway, independent of glial cell line-derived neurotrophic factor," *Cancer Research*, vol. 65, no. 5, pp. 1729–1737, 2005.

[50] F. Carlomagno, D. Vitagliano, T. Guida et al., "The kinase inhibitor PP1 blocks tumorigenesis induced by RET oncogenes," *Cancer Research*, vol. 62, no. 4, pp. 1077–1082, 2002.

[51] F. Carlomagno, D. Vitagliano, T. Guida et al., "ZD6474, an orally available inhibitor of KDR tyrosine kinase activity, efficiently blocks oncogenic RET kinases," *Cancer Research*, vol. 62, no. 24, pp. 7284–7290, 2002.

[52] C. Lanzi, G. Cassinelli, T. Pensa et al., "Inhibition of transforming activity of the ret/ptc1 oncoprotein by a 2-indolinone derivative," *International Journal of Cancer*, vol. 85, no. 3, pp. 384–390, 2000.

[53] D. W. Kim, Y. S. Jo, H. S. Jung et al., "An orally administered multitarget tyrosine kinase inhibitor, SU11248, is a novel potent inhibitor of thyroid oncogenic RET/papillary thyroid cancer kinases," *Journal of Clinical Endocrinology and Metabolism*, vol. 91, no. 10, pp. 4070–4076, 2006.

[54] S. J. Dawson, N. M. Conus, G. C. Toner et al., "Sustained clinical responses to tyrosine kinase inhibitor sunitinib in thyroid carcinoma," *Anti-Cancer Drugs*, vol. 19, no. 5, pp. 547–552, 2008.

[55] M. Croyle, N. Akeno, J. A. Knauf et al., "RET/PTC-induced cell growth is mediated in part by epidermal growth factor receptor (EGFR) activation: evidence for molecular and functional interactions between RET and EGFR," *Cancer Research*, vol. 68, no. 11, pp. 4183–4191, 2008.

[56] N. A. Pennell, G. H. Daniels, R. I. Haddad et al., "A phase II study of gefitinib in patients with advanced thyroid cancer," *Thyroid*, vol. 18, no. 3, pp. 317–323, 2008.

[57] F. Carlomagno, S. Anaganti, T. Guida et al., "BAY 43-9006 inhibition of oncogenic RET mutants," *Journal of the National Cancer Institute*, vol. 98, no. 5, pp. 326–334, 2006.

[58] V. Gupta-Abramson, A. B. Troxel, A. Nellore et al., "Phase II trial of sorafenib in advanced thyroid cancer," *Journal of Clinical Oncology*, vol. 26, no. 29, pp. 4714–4719, 2008.

[59] S. I. Sherman, L. J. Wirth, J. P. Droz et al., "Motesanib diphosphate in progressive differentiated thyroid cancer," *New England Journal of Medicine*, vol. 359, no. 1, pp. 31–42, 2008.

[60] M. J. Schlumberger, R. Elisei, L. Bastholt et al., "Phase II study of safety and efficacy of motesanib in patients with progressive or symptomatic, advanced or metastatic medullary thyroid cancer," *Journal of Clinical Oncology*, vol. 27, no. 23, pp. 3794–3801, 2009.

[61] E. E. W. Cohen, L. S. Rosen, E. E. Vokes et al., "Axitinib is an active treatment for all histologic subtypes of advanced thyroid cancer: results from a phase II study," *Journal of Clinical Oncology*, vol. 26, no. 29, pp. 4708–4713, 2008.

[62] J. P. Eder, L. Appleman, E. Heath et al., "A phase I study of a novel spectrum selective kinase inhibitor (SSKI), XL880, administered orally in patients (pts) with advanced solid tumors (STs)," *Journal of Clinical Oncology*, vol. 24, no. 18S, p. 3041, 2006, ASCO Annual Meeting Proceedings Part I.

[63] P. LoRusso, L. Appleman, A. X. Zhu et al., "Pharmacodynamics of XL880, a novel spectrum selective kinase inhibitor (SSKI) administered orally in patients with advanced solid tumors (AST)," in *Proceedings of the 18th EORTC-NCI-AACR Symposium on Molecular Targets and Cancer Therapeutics*, Prague, Czech Republic, November 2006, Abstract 404.

[64] R. W. Ross, M. Stein, J. Sarantopoulos et al., "A phase II study of the c-Met RTK inhibitor XL880 in patients (pts) with papillary renal-cell carcinoma (PRC)," *Journal of Clinical Oncology*, vol. 25, no. 18S, p. 15601, 2007, ASCO Annual Meeting Proceedings.

[65] R. Salgia, D. S. Hong, L. H. Camacho et al., "A phase I dose-escalation study of the safety and pharmacokinetics (PK) of XL184, a VEGFR and MET kinase inhibitor, administered orally to patients (pts) with advanced malignancies," *Journal of Clinical Oncology*, vol. 25, no. 18S, p. 14031, 2007, ASCO Annual Meeting Proceedings.

[66] C. J. Strock, J. I. Park, M. Rosen et al., "CEP-701 and CEP-751 inhibit constitutively activated RET tyrosine kinase activity and block medullary thyroid carcinoma cell growth," *Cancer Research*, vol. 63, no. 17, pp. 5559–5563, 2003.

[67] M. S. Cohen, H. B. Hussain, and J. F. Moley, "Inhibition of medullary thyroid carcinoma cell proliferation and RET phosphorylation by tyrosine kinase inhibitors," *Surgery*, vol. 132, no. 6, pp. 960–967, 2002.

[68] M. A. Skinner, J. A. Moley, W. G. Dilley, K. Owzar, M. K. DeBenedetti, and S. A. Wells, "Prophylactic thyroidectomy in multiple endocrine neoplasia type 2A," *New England Journal of Medicine*, vol. 353, no. 11, pp. 1105–1113, 2005.

[69] J. F. Lyons, S. Wilhelm, B. Hibner, and G. Bollag, "Discovery of a novel Raf kinase inhibitor," *Endocrine-Related Cancer*, vol. 8, no. 3, pp. 219–225, 2001.

[70] Y. C. Henderson, S. H. Ann, Y. Kang, and G. L. Clayman, "Sorafenib potently inhibits papillary thyroid carcinomas harboring RET/PTC1 rearrangement," *Clinical Cancer Research*, vol. 14, no. 15, pp. 4908–4914, 2008.

[71] C. Lanzi, G. Cassinelli, G. Cuccuru et al., "Inactivation of Ret/Ptc1 oncoprotein and inhibition of papillary thyroid carcinoma cell proliferation by indolinone RPI-1," *Cellular and Molecular Life Sciences*, vol. 60, no. 7, pp. 1449–1459, 2003.

[72] D. B. Mendel, A. Douglas Laird, X. Xin et al., "In vivo antitumor activity of SU11248, a novel tyrosine kinase inhibitor targeting vascular endothelial growth factor and platelet-derived growth factor receptors: determination of a pharmacokinetic/pharmacodynamic relationship," *Clinical Cancer Research*, vol. 9, no. 1, pp. 327–337, 2003.

[73] T. J. Abrams, L. B. Lee, L. J. Murray, N. K. Pryer, and J. M. Cherrington, "SU11248 inhibits KIT and platelet-derived growth factor receptor beta in preclinical models of human small cell lung cancer," *Molecular Cancer Therapeutics*, vol. 2, no. 5, pp. 471–478, 2003.

[74] C. J. Strock, J. I. Park, D. M. Rosen et al., "Activity of irinotecan and the tyrosine kinase inhibitor CEP-751 in medullary thyroid cancer," *Journal of Clinical Endocrinology and Metabolism*, vol. 91, no. 1, pp. 79–84, 2006.

[75] S. D. Undevia, N. J. Vogelzang, A. M. Mauer, L. Janisch, S. Mani, and M. J. Ratain, "Phase I clinical trial of CEP-2563 dihydrochloride, a receptor tyrosine kinase inhibitor, in patients with refractory solid tumors," *Investigational New Drugs*, vol. 22, no. 4, pp. 449–458, 2004.

[76] T. K. Choueiri, "Axitinib, a novel anti-angiogenic drug with promising activity in various solid tumors," *Current Opinion in Investigational Drugs*, vol. 9, no. 6, pp. 658–671, 2008.

[77] A. Polverino, A. Coxon, C. Starnes et al., "AMG 706, an oral, multikinase inhibitor that selectively targets vascular endothelial growth factor, platelet-derived growth factor, and kit receptors, potently inhibits angiogenesis and induces regression in tumor xenografts," *Cancer Research*, vol. 66, no. 17, pp. 8715–8721, 2006.

[78] F. Carlomagno, T. Guida, S. Anaganti et al., "Disease associated mutations at valine 804 in the RET receptor tyrosine kinase confer resistance to selective kinase inhibitors," *Oncogene*, vol. 23, no. 36, pp. 6056–6063, 2004.

[79] P. P. Knowles, J. Murray-Rust, S. Kjær et al., "Structure and chemical inhibition of the RET tyrosine kinase domain," *Journal of Biological Chemistry*, vol. 281, no. 44, pp. 33577–33587, 2006.

[80] I. Plaza-Menacho, L. Mologni, E. Sala et al., "Sorafenib functions to potently suppress RET tyrosine kinase activity by direct enzymatic inhibition and promoting RET lysosomal degradation independent of proteasomal targeting," *Journal of Biological Chemistry*, vol. 282, no. 40, pp. 29230–29240, 2007.

[81] D. G. Pfister and J. A. Fagin, "Refractory thyroid cancer: a paradigm shift in treatment is not far off," *Journal of Clinical Oncology*, vol. 26, no. 29, pp. 4701–4704, 2008.

[82] P. P. Joshi, M. V. Kulkarni, B. K. Yu et al., "Simultaneous downregulation of CDK inhibitors p18 and p27 is required for MEN2A-RET-mediated mitogenesis," *Oncogene*, vol. 26, no. 4, pp. 554–570, 2007.

[83] W. Van Veelen, C. J. R. Van Gasteren, D. S. Acton et al., "Synergistic effect of oncogenic RET and loss of p18 on medullary thyroid carcinoma development," *Cancer Research*, vol. 68, no. 5, pp. 1329–1337, 2008.

SAGE-Hindawi Access to Research
Journal of Thyroid Research
Volume 2011, Article ID 102636, 11 pages
doi:10.4061/2011/102636

Review Article

Targeted Treatment of Differentiated and Medullary Thyroid Cancer

Shannon R. Bales and Inder J. Chopra

Division of Endocrinology, Diabetes, and Hypertension, University of California, Los Angeles, CA 90095, USA

Correspondence should be addressed to Inder J. Chopra, ichopra@mednet.ucla.edu

Received 14 January 2011; Accepted 14 June 2011

Academic Editor: Nelson Wohllk

The incidence of thyroid cancer is increasing, with a concomitant increase in the number of patients with advanced and metastatic disease. Discoveries regarding the pathogenesis of thyroid cancer have led to the recent development of new therapeutic agents that are beginning to appear on the market. Many of these new agents are targeted kinase inhibitors primarily affecting oncogenic kinases (BRAF V600E, RET/PTC) or signaling kinases (VEGFR, PDGFR). Some of these agents report significant partial response rates, while others attain stabilization of disease as their best response. Their impact on survival is unclear. While these agents target similar pathways, a wide variety of differences exist regarding efficacy and side effect profile. Current expert opinion advises that these agents be used only in a specific subset of patients.

1. Introduction

The incidence of thyroid cancer is increasing at an alarming rate. In fact, the incidence has more than doubled in the past fifty years, and it rose approximately 6% per year from 1997 to 2006 [1]. Peak incidence is in the early fifth decade for women and the late sixth decade for men. It is two to three times more common in women than in men, though mortality rates are higher in men. Mortality rates are also higher in patients with African ethnic heritage [1].

Total thyroidectomy followed by radioactive iodine (^{131}I) ablation and thyroid hormone suppression of serum TSH are the mainstay of treatment for differentiated thyroid cancer (DTC). While cure is generally attainable in well-differentiated thyroid carcinomas (papillary and follicular subtypes), recurrence occurs in up to 40% of patients [2]. Unfortunately, in a small percentage of patients with thyroid cancer recurrence, the tumor becomes dedifferentiated. It does not concentrate iodine and thereby becomes unresponsive to (^{131}I) treatment, likely the result of mutational changes in the sodium-iodine symporter [3]. Such tumor often shows increased aggressiveness and has a tendency to metastasize [4, 5].

Patients with medullary thyroid cancer (MTC) are susceptible to early metastatic disease. Between 20 to 30% of patients with T1 tumors at the time of diagnosis already have metastasis to lymph nodes [6]. The mainstay of treatment for these patients is total thyroidectomy with aggressive lymph node dissection. For patients with a family history of MTC or multiple endocrine neoplasia 2A or 2B, prophylactic thyroidectomy is recommended as soon as possible, even in patients who are less than one-year-old [6].

Popular treatment options for advanced stages of DTC and MTC consist of radiotherapy and chemotherapy, which confer only a modest benefit on tumor burden and overall survival. Current treatment regimens for advanced thyroid cancer include bleomycin, doxorubicin, platinum-containing compounds, or a combination of these agents. For the most part, they result in minor responses, and their use is limited by their toxicities. Bleomycin is well known for its pulmonary toxicity, while doxorubicin can cause both cardiac arrhythmias and heart failure. Platinum-based therapies result in neuropathy, nausea, and renal toxicity [7].

However, recent research has shed light on the underlying molecular mechanisms of thyroid cancer and on the role of oncogenic kinases in metastatic thyroid cancer in particular

[8]. Given the high incidence of thyroid cancer and its recently elucidated molecular mechanisms, thyroid cancer has become a focus of effort for use of new targeted therapies, especially the new class of agents that inhibit kinases involved in signaling, cellular growth, and angiogenesis [8]. Most of the therapeutic agents being developed actually target both the oncogenic and the signaling pathways.

2. Overview of the Molecular Pathways of Thyroid Cancer

Comprehensive studies of mutation pathways in DTC and MTC have been undertaken in the past two decades [9–21]. The knowledge gained from these analyses may render DTC and MTC amenable to designer therapeutics. The most important findings center on the discovery of oncogenic kinases, as well as the elucidation of various signaling pathway adaptations occurring in malignant cells. Of the oncogenic kinases, BRAF V600E mutation and RET/PTC mutations are being targeted as potential pathways for therapeutic intervention. Both of these mutations have the potential to activate the mitogen-activated protein kinase (MAPK) pathway downstream. Therapeutics targeting RET/PTC are being developed particularly for use in MTC. The vascular endothelial growth factor (VEGF) and platelet-derived growth factor (PDGF) pathways, as well as the phosphatidylinositol-3-kinase-(PI3K-) phosphatase with tensin homology (PTEN) pathway are important signaling cascades being investigated for possible development of therapeutic kinase inhibitors (Figure 1).

2.1. Oncogenic Kinases. BRAF mutations are the most commonly encountered mutation in PTC [13, 22, 23]. BRAF mutations are present in 29–83% of cases of papillary thyroid cancer (PTC) [8, 24]. Anaplastic thyroid carcinoma (ATC) also has a high frequency of BRAF mutations, with up to 50% of ATC harboring a mutation in this entity [25]. The BRAF gene is located on chromosome 7q24. Oncogenic BRAF mutations in PTC commonly (approximately 80%) are comprised of a thymidine to adenine substitution in exon 15 (T1799A) resulting in an amino acid sequence change of valine to glutamate (V600E) [22, 26]. This change destabilizes the inactive conformation of BRAF, rendering it constitutively active [14, 26, 27]. Activated oncogenic mutant BRAF has a higher affinity for MEK1 and MEK2 and increases the phosphorylation of MEK. BRAF V600E also potently activates MAPK pathway directly. BRAF can be activated by another genetic rearrangement leading to formation of a fusion protein, AKAP9-BRAF, which can activate MAPK pathways. This rearrangement is present in approximately 11% of PTC [28]. The basis of these mutations is not known. The BRAF V600E mutant does not seem related to radiation exposure. In contrast, the AKAP9-BRAF is thought to be related to irradiation [28–30].

Some authors suggest that PTCs with BRAF mutations are more aggressive and tend to present at a more advanced clinical stage and with extrathyroidal invasion [24, 31]. BRAF mutations are more frequently present in older patients with otherwise classical PTC, who are at a more advanced stage of the disease at the time of diagnosis [24, 31, 32]. This suggestion is also supported by the observation that the tall-cell variant of PTC has a high prevalence of BRAF mutations [33]. Additionally, BRAF mutation is common in aggressive microcarcinomas [34, 35]. These mutations occur rarely or not at all in follicular or medullary thyroid carcinomas, benign adenomas, or benign hyperplasias [23, 36, 37]. Many undifferentiated and anaplastic carcinomas arising from pre-existing PTC have BRAF mutations [32, 38]. Additionally, tumors with BRAF mutations tend to have decreased expression of NIS symporter, and leading the tumor to become refractory to radioiodine treatment [39–41]. Interestingly, BRAF mutation is generally present without other common mutations found in PTC, suggesting that BRAF mutation alone may be sufficient for tumorigenesis [13, 36, 37].

The oncogenic RET/PTC mutation is also commonly found in PTCs, approximately 10–50% [21]. Familial forms of medullary thyroid carcinoma (MTC) also arise from inheritable activating mutations in RET (the most studied being the C634R change) [42, 43]. RET/PTC rearrangements are very common in thyroid tissue exposed to radiation, and are also commonly noted in pediatric PTC [44, 45]. Radiation has been shown to induce this recombination in thyroid cell lines and in normal human thyroid tissue transplanted onto SCID mice [46]. Twelve forms of RET/PTC mutations have been described, with forms 1 and 3 being the most common [16]. RET/PTC1 is typically associated with classical PTC, while RET/PTC3 rearrangement is associated with solid-variant PTCs [17]. These mutations result in the linking of the promoter and N-terminus to unrelated C-terminus fragments of RET, leading to a chimeric receptor that is constitutively active. RET/PTC mutations are uncommon in poorly differentiated cancers, suggesting that this mutation may imply a favorable prognosis [18]. Curiously, RET/PTC expression in thyroid cells has been found to be associated with impaired hormonogenesis and hypothyroidism, particularly Hashimoto's thyroiditis (HT). Whether or not this predisposes an individual with HT to thyroid cancer is unclear [47–49].

2.2. Signaling Kinases. A few of the important signaling cascades being investigated for the possible development of therapeutic kinase inhibitors are the VEGF and PDGF pathways, as well as the PI3K/PTEN pathway. VEGF is a proangiogenic factor that binds to two receptor tyrosine kinases (VEGFR-1 and VEGFR-2), of which VEGFR-2 is widely recognized to be the primary mediator of angiogenesis. PDGF-B is required for the maturation of microvasculature, while tumor-derived PDGF-A recruits angiogenic stroma to the tissue. VEGFR and PDGFR mutually support the increased activity of each other [50]. Increased VEGF expression appears to be related to worse prognosis, increased risk of recurrence, and the presence of metastasis [51, 52].

The PI3K/PTEN pathway is responsible for regulating glucose metabolism, cell survival, adhesion, and motility [20, 53, 54]. It is found in some thyroid carcinomas (particularly follicular carcinomas) as well as other types of cancers [55–60]. Epigenetic methylation leads to silencing of the negative

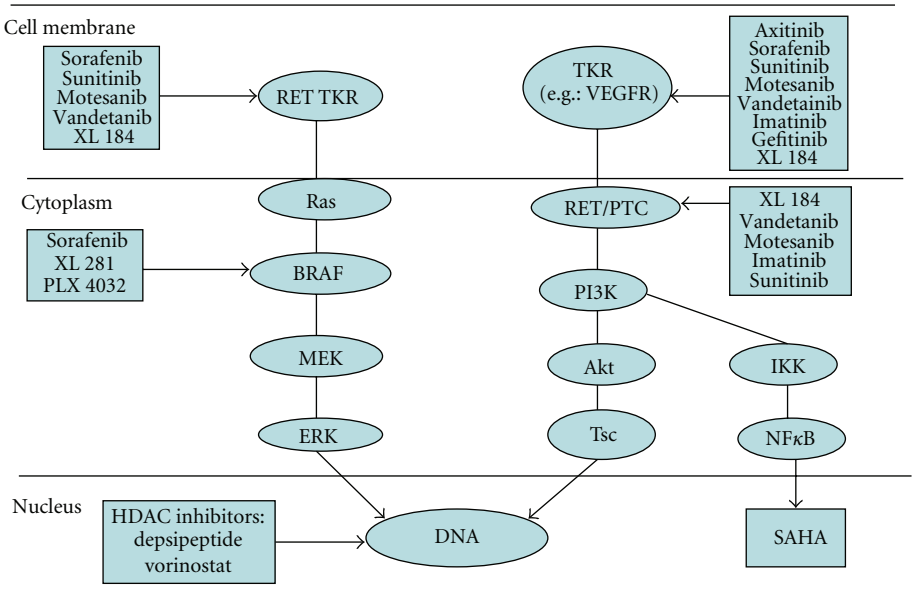

Figure 1: Molecular pathways of thyroid cancer and their corresponding therapeutic agents.

regulator PTEN gene, thus facilitating increased activity of the downstream PI3K/Akt pathway [61]. Changes in this pathway occurred in 31% of benign thyroid adenomas, 24% of PTCs, 55% of FTCs, and 58% of ATCs according to one study. The authors concluded that this pathway may be important in the progression from benign thyroid adenoma to follicular cancer to ATC [62]. BRAF mutations have been found along with mutations in PI3K/PTEN pathway in undifferentiated thyroid carcinoma, perhaps promoting progression from DTC to undifferentiated thyroid cancer [15].

3. New Agents for the Treatment of Thyroid Cancer

3.1. Agents Primarily Targeting Oncogenic Kinases. Given the increased frequency of BRAF mutations in PTC, a number of newer therapeutic agents have been developed that inhibit BRAF. The BRAF inhibitor studied most in thyroid cancer is sorafenib. Sorafenib (Nexavar, BAY 43-9006, Bayer) is an oral tyrosine kinase inhibitor which has been approved by the Food and Drug Administration for the treatment of advanced renal cell carcinoma and unresectable hepatocellular carcinoma. It inhibits VEGFR 2/3, RET including RET/PTC1 mutant, c-kit, PDGFR-beta, and BRAF (including the V600E mutation) [63, 64]. It is a biaryl compound that locks the mutant constitutively active kinase in an inactive state. It competitively inhibits ATP binding in the catalytic domains of both normal and mutant BRAF. This triggers G1 phase arrest.

None of the four phase 1 trials of sorafenib included subjects with thyroid cancer, but there is in vitro data in thyroid cancer cell lines that demonstrated efficacy. The phase 1 trials established the optimum dosing regimen as 400 mg twice a day [65]. A number of phase II trials of sorafenib involved advanced or metastatic DTC. These patients' tumors demonstrated partial responses in 15–27% of participants, and stable disease in a little over 34–61% [66–68]. It should be noted that a recent retrospective review of thirteen patients with advanced DTC from MD Anderson demonstrated particular efficacy of this agent in lung metastasis, while it was less efficacious in bone metastasis [69]. Given its ability to interfere with RET and RET/PTC pathways, treatment with sorafenib was attempted in a phase II trial of MTC. Only a very small portion of patients achieved a partial response, although stable disease response rates were comparable to those seen in the DTC phase II trials [70].

While sorafenib is generally well tolerated with side effects including rash, diarrhea, hand-foot syndrome, and fatigue, treatment with sorafenib may be associated with an increased risk of cardiac toxicities, with up to 40% of patients experiencing EKG changes. Myocardial infarction has also been reported as a side effect of sorafenib in patients being treated for renal cell carcinoma [71, 72]. Increased risk for cutaneous squamous cell carcinomas has been ascribed to the entire class of BRAF inhibitors, and sorafenib is no exception [73].

PLX4032 (RG7204, a Plexxikon drug being codeveloped with Roche) is a 7-azaindole derivative that is currently in clinical trials. PLX4032 specifically inhibits BRAF V600E to a greater extent than wild-type BRAF [74, 75]. Unlike sorafenib which only binds to the inactive conformation of BRAF and keeps it inactive, PLX4032 binds to both the active form and inactive forms of BRAF. It has been shown to actively inhibit proliferation of BRAF-mutant-positive cell lines, particularly in melanoma; thus, most of the clinical trials have been focused on melanoma [76].

Notably, not all cell lines with BRAF V600E mutations respond equally to treatment with PLX4032. Although mutant BRAF V600E has been identified in ATC, PLX4032

did not lead to apoptosis of the anaplastic thyroid carcinoma cell line ARO [77]. Different melanoma cell lines with BRAF V600E demonstrate differential response to PLX4032 as well; some are highly sensitive while some are essentially unresponsive to treatment with this agent. These differences might be explained by whether the cell line is homozygous or heterozygous for the BRAF V600E mutation. Variation in the upregulation of the PI3K/PTEN pathway in response to treatment with this agent potentially mediates the observed resistance in nonresponding cell lines [78].

An early clinical trial of PLX4032 demonstrated that one out of three participants with thyroid cancer achieved a partial response [79]. Rashes are the most common side effect of this agent. Again noted is an increase in risk for development of cutaneous squamous cell carcinomas, likely owing to its anti-BRAF activity [79]. XL281 (Exelixis, Bristol-Meyers-Squibb BMS-908662) is another oral agent similar to PLX4032 in that it inhibits both wild-type and mutant BRAF kinases. Phase I clinical trials are ongoing and include subjects with thyroid carcinoma though early results are not encouraging [80].

Sunitinib (Sutent, SU11248, Pfizer) is a tyrosine kinase inhibitor affecting VEGFR 1/2/3, RET, RET/PTC1, and RET/PTC3 [81]. Of DTC and MTC patients enrolled in a phase II trial of sunitinib receiving 50 mg/day, partial response was observed in 13% of patients with DTC, while stable disease was the best response in 68% of patients with DTC. Eighty-three percent of patients with MTC achieved stable disease [82]. Additionally, there are case reports of patients with advanced MTC having a dramatic response to treatment with sunitinib with respect to both serum calcitonin levels and tumor burden [83]. Patients experience side effects primarily relating to fatigue, and diarrhea when treated with sunitinib. Another unique adverse effect of this agent is palmar-plantar erythrodesia.

Sunitinib can also cause hypothyroidism like many of the tyrosine kinase inhibitors. The mechanism is thought to be related to a destructive thyroiditis when administered for the treatment of renal cell carcinoma [84, 85]. However, this is unlikely to be the cause of hypothyroidism in thyroid cancer patients, as they have all presumably undergone total thyroidectomy. There is other evidence suggesting that increases in TSH in athyreotic patients are associated with increased type 3 deiodination and augmented peripheral thyroid hormone metabolism [86]. Interestingly, some studies suggest that development of hypothyroidism during treatment for other cancers other than thyroid cancer may actually be an encouraging prognostic factor [87, 88].

Heart failure may also be a serious adverse effect sunitinib, occurring in 2.7% of patients from a retrospective study of 600 patients at MD Anderson [69]. A different retrospective analysis including 75 patients involved in phase I and II trials with sunitinib at several centers around the United States reported an 11% cardiac event rate, and a decrease in left ventricular ejection fraction of greater than 10% in 47% of included subjects. Half of the included patients developed hypertension [89]. While the mechanism of heart failure associated with tyrosine kinase inhibitors may be related to mitochondrial damage, recent studies postulate that myocyte damage occurs secondary to a lack of target selectivity of binding to both tyrosine kinases and serine-threonine kinases [89–91]. Of the clinically available tyrosine kinase inhibitors used in one comparison study, sunitinib, sorafenib, and pazopanib induced the highest degree of myocyte damage as measured by lactate dehydrogenase leakage [90].

Vandetanib (Zactima, ZD6474, iPR Pharmaceuticals, AstraZeneca Pharmaceuticals) is an oral tyrosine kinase inhibitor that targets VEGFR 2/3, RET, and EGFR [92, 93]. It is a heteroaromatic-substituted anilinoquinazoline. It specifically inhibits RET/PTC1 and RET/PTC3 in PTC, and M918R RET mutations in MEN2B [94, 95]. Recent investigations into the mechanism of action of vandetanib in cell culture revealed that the agents ability to block both RET and EGFR simultaneously can prevent escape from RET blockade [96]. A completed phase II trial demonstrated efficacy in metastatic familial MTC [97]; 21% of patients treated with 300 mg/day showed a partial response, while 53% patients had stable disease at 24 weeks. There was a decrease in levels of calcitonin in most patients. Adverse effects were significant enough to require dose reductions in several subjects and consisted of diarrhea, severe rash, fatigue, and QTC prolongation [97].

The vandetanib safety database, which accrues data from treatment of multiple cancer types, noted a potential increase in other serious entities such as cerebrovascular accidents and interstitial lung disease [98]. Recent US Food and Drug Administration review cites concern regarding the side effect profile of this agent and propose limiting the indications to progressive symptomatic disease [98]. Another recently published study of subjects with locally advanced or metastatic hereditary MTC administered only 100 mg/day of the drug with nearly similar response rates compared to the above study, and was somewhat better tolerated regarding side effects [99]. Other phase II trials for familial MTC and DTC are underway, as are phase III trials for metastatic MTC. Based on the above mentioned trials as well as other recent data, in April 2011, the US Food and Drug Administration approved vandetanib for use in late-stage MTC. This is the first medication approved by the FDA for the treatment of MTC [100].

Imatinib Mesylate (STI571, Gleevec, Novartis) is an oral tyrosine kinase inhibitor (TKI) that suppresses c-ABL mutation, c-KIT, and inhibits RET autophosphorylation [101]. It was first utilized in the 1990s for treatment of BCR/ABL-positive leukemias. In anaplastic thyroid cancer cell lines (FRO and ARO), it caused growth inhibition, but did not inhibit growth in papillary thyroid cancer cell lines [102, 103]. Two small phase II trials of patients with MTC showed only a small percentage of subjects achieving a stable disease as their best tumor response [104, 105]. These patients were treated with 600 mg daily of imatinib. Over half of the patients were noted to have profound hypothyroidism and required significant increases in their need for thyroid hormone.

New agents are also on the horizon, particularly in RET-mutant MTC. Withaferin A (WA) is a novel compound which appears effective against MTC cell proliferation in

culture. WA inhibits both activation and phosphorylation of RET as well as total RET expression. The investigators recently published evidence of its efficacy in a murine model of MTC. Treatment with WA resulted in 80% regression of tumor volume in the treated animals with a corresponding significant decrease in calcitonin levels. Additionally, all the treated animals were alive at 6 weeks, while essentially all the control animals died by this point in time [106].

3.2. Agents Primarily Targeting Signaling Kinases. Pazopanib (Votrient, GlaxoSmithKline, GW786034) is a second-generation oral small molecule kinase inhibitor that targets VEGFR-1, 2, and 3, as well as alpha and beta PDGFR [107]. There is new data from studies of breast cancer indicating that it also targets multiple forms of Raf, though it likely does not affect the common BRAF V600E mutant [108]. It is approved for use in renal cell carcinoma and is likely effective in other forms of cancer including ovarian cancer, and nonsmall cell lung carcinoma [109–111].

A phase II study completed in early 2009 of thyroid cancer patients led by the Mayo Clinic demonstrated a confirmed partial response rate by RECIST criteria in 49% of enrolled subjects (18 patients). There were no complete responses [112]. Starting dose was 800 mg per day. Patients able to tolerate maximum doses of the medication significantly decreased their tumor size as compared to those patients unable to tolerate maximum doses of the agent. Although not statistically significant, the subset of patients with FTC attained a partial response more frequently than subjects with PTC. Forty-three percent (43%) required dose reductions, owing most frequently to fatigue, skin and hair hypopigmentation, diarrhea, and nausea. Nearly 66% of patients doubled their TSH concentrations. Also of note, three patients (8%) developed grade 3 lower gastrointestinal hemorrhage, which according to the authors is similar to the rate noted in trials with Sorafenib [112].

Motesanib (AMG706, Amgen) is an oral tyrosine-kinase inhibitor that inhibits autophosphorylation of RET and also targets VEGFR 1, 2, and 3, PDGFR, and c-KIT. It demonstrates both direct antitumor and antiangiogenic properties [113]. Phase 1 trials were encouraging with 3 DTC patients registering a partial response [114]. A subsequent phase II trial administering 125 mg/day to patients with DTC demonstrated a partial response in 14% of patients, while 35% of patients had stable disease after 48 weeks [115]. A separate arm of this study examined a cohort of patients with advanced, progressive, symptomatic, or metastatic MTC. In this MTC cohort, 2% of patients showed an objective response, 81% maintained stable disease, and an overall 76% of patients showed decrease in the size of their target lesions [116]. Motesanib was generally well tolerated in both cohorts with fatigue, nausea, diarrhea, and hypertension comprising the majority of adverse side effects. As a result of treatment with motesanib, greater than 60% of patients experienced a TSH elevation out of the desired therapeutic range at some time during the study [116]. A recent study of both DTC and MTC revealed that a decrease in soluble VEGFR-2 and a concurrent increase in placental growth factor (PlGF) during the course of treatment with motesanib predicted which patients would respond to treatment with this agent [117].

Axitinib (AG-013736) inhibits VEGFR more specifically than the agents discussed above. A phase I study included patients with thyroid cancer though none demonstrated partial responses [118]. A phase II study using a dose of 5 mg orally two times per day noted partial responses in 31% of the patients with DTC and in 18% of the patients with MTC. Side effects included fatigue, stomatitis, and hypertension [119]. Further trials are ongoing.

XL 184 (BMS-907351) inhibits VEGF 1 and 2, C-MET, RET, c-kit, fms-related tyrosine kinase 3 (FLT3), and TIE-2. A unique aspect of this agent is its activity against hepatocyte growth factor (HGF) and C-MET, both of which are overexpressed in PTC [120]. A phase 1 trial was promising; 55% of 36 patients MTC demonstrated a partial response, and 84% overall had stable disease [121]. Interestingly, patients both with and without RET mutations responded. A phase III trial exploring XL 184 in MTC is currently underway.

Other recently evaluated novel agents include pyrazolopyrimidine derivatives like CLM3 and CLM29, which also appear to be widely effective against cytoplasmic and receptor ATP competitive tyrosine kinases including RET, EGFR, VEGFR, and angiogenesis pathways. These agents are unique because they induce apoptosis and decrease tumor volume in murine models of dedifferentiated PTC, irrespective of BRAFV600E mutation [122].

4. Conclusion

Recent increased incidence of thyroid cancer is associated with a rise in the number of patients with metastatic disease and tumors that are resistant to the effect of radioiodine. Presently, there are no consensus guidelines about safe and effective methods to treat advanced-stage thyroid cancers. However, the recent elucidation of the pathogenesis of thyroid cancer has facilitated the development of new targeted agents intended to have activity against specific biochemical and oncologic pathways. Many of these newer agents being developed and tested are kinase inhibitors that show a promise for improved treatment of advanced DTC, as well as MTC.

In general, options for the chemotherapeutic treatment of advanced-stage thyroid cancers remain limited. The most promising agents display activity against VEGFR, including pazopanib, motesanib, sorafenib, sunitinib, and vandetanib. There is structural similarity between VEGFR and RET kinases, and cross-activity likely occurs perhaps increasing the efficacy of these agents. Interestingly, axitinib (a tyrosine kinase inhibitor that more specifically targets VEGFR) garnered similar promising tumor responses to the above noted multitargeted kinase inhibitors [119]. In addition, the effective targeted kinase inhibitors not only demonstrate specific activity against VEGFR, but also exhibit activity against a wide array of cellular pathways.

Perhaps owing to their wide ranging cellular targets, there are also numerous concerning side effects of these multitargeted kinase inhibitors. Several trials of the above listed agents reported a significant percentage of patients

requiring a dose reduction during the study period for general tolerability. The most concerning adverse effects are increases in the incidence of cardiomyopathy and associated hypertension and stroke. Additionally, minor-to-severe bleeding (often in the form of gastrointestinal bleeding) should not be overlooked. Trials of motesanib and sunitinib noted increasing TSH values during the course of treatment, placing patients at risk for being on subtherapeutic doses of suppressive thyroid hormone for a period of time.

Other targeted kinase agents have been shown less effective than previously hoped. Imatinib does not appear to be a candidate for further study in MTC, nor does gefitinib which was not discussed in detail because a phase II trial did not demonstrate any partial responses [123]. Agents specifically targeting the BRAF pathway and BRAF V600E are in earlier stages of clinical trials; however, stable disease appears to be the best response achieved in this class of agents, including PLX4032 as well as XL281. The more specific BRAF inhibitors also have concerning side effects, including an increased incidence of squamous cell neoplasms.

Overall, options for targeted therapy of patients with advanced thyroid cancer remain limited. While these agents may improve radiographic tumor response, change in survival is unclear. Most trials have demonstrated that only small percentages of patients achieved partial responses. There has been a lack of complete responses [124]. Current expert opinion advises that these agents be used only in a specific subset of patients. They should be administered only to patients with rapidly progressive radioiodine refractory metastatic disease. Locally recurrent, unresectable cancer which is unresponsive to radiation may also be considered appropriate for treatment [125].

Other lines of research must be pursued including immunotherapy with vaccines and interferon administration, as well as efforts to induce redifferentiation of tumor cells to take up radioiodine with histone deacetylase inhibitors Romidepsin and Vorinostat, for example [126–131]. Another area that warrants further investigation is the exploration of biomarkers that may be able to predict response to a given agent, which may help tailor treatment to an individual. Additionally, both *in vivo* and *in vitro* chemosensitivity testing is becoming more common, and is currently available in several clinical trials. These tests appear to be most useful in terms of negative predictability, meaning a treatment is very likely to be unsuccessful in vivo if it is unsuccessful in vitro. Unfortunately the positive predictability of such tests is not as robust. There are many diverse challenges to be addressed before chemosensitivity becomes routine [122, 132]. Promising new studies are being performed investigating combinations of tyrosine kinase inhibitors with other conventional modalities of treatment, like radiation [133]. Much new data is required before such agents are offered routinely for the treatment of advanced or dedifferentiated thyroid cancer.

Conflict of Interests

The authors declare that there is no conflict of interests.

References

[1] "Surveillance, Epidemiology, and End Results (S.E.E.R. Program)," Generate custom reports from the cancer statistics review, Seer 9: 1975–2007, December 2010, http://seer.cancer.gov/.

[2] M. J. Schlumberger, "Papillary and follicular thyroid carcinoma," *New England Journal of Medicine*, vol. 338, no. 5, pp. 297–306, 1998.

[3] M. R. Castro, E. R. Bergert, J. R. Goellner, I. D. Hay, and J. C. Morris, "Immunohistochemical analysis of sodium iodide symporter expression in metastatic differentiated thyroid cancer: correlation with radioiodine uptake," *Journal of Clinical Endocrinology and Metabolism*, vol. 86, no. 11, pp. 5627–5632, 2001.

[4] L. S. Ward, P. L. Santarosa, F. Granja, L. V. M. Da Assumpção, M. Savoldi, and G. H. Goldman, "Low expression of sodium iodide symporter identifies aggressive thyroid tumors," *Cancer Letters*, vol. 200, no. 1, pp. 85–91, 2003.

[5] J. A. Fagin, "How thyroid tumors start and why it matters: kinase mutants as targets for solid cancer pharmacotherapy," *Journal of Endocrinology*, vol. 183, no. 2, pp. 249–256, 2004.

[6] C. Scollo, E. Baudin, J. P. Travagli et al., "Rationale for central and bilateral lymph node dissection in sporadic and hereditary medullary thyroid cancer," *Journal of Clinical Endocrinology and Metabolism*, vol. 88, no. 5, pp. 2070–2075, 2003.

[7] S. I. Sherman, "Cytotoxic chemotherapy for differentiated thyroid carcinoma," *Clinical Oncology*, vol. 22, no. 6, pp. 464–468, 2010.

[8] M. Xing, "BRAF mutation in thyroid cancer," *Endocrine-Related Cancer*, vol. 12, no. 2, pp. 245–262, 2005.

[9] G. Salvatore, V. De Falco, P. Salerno et al., "BRAF is a therapeutic target in aggressive thyroid carcinoma," *Clinical Cancer Research*, vol. 12, no. 5, pp. 1623–1629, 2006.

[10] B. Ouyang, J. A. Knauf, E. P. Smith et al., "Inhibitors of Raf kinase activity block growth of thyroid cancer cells with RET/PTC or BRAF mutations in vitro and in vivo," *Clinical Cancer Research*, vol. 12, no. 6, pp. 1785–1793, 2006.

[11] P. Hou, E. Bojdani, and M. Xing, "Induction of thyroid gene expression and radioiodine uptake in thyroid cancer cells by targeting major signaling pathways," *Journal of Clinical Endocrinology and Metabolism*, vol. 95, no. 2, pp. 820–828, 2010.

[12] D. J. Lim, K. H. Baek, Y. S. Lee et al., "Clinical, histopathological, and molecular characteristics of papillary thyroid microcarcinoma," *Thyroid*, vol. 17, no. 9, pp. 883–888, 2007.

[13] E. T. Kimura, M. N. Nikiforova, Z. Zhu, J. A. Knauf, Y. E. Nikiforov, and J. A. Fagin, "High prevalence of BRAF mutations in thyroid cancer: genetic evidence for constitutive activation of the RET/PTC-RAS-BRAF signaling pathway in papillary thyroid carcinoma," *Cancer Research*, vol. 63, no. 7, pp. 1454–1457, 2003.

[14] P. T. C. Wan, M. J. Garnett, S. M. Roe et al., "Mechanism of activation of the RAF-ERK signaling pathway by oncogenic mutations of B-RAF," *Cell*, vol. 116, no. 6, pp. 855–867, 2004.

[15] P. Hou, D. Liu, Y. Shan et al., "Genetic alterations and their relationship in the phosphatidylinositol 3-kinase/Akt pathway in thyroid cancer," *Clinical Cancer Research*, vol. 13, no. 4, pp. 1161–1170, 2007.

[16] M. Santoro, N. A. Dathan, M. T. Berlingieri et al., "Molecular characterization of RET/PTC3; a novel rearranged version of the RETproto-oncogene in a human thyroid papillary carcinoma," *Oncogene*, vol. 9, no. 2, pp. 509–516, 1994.

[17] Y. E. Nikiforov, J. M. Rowland, K. E. Bove, H. Monforte-Munoz, and J. A. Fagin, "Distinct pattern of ret oncogene rearrangements in morphological variants of radiation-induced and sporadic thyroid papillary carcinomas in children," *Cancer Research*, vol. 57, no. 9, pp. 1690–1694, 1997.

[18] G. Tallini, M. Santoro, M. Helie et al., "RET/PTC oncogene activation defines a subset of papillary thyroid carcinomas lacking evidence of progression to poorly differentiated or undifferentiated tumor phenotypes," *Clinical Cancer Research*, vol. 4, no. 2, pp. 287–294, 1998.

[19] M. D. Ringel, N. Hayre, J. Saito et al., "Overexpression and overactivation of Akt in thyroid carcinoma," *Cancer Research*, vol. 61, no. 16, pp. 6105–6111, 2001.

[20] H. Sun, R. Lesche, D. M. Li et al., "PTEN modulates cell cycle progression and cell survival by regulating phosphatidylinositol 3,4,5,-trisphosphate and Akt/protein kinase B signaling pathway," *Proceedings of the National Academy of Sciences of the United States of America*, vol. 96, no. 11, pp. 6199–6204, 1999.

[21] R. Ciampi and Y. E. Nikiforov, "Minireview: RET/PTC rearrangements and braf mutations in thyroid tumorigenesis," *Endocrinology*, vol. 148, no. 3, pp. 936–941, 2007.

[22] Y. Cohen, M. Xing, E. Mambo et al., "BRAF mutation in papillary thyroid carcinoma," *Journal of the National Cancer Institute*, vol. 95, no. 8, pp. 625–627, 2003.

[23] E. Puxeddu, S. Moretti, R. Elisei et al., "BRAFV599E mutation is the leading genetic event in adult sporadic papillary thyroid carcinomas," *Journal of Clinical Endocrinology and Metabolism*, vol. 89, no. 5, pp. 2414–2420, 2004.

[24] R. Elisei, C. Ugolini, D. Viola et al., "BRAFV600E mutation and outcome of patients with papillary thyroid carcinoma: a 15-year median follow-up study," *Journal of Clinical Endocrinology and Metabolism*, vol. 93, no. 10, pp. 3943–3949, 2008.

[25] A. M. Costa, A. Herrero, M. F. Fresno et al., "BRAF mutation associated with other genetic events identifies a subset of aggressive papillary thyroid carcinoma," *Clinical Endocrinology*, vol. 68, no. 4, pp. 618–634, 2008.

[26] H. Davies, G. R. Bignell, C. Cox et al., "Mutations of the BRAF gene in human cancer," *Nature*, vol. 417, no. 6892, pp. 949–954, 2002.

[27] T. Brummer, H. Naegele, M. Reth, and Y. Misawa, "Identification of novel ERK-mediated feedback phosphorylation sites at the C-terminus of B-Raf," *Oncogene*, vol. 22, no. 55, pp. 8823–8834, 2003.

[28] R. Ciampi, J. A. Knauf, R. Kerler et al., "Oncogenic AKAP9-BRAF fusion is a novel mechanism of MAPK pathway activation in thyroid cancer," *Journal of Clinical Investigation*, vol. 115, no. 1, pp. 94–101, 2005.

[29] M. N. Nikiforova, R. Ciampi, G. Salvatore et al., "Low prevalence of BRAF mutations in radiation-induced thyroid tumors in contrast to sporadic papillary carcinomas," *Cancer Letters*, vol. 209, no. 1, pp. 1–6, 2004.

[30] B. J. Collins, A. B. Schneider, R. A. Prinz, and X. Xu, "Low frequency of BRAF mutations in adult patients with papillary thyroid cancers following childhood radiation exposure," *Thyroid*, vol. 16, no. 1, pp. 61–66, 2006.

[31] M. Xing, W. H. Westra, R. P. Tufano et al., "BRAF mutation predicts a poorer clinical prognosis for papillary thyroid cancer," *Journal of Clinical Endocrinology and Metabolism*, vol. 90, no. 12, pp. 6373–6379, 2005.

[32] M. N. Nikiforova, E. T. Kimura, M. Gandhi et al., "BRAF mutations in thyroid tumors are restricted to papillary carcinomas and anaplastic or poorly differentiated carcinomas arising from papillary carcinomas," *Journal of Clinical Endocrinology and Metabolism*, vol. 88, no. 11, pp. 5399–5404, 2003.

[33] A. J. Adeniran, Z. Zhu, M. Gandhi et al., "Correlation between genetic alterations and microscopic features, clinical manifestations, and prognostic characteristics of thyroid papillary carcinomas," *American Journal of Surgical Pathology*, vol. 30, no. 2, pp. 216–222, 2006.

[34] I. Sedliarou, V. Saenko, D. Lantsov et al., "The BRAFT1796A transversion is a prevalent mutational event in human thyroid microcarcinoma," *International journal of oncology*, vol. 25, no. 6, pp. 1729–1735, 2004.

[35] X. Lee, M. Gao, Y. Ji et al., "Analysis of differential BRAFV600E mutational status in high aggressive papillary thyroid microcarcinoma," *Annals of Surgical Oncology*, vol. 16, no. 2, pp. 240–245, 2009.

[36] M. Frattini, C. Ferrario, P. Bressan et al., "Alternative mutations of BRAF, RET and NTRK1 are associated with similar but distinct gene expression patterns in papillary thyroid cancer," *Oncogene*, vol. 23, no. 44, pp. 7436–7440, 2004.

[37] P. Soares, V. Trovisco, A. S. Rocha et al., "BRAF mutations and RET/PTC rearrangements are alternative events in the etiopathogenesis of PTC," *Oncogene*, vol. 22, no. 29, pp. 4578–4580, 2003.

[38] R. M. Quiros, H. G. Ding, P. Gattuso, R. A. Prinz, and X. Xu, "Evidence that one subset of anaplastic thyroid carcinomas are derived from papillary carcinomas due to BRAF and p53 mutations," *Cancer*, vol. 103, no. 11, pp. 2261–2268, 2005.

[39] C. Durante, E. Puxeddu, E. Ferretti et al., "Brief report: BRAF mutations in papillary thyroid carcinomas inhibit genes involved in iodine metabolism," *Journal of Clinical Endocrinology and Metabolism*, vol. 92, no. 7, pp. 2840–2843, 2007.

[40] D. Liu, S. Hu, P. Hou, D. Jiang, S. Condouris, and M. Xing, "Suppression of BRAF/MEK/MAP kinase pathway restores expression of iodide-metabolizing genes in thyroid cells expressing the V600E BRAF mutant," *Clinical Cancer Research*, vol. 13, no. 4, pp. 1341–1349, 2007.

[41] G. Riesco-Eizaguirre, I. Rodríguez, A. De La Vieja et al., "The BRAFV600E oncogene induces transforming growth factor β secretion leading to sodium iodide symporter repression and increased malignancy in thyroid cancer," *Cancer Research*, vol. 69, no. 21, pp. 8317–8325, 2009.

[42] J. A. Fagin, K. Matsuo, A. Karmakar, Dan Lin Chen, S. H. Tang, and H. P. Koeffler, "High prevalence of mutations of the p53 gene in poorly differentiated human thyroid carcinomas," *Journal of Clinical Investigation*, vol. 91, no. 1, pp. 179–184, 1993.

[43] L. Ludwig, H. Kessler, M. Wagner et al., "Nuclear factor-κB is constitutively active in C-cell carcinoma and required for RET-induced transformation," *Cancer Research*, vol. 61, no. 11, pp. 4526–4535, 2001.

[44] A. Bounacer, R. Wicker, B. Caillou et al., "High prevalence of activating ret proto-oncogene rearrangements, in thyroid tumors from patients who had received external radiation," *Oncogene*, vol. 15, no. 11, pp. 1263–1273, 1997.

[45] C. L. Fenton, Y. Lukes, D. Nicholson, C. A. Dinauer, G. L. Francis, and R. M. Tuttle, "The ret/PTC mutations are common in sporadic papillary thyroid carcinoma of children and young adults," *Journal of Clinical Endocrinology and Metabolism*, vol. 85, no. 3, pp. 1170–1175, 2000.

[46] T. Mizuno, K. S. Iwamoto, S. Kyoizumi et al., "Preferential induction of RET/PTC1 rearrangement by X-ray irradiation," *Oncogene*, vol. 19, no. 3, pp. 438–443, 2000.

[47] A. Wirtschafter, R. Schmidt, D. Rosen et al., "Expression of the RET/PTC fusion gene as a marker for papillary carcinoma in Hashimoto's thyroiditis," *Laryngoscope*, vol. 107, no. 1, pp. 95–100, 1997.

[48] O. M. Sheils, J. J. O'Leary, V. Uhlmann, K. Lüttich, and E. C. Sweeney, "ret/PTC-1 activation in Hashimoto thyroiditis," *International Journal of Surgical Pathology*, vol. 8, no. 3, pp. 185–189, 2000.

[49] M. N. Nikiforova, C. M. Caudill, P. Biddinger, and Y. E. Nikiforov, "Prevalence of RET/PTC rearrangements in Hashimoto's thyroiditis and papillary thyroid carcinomas," *International Journal of Surgical Pathology*, vol. 10, no. 1, pp. 15–22, 2002.

[50] N. Ferrara and R. S. Kerbel, "Angiogenesis as a therapeutic target," *Nature*, vol. 438, no. 7070, pp. 967–974, 2005.

[51] M. Klein, J. M. Vignaud, V. Hennequin et al., "Increased expression of the vascular endothelial growth factor is a pejorative prognosis marker in papillary thyroid carcinoma," *Journal of Clinical Endocrinology and Metabolism*, vol. 86, no. 2, pp. 656–658, 2001.

[52] C. M. Lennard, A. Patel, J. Wilson et al., "Intensity of vascular endothelial growth factor expression is associated with increased risk of recurrence and decreased disease-free survival in papillary thyroid cancer," *Surgery*, vol. 129, no. 5, pp. 552–558, 2001.

[53] A. K. Ghosh, I. Grigorieva, R. Steele, R. G. Hoover, and R. B. Ray, "PTEN transcriptionally modulates c-myc gene expression in human breast carcinoma cells and is involved in cell growth regulation," *Gene*, vol. 235, no. 1-2, pp. 85–91, 1999.

[54] M. Tamura, J. Gu, E. H. J. Danen, T. Takino, S. Miyamoto, and K. M. Yamada, "PTEN interactions with focal adhesion kinase and suppression of the extracellular matrix-dependent phosphatidylinositol 3-kinase/Akt cell survival pathway," *Journal of Biological Chemistry*, vol. 274, no. 29, pp. 20693–20703, 1999.

[55] P. A. Steck, M. A. Pershouse, S. A. Jasser et al., "Identification of a candidate tumour suppressor gene, MMAC1, at chromosome 10q23.3 that is mutated in multiple advanced cancers," *Nature Genetics*, vol. 15, no. 4, pp. 356–362, 1997.

[56] D. S. Byun, K. Cho, B. K. Ryu et al., "Frequent monoallelic deletion of PTEN and its reciprocal associatioin with PIK3CA amplification in gastric carcinoma," *International Journal of Cancer*, vol. 104, no. 3, pp. 318–327, 2003.

[57] T. Kimura, A. Suzuki, Y. Fujita et al., "Conditional loss of PTEN leads to testicular teratoma and enhances embryonic germ cell production," *Development*, vol. 130, no. 8, pp. 1691–1700, 2003.

[58] S. Wang, A. J. Garcia, M. Wu, D. A. Lawson, O. N. Witte, and H. Wu, "Pten deletion leads to the expansion of a prostatic stem/progenitor cell subpopulation and tumor initiation," *Proceedings of the National Academy of Sciences of the United States of America*, vol. 103, no. 5, pp. 1480–1485, 2006.

[59] A. Yokomizo, D. J. Tindall, L. Hartmann, R. B. Jenkins, D. I. Smith, and W. Liu, "Mutation analysis of the putative tumor suppressor PTEN/MMAC1 in human ovarian cancer," *International Journal of Oncology*, vol. 13, no. 1, pp. 101–105, 1998.

[60] M. E. McMenamin, P. Soung, S. Perera, I. Kaplan, M. Loda, and W. R. Sellers, "Loss of PTEN expression in paraffin-embedded primary prostate cancer correlates with high Gleason score and advanced stage," *Cancer Research*, vol. 59, no. 17, pp. 4291–4296, 1999.

[61] P. Hou, M. Ji, and M. Xing, "Association of PTEN gene methylation with genetic alterations in the phosphatidylinositol 3-kinase/AKT signaling pathway in thyroid tumors," *Cancer*, vol. 113, no. 9, pp. 2440–2447, 2008.

[62] P. Hou, D. Liu, Y. Shan et al., "Genetic alterations and their relationship in the phosphatidylinositol 3-kinase/Akt pathway in thyroid cancer," *Clinical Cancer Research*, vol. 13, no. 4, pp. 1161–1170, 2007.

[63] S. M. Wilhelm, C. Carter, L. Tang et al., "BAY 43-9006 exhibits broad spectrum oral antitumor activity and targets the RAF/MEK/ERK pathway and receptor tyrosine kinases involved in tumor progression and angiogenesis," *Cancer Research*, vol. 64, no. 19, pp. 7099–7109, 2004.

[64] Y. C. Henderson, S. H. Ann, Y. Kang, and G. L. Clayman, "Sorafenib potently inhibits papillary thyroid carcinomas harboring RET/PTC1 rearrangement," *Clinical Cancer Research*, vol. 14, no. 15, pp. 4908–4914, 2008.

[65] D. Strumberg, J. W. Clark, A. Awada et al., "Safety, pharmacokinetics, and preliminary antitumor activity of sorafenib: a review of four phase I trials in patients with advanced refractory solid tumors," *Oncologist*, vol. 12, no. 4, pp. 426–437, 2007.

[66] V. Gupta-Abramson, A. B. Troxel, A. Nellore et al., "Phase II trial of sorafenib in advanced thyroid cancer," *Journal of Clinical Oncology*, vol. 26, no. 29, pp. 4714–4719, 2008.

[67] R. T. Kloos, M. D. Ringel, M. V. Knopp et al., "Phase II trial of sorafenib in metastatic thyroid cancer," *Journal of Clinical Oncology*, vol. 27, no. 10, pp. 1675–1684, 2009.

[68] H. Hoftijzer, K. A. Heemstra, H. Morreau et al., "Beneficial effects of sorafenib on tumor progression, but not on radioiodine uptake, in patients with differentiated thyroid carcinoma," *European Journal of Endocrinology*, vol. 161, no. 6, pp. 923–931, 2009.

[69] M. E. Cabanillas, S. G. Waguespack, Y. Bronstein et al., "Treatment with tyrosine kinase inhibitors for patients with differentiated thyroid cancer: the M. D. Anderson experience," *Journal of Clinical Endocrinology and Metabolism*, vol. 95, no. 6, pp. 2588–2595, 2010.

[70] E. T. Lam, M. D. Ringel, R. T. Kloos et al., "Phase II clinical trial of sorafenib in metastatic medullary thyroid cancer," *Journal of Clinical Oncology*, vol. 28, no. 14, pp. 2323–2330, 2010.

[71] M. Schmidinger, C. C. Zielinski, U. M. Vogl et al., "Cardiac toxicity of sunitinib and sorafenib in patients with metastatic renal cell carcinoma," *Journal of Clinical Oncology*, vol. 26, no. 32, pp. 5204–5212, 2008.

[72] Y. Arima, S. Oshima, K. Noda et al., "Sorafenib-induced acute myocardial infarction due to coronary artery spasm," *Journal of Cardiology*, vol. 54, no. 3, pp. 512–515, 2009.

[73] J. P. Arnault, J. Wechsler, B. Escudier et al., "Keratoacanthomas and squamous cell carcinomas in patients receiving sorafenib," *Journal of Clinical Oncology*, vol. 27, no. 23, pp. e59–e61, 2009.

[74] G. Bollag, P. Hirth, J. Tsai et al., "Clinical efficacy of a RAF inhibitor needs broad target blockade in BRAF-mutant melanoma," *Nature*, vol. 467, no. 7315, pp. 596–599, 2010.

[75] E. W. Joseph, C. A. Pratilas, P. I. Poulikakos et al., "The RAF inhibitor PLX4032 inhibits ERK signaling and tumor cell proliferation in a V600E BRAF-selective manner," *Proceedings of the National Academy of Sciences of the United States of America*, vol. 107, no. 33, pp. 14903–14908, 2010.

[76] P. Salerno, V. De Falco, A. Tamburrino et al., "Cytostatic activity of adenosine triphosphate-competitive kinase inhibitors in BRAF mutant thyroid carcinoma cells," *Journal of Clinical Endocrinology and Metabolism*, vol. 95, no. 1, pp. 450–455, 2010.

[77] E. Sala, L. Mologni, S. Truffa, C. Gaetano, G. E. Bollag, and C. Gambacorti-Passerini, "BRAF silencing by short hairpin RNA or chemical blockade by PLX4032 leads to different responses in melanoma and thyroid carcinoma cells," *Molecular Cancer Research*, vol. 6, no. 5, pp. 751–759, 2008.

[78] J. N. Søndergaard, R. Nazarian, Q. Wang et al., "Differential sensitivity of melanoma cell lines with BRAFV600Emutation to the specific Raf inhibitor PLX4032," *Journal of Translational Medicine*, vol. 8, article 39, 2010.

[79] K. T. Flaherty, I. Puzanov, K. B. Kim et al., "Inhibition of mutated, activated BRAF in metastatic melanoma," *New England Journal of Medicine*, vol. 363, no. 9, pp. 809–819, 2010.

[80] G. K. Schwartz, S. Robertson, A. Shen et al., "A Phase I study of XL281, a selective oral RAF kinase inhibitor, in patients with advanced solid tumors," *Journal of Clinical Oncology*, vol. 27, no. 15s, abstract 3513, 2009.

[81] D. W. Kim, Y. S. Jo, H. S. Jung et al., "An orally administered multitarget tyrosine kinase inhibitor, SU11248, is a novel potent inhibitor of thyroid oncogenic RET/papillary thyroid cancer kinases," *Journal of Clinical Endocrinology and Metabolism*, vol. 91, no. 10, pp. 4070–4076, 2006.

[82] E. E. W. Cohen, B. M. Needles, K. J. Cullen et al., "Phase II study of sunitinib in refractory thyroid cancer," *Journal of Clinical Oncology*, vol. 26, abstract 6025, 2008.

[83] M. J. Bugalho, R. Domingues, and A. Borges, "A case of advanced medullary thyroid carcinoma successfully treated with sunitinib," *Oncologist*, vol. 14, no. 11, pp. 1083–1087, 2009.

[84] D. Mannavola, P. Coco, G. Vannucchi et al., "A novel tyrosine-kinase selective inhibitor, sunitinib, induces transient hypothyroidism by blocking iodine uptake," *Journal of Clinical Endocrinology and Metabolism*, vol. 92, no. 9, pp. 3531–3534, 2007.

[85] E. Wong, L. S. Rosen, M. Mulay et al., "Sunitinib induces hypothyroidism in advanced cancer patients and may inhibit thyroid peroxidase activity," *Thyroid*, vol. 17, no. 4, pp. 351–355, 2007.

[86] M. B. Bass, S. I. Sherman, M. J. Schlumberger et al., "Biomarkers as predictors of response to treatment with motesanib in patients with progressive advanced thyroid cancer," *Journal of Clinical Endocrinology and Metabolism*, vol. 95, no. 11, pp. 5018–5027, 2010.

[87] V. Baldazzi, R. Tassi, A. Lapini, C. Santomaggio, M. Carini, and R. Mazzanti, "The impact of sunitinib-induced hypothyroidism on progression-free survival of metastatic renal cancer patients: a prospective single-center study," *Urologic Oncology: Seminars and Original Investigations*. In press.

[88] M. Schmidinger, U. M. Vogl, M. Bojic et al., "Hypothyroidism in patients with renal cell carcinoma: blessing or curse?" *Cancer*, vol. 117, no. 3, pp. 534–544, 2011.

[89] T. F. Chu, M. A. Rupnick, R. Kerkela et al., "Cardiotoxicity associated with tyrosine kinase inhibitor sunitinib," *Lancet*, vol. 370, no. 9604, pp. 2011–2019, 2007.

[90] B. B. Hasinoff and D. Patel, "The lack of target specificity of small molecule anticancer kinase inhibitors is correlated with their ability to damage myocytes in vitro," *Toxicology and Applied Pharmacology*, vol. 249, no. 2, pp. 132–139, 2010.

[91] M. H. Chen, R. Kerkelä, and T. Force, "Mechanisms of cardiac dysfunction associated with tyrosine kinase inhibitor cancer therapeutics," *Circulation*, vol. 118, no. 1, pp. 84–95, 2008.

[92] S. R. Wedge, D. J. Ogilvie, M. Dukes et al., "ZD6474 inhibits vascular endothelial growth factor signaling, angiogenesis, and tumor growth following oral administration," *Cancer Research*, vol. 62, no. 16, pp. 4645–4655, 2002.

[93] F. Ciardiello, R. Caputo, V. Damiano et al., "Antitumor effects of ZD6474, a small molecule vascular endothelial growth factor receptor tyrosine kinase inhibitor, with additional activity against epidermal growth factor receptor tyrosine kinase," *Clinical Cancer Research*, vol. 9, no. 4, pp. 1546–1556, 2003.

[94] R. S. Herbst, J. V. Heymach, M. S. O'Reilly, A. Onn, and A. J. Ryan, "Vandetanib (ZD6474): an orally available receptor tyrosine kinase inhibitor that selectively targets pathways critical for tumor growth and angiogenesis," *Expert Opinion on Investigational Drugs*, vol. 16, no. 2, pp. 239–249, 2007.

[95] F. Carlomagno, D. Vitagliano, T. Guida et al., "ZD6474, an orally available inhibitor of KDR tyrosine kinase activity, efficiently blocks oncogenic RET kinases," *Cancer Research*, vol. 62, no. 24, pp. 7284–7290, 2002.

[96] D. Vitagliano, V. De Falco, A. Tamburrino et al., "The tyrosine kinase inhibitor ZD6474 blocks proliferation of RET mutant medullary thyroid carcinoma cells," *Endocrine-Related Cancer*, vol. 18, no. 1, pp. 1–11, 2011.

[97] S. A. Wells Jr., J. E. Gosnell, R. F. Gagel et al., "Vandetanib for the treatment of patients with locally advanced or metastatic hereditary medullary thyroid cancer," *Journal of Clinical Oncology*, vol. 28, no. 5, pp. 767–772, 2010.

[98] "FDA Briefing Document Oncologic Drugs Advisory Committee Meeting," December 2010, http://www.fda.gov/downloads/AdvisoryCommittees/CommitteesMeetingMaterials/Drugs/OncologicDrugsAdvisoryCommittee/UCM235086.pdf.

[99] B. G. Robinson, L. Paz-Ares, A. Krebs, J. Vasselli, and R. Haddad, "Vandetanib (100 mg) in patients with locally advanced or metastatic hereditary medullary thyroid cancer," *Journal of Clinical Endocrinology and Metabolism*, vol. 95, no. 6, pp. 2664–2671, 2010.

[100] United States Food and Drug Administration Press Release, "FDA approves new treatment for rare form of thyroid cancer," April 2011, http://www.fda.gov/NewsEvents/Newsroom/PressAnnouncements/ucm250168.htm.

[101] M. Carroll, S. Ohno-Jones, S. Tamura et al., "CGP 57148, a tyrosine kinase inhibitor, inhibits the growth of cells expressing BCR-ABL, TEL-ABL, and TEL-PDGFR fusion proteins," *Blood*, vol. 90, no. 12, pp. 4947–4952, 1997.

[102] A. Podtcheko, A. Ohtsuru, S. Tsuda et al., "The selective tyrosine kinase inhibitor, STI571, inhibits growth of anaplastic thyroid cancer cells," *Journal of Clinical Endocrinology and Metabolism*, vol. 88, no. 4, pp. 1889–1896, 2003.

[103] J. M. Dziba and K. B. Ain, "Imatinib mesylate (Gleevec; STI571) monotherapy is ineffective in suppressing human anaplastic thyroid carcinoma cell growth in vitro," *Journal of Clinical Endocrinology and Metabolism*, vol. 89, no. 5, pp. 2127–2135, 2004.

[104] J. W. B. De Groot, B. A. Zonnenberg, P. Q. Van Ufford-Mannesse et al., "A phase II trial of imatinib therapy for metastatic medullary thyroid carcinoma," *Journal of Clinical Endocrinology and Metabolism*, vol. 92, no. 9, pp. 3466–3469, 2007.

[105] K. Frank-Raue, M. Fabel, S. Delorme, U. Haberkorn, and F. Raue, "Efficacy of imatinib mesylate in advanced medullary thyroid carcinoma," *European Journal of Endocrinology*, vol. 157, no. 2, pp. 215–220, 2007.

[106] A. K. Samadi, R. Mukerji, A. Shah, B. N. Timmermann, and M. S. Cohen, "A novel RET inhibitor with potent efficacy against medullary thyroid cancer in vivo," *Surgery*, vol. 148, no. 6, pp. 1228–1236, 2010.

[107] R. Kumar, V. B. Knick, S. K. Rudolph et al., "Pharmacokinetic-pharmacodynamic correlation from mouse to human with pazopanib, a multikinase angiogenesis inhibitor with potent antitumor and antiangiogenic activity," *Molecular Cancer Therapeutics*, vol. 6, no. 7, pp. 2012–2021, 2007.

[108] B. Gril, D. Palmieri, Y. Qian et al., "Pazopanib reveals a role for tumor cell B-Raf in the prevention of HER2+ breast cancer brain metastasis," *Clinical Cancer Research*, vol. 17, no. 1, pp. 142–153, 2011.

[109] M. Friedlander, K. C. Hancock, D. Rischin et al., "A Phase II, open-label study evaluating pazopanib in patients with recurrent ovarian cancer," *Gynecologic Oncology*, vol. 119, no. 1, pp. 32–37, 2010.

[110] N. Altorki, M. E. Lane, T. Bauer et al., "Phase II proof-of-concept study of pazopanib monotherapy in treatment-naive patients with stage I/II resectable non-small-cell lung cancer," *Journal of Clinical Oncology*, vol. 28, no. 19, pp. 3131–3137, 2010.

[111] J. E. Ward and W. M. Stadler, "Pazopanib in renal cell carcinoma," *Clinical Cancer Research*, vol. 16, no. 24, pp. 5923–5927, 2010.

[112] K. C. Bible, V. J. Suman, J. R. Molina et al., "Efficacy of pazopanib in progressive, radioiodine-refractory, metastatic differentiated thyroid cancers: results of a phase 2 consortium study," *The Lancet Oncology*, vol. 11, no. 10, pp. 962–972, 2010.

[113] A. Polverino, A. Coxon, C. Starnes et al., "AMG 706, an oral, multikinase inhibitor that selectively targets vascular endothelial growth factor, platelet-derived growth factor, and kit receptors, potently inhibits angiogenesis and induces regression in tumor xenografts," *Cancer Research*, vol. 66, no. 17, pp. 8715–8721, 2006.

[114] L. S. Rosen, R. Kurzrock, M. Mulay et al., "Safety, pharmacokinetics, and efficacy of AMG 706, an oral multikinase inhibitor, in patients with advanced solid tumors," *Journal of Clinical Oncology*, vol. 25, no. 17, pp. 2369–2376, 2007.

[115] S. I. Sherman, L. J. Wirth, J. P. Droz et al., "Motesanib diphosphate in progressive differentiated thyroid cancer," *New England Journal of Medicine*, vol. 359, no. 1, pp. 31–42, 2008.

[116] M. J. Schlumberger, R. Elisei, L. Bastholt et al., "Phase II study of safety and efficacy of motesanib in patients with progressive or symptomatic, advanced or metastatic medullary thyroid cancer," *Journal of Clinical Oncology*, vol. 27, no. 23, pp. 3794–3801, 2009.

[117] M. B. Bass, S. I. Sherman, M. J. Schlumberger et al., "Biomarkers as predictors of response to treatment with motesanib in patients with progressive advanced thyroid cancer," *Journal of Clinical Endocrinology and Metabolism*, vol. 95, no. 11, pp. 5018–5027, 2010.

[118] H. S. Rugo, R. S. Herbst, G. Liu et al., "Phase I trial of the oral antiangiogenesis agent AG-013736 in patients with advanced solid tumors: pharmacokinetic and clinical results," *Journal of Clinical Oncology*, vol. 23, no. 24, pp. 5474–5483, 2005.

[119] E. E. W. Cohen, L. S. Rosen, E. E. Vokes et al., "Axitinib is an active treatment for all histologic subtypes of advanced thyroid cancer: results from a phase II study," *Journal of Clinical Oncology*, vol. 26, no. 29, pp. 4708–4713, 2008.

[120] R. Mineo, A. Costantino, F. Frasca et al., "Activation of the Hepatocyte Growth Factor (HGF)-Met system in papillary thyroid cancer: biological effects of HGF in thyroid cancer cells depend on Met expression levels," *Endocrinology*, vol. 145, no. 9, pp. 4355–4365, 2004.

[121] R. Kurzrock, S. Sherman, D. Hong et al., "A Phase I study of XL184, a MET, VEGFR2, and RET kinase inhibitor, administered orally to patients with advanced malignancies, including a subgroup of patients with medullary thyroid carcinoma," in *the EORTC-NCI-AACR International Conference on Molecular Targets and Cancer Therapeutics*, Geneva, Switzerland, October 2008, poster number 379.

[122] A. Antonelli, G. Bocci, C. La Motta et al., "Novel pyrazolopyrimidine derivatives as tyrosine kinase inhibitors with antitumoral activity in vitro and in vivo in papillary dedifferentiated thyroid cancer," *Journal of Clinical Endocrinology and Metabolism*, vol. 96, no. 2, pp. E288–E296, 2011.

[123] N. A. Pennell, G. H. Daniels, R. I. Haddad et al., "A phase II study of gefitinib in patients with advanced thyroid cancer," *Thyroid*, vol. 18, no. 3, pp. 317–323, 2008.

[124] S. I. Sherman, "Targeted therapy of thyroid cancer," *Biochemical Pharmacology*, vol. 80, no. 5, pp. 592–601, 2010.

[125] J. A. Fagin, R. M. Tuttle, and D. G. Pfister, "Harvesting the low-hanging fruit: kinase inhibitors for therapy of advanced medullary and nonmedullary thyroid cancer," *Journal of Clinical Endocrinology and Metabolism*, vol. 95, no. 6, pp. 2621–2624, 2010.

[126] F. Furuya, H. Shimura, H. Suzuki et al., "Histone deacetylase inhibitors restore radioiodide uptake and retention in poorly differentiated and anaplastic thyroid cancer cells by expression of the sodium/iodide symporter thyroperoxidase and thyroglobulin," *Endocrinology*, vol. 145, no. 6, pp. 2865–2875, 2004.

[127] J. A. Woyach, R. T. Kloos, M. D. Ringel et al., "Lack of therapeutic effect of the histone deacetylase inhibitor vorinostat in patients with metastatic radioiodine-refractory thyroid carcinoma," *Journal of Clinical Endocrinology and Metabolism*, vol. 94, no. 1, pp. 164–170, 2009.

[128] F. Furuya, H. Shimura, H. Suzuki et al., "Histone deacetylase inhibitors restore radioiodide uptake and retention in poorly differentiated and anaplastic thyroid cancer cells by expression of the sodium/iodide symporter thyroperoxidase and thyroglobulin," *Endocrinology*, vol. 145, no. 6, pp. 2865–2875, 2004.

[129] P. Hou, E. Bojdani, and M. Xing, "Induction of thyroid gene expression and radioiodine uptake in thyroid cancer cells by targeting major signaling pathways," *Journal of Clinical Endocrinology and Metabolism*, vol. 95, no. 2, pp. 820–828, 2010.

[130] G. Vitale, P. Tagliaferri, M. Caraglia et al., "Slow release lanreotide in combination with interferon-α2b in the treatment of symptomatic advanced medullary thyroid carcinoma," *Journal of Clinical Endocrinology and Metabolism*, vol. 85, no. 3, pp. 983–988, 2000.

[131] T. Bachleitner-Hofmann, J. Friedl, M. Hassler et al., "Pilot trial of autologous dendritic cells loaded with tumor lysate(s) from allogeneic tumor cell lines in patients with metastatic medullary thyroid carcinoma," *Oncology Reports*, vol. 21, no. 6, pp. 1585–1592, 2009.

[132] R. D. Blumenthal and D. M. Goldenberg, "Methods and goals for the use of in vitro and in vivo chemosensitivity testing," *Molecular Biotechnology*, vol. 35, no. 2, pp. 185–197, 2007.

[133] T. J. Kruser, D. L. Wheeler, E. A. Armstrong et al., "Augmentation of radiation response by motesanib, a multikinase inhibitor that targets vascular endothelial growth factor receptors," *Clinical Cancer Research*, vol. 16, no. 14, pp. 3639–3647, 2010.

SAGE-Hindawi Access to Research
Journal of Thyroid Research
Volume 2011, Article ID 895470, 7 pages
doi:10.4061/2011/895470

Review Article

The Role of Epigenetic Alterations in Papillary Thyroid Carcinogenesis

Ogechukwu P. Eze,[1,2] Lee F. Starker,[1,2] and Tobias Carling[1,2,3]

[1] *Department of Surgery, Yale University School of Medicine, 333 Cedar Street, TMP202, Box 208062, New Haven, CT 06520-8062, USA*
[2] *Yale Endocrine Neoplasia Laboratory, Yale University School of Medicine, 333 Cedar Street, TMP202, Box 208062, New Haven, CT 06520-3206, USA*
[3] *The Cancer Genetics Program, Yale Cancer Center, Yale University School of Medicine, New Haven, CT 06520-8028, USA*

Correspondence should be addressed to Tobias Carling, tobias.carling@yale.edu

Received 14 January 2011; Accepted 4 April 2011

Academic Editor: Ana O. Hoff

Papillary thyroid carcinoma (PTC) accounts for over 80% of all thyroid malignancies. The molecular pathogenesis remains incompletely clarified although activation of the RET fusion oncogenes, and RAS and BRAF oncogenes, has been well characterized. Novel technologies using genome-wide approaches to study tumor genomes and epigenomes have provided great insights into tumor development. Growing evidence shows that acquired epigenetic abnormalities participate with genetic alterations to cause altered patterns of gene expression/function. It has been established beyond doubt that promoter cytosine methylation in CpG islands, and the subsequent gene silencing, is intimately involved in cancer development. These epigenetic events very likely contribute to significant variation in gene expression profiling, phenotypic features, and biologic characteristics seen in PTC. Hypermethylation of promoter regions has also been analyzed in PTC, and most studies have focused on individual genes or a small cohort of genes implicated in tumorigenesis.

1. Background

Thyroid carcinoma is the most common endocrine malignancy. Papillary thyroid cancer (PTC) accounts for over 90% of thyroid malignancies [1]. With improved diagnostic techniques, papillary thyroid carcinoma is identified much more frequently than in the past [2]. Currently, ways to preoperatively identify patients with invasive thyroid cancer include asymptomatic disease with concomitant vocal cord dysfunction or subglottic/tracheal mass, recurrent disease in the central compartment, symptomatic disease with voice changes, dyspnea, hemoptysis, or dysphagia, and finally documented invasive disease based on preoperative imaging [3]. More papillary thyroid cancers are diagnosed as microcarcinomas; therefore, molecular methods of detecting aggressive disease will aid in treatment planning.

The majority of genetic alterations in thyroid cancer exert their oncogenic actions at least partially through the activation of the MAP kinase/ERK pathway. Constitutive activation of the MAP kinase/ERK pathway leads to tumorigenesis by upregulating cell division and proliferation [4]. Activation of this pathway is a common and important mechanism in the genesis and progression of human cancers. When constitutively activated, the MAP kinase pathway leads to tumorigenesis [4]. Alterations of RET/PTC, BRAF, and RAS genes are linked to papillary thyroid tumorigenesis.

RET proto-oncogene encodes a cell membrane receptor tyrosine kinase. Ligands of the kinase are of the glial-cell line-derived neurotrophic factor (GDNF) family which cause the receptors to dimerize upon binding, leading to autophosphorylation of tyrosine residues and initiation of the MAP kinase/ERK pathway signaling cascade [5]. High expression of RET in parafollicular C-cells of the thyroid gland is consistent with its role in the development of neural crest-derived cell lineages. This high expression of RET does not normally occur in thyroid follicular cells;

however, RET activation in these cells occurs by fusion of the 3' tyrosine domain of RET to the 5' portion of constitutively expressed genes. The most common RET/PTC rearrangements seen in PTC are RET/PTC1 (fusion with H4 gene) and RET/PTC3 (fusion with NCOA4 gene). Prevalence of RET/PTC rearrangements in PTC is greatest in populations exposed to radiation (60–70%). In the general population, the prevalence is higher in children [6]. Activation of RET/PTC results in downregulation of thyroglobulin and sodium iodide importer genes, which are thyroid specific, and thyroid follicular cell differentiation. Wild-type and truncated forms of RET/PTC activate the PI3K/AKT pathway leading to tumorigenesis [6, 7].

Mutations of BRAF, a serine-threonine kinase and downstream signaling molecule of RAS and RET, are potent activators of the MAP kinase/ERK pathway [4, 8]. These missense mutations of the BRAF gene, located on chromosome 7, occur in the kinase domain with the T1799A transversion mutation that results in a single amino acid substitution of valine to glutamic acid (V600E) accounting for 80–90% of BRAF activating mutations [6, 9]. The V600E mutation is thought to mimic phosphorylation in the activation segment of BRAF by inserting a negatively charged residue adjacent to an activating phosphorylation site [4].

BRAF V600E occurs as a sporadic mutation in thyroid cancer [9, 10] and is restricted to papillary and anaplastic or poorly differentiated carcinomas [11]. Prevalence of the mutation is reported in papillary thyroid cancer at 35–40%, with a significantly higher prevalence in males than females [9]. The rate of BRAF mutation in PTC is the second highest to that in melanomas (60%) and is much higher than other cancers such as colorectal adenocarcinomas (5–10%) and lung cancers (1.8%) [9]. BRAF V600E correlates with poorer clinicopathologic outcomes defined as extrathyroidal extension, lymph node metastasis, and advanced tumor grade (III/IV) at presentation and is prognostic of tumor recurrence [12–15].

Activating mutations of the three RAS oncogenes (H-RAS, K-RAS, and N-RAS) occur in thyroid tumors; however, their prevalence depending on histology of the tumors has been controversial [16]. Early studies demonstrated that RAS mutations were more frequent in follicular tumors than papillary thyroid cancers, in addition to different patterns of mutations occurring in the two types. Indeed, mutations in up to 50% on microfollicular adenoma further supported the idea that RAS oncogene activation was an early event in follicular thyroid tumorigenesis. More recent studies have reported varying incidences of RAS mutations in thyroid tumors (0–50% in PTC, 0–85% in adenomas, 14–62% in FTC, and 0–60% in anaplastic carcinomas). Some investigators find no correlation between RAS mutation isoforms and tumor pathology, while others report a higher frequency of mutations in codon61 of H-RAS and N-RAS in FTC and poorly differentiated carcinomas.

Although not confirmed by similar studies [10], 38% of BRAF-positive papillary thyroid tumors showed RET/PTC rearrangement [9], contrary to reports that BRAF V600E mutation does not occur with RET/PTC or RAS mutations in cancer [10]. Concurrent RET/PTC and BRAF mutations has also recently been reported in papillary thyroid cancer [17]. The low oncogenic potential of both BRAF and RET/PTC1 suggest that both mutations occurring in the same pathway are not necessarily redundant but may cooperate in papillary thyroid tumorigenesis. Indeed, RET/PTC1 and RAS mutations have been shown to synergistically lead to tumorigenesis [9].

The molecular pathogenesis of PTC thus remains incompletely clarified. With respect to gene alterations, papillary thyroid cancers have relatively low rates of loss of heterozygosity, with no specific region displaying a particularly high prevalence when compared to follicular thyroid cancers [18]. Like RET, BRAF, or RAS mutations, other molecular alterations are thought to be essential for the induction of papillary thyroid cancer. Epigenetic events very likely contribute to significant variation in gene expression profiling, phenotypical features, and biologic characteristics seen among papillary thyroid carcinoma [19].

2. Epigenetics Mechanisms Involved in Tumorigenesis

Epigenetic silencing of regulatory genes is part of the global genomic alterations in cancer that alter pathways relevant to stem-cell growth and differentiation. Epigenetic silencing mechanisms include covalent modifications of chromatin, DNA cytosine methylation, noncoding RNAs, and nucleosome remodeling [20]. It has been proposed that epigenetic abnormalities may play a seminal role in the earliest steps in tumorigenesis [21–24]. Epigenetic changes may act in concert with genetic changes resulting in tumorigenesis, because they are mitotically heritable. The high degree of mitotic stability of silencing plus the progressive nature by which it is achieved makes pathological silencing of growth controlling and other genes essential to carcinogenesis.

Patterns of DNA methylation are linked to gene expression; for example, methylation in a gene promoter region generally correlates with a silenced gene [25]. DNA methylation, the DNA methyltransferase (DNMT) catalyzed addition of methyl group to cytosine ring, is restricted to cytosines that precede a guanosine in the DNA sequence (the CpG dinucleotide) in humans and other mammals [25]. The distribution of CpG dinucleotides in the genome is unusually asymmetric, occurring in small clusters called "CpG islands". The CpG islands are often in promoter regions of genes and are usually unmethylated regardless of the transcriptional state. This highlights the importance of DNA methylation for gene expression, especially in transcriptional silencing [25].

Aberrant DNA methylation plays a strong role in tumorigenesis. Global hypomethylation of intergenic CpG dinucleotides and regional hypermethylation of CpG islands in promoter regions are characteristic hallmarks of many cancers [24]. The impact of hypermethylation on tumorigenesis is further illustrated by the silencing of multiple tumor suppressor genes, thereby contributing to the hallmarks of carcinogenesis which include evading apoptosis (P53, p14ARF, BNIP3 and Caspase-8), insensitivity to antigrowth signals (p16INK4a and miR-124a), sustained angiogenesis (TIMP3 and TSP1), limitless replicative potential

(hTERT), and tissue invasion and metastasis (E-cadherin and LIMS2).

Transcriptional silencing is also a result of chromatin compaction due to convergence of DNA methylation and histone modifications. Methylated DNA recruits methyl-binding proteins (MBDPs), which have methyl-CpG-binding domains (MBD), to hypermethylated DNA. MBDPs associate with histone deacetylases, resulting in chromatin remodeling and gene silencing. In addition to these mechanisms of silencing, histone methyltransferase (HMTs) repress transcription by methylation of lysine 9 of histone 3 (H3K9) or lysine 27 of histone 3 (H3K27). An excellent review of epigenetic modifications of chromatin is provided by Iacobuzio-Donahue [26].

The influence of epigenetic events on tumorigenesis is well illustrated by the evolution of colon cancer, in which risk factors for common cancers such as aging and inflammation are shown to cause expansions in either normal colon epithelial stem cells or precursor cells derived from them. Epigenetic gatekeepers such as cyclin-dependent kinase inhibitor 2A (CDKN2A/p16), secreted frizzled-related protein (SFRP), GATA-binding protein 4 and 5 (GATA-4 and -5), and adenomatous polyposis of the colon (APC) prevent early tumor progression in colon cancer. Normal epigenetic modulation of these gatekeeper genes allows them to prevent stem/precursor cells from becoming immortalized during periods of chronic stresses and renewal pressures on cell systems. APC is a classically mutated tumor suppressor gene in colon cancer, which is also inactivated by epigenetic mechanisms [27]. Epigenetic silencing of one allele serves as a second-hit in Knudson's hypothesis for tumor suppressor gene inactivation when paired which mutations on the other allele [21].

Like APC, loss of p16 can be epigenetically mediated, permitting expanding cells to develop genomic instability [28, 29] and further epigenetic gene-silencing events [30]. Its loss is seen in subsets of preinvasive stages of colon and other cancers [30]. Finally, GATA-4 and -5 transcription factor genes, important for both embryonic gastrointestinal epithelial development and for maturation in adults, are epigenetically silenced in about half of all the preinvasive and invasive lesions for colon cancer [31]. This can hamper differentiation and promote precursor cell expansion.

The wingless-type MMTV integration site (Wnt) pathway activation also illustrates how multiple epigenetic events may act in concert to affect a single-cell pathway. Inappropriate silencing of these genes leads to abnormal activation of the Wnt pathway, which plays a canonical role in colon tumorigenesis [23]. These genes are independently affected by epigenetic events but result in Wnt activation. Four genes in the SFRP family encoding proteins that antagonize the action of the Wnt ligand at the cell membrane are hypermethylated simultaneously in the majority of preinvasive lesions for colon cancer. Upregulation of the survival protein Sirtuin 1 (SIRT1) also results in Wnt pathway activation. SIRT1 is upregulated as a result of loss of the transcription factor hypermethylated in cancer 1 (HIC1) via hypermethylation in early preinvasive lesions in colon cancer as well as other types of cancer [23]. Loss of HIC1 also results in additional gene silencing events as well as downregulation of tumor protein 53 (p53).

Loss of DNA methylation results in the weakening of transcriptional repression in normally silent regions of the genome resulting in harmful expression of inserted or normally silenced genes, and loss of functional stability of chromosomes. It has been established that covalent histone modification is linked to DNA methylation. Cytosine methylation attracts methylated DNA-binding proteins and histone deacetylases to methylated CpG islands during chromatin compaction and gene silencing [32, 33]. In addition to epigenetic modification of transcriptional start sites, there is evidence for more global changes in chromatin structure. For instance, there is an overall decrease in the 5-methylcytosine content of cancer genomes that is reflected as hypermethylation in CpG islands [34]. The consistently observed hypermethylation is due to a change in 5-methylcytosine distributions rather than an overall increase in total amount of methylation. It has also been observed that large stretches of DNA can become abnormally methylated in cancer.

3. Epigenetics of Papillary Thyroid Carcinogenesis

Quantitative analysis of promoter hypermethylation in thyroid cancer has involved RASSF1A, TSHR, RARβ2, DAPK, S100, p16, CDH1, CALCA, TIMP3, TGF-β, and GSTpi [35]. Hypermethylation of 2 or more markers (RASSF1A, TSHR, RARβ2, DAPK, CDH1, TIMP3, and TGF-β) was detectable in 25% of thyroid hyperplasias, 38% of adenomas, 48% of thyroid cancers, and 100% of cell lines. Rank correlation analysis of marker hypermethylation suggests that a subset of the markers were hypermethylated in concert, which may represent a thyroid-specific regulatory process [35]. Additionally, a positive correlation was observed between BRAF mutation and RARβ2 and a negative correlation between BRAF mutation and RASSF1A [35].

Investigation of DNA methylation in PTC has been predominantly restricted to individual candidate tumor suppressor genes and genes known for their role in thyroid function, using locus specific nonquantitative methods. BRAF, RASSFIA, TSHR, ECAD, NIS-L, ATM, DAPK, SLC5A8, TIMP3, and RARβ2 have been analyzed for DNA methylation. Promoter hypermethylation of TSHR, NIS-L, ATM, and ECAD has been demonstrated in 34–59% [36, 37], 22%, 50%, and 56% of patients with papillary thyroid cancer, respectively [37].

3.1. Thyroid-Stimulating Hormone Receptor (TSHR) and Sodium Iodide Symporter (NIS). TSHR stimulates several key steps in thyrocyte concentration of iodine, including uptake by NIS and oxidation before incorporation into thyroglobulin by thyroid peroxidase [36]. The methylation status of the NIS and TSHR promoter regions are important, because these genes are specific to the thyroid and play a role in the uptake of iodine and normal cellular function [37]. Promoter hypermethylation resulting in decreased expression of TSHR and NIS may result in a decreased ability to concentrate iodine, rendering ablative doses

of ^{131}I ineffective [37]. Promoter hypermethylation of TSHR is reported in 34–59% [36, 37] of patients with papillary thyroid cancer. NIS mRNA expression has been shown to be decreased in thyroid cancers [37, 38], and this has been proposed to be secondary to methylation of the promoter region [32, 37]. The NIS-L region within the promoter was shown to be hypermethylated in 22% (7/32) of patients with papillary thyroid cancer [37] but was not methylated in surrounding histologically benign tissue.

3.2. E-Cadherin (ECAD). E-cadherin complexes with catenins to promote Ca^{2+}-dependent, homotypic cell-to-cell adhesion and to establish normal epithelial tissue architecture [39]. Disruption of the E-cadherin/catenin complex contributes to tumor metastasis, and decreased expression of E-cadherin is observed in advanced stage, poorly differentiated carcinomas [39]. Promoter hypermethylation has been demonstrated in multiple human cancers, including papillary thyroid cancer in 56% (18/32) of patients [37].

3.3. Ataxia Telangiectasia Mutated (ATM). ATM is a member of the phosphatidylinositol 3-kinase family of proteins that respond to DNA damage by phosphorylating key substrates (p53 and BRCA1) involved in DNA repair and/or cell cycle control [40–42]. Hypermethylation of ATM promoter was observed in 50% (16/32) of patients with papillary thyroid cancer analyzed [37].

3.4. Apical Iodide Transporter (AIT). The thyroid apical iodide transporter AIT encoded by the SCL5A8 gene has been defined as a sodium-coupled transporter of short-chain fatty acid. It is thought that AIT may be involved in the passive transport of iodide from thyrocyte to the follicle lumen [43, 44]. Expression of SCL5A8 is decreased in thyroid cancers compared to other iodide transporters [43] and is expressed abundantly in colon cancer, functioning as a tumor-suppressor gene. Silencing of SLC5A8 occurs by promoter hypermethylation in about 50% of colon cancer cell lines and primary colon cancers. Decreased expression of SLC5A8 observed in classical variant of papillary thyroid cancer is linked to hypermethylation of exon 1 of the gene [44].

Hypermethylation occurred in 33% (76/231) of PTC and was associated with extrathyroidal invasion (40%) and multifocality (40%) [45]. This epigenetic event is thought occur at a later stage in papillary thyroid cancer and specific of the classical variant; therefore, it may be secondary to other genetic alterations occurring selectively in the tumor type [44]. Indeed, SLC5A8 and BRAF discriminate the classical variant PTC, supporting the argument. In addition, a strong association between low SLC5A8 expression and the presence of BRAF V600E [44] or advanced clinicopathologic features [45] suggests a link in the progression to more aggressive papillary thyroid cancer.

3.5. The Tissue Inhibitor of Metalloproteinase 3 (TIMP3). TIMP3 is one of 4 tissue inhibitors of metalloproteinase thought to inhibit growth, angiogenesis, invasion, and metastasis in several human cancers [45, 46]. TIMP3 inhibits vascular endothelial factor-(VEGF-) mediated angiogenesis by blocking the binding of VEGF to VEGF receptor-2, thereby inhibiting downstream signaling and angiogenesis [46]. Promoter hypermethylation, and downregulation of TIMP3 expression, is observed in various human cancers [45, 47–49]. Hypermethylation in PTC occurred in 53% of tumors analyzed and was associated with extrathyroidal invasion (38%), lymph node metastasis (43%), and multifocality (49%).

3.6. Death-Associated Protein Kinase (DAPK). DAPK is a calcium/calmodulin-dependent serine threonine kinase protein with a proapoptotic, tumor-suppressor function [45, 50]. The DAPK gene is silenced by hypermethylation in several human cancers [45, 51, 52], including thyroid cancer, and its expression has been shown to be a useful marker for cancer prognosis [50]. In addition to aberrant DNA methylation, chromatin immunoprecipitation analysis demonstrated that histone deacetylation of the 5' CpG island is involved in gastrointestinal malignancies [51]. In papillary thyroid cancer, promoter hypermethylation of DAPK was demonstrated in 34% of PTC and was associated with tumor multifocality (51%) [45].

3.7. Retinoic Acid Receptor-β2 (RARβ2). RARβ2 plays a central role in the regulation of epithelial cell growth and tumorigenesis. Effects of retinoids are mediated by nuclear receptors, RAR-α, RAR-β, and RAR-γ, RXR-α, RXR-β, and RXR-γ which form RXR-RAR heterodimers, that bind to specific DNA sequences, called RAR elements. It is thought that decreased expression of RARs may lead to resistance to retinoid effects [53]. Hypermethylation of RARβ2 was demonstrated in 22% of papillary thyroid cancer and was not associated with any aggressive clinicopathologic features [45].

4. Conclusion

With improved diagnostic techniques, endocrine tumors are identified much more frequently than in the past. For instance, benign parathyroid tumors occur in as many as 2.3% of postmenopausal women [54], and primary hyperaldosteronism may be the cause of hypertension in as many as 4.8% of all patients with elevated blood pressure [55]. The molecular genetics of rare inherited endocrine tumor susceptibility syndromes, such as multiple endocrine neoplasia (MEN) type 1 and 2, familial pheochromocytoma syndromes, Carney complex, and Beckwith-Wiedemann syndrome have all contributed to our understanding of endocrine tumor development [56, 57]. Among different tumor types, there exist common pathways that lead to tumorigenesis, such as inactivation of the MEN1 tumor suppressor and activation of the RET proto-oncogene. As in other cancers, it is believed that the vast majority of genetic changes are somatic, that is, tumor-specific mutations acquired during tumor progression [58].

Epigenetic mechanisms, especially aberrant DNA methylation, very likely play an important role in papillary thyroid tumorigenesis. Genome-wide DNA methylation studies in

PTC provide a powerful tool to identify disease-causing genes. Additionally, unbiased, systematic analyses of tumor methylomes are likely to identify signaling pathways of importance in cancer development, in general. Analyzing epigenetic alterations in papillary thyroid cancer would help to characterize pathogenesis and may play a critical role in tumor classification and diagnosis. It has recently been shown that there are differences in global methylation profiles between prognostic subsets of chronic lymphocytic leukemia (CLL) [59]. The specific silencing of unmethylated tumor suppressor genes was seen in the unmutated IGHV subgroup of CLL, implying a critical role for epigenetic changes during leukemogenesis. Interestingly, patients with immunoglobulin heavy-chain variable gene (IGHV) unmutated CLL have worse prognoses compared to CLL patients with mutated IGHV genes [59].

These studies may also pave the way for the application of epigenetic therapeutics, by targeted reversal of gene silencing. Azanucleoside drugs are demethylating agents that are currently approved for treatment of myelodyspastic syndrome [20, 56]. These function as DNA methyltransferase enzymes that require incorporation into DNA to be effective and affect the differentiated state. Other nucleoside DNA methylation inhibitors include 5-fluoro-2'-deoxycytidine and zebulamine [60] which are in development. Histone deacetylases [61, 62] and histone methyltransferases are another reasonable option for therapeutics. The histone deacetylase SAHA is currently approved by the FDA for treatment of Tcell lymphoma [63].

Just as multiple epigenetic events may act in concert to affect a single-cell pathway, it is most likely that epigenetic therapy will involve using multiple drugs that individually affect epigenetic silencing but have synergistic effects. Proposed strategies for the FDA approved epigenetic drugs are as single therapies or in combination as primary or secondary treatment after neoadjuvant chemotherapy. Lack of specificity may not pose a problem, since DNMT inhibitors act only on dividing cells. The drugs preferentially activate genes that have become abnormally silenced in cancer [64]. Moreover, the chromatin structure associated with a pathologically silenced gene may be more susceptible to reactivation than the highly compacted state induced by physiological silencing [20].

References

[1] A. Jemal, R. Siegel, J. Xu, and E. Ward, "Cancer statistics," *Cancer Journal for Clinicians*, vol. 60, pp. 277–300, 2010.

[2] L. Davies and H. G. Welch, "Increasing incidence of thyroid cancer in the United States, 1973–2002," *Journal of the American Medical Association*, vol. 295, no. 18, pp. 2164–2167, 2006.

[3] M. L. Urken, "Prognosis and management of invasive well-differentiated thyroid cancer," *Otolaryngologic Clinics of North America*, vol. 43, no. 2, pp. 301–328, 2010.

[4] M. Xing, "BRAF mutation in thyroid cancer," *Endocrine-Related Cancer*, vol. 12, pp. 245–262, 2005.

[5] Y. E. Nikiforov, "RET/PTC rearrangement in thyroid tumors," *Endocrine Pathology*, vol. 13, pp. 3–16, 2002.

[6] R. Ciampi and Y. E. Nikiforov, "RET/PTC rearrangements and BRAF mutations in thyroid tumorigenesis," *Endocrinology*, vol. 148, pp. 936–941, 2007.

[7] M. Xing, "Genetic alterations in the phosphatidylinositol-3 kinase/Akt pathway in thyroid cancer," *Thyroid*, vol. 20, pp. 697–706, 2010.

[8] H. Davies, G. N. Ranzani, P. Bianchi et al., "Mutations of the BRAF gene in human cancer," *Nature*, vol. 417, pp. 949–954, 2002.

[9] X. Xu, R. M. Quiros, P. Gattuso, K. B. Ain, and R. A. Prinz, "High prevalence of BRAF gene mutation in papillary thyroid carcinomas and thyroid tumor cell lines," *Cancer Research*, vol. 19, pp. 4561–4567, 2003.

[10] E. T. Kimura, E. Rosenbaum, K. J. Rhoden et al., "High prevalence of BRAF mutations in thyroid cancer: genetic evidence for constitutive activation of the RET/PTC-RAS-BRAF signaling pathway in papillary thyroid carcinoma," *Cancer Research*, vol. 63, pp. 1454–1457, 2003.

[11] M. N. Nikiforova, E. T. Kimura, M. Gandhi et al., "BRAF mutations in thyroid tumors are restricted to papillary carcinomas and anaplastic or poorly differentiated carcinomas arising from papillary carcinomas," *Journal of Clinical Endocrinology and Metabolism*, vol. 88, no. 11, pp. 5399–5404, 2003.

[12] V. Vasko, S. Hu, G. Wu et al., "High prevalence and possible de novo formation of BRAF mutation in metastasized papillary thyroid cancer in lymph nodes," *Journal of Clinical Endocrinology and Metabolism*, vol. 90, no. 9, pp. 5265–5269, 2005.

[13] M. Xing, W. H. Westra, R. P. Tufano et al., "BRAF mutation predicts a poorer clinical prognosis for papillary thyroid cancer," *Journal of Clinical Endocrinology and Metabolism*, vol. 90, no. 12, pp. 6373–6379, 2005.

[14] M. Rivera, W. H. Westra, R. P. Tufano et al., "Molecular, morphologic, and outcome analysis of thyroid carcinomas according to degree of extrathyroid extension," *Thyroid*, vol. 20, pp. 1085–1093, 2010.

[15] T. J. Musholt, W. H. Westra, R. P. Tufano et al., "Detection of papillary thyroid carcinoma by analysis of BRAF and RET/PTC1 mutations in fine-needle aspiration biopsies of thyroid nodules," *World Journal of Surgery*, vol. 34, pp. 2595–2603, 2010.

[16] V. Vasko, M. Ferrand, J. Di Cristofaro, P. Carayon, J. F. Henry, and C. De Micco, "Specific pattern of RAS oncogene mutations in follicular thyroid tumors," *Journal of Clinical Endocrinology and Metabolism*, vol. 88, no. 6, pp. 2745–2752, 2003.

[17] T. J. Musholt, W. H. Westra, R. P. Tufano et al., "Impact of pathognomonic genetic alterations on the prognosis of papillary thyroid carcinoma. ESES vienna presentation," *Langenbeck Archives of Surgery*, vol. 395, pp. 877–883, 2010.

[18] E. Ishida, M. Nakamura, K. Shimada et al., "DNA hypermethylation status of multiple genes in papillary thyroid carcinomas," *Pathobiology*, vol. 74, no. 6, pp. 344–352, 2007.

[19] H. Zuo, M. Gandhi, M. M. Edreira et al., "Downregulation of Rap1GAP through epigenetic silencing and loss of heterozygosity promotes invasion and progression of thyroid tumors," *Cancer Research*, vol. 70, no. 4, pp. 1389–1397, 2010.

[20] P. A. Jones and S. B. Baylin, "The Epigenomics of Cancer," *Cell*, vol. 128, no. 4, pp. 683–692, 2007.

[21] M. Esteller, M. F. Fraga, M. Guo et al., "DNA methylation patterns in hereditary human cancers mimic sporadic tumorigenesis," *Human Molecular Genetics*, vol. 10, no. 26, pp. 3001–3007, 2001.

[22] A. P. Feinberg, R. Ohlsson, and S. Henikoff, "The epigenetic progenitor origin of human cancer," *Nature Reviews Genetics*, vol. 7, no. 1, pp. 21–33, 2006.

[23] S. B. Baylin and J. E. Ohm, "Epigenetic gene silencing in cancer—a mechanism for early oncogenic pathway addiction?" *Nature Reviews Cancer*, vol. 6, no. 2, pp. 107–116, 2006.

[24] A. Eden, F. Gaudet, A. Waghmare, and R. Jaenisch, "Chromosomal instability and tumors promoted by DNA hypomethylation," *Science*, vol. 300, no. 5618, p. 455, 2003.

[25] J. G. Herman and S. B. Baylin, "Gene silencing in cancer in association with promoter hypermethylation," *New England Journal of Medicine*, vol. 349, no. 21, pp. 2042–2054, 2003.

[26] C. A. Iacobuzio-Donahue, "Epigenetic changes in cancer," *Annual Review of Pathology*, vol. 4, pp. 229–249, 2009.

[27] M. Esteller, A. Sparks, M. Toyota et al., "Analysis of adenomatous polyposis coli promoter hypermethylation in human cancer," *Cancer Research*, vol. 60, no. 16, pp. 4366–4371, 2000.

[28] S. A. Foster, D. J. Wong, M. T. Barrett, and D. A. Galloway, "Inactivation of p16 in human mammary epithelial cells by CpG island methylation," *Molecular and Cellular Biology*, vol. 18, pp. 1793–1801, 1998.

[29] T. Kiyono, S. A. Foster, J. I. Koop, J. K. McDougall, D. A. Galloway, and A. J. Klingelhutz, "Both Rb/p16INK4a inactivation and telomerase activity are required to immortalize human epithelial cells," *Nature*, vol. 396, no. 6706, pp. 84–88, 1998.

[30] P. A. Reynolds, M. Sigaroudinia, G. Zardo et al., "Tumor suppressor p16 regulates polycomb-mediated DNA hypermethylation in human mammary epithelial cells," *Journal of Biological Chemistry*, vol. 281, no. 34, pp. 24790–24802, 2006.

[31] Y. Akiyama, N. Watkins, H. Suzuki et al., "GATA-4 and GATA-5 transcription factor genes and potential downstream antitumor target genes are epigenetically silenced in colorectal and gastric cancer," *Molecular and Cellular Biology*, vol. 23, no. 23, pp. 8429–8439, 2003.

[32] X. Nan, H. H. Ng, C. A. Johnson et al., "Transcriptional repression by the methyl-CpG-binding protein MeCP2 involves a histone deacetylase complex," *Nature*, vol. 393, no. 6683, pp. 386–389, 1998.

[33] P. L. Jones, G. J. C. Veenstra, P. A. Wade et al., "Methylated DNA and MeCP2 recruit histone deacetylase to repress transcription," *Nature Genetics*, vol. 19, no. 2, pp. 187–191, 1998.

[34] A. P. Feinberg and B. Tycko, "The history of cancer epigenetics," *Nature Reviews Cancer*, vol. 4, no. 2, pp. 143–153, 2004.

[35] M. O. Hoque, E. Rosenbaum, W. H. Westra et al., "Quantitative assessment of promoter methylation profiles in thyroid neoplasms," *Journal of Clinical Endocrinology and Metabolism*, vol. 90, no. 7, pp. 4011–4018, 2005.

[36] M. Xing, H. Usadel, Y. Cohen et al., "Methylation of the thyroid-stimulating hormone receptor gene in epithelial thyroid tumors: a marker of malignancy and a cause of gene silencing," *Cancer Research*, vol. 63, no. 9, pp. 2316–2321, 2003.

[37] J. A. Smith, C. Y. Fan, C. Zou, D. Bodenner, and M. S. Kokoska, "Methylation status of genes in papillary thyroid carcinoma," *Archives of Otolaryngology*, vol. 133, no. 10, pp. 1006–1011, 2007.

[38] G. M. Venkataraman, M. Yatin, R. Marcinek, and K. B. Ain, "Restoration of iodide uptake in dedifferentiated thyroid carcinoma: relationship to human Na+/I symporter gene methylation status," *Journal of Clinical Endocrinology and Metabolism*, vol. 84, no. 7, pp. 2449–2457, 1999.

[39] J. R. Graff, V. E. Greenberg, J. G. Herman et al., "Distinct patterns of E-cadherin CpG island methylation in papillary, follicular, hurthle's cell, and poorly differentiated human thyroid carcinoma," *Cancer Research*, vol. 58, no. 10, pp. 2063–2066, 1998.

[40] S. Banin, L. Moyal, S. Y. Shieh et al., "Enhanced phosphorylation of p53 by ATM in response to DNA damage," *Science*, vol. 281, no. 5383, pp. 1674–1677, 1998.

[41] C. E. Canman, D. S. Lim, K. A. Cimprich et al., "Activation of the ATM kinase by ionizing radiation and phosphorylation of p53," *Science*, vol. 281, no. 5383, pp. 1677–1679, 1998.

[42] D. Cortez, Y. Wang, J. Qin, and S. J. Elledge, "Requirement of ATM-dependent phosphorylation of Brca1 in the DNA damage response to double-strand breaks," *Science*, vol. 286, no. 5442, pp. 1162–1166, 1999.

[43] L. Lacroix, T. Pourcher, C. Magnon et al., "Expression of the apical iodide transporter in human thyroid tissues: a comparison study with other iodide transporters," *Journal of Clinical Endocrinology and Metabolism*, vol. 89, no. 3, pp. 1423–1428, 2004.

[44] V. Porra, C. Ferraro-Peyret, C. Durand et al., "Silencing of the tumor suppressor gene SLC5A8 is associated with BRAF mutations in classical papillary thyroid carcinomas," *Journal of Clinical Endocrinology and Metabolism*, vol. 90, no. 5, pp. 3028–3035, 2005.

[45] S. Hu, D. Liu, R. P. Tufano et al., "Association of aberrant methylation of tumor suppressor genes with tumor aggressiveness and BRAF mutation in papillary thyroid cancer," *International Journal of Cancer*, vol. 119, no. 10, pp. 2322–2329, 2006.

[46] J. H. Qi, Q. Ebrahem, N. Moore et al., "A novel function for tissue inhibitor of metalloproteinases-3 (TIMP3): inhibition of angiogenesis by blockage of VEGF binding to VEGF receptor-2," *Nature Medicine*, vol. 9, no. 4, pp. 407–415, 2003.

[47] S. J. Darnton, L. J. Hardie, R. S. Muc, C. P. Wild, and A. G. Casson, "Tissue inhibitor of metalloproteinase-3 (TIMP-3) gene is methylated in the development of esophageal adenocarcinoma: loss of expression correlates with poor prognosis," *International Journal of Cancer*, vol. 115, no. 3, pp. 351–358, 2005.

[48] H. Feng, A. N. Y. Cheung, W. C. Xue et al., "Down-regulation and promoter methylation of tissue inhibitor of metalloproteinase 3 in choriocarcinoma," *Gynecologic Oncology*, vol. 94, no. 2, pp. 375–382, 2004.

[49] P. A. Van der Velden, W. Zuidervaart, M. H. M. H. Hurks et al., "Expression profiling reveals that methylation of TIMP3 is involved in uveal melanoma development," *International Journal of Cancer*, vol. 106, no. 4, pp. 472–479, 2003.

[50] R. Schneider-Stock, A. Roessner, and O. Ullrich, "DAP-kinase—protector or enemy in apoptotic cell death," *International Journal of Biochemistry and Cell Biology*, vol. 37, no. 9, pp. 1763–1767, 2005.

[51] A. Satoh, M. Toyota, F. Itoh et al., "DNA methylation and histone deacetylation associated with silencing DAP kinase gene expression in colorectal and gastric cancers," *British Journal of Cancer*, vol. 86, no. 11, pp. 1817–1823, 2002.

[52] S. V. Harden, M. Toyota, F. Itoh et al., "Gene promoter hypermethylation in tumors and lymph nodes of stage I lung cancer patients," *Clinical Cancer Research*, vol. 9, pp. 1370–1375, 2003.

[53] E. M. Youssef, D. Lotan, J. P. Issa et al., "Hypermethylation of the retinoic acid receptor-β gene in head and neck carcinogenesis," *Clinical Cancer Research*, vol. 10, no. 5, pp. 1733–1742, 2004.

[54] E. Lundgren, J. Rastad, E. Thurfjell, G. Akerstrom, and S. Ljunghall, "Population-based screening for primary hyperparathyroidism with serum calcium and parathyroid hormone values in menopausal women," *Surgery*, vol. 121, no. 3, pp. 287–294, 1997.

[55] G. P. Rossi, G. Bernini, C. Caliumi et al., "A prospective study of the prevalence of primary aldosteronism in 1,125 hypertensive patients," *Journal of the American College of Cardiology*, vol. 48, no. 11, pp. 2293–2300, 2006.

[56] T. Carling, "Molecular pathology of parathyroid tumors," *Trends in Endocrinology and Metabolism*, vol. 12, no. 2, pp. 53–58, 2001.

[57] T. Carling, "Multiple endocrine neoplasia syndrome: genetic basis for clinical management," *Current Opinion in Oncology*, vol. 17, no. 1, pp. 7–12, 2005.

[58] M. R. Stratton, P. J. Campbell, and P. A. Futreal, "The cancer genome," *Nature*, vol. 458, no. 7239, pp. 719–724, 2009.

[59] M. Kanduri, N. Cahill, H. Göransson et al., "Differential genome-wide array-based methylation profiles in prognostic subsets of chronic lymphocytic leukemia," *Blood*, vol. 115, no. 2, pp. 296–305, 2010.

[60] J. C. Cheng, C. B. Yoo, D. J. Weisenberger et al., "Preferential response of cancer cells to zebularine," *Cancer Cell*, vol. 6, no. 2, pp. 151–158, 2004.

[61] P. Marks, R. A. Rifkind, V. M. Richon, R. Breslow, T. Miller, and W. K. Kelly, "Histone deacetylases and cancer: causes and therapies," *Nature Reviews Cancer*, vol. 1, no. 3, pp. 194–202, 2001.

[62] S. Minucci and P. G. Pelicci, "Histone deacetylase inhibitors and the promise of epigenetic (and more) treatments for cancer," *Nature Reviews Cancer*, vol. 6, no. 1, pp. 38–51, 2006.

[63] J. E. Bolden, M. J. Peart, and R. W. Johnstone, "Anticancer activities of histone deacetylase inhibitors," *Nature Reviews Drug Discovery*, vol. 5, no. 9, pp. 769–784, 2006.

[64] G. Liang, M. L. Gonzalgo, C. Salem, and P. A. Jones, "Identification of DNA methylation differences during tumorigenesis by methylation-sensitive arbitrarily primed polymerase chain reaction," *Methods*, vol. 27, no. 2, pp. 150–155, 2002.

SAGE-Hindawi Access to Research
Journal of Thyroid Research
Volume 2011, Article ID 985780, 9 pages
doi:10.4061/2011/985780

Review Article

Challenges Associated with Tyrosine Kinase Inhibitor Therapy for Metastatic Thyroid Cancer

Maria E. Cabanillas,[1] Mimi I. Hu,[1] Jean-Bernard Durand,[2] and Naifa L. Busaidy[1]

[1] *Department of Endocrine Neoplasia and Hormonal Disorders, The University of Texas MD Anderson Cancer Center, Houston, TX 77030, USA*
[2] *Department of Cardiology, The University of Texas MD Anderson Cancer Center, Houston, TX 77030, USA*

Correspondence should be addressed to Maria E. Cabanillas, mcabani@mdanderson.org

Received 30 June 2011; Accepted 16 July 2011

Academic Editor: Maria João M. Bugalho

Tyrosine kinase inhibitors (TKIs) which target angiogenesis are promising treatments for patients with metastatic medullary and differentiated thyroid cancers. Sorafenib, sunitinib, and pazopanib are commercially available drugs which have been studied in these diseases. Vandetanib is the first drug approved in the United States for treatment of medullary thyroid cancer. These TKIs are used as chronic therapies, and therefore it is imperative to understand the adverse event profile in order to avoid excessive toxicity and maintain patients on therapy as long as it proves beneficial. Here we review common toxicities, management of these, and other challenging situations that arise when using TKIs in patients with thyroid cancer.

1. Introduction

Thyroid cancer is now the 5th most commonly diagnosed cancer in women and 9th in overall incidence in the United States; however, fewer than 2000 people die per year of their disease and mortality rates have remained fairly stable for the past several decades [1]. The most common form of thyroid cancer, differentiated thyroid cancer (DTC), is derived from the follicular cells of the thyroid, and it includes papillary and follicular thyroid cancers. While most patients are cured or have indolent disease, a small percentage develop metastases that no longer respond to treatment with radioactive iodine or TSH suppressive therapy. Medullary thyroid cancer (MTC) accounts for only about 2-3% of thyroid cancers and is derived from the neuroendocrine "C" cells of the thyroid gland. The only treatment with curative intent for medullary thyroid carcinoma is complete surgical resection.

Therapy with tyrosine kinase inhibitors (TKIs) has only recently been studied in thyroid cancer. The discovery that BRAF (in papillary and anaplastic thyroid cancers) and RET (in MTC) mutations, as well as angiogenesis, play a significant role in tumorigenesis in DTC and MTC led to several clinical trials over the past decade with multikinase inhibitors. For purposes of this paper, TKIs refer to small molecule drugs, which target multiple pathways, including, but are not limited to, vascular endothelial growth factor receptor (VEGFR). Sorafenib, sunitinib, and pazopanib are three commercially available TKIs which have shown favorable results in phase II trials in DTC [2–4]. Although these small trials have reported favorable responses, at this time, there are no published results of large phase III trials in DTC. Favorable results of a phase III, randomization study of vandetanib versus placebo in MTC have been reported [5]; however, it is important to note that patients on this study were not required to have progressive disease prior to study entry. Vandetanib was recently approved by the Food and Drug Administration for symptomatic or progressive MTC, establishing it as the first drug to be approved for this disease. The drug is available only through the Vandetanib Risk Evaluation and Mitigation Strategy (REMS) Program due to the prolongation of the QT interval and reported cases of torsades de pointes and sudden death in clinical trials. Sorafenib has also been studied in MTC in a phase II trial [6], and encouraging results of sunitinib in MTC have been presented at a national meeting [7].

Table 1: Major adverse events associated with commercially available TKIs which have been studied in thyroid cancer.

Adverse event	Sorafenib (%)		Sunitinib (%)		Pazopanib (%)		Vandetanib (%)	
	All-grade	≥grade 3	All-grade	≥grade 3	All-grade	≥grade 3	All-grade	≥grade 3
Hypertension	17	4	30	12	40	4	33	9
CHF or LVEF decline	1.7	NR	13	3	<1%	NR	<1	NR
Proteinuria	NR	NR	NR	NR	9	<1	10	0
Hand-foot skin reaction	30	6	29	6	6	NR	NR	NR
Stomatitis	NR	NR	30	1	4	NR	NR	NR
Anorexia	16	<1	34	2	22	2	21	4
Weight loss	10	<1	12	<1	52	3.5	10	1
Diarrhea	43	2	61	9	52	3.5	57	11
AST elevation	NR	NR	56	2	53	7.5	NR	NR
ALT elevation	NR	NR	51	2.5	53	12	51	2
Fatigue	37	5	54	11	19	2	24	6
Hypothyroidism	NR	NR	14	2	7	NR	NR	NR
Arterial thromboembolism	2.9	NR	NR	NR	3	2	NR	NR
Hemorrhage/bleeding (all sites)	15	3	30	3	13	2	NR	NR

CHF: congestive heart failure; LVEF: left ventricular ejection fraction; AST: aspartate aminotransferase; ALT: alanine aminotransferase; NR: not reported.
Data extracted from the phase 3 trials or from the prescribing drug reference information [9, 28–30].
Table is adapted from [31].

There are many challenges posed by the use of TKIs, which we believe should be used with caution and reserved for patients with either advanced, progressive disease or bulky disease which may compromise organ function. This review focuses on highlighting the most common and problematic adverse events associated with TKIs with suggestions for management. Other dilemmas that often arise with use of these drugs will be described as well.

2. Adverse Event Management

Although TKIs are generally better tolerated than cytotoxic chemotherapy, many patients develop side effects from on-target and off-target effects which require aggressive management in order to maintain patient compliance, optimize therapy, and avoid potentially life-threatening consequences. Since many patients require long-term use of TKIs for continued control of disease, it is imperative for the treating clinician to be familiar with the potential side effects of these drugs. The most frequent side effects of TKIs are hypertension, dermatologic effects, fatigue, and diarrhea. In addition, the risk of bleeding and liver toxicity may be fatal. The clinician should conduct thorough physical and laboratory examinations prior to considering therapy with these drugs to identify the most appropriate choice of treatment and must monitor and treat adverse events during therapy. Treatment of all comorbid conditions should be optimized and drug-drug interaction, antifungals, antiemetics, and class III antiarrhythmic agents avoided to prevent interactions with TKIs. In this section we will discuss the most common and potentially fatal side effects of TKIs with management recommendations.

Table 1 lists adverse events of the commercially available TKIs relevant to thyroid cancer, their incidence, and grades (data extracted from phase III trials in renal cell carcinoma and package inserts) using Common Terminology Criteria for Adverse Events version 3.0 (CTCAE v3.0). The CTCAE is a list of descriptive terminology utilized for adverse event grading and reporting on clinical trials and is made available through the CTEP website at http://ctep.cancer.gov/protocoldevelopment/electronic_applications/docs/ctcaev3.pdf.

2.1. Drug-Drug Interactions. Cytochrome P450 enzymes, expressed primarily in the liver, play a primary role in the metabolism of many drugs. Sunitinib, sorafenib, pazopanib, and vandetanib are all metabolized by cytochrome P450 3A4 (CYP3A4). Of the four drugs, sorafenib appears to be the least susceptible to CYP3A4 inducers or inhibitors, although the package labeling warns against concomitant use of CYP3A4 inducers [8]. Concomitant use of CYP3A4 inducers may decrease the plasma concentration of the TKI, resulting in decreased efficacy, while inhibitors may increase the plasma concentration, resulting in toxicity. Itraconazole, a potent inhibitor of CYP3A4, does not appear to affect the metabolism of vandetanib [9]. Table 2 lists the more common, clinically significant drugs metabolized via the CYP3A4 enzyme system.

The medical history should include a thorough review of medications which may affect the metabolism of the TKI. Concomitant drugs which are metabolized via CYP3A4 should be avoided or substituted for another drug. If a CYP3A4 inhibitor drug cannot be eliminated, a dose reduction in the TKI should be considered. Patients should also be monitored for increasing side effects if a CYP3A4 inhibitor is coadministered.

2.2. Cardiovascular. Hypertension is the most common cardiovascular side effect associated with antiangiogenic drugs.

Table 2: Clinically significant CYP3A4 inducers, inhibitors, and substrates.

CYP3A4 inducers	CYP3A4 inhibitors	CYP3A4 substrates
Dexamethasone	Calcium channel blockers: amiodarone, verapamil	Statins: atorvastatin, lovastatin, and simvastatin (not pravastatin) (not rosuvastatin)
Anticonvulsants: phenytoin, carbamazepine	Azole antifungals: itraconazole, voriconazole, and ketoconazole	Calcium channel blockers: amlodipine, diltiazem, felodipine, nifedipine, and verapamil
Phenobarbital		
Rifampin	Macrolide antibiotics: erythromycin, and clarithromycin (not azithromycin)	
St. John's wort		
HIV antivirals: nonnucleoside reverse transcriptase inhibitors: efavirenz, and nevirapine	HIV antivirals: protease inhibitors: indinavir, nelfinavir, and ritonavir	
Pioglitazone		

The mechanism of hypertension is not well understood, but it has been suggested that it is due to increased fluid retention, endothelial dysfunction, nitrous oxide inhibition, rarefaction [10], reduction of vascular surface area, and increase in peripheral vascular resistance caused by inhibition of angiogenesis [11–14]. A recent study by Rini et al. suggests that the rise in blood pressure above 140/90 may be a biomarker for anticancer therapy and was associated with significant survival benefit even with treatment of antihypertensives. The use of antihypertensives did not reduce the efficacy of sunitinib in metastatic renal cell carcinoma [15].

The onset of hypertension is variable. Blood pressure may begin to rise within days of therapy prior to steady state or the onset of the therapies' biological effects or may be more indolent. There are no clear guidelines for managing TKI-induced hypertension. It is our clinical practice to use ACE inhibitors, angiotensin receptor blockers (ARBs) or a beta blocker as first-line therapy for hypertension since these drugs are not metabolized via the CYP3A4 enzyme system. However, the choice of an antihypertensive should be individualized. The Angiogenesis Task Force of the National Cancer Institute Investigational Drug Steering Committee recently published guidelines for management of hypertension with TKIs [16]. Hypertension should be controlled based on compelling and noncompelling indications to a goal of <140/90 prior to starting TKIs. Once a TKI is initiated, patients should have the blood pressure monitored within 1 week. Blood pressure monitoring at home may be more effective at prediction of outcomes from cardiovascular disease than clinic blood pressure monitoring [17]. If the blood pressure is above goal, antihypertensive therapy should be initiated or adjusted. Patients should continue to check their blood pressure daily (with brachial blood pressure device) and report results on a weekly basis (until adequate blood pressure control is achieved), and antihypertensive drugs should be rapidly titrated or new drugs added to the regimen. Once control of blood pressure is obtained, the blood pressure should be monitored on a monthly basis. Interruption or dose reduction of the TKI may be necessary in order to achieve adequate blood pressure control. Some calcium-channel blockers, such as felodipine, diltiazem, nifedipine, and verapamil, are CYP3A4 substrates or inhibitors and should be avoided.

Sunitinib and pazopanib can lead to QT interval prolongation; therefore, they should be used with caution in patients with a history of QT prolongation and patients taking antiarrhythmic drugs. Torsade de pointes was seen in <0.1% of patients exposed to sunitinib and <2% of patients treated with pazopanib. Vandetanib carries a black box warning due to QT interval prolongation, Torsade de pointes, and sudden death observed in clinical trials involving patients with a broad variety of solid malignancies. Serial monitoring of electrocardiograms and electrolytes is mandated and electrolyte abnormalities should be corrected [9, 18, 19]. In a phase III trial that examined the efficacy and safety of vandetanib 300 mg in the treatment of unresectable locally advanced or metastatic MTC, QT prolongation was reported in 14% of patients randomized to vandetanib and in 1% of patients randomized to placebo, with 8% (18/231) and 1% (1/99), respectively, being ≥grade 3 events. Vandetanib should not be given to patients who have a history of Torsades de pointes, congenital long QT syndrome, bradyarrhythmias, or uncompensated heart failure. Vandetanib should not be started in patients whose corrected QT interval (QTcF, Fridericia formula) is greater than 450 ms. Specific guidelines for monitoring of QT abnormalities and electrolytes in patients taking vandetanib are specified in the package insert [9]. In addition, use of concomitant drugs known to prolong the QT interval, such as amiodarone and erythromycin, should be avoided.

A less common but serious adverse event associated with TKIs is systolic and diastolic congestive heart failure. It appears to be more common with sunitinib but has been reported with sorafenib and pazopanib. Patients may present with very dramatic symptoms of heart failure, while others demonstrate mild symptoms which may be difficult to differentiate from fatigue due to the TKI or the tumor itself [20]. Cardiac toxicity, although not always completely reversible, is often a manageable condition if patients have

careful monitoring and treatment with routine heart failure therapies with beta blockers and ACE inhibitors/ARB as recommended by the guidelines of heart failure management by the American College of Cardiology. The etiology of the heart failure is thought to be due to direct reversible cardiomyocyte toxicity, possibly exacerbated by hypertension which may progress to irreversible, progressive injury if not treated with standard heart failure therapy [21]. This toxicity is not completely understood, but platelet-derived growth factor receptor-β (PDGFR-β) inhibition has been implicated as playing a role in the response to pressure-overload-induced stress [22]. We recommend that all patients initiating TKIs have a baseline echocardiogram and periodic monitoring while they are on therapy. Furthermore, aggressive management of hypertension may help reduce cardiomyocyte damage.

Case Number 1. A 69-year-old woman with a history of hypertension and premature ventricular contractions was referred to our center. She had a history of T4a, N0, M0, stage IVA papillary thyroid cancer for 10 years prior. The patient's thyroid cancer was initially managed with total thyroidectomy and radioactive iodine ablation, but she developed local recurrence and pulmonary metastases several years later. She continued to have progressive disease in the lungs and neck and was referred to our center. The patient was enrolled into a phase II clinical trial with an investigational TKI targeting VEGFRs, PDGFR, and others. The patient's blood pressure was normal prior to initiation of the investigational TKI, but one week later she developed grade 2 hypertension which was difficult to control despite treatment with multiple antihypertensive agents. Her pretreatment echocardiogram demonstrated an ejection fraction of 55–60%. Nearly 4 months after starting on the investigational agent, she underwent adenosine stress test which identified a 30% ejection fraction with hypokinesia in the anterior septal segments which partially reversed with rest. Because of the presence of a left bundle branch block at baseline, definitive diagnosis of ischemia was not possible from the images. Carvedilol was initiated, and the investigational TKI was held. Echocardiogram confirmed the low ejection fraction. A cardiac catheterization with myocardial biopsy was performed. She was found to have mild ischemic heart disease (defined as less than 50% stenosis in any coronary) which was disproportionate to her degree of heart failure, and therefore the heart failure was attributed to the TKI. Direct cardiomyocyte toxicity was confirmed with the biopsy, demonstrating hypertrophy and interstitial edema, increased lipid droplets, and dilatation of sarcotubular elements (Figure 1). Since the biopsy showed no myocyte death (indicating reversibility) and the echocardiogram showed a return to baseline, after 3 weeks, the investigational agent was reintroduced at a reduced dose. Two months later she was found to have progression of disease, and the investigational agent was discontinued permanently.

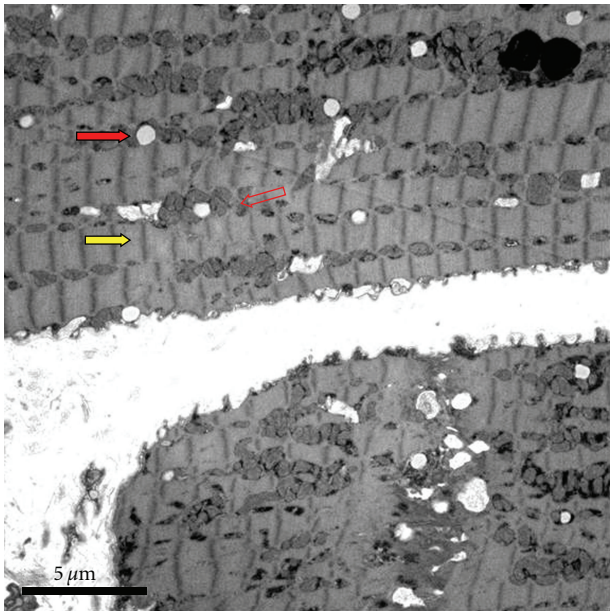

Figure 1: Transmission electron micrographs of endomyocardial biopsy from patient with systolic heart failure treated with a TKI. Section shows hypertrophy and interstitial edema with edematous mitochondria (open red arrow), with increased lipid droplets (solid red arrow) and dilatation of sarcotubular elements (yellow arrow). These findings are consistent with acute but reversible injury.

2.3. Renal. Proteinuria associated with antiangiogenic therapies was first described with bevacizumab, a monoclonal antibody against VEGF [23]. Small-molecule tyrosine kinase inhibitors, which inhibit VEGF-R, lead to proteinuria as well [24]. Thrombotic microangiopathy and acute interstitial nephritis have been reported with sorafenib and sunitinib [25, 26]. The glomerular podocytes express VEGF, and glomerular endothelial cells express VEGF receptors. Thus, a proposed mechanism of proteinuria is that deletion of VEGF allele in podocytes or inhibited VEGF signaling leads to proteinuria and capillary endotheliosis [27].

All patients who will receive antiangiogenic therapies should have a baseline urinalysis and protein to creatinine ratio, with routine monitoring for development of proteinuria while on treatment. A urine protein to creatinine ratio of ≥ 1 or 24-hour urine with ≥ 1 gram/dL/24 hours of protein should prompt intervention. The decision to hold drug should be considered on a case-by-case basis. Treatment with an ACE inhibitor or ARB should be initiated and consultation with nephrology may be warranted. As proteinuria is a class effect of antiangiogenic treatments, changing from one agent to another may not prevent this effect in a patient.

2.4. Dermatologic. Dermatologic reactions observed with TKIs include hand-foot syndrome (HFS), skin induration or callous formation, rash, alopecia, hair texture and color changes, and skin discoloration. HFS, the most common and potentially most debilitating dermatologic effect, presents as desquamating lesions in a palmoplantar distribution typically at pressure points or areas of friction or trauma. The lesions can significantly affect a patient's quality of life, thus

Table 3: Suggested dose modification for skin toxicity for sorafenib [8].

Skin toxicity grade	Occurrence	Suggested dose modification
Grade 1: numbness, dysesthesia, paresthesia, tingling, painless swelling, erythema or discomfort of the hands or feet which does not disrupt the patient's normal activities	Any occurrence	Continue sorafenib and consider topical therapy for symptomatic relief
Grade 2: Painful erythema and swelling of the hands or feet and/or discomfort affecting the patient's normal activities	1st occurrence	Continue sorafenib and consider topical therapy for symptomatic relief. If no improvement within 7 days, see below
	No improvement within 7 days or 2nd or 3rd occurrence	Interrupt sorafenib until toxicity resolves to grade 0-1. When resuming treatment, decrease sorafenib dose by one dose level (400 mg daily or 400 mg every other day)
	4th occurrence	Discontinue sorafenib treatment
Grade 3: Moist desquamation, ulceration, blistering or severe pain of the hands or feet, or severe discomfort that causes the patient to be unable to work or perform activities of daily living	1st or 2nd occurrence	Interrupt sorafenib until toxicity resolves to grade 0-1. When resuming treatment, decrease sorafenib dose by one dose level (400 mg daily or 400 mg every other day)
	3rd occurrence	Discontinue sorafenib treatment

necessitating drug discontinuation or dose reduction. The pathogenesis of HFS is not entirely clear. Preventive application of hand and foot lubricants should be implemented at time of drug initiation. The package insert for sorafenib gives clear recommendations on dose modifications and holds for skin toxicity (Table 3). It has been the authors' experience with sorafenib that when patients develop grade ≥ 3 HFS, drug interruption until skin toxicity declines to grade ≤ 1 with reinitiation at 200 mg daily, and titration by 200 mg every 3–5 days can prevent further escalation of skin toxicity (unpublished data). Stevens-Johnson syndrome, characterized by a prodrome of malaise and fever, followed by rapid development of erythematous or purpuric macules, which can progress to epidermal necrosis or sloughing, has been reported with vandetanib. A patient with these signs and/or symptoms should discontinue drug therapy immediately and seek medical attention, as this could be a life-threatening adverse effect.

Skin induration and callous formation can lead to pain at pressure points and limit mobility. Referral to podiatry can be considered to reduce callous size. Skin evaluation for development of actinic keratoses or keratoacanthoma-type squamous cell carcinomas (KA-SCC) should be performed regularly while being treated with sorafenib and BRAF inhibitors, as these lesions have been described primarily with targeted therapy against Raf kinase or mutant BRAF [32–35]. These lesions can develop as solitary or multiple lesions, weeks to months after starting drug therapy, and do not need to be confined to sun-exposed areas. Fortunately, KA-SCC has not been reported to metastasize, and spontaneous regression has been reported [32]. KA-SCCs should be completely excised. It has not been uniformly recommended that drug discontinuation occur when KA-SCCs develop due to the low metastatic potential; however, patients should be made aware of this effect and maintain routine skin evaluations.

2.5. Gastrointestinal System. Diarrhea, nausea, mucositis, stomatitis, dysgeusia, anorexia, abdominal discomfort, and weight loss may develop with the use of these drugs. Reduced side effects may occur if medication is taken with a large meal and water, if appropriate for administration per package insert. Appropriate use of supportive therapies with antidiarrheal or antiemetic medications may prevent the need for dose reduction or discontinuation. In the case of severe, unresponsive gastrointestinal effects, drug discontinuation should be implemented and reinitiated at a reduced dose once symptoms resolve to baseline or grade 1 level. Gastrointestinal perforation or fistula development is a rare, but potentially life-threatening, adverse event reported with TKIs. Risk factors include underlying tumor at perforation, diverticulitis, bowel obstruction, recent sigmoidoscopy or colonoscopy, and historical abdominal/pelvic irradiation [36]. Drug discontinuation is warranted if perforation event occurs. Consideration for a different TKI will need to be done with caution.

Hepatic toxicity or abnormalities, demonstrated by elevations in aspartate aminotransferase (AST) and alanine aminotransferase (ALT) and bilirubin, can occur. Elevations in AST or ALT were the most common metabolic abnormality requiring treatment seen in the phase III trial of pazopanib in renal cell carcinoma [28]. Although isolated elevations of total bilirubin were also seen at a similar frequency, concurrent elevations of ALT and total bilirubin were rare. The presence of a polymorphism in the uridine diphosphate glucuronosyltransferase 1A1 (UGT1A1) gene, which predisposes to Gilbert's syndrome, leads to reduced enzymatic activity necessary for the conjugation of bilirubin allowing it to be excreted in bile. Xu et al. reported that the presence of a polymorphism in UGT1A1 was significantly associated with pazopanib-induced hyperbilirubinemia, indicating that isolated unconjugated hyperbilirubinemia was a benign finding associated with Gilbert's

syndrome, which did not require discontinuation of drug therapy [37]. Conjugated hyperbilirubinemia would require further investgation. None of the genetic markers evaluated in this study were associated with hepatic transaminase elevation, thus leaving the etiology still to be determined.

TKIs can lead to asymptomatic increases in pancreatic enzymes or rarely acute pancreatitis, most commonly reported with sorafenib and pazopanib. Standard treatment for pancreatitis and evaluation with endoscopic ultrasonography and other diagnostic testings for underlying causes of pancreatitis should be implemented. However, radiologic evidence of pancreatic damage or pancreatitis often is not found. Thus, dose-limiting toxicity for pancreatic enzyme elevation should be applied to grade 4 levels associated with clinical findings of pancreatitis, or if considered to be life threatening [38]. The cause of elevation in amylase and lipase is unclear, although some have attributed it to pancreatic ischemia from antiangiogenesis or to other drug-related effects.

2.6. Hematologic. Mucosal bleeding (e.g., epistaxis) to hemorrhage (i.e., gastrointestinal, pulmonary, cerebral, vaginal) has been reported with TKIs. Although mild mucosal bleeding could be attributed to inhibition of VEGFR-2 causing microvascular leaks from endothelial cell damage, clinically more severe hemorrhage is attributed to tumoral invasion of large vessels or other concurrent pathological conditions [36]. Additionally, thrombosis has been identified with TKI use. Inhibition of VEGF signaling could lead to overproduction of erythropoietin in the liver, which increases hematocrit and blood viscosity [39, 40]. Additionally, as wound healing is dependent upon angiogenesis, VEGF-inhibitors can impair or delay wound healing after surgery or other invasive procedures. Thus, drug should be withheld before and after surgery to optimize wound healing [36].

Hematologic laboratory abnormalities with neutropenia, lymphopenia, and thrombocytopenia are associated with TKIs. In contrast, anemia occurs less frequently, which may be explained by the relative increased erythrocytosis seen with this class of drugs. As patients with differentiated thyroid carcinoma may have received large cumulative doses of radioactive iodine and thyroid cancer patients may have received external beam radiation therapy, myelosuppression may be present prior to TKI initiation. Thus, routine monitoring of complete blood count and differential is required while on therapy.

2.7. Miscellaneous. Hypothyroidism or rising thyroid stimulating hormone (TSH), requiring increasing the thyroid hormone replacement doses, is seen as a class effect. Suggested etiologies have been poor absorption of levothyroxine from concomitant treatment-related diarrhea, or in patients with intact thyroid glands, regression of thyroid capillaries, or inhibition of thyroid peroxidase [36, 41]. Thyroid function should be monitored routinely while on TKI treatment to maintain a suppressed TSH in patients with DTC and a normal TSH in MTC patients.

Fatigue is a pervasive and often difficult-to-manage problem in cancer patients and may be related to many factors, in addition to direct toxicity of targeted drug therapy. Investigation for causes (e.g., anemia, hypothyroidism, cardiac dysfunction, renal dysfunction) should be performed. Supportive care with adequate nutrition, exercise, and stress reducing techniques is encouraged.

3. Recommendations for Dose Modifications or Discontinuation of TKIs due to Intolerance

Nonhematologic Adverse Events (AEs). Patients with tolerable grade 1-2 nonhematologic AEs may continue TKI therapy while treatment for the AE is being optimized. For example, grade 1–3 hypertension does not necessarily require a dose modification or drug hold if the patient can be managed with antihypertensive agents. On the other hand, adverse events such as grade 1-2 skin rash, which have minimally effective treatments and/or are distressful or embarrassing to patients, may require drug interruptions. Although the package insert for sorafenib describes dose modification recommendation for cutaneous toxicity [8] (Table 3), others do not have clearly defined dose modifications for this toxicity. Recurrent grade 2 AEs require drug hold and often dose reduction if they are possibly related to the TKI and not responding to optimal supportive therapy. However, since TKIs are often chronic treatments for patients with thyroid cancer, the decision to hold and reduce the dose is often dictated in part by the patient's quality of life and physician judgment. Most grade 3 toxicities will require a drug hold until the AE improves significantly with resumption of the TKI at a reduced dose. However, grade 3 toxicities which can be readily managed (such as correction of hypokalemia arising from diarrhea which can be controlled) do not require a drug hold. Second occurrence of grade 3 toxicity should be managed again with drug hold and reduction of the dose. Third occurrences which cannot be effectively managed often require discontinuation of the TKI. Grade 4 AEs are life-threatening events, and if related to the TKI, require discontinuation of drug. However, in some select cases, it may be appropriate to resume treatment after reduction of the dose by two dose levels and if other interventions are implemented to prevent recurrence of the event. Thus, the decision to resume drug in patients with manageable grade 4 AEs, even when drug related, must be individualized and the benefit/risk ratio should be considered. Careful review of concomitant medications and herbal remedies which may cause increases in the drug levels of the TKI should also be given consideration.

Hematologic Adverse Events. Grade 2 hematologic toxicities do not require dose reduction. Grade 3-4 neutropenia and thrombocytopenia and grade 4 anemia require dose reductions upon first and second occurrences. Grade 3 and 4 hematologic toxicities are rare in thyroid cancer patients receiving TKIs; thus, other causes such as myelodysplasia should be ruled out.

Intolerance to TKIs. The definition of intolerance, proposed by Jabbour et al. in the context of leukemia, is met if the patient has one or more criterion as delineated in the manuscript [19]. We propose the following modified criteria as a definition of TKI intolerance: presence of one or more of the following criteria: (i) any grade 3-4 non-hematologic toxicity related to TKI therapy that has recurred despite dose reduction and optimal symptomatic measures, (ii) any grade 2 non-hematologic, intolerable toxicity, related to TKI therapy, that persists for more than a month despite optimal supportive measures, or (iii) grade 3-4 hematologic toxicity, related to TKI therapy, that is unresponsive to supportive measures and would require dose reductions below the accepted minimal effective dose, (iv) any life-threatening grade 4 non-hematological toxicity related to TKI therapy.

4. Variable Responses in Different Tissues

Case Number 2. A 54-year-old man with a history of stage IV papillary thyroid carcinoma was seen at our institution. He developed progressive disease that was noted to be nonavid to radioactive iodine. He was initiated on a clinical trial investigating a TKI in metastatic progressive thyroid carcinoma. He developed an excellent response (48% decrease in target lesion by RECIST), but his spinal bone metastasis continued to progress and became symptomatic (Figures 2(a) and 2(b)). His TKI therapy was held, and his progressive bone lesion was treated with external beam radiation. Due to overall favorable response in soft tissues, the TKI was restarted. The patient is still on therapy 24 months later with stabilization of disease in his bone and soft tissue lesions.

This case illustrates two points. First, tumor regression in response to TKI therapy can occur in some organs but not in other areas in the same patient. Additionally, TKI therapy can be continued in a patient with differential responses in various organs provided that local therapy is initiated for the region of progressive disease. This case is not unique; this scenario of varying responses to therapy in different organs is often encountered in metastatic thyroid cancer patients treated with TKI therapy. For example, lung metastases respond more favorably to sorafenib and sunitinib than do bone or pleura [42]. It has been noted that TKIs may lead to varying responses in different tissue sites in other cancers as well [43] and that continuation of systemic therapy after appropriate local therapy could be beneficial [44]. This differential response may not be unique to TKIs [45]. The pathophysiologic mechanism behind this variable response is not well elucidated. Some theories include host, tumor, and stroma factors. Resistance to TKI therapy has proven mechanisms in tumor and stroma as well. Some postulated theories include varying hepatocyte growth factor (HGF), VEGF receptors or serum levels, decreased drug bioavailability in certain organs, and organ-specific tumor resistance.

Until mechanisms are better elucidated to direct therapy for organ-specific TKI selection, consideration should be given to local therapies for areas of progressive disease. Clinically, one should consider irradiating bone lesions (especially if symptomatic) if they progress on TKI therapy. If a bone lesion is threatening vital structures (i.e., the spinal cord), consideration should be given to treating the bone lesion prior to TKI therapy. This may avoid a drug hold later and further compromise of vital structures. In general, the TKI is held during radiation therapy, although there are upcoming trials that may inform us differently. Bony metastatic lesion may also be treated with bisphosphonates or denosumab. This may decrease pain in the bony lesions or may decrease rate of progression, although trials are needed to determine efficacy of these therapies and frequency of dosing.

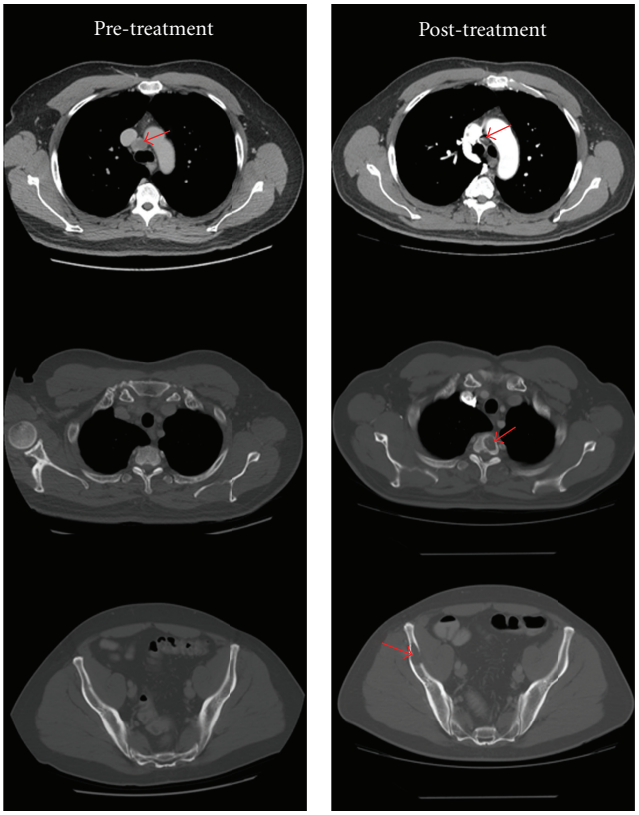

(a) (b)

Figure 2: Patient with partial response in lymph nodes but progression in bone. CT scans before (a) and after (b) 6 months of therapy with a TKI. The patient had a partial response in mediastinal and hilar adenopathy but progression in bone with cortical destruction. The patient's bone lesions were irradiated, and he was restarted on the TKI. The patient continues on the TKI after 24 months and has no further evidence of progression.

5. Sequential Use of TKIs

The former belief that if a patient has progressed through one TKI, he/she will fail with another TKI is false and outdated. Due to the many overlapping targets it was assumed that there would be complete cross-resistance. There is increasing evidence that with sequential application of these drugs, a patient who had progressive disease with one TKI may still

respond to the next one. In a cohort of metastatic renal cell carcinoma treated with sunitinib after progression through sorafenib, the response rate (or efficacy) seen with second-line sunitinib after sorafenib was similar to that of first line sunitinib [46]. Investigations are under way to determine the best order for sequential TKI and other targeted therapies.

6. Summary

Drug development in oncology has led to several new targeted agents which have demonstrated efficacy in progressive thyroid cancer. Although it was initially thought that these drugs would prove to be less toxic than cytotoxic chemotherapy, the fact that these drugs have many off-target effects and the likelihood that most patients will be treated chronically beg the need for further research to better understand the cause of these toxicities and their optimal management. It also underscores the importance of appropriate patient selection.

Patients and physicians must understand the possible adverse effects and weigh the advantages versus the risks of these drugs. Alternatives to systemic therapy for localized disease, such as external beam radiation or embolization should be considered when appropriate. Until prolongation of overall survival can be demonstrated with the use of the drugs, physicians should exercise caution in the selection of patients to undergo therapy with a TKI.

Finally, more optimal drug selection should be personalized for the individual patient and tumor. Further research is needed to determine the ideal targeted therapy for an individual based on the molecular characterization of the tumor, stroma, and host factors. Future targeted therapy development may require that the on-target and off-target effects may be reengineered to enhance antiangiogenesis pathways and avoid cardiovascular, renal, and dermatologic pathways [47].

Acknowledgments

The authors would like to acknowledge Dr. Steven I. Sherman for his assistance with this manuscript.

Disclosures

M. E. Cabanillas, M. I. Hu, and J. B. Durand have no conflicts to disclose. N. L. Busaidy has received research support from Bayer.

References

[1] American Cancer Society, *Cancer Facts and Figures*, American Cancer Society, 2010.

[2] K. C. Bible, V. J. Suman, J. R. Molina et al., "Efficacy of pazopanib in progressive, radioiodine-refractory, metastatic differentiated thyroid cancers: results of a phase 2 consortium study," *The Lancet Oncology*, vol. 11, no. 10, pp. 962–972, 2010.

[3] L. L. Carr, D. A. Mankoff, B. H. Goulart et al., "Phase II study of daily sunitinib in FDG-PET-positive, iodine-refractory differentiated thyroid cancer and metastatic medullary carcinoma of the thyroid with functional imaging correlation," *Clinical Cancer Research*, vol. 16, no. 21, pp. 5260–5268, 2010.

[4] R. T. Kloos, M. D. Ringel, M. V. Knopp et al., "Phase II trial of sorafenib in metastatic thyroid cancer," *Journal of Clinical Oncology*, vol. 27, no. 10, pp. 1675–1684, 2009.

[5] S. A. Wells, B. G. Robinson, R. F. Gagel et al., "Vandetanib (VAN) in locally advanced or metastatic medullary thyroid cancer (MTC): a randomized, double-blind phase III trial (ZETA)," *Journal of Clinical Oncology*, vol. 28, supplement, 2010.

[6] E. T. Lam, M. D. Ringel, R. T. Kloos et al., "Phase II clinical trial of sorafenib in metastatic medullary thyroid cancer," *Journal of Clinical Oncology*, vol. 28, no. 14, pp. 2323–2330, 2010.

[7] J. A. De Souza, N. Busaidy, A. Zimrin et al., "Phase II trial of sunitinib in medullary thyroid cancer (MTC)," *Journal of Clinical Oncology*, vol. 28, supplement, 2010.

[8] Package insert sorafenib (Nexavar). In: Bayer HealthCare and Onyx Pharmaceuticals.

[9] Package insert vandetanib (Vandetanib). In: AstraZeneca Pharmaceuticals.

[10] R. J. Johnson, S. D. Kivlighn, Y. G. Kim, S. Suga, and A. B. Fogo, "Reappraisal of the pathogenesis and consequences of hyperuricemia in hypertension, cardiovascular disease, and renal disease," *American Journal of Kidney Diseases*, vol. 33, no. 2, pp. 225–234, 1999.

[11] D. C. Sane, L. Anton, and K. B. Brosnihan, "Angiogenic growth factors and hypertension," *Angiogenesis*, vol. 7, no. 3, pp. 193–201, 2004.

[12] M. Schmidinger, D. Arnold, C. Szczylik, J. Wagstaff, and A. Ravaud, "Optimizing the use of sunitinib in metastatic renal cell carcinoma: an update from clinical practice," *Cancer Investigation*, vol. 28, no. 8, pp. 856–864, 2010.

[13] M. L. Veronese, A. Mosenkis, K. T. Flaherty et al., "Mechanisms of hypertension associated with BAY 43-9006," *Journal of Clinical Oncology*, vol. 24, no. 9, pp. 1363–1369, 2006.

[14] H. A. J. Struijker Boudier, J. L. M. L. Le Noble, M. W. J. Messing, M. S. P. Huijberts, F. A. C. Le Noble, and H. Van Essen, "The microcirculation and hypertension," *Journal of Hypertension*, vol. 10, no. 7, supplement, pp. S147–S156, 1992.

[15] B. I. Rini, D. P. Cohen, D. R. Lu et al., "Hypertension as a biomarker of efficacy in patients with metastatic renal cell carcinoma treated with sunitinib," *Journal of the National Cancer Institute*, vol. 103, no. 9, pp. 763–773, 2011.

[16] M. L. Maitland, G. L. Bakris, H. R. Black et al., "Initial assessment, surveillance, and management of blood pressure in patients receiving vascular endothelial growth factor signaling pathway inhibitors," *Journal of the National Cancer Institute*, vol. 102, no. 9, pp. 596–604, 2010.

[17] S. Mallick, R. Kanthety, and M. Rahman, "Home blood pressure monitoring in clinical practice: a review," *American Journal of Medicine*, vol. 122, no. 9, pp. 803–810, 2009.

[18] Package insert sunitinib (Sutent). In: Pfizer Labs.

[19] Package insert pazopanib (Votrient). In: GlaxoSmithKline.

[20] A. Y. Khakoo, C. M. Kassiotis, N. Tannir et al., "Heart failure associated with sunitinib malate: a multitargeted receptor tyrosine kinase inhibitor," *Cancer*, vol. 112, no. 11, pp. 2500–2508, 2008.

[21] T. F. Chu, M. A. Rupnick, R. Kerkela et al., "Cardiotoxicity associated with tyrosine kinase inhibitor sunitinib," *The Lancet*, vol. 370, no. 9604, pp. 2011–2019, 2007.

[22] V. Chintalgattu, D. Ai, R. R. Langley et al., "Cardiomyocyte PDGFR-β signaling is an essential component of the mouse

cardiac response to load-induced stress," *Journal of Clinical Investigation*, vol. 120, no. 2, pp. 472–484, 2010.

[23] X. Zhu, S. Wu, W. L. Dahut, and C. R. Parikh, "Risks of proteinuria and hypertension with bevacizumab, an antibody against vascular endothelial growth factor: systematic review and meta-analysis," *American Journal of Kidney Diseases*, vol. 49, no. 2, pp. 186–193, 2007.

[24] T. V. Patel, J. A. Morgan, G. D. Demetri et al., "A preeclampsia-like syndrome characterized by reversible hypertension and proteinuria induced by the multitargeted kinase inhibitors sunitinib and sorafenib," *Journal of the National Cancer Institute*, vol. 100, no. 4, pp. 282–284, 2008.

[25] C. Frangié, C. Lefaucheur, J. Medioni, C. Jacquot, G. S. Hill, and D. Nochy, "Renal thrombotic microangiopathy caused by anti-VEGF-antibody treatment for metastatic renal-cell carcinoma," *The Lancet Oncology*, vol. 8, no. 2, pp. 177–178, 2007.

[26] S. K. Winn, S. Ellis, P. Savage, S. Sampson, and J. E. Marsh, "Biopsy-proven acute interstitial nephritis associated with the tyrosine kinase inhibitor sunitinib: a class effect?" *Nephrology Dialysis Transplantation*, vol. 24, no. 2, pp. 673–675, 2009.

[27] V. Eremina, M. Sood, J. Haigh et al., "Glomerular-specific alterations of VEGF-A expression lead to distinct congenital and acquired renal diseases," *Journal of Clinical Investigation*, vol. 111, no. 5, pp. 707–716, 2003.

[28] C. N. Sternberg, I. D. Davis, J. Mardiak et al., "Pazopanib in locally advanced or metastatic renal cell carcinoma: results of a randomized phase III trial," *Journal of Clinical Oncology*, vol. 28, no. 6, pp. 1061–1068, 2010.

[29] B. Escudier, T. Eisen, W. M. Stadler et al., "Sorafenib in advanced clear-cell renal-cell carcinoma," *New England Journal of Medicine*, vol. 356, no. 2, pp. 125–134, 2007.

[30] R. J. Motzer, T. E. Hutson, P. Tomczak et al., "Overall survival and updated results for sunitinib compared with interferon alfa in patients with metastatic renal cell carcinoma," *Journal of Clinical Oncology*, vol. 27, no. 22, pp. 3584–3590, 2009.

[31] F. A. B. Schutz, T. K. Choueiri, and C. N. Sternberg, "Pazopanib: clinical development of a potent anti-angiogenic drug," *Critical Reviews in Oncology/Hematology*, vol. 77, no. 3, pp. 163–171, 2011.

[32] C. Robert, J. P. Arnault, and C. Mateus, "RAF inhibition and induction of cutaneous squamous cell carcinoma," *Current Opinion in Oncology*, vol. 23, no. 2, pp. 177–182, 2011.

[33] M. E. Lacouture, A. Desai, K. Soltani et al., "Inflammation of actinic keratoses subsequent to therapy with sorafenib, a multitargeted tyrosine-kinase inhibitor," *Clinical and Experimental Dermatology*, vol. 31, no. 6, pp. 783–785, 2006.

[34] D. S. Hong, S. B. Reddy, V. G. Prieto et al., "Multiple squamous cell carcinomas of the skin after therapy with sorafenib combined with tipifarnib," *Archives of Dermatology*, vol. 144, no. 6, pp. 779–782, 2008.

[35] J. P. Arnault, J. Wechsler, B. Escudier et al., "Keratoacanthomas and squamous cell carcinomas in patients receiving sorafenib," *Journal of Clinical Oncology*, vol. 27, no. 23, pp. e59–e61, 2009.

[36] T. Kamba and D. M. McDonald, "Mechanisms of adverse effects of anti-VEGF therapy for cancer," *British Journal of Cancer*, vol. 96, no. 12, pp. 1788–1795, 2007.

[37] C. F. Xu, B. H. Reck, Z. Xue et al., "Pazopanib-induced hyperbilirubinemia is associated with Gilbert's syndrome UGT1A1 polymorphism," *British Journal of Cancer*, vol. 102, no. 9, pp. 1371–1377, 2010.

[38] H. Minami, K. Kawada, H. Ebi et al., "Phase I and pharmacokinetic study of sorafenib, an oral multikinase inhibitor, in Japanese patients with advanced refractory solid tumors," *Cancer Science*, vol. 99, no. 7, pp. 1492–1498, 2008.

[39] J. L. Spivak, "Polycythemia vera: myths, mechanisms, and management," *Blood*, vol. 100, no. 13, pp. 4272–4290, 2002.

[40] B. Y. Y. Tam, K. Wei, J. S. Rudge et al., "VEGF modulates erythropoiesis through regulation of adult hepatic erythropoietin synthesis," *Nature Medicine*, vol. 12, no. 7, pp. 793–800, 2006.

[41] E. Wong, L. S. Rosen, M. Mulay et al., "Sunitinib induces hypothyroidism in advanced cancer patients and may inhibit thyroid peroxidase activity," *Thyroid*, vol. 17, no. 4, pp. 351–355, 2007.

[42] M. E. Cabanillas, S. G. Waguespack, Y. Bronstein et al., "Treatment with tyrosine kinase inhibitors for patients with differentiated thyroid cancer: the M. D. Anderson experience," *Journal of Clinical Endocrinology and Metabolism*, vol. 95, no. 6, pp. 2588–2595, 2010.

[43] E. R. Plimack, N. Tannir, E. Lin, B. N. Bekele, and E. Jonasch, "Patterns of disease progression in metastatic renal cell carcinoma patients treated with antivascular agents and interferon," *Cancer*, vol. 115, no. 9, pp. 1859–1866, 2009.

[44] K. Kim, K. Flaherty, P. Champman et al., "Pattern and outcome of disease progression in phase I study of vemurafenib in patients with metastatic melanoma (MM)," *Journal of Clinical Oncology*, vol. 29, supplement, 2011.

[45] J. A. Gottlieb and C. S. Hill Jr., "Chemotherapy of thyroid cancer with adriamycin. Experience with 30 patients," *New England Journal of Medicine*, vol. 290, no. 4, pp. 193–197, 1974.

[46] K. Zimmermann, A. Schmittel, U. Steiner et al., "Sunitinib treatment for patients with advanced clear-cell renal-cell carcinoma after progression on sorafenib," *Oncology*, vol. 76, no. 5, pp. 350–354, 2009.

[47] A. Fernández, A. Sanguino, Z. Peng et al., "An anticancer C-Kit kinase inhibitor is reengineered to make it more active and less cardiotoxic," *Journal of Clinical Investigation*, vol. 117, no. 12, pp. 4044–4054, 2007.