BioMed Research International

New Trends in Instrumentation and Complex Techniques in Spine Surgery

Guest Editors: Alessandro Landi, Roberto Delfini, Alessandro Ricci, Andrea Barbanera, Giulio Anichini, and Christian Brogna

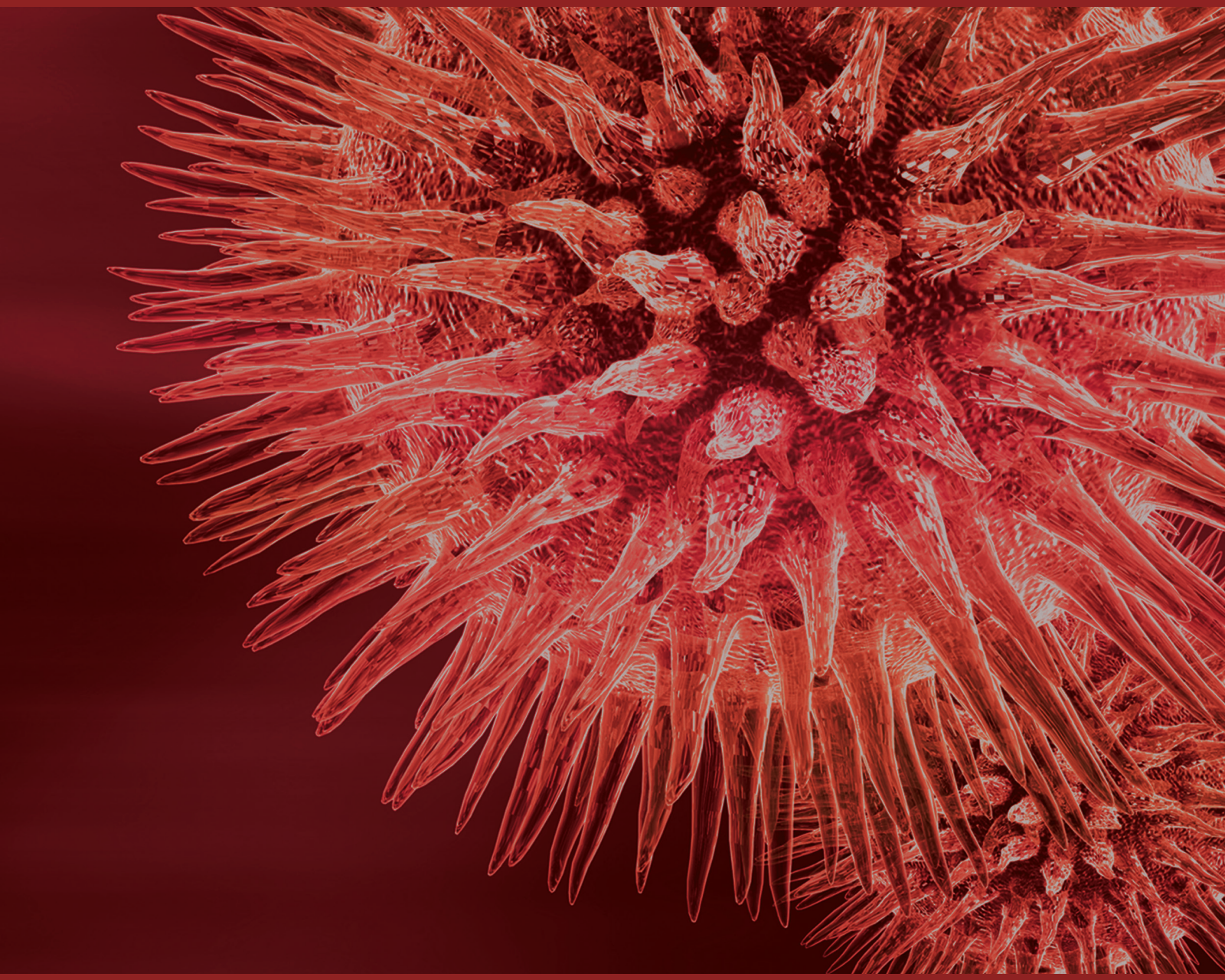

New Trends in Instrumentation and Complex Techniques in Spine Surgery

BioMed Research International

New Trends in Instrumentation and Complex Techniques in Spine Surgery

Guest Editors: Alessandro Landi, Roberto Delfini, Alessandro Ricci, Andrea Barbanera, Giulio Anichini, and Christian Brogna

Contents

Hindawi Publishing Corporation
BioMed Research International
Volume 2015, Article ID 216384, 3 pages
http://dx.doi.org/10.1155/2015/216384

Editorial

New Trends in Instrumentation and Complex Techniques in Spine Surgery

Alessandro Landi,[1] Roberto Delfini,[1] Alessandro Ricci,[2] Andrea Barbanera,[3] Giulio Anichini,[4] and Christian Brogna[5]

[1] *Department of Neurology and Psychiatry, Neurosurgery, "Sapienza" University of Rome, 00181 Rome, Italy*
[2] *Department of Neurosurgery, University of L'Aquila, 67100 L'Aquila, Italy*
[3] *Department of Neurosurgery, Civil Hospital of Alessandria, 15121 Alessandria, Italy*
[4] *Department of Neuroscience, Neurosurgery, Imperial College, Charing Cross Hospital, London SW72AZ, UK*
[5] *Department of Neurosurgery, King's College London, London WC2R 2LS, UK*

Correspondence should be addressed to Alessandro Landi; dott.alessandro.landi@gmail.com

Received 29 November 2015; Accepted 9 December 2015

The overall characteristics of the vertebral column are, namely, elastic resistance to movement, twisting potential, and elastic resistance to load bearing. These aspects reflect the three main functional characteristics of spine: motility in all the spatial planes, passive and active resistance to the axial load, and elastic resistance to excessive degrees of movement. In light of this, we can assert that motility at the level of a single metamere should be interpreted not only merely as movement on the three planes but also, and above all, as elastic resistance to dynamic stress on these three planes. In fact, metameric movement depends on an active motility, involving the intervertebral disc, the articular masses, and the muscular structures, and a passive motility, involving the disc, ligamentous system, and articular masses. In light of this, the aim of spine surgery is to decompress the neural structures and neutralize excessive movements while preserving as much as possible the physiological biomechanical properties of the metamere involved. Those objectives are mandatory for every type of pathology in which the spine is involved, such as degenerative, traumatic, malformative, and oncologic ones. In light of technical evolution of surgical instruments and software and of recent introduction of new surgical approaches, the future of spinal surgery is changing. The articles contained in the present issue include both reviews and original case-based studies focused on innovative technologies, new surgical techniques, and approaches to the spinal pathology, with the aim of describing experiences, tips and tricks, and lessons learnt.

The need to preserve, as much as possible, the biomechanical characteristics of the spine has become impelling, considering the long term results of the traditional surgery. It has become evident that surgery is effective in symptoms control in the short and medium term, but in the long term it might lead to physiological and biomechanical complications, if the specific spinal anatomical and functional features are not preserved. Considering those results, the research and the technological development in spinal surgery are the main characters of important innovations capable of assisting the work of the surgeon and the wellbeing of the patient. Such innovations are being created in three main specific fields.

Development of New Surgical Techniques. The main aim is to make spine surgery less invasive and safer for the patient, focusing on the reduction of hospitalizing times, the reduction of procedure related risks, and the accelerating of functional recovery. Goals of the new techniques are both the decompressive and the reconstructive phase, generally performed as fusion. The percutaneous MIS and the endoscopic surgery have become always more important in spine surgery. They allow performing traditionally open procedures, such

as microdiscectomy or spinal fusion, through percutaneous and endoscopic approaches extremely minimally invasive and atraumatic for the tissues. Moreover the association of minimally invasive techniques with the operative microscope allows the surgeon to minimize the tissue damage gaining optimal results in terms of outcome [1, 2].

Among the most recent stabilization techniques that are worthy to be mentioned are the "cortical bone trajectory screws." They allow the contextual execution of a stabilization with the insertion of isthmic screws and the decompression through a minimal approach (only few centimeters) [3, 4].

The interarticular stabilization with Facet-Wedge has a role in spinal surgery too. This is a recently developed technique that allows, through the surgical ankyloses of the articular masses, a high strength stabilization [5]. MIS and percutaneous techniques are currently considered the gold standard for the treatment of degenerative, traumatic, and tumoral pathology. Percutaneous pedicle screw fixation in spinal trauma allows a faster functional recovery without requiring external orthesis [6–8]. In tumour surgery, the percutaneous stabilization of primary or metastatic spine tumours allows the patient to undergo adjuvant treatments, such as radiotherapy, in shorter times, with a better improvement in quality of life if compared to the classic standard techniques [7].

The development of new surgical approaches to the spine, such as the lateral approaches XLIF and LLIF [9–12], allows the execution of newer interbody fusion procedures, with a higher rate of fusion. Furthermore, the expansion of motion preservation surgery is revolutionizing the traditional surgical approaches for rigid stabilization and fusion. The creation of dynamic stabilization systems and of disc prosthesis represents the future of spinal surgery, even if the current state of the art needs a further implementation in both technique and materials [13].

Development of New Technologies. The main aim is to give the surgeon new technologies, new materials, and new devices capable of the following:

(1) Giving help during surgery: increasing safety, precision, and reliability of the procedure, focusing on pedicle screw placement (the rate of revision surgery to rectify misplaced screws ranges from 1 to 5%; the additional cost of one revision surgery to correct a misplaced screw ranges from $17,650 to $27,677). There are several technologies available for this function. "Procedurally integrated neuromonitoring" is able to check in every moment and in real time the functions of the neuromuscular structures during pedicle screw placement or other surgical procedures [14]. "Spinal Neuronavigation" plays a very important role in many spine surgery centres, thanks to the possibility of preoperatively planning the whole surgical procedure and making intraoperative changes through a digital elaboration [15, 16]. Very interesting are the "3D Printed Tubular Guides," patient matched guides for pedicle screw placement that are built by a 3D printer on the basis of a preoperative CT scan. This custom-made solution, as also Neuronavigation, provides a more precise and accurate screw insertion, particularly in patients with deformity and alteration of the normal surgical anatomy, and a correct sizing of the screws, reducing the risk of pull-out [16]. The most recently developed device is the "3D Printed Vertebra," a 3D print titanium customized implant for the substitution of one or more vertebral bodies with a prosthesis designed on the patient [17].

(2) Reducing the exposure to ionizing radiations for both patient and surgical staff: worth mentioning are the new "robot based imaging and 3D fluoroscopy" systems, able to perform high quality 3D reconstructions with a robotic C-arm [18]. It can be integrated with the neuronavigation system, with a reduction in the ionizing radiation exposure. Another robotic system developed in spinal surgery is the "Robotic Arm Guidance." This system, based on a preoperative planning developed in a virtual 3D setting, offers a high accuracy in pedicle screw insertion, with a margin of error of 1,5 mm, and can be used in both open and percutaneous procedures [18].

Development of New Materials. The research in the field of new biomaterials is fundamental because implant surgery is the basis for the treatment of many spinal pathologies. The development of materials with a high biocompatibility, with biomechanical characteristics similar to the native tissue and capable of promoting tissue regeneration, is opening new and interesting scenarios [19].

From this point of view, the research for new haemostatic materials is gaining good results, with the development of materials to reduce and control the difficult intraoperative bleedings, often related to postoperative consequences for the patient [20].

Moreover, the efforts to find new osteoinductive materials, such as nanomolecular hydroxyapatite, might result in a faster and more physiological ossification, respecting the biomechanical characteristics and reducing time of hospitalization and related expense [21].

Conclusions. Novel technologies actually are developing to help the surgeon to perform a most accurate, safe, and adequately planned surgery and to reduce the exposure to ionizing radiations. Instead new techniques are developing as an alternative to standard surgical approaches with specific surgical indications, with the aim of reducing tissue damage, length of hospitalization, and postoperative pain, and of promoting a faster functional restoration. New trends in spinal surgery are going towards a customization of the implants, tailored to the single patient, and towards minimally invasive, percutaneous, and endoscopic surgery. Unfortunately behind every new technology and technique there is a constant pressure of the companies. Clearly, in light of this, any of them can be validated only by experience, follow-up, and an accurate risk-benefit ratio. We hope that this special issue would shed light on major innovative trends and complex techniques in spinal surgery and attract attention by the scientific

community to pursue further investigations leading to the rapid implementation of these innovations in the spinal fields.

Acknowledgments

We would like to express our appreciation to all the authors for their informative contributions and the reviewers for their support and constructive critiques in making this special issue possible.

Alessandro Landi
Roberto Delfini
Alessandro Ricci
Andrea Barbanera
Giulio Anichini
Christian Brogna

References

[1] U. Hubbe, P. Franco-Jimenez, J. H. Klingler, I. Vasilikos, C. Scholz, and E. Kogias, "Minimally invasive tubular microdiscectomy for recurrent lumbar disc herniation," *Journal of Neurosurgery: Spine*, pp. 1–6, 2015.

[2] T. Sanusi, J. Davis, N. Nicassio, and I. Malik, "Endoscopic lumbar discectomy under local anesthesia may be an alternative tomicrodiscectomy: a single centre's experience using the far lateral approach," *Clinical Neurology and Neurosurgery*, vol. 139, pp. 324–327, 2015.

[3] Y. T. Akpolat, S. İnceoğlu, N. Kinne, D. Hunt, and W. K. Cheng, "Fatigue performance of cortical bone trajectory screw compared to standard trajectory pedicle screw," *Spine*, 2015.

[4] K. Phan, J. Hogan, M. Maharaj, and R. J. Mobbs, "Cortical bone trajectory for lumbar pedicle screw placement: a review of published reports," *Orthopaedic Surgery*, vol. 7, no. 3, pp. 213–221, 2015.

[5] A. Landi, B. Fazzolari, N. Marotta, and R. Delfini, "Facet wedge fixation in lumbar spine degenerative pathology: a new option for minimally-invasive posterior approach?" *Orthopedic & Muscular System: Current Research*, vol. 4, article e115, 2015.

[6] M. Pishnamaz, S. Oikonomidis, M. Knobe, K. Horst, H. C. Pape, and P. Kobbe, "Open versus percutaneous stabilization of thoracolumbar spine fractures: a short-term functional and radiological follow-up," *Acta Chirurgiae Orthopaedicae et Traumatologiae Cechoslovaca*, vol. 82, no. 4, pp. 274–281, 2015.

[7] R. J. Mobbs, A. Park, M. Maharaj, and K. Phan, "Outcomes of percutaneous pedicle screw fixation for spinal trauma and tumours," *Journal of Clinical Neuroscience*, 2015.

[8] A. Landi, N. Marotta, C. Mancarella, M. C. Meluzio, A. Pietrantonio, and R. Delfini, "Percutaneous short fixation vs conservative treatment: comparative analysis of clinical and radiological outcome for A.3 burst fractures of thoraco-lumbar junction and lumbar spine," *European Spine Journal*, vol. 23, supplement 6, pp. S671–S676, 2014.

[9] I. Cheng, M. Briseño, R. T. Arrigo, N. Bains, S. Ravi, and A. Tran, "Outcomes of two different techniques using the lateral approach for lumbar interbody arthrodesis," *Global Spine Journal*, vol. 5, no. 4, pp. 308–314, 2015.

[10] K. Phan, P. J. Rao, D. B. Scherman, G. Dandie, and R. J. Mobbs, "Lateral lumbar interbody fusion for sagittal balance correction and spinal deformity," *Journal of Clinical Neuroscience*, vol. 22, no. 11, pp. 1714–1721, 2015.

[11] A. Landi, F. Gregori, C. Mancarella et al., "Lumbar spinal degenerative 'microinstability': hype or hope? Proposal of a new classification to detect it and to assess surgical treatment," *European Spine Journal*, vol. 24, pp. 872–878, 2015.

[12] A. Landi, F. Gregori, N. Marotta, P. Donnarumma, and R. Delfini, "Hidden spondylolisthesis: unrecognized cause of low back pain? Prospective study about the use of dynamic projections in standing and recumbent position for the individuation of lumbar instability," *Neuroradiology*, vol. 57, no. 6, pp. 583–588, 2015.

[13] A. Landi, "Elastic resistance of the spine: why does motion preservation surgery almost fail?" *World Journal of Clinical Cases*, vol. 1, no. 4, pp. 134–139, 2013.

[14] Y. Takata, T. Sakai, K. Higashino et al., "State of the art: intraoperative neuromonitoring in spinal deformity surgery," *The Journal of Medical Investigation*, vol. 62, no. 3.4, pp. 103–108, 2015.

[15] S. Kapoor, R. Sharma, S. Garg, R. Jindal, R. Gupta, and A. Goe, "Navigated pedicle screw placement using computed tomographic data in dorsolumbar fractures," *Indian Journal of Orthopaedics*, vol. 48, no. 6, pp. 555–561, 2014.

[16] A. Landi, C. Mancarella, F. Gregori, and R. Delfini, "Spinal neuronavigation and 3D-printed tubular guide for pedicle screw placement: a really new tool to improve safety and accuracy of the surgical technique?" *Journal of Spine*, vol. 4, no. 5, article e118, 2015.

[17] N. Xu, F. Wei, X. Liu et al., "Reconstruction of the upper cervical spine using a personalized 3D-printed vertebral body in an adolescent with ewing sarcoma," *Spine*, 2015.

[18] N. Lonjon, E. Chan-Seng, V. Costalat, B. Bonnafoux, M. Vassal, and J. Boetto, "Robot-assisted spine surgery: feasibility study through a prospective case-matched analysis," *European Spine Journal*, pp. 1–10, 2015.

[19] A. Landi, R. Tarantino, N. Marotta et al., "The use of platelet gel in postero-lateral fusion: preliminary results in a series of 14 cases," *European Spine Journal*, vol. 20, supplement 1, pp. 61–67, 2011.

[20] A. Landi, F. Gregori, N. Marotta, and R. Delfini, "Efficacy, security, and manageability of gelified hemostatic matrix in bleeding control during thoracic and lumbar spine surgery: FloSeal versus surgiflo," *Journal of Neurological Surgery Part A: Central European Neurosurgery*, 2015.

[21] B. Huang, Y. Yuan, S. Ding et al., "Nanostructured hydroxyapatite surfaces-mediated adsorption alters recognition of BMP receptor IA and bioactivity of bone morphogenetic protein-2," *Acta Biomaterialia*, vol. 27, pp. 275–285, 2015.

Hindawi Publishing Corporation
BioMed Research International
Volume 2015, Article ID 160237, 8 pages
http://dx.doi.org/10.1155/2015/160237

Research Article

Computer Simulation and Analysis on Flow Characteristics and Distribution Patterns of Polymethylmethacrylate in Lumbar Vertebral Body and Vertebral Pedicle

Da Liu,[1] Xu-li Liu,[2] Bo Zhang,[1] Dong-fa Liao,[1] Zhi-qiang Li,[1] Jiang-jun Zhou,[3] Xia Kang,[1] Wei Zheng,[1] and Wei Lei[4]

[1] *Department of Orthopaedics, Chengdu Military General Hospital, No. 270, Rongdu Avenue, Jinniu District, Chengdu, Sichuan 610083, China*
[2] *Department of Orthopaedics, Naval Hospital, No. 6, Mazhang District, Zhanjiang, Guangdong 524096, China*
[3] *Department of Orthopaedics, Hospital of Nanjing Military Region, No. 4, Hudong Street, Yingtan, Jiangxi 335000, China*
[4] *Department of Orthopaedics, Xijing Hospital, Fourth Military Medical University, No. 15, Changle West Road, Xi'an, Shaanxi 710032, China*

Correspondence should be addressed to Da Liu; liuda313@163.com and Wei Lei; leiweispine@163.com

Received 3 August 2015; Accepted 16 November 2015

Academic Editor: Alessandro Landi

This study was designed to analyze the flow and distribution of polymethylmethacrylate (PMMA) in vertebral body through computer simulation. Cadaveric lumbar vertebrae were scanned through electron beam tomography (EBT). The data was imported into Mimics software to build computational model. Vertebral body center and junction of pedicle and vertebral body were chosen as injection points. Silicone oil with viscosity of 100,000 cSt matching with PMMA bone cement was chosen for injection. The flow and distribution of silicone oil were analyzed using Fluent software. In vertebral body, silicone oil formed a circle-like shape centered by injection point on transverse and longitudinal sections, finally forming a sphere-like shape as a whole. Silicone oil diffused along lateral and posterior walls forming a circle-like shape on transverse section centered by injection point in pedicle, eventually forming a sphere-like shape as a whole. This study demonstrated that silicone oil flowed and diffused into a circle-like shape centered by injection point and finally formed a sphere-like shape as a whole in both vertebral body and pedicle. The flow and distribution of silicon oil in computational model could simulate PMMA distribution in vertebral body. It may provide theoretical evidence to reduce PMMA leakage risk during percutaneous vertebroplasty.

1. Introduction

Percutaneous vertebroplasty (PVP) is currently a common and effective treatment for vertebral lesions (e.g., high risk osteoporotic vertebrae, osteoporotic vertebral fractures, and vertebral tumor) [1–4]. However, bone cement leakage is one of the most common and serious complications [5–7]. Unclearness of the flow characteristics and distribution patterns of bone cement in the vertebral body is the key factor of this complication. For this reason, the related studies on the flow characteristics and distribution pattern of PMMA in the vertebral bodies were necessary to perform to provide theoretical basis to decrease the cement leakage risk in PVP [8–11].

In this study, the process of PMMA injection into vertebral body was simulated by computer program and the flow characteristics and distribution pattern of PMMA were further analyzed and measured using related software. We tend to explore the flow characteristics and distribution pattern of bone cement in vertebral body aiming at reducing the cement leakage risk during PVP.

2. Materials and Methods

2.1. Specimens. Vertebral specimens (L1–L4) were collected from four fresh cadavers (3 males and 1 female) aged from 24 to 38 years (average 31 years) provided by the Department

of Anatomy of Fourth Military Medical University. All specimens were examined by X-ray analysis to exclude vertebral fracture, deformity, and osteolysis resulting from malignancy. Surrounding soft tissue was then removed and single lumbar vertebral bodies were separated from intervertebral discs. Vertebral bodies were degreased using 95% alcohol and stored in a freezer at −76°C for later use.

2.2. Computational Modeling. Continuous electron beam tomography (EBT) (GEImatronC-150EBCT, USA) scan was performed on the vertebrae (L1–L4) collected previously. Scanning parameters were as follows: slice thickness 2 mm, slice increment 2 mm, scan time 0.3 s, tube voltage 130 kV, and electric current 620 mA. The acquired EBT data were then imported into Mimics software (V10.01, Materialise, Belgium), and 3D reconstruction was performed after bone mineral density CT value was selected. The average value of vertebral shape was chosen to simulate computational models of vertebral body shape (appendix of vertebra excluded). Vertebral bodies were cut into pieces and one piece of every vertebra was observed by scanning electron microscope (SEM) to measure the poriness and average pore diameter. The poriness of vertebra samples in this study was measured to be about 70–80%, and the average poriness in computational model was 75% according to the related literatures. The average pore diameter was 0.90 ± 0.22 mm.

Silicone oil with viscosity of 100,000 cSt (Dow Corning, USA) matching with the PMMA was chosen for injection. The unsteady incompressible viscous laminar flow in the porous medium was used as a flow model to analyze the flow characteristics and distribution pattern of PMMA inside the vertebral bodies. Due to the flow characteristics and boundary conditions, Darcy Law ($\nabla P = -(\mu/\alpha)\vec{v}$) was chosen as the constitutive equation in the transfer process of porous medium. Numerical simulation of the injecting and flowing of PMMA was performed by Fluent software (V6.3, ANSYS, USA), and the flow characteristics and distribution patterns of PMMA were analyzed using Euler's method.

2.3. Simulation and Analysis of Silicone Oil Distribution in Vertebral Body. The posterior wall and physical center of the vertebral model were selected as the insertion point and the injection point, respectively. Silicone oil with a viscosity of 100,000 cSt was injected at the physical center inside the vertebral body. As shown in Figure 1, the physical center of the vertebral body was also set as the origin of a 3D coordinate system with the long axis of the vertebral body as y-axes, short axis as x-axes, and vertical axis as z-axes. During the analysis, transverse section through the injection point was set as the datum plane (plane 1, $z = 0$) of the vertical axis, defined as positive above the datum plane and negative below the datum plane. Two additional symmetric transverse sections (plane 2, $z = 0.002$; plane 3, $z = -0.002$) were selected to simulate and analyze the flow characteristics and distribution patterns of silicon oil on the transverse sections in vertebral body. Longitudinal section through the injection point was set as the datum plane (plane 6, $y = 0$) of the long axis, defined as positive on the right and negative on the left. Similarly, two additional symmetric longitudinal sections

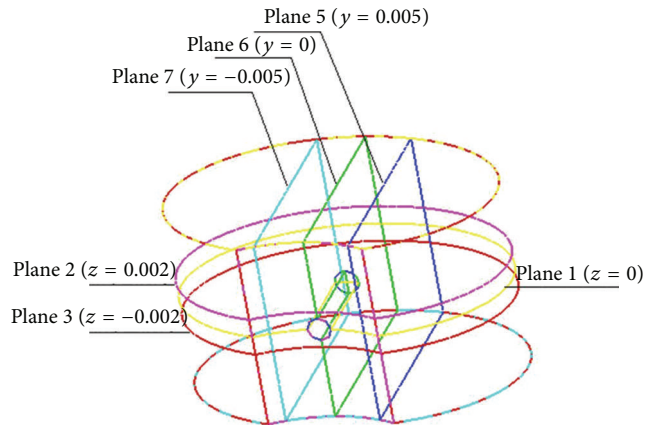

Figure 1: Spatial structure of a vertebral body and the observing sections.

(plane 7, $y = -0.005$; plane 5, $y = 0.005$) were selected to simulate and analyze the flow characteristics and distribution patterns of silicon oil on the longitudinal sections in vertebral body. Diameters of the distribution range on both transverse and longitudinal sections were calculated.

2.4. Simulation and Analysis of Silicone Oil Distribution in Pedicle. The junction of the pedicle and the vertebral body was selected as the injection point. Silicone oil with a viscosity of 100,000 cSt was injected at this point to simulate injection in pedicle. The injection point was set as the origin of a 3D coordinate system with the long axis of the vertebral body as y-axes, short axis as x-axes, and vertical axis as z-axes. During the analysis, transverse section through the injection point was set as the datum plane (plane 1, $z = 0$) of the vertical axis, defined as positive above the datum plane and negative below the datum plane. Two additional symmetric transverse sections (plane 2, $z = 0.002$; plane 3, $z = -0.002$) were selected to simulate and analyze the flow characteristics and distribution patterns of silicon oil on the transverse sections in vertebral pedicle. Diameters of the distribution range on transverse sections were also calculated. The transverse section (plane 4, $z = 0.0097$) 0.3 mm distant to the upper endplate was selected to simulate and analyze the flow and distribution of silicon oil when it reaches the endplate wall. Diameters of the transverse distribution range were also calculated. The ring-shaped sections of lateral and posterior walls of vertebral body around the injection point were selected to analyze the flow and distribution of silicon oil when it reaches lateral vertebral wall and posterior vertebral wall, respectively.

3. Results

3.1. Silicon Oil Distribution on Transverse Sections in Vertebral Body. With gradual injection in vertebral body, as shown in Figure 2, silicon oil diffused into the surrounding area centered by the injection point and formed a circle-like shape on plane 1. Meanwhile, on both plane 2 and plane 3, silicon oil flowed into the surrounding area forming a circle-like shape centered by the intersection points of vertical axis to

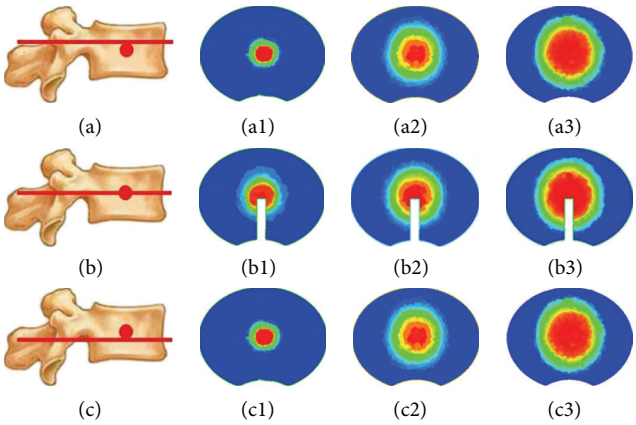

Figure 2: Simulation of silicon oil distribution on transverse section in vertebral body. (a), (b), and (c) represent plane 2, plane 1, and plane 3, respectively. (1), (2), and (3) represent 1 s, 4 s, and 7 s after injection.

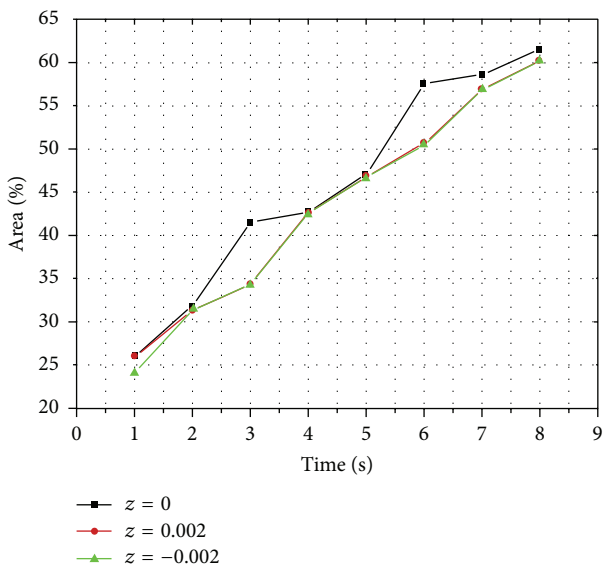

Figure 3: Line chart of silicon oil percentage of distribution area and time on transverse sections in vertebral body.

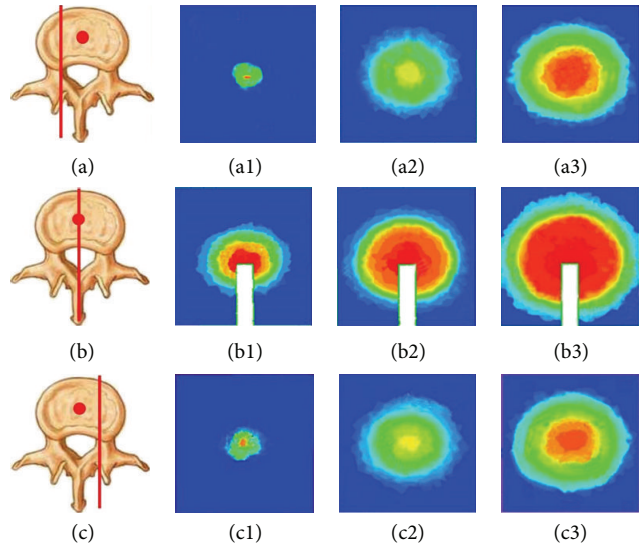

Figure 4: Simulation of silicon oil distribution on longitudinal sections in vertebral body. (a), (b), and (c) represent plane 7, plane 6, and plane 5, respectively. (1), (2), and (3) represent 1 s, 4 s, and 7 s after injection.

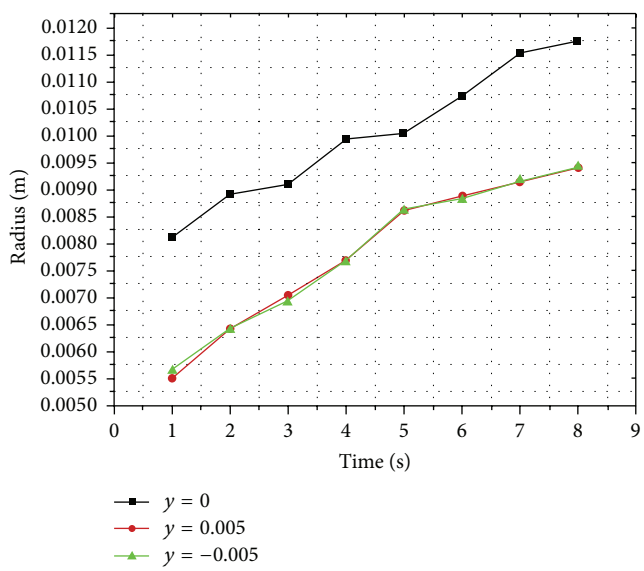

Figure 5: Line chart of silicon oil distribution radius and time on longitudinal sections in vertebral body.

the transverse section through the injection point and these two planes. The volume concentration of silicon oil decreased gradually from the center to the surrounding area at each time point and on each transverse section (Figure 2). At each time point, there was similar distribution area percent of silicon oil between plane 2 and plane 3, while there was the largest distribution area on plane 1 compared with the other two planes at most time points (Figure 3). The distribution area of silicon oil on plane 1 was similar to those on both plane 2 and plane 3 at few time points (Figure 3).

3.2. Silicon Oil Distribution on Longitudinal Sections in Vertebral Body. With the gradual injection in vertebral body, as shown in Figure 4, the silicon oil diffused into the surrounding area centered by the injection point and formed a circle-like shape on plane 6. Meanwhile, on both plane 7 and plane 5, silicon oil flowed into the surrounding area forming a circle-like shape centered by the intersection points of vertical axis to the longitudinal section through the injection point and these two planes. The volume concentration of silicon oil decreased gradually from the center to the surrounding area at each time point and on each longitudinal section (Figure 4). At each time point, there was similar distribution radius of silicon oil between both plane 5 and plane 7, while there was the largest distribution radius on plane 6 compared with the other two planes (Figure 5).

Based on the distribution of silicone oil on both transverse and longitudinal sections, the silicone oil flowed into

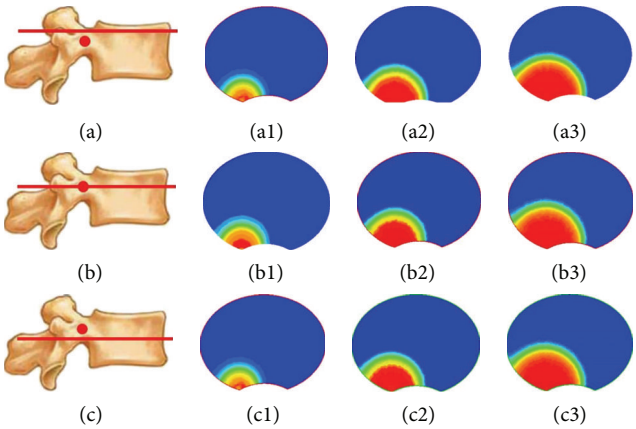

Figure 6: Simulation of silicon oil distribution on horizontal sections in pedicle. (a), (b), and (c) represent plane 2, plane 1, and plane 3, respectively. (1), (2), and (3) represent 1 s, 4 s, and 7 s after injection.

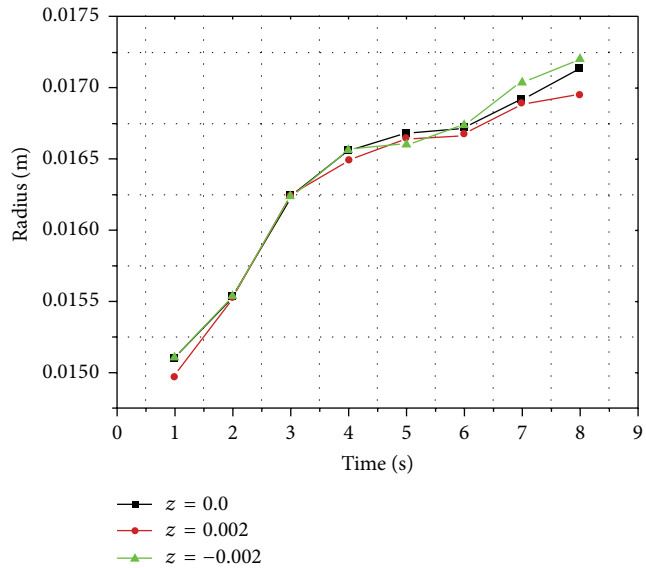

Figure 7: Line chart of silicon oil distribution radius and time on transverse sections in pedicle.

a circle-like shape on plane and eventually formed a sphere-like shape as a whole in vertebral body.

3.3. Silicon Oil Distribution on Transverse Sections in Pedicle. With gradual injection in pedicle, as shown in Figure 6, silicon oil flowed into the surrounding area centered by the injection point and diffused peripherad along the wall after reaching the vertebral wall, eventually forming a circle-like shape. Meanwhile, on both plane 2 and plane 3, silicon oil flowed into the surrounding area and diffused peripherad along the wall after reaching the vertebral wall forming a circle-like shape centered by the intersection points of vertical axis to the transverse section through the injection point and these two planes. The volume concentration of silicon oil decreased gradually from the center to the surrounding area at each time point and on each transverse section (Figure 6). There were no significant differences on silicon oil distribution radius among the three planes at most time points (Figure 7).

3.4. Silicon Oil Distribution on the Upper Endplate. With the gradual injection, as shown in Figure 8, it was found that appearance of silicon oil was earlier on plane 4 than that on upper endplate. It flowed into the surrounding area and diffused peripherad along the wall after reaching the vertebral wall forming a circle-like shape centered by the intersection points of vertical axis to the transverse section through the injection point and plane 4. The volume concentration of silicon oil decreased gradually from the center to the surrounding area at each time point on both upper endplate and plane 4. Distribution pattern of silicon oil on the upper endplate is smaller than that on plane 4 (Figure 8). At all time points, silicon oil distribution radius on upper endplate was less than that on plane 4 (Figure 9).

3.5. Silicon Oil Distribution on the Lateral and Posterior Walls. Silicon oil was found on both lateral and posterior walls soon after injection. As shown in Figure 10, it flowed into

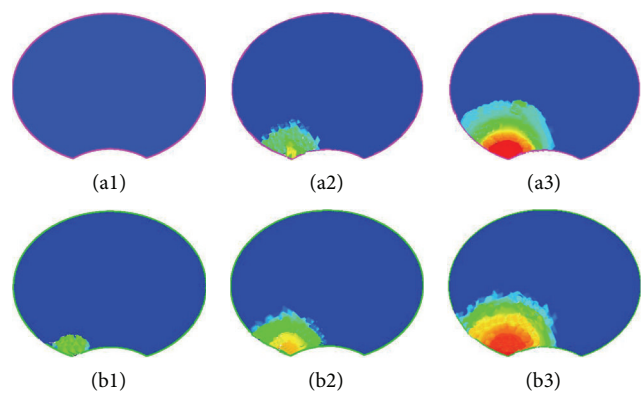

Figure 8: Silicon oil distribution on the upper endplate and plane 4. (a) and (b) represent the upper endplate and plane 4, respectively. (1), (2), and (3) represent 2 s, 4 s, and 7 s after injection.

the surrounding area centered by the injection point as center and diffused peripherad along the wall after reaching the vertebral wall, eventually forming a circle-like shape. The volume concentration of silicon oil decreased gradually from the center to the surrounding area at each time point (Figure 10).

Based on the distribution of silicone oil on transverse sections, upper endplate, and lateral and posterior walls, the silicone oil flowed into a circle-like shape and eventually formed a sphere-like shape as a whole in pedicle.

4. Discussion

Currently, PVP is the main surgical treatment for osteoporotic vertebral compression fractures. Bone cement leakage in adjacent venous system or spinal cord causing nerve root injury and spinal cord compression is the most frequent intraoperative complication [11], which occurs at a rate as high

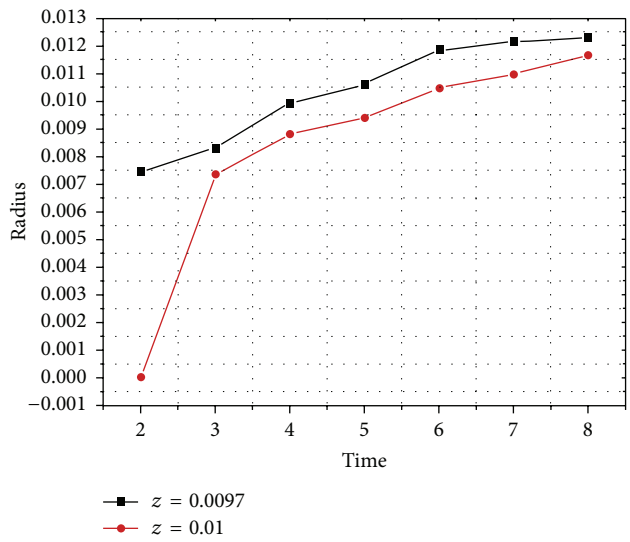

Figure 9: Line chart of silicon oil distribution radius and time on the upper endplate and plane 4.

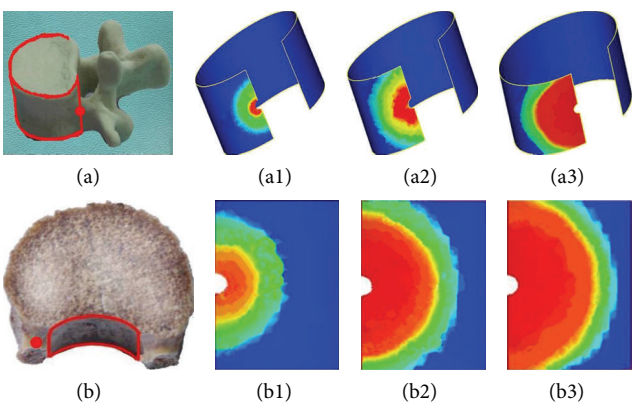

Figure 10: Silicon oil distribution on the lateral and posterior walls. Red points represent injection point; (a) and (b) represent distributions on the lateral and posterior walls, respectively. (1), (2), and (3) represent 1 s, 4 s, and 7 s after injection.

as 65% [5]. Baroud et al. [10, 12] studied the transverse and longitudinal permeability of PMMA infiltrating in human vertebrae and relationship between permeability of PMMA and bone mineral density. They also described the relationship between PMMA infiltration rate within vertebrae and time. Tschirhart et al. [13] analyzed the spinal biomechanical strength and stability augmented with different distribution patterns and different volume of PMMA in percutaneous vertebroplasty through a three-dimensional parametric finite element model. However, no research has yet been performed to study the flow characteristics and distribution patterns of PMMA within the vertebrae after injection, especially using computational simulation and analysis.

PMMA is a nonlinear viscous fluid. Its viscosity is unstable which makes it difficult to analyze its flow characteristics and distribution patterns through the fluid mechanics methods [12, 14, 15]. Therefore, this study mainly focused on fluid distribution ignoring the thermal transmission. Moreover, the flow characteristics and distribution patterns of fluid are mainly influenced by poriness, porosity, permeability, and fluid viscosity, so we chose silicon oil with a viscosity of 100,000 cSt matching that of PMMA for study [16–18]. Computational models were established to simulate the flow characteristics and distribution patterns of silicon oil in vertebral bodies. Since the structure of appendix of vertebra is complicated, this study mainly focused on the modeling of vertebral body (appendix of vertebra excluded) by computer.

Silicon oil flow was regarded as continuous medium in this study. In the real process of injection, a large amount of silicon oil was injected in a very short time making the compression and resistance of silicon oil different at the different injection site and injection time. The flow whose parameters change with time is called unsteady flow. So the flow of silicon oil in this study is regarded as an unsteady process. For this reason, the flow characteristics and distribution patterns of silicon oil can be better described using an unsteady model. Because of the air occupying the dry vertebrae, the silicon oil flow inside vertebrae became a two-phase flow between silicon oil and air. There was no chemical reaction and thermal transmission between these two objects, so chemical equations and energy equations were ignored during the computational modeling. Furthermore, we controlled the flow speed of silicon oil into vertebral body by managing the injection pressure. Due to the high viscosity and low flow speed of silicon oil, the flow of silicon oil inside the vertebrae can be regarded as a three-dimensional laminar flow. Therefore, the unsteady incompressible viscous laminar flow in porous medium was used as flow model in the present study [10, 19–21].

Based on the complexity of porous medium, we made the following hypotheses during modeling: (1) the internal framework of vertebral bodies is incompressible and immovable; (2) physical property parameters of solid, liquid, and gas phases are constants, and the thermal transmission, chemical reactions, and phase change among three phases are not considered; (3) basic flow characteristics are controlled by main items of the basic equation; (4) permeability differences between transverse and longitudinal directions are neglected, and cancellous bone within a vertebral body was considered as isotropic rigid material; (5) no slipping occurred near the solid surface (cortical bone); (6) due to the flow characteristics and boundary conditions, Darcy Law ($\nabla P = -(\mu/\alpha)\vec{v}$) was chosen as the constitutive equation in the transfer process of porous medium [19, 22].

Fluent (V6.3, ANSYS) software was used to perform numerical simulation of the flow process. The boundary conditions and initial conditions should be determined firstly. Boundary conditions included the following: vertebral body was considered as elliptical cylinder composed of surface layer with cortical bone and inner space filled with cancellous bone. Because of the very small porosity of cortical bone, the permeability of cortical bone was considered as 0. The vertebral body was simplified to the model with a solid surface and porous medium inside. Initial conditions were as follows: before the injection, porous medium within the vertebral bodies was filled with air (i.e., volume fraction was 1)

and no silicon oil existed in porous medium (i.e., fluid volume fraction was 0). Fluid flow was described through methods of mathematical physics, and the motion state and evolution of fluid were described by a group of continuous functions and then analyzed through mathematical methods. We used Euler's methods to change the physical parameters of fluid on different spaces and at different time points into the functions of fixed coordinate and time. Streamlines were then used to transfer the flowing mathematical descriptions into flowing intuitional images [9, 23, 24].

Because of no significant differences on permeability and diffusibility between transverse and longitudinal directions, medium inside the vertebral body was considered as isotropic material [25–27]. Although silicon oil has a relatively high viscosity, it can still be regarded as continuous medium according to the basic principles and basic hypothesis of fluid mechanics. When continuous medium flows in the isotropic material, flow characteristics are similar to each other on different spaces and at different time points. According to the numerical simulation results, the pores within vertebral models were occupied by air before the injection. In other words, silicon oil volume fraction in vertebral body was 0 (shown as blue color in Figures 2, 4, 6, 8, and 10). After the injection, silicon oil started to take up the space originally occupied by air and the air was pushed by silicon oil to flow towards all directions. In volume fraction in the center (shown as red color) approach 1, silicon oil began to spread with the surrounding volume fraction decreasing gradually. The results showed a similar circle-like distribution pattern on all sections within the vertebral body. At the same time point, distribution patterns are similar between those on the two symmetric sections paralleled with the transvers section or longitudinal section through injection point. Silicon oil distribution area was the largest on the longitudinal sections through the injection point at all time points comparing with other longitudinal sections. Though distribution area of silicon oil on the transverse section through the injection point was similar to those on the adjacent transverse sections at few time points (Figure 4), it was the largest on the transverse section through injection point compared with other transverse sections at most time points. This might be caused by overclosure of the selected transverse sections which was within the acceptable scope of engineering calculation error, but it also revealed these flow characteristics and distribution patterns in vertebral body. The results showed that silicon oil flowed towards all directions resulting in a circle-like shape centered by the injection points on each section, eventually forming a sphere-like shape as a whole in vertebral body.

In the pedicle, silicon oil flowed forming a circle-like shape centered by the injection points as center on the transverse sections and spread along the wall when it reached the wall. At the same time points, diffusion radius of silicon oil was similar among the two symmetric transverse sections without injection point and the transverse sections through the injection point. This might be caused by overclosure of the selected sections or the anatomical features and space limitations of vertebral pedicles, but it still reflected these distribution patterns in pedicle. Because of the high viscosity of silicon oil, gravity influence can be ignored within a short period of time after injection. Therefore, we chose upper endplate as study object and selected a close transverse section (plane 4) for comparative study during the simulation of silicon oil flow and distribution in pedicle.

When silicon oil reached plane 4, it diffused faster on the transverse plane than on the longitudinal section. This was the reason for the fact that silicon oil was found on plane 4 earlier than on the endplate. So, the distribution radius of silicon oil was obviously different between plane 4 and upper endplate at the first time point after injection (Figure 9). With the increasing amount of injection, silicon oil diffused into the upper endplate. The concentration gradient became the main power of oil flow when silicon oil reached the upper endplate. Therefore, the distribution radius on the upper endplate became approximated to that on plane 4 as time went on. Observation of silicon oil distributions revealed that flow and distribution of silicon oil were found on the lateral and posterior wall of vertebral pedicles as soon as injection was started. It diffused towards all directions and spread along the lateral and posterior wall after reaching the wall, finally forming a circle-like shape. The volume concentration decreased from the center to the surrounding area at each time point. It was demonstrated that silicon oil flowed resulting in a circle-like shape centered by the injection point on all sections in pedicle and spread along the lateral and posterior walls also forming a circle-like shape. It finally formed a sphere-like structure as a whole.

However, there are several limitations in this study. The specimens in our study were degreased which is different from vertebrae with blood, fat tissue, and bone marrow during the operation. Considering the liquidity of blood and permeability of nutrient foramen, a further accurate vertebral model should be constructed to perform a quantitative study on flow characteristics and distribution patterns of PMMA within vertebral body, which will provide more sufficient theoretical basis and technical support to reduce bone cement leakage risk in PVP.

5. Conclusions

Silicone oil flowed and diffused resulting in a circle-like shape centered by the injection point on all sections and it finally formed a sphere-like shape as a whole in vertebral body. It flowed forming a circle-like shape centered by the injection on all sections and spread along the lateral and posterior walls, eventually forming a sphere-like shape as a whole in pedicle. We believe the computational model we constructed is capable of simulating silicon oil flow and distribution in vertebral body. These flow characteristics and distribution patterns can be used to simulate the distribution of PMMA within vertebral bodies, which may provide theoretical basis to reduce cement leakage risk in PVP.

Ethical Approval

All the procedures involving human cadaveric specimens use were conducted according to the ethics guidelines established by local ethics committee. The ethical approval was obtained

from the Ethics Committee of the Fourth Military Medical University and Chengdu Military General Hospital.

Disclosure

Da Liu is the first author, and Xu-li Liu is the co-first author. No benefits in any form have been or will be received from a commercial party directly or indirectly related to the subject of this paper.

Conflict of Interests

The authors have declared that no conflict of interests exists.

Authors' Contribution

Da Liu and Xu-li Liu contributed equally to this study.

Acknowledgments

This study is funded by the National Natural Science Foundation of China (81301606) and the Foundation of Chengdu Military General Hospital (2013YG-B015).

References

[1] M. Mazzantini, P. Carpeggiani, A. d'Ascanio, S. Bombardieri, and O. Di Munno, "Long-term prospective study of osteoporotic patients treated with percutaneous vertebroplasty after fragility fractures," *Osteoporosis International*, vol. 22, no. 5, pp. 1599–1607, 2011.

[2] M. Shengzhong, W. Dongjin, W. Shiqing et al., "Modification of percutaneous vertebroplasty for painful old osteoporotic vertebral compression fracture in the elderly: preliminary report," *Injury*, vol. 43, no. 4, pp. 486–489, 2012.

[3] F. Omidi-Kashani, E. G. Hasankhani, S. Akhlaghi, F. Golhasani-Keshtan, and K. Toosi, "Percutaneous vertebroplasty in symptomatic hemangioma versus osteoporotic compression fracture," *Indian Journal of Orthopaedics*, vol. 47, no. 3, pp. 234–237, 2013.

[4] Z. Yang, D. Yang, L. Xie et al., "Treatment of metastatic spinal tumors by percutaneous vertebroplasty versus percutaneous vertebroplasty combined with interstitial implantation of 125I seeds," *Acta Radiologica*, vol. 50, no. 10, pp. 1142–1148, 2009.

[5] M. J. Nieuwenhuijse, A. R. Van Erkel, and P. D. S. Dijkstra, "Cement leakage in percutaneous vertebroplasty for osteoporotic vertebral compression fractures: identification of risk factors," *Spine Journal*, vol. 11, no. 9, pp. 839–848, 2011.

[6] M. Gstöttner, A. Angerer, R. Rosiek, and C. M. Bach, "Quantitative volumetry of cement leakage in viscosity-controlled vertebroplasty," *Journal of Spinal Disorders and Techniques*, vol. 25, no. 5, pp. E150–E154, 2012.

[7] H. Abdelrahman, A. E. Siam, A. Shawky, A. Ezzati, and H. Boehm, "Infection after vertebroplasty or kyphoplasty. A series of nine cases and review of literature," *The Spine Journal*, vol. 13, no. 12, pp. 1809–1817, 2013.

[8] M. Bohner, B. Gasser, G. Baroud, and P. Heini, "Theoretical and experimental model to describe the injection of a polymethylmethacrylate cement into a porous structure," *Biomaterials*, vol. 24, no. 16, pp. 2721–2730, 2003.

[9] Z. Lian, C.-K. Chui, and S.-H. Teoh, "A biomechanical model for real-time simulation of PMMA injection with haptics," *Computers in Biology and Medicine*, vol. 38, no. 3, pp. 304–312, 2008.

[10] G. Baroud, R. Falk, M. Crookshank, S. Sponagel, and T. Steffen, "Experimental and theoretical investigation of directional permeability of human vertebral cancellous bone for cement infiltration," *Journal of Biomechanics*, vol. 37, no. 2, pp. 189–196, 2004.

[11] M. Stańczyk, "Study on modelling of PMMA bone cement polymerisation," *Journal of Biomechanics*, vol. 38, no. 7, pp. 1397–1403, 2005.

[12] G. Baroud, J. Z. Wu, M. Bohner, S. Sponagel, and T. Steffen, "How to determine the permeability for cement infiltration of osteoporotic cancellous bone," *Medical Engineering and Physics*, vol. 25, no. 4, pp. 283–288, 2003.

[13] C. E. Tschirhart, S. E. Roth, and C. M. Whyne, "Biomechanical assessment of stability in the metastatic spine following percutaneous vertebroplasty: effects of cement distribution patterns and volume," *Journal of Biomechanics*, vol. 38, no. 8, pp. 1582–1590, 2005.

[14] J.-Y. Wang, G. Tozzi, J. Chen, F. Contal, C. Lupton, and J. Tong, "Bone-cement interfacial behaviour under mixed mode loading conditions," *Journal of the Mechanical Behavior of Biomedical Materials*, vol. 3, no. 5, pp. 392–398, 2010.

[15] M. A. K. Liebschner, W. S. Rosenberg, and T. M. Keaveny, "Effects of bone cement volume and distribution on vertebral stiffness after vertebroplasty," *Spine*, vol. 26, no. 14, pp. 1547–1554, 2001.

[16] R. K. Wilcox, "The biomechanics of vertebroplasty: a review," *Proceedings of the Institution of Mechanical Engineers H*, vol. 218, no. 1, pp. 1–10, 2004.

[17] S. M. Belkoff, J. M. Mathis, L. E. Jasper, and H. Deramond, "An ex vivo biomechanical evaluation of a hydroxyapatite cement for use with vertebroplasty," *Spine*, vol. 26, no. 14, pp. 1542–1546, 2001.

[18] Y. Chevalier, D. Pahr, M. Charlebois, P. Heini, E. Schneider, and P. Zysset, "Cement distribution, volume, and compliance in vertebroplasty: some answers from an anatomy-based nonlinear finite element study," *Spine*, vol. 33, no. 16, pp. 1722–1730, 2008.

[19] M. A. Pérez, N. Nuño, A. Madrala, J. M. García-Aznar, and M. Doblaré, "Computational modelling of bone cement polymerization: temperature and residual stresses," *Computers in Biology and Medicine*, vol. 39, no. 9, pp. 751–759, 2009.

[20] D. Waanders, D. Janssen, K. A. Mann, and N. Verdonschot, "The mechanical effects of different levels of cement penetration at the cement-bone interface," *Journal of Biomechanics*, vol. 43, no. 6, pp. 1167–1175, 2010.

[21] Y.-B. Yan, E.-C. Teo, T.-X. Qiu et al., "Finite element study on the amount of injection cement during the pedicle screw augmentation," *Journal of Spinal Disorders and Techniques*, vol. 26, no. 1, pp. 29–36, 2013.

[22] S. B. Kim, Y. J. Kim, T. L. Yoon et al., "The characteristics of a hydroxyapatite-chitosan-PMMA bone cement," *Biomaterials*, vol. 25, no. 26, pp. 5715–5723, 2004.

[23] H. Frei, M. S. Gadala, B. A. Masri, C. P. Duncan, and T. R. Oxland, "Cement flow during impaction allografting: a finite element analysis," *Journal of Biomechanics*, vol. 39, no. 3, pp. 493–502, 2006.

[24] G. Tozzi, Q.-H. Zhang, and J. Tong, "3D real-time micromechanical compressive behaviour of bone-cement interface:

experimental and finite element studies," *Journal of Biomechanics*, vol. 45, no. 2, pp. 356–363, 2012.

[25] J.-C. M. Teo and S.-H. Teoh, "Permeability study of vertebral cancellous bone using micro-computational fluid dynamics," *Computer Methods in Biomechanics and Biomedical Engineering*, vol. 15, no. 4, pp. 417–423, 2012.

[26] D. Janssen, K. A. Mann, and N. Verdonschot, "Micromechanical modeling of the cement-bone interface: the effect of friction, morphology and material properties on the micromechanical response," *Journal of Biomechanics*, vol. 41, no. 15, pp. 3158–3163, 2008.

[27] D. Janssen, K. A. Mann, and N. Verdonschot, "Finite element simulation of cement-bone interface micromechanics: a comparison to experimental results," *Journal of Orthopaedic Research*, vol. 27, no. 10, pp. 1312–1318, 2009.

Hindawi Publishing Corporation
BioMed Research International
Volume 2015, Article ID 417801, 14 pages
http://dx.doi.org/10.1155/2015/417801

Review Article

Lumbar Endoscopic Microdiscectomy: Where Are We Now? An Updated Literature Review Focused on Clinical Outcome, Complications, and Rate of Recurrence

Giulio Anichini,[1] Alessandro Landi,[2] Federico Caporlingua,[2] André Beer-Furlan,[3] Christian Brogna,[4] Roberto Delfini,[2] and Emiliano Passacantilli[2]

[1] *Department of Neuroscience, Neurosurgery, Imperial College of London, Charing Cross Hospital, London, UK*
[2] *Department of Neurology and Psychiatry, Neurosurgery, University of Rome "Sapienza", Rome, Italy*
[3] *Department of Neurological Surgery, Wexner Medical Center, The Ohio State University College of Medicine, Columbus, OH, USA*
[4] *Department of Neurosurgery, King's College of London, London, UK*

Correspondence should be addressed to Giulio Anichini; giulioanichini@gmail.com

Received 7 August 2015; Accepted 5 October 2015

Academic Editor: Panagiotis Korovessis

Endoscopic disc surgery (EDS) for lumbar spine disc herniation is a well-known but developing field, which is increasingly spreading in the last few years. Rate of recurrence/residual, complications, and outcomes, in comparison with standard microdiscectomy (MD), is still debated and need further data. We performed an extensive review based on the last 6 years of surgical series, systematic reviews, and meta-analyses reported in international, English-written literature. Articles regarding patients treated through endoscopic transforaminal or interlaminar approaches for microdiscectomy (MD) were included in the present review. Papers focused on endoscopic surgery for other spinal diseases were not included. From July 2009 to July 2015, we identified 51 surgical series, 5 systematic reviews, and one meta-analysis reported. In lumbar EDS, rate of complications, length of hospital staying, return to daily activities, and overall patients' satisfaction seem comparable to standard MD. Rate of recurrence/residual seems higher in EDS, although data are nonhomogeneous among different series. Surgical indication and experience of the performing surgeon are crucial factors affecting the outcome. There is growing but still weak evidence that lumbar EDS is a valid and safe alternative to standard open microdiscectomy. Statistically reliable data obtained from randomized controlled trials (better if multicentric) are desirable to further confirm these results.

1. Introduction

Endoscopic disc surgery (EDS) is a relatively well-known technique, which has been introduced since the '80s, but shows rapidly expanding interest in the last few years. The concept behind it is to provide a minimally invasive approach to the lumbar spine when treating disc herniations. Ideally, the goal of the developing endoscopic disc surgery is to get the same results obtained using standard microdiscectomy, providing effective treatment, targeted to the nerve decompression and not only focused on pain relief, like in nerve root/peridural injections, but at the same time avoiding discomfort related with open techniques.

Although fascinating, results of this technique are still debated, mostly due to (1) learning curve for surgeons not confident with the endoscopic kit in a spinal environment; (2) rate of recurrences of symptoms/radiological finding, which still seems to be higher compared to standard microdiscectomy; (3) lack of consistent evidence comparing outcomes of endoscopic and microscopic discectomy.

We performed an extensive review of the literature about EDS. The review is focused on introduction and development of the technique over time, results in terms of outcome, recurrence, and complications rate, available evidence reporting comparison between EDS and standard microdiscectomy, and possible future development.

2. Historical Background

First series of EDS are reported from the late '80s. Kambin and Schaffer reported initially successful experience in 88% of patients undergoing percutaneous discectomy [1] and similar results after the introduction of the endoscope in the so-called arthroscopic discectomy [2]. Between the end of the '80s and the beginning of the '90s other authors reported similar results [3–7], with a variable success rate being variable (65–85% of "good results"). All these series reported a combination of posterior-lateral or far lateral approach to the disc through the lateral foramen. This is performed under radiological guidance, with subsequent introduction of cannulated system and endoscope for disc fragment removal.

Consequent diffusion of the technique led to extended series, reported in the mid '90s. With growing surgical experience, several authors started to raise and assess criticisms related with the far lateral percutaneous approach. The main problem concerned the lack of improvement in radicular symptoms, requiring reexploration surgery in 7 to 11% of cases [8–11]. Moreover, as pointed out by Kim and Park in a comparative review, the percutaneous discectomy through a far lateral approach might be limited by anatomical factors, such as presence of iliac crest, large facet joint, or L5 transverse process [12]. To overcome these problems, endoscopic interlaminar approach was subsequently developed and popularized by several authors [13–16]. This is performed by a posterior approach to the disc space from the standard microdiscectomy route, through a window obtained by positioning the cannula into the interlaminar space and removing the disc fragment after opening of the ligamentum flavum.

3. Surgical Technique

As mentioned above, EDS has been broadly practiced, and many variations in name and techniques have been reported. Terminology is quite variable and, as always, different names indicating the same procedure with few variations are reported. However, to sum things up we might say that EDS mainly include two different approaches. The first one is the one we define here as the *transforaminal approach*; possible variations of this name include far lateral endoscopic approach, posterior-lateral endoscopic approach, and arthroscopic far lateral/posterior-lateral approach. The second one is the *interlaminar approach* described by Ruetten et al. [14]. Indications and technique for these approaches are different, and they both require thorough preoperative evaluation.

It is not our intentions to describe the surgical technique in detail, since authoritative textbooks and papers already report it [17]. However, the main basic steps and few important nuances are reported in the following paragraphs.

3.1. Transforaminal Approach

Indications. Indications are intraforaminal disc herniations, extreme lateral/far lateral/extracanalar disc herniations, lateral disc herniations in selected cases, and confidence in the technique (Figure 1).

Contraindications. Contraindications are L5-S1 segment (iliac crest and/or L5 transverse process are obstacles for surgical route), anatomical variations, large median and paramedian disc herniations/cauda equina syndrome (decompression not achievable through this route), caudally or cranially migrated fragments, and elderly patients with stenosis-like picture (even if only on the recess).

Advantages. Minimally invasive approach, lower degree of muscle manipulation/damage, reduced postop back pain, reduced postop fibrosis (both muscle and periradicular), and limited bone decompression prevent risk of postop instability due to excessive removal of facet joint, direct visualization of decompressed root from its extracanalar route.

Disadvantages. Disadvantages are need for experience, learning curve for surgeons used to standard microdiscectomy, progressively more limited movements as the foramen is entered, and no possible treatment for L5-S1 level and median disc herniations.

Surgical Technique. Standard operative conditions are obtained. While usually performed under general anaesthesia for better comfort of both the surgeon and the patient, use of local anaesthesia might be helpful to localize the nerve root intraoperatively. C-arm covered with sterile drape is mandatory throughout the whole procedure. Surgeons, nurses, radiology, and anaesthetics team must wear appropriate protection. Patient is positioned on a standard frame, taking into account not to cause abdominal compression, which might increase venous bleeding. Skin entry point is localized empirically between 10 and 12 cm from the midline; further lateralization might be required in heavyweight patients (Figure 3). Continuous fluoroscopic guidance is used to introduce an 18-gauge needle and to check its position in both anterior-posterior (AP) and lateral projections (Figure 1). The aim of the needle is the triangular working zone, an area of the extracanalar space defined superiorly by the existing root and ganglion, inferiorly by the disc itself, and medially by the lateral margin of the facet joint. In AP projections, pedicle is ideally divided into three lines: lateral, mid, and medial pedicular lines [17]. Ideal positioning of the tip of the needle should be at the level of the mid pedicular line in anterior-posterior projections and inferior margin of the foramen in lateral projection, parallel to the superior end plate of the inferior vertebral body. At this point, needle is replaced with a wire; then skin incision is made around it and the wire is used as a guide to introduce cannula. Cannula is then maintained against the disc fibres and continuous washing of saline through the cannula is used to continuously clean the surgical view. Ideally, a washing system should be integrated with the cannula. Different angle endoscopic optics (30°, 45°, 70°, and 90°) can be used for the inspection and discectomy. Once the endoscope is inserted, discectomy or fragment removal is performed using dedicated forceps, also provided with different angles, which allow resection

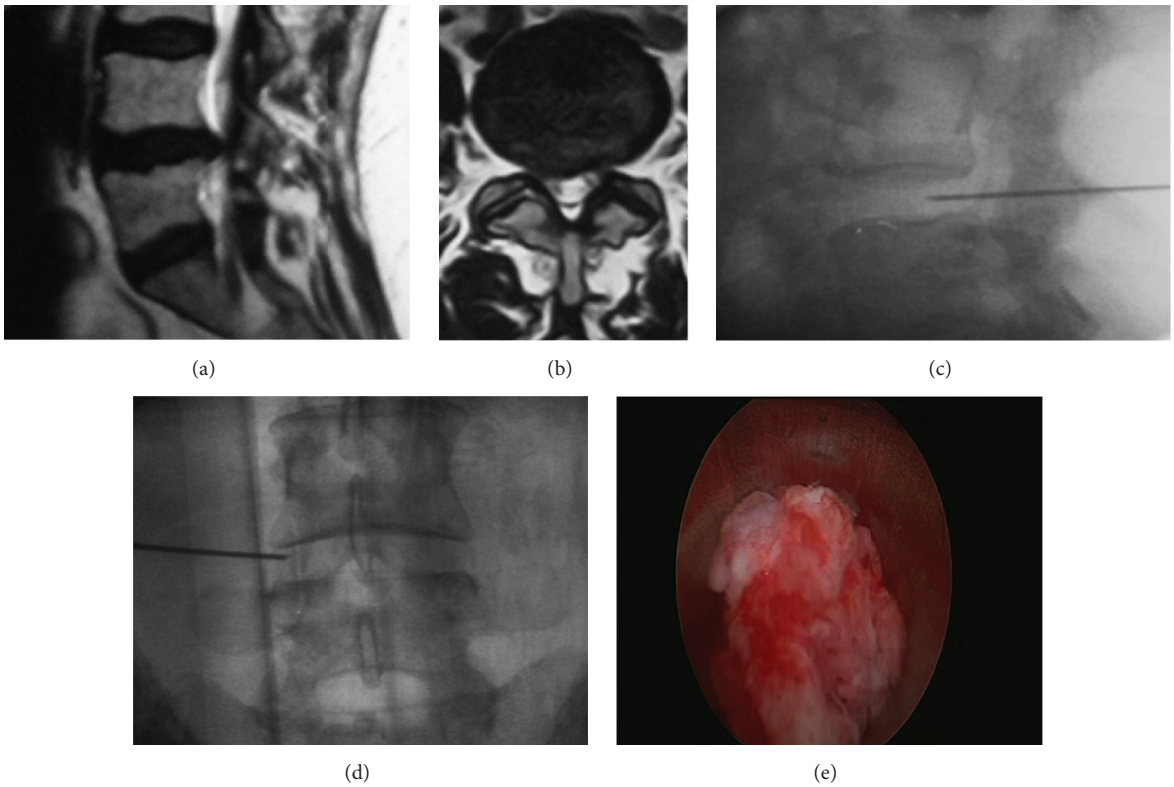

Figure 1: (a-b) Sagittal and axial T2-weighted MRI images of an L4-L5 right disc bulging causing foraminal stenosis. Approach is performed through an entry point located ~7 cm from the midline. (c-d) Intraoperative fluoroscopy and lateral and anteroposterior (AP) projections showing the position of the instrumentation. (e) Fragment of the disc removed from the endoscopic cannula.

in all possible directions. Lateralization of the entry point allows achieving more medial exposure and resection and even removing bulging located into the spinal canal. From this point of view, several variations of the approach have been described, including bilateral and unilateral biportal approaches [18–20], all used to obtain different degree of exposure and discectomy. Once the decompression of the nerve root is satisfactory, haemostasis is performed and instruments are removed. Skin is closed with one or two stitches.

3.2. Interlaminar Approach

Indications. Indications are prolapsed median or paramedian disc herniations, recess/lateral canal stenosis, and synovial cysts.

Contraindications. Contraindications are intra- or extra-foraminal disc herniation, lumbar stenosis, and spinal instability at the same segment.

Advantages. Best access to L5-S1 disc space (as compared with the transforaminal approach), lower degree of muscle manipulation/damage, reduced postop back pain, reduced postop fibrosis (both muscle and periradicular), and limited bone decompression prevent risk of postop instability due to excessive removal of facet joint (Figure 2).

Disadvantages. Disadvantages are being still not ideal for spinal stenosis, need for experience, learning curve for surgeons used to standard microdiscectomy, and higher rate of recurrence.

Surgical Technique. Endoscopic access is determined under fluoroscopic AP guidance; skin incision is made as medial as possible in the craniocaudal midline of the interlaminar window (Figure 3(b)). A dilator is inserted bluntly toward the lateral edge of the interlaminar window as far as the flavum ligament. Dilator must have an oblique direction from the midline, to the lateral edge of the flavum ligament to permit endoscopic access under the zygapophyseal joint. The subsequent part of the operation is performed under lateral fluoroscopic guidance. An operating sheath is inserted with beveled opening directed toward the flavum ligament. Direction in lateral fluoroscopic view must be pointed towards the disc space with the instruments end just upon the facet joint. Dilator is removed and the endoscope is inserted. The further procedure is performed under visual control and constant irrigation. All the endoscopic instruments and radiofrequency bipolar system pass through the working channel. The flavum ligament is clearly exposed with the aid of radiofrequency bipolar and forceps. A lateral incision is made, approximately 5 mm long, up to the zygapophyseal joint. With lateral fluoroscopic guidance being possible to have an easy craniocaudal orientation, medial to lateral

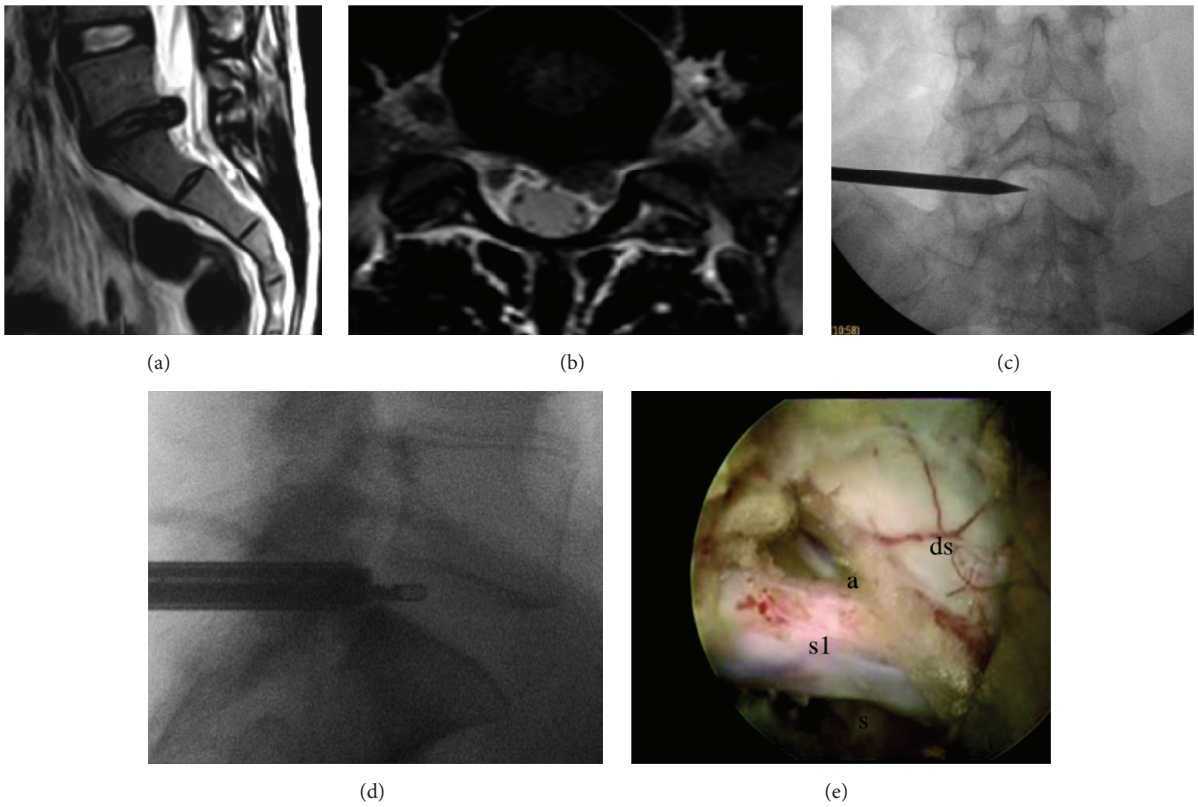

Figure 2: (a-b) Preoperative T2-weighted sagittal and axial MRI showing an L5-S1 disc herniation impinging the left S1 nerve root. (c-d) Intraoperative fluoroscopy showing different phases of the transforaminal approach. AP view: pointer showing the L5-S1 interlaminar window and lateral view showing the radiofrequency bipolar endoscopic probe inside the L5-S1 intervertebral disc. (e) Removal of the herniated disc material has been completed. At the end of the procedure, the dural sac (ds), the S1 nerve root (s1) with its axilla (a), and shoulder (s) can be clearly visualized. Taken from the senior author's personal series.

orientation is obtained reaching the facet joint and touching bone with instruments and dissector (Figure 2). Bone of the ascending facet and superior lamina can be partially resected, thus obtaining a wide exposure of the descending facet. Opening is enlarged using burrs and endoscopic bone punch. After entering the spinal canal the flouting epidural fat is clearly visible; neural structures are exposed. After having clearly recognized the passing nerve root and the dural sac, the operating sheath with beveled opening serves as a second instrument to protect and gently manipulate the neural structures in order to expose and remove the disc herniation. In order to avoid neural damage, particularly in the cranial segment, prolonged lateral displacement of the passing root must be avoided. Traction is performed on intermittent basis only after having clearly gained medial to lateral orientation inside the spinal canal. If gently lateral traction cannot be achieved, drilling of the descending facet can be considered in order to gain more space and achieve a first indirect decompression. At the end of the procedure the passing nerve root must appear clearly decompressed with the fatty lubricating tissue floating around the nervous structures (Figure 2(e)). It is possible to gently retract medially the passing nerve root with a blunt dissector; just make sure all prolapsed disc fragments have been removed.

4. Materials and Methods

There is extensive literature about EDS and multiple surgical series are reported. Many reviews have also been published, although not systematic in most cases, and few clinical trials comparing EDS with standard microdiscectomy.

It was not the purpose of this paper to perform an extensive and omnicomprehensive literature review. For these reasons, with few exceptions, literature review is focused on the last six years. We reviewed all English-written papers about lumbar spine endoscopic microdiscectomy. Papers were collected using PubMed Database, and keywords for Medline were "endoscopic lumbar discectomy". Literature reviews, case series, meta-analysis, randomized controlled trials, case-cohort studies, and prospective and retrospective series were all included. Small series (<10 cases) and case reports were excluded. Series focused on new techniques, disc recurrences, spinal instability, or different techniques were not considered, although some of them are mentioned in the Discussion.

5. Limitations

Literature review was limited to English-written papers and only included the last 6 years of publications; thus it is

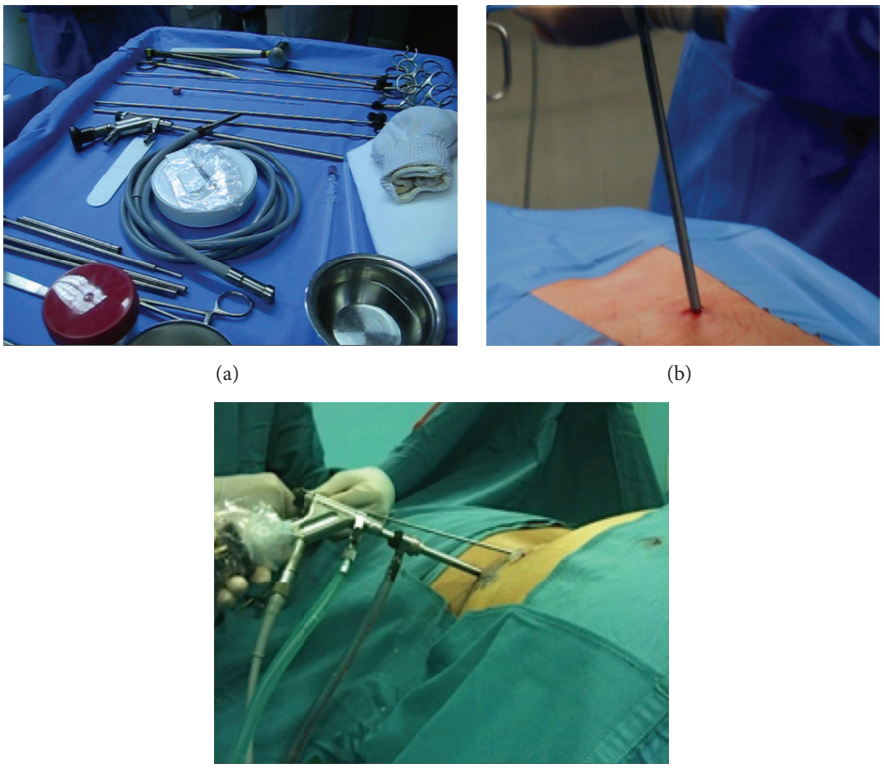

(a) (b) (c)

Figure 3: (a) Instrumentation: light source at the center of the surgical table, endoscopic cannula, and different pituitary forceps adapted for endoscopic use on the top of the picture. (b) Positioning of the endoscope during an interlaminar approach. (c) Positioning of the endoscope during a transforaminal approach, extreme lateral variation.

not intended as systematic review or meta-analysis or as a comprehensive review about this topic.

6. Results

6.1. Case Series. From July 2009 to July 2015, we found 51 series about lumbar endoscopic discectomy reported in the international literature. Main results of each series are reported in Table 1 [21–28, 30–61, 63, 65–72].

Out of this group, 21 articles reported results of surgical series, 5 papers were focused on analysis of surgical technique and its variations, 4 were comparison between endoscopic discectomy and standard microdiscectomy, 5 were focused on complications, and the rest were focused on different topics (learning curve, use of annuloplasty, etc.), Table 1 [21–28, 30–61, 63, 65–72].

Number of patients enrolled varied from 15 [26] to 400 [40]. Most common scales used for assessment and outcome were Visual Analog Scale (VAS), Oswestry Disability Index (ODI), and MacNab criteria. Several Asian authors also used Japanese Orthopedic Association (JOA) scale.

Surgical technique was not always specified, but larger series of patients treated through interlaminar approach were growing through the years. Specifically, both Yadav and Kaushal reported 400 and 300 patients treated through interlaminar approach, respectively [40, 51]. However, this should not be misleading. Indications for transforaminal and interlaminar approaches became more defined over the years. Transforaminal approaches were used mostly for far lateral, foraminal, and extraforaminal disc herniations. Several variations of this technique were reported, including the possibility of reaching the spinal canal by enlarging the discectomy from outside the spinal canal, thus improving the working channel [18, 19]. This approach was partially abandoned with the advent of interlaminar approach, which made it possible to remove even medially located disc fragments. Today, choosing the different approach mostly depends on the experience of the surgeon and accurate selection of patients. As exposed in Table 1, recent series are reporting patients treated with both techniques, but different indications.

Outcomes reported are quite homogeneous among most series. Virtually all authors report a good to excellent outcome in 70 to 90% of patients treated, according to MacNab criteria. Rate of recurrence/residual is by far one of the most debated topics in literature. Interestingly, most series reported a rate of recurrence similar to standard microdiscectomy (2 to 10%). However, results are extremely variable from this point of view. One of the largest series [40] reported 2 patients over 400 showing recurrence at follow-up (0,2%), the other one reporting 10% rate of recurrence on 344 patients [42]. Kulkarni and Sencer reported 1,5% and 5%, on 188

Table 1: Series reported in the literature in the last 6 years. FED: full endoscopic discectomy; MED: microendoscopic discectomy; EDS: endoscopic discectomy; MD: microdiscectomy; TF: transforaminal; IL: interlaminar; OC: outcome; DVT: deep venous thrombosis. *When reported alone, values are referred only to as recurrence rate.

First author	Year	Study	Number of pts.	Techn.	OC measures	Outcome	Recurrence rate/residual/redo*	Complications
Li [21]	2015	EDS, comparison between FED and MED	65	TF and IL	VAS and ODI	No differences, shorter hospital staying in FED group	8,6% FED; 6,7% MED	1 dural tear
Türk [22]	2015	Surgical series EDS	105	TF	VAS and ODI	90,4% pain relief	2 redo surgeries	Not mentioned
Wang [23]	2015	Surgical series EDS	207	TF	VAS, ODI, and MacNab	71–86% excellent OC, age related	3 to 5% age-related	3 dural tears, 1 postop instability
Li [24]	2015	Surgical series EDS	72	IL	VAS, ODI, and MacNab	97% good to excellent OC	1	No complications noted
Sairyo [25]	2014	Surgical series EDS, analysis of complications	100	TF and IL	—	—	—	2% nerve injury; 1% postop hematoma
Liao [26]	2014	Surgical series EDS	15	TF	VAS and MacNab	93% good to excellent OC	—	—
Sencer [27]	2014	Surgical series EDS	163	TF and IL	VAS and ODI	88% good to excellent OC	8 (5%)	6 (3%) dural tears; 5 (2,9%) types of postop worsening
Yoshimoto [28]	2014	Surgical series EDS, comparison between far lateral and intraforaminal disc herniations removal	25 (far lateral) + 93 (IL)	TF	VAS and JOA	No significant differences in pain relief between the two groups	—	—
Jasper [29]	2014	Surgical series EDS, comparison between transforaminal and interlaminar approaches	41	TF and IL	VAS and MacNab	75% pain relief in both groups	—	No complications noted
Xu [30]	2014	Surgical series EDS, analysis of learning curve	36	IL	VAS	Excellent outcome	2 pts. converted to open surgery	No complications noted
Hussein [31]	2014	Comparison between EDS and MD	185	IL	NRS, MacNab, and ODI	Statistically significant pain relief in both groups	2; 8 converted to open surgery	3 dural tears
Kulkarni [32]	2014	Surgical series EDS	188	IL	VAS and ODI	Statistically significant pain relief	3 (1,5%)	11 (5%) dural tears, 1 (0,5%) infection, and 1 (0,5%) wrong level
Choi [33]	2013	Surgical series EDS, comparison between transforaminal and interlaminar approaches	30	TF and IL	VAS and ODI	Shorter recovery time in interlaminar	3,3% TF; 6,7% IL	6,7% postop dysesthesia
Wang [34]	2013	Surgical series EDS, comparison between early and delayed surgery	145	—	VAS and MacNab	No significant differences in pain relief between the two groups	8 to 11% redo	No complications noted

Table 1: Continued.

First author	Year	Study	Number of pts.	Techn.	OC measures	Outcome	Recurrence rate/residual/redo*	Complications
Kim [12]	2013	Surgical series EDS, comparison between interlaminar approach alone and interlaminar + annular sealing	224	IL	VAS and ODI	Statistically significant pain relief in both groups	5% IL + sealing; 13% IL alone	—
Yoshimoto [35]	2013	Surgical series EDS	25	—	JOA	80,4% of pain improvement	0	No complications noted
Jasper [36–38]	2013	Surgical series EDS	195	TF	VAS	83,9% improvement in single level pathology; 69,7% improvement in multilevel	—	—
Wang [39]	2013	Surgical series EDS, analysis of learning curve (comparison between 2 groups operated on by surgeons with different level of training)	120	TF	VAS and JOA	Significant improvements in both groups	20 residuals, 14 (23%) group A; 6 (10%) group B; 2 recurrences	2 postop infections
Choi [33]	2013	Surgical series EDS, intraop magnetic imaging	89	TF	VAS, ODI, and MacNab	Significant improvement	4 (4,5%) residuals; 2 (2%) recurrences	2 postop hematomas
Jasper [36–38]	2013	Surgical series EDS	50	TF	VAS	71 to 75% pain relief	10%	No complications
Yadav [40]	2013	Surgical series EDS	400	IL	VAS and MacNab	90% significant improvement	2 (0,5%)	3 facet injuries; 7 dural tears; 2 infections; 1 persistent paresthesias
Soliman [41]	2013	Surgical series EDS	41	IL	VAS and ODI	95% excellent to good improvement	1	2 dural tears
Matsumoto [42]	2013	Surgical series EDS, analysis of recurrences	344	—	JOA	75 to 83% recovery rate	37 (10,8%)	—
Hsu [43]	2013	Comparison between EDS and MD	59	TF and IL	VAS and ODI	No significant differences between EDS and standard microdiscectomy groups	2 recurrences, 4 persistent symptoms	2 nerve root injuries
Chaichankul [44]	2012	Surgical series EDS, analysis of learning curve	50	TF	VAS	Significant improvement in both groups, higher in later stages of learning curve	—	—
Kim [45]	2012	Surgical series EDS for migrated discs	18	IL	MacNab	89% of complete removal	2 residuals	1 dural tear

Table 1: Continued.

First author	Year	Study	Number of pts.	Techn.	OC measures	Outcome	Recurrence rate/residual/redo*	Complications
Hirano [46]	2012	Surgical series EDS	37	TF and IL	VAS and JOA	Significant improvement	2	—
Yoon [47]	2012	Surgical series, comparison of EDS and tubular-retractor microdiscectomy	37 EDS + 35 MD	TF	VAS, ODI, and SF-36	No significant differences between EDS and standard microdiscectomy groups	1 in each group	1 dural tear; 1 bowel perforation
Wang [48]	2012	Surgical series EDS	151	—	MacNab	91% good to excellent OC	5 (3,5%)	5 pts. (3,5%) dural tears; 3 pts. (2,1%) discitis
Lübbers [49]	2012	Surgical series EDS	22	TF and IL	VAS, ODI, and MacNab	18 pts. (81%) good OC	2 (9,1%)	1 stroke
Han [50]	2012	Surgical series EDS, analysis of technique	41	TF	MacNab	39 pts. excellent to good OC	—	2 nerve root injuries
Kaushal [51]	2012	Surgical series EDS	300	IL	MacNab	90% excellent to good OC	—	6 discitis cases; 5 dural tears; 2 nerve root injuries
Kim [45]	2012	Surgical series EDS, analysis of technique	30	IL	—	Significant improvement	—	No complications noted
Tenenbaum [52]	2011	Surgical series EDS, analysis of technique, complications, and learning curve	124	TF	VAS and ODI	OC comparable to open surgery	20,9% redo surgery	1,6% complication rate
Chumnanvej [53]	2011	Surgical series EDS	60	IL	MacNab	91,6% excellent outcome	2	No complications
Cho [54]	2011	Surgical series EDS, analysis of complications	154	TF	VAS and ODI	Significant improvement	3 (1,95%)	1 dural tear; 1 discitis
Choi [55]	2011	Surgical series EDS, focused on annuloplasty and LBP improvement	52	TF	VAS and ODI	78,4% improvement	18 residuals; 2 recurrences	No complications noted
Chen [56]	2011	Surgical series EDS, focused on anesthesia	123	IL	VAS and ODI	Significant improvements in both groups	3	1 dural tear
Dezawa [57]	2011	Surgical series EDS, focused on technique	30	IL	—	Significant improvement	1 persistent radiculopathy	—
Garg [58]	2011	Comparison between EDS and MD	112	TF	ODI	Statistically significant pain relief in both groups	1	EDS, 5 dural tears
Doi [59]	2011	Surgical series EDS	17	TF and IL	JOA	16 pts. significant improvement	3	No complications noted

Table 1: Continued.

First author	Year	Study	Number of pts.	Techn.	OC measures	Outcome	Recurrence rate/residual/redo*	Complications
Casal-Moro [60]	2011	Surgical series EDS	120	TF and IL	VAS and ODI	92% good to excellent OC	7,5% redo surgery	4,1% dural tear; 4 nerve root injuries; 1 DVT; 1 discitis
Wang [61]	2011	Surgical series EDS, analysis of learning curve	30	IL	VAS	Significant improvement	20% converted to open	12 to 10%, depending on the group
Lee et al. [62]	2010	Surgical series EDS	25	TF	VAS and ODI	Significant improvement	1 residual; 1 recurrence	No complications noted
Ahn [63]	2010	Surgical series EDS, focused on annuloplasty and LBP improvement	87	TF	VAS, ODI, and MacNab	72% good to excellent OC	13 converted to open	No complications noted
Jhala and Mistry [64]	2010	Surgical series EDS	100	IL	MacNab	91% good to excellent OC	4	4 discitis cases; 1 nerve root damage
Teli [65]	2010	Comparison between EDS and MD, focused on complications	224	—	VAS, ODI, and SF-36	Higher rate of complications in EDS group	8	6 dural tears; 2 nerve injuries; 1 discitis
Peng [66]	2010	Surgical series EDS	55	—	VAS, NASS, and SF-36	Significant improvement	5%	—
Lee [67]	2009	Comparison between EDS and MD	54—25 EDS, 29 MD	TF	VAS and ODI	Significant improvement in both groups, but reduction in hospital staying and recurrence rate in EDS group	1 EDS persistent pain; 4%	1 unspecified complication
Chae [68]	2009	Surgical series EDS, analysis of technique	153	TF	VAS and MacNab	94% excellent to good OC	Not reported	1 paravertebral hematoma; 3 transient pareses; 8 transient hypoesthesia cases
Zhou [69]	2009	Surgical series EDS	275	TF	MacNab	91% good to excellent OC	5	5 dural tears; 3 infections

and 163 patients, respectively. Most patients of these series were treated through interlaminar approach, thus ideally comparable with standard microdiscectomy. One large series of patients treated through transforaminal approach reported rate of recurrence of 20% [52], and similar amount was reported by Wang et al. in a series comparing two different surgeons at a different stage of their learning curve [61]. Rate of complications (CSF leak, dysesthesia, nerve root damage, etc.) is quite homogeneous in all series.

The overall opinion reported in discussion/conclusions sections of most authors is that results of endoscopic microdiscectomy are comparable to the one of standard microdiscectomy. Out of this group, two series report considerations worth mentioning. The first is the one from Teli and colleagues, who reported a higher rate of complications in patients treated with endoscopic discectomy (224 patients, randomized in 3 groups) [65], the second being the one from Lee et al., who reported significant reduction of low back pain in patients treated through endoscopic technique (54 patients, nonrandomized).

6.2. Literature Reviews: Systematic Reviews and Meta-Analyses. In early 2015, Dohrmann and Mansour published one of the largest reviews analysing results of different surgical techniques for lumbar disc herniations. Outcomes of multiple studies were reviewed and compared. Good to excellent outcome is reported in 80% of patients undergoing endoscopic discectomy. These results were similar to the standard microdiscectomy (70 to 84%) [73]. Despite being based on the largest cohort of patients collected from international literature (39.000 overall), this review was based on extremely nonhomogeneous studies, and therefore it did not discuss further important data regarding endoscopic microdiscectomy, such as the rate of complications, recurrence, issues related to indications, and learning curve.

The main problem with the data analysis is the lack of systematic reviews, this being also related to lack of randomized control trials comparing standard microdiscectomy/open discectomy with endoscopic lumbar discectomy.

In the last 6 years of medical literature, we found 6 reviews overall, including the one from Dohrmann et al., 2 of them being Cochrane reviews [73–78].

Smith and colleagues reported a detailed selection of studies over a 6-year period, in order to identify randomized control trials comparing endoscopic discectomy with microdiscectomy [Smith]. Out of 109 studies analysed, the authors found only 4 randomized controlled trials meeting the eligibility criteria [58, 65, 79, 80]. As expected, no significant outcome differences were noted between standard microdiscectomy and endoscopic discectomy. However, Teli and colleagues series reported higher rate of complications in patients undergoing endoscopic discectomy. This study has obviously a deep impact on this analysis, being one of the largest randomized series reported.

Another interesting review is the one reported by Birkenmaier and colleagues [78]. This found 5 randomized control trials [80–84], all of them reporting similar results about endoscopic discectomy: (1) reduced hospital staying and quicker return to work following endoscopic procedures; (2) lower rate of complications in endoscopic series; (3) similar rate of recurrences observed in either of the two techniques. However, this review included also cervical endoscopic discectomy series, and it did not include the previously mentioned series from Teli et al. [65], which reported different results.

Two Cochrane reviews were also reported [74, 75]. The first one, by Gibson et al., systematically reviewed quality and results of randomized and quasi-randomized trials of the surgical management of disc prolapse [75]. This included a variety of different techniques, including standard microdiscectomy, endoscopic discectomy, and chemonucleolysis. Results did not show strong clinical evidence supporting percutaneous techniques. The second one, by Rasouli et al., specifically compared randomized and quasirandomized control trials of standard microdiscectomy techniques and all minimally invasive techniques, including endoscopic microdiscectomy and tubular microdiscectomy [74]. Analysis was focused on outcome in terms of pain relief and functional results, as well as on all related data, such as length of hospital admission, rate of complications, and rate of recurrence. The authors reported weak evidence that minimally invasive techniques were associated with a slightly higher risk of recurrence and worse outcome, but with lower risks of complications related with the procedure [74].

All the previously mentioned reviews reported that more randomized control trials are needed in order to get stronger evidence about endoscopic lumbar discectomy.

Finally, one meta-analysis was reported so far in the international literature [85]. This included 9 randomized controlled trials (most of them already mentioned above) and compared their results. In terms of length of hospital staying, overall patient satisfaction, outcome as measured with MacNab criteria, and minor blood loss, the overall rate of good outcome seems to be higher in EDS, although with different degrees of statistical significance. Even here, however, the authors stressed the need for more randomized controlled trial and the fact that the evidence supporting these results is still not strong, despite this being probably the more statistically reliable study published so far.

7. Discussion

This review has serious limitations and, as specified before, it should not be intended as a systematic or comprehensive review of all studies reported in the literature. Our goal was only to provide an update about this topic, focusing on the main debated issues (recurrence/complications rate) and on possible future developments.

What we know today is that the number of centres and surgeons practicing EDS is exponentially increasing. Despite its basics being described since the early '90s, in the last ten years we have assisted at a wide diffusion and rapidly growing spreading of this technique. As mentioned previously, 51 surgical series have been reported in the English literature, and far more were found in other languages. Moreover, we

focused our attention only on transforaminal and interlaminar endoscopic discectomy, also excluding recurrence series and series focused on a specific aspect.

One of the largest series of EDS reported has been published in 2015 and includes 10228 patients treated through a transforaminal approach [86]. The authors reported an incomplete removal in 2,8% of cases and recurrence rate of 0,8%; both these two types of data, taken alone, are comparable to those reported on standard microdiscectomy series. Remarkably, the authors focused their attention on the rate of incomplete removal and recurrences related to the learning curve of the surgeons and the inappropriate positioning of the surgical instruments, which have been found to be the main factors influencing negative outcome in this particular study. These have been also stressed by several series reported in Table 1 and they seem to be one of the crucial points of the debate around EDS. In fact, we might also speculate that all different results might be related to different indications and different experience of the reporting surgeon(s).

Proper choice of indication is of paramount importance for the outcome. In authors' experience and on the basis of the literature data, endoscopic techniques should be used in patients showing fresh or relatively fresh fragments, even migrated, with minor or no signs of diffuse spinal degenerative disease, such as broad disc bulge, spinal stenosis secondary to hypertrophic ligament/osteophytes, and spinal instability. Moreover, use of the endoscope in spinal procedures may be challenging for surgeons not used to the endoscopic kit and techniques, and it requires dedicated training and learning curve. Two series recently reported highlighted the different results obtained from surgeons with different level of experience in EDS. Specifically, both articles reported higher rate of recurrence/residual in patients operated on by surgeons at the earlier stage of their learning curve [44, 61]. However, the majority of largest series reported in the last 6 years showed results comparable to those of standard microdiscectomy, with growing number of authors describing even better results in terms of postop pain and return to work (Table 1).

However, the lack of randomized controlled trial keeps us cautious about the interpretation of these results. Ideally, a multicentred, randomized control trial enrolling large number of patients and surgeons with similar degree of experience should clarify whether results of EDS are comparable or superior to the ones of standard microdiscectomy.

8. Conclusions: What Is Next?

Despite the lack of defined clinical evidence, lumbar EDS is undoubtedly a rapidly expanding field and it is not unreasonable to look at its future developments as incredibly promising. Even if not mentioned here, indications for endoscopic techniques are gradually extending to other lumbar diseases, such as instability [29], multilevels surgery [87], recurrent discs [88], and spinal stenosis [89, 90].

Basing on the data available so far about lumbar EDS, few points are highlighted.

(1) There is growing but still not sufficient evidence that lumbar EDS shows slightly better results in terms of minor tissue damage, shorter hospital staying, quicker return to normal daily activities, and patient satisfaction.

(2) Rate of recurrence/residual is still a matter of debate, and it seems to be strictly related to appropriate surgical indications and level of training of the operating surgeon.

(3) Rate of complications seems similar in both open and endoscopic techniques; however results reported are extremely nonhomogeneous in different series.

(4) More randomized controlled trials, systematic reviews and meta-analysis are needed to clarify whether lumbar EDS can be considered comparable if not superior to standard open discectomy or not.

Conflict of Interests

There is no conflict of interests of any author in relation to the submission.

References

[1] P. Kambin and J. L. Schaffer, "Percutaneous lumbar discectomy. Review of 100 patients and current practice," *Clinical Orthopaedics and Related Research*, no. 238, pp. 24–34, 1989.

[2] P. Kambin, "Arthroscopic microdiscectomy," *Arthroscopy*, vol. 8, no. 3, pp. 287–295, 1992.

[3] D. Kovac, "Automated endoscopic percutaneous diskectomy in the treatment of lumbar disk hernia," *Lijecnicki Vjesnik*, vol. 113, no. 5-6, pp. 158–161, 1991.

[4] H. J. Leu and A. Schreiber, "10 years of percutaneous disk surgery: results and developments," *Schweizerische Rundschau für Medizin Praxis*, vol. 78, no. 51, pp. 1434–1439, 1989.

[5] Y. Suezawa and A. Schreiber, "Percutaneous nucleotomy with discoscopy. 7 years' experience and results," *Zeitschrift für Orthopädie und ihre Grenzgebiete*, vol. 126, no. 1, pp. 1–7, 1988.

[6] A. Schreiber and Y. Suezawa, "Transdiscoscopic percutaneous nucleotomy in disk herniation," *Orthopaedic Review*, vol. 15, no. 1, pp. 35–38, 1986.

[7] B. Hausmann and R. Forst, "Nucleoscope. Instrumentarium for endoscopy of the intervertebral disc space," *Archives of Orthopaedic and Traumatic Surgery*, vol. 102, no. 1, pp. 57–59, 1983.

[8] P. Kambin, E. O'Brien, L. Zhou, and J. L. Schaffer, "Arthroscopic microdiscectomy and selective fragmentectomy," *Clinical Orthopaedics and Related Research*, no. 347, pp. 150–167, 1998.

[9] P. Kambin and S. Sampson, "Posterolateral percutaneous suction-excision of herniated lumbar intervertebral discs. Report of interim results," *Clinical Orthopaedics and Related Research*, vol. 207, pp. 37–43, 1986.

[10] P. M. Tsou and A. T. Yeung, "Transforaminal endoscopic decompression for radiculopathy secondary to intracanal noncontained lumbar disc herniations," *Spine Journal*, vol. 2, no. 1, pp. 41–48, 2002.

[11] A. T. Yeung and P. M. Tsou, "Posterolateral endoscopic excision for lumbar disc herniation: surgical technique, outcome, and

complications in 307 consecutive cases," *Spine*, vol. 27, no. 7, pp. 722–731, 2002.

[12] H. S. Kim and J. Y. Park, "Comparative assessment of different percutaneous endoscopic interlaminar lumbar discectomy (PEID) techniques," *Pain Physician*, vol. 16, no. 4, pp. 359–367, 2013.

[13] G. Choi, S.-H. Lee, P. P. Raiturker, S. Lee, and Y.-S. Chae, "Percutaneous endoscopic interlaminar discectomy for intracanalicular disc herniations at L5-S1 using a rigid working channel endoscope," *Neurosurgery*, vol. 58, no. 1, pp. ONS-59–ONS-68, 2006.

[14] S. Ruetten, M. Komp, and G. Godolias, "A new full-endoscopic technique for the interlaminar operation of lumbar disc herniations using 6-mm endoscopes: prospective 2-year results of 331 patients," *Minimally Invasive Neurosurgery*, vol. 49, no. 2, pp. 80–87, 2006.

[15] S. Ruetten, M. Komp, H. Merk, and G. Godolias, "Use of newly developed instruments and endoscopes: full-endoscopic resection of lumbar disc herniations via the interlaminar and lateral transforaminal approach," *Journal of Neurosurgery: Spine*, vol. 6, no. 6, pp. 521–530, 2007.

[16] S. Ruetten, M. Komp, H. Merk, and G. Godolias, "Full-endoscopic interlaminar and transforaminal lumbar discectomy versus conventional microsurgical technique. A prospective, randomized, controlled study," *Spine*, vol. 33, no. 9, pp. 931–939, 2008.

[17] H. M. Mayer, *Minimally Invasive Spine Surgery*, Springer, 2nd edition, 2006.

[18] P. Kambin, E. OBrien, L. Zhou, and J. L. Schaffer, "Arthroscopic microdiscectomy, selective fragmentectomy," *Clinical Orthopaedics and Related Research*, vol. 347, pp. 150–167, 1998.

[19] R. H. Peterson, "Posterolateral microdiskectomy in a general orthopaedic practice," *Seminars in Orthopaedics*, vol. 6, no. 2, p. 117, 1991.

[20] P. Kambin, T. Gennarelli, and F. Hermantin, "Minimally invasive techniques in spinal surgery: current practice," *Neurosurgical Focus*, vol. 4, no. 2, p. E10, 1998.

[21] M. Li, H. Yang, and Q. Yang, "Full-endoscopic technique discectomy versus microendoscopic discectomy for the surgical treatment of lumbar disc herniation," *Pain Physician*, vol. 18, no. 4, pp. 359–363, 2015.

[22] C. Ç. Türk, N. N. Kara, B. Biliciler, and M. Karasoy, "Clinical outcomes and efficacy of transforaminal lumbar endoscopic discectomy," *Journal of Neurosciences in Rural Practice*, vol. 6, no. 3, pp. 344–348, 2015.

[23] K. Wang, X. Hong, B. Y. Zhou et al., "Evaluation of transforaminal endoscopic lumbar discectomy in the treatment of lumbar disc herniation," *International Orthopaedics*, vol. 39, no. 8, pp. 1599–1604, 2015.

[24] Z.-Z. Li, S.-X. Hou, W.-L. Shang, K.-R. Song, and H.-L. Zhao, "The strategy and early clinical outcome of full-endoscopic L5/S1 discectomy through interlaminar approach," *Clinical Neurology and Neurosurgery*, vol. 133, pp. 40–45, 2015.

[25] K. Sairyo, T. Matsuura, K. Higashino et al., "Surgery related complications in percutaneous endoscopic lumbar discectomy under local anesthesia," *Journal of Medical Investigation*, vol. 61, no. 3-4, pp. 264–269, 2014.

[26] Z. Liao, W. Chen, and C.-H. Wang, "Transforaminal percutaneous endoscopic surgery for far lateral lumbar intervertebral disk herniation," *Orthopedics*, vol. 37, no. 8, pp. e717–e727, 2014.

[27] A. Sencer, A. G. Yorukoglu, M. O. Akcakaya et al., "Fully endoscopic interlaminar and transforaminal lumbar discectomy: short-term clinical results of 163 surgically treated patients," *World Neurosurgery*, vol. 82, no. 5, pp. 884–890, 2014.

[28] M. Yoshimoto, T. Iwase, T. Takebayashi, K. Ida, and T. Yamashita, "Microendoscopic discectomy for far lateral lumbar disk herniation: less surgical invasiveness and minimum 2-year follow-up results," *Journal of Spinal Disorders and Techniques*, vol. 27, no. 1, pp. E1–E7, 2014.

[29] G. P. Jasper, G. M. Francisco, and A. E. Telfeian, "Transforaminal endoscopic discectomy with foraminoplasty for the treatment of spondylolisthesis," *Pain Physician*, vol. 17, no. 6, pp. E703–E708, 2014.

[30] H. Xu, X. Liu, G. Liu, J. Zhao, Q. Fu, and B. Xu, "Learning curve of full-endoscopic technique through interlaminar approach for L5/S1 disk herniations," *Cell Biochemistry and Biophysics*, vol. 70, no. 2, pp. 1069–1074, 2014.

[31] M. Hussein, A. Abdeldayem, and M. M. M. Mattar, "Surgical technique and effectiveness of microendoscopic discectomy for large uncontained lumbar disc herniations: a prospective, randomized, controlled study with 8 years of follow-up," *European Spine Journal*, vol. 23, no. 9, pp. 1992–1999, 2014.

[32] A. G. Kulkarni, A. Bassi, and A. Dhruv, "Microendoscopic lumbar discectomy: technique and results of 188 cases," *Indian Journal of Orthopaedics*, vol. 48, no. 1, pp. 81–87, 2014.

[33] K.-C. Choi, J.-S. Kim, K.-S. Ryu, B. U. Kang, Y. Ahn, and S.-H. Lee, "Percutaneous endoscopic lumbar discectomy for L5-S1 disc herniation: transforaminal versus interlaminar approach," *Pain Physician*, vol. 16, no. 6, pp. 547–556, 2013.

[34] H. Wang, B. Huang, W. Zheng et al., "Comparison of early and late percutaneous endoscopic lumbar discectomy for lumbar disc herniation," *Acta Neurochirurgica*, vol. 155, no. 10, pp. 1931–1936, 2013.

[35] M. Yoshimoto, T. Takebayashi, K. Ida, K. Tanimoto, and T. Yamashita, "Microendoscopic discectomy in athletes," *Journal of Orthopaedic Science*, vol. 18, no. 6, pp. 902–908, 2013.

[36] G. P. Jasper, G. M. Francisco, and A. Telfeian, "Outpatient, awake, ultra-minimally invasive endoscopic treatment of lumbar disc herniations," *Rhode Island Medical Journal*, vol. 97, no. 6, pp. 47–49, 2013.

[37] G. P. Jasper, G. M. Francisco, and A. E. Telfeian, "Clinical success of transforaminal endoscopic discectomy with foraminotomy: a retrospective evaluation," *Clinical Neurology and Neurosurgery*, vol. 115, no. 10, pp. 1961–1965, 2013.

[38] G. P. Jasper, G. M. Francisco, and A. E. Telfeian, "A retrospective evaluation of the clinical success of transforaminal endoscopic discectomy with foraminotomy in geriatric patients," *Pain Physician*, vol. 16, no. 3, pp. 225–229, 2013.

[39] H. Wang, B. Huang, C. Li et al., "Learning curve for percutaneous endoscopic lumbar discectomy depending on the surgeon's training level of minimally invasive spine surgery," *Clinical Neurology and Neurosurgery*, vol. 115, no. 10, pp. 1987–1991, 2013.

[40] Y. R. Yadav, V. Parihar, H. Namdev, M. Agarwal, and P. R. Bhatele, "Endoscopic interlaminar management of lumbar disc disease," *Journal of Neurological Surgery Part A: Central European Neurosurgery*, vol. 74, no. 2, pp. 77–81, 2013.

[41] H. M. Soliman, "Irrigation endoscopic discectomy: a novel percutaneous approach for lumbar disc prolapse," *European Spine Journal*, vol. 22, no. 5, pp. 1037–1044, 2013.

[42] M. Matsumoto, K. Watanabe, N. Hosogane et al., "Recurrence of lumbar disc herniation after microendoscopic discectomy,"

Journal of Neurological Surgery Part A: Central European Neurosurgery, vol. 74, no. 4, pp. 222–227, 2013.

[43] H.-T. Hsu, S.-J. Chang, S. S. Yang, and C. L. Chai, "Learning curve of full-endoscopic lumbar discectomy," *European Spine Journal*, vol. 22, no. 4, pp. 727–733, 2013.

[44] C. Chaichankul, S. Poopitaya, and W. Tassanawipas, "The effect of learning curve on the results of percutaneous transforaminal endoscopic lumbar discectomy," *Journal of the Medical Association of Thailand*, vol. 95, supplement 10, pp. S206–S212, 2012.

[45] C. H. Kim, C. K. Chung, and J. W. Woo, "Surgical outcome of percutaneous endoscopic interlaminar lumbar discectomy for highly migrated disc herniation," *Journal of Spinal Disorders and Techniques*, 2012.

[46] Y. Hirano, J. Mizuno, M. Takeda, Y. Itoh, H. Matsuoka, and K. Watanabe, "Percutaneous endoscopic lumbar discectomy—early clinical experience," *Neurologia Medico-Chirurgica*, vol. 52, no. 9, pp. 625–630, 2012.

[47] S. M. Yoon, S. S. Ahn, K. H. Kim, Y. D. Kim, J. H. Cho, and D. Kim, "Comparative study of the outcomes of percutaneous endoscopic lumbar discectomy and microscopic lumbar discectomy using the tubular retractor system based on the VAS, ODI, and SF-36," *Korean Journal of Spine*, vol. 9, no. 3, pp. 215–222, 2012.

[48] M. Wang, Y. Zhou, J. Wang, Z. Zhang, and C. Li, "A 10-year follow-up study on long-term clinical outcomes of lumbar microendoscopic discectomy," *Journal of Neurological Surgery Part A: Central European Neurosurgery*, vol. 73, no. 4, pp. 195–198, 2012.

[49] T. Lübbers, R. Abuamona, and A. E. Elsharkawy, "Percutaneous endoscopic treatment of foraminal and extraforaminal disc herniation at the L5-S1 level," *Acta Neurochirurgica*, vol. 154, no. 10, pp. 1789–1795, 2012.

[50] I. H. Han, B. K. Choi, W. H. Cho, and K. H. Nam, "The obturator guiding technique in percutaneous endoscopic lumbar discectomy," *Journal of Korean Neurosurgical Society*, vol. 51, no. 3, pp. 182–186, 2012.

[51] M. Kaushal and R. Sen, "Posterior endoscopic discectomy: results in 300 patients," *Indian Journal of Orthopaedics*, vol. 46, no. 1, pp. 81–85, 2012.

[52] S. Tenenbaum, H. Arzi, A. Herman et al., "Percutaneous posterolateral transforaminal endoscopic discectomy: clinical outcome, complications, and learning curve evaluation," *Surgical Technology International*, vol. 21, pp. 278–283, 2011.

[53] S. Chumnanvej, W. Kesornsak, P. Sarnvivad, and V. Kuansongthum, "Full endoscopic lumbar discectomy via interlaminar approach: 2-year results in Ramathibodi Hospital," *Journal of the Medical Association of Thailand*, vol. 94, no. 12, pp. 1465–1470, 2011.

[54] J. Y. Cho, S.-H. Lee, and H.-Y. Lee, "Prevention of development of postoperative dysesthesia in transforaminal percutaneous endoscopic lumbar discectomy for intracanalicular lumbar disc herniation: floating retraction technique," *Minimally Invasive Neurosurgery*, vol. 54, no. 5-6, pp. 214–218, 2011.

[55] K.-C. Choi, J.-S. Kim, B.-U. Kang, C. D. Lee, and S.-H. Lee, "Changes in back pain after percutaneous endoscopic lumbar discectomy and annuloplasty for lumbar disc herniation: a prospective study," *Pain Medicine*, vol. 12, no. 11, pp. 1615–1621, 2011.

[56] H. T. Chen, C. H. Tsai, S. C. Chao et al., "Endoscopic discectomy of L5-S1 disc herniation via an interlaminar approach: prospective controlled study under local and general anesthesia," *Surgical Neurology International*, vol. 2, article 93, 2011.

[57] A. Dezawa and K. Sairyo, "New minimally invasive discectomy technique through the interlaminar space using a percutaneous endoscope," *Asian Journal of Endoscopic Surgery*, vol. 4, no. 2, pp. 94–98, 2011.

[58] B. Garg, U. B. Nagraja, and A. Jayaswal, "Microendoscopic versus open discectomy for lumbar disc herniation: a prospective randomised study," *Journal of Orthopaedic Surgery*, vol. 19, no. 1, pp. 30–34, 2011.

[59] T. Doi, K. Harimaya, Y. Matsumoto, O. Tono, K. Tarukado, and Y. Iwamoto, "Endoscopic decompression for intraforaminal and extraforaminal nerve root compression," *Journal of Orthopaedic Surgery and Research*, vol. 6, article 16, 2011.

[60] R. Casal-Moro, M. Castro-Menéndez, M. Hernández-Blanco, J. A. Bravo-Ricoy, and F. J. Jorge-Barreiro, "Long-term outcome after microendoscopic diskectomy for lumbar disk herniation: a prospective clinical study with a 5-year follow-up," *Neurosurgery*, vol. 68, no. 6, pp. 1568–1575, 2011.

[61] B. Wang, G. Lü, A. A. Patel, P. Ren, and I. Cheng, "An evaluation of the learning curve for a complex surgical technique: the full endoscopic interlaminar approach for lumbar disc herniations," *Spine Journal*, vol. 11, no. 2, pp. 122–130, 2011.

[62] S.-H. Lee, H. S. Kang, G. Choi et al., "Foraminoplastic ventral epidural approach for removal of extruded herniated fragment at the L5-S1 level," *Neurologia Medico-Chirurgica*, vol. 50, no. 12, pp. 1074–1078, 2010.

[63] Y. Ahn and S.-H. Lee, "Outcome predictors of percutaneous endoscopic lumbar discectomy and thermal annuloplasty for discogenic low back pain," *Acta Neurochirurgica*, vol. 152, no. 10, pp. 1695–1702, 2010.

[64] A. Jhala and M. Mistry, "Endoscopic lumbar discectomy: experience of first 100 cases," *Indian Journal of Orthopaedics*, vol. 44, no. 2, pp. 184–190, 2010.

[65] M. Teli, A. Lovi, M. Brayda-Bruno et al., "Higher risk of dural tears and recurrent herniation with lumbar micro-endoscopic discectomy," *European Spine Journal*, vol. 19, no. 3, pp. 443–450, 2010.

[66] C. W. B. Peng, W. Yeo, and S. B. Tan, "Percutaneous endoscopic discectomy: clinical results and how it affects the quality of life," *Journal of Spinal Disorders & Techniques*, vol. 23, no. 6, pp. 425–430, 2010.

[67] D. Y. Lee, C. S. Shim, Y. Ahn, Y.-G. Choi, H. J. Kim, and S.-H. Lee, "Comparison of percutaneous endoscopic lumbar discectomy and open lumbar microdiscectomy for recurrent disc herniation," *Journal of Korean Neurosurgical Society*, vol. 46, no. 6, pp. 515–521, 2009.

[68] K. H. Chae, C. I. Ju, S. M. Lee, B. W. Kim, S. Y. Kim, and H. S. Kim, "Strategies for noncontained lumbar disc herniation by an endoscopic approach: transforaminal uprapedicular approach, semi-rigid flexible curved probe, and 3-dimensional reconstruction CT with discogram," *Journal of Korean Neurosurgical Society*, vol. 46, no. 4, pp. 312–316, 2009.

[69] Y. Zhou, M. Wang, J. Wang, T.-W. Chu, Z.-F. Zhang, and C.-Q. Li, "Clinical experience and results of lumbar microendoscopic discectomy: a study with a five-year follow-up," *Orthopaedic Surgery*, vol. 1, no. 3, pp. 171–175, 2009.

[70] G. Choi, H. N. Modi, N. Prada et al., "Clinical results of XMR-assisted percutaneous transforaminal endoscopic lumbar discectomy," *Journal of Orthopaedic Surgery and Research*, vol. 8, article 14, 2013.

[71] C. H. Kim and C. K. Chung, "Endoscopic interlaminar lumbar discectomy with splitting of the ligament flavum under visual

control," *Journal of Spinal Disorders and Techniques*, vol. 25, no. 4, pp. 210–217, 2012.

[72] J. S. Kim, H. S. Kang, G. Choi et al., "Foraminoplastic ventral epidural approach for removal of extruded herniated fragment at the L5-S1 level," *Neurologia Medico-Chirurgica*, vol. 50, no. 12, pp. 1074–1078, 2010.

[73] G. J. Dohrmann and N. Mansour, "Long-term results of various operations for lumbar disc herniation: analysis of over 39,000 patients," *Medical Principles and Practice*, vol. 24, no. 3, pp. 285–290, 2015.

[74] M. R. Rasouli, V. Rahimi-Movaghar, F. Shokraneh, M. Moradi-Lakeh, and R. Chou, "Minimally invasive discectomy versus microdiscectomy/open discectomy for symptomatic lumbar disc herniation," *Cochrane Database of Systematic Reviews*, vol. 9, Article ID CD010328, 2014.

[75] J. N. A. Gibson, J. G. Cowie, and M. Iprenburg, "Transforaminal endoscopic spinal surgery: the future 'gold standard' for discectomy?—a review," *Surgeon*, vol. 10, no. 5, pp. 290–296, 2012.

[76] J. Nellensteijn, R. Ostelo, R. Bartels, W. Peul, B. van Royen, and M. van Tulder, "Transforaminal endoscopic surgery for symptomatic lumbar disc herniations: a systematic review of the literature," *European Spine Journal*, vol. 19, no. 2, pp. 181–204, 2010.

[77] N. Smith, J. Masters, C. Jensen, A. Khan, and A. Sprowson, "Systematic review of microendoscopic discectomy for lumbar disc herniation," *European Spine Journal*, vol. 22, no. 11, pp. 2458–2465, 2013.

[78] C. Birkenmaier, M. Komp, H. F. Leu, B. Wegener, and S. Ruetten, "The current state of endoscopic disc surgery: review of controlled studies comparing full-endoscopic procedures for disc herniations to standard procedures," *Pain Physician*, vol. 16, no. 4, pp. 335–344, 2013.

[79] T.-J. Huang, R. W.-W. Hsu, Y.-Y. Li, and C.-C. Cheng, "Less systemic cytokine response in patients following microendoscopic versus open lumbar discectomy," *Journal of Orthopaedic Research*, vol. 23, no. 2, pp. 406–411, 2005.

[80] O. Righesso, A. Falavigna, and O. Avanzi, "Comparison of open discectomy with microendoscopic discectomy in lumbar disc herniations: results of a randomized controlled trial," *Neurosurgery*, vol. 61, no. 3, pp. 545–549, 2007.

[81] S. Ruetten, M. Komp, H. Merk, and G. Godolias, "Full-endoscopic cervical posterior foraminotomy for the operation of lateral disc herniations using 5.9 mm endoscopes: a prospective, randomized, controlled study," *Spine*, vol. 33, no. 9, pp. 940–948, 2008.

[82] S. Ruetten, M. Komp, H. Merk, and G. Godolias, "Full-endoscopic interlaminar and transforaminal lumbar discectomy versus conventional microsurgical technique: a prospective, randomized, controlled study," *Spine*, vol. 33, no. 9, pp. 931–939, 2008.

[83] S. Ruetten, M. Komp, H. Merk, and G. Godolias, "Recurrent lumbar disc herniation after conventional discectomy: a prospective, randomized study comparing full-endoscopic interlaminar and transforaminal versus microsurgical revision," *Journal of Spinal Disorders and Techniques*, vol. 22, no. 2, pp. 122–129, 2009.

[84] S. Ruetten, M. Komp, H. Merk, and G. Godolias, "Full-endoscopic anterior decompression versus conventional anterior decompression and fusion in cervical disc herniations," *International Orthopaedics*, vol. 33, no. 6, pp. 1677–1682, 2009.

[85] L. Cong, Y. Zhu, and G. Tu, "A meta-analysis of endoscopic discectomy versus open discectomy for symptomatic lumbar disk herniation," *European Spine Journal*, pp. 1–10, 2015.

[86] K.-C. Choi, J.-H. Lee, J.-S. Kim et al., "Unsuccessful percutaneous endoscopic lumbar discectomy: a single-center experience of 10,228 cases," *Neurosurgery*, vol. 76, no. 4, pp. 372–380, 2015.

[87] J.-W. Hur, J.-S. Kim, M.-H. Shin, K.-S. Ryu, C.-K. Park, and S.-H. Lee, "Percutaneous endoscopic lumbar discectomy and annuloplasty for lumbar disc herniation at the low two contiguous levels: single-portal, double surgeries," *Journal of Neurological Surgery, Part A: Central European Neurosurgery*, vol. 75, no. 5, pp. 381–385, 2014.

[88] K. Nomura, M. Yoshida, M. Kawai, M. Okada, and S.-I. Nakao, "A novel microendoscopically assisted approach for the treatment of recurrent lumbar disc herniation: transosseous discectomy surgery," *Journal of Neurological Surgery Part A: Central European Neurosurgery*, vol. 75, no. 3, pp. 183–188, 2014.

[89] Y. Ahn, "Percutaneous endoscopic decompression for lumbar spinal stenosis," *Expert Review of Medical Devices*, vol. 11, no. 6, pp. 605–616, 2014.

[90] B.-S. Xu, Q.-S. Tan, Q. Xia, N. Ji, and Y.-C. Hu, "Bilateral decompression via unilateral fenestration using mobile microendoscopic discectomy technique for lumbar spinal stenosis," *Orthopaedic Surgery*, vol. 2, no. 2, pp. 106–110, 2010.

Hindawi Publishing Corporation
BioMed Research International
Volume 2015, Article ID 639542, 6 pages
http://dx.doi.org/10.1155/2015/639542

Clinical Study

Minimal Invasive Circumferential Management of Thoracolumbar Spine Fractures

S. Pesenti, T. Graillon, N. Mansouri, P. Rakotozanani, B. Blondel, and S. Fuentes

Spine Unit, Aix-Marseille Université, CHU Timone, 264 rue Saint-Pierre, 13005 Marseille, France

Correspondence should be addressed to S. Fuentes; sfuentes@ap-hm.fr

Received 7 August 2015; Revised 21 October 2015; Accepted 2 November 2015

Academic Editor: Giulio Anichini

Introduction. While thoracolumbar fractures are common lesions, no strong consensus is available at the moment. *Objectives*. The aim of this study was to evaluate the results of a minimal invasive strategy using percutaneous instrumentation and anterior approach in the management of thoracolumbar unstable fractures. *Methods*. 39 patients were included in this retrospective study. Radiologic evaluation was based on vertebral and regional kyphosis, vertebral body height restoration, and fusion rate. Clinical evaluation was based on Visual Analogic Score (VAS). All evaluations were done preoperatively and at 1-year follow-up. *Results*. Both vertebral and regional kyphoses were significantly improved on postoperative evaluation (13° and 7° versus −1° and −9° $P < 0.05$, resp.) as well as vertebral body height (0.92 versus 1.16, $P < 0.05$). At 1-year follow-up, mean loss of correction was 1°. A solid fusion was visible in all the cases, and mean VAS was significantly reduced form 8/10 preoperatively to 1/10 at the last follow-up. *Conclusion*. Management of thoracolumbar fractures using percutaneous osteosynthesis and minimal invasive anterior approach (telescopic vertebral body prosthesis) is a valuable strategy. Results of this strategy offer satisfactory and stable results in time.

1. Introduction

Thoracolumbar fractures consecutive to compression trauma (A fractures in the AO classification) [1] can lead to spine instability and potential neurologic deficits. Furthermore, the collapse of the vertebral body can result, at long follow-up, in a major kyphotic deformity [2]. This kyphotic deformity can therefore be responsible for an overall sagittal anterior malalignment known as a key factor for the development of posttraumatic chronic back pain syndrome [3]. According to these risks, a surgical treatment of these fractures can be advocated in order to restore vertebral body height, correct the kyphotic deformity, and if necessary decompress the neurologic elements [4, 5].

While many treatment options have been described in the literature, there is still a lack of clear consensus regarding the modalities of surgical management for these thoracolumbar unstable fractures. Posterior transpedicular instrumentation is a commonly performed procedure that allows the correction of the kyphotic deformity induced by the fracture. Such spinal fixation can be performed via a traditional open approach or using percutaneous technique. A theoretical advantage of percutaneous techniques is the possibility to avoid complications related to open approach while allowing a same quality of reduction of the posttraumatic kyphotic deformity.

When needed, and especially when there is a high comminution of the vertebral body, an anterior support associated with the posterior instrumentation can be performed in order to obtain an optimal spinal stabilization. Various studies have shown the benefit of the anterior intervertebral stabilization in terms of kyphosis correction or sustainability of this correction at long follow-up [6–8]. With regard to the anterior surgical techniques, different procedures have been described using bone graft, cages, or telescopic vertebral body prosthesis. Such techniques can also be performed using minimal invasive techniques in order to reduce surgical trauma and to improve postoperative course for the patients.

The aim of this study was to report results of our experience in the management of unstable thoracolumbar fractures

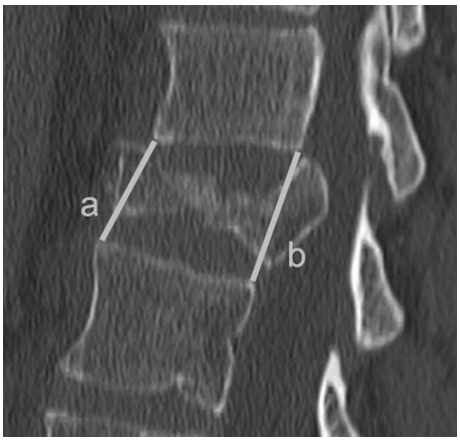

Figure 1: Measurement of the ratio between the anterior and the posterior wall of the collapsed vertebra.

using a posterior percutaneous transpedicular instrumentation combined with an anterior stabilization using telescopic vertebral body prosthesis.

2. Methods

2.1. Study Design. In this retrospective study, medical chart of 39 patients (16 women and 23 men) admitted in our institution for thoracolumbar unstable spine fractures was analyzed by an independent observer from surgery. Inclusion criteria were all the patients admitted for unstable thoracolumbar spine fractures without neurologic deficit and treated using percutaneous posterior instrumentation associated with anterior telescopic vertebral body prosthesis, with at least 1 year of follow-up. Indication for anterior approach was based on important vertebral body comminution and/or disc lesion on the preoperative MRI that required anterior column support.

Patients with history of evolutive carcinoma and infectious or inflammatory disease were excluded. Patients with less than 1-year follow-up were also excluded (due to the fact that fusion was assessed on the 1-year follow-up CT-scan).

All the treated fractures were classified using a preoperative CT-scan. A preoperative MRI was also routinely prescribed in order to evaluate intervertebral discs and ligaments, as well as the risk of neurologic impairment due to the fracture. A postoperative CT-scan was also performed in order to confirm the good positioning of the implant and was repeated at one-year follow-up for the evaluation of bone fusion.

2.2. Radiographic Measurements. All measurements were performed on pre- and postoperative CT-scan and at last follow-up. Vertebral and regional kyphoses were measured. The regional kyphosis was defined as the angle between the superior endplate of the overlying vertebra and the inferior endplate of the underlying vertebra. The ratio between the anterior and the posterior wall of the collapsed vertebra was also performed (AP ratio) [9] (Figure 1).

The accuracy of pedicle screw placement was also assessed on immediate postoperative CT-scan. A screw was considered as extrapedicular when a cortical breach superior to 2 mm was visible on the postoperative CT-scan [10].

2.3. Surgical Technique. On the whole series, surgical strategy was standardized and performed as follows.

(i) The first step was systematically a posterior percutaneous transpedicular instrumentation using monoaxial screws (Longitude©, Medtronic Inc., Memphis, TN), under AP and lateral fluoroscopic control. A short instrumentation was performed in 27 cases (one level above and below the fracture) and a longer instrumentation was performed in 12 cases according to the fracture. Correction of the deformity was achieved using dedicated ancillary and *in situ* contouring techniques.

(ii) The second step was a partial corpectomy (Figure 2) of the collapsed endplate followed by anterior reconstruction using a telescopic prosthetic body (V-lift, Stryker, Kalamazoo, MI), under lateral fluoroscopic control. According to the fracture level, the approach was either a right minithoracotomy (T4–T8), a left minithoracophrenolombotomy (T10-L2), a left minilombotomy (L3-L4), or a retroperitoneal approach (L5) [11]. The prosthetic body was fulfilled with cancellous bone (from the corpectomy) associated with rhBMP-2 (Inductos, Medtronic Inc., Memphis, Tennessee).

(iii) When both adjacent intervertebral discs were affected on the preoperative MRI, the corpectomy was associated with a double discectomy followed by anterior reconstruction using the same telescopic prosthetic body (Figure 3).

The procedure was performed either in one surgical step or in two steps according to patient's comorbidities and associated lesions. In all cases, patients were informed preoperatively about all the surgical and nonsurgical options, the new surgical strategy chosen, and consented accordingly.

2.4. Evaluation of Bone Fusion. The assessment of bone fusion was done based on the 1-year follow-up CT-scan. The fusion was considered as acquired when the following criteria were obtained: existence of a bone bridge between over- and underlying vertebras, absence of implant subsidence, absence of hardware failure (anterior or posterior), and absence of osteolytic lesions around the instrumentation (anterior or posterior) [12].

2.5. Statistical Analysis. Student's t-test was performed to evaluate preoperative to postoperative changes based on radiographic measurements (vertebral and local kyphosis and AP ratio). For each test, the level of significance was set at 5%; that is, P values lower than 0.05 were considered to be statistically significant.

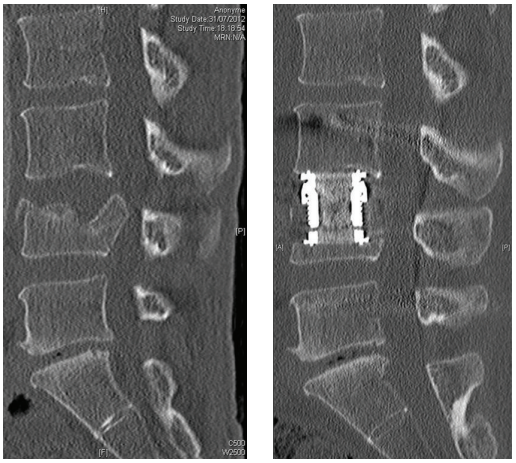

(a) (b)

Figure 2: Sagittal pre- (a) and postoperative (b) CT-scan showing a vertebral fracture with a lesion of the superior disc and results after posterior percutaneous osteosynthesis and partial corpectomy.

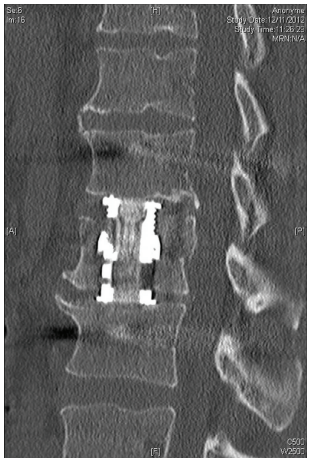

Figure 3: Sagittal postoperative CT-scan showing results after posterior percutaneous osteosynthesis and anterior body graft using an expandable body prosthesis.

3. Results

3.1. Population. 39 patients (23 males and 16 females) with a mean age of 42 years [16–72] were included in this retrospective study. Level distribution of the fractured vertebrae included L1 in 18 cases (46%), T12 in 7 cases (18%), L2 in 6 cases (15%), L4 in 4 cases (10%) and T4, T8, L3, and L5 in 1 case each. According to the AO classification, 25 fractures were classified as A3.3 (64%), 6 as A3.2 (15%), 5 as A3.1 (13%), and 3 as A2 (8%).

Surgical procedure was performed in a single session for 5 patients without comorbidities and associated lesions. In the remaining 34 patients, procedure was achieved in 2 surgical steps according to the fracture, comorbidities, and associated lesions. For patients with a two-step surgical management, anterior approach was done after an average time of 12.3 days [2–47]. A complete corpectomy was performed in 20 cases and a partial corpectomy was performed in the last 19 cases.

Preoperative neurological evaluation did not reveal any deficit in 37 cases. For the 2 last patients, one was classified as Frankel C and one as Frankel D. In these 2 cases, the neurological deficit was not diagnosed immediately due to a concomitant lower limb fracture and anterior approach was done after a 2-day interval.

3.2. Kyphosis Reduction. Based on the preoperative CT-scan, mean vertebral kyphosis was measured at 13° [−8; 36°] and regional kyphosis at 7° [−37; 26°]. On postoperative examinations (after the posterior and anterior spinal fixation), mean vertebral kyphosis was measured at −1° [−26; 12°] and regional kyphosis at −8° [−51; 17°]. For both of these parameters, postoperative reduction was statistically significant ($P < 0.001$) with an average gain of 14° for vertebral kyphosis and 16° for regional kyphosis.

Among the 34 patients managed by a two-step procedure, vertebral and regional kyphoses after the posterior percutaneous instrumentation were measured at 2° [−4; 10°] and −5° [−37; 20°] with an average gain of 11° and 13°, respectively. Both vertebral and regional kyphoses were significantly improved after the posterior instrumentation (14° versus 2° $P < 0.001$ and 9° versus −5°, $P < 0.001$, resp.). Further correction of the kyphotic deformity after the anterior approach was also significant for the vertebral kyphosis and for the regional kyphosis (average gain of 4 and 3°, resp., $P < 0.05$).

At one-year follow-up, mean vertebral kyphosis was −1° and regional kyphosis was −8°, without significant loss of reduction compared to the immediate postoperative evaluation average loss of correction of 1° for vertebral kyphosis ($P = 0.97$) and 1° for regional kyphosis ($P = 0.85$).

3.3. Vertebral Body Height Restoration. Comparison between average pre- and postoperative A/P ratio showed a statistically significant ($P < 0.001$) improvement from 0.92 [0.64–1.18] to 1.16 [0.83–1.52].

Among the 34 patients treated during two surgical sessions, A/P ration after the posterior instrumentation was 1.12 on average [0.8–1.35], significantly improved when compared to the preoperative measurement (0.12 versus 1.12, $P < 0.001$). No further significant improvement of the A/P ratio was noticed after the anterior approach (1.12 versus 1.16, $P = 0.14$).

3.4. Complications. On the whole series, an unplanned surgical procedure for mechanical complication was never necessary. Based on postoperative CT-scan, the rate of extrapedicular screw (breach superior to 2 mm) was evaluated at 1.8%, without neurologic compromise that required replacement of a screw. Blood loss was inferior to 200 mL in all the cases, only one patient (2.6%) required a blood transfusion during the postoperative course due to associated lesions. At last follow-up, no cases of infection were reported.

For all the patients with a normal preoperative neurological examination, no postoperative deficit was noticed, and a complete recovery was obtained for the 2 patients with preoperative deficits.

3.5. Operative Data and Length of Stay. Average operative time was 177 minutes (137 to 263 minutes) when circumferential fusion was performed in the same surgical session. With regard to posterior instrumentation alone, average surgical time was 62 minutes (28 to 99 minutes) and 73 minutes (50 to 105 minutes) for the anterior approach.

Among the 34 patients who underwent two surgical sessions, mean delay between the two procedures was 12 days (2 to 37 days) according to associated lesions.

Average length of stay at the hospital was 15 days (7 to 48 days) dependent on the associated lesions.

3.6. Functional Evaluation. On the day of admission, mean VAS was evaluated at 8/10 [3–10]. On the day of discharge of the hospital, mean VAS was at 5/10 and at 1/10 [0–5] at the one-year follow-up evaluation. None of the patients used grade III analgesics at last follow-up.

3.7. Fusion Rate. Based on the last follow-up CT-scan, all patients were considered as fused with regard to fusion criteria used for this study and no case of implant failure was noticed.

4. Discussion

4.1. Surgical Management. Surgical management of thoracolumbar fractures with an important comminution and a kyphotic deformity is nowadays widely accepted. However, there is still a lack of strong consensus of the best strategy in order to achieve best results for these lesions.

Transpedicular posterior instrumentation offers the possibility to achieve a good reduction of the deformity. However, if performed without additional bone graft, posterior instrumentation alone commonly requires an anterior support to reinforce spine stability. It has been advocated by several authors that in case of important bone defect, long-term spinal stability is not guaranteed and a loss of correction up to 10° can occur using posterior instrumentation alone [6–8, 13].

It can therefore be a valuable alternative to perform a circumferential fusion in order to reduce the deformity with stable results [14–16], using a balloon kyphoplasty [17, 18] or an anterior approach [19]. In this series, rationale for an anterior approach instead of balloon kyphoplasty was based on the important bone defect on the initial CT-scan or the presence of a disc disruption on the preoperative MRI.

4.2. Percutaneous Osteosynthesis. While conventional open posterior surgery leads to satisfactory results, it can also be a potential source of complications. Among them, intraoperative blood loss and postoperative infection are the most common [20]. Furthermore, it seems that important muscle damage and prolonged retraction can be responsible for local disorders leading to an increased rate of failed back syndrome [21].

A theoretical advantage of percutaneous osteosynthesis is the absence of muscle dissection with decreased blood loss and postoperative infection rate. It has also been demonstrated that satisfactory kyphotic deformity reduction can be obtained using percutaneous approach [22–24]. Results from this study revealed that kyphosis reduction after the posterior instrumentation was satisfactory with a significant restoration of vertebral and regional kyphosis as well as vertebral body height. These results reinforce the previously reported data on the ability of percutaneous procedures that can be associated to in situ contouring for the reduction of kyphotic deformity.

4.3. Anterior Corpectomy and Instrumentation. According to our results, regional and vertebral kyphosis was still significantly improved after the anterior approach even if the amplitude of correction was smaller than that after the posterior fixation. This difference can be explained by the distraction effect of the telescopic vertebral body prosthesis.

However, we believe that the clinical impact of this further reduction of the deformity is rather small when compared to the posterior correction. Nevertheless, at one-year follow-up, no significant loss of reduction was visible on CT-scan measurements. These results confirm the interest of anterior approach not to improve the deformity reduction obtained by the posterior instrumentation, but in order to obtain a solid and stable time construct [19].

4.4. Fusion Rate. A solid bone fusion was visible in all patients of this series at 1-year follow-up. These results can be related to the absence of important muscle dissection which can be a potential source of pseudoarthrosis [21]. Furthermore, performing a corpectomy with discs resection can increase fusion rate and allow a removal of disc trapped in the vertebral body. Of course, the use of rhBMP-2 is also an important factor in intervertebral fusion rate [25].

4.5. Neurologic Decompression. In our series, 2 patients have preoperative incomplete neurologic deficit (Figure 3). Reduction of the kyphotic deformity and distraction maneuvers led, by ligamentotaxis, to a restoration of a normal vertebral canal diameter [26]. Ataka et al. [27] showed that it was possible to restore neurologic function in these patients with incomplete deficits using a posterior only instrumentation without neurological decompression. Using a percutaneous procedure can therefore be a valuable alternative, even for patients with incomplete deficits, as it leads to identical deformity reduction when compared to open procedures.

Furthermore, in this two-step strategy, performing a corpectomy gives a satisfactory access to the vertebral canal. It is therefore possible to obtain via an anterior approach a complete neurologic decompression [28, 29] even more appropriate than a laminectomy due the anterior compression of the neurologic structures.

The presence of an incomplete neurologic deficit is therefore not an absolute contraindication to minimal invasive procedures. It can furthermore be an interesting technique for fragile patients such as polytrauma or elderly.

5. Conclusion

Surgical management of thoracolumbar fractures using a percutaneous instrumentation associated with a minimal invasive anterior approach (with a telescopic vertebral prosthesis) leads to a satisfactory and stable reduction of the deformity. While these strategies are commonly used for patients without neurologic deficits, it can also be proposed for patients with incomplete deficits. According to us, this minimal invasive strategy can be a valuable surgical technique in the management of thoracolumbar fractures with a low rate of complications.

Conflict of Interests

The authors declare that there is no conflict of interests.

References

[1] F. Magerl, M. Aebi, S. D. Gertzbein, J. Harms, and S. Nazarian, "A comprehensive classification of thoracic and lumbar injuries," *European Spine Journal*, vol. 3, no. 4, pp. 184–201, 1994.

[2] C.-E. Heyde, S. K. Tschoeke, M. Hellmuth, A. Hostmann, W. Ertel, and A. Oberholzer, "Trauma induces apoptosis in human thoracolumbar intervertebral discs," *BMC Clinical Pathology*, vol. 6, article 5, 2006.

[3] A. Hempfing, J. Zenner, L. Ferraris, O. Meier, and H. Koller, "Restoration of sagittal balance in treatment of thoracic and lumbar vertebral fractures," *Orthopade*, vol. 40, no. 8, pp. 690–702, 2011.

[4] P. W. Hitchon, J. C. Torner, S. F. Haddad, and K. A. Follett, "Management options in thoracolumbar burst fractures," *Surgical Neurology*, vol. 49, no. 6, pp. 619–627, 1998.

[5] J. Mumford, J. N. Weinstein, K. F. Spratt, and V. K. Goel, "Thoracolumbar burst fractures. The clinical efficacy and outcome of nonoperative management," *Spine*, vol. 18, no. 8, pp. 955–970, 1993.

[6] H. D. Been and G. J. Bouma, "Comparison of two types of surgery for thoraco-lumbar burst fractures: combined anterior and posterior stabilisation vs. posterior instrumentation only," *Acta Neurochirurgica*, vol. 141, no. 4, pp. 349–357, 1999.

[7] C. Knop, H. F. Fabian, L. Bastian, and M. Blauth, "Late results of thoracolumbar fractures after posterior instrumentation and transpedicular bone grafting," *Spine*, vol. 26, no. 1, pp. 88–99, 2001.

[8] J. J. Verlaan, C. H. Diekerhof, E. Buskens et al., "Surgical treatment of traumatic fractures of the thoracic and lumbar spine: a systematic review of the literature on techniques, complications, and outcome," *Spine*, vol. 29, no. 7, pp. 803–814, 2004.

[9] G. Maestretti, C. Cremer, P. Otten, and R. P. Jakob, "Prospective study of standalone balloon kyphoplasty with calcium phosphate cement augmentation in traumatic fractures," *European Spine Journal*, vol. 16, no. 5, pp. 601–610, 2007.

[10] P. J. Belmont Jr., W. R. Klemme, A. Dhawan, and D. W. Polly Jr., "In vivo accuracy of thoracic pedicle screws," *Spine*, vol. 26, no. 21, pp. 2340–2346, 2001.

[11] C. F. Litré, J. Duntze, Y. Benhima et al., "Anterior minimally invasive extrapleural retroperitoneal approach to the thoracolumbar junction of the spine," *Orthopaedics and Traumatology: Surgery and Research*, vol. 99, no. 1, pp. 94–98, 2013.

[12] J. K. Burkus, K. Foley, R. W. Haid, and J. C. LeHuec, "Surgical Interbody Research Group—radiographic assessment of interbody fusion devices: fusion criteria for anterior lumbar interbody surgery," *Neurosurgical Focus*, vol. 10, article E11, 2001.

[13] K. Uchida, S. Kobayashi, M. Matsuzaki et al., "Anterior versus posterior surgery for osteoporotic vertebral collapse with neurological deficit in the thoracolumbar spine," *European Spine Journal*, vol. 15, no. 12, pp. 1759–1767, 2006.

[14] M. Elzinga, M. Segers, J. Siebenga, E. Heilbron, E. S. M. De Lange-De Klerk, and F. Bakker, "Inter- and intraobserver agreement on the Load Sharing Classification of thoracolumbar spine fractures," *Injury*, vol. 43, no. 4, pp. 416–422, 2012.

[15] L. Hrabalek, T. Wanek, M. Adamus, and K. Langova, "Reliability of load-sharing classification in indications for anterior vertebral body replacement in thoracolumbar spine fractures," *Rozhledy v Chirurgii*, vol. 89, pp. 223–228, 2010.

[16] T. McCormack, E. Karaikovic, and R. W. Gaines, "The load sharing classification of spine fractures," *Spine*, vol. 19, no. 15, pp. 1741–1744, 1994.

[17] S. Fuentes, B. Blondel, P. Metellus, J. Gaudart, T. Adetchessi, and H. Dufour, "Percutaneous kyphoplasty and pedicle screw fixation for the management of thoraco-lumbar burst fractures," *European Spine Journal*, vol. 19, no. 8, pp. 1281–1287, 2010.

[18] F. Zairi, C. Court, P. Tropiano et al., "Minimally invasive management of thoraco-lumbar fractures: combined percutaneous fixation and balloon kyphoplasty," *Orthopaedics and Traumatology: Surgery and Research*, vol. 98, no. 6, pp. S105–S111, 2012.

[19] A. Shawky, A.-M. A. R. Z. Al-Sabrout, M. El-Meshtawy, K. M. Hasan, and H. Boehm, "Thoracoscopically assisted corpectomy and percutaneous transpedicular instrumentation in management of burst thoracic and thoracolumbar fractures," *European Spine Journal*, vol. 22, no. 10, pp. 2211–2218, 2013.

[20] G. R. Rechtine, P. L. Bono, D. Cahill, M. J. Bolesta, and A. M. Chrin, "Postoperative wound infection after instrumentation of thoracic and lumbar fractures," *Journal of Orthopaedic Trauma*, vol. 15, no. 8, pp. 566–569, 2001.

[21] T. Sihvonen, A. Herno, L. Paljarvi, O. Airaksinen, J. Partanen, and A. Tapaninaho, "Local denervation atrophy of paraspinal muscles in postoperative failed back syndrome," *Spine*, vol. 18, no. 5, pp. 575–581, 1993.

[22] B. Blondel, S. Fuentes, G. Pech-Gourg, T. Adetchessi, P. Tropiano, and H. Dufour, "Percutaneous management of thoracolumbar burst fractures: evolution of techniques and strategy," *Orthopaedics and Traumatology: Surgery and Research*, vol. 97, no. 5, pp. 527–532, 2011.

[23] Y. P. Charles, A. Walter, S. Schuller, D. Aldakheel, and J.-P. Steib, "Thoracolumbar fracture reduction by percutaneous in situ contouring," *European Spine Journal*, vol. 21, no. 11, pp. 2214–2221, 2012.

[24] S. Fuentes, P. Metellus, J. Fondop, G. Pech-Gourg, H. Dufour, and F. Grisoli, "Percutaneous pedicle screw fixation and kyphoplasty for management of thoracolumbar burst fractures," *Neurochirurgie*, vol. 53, no. 4, pp. 272–276, 2007.

[25] L. Pimenta, L. Marchi, L. Oliveira, E. Coutinho, and R. Amaral, "A prospective, randomized, controlled trial comparing radiographic and clinical outcomes between stand-alone lateral interbody lumbar fusion with either silicate calcium phosphate or rh-BMP2," *Journal of Neurological Surgery Part A: Central European Neurosurgery*, vol. 74, no. 6, pp. 343–350, 2013.

[26] W.-J. Jeong, J.-W. Kim, D.-K. Seo et al., "Efficiency of ligamentotaxis using PLL for thoracic and lumbar burst fractures in the load-sharing classification," *Orthopedics*, vol. 36, no. 5, pp. e567–e574, 2013.

[27] H. Ataka, T. Tanno, and M. Yamazaki, "Posterior instrumented fusion without neural decompression for incomplete neurological deficits following vertebral collapse in the osteoporotic thoracolumbar spine," *European Spine Journal*, vol. 18, no. 1, pp. 69–76, 2009.

[28] R. Beisse, T. Mückley, M. H. Schmidt, M. Hauschild, and V. Bühren, "Surgical technique and results of endoscopic anterior spinal canal decompression," *Journal of Neurosurgery: Spine*, vol. 2, no. 2, pp. 128–136, 2005.

[29] J. S. Kirkpatrick, "Thoracolumbar fracture management: anterior approach," *The Journal of the American Academy of Orthopaedic Surgeons*, vol. 11, no. 5, pp. 355–363, 2003.

Hindawi Publishing Corporation
BioMed Research International
Volume 2015, Article ID 481945, 6 pages
http://dx.doi.org/10.1155/2015/481945

Research Article

Minimally Invasive Scoliosis Surgery: A Novel Technique in Patients with Neuromuscular Scoliosis

Vishal Sarwahi,[1] Terry Amaral,[1] Stephen Wendolowski,[1] Rachel Gecelter,[1] Melanie Gambassi,[1] Christos Plakas,[2] Benita Liao,[3] Sarika Kalantre,[4] and Chhavi Katyal[5]

[1] *Division of Pediatric Orthopedics, Cohen Children's Medical Center, New Hyde Park, NY 11040, USA*
[2] *Department of Orthopaedic Surgery, Children's Hospital at Montefiore and Albert Einstein College of Medicine, Bronx, NY 10467, USA*
[3] *Department of Pediatric Anesthesiology, Cohen Children's Medical Center, New Hyde Park, NY 11040, USA*
[4] *Division of Pediatric Cardiology, Children's Hospital at Montefiore and Albert Einstein College of Medicine, Bronx, NY 10467, USA*
[5] *Division of Critical Care, Department of Pediatrics, Children's Hospital at Montefiore and Albert Einstein College of Medicine, Bronx, NY 10467, USA*

Correspondence should be addressed to Vishal Sarwahi; vsarwahi@nshs.edu

Received 7 August 2015; Revised 6 October 2015; Accepted 15 October 2015

Academic Editor: Roberto Delfini

Minimally invasive surgery (MIS) has been described in the treatment of adolescent idiopathic scoliosis (AIS) and adult scoliosis. The advantages of this approach include less blood loss, shorter hospital stay, earlier mobilization, less tissue disruption, and relatively less pain. However, despite these significant benefits, MIS approach has not been reported in neuromuscular scoliosis patients. This is possibly due to concerns with longer surgery time, which is further increased due to more levels fused and instrumented, challenges of pelvic fixation, size and number of incisions, and prolonged anesthesia. We modified the MIS approach utilized in our AIS patients to be implemented in our neuromuscular patients. Our technique allows easy passage of contoured rods, placement of pedicle screws without image guidance, partial/complete facet resection, and all standard reduction maneuvers. Operative time needed to complete this surgery is comparable to the standard procedure and the majority of our patients have been extubated at the end of procedure, spending 1 day in the PICU and 5-6 days in the hospital. We feel that MIS is not only a feasible but also a superior option in patients with neuromuscular scoliosis. Long-term results are unavailable; however, short-term results have shown multiple benefits of this approach and fewer limitations.

1. Introduction

MIS technique in AIS has been shown to provide similar correction and pedicle screw accuracy with lower blood loss and rate of transfusion [1]. In adult scoliosis patients, short-term benefits such as less pain, narcotics usage, and shorter hospital stay have also been reported [2]. These benefits seem ideal for patients with neuromuscular scoliosis, who routinely spend more days in the ICU and in the hospital, require prolonged intubation, have increased blood loss, and require multiple units of blood transfusion [3–5]. However, curves in children with neuromuscular scoliosis are usually larger and stiffer, with more number of levels fused and instrumented (16–18) and a need for pelvic fixation [5]. The length and type of skin incision are also important. The standard stab incision for placement of percutaneous pedicle screws cannot be utilized as passing a rod that is contoured in the normal sagittal profile (thoracic kyphosis and lumbar lordosis) will be quite challenging and thirty-two to thirty-eight stab incisions in the back for screw insertion are less than desired.

In MIS technique for AIS patients, the skin incisions have been modified to three noncontiguous midline incisions through which 2–4 levels (4–8 screws) can be fused utilizing a muscle splitting approach [6]. The pedicle screws are inserted in a free hand anatomic manner obviating the need for fluoroscopy and the technique allows for partial or complete facet osteotomy/excision [6]. Adequate fusion has been documented on CT scans as the fusion bed comprises

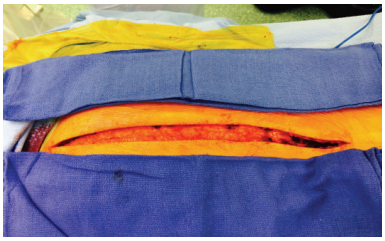

Figure 1: Intraoperative image showing the modification of skin incision to facilitate instrumentation.

the facet joint, pars, and variable areas of transverse process and lamina while preserving the midline osteoligamentous complex [6]. This approach also allows multiple reduction maneuvers, including rod translation, rod derotation, in situ bending, direct vertebral rotation, and spine translation [6]. However, despite all the advantages and feasibility of the technique, MIS approach in AIS takes much longer, which has thus far limited its application in neuromuscular scoliosis.

The purpose of this study is to detail a modification of the previously described technique for minimally invasive posterior spinal fusion, allowing its application in the neuromuscular scoliosis patient population with comparable length of surgery.

2. Materials and Methods

We have been utilizing minimally/less invasive spine surgery techniques in neuromuscular scoliosis patients for around one year. This technique allows for all standard reduction maneuvers, rod insertion, free hand anatomic insertion of pedicle screws with/without image guidance, adequate facet osteotomy to enable fusion, facet joint excision for stiffer curves, and pelvic fixation.

2.1. Surgical Technique. A single midline curvilinear skin incision is made for instrumentation of sixteen to eighteen segments following the deformity (Figure 1).

The skin is undermined and mobilized on either side of midline to allow for the placement of pedicle screws on both sides. The muscle dissection is started in the lumbar spine, where the facet can be manually palpated. A stab incision in the fascia is made, directly over the facet, and muscle plane is developed bluntly between multifidus and longissimus coli with a Cobb elevator or an insulated electrocautery (Figures 2 and 3).

The facet joint is exposed and a small Gelpi retractor is inserted. Further dissection is carried out as needed to expose the adjacent transverse process and portion of the lamina. We take advantage of the overlapping spine anatomy in locating the facet joints at the level above and at the level below. The midline osteoligamentous structures are preserved. Further dissection is extended caudally and cranially to expose additional levels. This approach thus creates a paramedian exposure similar to Wiltse approach along the entire length of the spine and also the posterior superior iliac spine. In the thoracic spine, the fibers of latissimus dorsi and trapezius

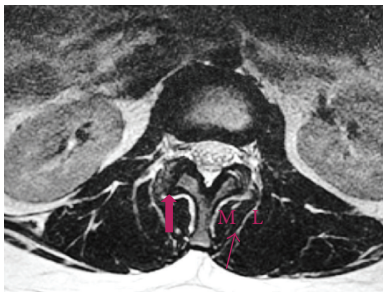

Figure 2: MRI axial image of the lumbar spine with the block arrow pointing to the facet joint, which is the most prominent area after the spinous process and is easily palpable after the lumbar fascia is incised. The thin arrow denotes the plane of dissection between multifidus medially (M) and longissimus laterally (L). This plane is approximately 2 to 2.5 cm lateral to the midline.

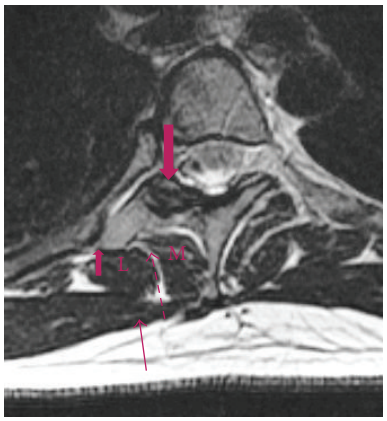

Figure 3: MRI axial image of the thoracic spine showing the facet joint (large block arrow), which is less prominent than the transverse process (small block arrow). The plane of dissection (dashed arrow) is between multifidus medially (M) and longissimus laterally (L). Also notice the fibers running transversely of the trapezius, which lies superficially to the thoracodorsal fascia and has to be incised to expose the surgical plane.

need to be dissected before reaching the thoracodorsal fascia. The longitudinal fibers can be split after the fascia is incised to expose the facet joint. After the facet joint is exposed, a facetectomy is performed with either a $1/4''$ osteotome or a high speed burr. Adequate excision of the facet joint is carried out to ensure a solid fusion. The adjacent transverse process, pars, and portion of lamina are decorticated to create a sizeable fusion bed after the muscle fibers are elevated with Bovie if needed. The fusion bed thus extends from the tip of the transverse process laterally to lamina medially and includes the facet joint and pars interarticularis. This fusion bed area reaches comparable size to standard techniques except for the spinous process, which is often excised by surgeons in the standard technique.

Pedicle screws are placed utilizing the free hand technique but can be inserted under fluoroscopy (Figure 4).

Complete exposure of the transverse process is usually not needed to identify the entry point but can be carried

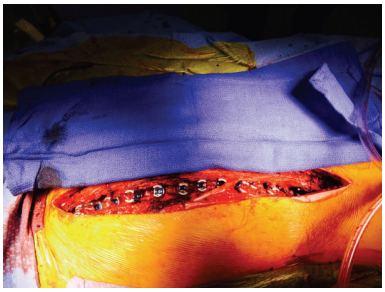

Figure 4: Intraoperative image showing pedicle screws that have been inserted utilizing free hand anatomic technique on the left side at multiple levels.

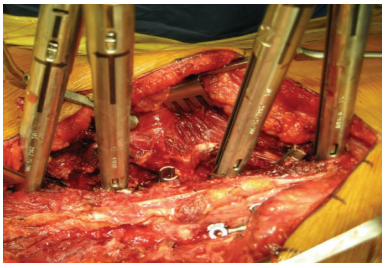

Figure 5: A close-up view of the lumbar spine with rod reduction instruments attached to the pedicle screws at the time of rod insertion.

out if desired. Sacral screw insertion is carried out in a free hand manner but can also be done under fluoroscopy for a tricortical approach. Pelvic fixation can be carried out similarly. The PSIS serves as an attachment for multifidus and thus the dissection plane leads to the entry point. We prefer to place pelvic screws under intermittent fluoroscopy to direct the screw towards dense bone superior to the sciatic notch. Two rods, cut to appropriate length, are contoured in the normal sagittal plane and are inserted caudad to cephalad. We start with the concave rod first. A rod translation or rod derotation maneuver can be carried out to seat the rod compression and distraction as needed can also be carried out. In situ rod contouring can also be carried out but is not our preference. Direct vertebral rotation maneuver is then carried out off the concave-side screws (Figures 5 and 6).

A mix of allograft and autograft mixed with vancomycin powder is layered after burring the posterior portion of spine. Closure is fairly rapid and is carried out in a layered fashion. We utilize subcutaneous medium hemovac drain. Intraoperative anteroposterior and lateral X-rays are taken to confirm adequate correction. An assessment is made at the end of the case about extubating the patient and in most cases is carried out in the operating room. We prefer to use Ketorolac (Toradol, Roche Laboratories, Nutley, NJ) rather than morphine for analgesia. We do not brace our patients and child is allowed sitting and/or wheelchair transfers next day. Activity is increased gradually as tolerated within the limits of pain. Patients can return to school in 3-4 weeks.

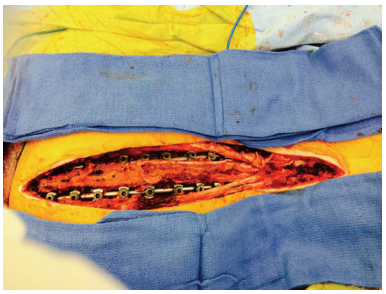

Figure 6: Rods have been inserted on both of the sides and correction has been obtained. Notice that the midline osteoligamentous structures have been preserved.

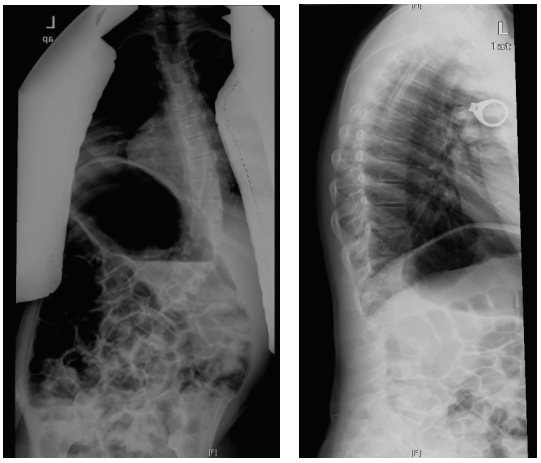

Figure 7: Preoperative radiographs showing a 54-degree scoliosis deformity in a patient with Rett syndrome. Patient has coronal imbalance. The pelvis is level.

3. Results

We present two case examples to show the degree of correction and benefits of MIS technique in neuromuscular scoliosis. In our first case, the patient is an 11-year-old girl with a 54° right-sided long C shaped curve (Figure 7).

She had underlying diagnoses of Rett syndrome. Patient was noncommunicative but was able to ambulate independently. Patient had minimal pelvic obliquity, 5.4 cm of coronal imbalance, and normal sagittal parameters. Patient underwent posterior spine fusion from T3-S1 utilizing pedicle screw instrumentation and the approach described above. Multimodality neuromonitoring was utilized with no changes throughout the surgery. Total duration was 5 hours and estimated blood loss was 600 mL. Patient received 1 unit of packed red blood cells intraoperatively and was successfully extubated at the end of the procedure. Her PICU stay was one day and she was able to get out of bed and ambulate with a walker on POD #2. Her pain was controlled with Tylenol and Toradol around the clock, with oxycodone for breakthrough pain. She was discharged home on POD #4 with her pain controlled on oral medication. At most recent follow-up, she was at her preoperative levels of activity, ambulating, and

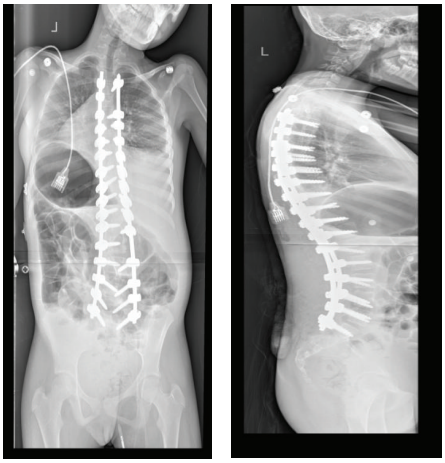

Figure 8: Immediate postoperative radiographic images showing excellent correction of the deformity. Patient is well-balanced in coronal and sagittal planes. The pelvis and shoulder are level.

with no significant pain. Postoperative X-rays are shown in Figure 8.

In our second case, a 13.5-year-old girl with a 100° right-sided main thoracic curve (T6-L1) underwent minimally invasive surgery for correction of her spinal deformity. She presented with cerebral palsy in addition to a history of seizures, developmental delay, and a recent diagnosis of obstructive sleep apnea (Figure 9).

Moreover, the patient is nonverbal, nonambulatory, feeding tube dependent, and asthmatic. Using a similar approach, the patient was instrumented with pedicle screws from T3-S1. No remarkable neuromonitoring changes occurred during the surgery. Total surgical duration was 7 hours with an estimated blood loss of 800 mL. Patient received 2 units of packed red blood cells and 1 unit of platelets intraoperatively. Patient was extubated POD #1 and was transferred to the floor. Pain management was similar to the previously described case. Patient was discharged on POD #5. The postoperative X-rays demonstrate pelvic fixation and show good correction in the coronal and sagittal planes (Figure 10).

4. Discussion

Patients with neuromuscular scoliosis experience higher rates of complications, prolonged ICU stay, and increased blood loss. Jain et al. grouped 617 patients with different diagnosis to assess the relationship between diagnosis and blood loss in children undergoing posterior spinal fusion surgery. They found that patients with cerebral palsy and other neuromuscular disorders had a significantly higher normalized blood loss than patients with idiopathic scoliosis [7]. Edler et al. [5] compared 163 neuromuscular patients with 80 nonneuromuscular patients. They found that 65% of neuromuscular patients lost more than 50% of their estimated blood volume. Modi et al. reported a mean blood loss of 3221 ± 1711 mL in their review of 50 patients with neuromuscular scoliosis who underwent posterior spine fusion using all pedicle screw construct [8]. Twenty of their patients had blood loss of 3500 mL or more, which they found to be a clear determinant of postoperative complications[8]. Tsirikos and Mains reviewed 45 consecutive patients with quadriplegic cerebral palsy who underwent spinal fusion using pedicle screw instrumentation. Thirty-eight patients underwent posterior spine fusion, while 7 underwent staged anterior and posterior spine fusion. They reported an average correction of 74.1%, overall with average blood loss of 0.8 blood volumes, ICU stay of 3.5 days, and hospital stay of 17.6 days in posterior-only group. In anteroposterior group, the average blood loss was 0.9 blood volumes, ICU stay was 8.9 days, and hospital stay was 27.4 days [9]. Tsirikos et al. carried out a retrospective review of 287 patients treated with the unit rod instrumentation with 242 posterior-only and 45 anterior-posterior procedures. They reported an average 68% correction of the deformity. In posterior-only fusion, the average blood loss was 2.8 L, ICU stay was 4.9 days, and the hospital stay was 19.6 days. In combined procedures, the average blood loss was 3.4 L, ICU stay was 6.7 days, and the hospital stay was 24.5 days [10]. Hammett et al. retrospectively reviewed 11 patients with Rett syndrome who underwent scoliosis surgery. The average age of the cohort was 12. Eight of their patients suffered one or more significant complications with an average inpatient stay of 18.2 days [11]. Rumbak et al. reviewed patients with Rett syndrome undergoing scoliosis surgery in regard to rates of respiratory failure and rates of ventilator-acquired pneumonia in comparison to patients with neurologic scoliosis and adolescent idiopathic scoliosis. There were 133 patients with adolescent idiopathic scoliosis, 48 patients with neurologic scoliosis, and 8 patients with Rett syndrome. They found that patients with Rett syndrome undergoing scoliosis surgery have higher rates of respiratory failure and longer ventilation times in the postoperative period when compared with both adolescent idiopathic scoliosis and neurologic scoliosis patients [12].

Considering the reported advantages of the MIS technique in AIS and adult scoliosis surgery, it is intuitive to apply the benefits in neuromuscular scoliosis. Certainly less blood loss and pain can impact the amount of pain medications, fluids, and even the duration of intubation in these compromised children. However, MIS technique in neuromuscular scoliosis has thus far not been reported largely due to concern for prolonged surgery and anesthesia, which can increase the blood loss, fluids, and risk of infection. Also it is challenging to pass a curved rod over 12-13 segments through small incisions and to pass it over 16–18 segments and the pelvic fixation appears quite daunting. We have therefore modified the MIS for AIS approach and have utilized it in neuromuscular patients. Instead of multiple skin incisions, we now use a single midline incision that follows the curve. After this the dissection is between the multifidus medially and longissimus laterally. Since this plane exists naturally, the dissection involves separation of the muscles and is quite bloodless. Occasionally, a small leash of blood vessel is seen on the surface of longissimus and can be coagulated preemptively. Instead of making separate stab incisions in the fascia, which is done in the MIS approach, we make a longitudinal incision along the muscle plane. We find that multiple stab incisions made over adjacent levels

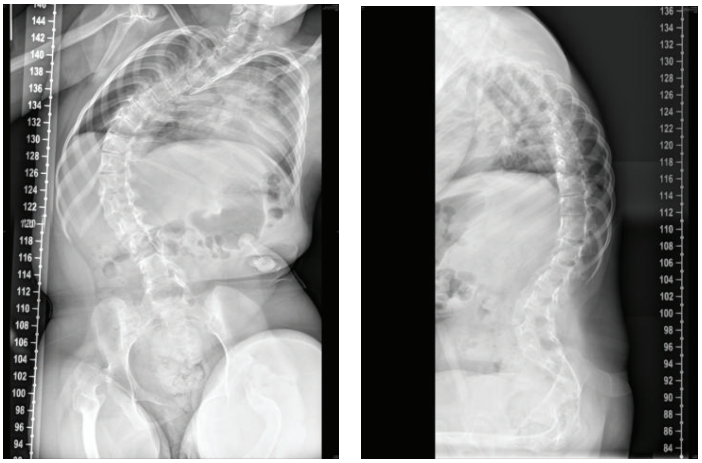

Figure 9: Preoperative radiographs showing a 100-degree scoliosis deformity in a severely involved cerebral palsy patient. The patient has pelvic obliquity of 15 degrees with significant coronal decompensation. Patient is nonambulatory with unilateral hip dislocation.

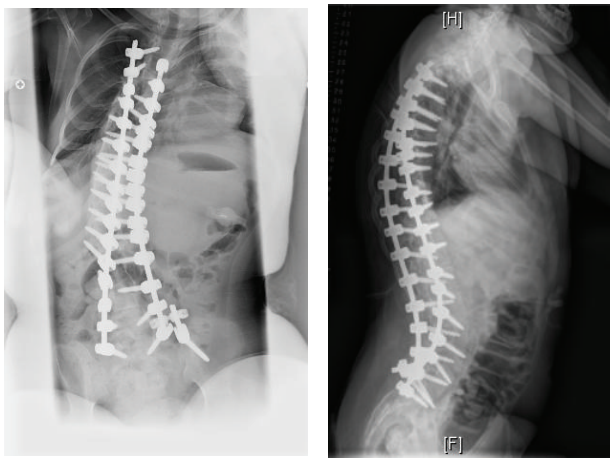

Figure 10: Immediate postoperative radiograph images showing spinal fusion and instrumentation from T3-S1 with significant improvement of the deformity. Unilateral pelvic fixation was carried out in this patient.

tend to coalesce leading to a long incision in the fascia along the muscle plane. Thus single long fascial incision makes the dissection neat and efficient. In the thoracic spine, the crossing fibers of latissimus dorsi and trapezius overlie the thoracodorsal fascia and they need to be dissected to allow access to the facet joint. Generally the facet joints lie 1.5–2 cm from the midline on the concave side and 2–2.5 cm on the convex side. As the dissection proceeds caudally, this distance becomes smaller. In the lumbar spine the facet joints lie more superficial to the transverse process and are easily palpable, whereas in the thoracic spine the transverse process is more prominent. Thus we prefer to start in the lumbar and thoracolumbar spine and extend cephalad following the overlapping spine anatomy to expose thoracic spine facets.

It can be argued that the size of the skin incision does not determine minimally invasive technique. Minimally invasive approach in this patient population refers to preservation of tissues, utilization of the preexisting muscle planes, and less disruptive and traumatic dissection. This leads to a lesser amount of pain and blood loss, which is determinant of complications in this group of patients [8]. We have utilized the MIS technique on curves up to 100 degrees and even in children with severe disease involvement. For curves >70 degrees or smaller but less flexible curves, we have utilized previously described transforaminal type osteotomy/facet resection [6]. The entire facet, facet joint capsule, and most ligamentum flavum can be excised, which increases the flexibility and can be carried out at multiple levels. The midline ligamentous and bony structures are preserved [6].

The highlight of this surgical technique paper is the immense perioperative benefit it accrues to children with neuromuscular scoliosis who are otherwise at a much higher risk for morbidity and mortality. The weaknesses are the short-term follow-up and concerns of loss of correction even nonunion. We are presenting this as a surgical technique paper with two case reports showing significant advantages for a challenged population. Our technique has lower blood loss, lesser transfusion risk, and comparable operative time. In addition patients have lower pain medication requirements, stay in the ICU for one day, and can be discharged home in 4–6 days. These advantages are due to better soft tissue preservation, utilizing intermuscular planes for dissection which decreases bleeding and pain. This in turn helps with ICU and hospital stay and pain medications. These combined benefits are much superior to those which have been previously reported and are worthy of reporting even with short-term follow-up. This technique paper hence focuses on the surgical approach and perioperative benefits. The pseudarthrosis rate previous to pedicle screw fixation was around 10% [13]. With pedicle screw fixation nonunion is rare and is usually associated with deep infection. Our technique is no different than the standard method in terms of fixation and is comparable to fusion area, but its perioperative benefits are far superior and can potentially change the outcomes in neuromuscular scoliosis which are otherwise riddled with major medical complications.

Our results indicate that good correction in coronal and sagittal planes can be achieved safely. In curves that are flexible, 75–80% correction can be achieved. However the greatest benefit of this technique is less blood loss, shorter PICU and hospital stay, earlier mobilization, and less pain and need for pain medication [1]. The operative time needed to complete this surgery is comparable to standard scoliosis surgery [1, 2].

5. Conclusion

Minimally invasive approach seems to provide the greatest benefits to patients with neuromuscular scoliosis in terms of blood loss, pain, and ICU and hospital stay. A longer-term study is currently underway at our institution.

Conflict of Interests

Vishal Sarwahi is a Consultant at Medtronic and Spinal USA and receives royalties from Spinal USA. All the other authors have no conflict of interests to declare.

References

[1] V. Sarwahi, J. J. Horn, P. M. Kulkarni et al., "Minimally invasive surgery in patients with adolescent idiopathic scoliosis: is it better than the standard approach? A two year follow-up study," *Journal of Spinal Disorders and Techniques*, 2014.

[2] N. Anand, R. Rosemann, B. Khalsa, and E. M. Baron, "Mid-term to long-term clinical and functional outcomes of minimally invasive correction and fusion for adults with scoliosis," *Neurosurgical focus*, vol. 28, article E6, 2010.

[3] N. A. Murphy, S. Firth, T. Jorgensen, and P. C. Young, "Spinal surgery in children with idiopathic and neuromuscular scoliosis. What's the difference?" *Journal of Pediatric Orthopaedics*, vol. 26, no. 2, pp. 216–220, 2006.

[4] D. L. Reames, J. S. Smith, K.-M. G. Fu et al., "Complications in the surgical treatment of 19,360 cases of pediatric scoliosis: a review of the Scoliosis Research Society Morbidity and Mortality database," *Spine*, vol. 36, no. 18, pp. 1484–1491, 2011.

[5] A. Edler, D. J. Murray, and R. B. Forbes, "Blood loss during posterior spinal fusion surgery in patients with neuromuscular disease: is there an increased risk?," *Paediatric Anaesthesia*, vol. 13, no. 9, pp. 818–822, 2003.

[6] V. Sarwahi, A. L. Wollowick, E. P. Sugarman, J. J. Horn, M. Gambassi, and T. D. Amaral, "Minimally invasive scoliosis surgery: an innovative technique in patients with adolescent idiopathic scoliosis," *Scoliosis*, vol. 6, article 16, 2011.

[7] A. Jain, D. B. Njoku, and P. D. Sponseller, "Does patient diagnosis predict blood loss during posterior spinal fusion in children?" *Spine*, vol. 37, no. 19, pp. 1683–1687, 2012.

[8] H. N. Modi, S.-W. Suh, J.-H. Yang et al., "Surgical complications in neuromuscular scoliosis operated with posterior- only approach using pedicle screw fixation," *Scoliosis*, vol. 4, article 11, 2009.

[9] A. I. Tsirikos and E. Mains, "Surgical correction of spinal deformity in patients with cerebral palsy using pedicle screw instrumentation," *Journal of Spinal Disorders & Techniques*, vol. 25, no. 7, pp. 401–408, 2012.

[10] A. I. Tsirikos, G. Lipton, W.-N. Chang, K. W. Dabney, and F. Miller, "Surgical correction of scoliosis in pediatric patients with cerebral palsy using the unit rod instrumentation," *Spine*, vol. 33, no. 10, pp. 1133–1140, 2008.

[11] T. Hammett, A. Harris, B. Boreham, and S. M. H. Mehdian, "Surgical correction of scoliosis in Rett syndrome: cord monitoring and complications," *European Spine Journal*, vol. 23, no. 1, pp. S72–S75, 2014.

[12] D. M. Rumbak, W. Mowrey, S. W. Schwartz et al., "Spinal fusion for scoliosis in rett syndrome with an emphasis on respiratory failure and opioid usage," *Journal of Child Neurology*, 2015.

[13] J. E. Lonstein, S. E. Koop, T. F. Novachek, and J. H. Perra, "Results and complications after spinal fusion for neuromuscular scoliosis in cerebral palsy and static encephalopathy using luque galveston instrumentation: experience in 93 patients," *Spine*, vol. 37, no. 7, pp. 583–591, 2012.

Hindawi Publishing Corporation
BioMed Research International
Volume 2015, Article ID 458284, 8 pages
http://dx.doi.org/10.1155/2015/458284

Clinical Study

Simultaneous Lateral Interbody Fusion and Posterior Percutaneous Instrumentation: Early Experience and Technical Considerations

Doniel Drazin,[1] Terrence T. Kim,[2] and J. Patrick Johnson[1,3]

[1] *Department of Neurosurgery, Cedars-Sinai Medical Center, Los Angeles, CA 90048, USA*
[2] *Department of Orthopedic Surgery, Cedars-Sinai Medical Center, Los Angeles, CA 90048, USA*
[3] *Department of Neurosurgery, UC Davis Medical Center, Sacramento, CA 95817, USA*

Correspondence should be addressed to J. Patrick Johnson; patrick.johnson@cshs.org

Received 7 August 2015; Accepted 25 October 2015

Academic Editor: Alessandro Landi

Lumbar fusion surgery involving lateral lumbar interbody graft insertion with posterior instrumentation is traditionally performed in two stages requiring repositioning. We describe a novel technique to complete the circumferential procedure simultaneously without patient repositioning. Twenty patients diagnosed with worsening back pain with/without radiculopathy who failed exhaustive conservative management were retrospectively reviewed. Ten patients with both procedures simultaneously from a single lateral approach and 10 control patients with lateral lumbar interbody fusion followed by repositioning and posterior percutaneous instrumentation were analyzed. Pars fractures, mobile grade 2 spondylolisthesis, and severe one-level degenerative disk disease were matched between the two groups. In the simultaneous group, avoiding repositioning leads to lower mean operative times: 130 minutes (versus control 190 minutes; $p = 0.009$) and lower intraoperative blood loss: 108 mL (versus 93 mL; NS). Nonrepositioned patients were hospitalized for an average of 4.1 days (versus 3.8 days; NS). There was one complication in the control group requiring screw revision. Lateral interbody fusion and percutaneous posterior instrumentation are both readily accomplished in a single lateral decubitus position. In select patients with adequately sized pedicles, performing simultaneous procedures decreases operative time over sequential repositioning. Patient outcomes were excellent in the simultaneous group and comparable to procedures done sequentially.

1. Introduction

Spinal fusions were conventionally done through open surgical methods via anterior or posterior approaches. With the recent advancements in technology, surgical methods, and imaging techniques, innovative minimally invasive spine surgery has emerged [1–3]. A recent popular development has been the lateral transpsoas approach, which became a reality through enhanced visual ability, improved retraction techniques, and a better understanding of surgical anatomy [1–3]. While this modern technique offers multiple advantages, surgeons should understand its methodology, indications, and possible complications. Introduced by Mayer in 1997 and later modified by McAfee, Pimenta, and Ozgur, the procedure approaches the lumbar spine laterally through retroperitoneal fat and the psoas major [4–6]. Problems are occasional because it evades the major blood vessels and abdominal organs, and it eliminates the need for another surgeon for anterior access [6].

Lateral interbody lumbar fusion procedures are becoming more common for degenerative lumbar disease requiring instrumentation and they are typically performed by repositioning the patient to complete the second stage of the circumferential procedure [7, 8]. We have developed a method for performing both procedures in a single lateral position, which may shorten the length of surgery and increase operative efficiency while maintaining surgical precision.

The following technique should be considered in select patients undergoing a minimally invasive lateral transpsoas interbody fusion with a subsequent posterior percutaneous

instrumentation. This technical note describes our early experience with this method, our technical nuances, and the potential benefits that it may provide for both the surgeon and the patient.

2. Preoperative Considerations

2.1. Patient's Bony Anatomy and Body Habitus. With normal anatomic variances among spine patients, we would tend to avoid this technique in "small or atrophic/dystrophic" pedicles, "rotated, asymmetric" pedicles, or certain L5 pedicles that are difficult to visualize. Additionally, on severe osteoporotic patients with difficult visualization of pedicle anatomy, it is not recommended. Although MIS techniques can be used effectively in larger obese patients, our technique is limited by the fluoroscopic penetrance through soft tissue—which can affect clear visualization of the bony anatomy. On the other hand, in patients with multiple severe comorbidities patients who require several personnel to assist for repositioning, we find that this is a strong consideration for application of this technique.

2.2. Number of Levels of Instrumentation. In patients with more than two levels of instrumentation, we have found unique limitations in the instrumentation systems, difficulty with pedicle cannulation, and complexity of rod delivery. As we find no appreciable gain/efficiency in operative time saved, we do not recommend this technique in patients beyond two levels of instrumentation.

Complication avoidance with simultaneous lateral interbody fusion and percutaneous posterior instrumentation in the lateral position consisted in the following:

Avoiding small, atrophic/dystrophic, rotated, asymmetric pedicles.

Avoiding morbidly obese if using fluoroscopy.

Limiting the procedure to two levels of instrumentation.

3. Operative Considerations

3.1. Selection of Operating Room Table. Table selection and patient positioning are crucial to the success of this surgical technique. Selection of the ideal operating table is typically one with multiplane adjustment capabilities for use after the patient is secured to the table (Sliding Skytron or breakable Jackson table). In our practice, we utilize a sliding Skytron table with a kidney bump. Before the patient is transferred to the operative table, a "reverse" of the orientation is made so the foot of the table is at the head anesthesiologist location. The table is also slid to the farthest extent to keep the base of the table at the anesthesiologist head—away from the operative field. This allows easy introduction of the mobile fluoroscopy unit and seamless transition between the AP and lateral planes.

3.2. Patient Positioning. Once the patient is turned in the lateral decubitus position, an axillary roll is inserted and all pressure areas are padded. The arms are positioned away from the abdomen, and the patient's thorax and pelvis/lower extremities are tapped to the table—aligning the greater trochanter to the break in the table. The table is then adjusted using fluoroscopic guidance to achieve the ideal visualization for the disc spaces and bony pedicles.

A specific note is made to placement of the lateral decubitus patient beyond the lateral edge of the table as much as possible (towards the surgeon's side). The dorsal lumbar soft tissue should be hanging over the lateral table and beyond a line drawn from the lateral edge of the OR table. This technical pearl is emphasized in order to achieve enough room for a lateral-medial trajectory for cannulation of the pedicles closest to the floor. We have found that if the patient's dorsal spine does not adequately hang over the lateral edge of the operative bed, then potentially the surgeon will be blocked by the OR table/mattress leading to a potentially unwanted lateral-based screw trajectory.

The lateral flank and posterior spine are prepped and draped in one contiguous fashion. Oftentimes, two iodine-impregnated adhesive skin barriers are required. A note is made to completely prep and drape out the entire dorsal posterior lumbar spine.

3.3. Specific Techniques: Transpsoas Lateral Interbody Fusion. To localize the incision, a perfect lateral fluoroscopic image is obtained centered over our desired disc space. Previous reports have identified ideal starting points for each lumbar disc in relation to the lumbar plexus anatomy [8]. A single oblique incision is made, and a combination of blunt and electrocautery dissection is made to the level of the oblique muscle fascia. The oblique and transversalis muscles are bluntly dissected without electrocautery to the deep abdominal/transversalis fascia. A sharp incision is made through the fascia under direct visualization with care not to pass point, and the retroperitoneal space is entered. Confirmation of the correct anatomic space is made with digital palpation and direct visual inspection. The retroperitoneal space is developed by sweeping the peritoneal contents ventrally, palpating the bony transverse process dorsally, palpating the ilium/iliac wing caudally, and identifying the belly of the psoas muscle deep. The opportunity to "shallow dock" or utilize a microscope for visualization is possible; however, this is not commonly employed in our practice.

A neuromonitoring electrical stimulation probe is guided down to the psoas with finger retraction of the peritoneal contents. A lateral fluoroscopic image is used to guide our probe trajectory. With free-running EMGs, the stimulated probe is used to traverse the psoas muscle and enter the disc space. Care is taken not to injure the lumbar plexus or associated nerve roots. Serial dilators and specialized illuminated retractors are deployed and the discectomy and interbody insertion are completed. Throughout the procedure neurophysiologic electromonitoring is utilized.

3.4. Specific Techniques: Percutaneous Posterior Instrumentation and Fusion. The patient position remains *unchanged* for the second-stage posterior procedure. Implant selection for

(a)

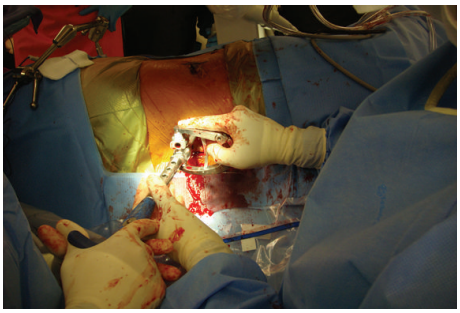

(b)

Figure 1: Intraoperative photographs of Jamshidi needle placement (a) followed by posterior fixation (b) while in the lateral position.

this technique is helpful as instrumenting a lateral decubitus patient requires an additional level of difficulty and spatial orientation. Recommendations are made to utilize MIS instrumentation systems that allow for "guided" insertion of the rod to the pedicle screw reduction towers. In our experience, for one- to three-level fusions, guided MIS rods (MIS Sextant, Medtronic Inc., Memphis, TN, and MIS Ballista, Biomet Inc., Warsaw, IN) offer the ability to insert percutaneous rods into pedicle screw reduction towers with ease and without significant soft tissue difficulty (Figures 1(a) and 1(b)). We recommend, however, any system with which the surgeon feels most comfortable.

Percutaneous delivery of posterior instrumentation is done in the standard fashion utilizing fluoroscopic guidance, Jamshidi trocar, Kirchner guide wires, and cannulated instruments. Traditional MIS techniques involving a lateral-based insertion point away from the adjacent facet joint, correlation with acceptable AP/lateral imaging, and confirmatory neuromonitoring stimulation of pedicle taps are employed. It is noted once again that because the patient is positioned beyond the lateral edge of the operative table, insertion of the ideal "lateral to medial" trajectory of the pedicles closest to the floor is uninhibited. We do confirm that there is an initial learning curve with instrumenting a laterally positioned patient and report the threshold for comfortability to be at approximately 8–10 cases.

The rods are inserted in a standard fashion either through a separate or previous incision and all set screws are final tightened to manufactured settings. All instrumentation is removed and the wounds are irrigated and closed in a standard fashion.

3.5. Intraoperative CT-Guided Navigation of Instrumentation. We have most recently replaced the use of fluoroscopy for posterior percutaneous instrumentation with intraoperative CT-guided spinal navigation for patients requiring more than one-level fusions. In this lateral position, we have found no significant limitations in interchanging imaging modalities. Additionally, we have found similar results in regard to workflow efficiency, OR time, and clinical outcomes. However, this remains outside of the full scope of this paper.

4. Methods

We performed a retrospective chart review of ten consecutive patients who underwent both procedures simultaneously (nonrepositioned) and compared the outcomes with a control group of ten patients who underwent the lateral interbody fusion and were then repositioned for posterior percutaneous screw fixation (repositioned). Across both groups, patients were matched for by age and reason for surgery. In both groups, pars fractures with instability (4), mobile grade two spondylolisthesis (4), and the remaining patients had severe degenerative disk disease at a single level (12). Indications for surgery included worsening back pain in patients who failed exhaustive conservative management.

5. Illustrative Case

A 47-year-old male presented with end-stage degenerative disc disease at L2/3 with associated severe back pain and bilateral lower extremity radiculopathy that had failed an extensive course of nonoperative management. Advanced imaging, including CT and MRI, revealed a grade 1 degenerative spondylolisthesis with associated facet arthrosis. Due to the collapse of the disc space, MRI demonstrated lateral recess and foraminal narrowing with neural stenosis but no acute herniated nucleus pulposus or severe ligamentum hypertrophy. Intraoperatively, the patient was placed in a right lateral decubitus position with the left flank and posterior dorsal spine prepped and draped in one setting. He underwent an L2/3 left lateral transpsoas discectomy and interbody fusion, followed by posterior percutaneous fixation without repositioning. Postoperative films were adequate (Figure 2), and he experienced no intraoperative or clinical complications.

6. Results

Between March 2010 and November 2011, twenty patients underwent lateral interbody fusion followed by posterior percutaneous screw fixation followed for an average of 9 months (range 6 months–12 months). The nonrepositioned group included 3 women and 7 men, while the repositioned group included 6 women and 4 men. The average age was 54.5 years (range 30–78, nonrepositioned) and 57.8 years (range 45–71, repositioned). Avoiding repositioning, operative time from incision to closure averaged 130.5 minutes (versus repositioned 190.3 minutes; $p < 0.05$) and intraoperative

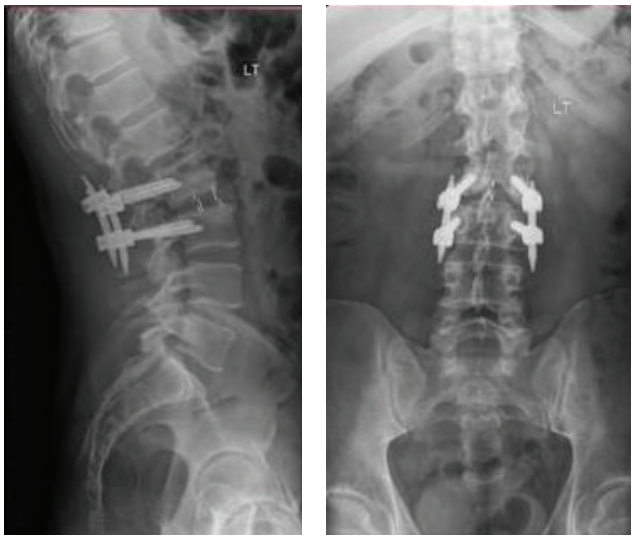

Figure 2: Postoperative lateral and AP views showing lateral interbody graft and posterior instrumentation.

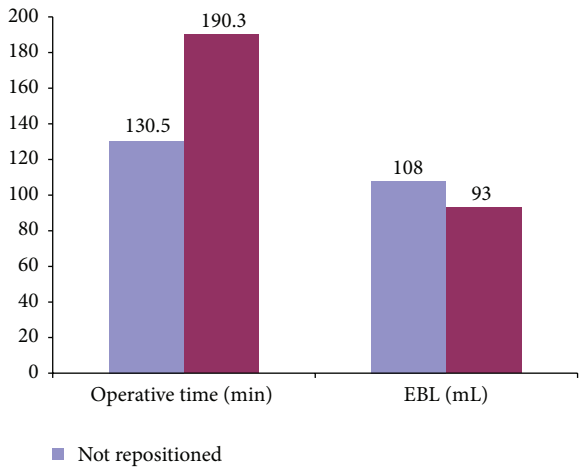

Figure 3: Graph of estimated blood loss and operative time in repositioned versus nonrepositioned patients.

blood loss was 108 mL (versus 93 mL; NS, Figure 3). Nonrepositioned patients were hospitalized for an average of 3.8 days (versus 4.1 days; NS). Details of patients' characteristics are outlined in Table 1. Of the twenty patients who underwent surgery, there were 3 patients (2 in repositioned and 1 in nonrepositioned) who experienced transient (less than 2 weeks) postoperative numbness on the side they had the lateral interbody fusion. No patient, in either group, reported weakness or significant pain related to the approach from the postoperative period through the most recent follow-up. Postoperative imaging confirmed appropriate positioning of the hardware; however one patient in the repositioned cohort required screw repositioning.

Table 1: Characteristics of patients with repositioned versus nonrepositioned surgery.

Characteristic	Population	
	Repositioned	Nonrepositioned
Number of patients	10	10
Mean age (range)	57.8 (45–71)	54.5 (30–78)
Gender		
Male	4	7
Female	6	3
M/F ratio	1 : 1.5	2.3 : 1
BMI, mean	28.46	24.87
Weight (kg), mean	82.9	75.64
Pertinent history (%)		
Pars fractures	2 (20)	2 (20)
Spondylolisthesis	2 (20)	2 (20)
Severe degenerative disc disease	6 (60)	6 (60)
Operative time (minutes), mean	190.3	130.5*
Estimated blood loss (mL), mean	93	108
Days hospitalized	4.1	3.8

* $p < 0.05$.

7. Discussion

During the earliest years, surgeons operated on the spine through the most direct approach to reach the vertebral column—via a posterior fashion [1]. With the emergence of Pott's disease, anterior approaches were introduced to combat this vertebral infectious process [1]. The focal point of both approaches was reestablishing spinal biomechanical stability. Compared to posterolateral fusions, interbody fusions have been theorized to provide finer alignment, greater rates of fusion, and superior patient results [9–13]. An anterior lumbar implant has been shown to contribute significantly to biomechanical durability [1], and implant placement techniques have advanced through ALIF, PLIF, TLIF, and laparoscopic ALIF to the more recent lateral interbody fusion (LIF).

Reported by Burns in 1933, the anterior lumbar interbody fusion (ALIF) was one of the first lumbar interbody surgeries performed [1, 3, 14]. As an anterior approach for the treatment of spondylolisthesis, a complete discectomy was performed and a cadaveric bone graft was utilized [1, 3, 14]. The ALIF delivers a straight approach to the disc space with perhaps the greatest exposure providing the capability to achieve a more complete discectomy and fusion [3, 9, 15–17]. Additionally, there is no nerve root retraction or intrusion into the spinal canal as seen with the PLIF [15, 18]. The utility of the procedure has expanded to treat a number of spine conditions, including neoplastic conditions, infectious process, deformities, and instability [3, 18–21]. Disadvantages are serious and include the possibility of damage to anterior vessels, abdominal organs, sympathetic nerve plexus, and retroperitoneal structures [1, 3]. Moreover, if supplemental posterior instrumentation or decompression is required, a separate posterior incision and approach must

be performed. The technique was modified posteriorly as a posterior lumbar interbody fusion (PLIF) in 1953 by Cloward with the goal of maintaining facet joints along with a cage or graft [2, 3, 22]. The PLIF permitted a thorough decompression of the nervous structures without disrupting abdominal elements. At the same time, it allowed the surgeon to perform a more circumferential fusion [1, 3]. Ntoukas and Müller compared results of the traditional "open" PLIF with a percutaneous minimally invasive PLIF and found the percutaneous approach to have less mean blood loss (135 versus 432 mL) and a shorter hospital stay (5 versus 10 days) but a longer operative time (275 versus 152 min) without significant difference in clinical and radiological outcome [23]. A disadvantage of the technique is that it entails retraction of nerve roots to permit sufficient discectomy potentiating nerve root and dural injuries, a hurdle that the transforaminal lumbar interbody fusion (TLIF) would attempt to counter later in the 1980s [1, 3, 9].

In the years following the introduction of the PLIF, reports about the ALIF's surgical strain and patient morbidity began to emerge [1, 24]. This would be the impetus later in 1990s for minimally invasive variations on the operation such as laparoscopic and mini-open approaches. But prior to these developments, an essential procedure was introduced in the 1980s: the TLIF. As mentioned, the TLIF tried to counter hurdles of its PLIF predecessor and additionally offered a better view of the disc space [1, 3, 9]. Since it is a posterior approach, spine surgeons were more comfortable with it, allowing them to correct posterior pathological processes and perform more complete fusions [25–27]. It also avoids any contralateral damage and thus decreases the likelihood of future complications in neighboring levels [3, 28–30]. In a prospective study of 52 patients undergoing the procedure, Hackenberg et al. [31] reported an average operative time of 173 minutes, an average blood loss of 485 mL, a fusion rate of 89%, and 4 (7.7%) patients developing serious complications. Unlike other approaches, the extent of discectomy that can be performed is limited with the TLIF [9]. Additionally, similar to the PLIF, the TLIF removes various components of the posterior structures compromising stability, can cause spinal canal scarring, and can damage paraspinal muscles [3, 21]. Nonetheless, the evolution in the way lumbar interbody fusions were performed up to this point would provide the framework for the development of the lateral transpsoas procedure introduced in 1997.

The 1990s saw pioneering alterations to lumbar spine fusion methods. Indeed, these new techniques would catapult spine surgery into the minimally invasive surgical era. In the earlier part of the decade, the laparoscopic and mini-open modifications of the ALIF were introduced [1–3]. While they were deemed as safer alternatives, they still had similar risks as the original, such as great vessel harm and retrograde ejaculation [1, 3, 6]. There were also the new obstacles of becoming familiar with laparoscopic tools, CO_2 gas insufflation, and possibility of bowl perforation [1, 32]. Additionally, the learning curve for some of these elaborate techniques seemed to be quite high [4, 6]. Over the next few years, significant improvements in retraction tools and advances in instrumentation would further the application of minimally invasive surgical techniques to the lumbar spine. McAfee was first to report on an anterolateral retroperitoneal approach for treatment of thoracolumbar fractures in the mid-1980s [1, 33]. Key players in lumbar spine surgery would later apply minimally invasive techniques to this operation during the mid-1990s.

In 1998, McAfee et al. published on a minimally invasive microsurgical retroperitoneal lateral approach that would lay the foundation for the direct lateral interbody fusion [4]. With a 4 cm skin incision, muscle-splitting exposure, a self-retaining spreader frame, and microscopy, the technique was revolutionary. The procedure minimized surgical trauma to the patient, used standardized surgical instruments, emphasized good illumination along with the surgical microscope, had minimal blood loss (67.8–168 mL), and decreased operative time (2.0–2.25 hours) [4]. Importantly, spine surgeons could easily implement this technique as it did not necessitate the learning of methods that were completely foreign to them, nor did it dictate the type of fusion [4, 34]. For patients, it provided minimal surgical discomfort, decreased postoperative morbidity, and improved recovery time [4, 34]. Problems are occasional and primarily involve temporary paresis and dysesthesias in the lower extremities [2, 35]. Shortly thereafter, McAfee reported a similar procedure that utilized endoscopy, balloon insufflator dissection, and placement of interbody cages [5]. Compared to the traditional anterior approach, the technique also had lower morbidity, mean length of hospital stay (2.9 days), mean blood loss (205 cc), and operative time (115.2 minutes). Additionally, there were no cases of pseudoarthrosis or implant migration at mean follow-up of 24.3 months. Ahmadian et al. would next describe what became known as the extreme lateral interbody fusion, which had tremendous advantages over conventional anterior and posterior methods [6].

The extreme LIF was initially presented by Pimenta in 2001 as a variation on the retroperitoneal approach to the lumbar spine [2, 6]. It provides similar advantages to its predecessors including a gentle learning curve, lack of necessity of an access surgeon, and a reduction in complications such as visceral harm, great vessel injury, and sexual dysfunction [3, 6]. Aside from this, it also preserves the posterior ligaments and bony structures and thus maintains anatomical stability and alignment while providing maximal access to the disc space and ring apophysis to allow for a complete disc extrusion and deformity adjustment [1]. It does not require retraction or distention of the psoas major and thus the likelihood of transient paresthesia and paresis due its injury are diminished compared with prior lateral approaches [6]. As with prior minimally invasive procedures, the extreme LIF is highly fluoroscopy dependent, which in return is operator and surgeon dependent [6]. As with all lateral fusions, there is also a risk of injury to the genitofemoral nerve and lumbosacral plexus, which has been cited as the most common complication [7]. Moreover, for patients that require percutaneous pedicle screws, repositioning is required to the prone position or a staged procedure is done [6]. Our new novel procedure, explained in detail in this paper, does not require repositioning or a staged procedure,

and screw placement is done simultaneously in the same lateral transpsoas position.

The minimally invasive retroperitoneal transpsoas lateral approach is becoming more popular among spine surgeons [7, 34]. Since its introduction, the technique has been applied to treat multiple spinal disorders including degenerative lumbar disease, spondylosis, spondylolisthesis, deformity, trauma, infection, and tumor [34]. As such, more and more LIFs are performed along with posterior percutaneous screw fixation. Typically, such a circumferential procedure is done by repositioning the patient to complete the second stage of screw placement. In order to avoid the problem of repositioning, we have developed a method for performing both procedures in a single lateral position. This technique will shorten the length of surgery and increase operative efficiency while maintaining surgical precision. We have shown that the procedure is applicable to a number of spinal conditions including degenerative disk disease, spondylolisthesis, ligamentous injury, and vertebral fractures. Additionally, the procedure has great utility in situations where emergent fixation is necessary as in trauma patients and in cases with contraindications to repositioning such as those with an exposed abdomen. By avoiding repositioning, operative time dropped significantly and intraoperative blood loss was comparable. Consequently, in select patients with adequate sized pedicles, performing simultaneous procedures offers an advantage over sequential surgery requiring repositioning. Implementing the operations together accomplished a three-column fusion with increased stability over each procedure performed alone. Patient outcomes were excellent and comparable to procedures done in series. We conclude that the lateral interbody fusion and percutaneous pedicle screw procedures are both readily accomplished in the lateral decubitus position and our preliminary data of this new method indicates that it offers less operative time and a promising potential reduction in morbidities.

With modern technological advances in surgical techniques, imaging modalities, bone graft alternatives, and attempts to decrease patient down time, spine surgery has seen a tremendous shift into the realm of minimally invasive surgery over the last 20 years [1–3, 9]. From the introduction of the operating microscope for discectomies to the more recent transformation of interbody fusions into the LIF, spine surgeons have adopted the notion of minimally invasive techniques. Attaining complete arthrodesis has been at the center of these recent advances in spine surgery, and introduction of bone morphogenic protein (BMP) and the interbody cage are just examples towards this aim [3]. In the realm of lumbar interbody fusions, the development of percutaneous pedicle and facet screw placement by Magerl would set the stage for Mayer, McAfee, and Pimenta for development of minimally invasive interbody fusion methods [2, 21, 36]. The novelties to this operation keep emerging with the most recent addition by Le et al. and Wang et al. to include a lateral plate [8]. Here, we introduce another innovative modification that would offer advantages to both the surgeon and the patient.

The technique described in this paper is to be considered for select patients undergoing a minimally invasive lateral transpsoas interbody fusion approach with a concomitant posterior percutaneous instrumentation. Our recommendation on the feasibility of this technique for a given patient is primarily determined by patient's bony anatomy, body habitus, and the number of levels fused. Pedicles for instrumentation should be large and clearly visualized on radiographs. Additionally, imaging of this anatomy may be affected abundance of soft tissue, a limitation in obese patients. Finally, the benefits of the procedure are not appreciated beyond two levels of instrumentation, and thus we do not recommend it.

A limitation of this study is that all pedicle screws that were placed in the lateral position were performed at a single center; thus the results need to be confirmed in a multicenter study. It is theoretical that the learning curve of this technique is commensurate with surgeon experience and that the combination of the senior surgeon's advanced experience and efficient workflow may explain the comparable excellent outcomes. In addition, there was no comparative radiographic review of lordosis between the repositioned and nonrepositioned patients. In that realm, a recent review by Yson et al. questioned whether prone-repositioning was necessary to gain the needed lordosis from posterior fixation following LIF [37]. In over fifty LIFs, they concluded that posterior fixation could be performed in a lateral position as there was no lordosis gained from repositioning.

Simultaneous lateral interbody fusion and percutaneous posterior pedicle screw fixation avoided repositioning, shortened operative time. Combining both procedures into a single lateral position also maintains surgical precision with comparable excellent outcomes. We are hopeful that this novel technique will contribute to the advancement of modern, minimally invasive spine surgery.

8. Conclusions

The lateral interbody fusion and percutaneous pedicle screw procedures can both be accomplished in the lateral decubitus position. In select patients with adequate size pedicles, performing simultaneous procedures offers an advantage over sequential surgery requiring repositioning. Performing the surgeries together accomplished a circumferential fusion with increased stability over each procedure performed alone. Patient outcomes were excellent and comparable to procedures done in series.

Conflict of Interests

The authors declare that there is no conflict of interests regarding the publication of this paper.

Acknowledgment

The authors would like to thank F. Shweikeh, M.D., for assisting with preparation of the paper.

References

[1] J. H. Oppenheimer, I. DeCastro, and D. E. McDonnell, "Minimally invasive spine technology and minimally invasive spine

surgery: a historical review," *Neurosurgical Focus*, vol. 27, no. 3, p. E9, 2009.

[2] F. H. Shen, D. Samartzis, A. J. Khanna, and D. G. Anderson, "Minimally Invasive Techniques for Lumbar Interbody Fusions," *Orthopedic Clinics of North America*, vol. 38, no. 3, pp. 373–386, 2007.

[3] H. M. Mayer, "A new microsurgical technique for minimally invasive anterior lumbar interbody fusion," *Spine*, vol. 22, no. 6, pp. 691–699, 1997.

[4] P. C. McAfee, J. J. Regan, W. Peter Geis, and I. L. Fedder, "Minimally invasive anterior retroperitoneal approach to the lumbar spine. Emphasis on the lateral BAK," *Spine*, vol. 23, no. 13, pp. 1476–1484, 1998.

[5] B. M. Ozgur, H. E. Aryan, L. Pimenta, and W. R. Taylor, "Extreme Lateral Interbody Fusion (XLIF): a novel surgical technique for anterior lumbar interbody fusion," *Spine Journal*, vol. 6, no. 4, pp. 435–443, 2006.

[6] A. Ahmadian, A. R. Deukmedjian, N. Abel, E. Dakwar, and J. S. Uribe, "Analysis of lumbar plexopathies and nerve injury after lateral retroperitoneal transpsoas approach: diagnostic standardization," *Journal of Neurosurgery: Spine*, vol. 18, no. 3, pp. 289–297, 2013.

[7] T. V. Le, D. A. Smith, M. S. Greenberg, E. Dakwar, A. A. Baaj, and J. S. Uribe, "Complications of lateral plating in the minimally invasive lateral transpsoas approach," *Journal of Neurosurgery: Spine*, vol. 16, no. 3, pp. 302–307, 2012.

[8] N. Anand and E. M. Baron, "Direct lateral approach to the lumbar spine," in *Textbook of spine Surgery*, K. H. Bridwell and R. L. DeWald, Eds., vol. 2, pp. 175–182, Lippincott Williams & Wilkins, Philadelphia, Pa, USA, 2001.

[9] T. V. Le, C. J. Burkett, A. R. Deukmedjian, and J. S. Uribe, "Postoperative lumbar plexus injury after lumbar retroperitoneal transpsoas minimally invasive lateral interbody fusion," *Spine*, vol. 38, no. 1, pp. E13–E20, 2013.

[10] N. Anand, J. F. Hamilton, B. Perri, H. Miraliakbar, and T. Goldstein, "Cantilever TLIF with structural allograft and RhBMP2 for correction and maintenance of segmental sagittal lordosis: long-term clinical, radiographic, and functional outcome," *Spine*, vol. 31, no. 20, pp. E748–E753, 2006.

[11] F. B. Christensen, E. S. Hansen, S. P. Eiskjær et al., "Circumferential lumbar spinal fusion with brantigan cage versus posterolateral fusion with titanium cotrel-dubousset instrumentation: a prospective, randomized clinical study of 146 patients," *Spine*, vol. 27, no. 23, pp. 2674–2683, 2002.

[12] M. S. DeBerard, A. L. Colledge, K. S. Masters, R. L. Schleusener, and J. D. Schlegel, "Outcomes of posterolateral versus BAK titanium cage interbody lumbar fusion in injured workers: a retrospective cohort study," *Journal of the Southern Orthopaedic Association*, vol. 11, no. 3, pp. 157–166, 2002.

[13] K. Yashiro, T. Homma, Y. Hokari, Y. Katsumi, H. Okumura, and A. Hirano, "The Steffee variable screw placement system using different methods of bone grafting," *Spine*, vol. 16, no. 11, pp. 1329–1334, 1991.

[14] B. H. Burns, "An operation for spondylolisthesis," *The Lancet*, vol. 221, no. 5728, p. 1233, 1933.

[15] P. Enker and A. D. Steffee, "Interbody fusion and instrumentation," *Clinical Orthopaedics and Related Research*, no. 300, pp. 90–101, 1994.

[16] A. Karim, D. Mukherjee, M. Ankem, J. Gonzalez-Cruz, D. Smith, and A. Nanda, "Augmentation of anterior lumbar interbody fusion with anterior pedicle screw fixation: demonstration of novel constructs and evaluation of biomechanical stability in cadaveric specimens," *Neurosurgery*, vol. 58, no. 3, pp. 522–527, 2006.

[17] J. A. Kozak, A. E. Heilman, and J. P. O'Brien, "Anterior lumbar fusion options. Technique and graft materials," *Clinical Orthopaedics and Related Research*, no. 300, pp. 45–51, 1994.

[18] H. Bohm, J. Harms, R. Donk, and K. Zielke, "Correction and stabilization of angular kyphosis," *Clinical Orthopaedics and Related Research*, no. 258, pp. 56–61, 1990.

[19] D. S. Bradford, "Adult scoliosis. Current concepts of treatment," *Clinical Orthopaedics and Related Research*, vol. 229, pp. 70–87, 1988.

[20] S. D. Gertzbein, C. M. Court-Brown, R. R. Jacobs et al., "Decompression and circumferential stabilization of unstable spinal fractures," *Spine*, vol. 13, no. 8, pp. 892–895, 1988.

[21] D. Drazin, J. C. Liu, and F. L. Acosta Jr., "CT navigated lateral interbody fusion," *Journal of Clinical Neuroscience*, vol. 20, no. 10, pp. 1438–1441, 2013.

[22] R. B. Cloward, "The treatment of ruptured lumbar intervertebral discs by vertebral body fusion. I. Indications, operative technique, after care," *Journal of Neurosurgery*, vol. 10, no. 2, pp. 154–168, 1953.

[23] V. Ntoukas and A. Müller, "Minimally invasive approach versus traditional open approach for one level posterior lumbar interbody fusion," *Minimally Invasive Neurosurgery*, vol. 53, no. 1, pp. 21–24, 2010.

[24] T. Faciszewski, R. B. Winter, J. E. Lonstein, F. Denis, and L. Johnson, "The surgical and medical perioperative complications of anterior spinal fusion surgery in the thoracic and lumbar spine in adults. A review of 1223 procedures," *Spine*, vol. 20, no. 14, pp. 1592–1599, 1995.

[25] H. T. Hee, F. P. Castro Jr., M. E. Majd, R. T. Holt, and L. Myers, "Anterior/posterior lumbar fusion versus transforaminal lumbar interbody fusion: analysis of complications and predictive factors," *Journal of Spinal Disorders*, vol. 14, no. 6, pp. 533–540, 2001.

[26] S. C. Humphreys, S. D. Hodges, A. G. Patwardhan, J. C. Eck, R. B. Murphy, and L. A. Covington, "Comparison of posterior and transforaminal approaches to lumbar interbody fusion," *Spine*, vol. 26, no. 5, pp. 567–571, 2001.

[27] W. S. Rosenberg and P. V. Mummaneni, "Transforaminal lumbar interbody fusion: technique, complications, and early results," *Neurosurgery*, vol. 48, no. 3, pp. 569–575, 2001.

[28] K. T. Foley and S. K. Gupta, "Percutaneous pedicle screw fixation of the lumbar spine: preliminary clinical results," *Journal of Neurosurgery*, vol. 97, no. 1, pp. 7–12, 2002.

[29] L. T. Holly, J. D. Schwender, D. P. Rouben, and K. T. Foley, "Minimally invasive transforaminal lumbar interbody fusion: indications, technique, and complications," *Neurosurgical Focus*, vol. 20, article E6, 2006.

[30] R. E. Isaacs, V. K. Podichetty, P. Santiago et al., "Minimally invasive microendoscopy-assisted transforaminal lumbar interbody fusion with instrumentation," *Journal of Neurosurgery: Spine*, vol. 3, no. 2, pp. 98–105, 2005.

[31] L. Hackenberg, H. Halm, V. Bullmann, V. Vieth, M. Schneider, and U. Liljenqvist, "Transforaminal lumbar interbody fusion: a safe technique with satisfactory three to five year results," *European Spine Journal*, vol. 14, no. 6, pp. 551–558, 2005.

[32] J. K. Hannon, W. B. Faircloth, D. R. Lane et al., "Comparison of insufflation vs retractional technique for laparoscopic- assisted intervertebral fusion of the lumbar spine," *Surgical Endoscopy*, vol. 14, no. 3, pp. 300–304, 2000.

[33] P. C. McAfee, H. H. Bohlman, and H. A. Yuan, "Anterior decompression of traumatic thoracolumbar fractures with incomplete neurological deficit using a retroperitoneal approach," *The Journal of Bone & Joint Surgery—American Volume*, vol. 67, no. 1, pp. 89–104, 1985.

[34] B. Hood and S. Vanni, "Minimally invasive extreme lateral trans-psoas approach to the lumbar spine: applications and techniques," in *Spine Surgery*, K. J. Chung, Ed., chapter 5, pp. 43–78, InTech, Rijeka, Croatia, 2012.

[35] R. Q. Knight, P. Schwaegler, D. Hanscom, and J. Roh, "Direct lateral lumbar interbody fusion for degenerative conditions: early complication profile," *Journal of Spinal Disorders and Techniques*, vol. 22, no. 1, pp. 34–37, 2009.

[36] F. Magerl, "External skeletal fixation of the lower thoracic and the lumbar spine," in *Current Concepts of External Fixation of Fractures*, H. K. Uhthoff and E. Stahl, Eds., pp. 353–366, Springer, New York, NY, USA, 1982.

[37] S. C. Yson, J. N. Sembrano, E. R. Santos et al., "Does prone repositioning before posterior fixation produce greater lordosis in lateral lumbar interbody fusion (LLIF)?" *Journal of Spinal Disorders & Techniques*, vol. 27, no. 7, pp. 364–369, 2012.