Single Port Laparoscopic Surgery: Concept and Controversies of New Technique

Guest Editors: Boris Kirshtein, Paul G. Curcillo, Pascal Bucher, Eric M. Haas, Andre Chow, and Paraskevas Paraskeva

Single Port Laparoscopic Surgery: Concept and Controversies of New Technique

Minimally Invasive Surgery

Single Port Laparoscopic Surgery: Concept and Controversies of New Technique

Guest Editors: Boris Kirshtein, Paul G. Curcillo, Pascal Bucher, Eric M. Haas, Andre Chow, and Paraskevas Paraskeva

Editorial Board

Contents

Hindawi Publishing Corporation
Minimally Invasive Surgery
Volume 2012, Article ID 456541, 2 pages
doi:10.1155/2012/456541

Editorial

Single Port Laparoscopic Surgery: Concept and Controversies of New Technique

Boris Kirshtein[1,2] and Eric M. Haas[3]

[1] *Department of Surgery A, Soroka University Medical Center, Beersheba, Israel*
[2] *Faculty of Health Sciences, Ben Gurion University of the Negev, P.O. Box 151, Beer Sheva 84101, Israel*
[3] *University of Texas Medical School at Houston, Houston, TX 77030, USA*

Correspondence should be addressed to Boris Kirshtein, borkirsh@bgu.ac.il

Received 30 September 2012; Accepted 30 September 2012

During the last two decades laparoscopic surgery has become the standard care for the management of various emergent and elective surgical pathologies. Well-known advantages of laparoscopy include faster recovery, less postoperative pain, lower perioperative complications, and improved cosmesis. Recent development of laparoscopy was represented with introduction of the concept of scarless surgery using natural orifice transluminal endoscopic surgery (NOTES). Unfortunately, NOTES approach has not yet has been overcome and refused due to need for specialized instruments, learning curve, and prolonged surgery time.

Single-port laparoscopic surgery (SPLS) is a rapidly evolving technique in the field of minimally invasive surgery. SPLS was initially described in 1992 for gynecologic surgery and in general surgery seven years later. The most commonly reported advantages of SPLS include improved cosmesis, lower morbidity associated with elimination of peripheral ports, shorter length of hospital stay, and potential for decreased incisional pain. Another advantage of this technique is the ability to convert to an alternate minimally invasive procedure such as multiport laparoscopy and avoid the need for an open procedure, therefore maintaining the patient benefits well associated with minimally invasive surgery.

Development of innovative articulated or bent instruments, adjustments in laparoscopes, and developed special multilumen access devices allowed simultaneous multiple instruments insertion facilitated the acceptance of this technique. Increasing application of this modality has been described through case reports and case series proving it is a safe and feasible technique for the surgical treatment of benign and malignant diseases expanded within general, urological, gynecological, and pediatric surgery. Recent publications described using SILS for appendectomy, cholecystectomy, colectomy, adrenalectomy, splenectomy, bariatric surgery, hysterectomy, ovarian cystectomy, and hernias repair. The interest for the technique has gradually progressed toward assessing its efficacy compared with established techniques in minimally invasive surgery. Comparative studies with standard and hand-assisted laparoscopic surgery have shown that SPLS maintains the benefits of minimally invasive surgery.

There are number of challenges associated with SPLS: special access ports, instrumentation, and surgical techniques. Many of healthcare manufacturers that designed and developed various access devices as SPLS port (Covidien, Mansfield, MA, USA), TriPort (Olympus, Wicklow, Ireland), AirSeal (SurgiQest, Inc., Orange, CT, USA), GelPoint (Applied Medical, Rancho Santa Margarita, CA, USA), Endocone (Karl Stortz GmbH & Co, KG, Tutlingen, Germany) have made single site surgery easier and more efficient.

While there exists concern about the learning curve of the experimented surgeons who are used to perform a classic laparoscopic approach, current evidence suggests that this technique can safely be mastered in the hands of experienced laparoscopic surgeons.

The technical challenges of SILS included limited triangulation and retraction due to confinement of the instrumentation to a single axis, requiring a greater level of surgical

experience. A cross-hand technique, flexible tip scope, and articulated instruments have been developed to solve this problem. However, more surgeons reported effective using regular laparoscopic instruments for SPLS procedures.

The concept of performing laparoscopic surgery through a single incision is gaining momentum among patients, surgeons, and industry alike. SPLS is a developing field and, to date, level I and II clinical data on the benefits of SILS are lacking. The various publications relating to the technique are mostly case reports or small series describing the feasibility and technical problems of operations. Most of them suggested that SPLS procedures are comparable to the standard laparoscopic surgery. Furthermore, increasing experience of SPLS will continue to innovate to further improve the ergonomics, feasibility, and range of the technique. This special issue included various reports about using SPLS approach in different surgical fields.

Appendectomy is one of the most frequent urgent surgical procedures. Regarding the use of SPLS for appendectomy, a multicentric study comparing SPLS with standard laparoscopic surgery shows the feasibility and success of this technique extended to not only uncomplicated patients but also to complicated and obese patients. There was no difference shown in spite of surgery time, postoperative pain, and postoperative complications. Patients were satisfied with better cosmesis following SPLS appendectomy.

In regards to biliary tract surgery, laparoscopic cholecystectomy still remains as the gold standard for the surgical removal of the gallbladder in the treatment of symptomatic cholelithiasis. The question is if SPLS cholecystectomy can replace traditional surgical approach. The cosmetic results offered by SPLS have resulted in improved patient satisfaction with the final incision versus the four scars created by the conventional laparoscopic approach. A thorough literature review, technical challenges and instrumentation, complications and outcomes of SPLS cholecystectomy are presented along the work in this special article. in authors' opinion SPLS cholecystectomy is long way off from replacing laparoscopic cholecystectomy due to increased rate of complications with longer operative time, lack of standardization and instrumentation, and needs an additional development.

In the field of colon and rectal surgery, the feasibility and the safety of the SPLS colectomy are gaining acceptance for the treatment of colon diseases and colon cancer. This article not only presents the accepted and proposed advantages for this surgical technique but it also makes it clear to us that some disadvantages are yet to be conquered before the procedure can become the standard in minimally invasive colorectal surgery.

The application of SPLS to a wide variety of procedures is explored during this special edition article as well. A literature review of the use of SPLS in patients with inflammatory bowel disease shows that in experienced hands the use of SPLS is feasible even in patients with complications when used in well-selected patients. The paper showed wide range of possible complications following single incision surgery for IBD and again absence of procedure standardization.

Following experience in adult surgery pediatric surgeons became SILS in children for appendectomy, cholecystectomy, pyloromyotomy, splenectomy and nephrectomy. In this special edition, we present the evolution of SPLS since the original development until the application into the pediatric field and the benefits of these techniques. Even with the success that exists in pediatrics with the use of these minimally invasive techniques, great obstacles will need to be overcome in order to optimize the approach in children.

Herein, we tried to show controversies in various aspects of single incision surgery. Patients and surgeons enthusiasm, technical progress, and prospective randomized control trials will show the future way and availability of this technique. We hope that you enjoy this special edition as much as we enjoyed working on it.

Boris Kirshtein
Eric M. Haas

Hindawi Publishing Corporation
Minimally Invasive Surgery
Volume 2012, Article ID 783074, 16 pages
doi:10.1155/2012/783074

Review Article

Single-Incision Laparoscopic Surgeries for Colorectal Diseases: Early Experiences of a Novel Surgical Method

Tomoki Makino, Jeffrey W. Milsom, and Sang W. Lee

Division of Colon and Rectal Surgery, New York Presbyterian Hospital, Weill Cornell Medical College, 525 East 68th Street, Box 172, New York, NY 10021, USA

Correspondence should be addressed to Sang W. Lee, sal2013@med.cornell.edu

Received 3 November 2011; Revised 29 February 2012; Accepted 5 March 2012

Academic Editor: Boris Kirshtein

Objectives. This paper aims to analyze the feasibility and safety of single-incision laparoscopic colectomy (SILC) and its potential benefits. *Methods*. Systematic review was performed for the years 1983–August 2011 to retrieve all relevant literature. A total of 21 studies with 477 patients undergoing SILC were selected. *Results*. Range of operative times and estimated blood losses were 75–229 min and 0–100 mL, respectively. Overall conversion rate was 5.9% (28/477) and an additional laparoscopic port was used in 4.9% (16/329) cases. Range of lymph node number for malignant cases was 12–24.6 and surgical margins were all negative. Overall mortality and morbidity rate was 0.4% (2/477) and 11.7% (43/368), respectively. The length of hospital stay (LOS) varied across reports (2.7–9.2 days). Among 6 case-matched studies, one showed less blood loss in SILC as compared to LAC and 2 showed shorter LOS after SILC versus HALC or LAC/HALC groups. In addition, one study reported maximum pain score on postoperative days 1 and 2 was lower in SILS compared to LAC and HALC. *Conclusions*. SILC procedure is feasible and safe when performed by surgeons highly skilled in laparoscopy. In spite of technical difficulties, there may be potential benefits associated with SILC over LAC/HALC.

1. Introduction

Recently, laparoscopic surgeries have been widely accepted as a treatment of colon diseases including colon cancer [1–3]. Most surgeons are convinced by the short time benefit of the laparoscopic approach in colorectal surgery, that is, early postoperative recovery, decreased postoperative pain, reduced pulmonary dysfunction, and shorter hospitalization [4–6]. Moreover, in oncological terms, it has also been shown to be safe in the treatment of colon cancer [1, 2]. In order to further improve upon the results of multiport laparoscopic colectomies (LACs), efforts have been made to further reduce the trauma caused by incisions. The rationale for further "scar-less" surgery is that decreasing the number and size of port accesses to the abdominal cavity might be an advantage not only from the cosmetic aspect but also in minimizing the risk of complications such as wound pain and infections as well as incision hernia and internal adhesion formation [7].

The excitement to develop new techniques has given rise to natural orifice transluminal endoscopic surgery (NOTES) [8–10]. This procedure in both animal [11] and human [12] models has shown some success but certainly has technical challenges: using transgastric, transvaginal, and transrectal access to the abdominal viscera and the need for expensive specialized equipment has hindered the widespread acceptance of this approach. Therefore use of the NOTES approach in performing routine colon resection is far from being practical at this time. Single-incision laparoscopic surgery (SILS) has advantages over NOTES in that existing laparoscopic instruments can be used and relatively minor adjustments from the current multiport laparoscopic technique are needed. The initial applications of SILS in gastrointestinal surgery were cholecystectomy [13], appendectomy [14] and recently, this technique has also been applied to colorectal surgery [15–18].

In comparison to multiport laparoscopic colectomy, the potential advantages of SILS are thought to be improved

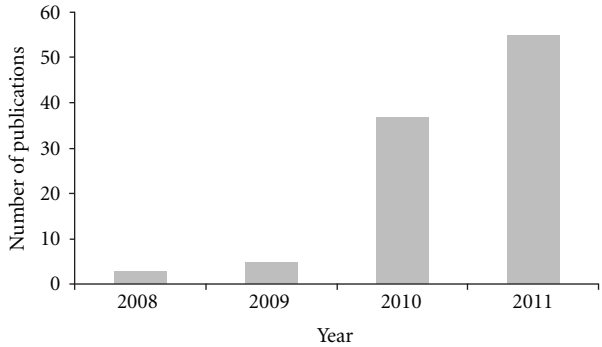

Figure 1: The number of publications regarding single-incision laparoscopic colectomy.

cosmesis as well as incisional and/or parietal pain and avoidance of port site-related complications [40]. Since 2008 when single-incision laparoscopic colectomy (SILC) was first introduced, the number of relevant publications has been increasing year by year as shown in Figure 1. However, because of still limited number of studies reporting SILC [41], its clinical significance remains to be elucidated. The aim of this study is to analyze current literature on SILC and access its potential benefits or efficacy as well as its feasibility and safety.

2. Materials and Methods

2.1. Literature Search Strategies. A systematic search of the scientific literature was carried out using the MEDLINE, EMBASE, the Cochrane Central Register of Controlled Trials ClinicalTrials.gov (Available at: http://clinicaltrials.gov/), National Research Register, The York (UK) Centre for Reviews, American College of Physicians (ACP) Journal Club, Australian Clinical Trials Registry, relevant online journals, and the Internet for the years 1983–August 2011 to obtain access to all relevant publications, especially randomized controlled trials, systematic reviews, and meta-analyses involving SILC. The search terms were "single-incision," "single port," "single access," "single site," "laparoscopic colectomy," "colectomy," and "laparoscopic colorectal surgery."

2.2. Inclusion and Exclusion Criteria. Articles were selected if the abstract contained data on patients who underwent SILC for colorectal diseases in the form of RCTs and other controlled or comparative studies. Conference abstracts were included if they contained relevant data. The reference lists of these articles were also reviewed to find additional candidate studies. Searches were conducted without language restriction. To avoid duplication of data, articles from the same unit or hospital were included only once if data was updated in a later publication. However, if surgical cases did not overlap among reports by even the same institute, these reports were all included. Reports with fewer than 10 cases of SILC and review articles were excluded from this study. Data extracted for this study were taken from the published reports; authors were not contacted to obtain additional information. All articles selected for full text review were distributed to 2 reviewers (T.M and S.L.), who independently decided on inclusion/exclusion and independently abstracted the study data. Any discrepancies in agreement were resolved by consensus. The flow chart of this selection process is summarized in Figure 2.

2.3. Result of the Literature Research. By using the above search strategy, a total of 249 potentially relevant citations were found. After the exception of 98 duplicated citations, we excluded 86 articles irrelevant of surgical specialty and 37 relevant articles with fewer than 10 cases by reviewing titles and abstracts. 28 publications were selected for review of full text, and 4 studies with no relevant data and 3 review articles were excluded from our paper. Twenty-one studies [19–39] with a total of 477 patients undergoing SILC met the criteria for analysis providing level 2–4 evidence (Table 1). There were one multi-institutional study and a total of 9 comparative studies including 6 case-matched ones between SILC and other minimally invasive procedures. There were no randomized controlled trials and meta-analyses in the selected literature.

3. Results

3.1. Indications and SILC Procedures. Demographic information and preoperative parameters are shown in Table 1. All studies except 4 performed SILC for colon cancer cases [21, 26, 29, 38]. Among them, 18 studies also included benign colon disease (diverticulitis, Crohn's disease, ulcerative colitis, polyps, etc.) [21, 22, 24–39]. The most common surgical procedures performed in these series were right hemicolectomy ($n = 277$), followed by sigmoidectomy ($n = 81$). Anterior resections were performed in 5 of 22 studies ($n = 37$). Range of body mass index (BMI) was 21.9–30.0 kg/m^2 in each study.

3.2. Surgical Instruments and Skin Incision Length. All studies except one [30] used commercially available single port devices as summarized in Table 3. Chen et al. used a surgical glove attached with three trocars for the purpose of reestablishing the pneumoperitoneum after extraction of the specimen and anastomosis [30]. Ross et al., instead of a single access device, used multiple trocars placed through a single skin incision for some patients [32]. All studies, with exception of two [29, 34], utilized three ports/trocars (5, 5, 5, or 12 mm) placed through the single access device. Sixteen studies reported on type of laparoscope used [20–26, 29, 30, 32–38]. Most of investigators from the studies reported using 30°-angled scopes while two studies used 0° laparoscopes [20, 21]. Types of instruments used are detailed in Table 3. The skin incision for the insertion of port systems initially measured 2 to 4 cm, and average length of final scar was 2.7–4.5 cm in 7 studies [22, 23, 27, 31–33, 36] with relevant data. The final (at the end of operation) length of incision scar was longer than the initial one in all 11 studies with available data [21–24, 27, 28, 30, 33–36].

Table 1: Characteristics of patients undergoing single-incision laparoscopic colorectal surgery.

Author/year	No. of patients	Evidence level	Age	Gender (M/F)	ASA (I/II/III/IV)	Past surgical history (%)	BMI (kg/m^2)	Indication
McNally et al. 2011 [19]	27	3	67[#] (26–86)	13/14	0/16/9/0	44.4	27[#]	Malignant
Bulut et al. 2011 [20]	10	4	67[#] (49–83)	2/8	3/6/1/0	60.0	23.5[#] (20–25)	Cancer
Gaujoux et al. 2011 [21]	13	4	53[#] (23–82)	5/8	I/II: 13 III/IV: 0	38.5	23.5[#] (18–30)	Polyp: 5 Crohn: 3 Diverticulitis: 3 Benign: 2
Ramos-Valadez et al. 2011 [22]	20	3	59 (37–76)	11/9	2[#]	50.0	25.9 (20–33)	Benign: 17 Malignant: 3
Katsuno et al. 2011 [23]	31	4	67 (58–79)	14/17	NA	NA	22.5	cancer
Wolthuis et al. 2011 [24]	14	3	56[#] (30–73)	5/9	0/12/2/0	NA	22 (20–24)	Crohn: 6 Cancer: 3 Adenoma: 3 Diverticulitis: 2
van den Boezem and Sietses 2011 [25]	50	4	65 (21–89)	18/32	NA	22.0	27 (17–35)	Malignant: 31 Diverticulitis: 8 Polyp: 7 Colitis ulcerosa: 4
Gash et al. 2011 [26]	10	4	31[#] (21–56)	4/6	NA	30.0	22[#] (20–28)	UC
Champagne et al. 2011 [27]	29	2	61 (25–93)	10/19	NA	27.6	27.4	Cancer: 12 Polyp: 4 Benign: 13
Chew et al. 2011 [28][#]	21	4	63[#] (48–63)	13/8	2[#]	NA	NA	Cancer: 14 Polyp: 4 Other: 3
Chew et al. 2011 [28][##]	11	4	66[#] (49–80)	5/6	2[#]	NA	NA	Cancer: 10 Polyp: 1
Fichera et al. 2011 [29]	10	4	28 (19–38)	8/2	NA	NA	21.9	UC: 10
Chen et al. 2011 [30]	18	3	69	10/8	I/II: 8 III/IV: 10	NA	23.3[#] (18–29)	Cancer: 16 Diverticulosis: 2
Papaconstantinou et al. 2011 [31]	29	3	60 (33–87)	13/16	0/16/12/1	34.5	30.0 (23–42)	Cancer: 15 Polyps: 12 Crohn: 2
Ross et al. 2011 [32]	39	4	58 (18–86)	16/23	NA	43.6	25.6 (16–40)	Cancer: 15 Polyps: 12 Diverticulitis: 7 Crohn: 5

Table 1: Continued.

Author/year	No. of patients	Evidence level	Age	Gender (M/F)	ASA (I/II/III/IV)	Past surgical history (%)	BMI (kg/m^2)	Indication
Gandhi et al. 2010 [33]	24	3	54	12/12	2.3	41.7	28.5	Benign: 15 Malignant: 9
Keshava et al. 2010 [34]	22	4	67[#] (18–90)	11/11	NA	NA	27[#] (19–30)	Cancer: 13 Adenoma: 5 Other: 4
Waters et al. 2010 [35]	16	3	65 (39–82)	8/8	2.5	43.8	29 (20–41)	Cancer: 10 Other: 6
Adair et al. 2010 [36]	17	3	67	5/12	NA	0[#]	26.2	Malignantcy: 11 Polyp: 4 Other: 2
Gash et al. 2010 [37]	20	4	46 (24–81)	7/13	9/5/6/0	40.0	25[#] (21–37)	Cancer: 8 Crohn: 4 UC: 3 Other: 5
Vestweber et al. 2010 [38]	10	4	64[#]	1/9	2[#]	50.0	26.7[#]	Diverticulitis
Boni et al. 2010 [39]	36	4	69	NA	NA	36.1	NA	Malignant: 32 Polyp: 4

[#]data of right colectomies, [##]data of anterior resections, ASA: American Society of Anesthesiologist, BMI: body mass index, NA: data not available, UC: ulcerative colitis, SSI: surgical site infection, TME: total mesorectal excision, LAC: multiport laparoscopic colectomy, HALS: hand assisted laparoscopic surgery, UTI: urinary tract infection, [#]median value.

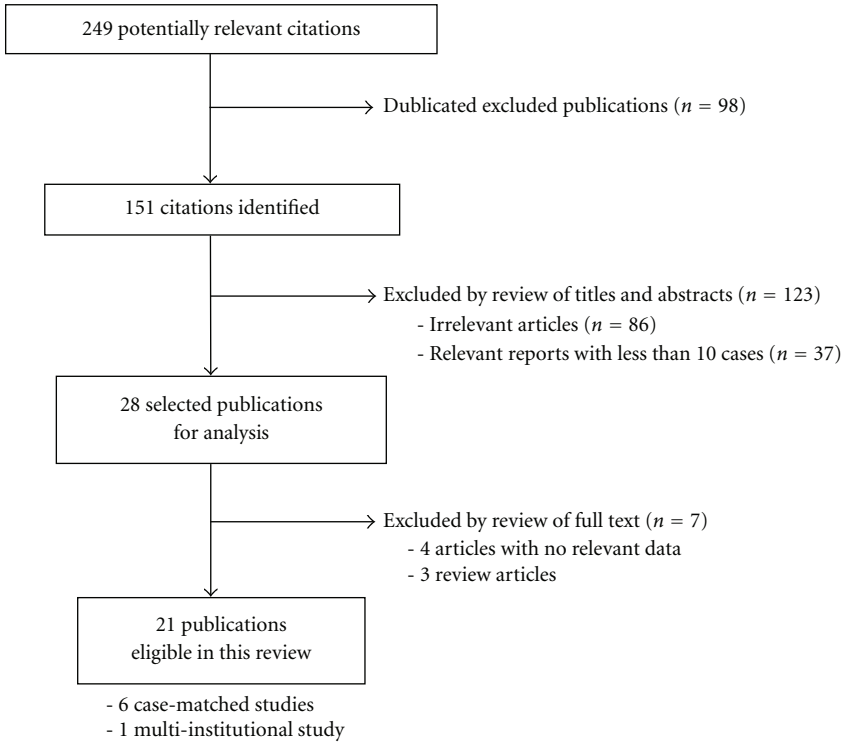

Figure 2: Flow chart of the selection process for studies included in the systematic review.

3.3. Intraoperative Parameters. The summary of various operative parameters is shown in Table 2. The range of operative times for SILC procedure was 75–229 minutes ($n = 21$ studies). The range of estimated blood loss was 0–100 mL ($n = 14$ studies). Among all 477 cases eligible in the current paper, a total of 5 cases (1.0%) were converted to open procedures, 3 cases (0.6%) to hand-assisted laparoscopic surgeries (HALS), and 20 cases (4.2%) to conventional (multiport) laparoscopic colectomies (LAC). Overall conversion rate was 5.9% (28/477). Reasons of conversion in these cases were the following: purpose for retraction or aid in colonic mobilization ($n = 9$), severe adhesion ($n = 4$), port trouble ($n = 3$), low-rectal lesions ($n = 3$), obesity ($n = 3$), bleeding ($n = 1$), fistula ($n = 1$), time constrains ($n = 1$), facilitating primary suture closure of colorectal anastomosis following a positive air insufflation test ($n = 1$), T4 tumor ($n = 1$), and unknown reason ($n = 1$). On the other hand, among 15 studies ($n = 329$) with available data, an additional port (adding only one port) was needed during the operation in a total of 16 cases (4.9%; 16/329). No major intraoperative complications were observed in these series.

3.4. Surgical Specimen. Five studies including right hemicolectomy, sigmoidectomy, and anterior resection showed that the range of specimen lengths was 15–43.5 cm (Table 4) [20, 24, 27, 28, 35]. All margins were free of cancer in these series. In 18 studies with available data, the range of number of removed lymph nodes for malignant cases and potential malignant diseases was 12–24.6 (Table 4) [19, 20, 22–25, 27, 28, 30–39].

3.5. Postoperative Parameters

3.5.1. Perioperative Mortality. Overall, 2 perioperative deaths (0.4%; 2/477) were observed. One death, reported by Adair et al., occurred on postoperative day 10, 8 days after discharge from the hospital, due to a pulmonary embolus [36]. Gandhi et al. reported another death, which was encountered in a patient following palliative SILC right hemicolectomy as a result of complications from metastatic disease [33].

3.5.2. Morbidity, Reoperation, and Length of Hospital Stay (LOS). Postoperative morbidities varied across studies (0–29.4%). Overall 43 patients (11.7%; 43/368) developed complications related to surgery. The most frequent complication was ileus ($n = 10$) and wound infection/hematoma/seroma ($n = 10$) followed by and anastomotic bleeding ($n = 4$) and arrhythmia ($n = 3$). Overall 6 out of 419 patients (1.4%) required reoperation and the reasons in these cases were as follows: anastomotic leakage ($n = 2$), anastomotic bleeding ($n = 1$), wound hematoma ($n = 1$), cecal ischemia with perforation ($n = 1$), and a negative relaparotomy to rule out anastomotic leakage ($n = 1$). In all 21 studies, the range of length of hospital stay (LOS) also varied across reports: 2.7–9.2 days. Notably, 2 studies reported fewer than 3 days of LOS in their series [33, 37].

3.5.3. Postoperative Anesthesia. Katsuno et al. reported that analgesics were used 1.4 ± 1.2 times in addition to routinely using the epidural catheter (0.2% ropivacaine hydrochloride hydrate 600 mg plus morphine hydrochloride hydrate 8 mg)

Table 2: Perioperative parameters of single-incision laparoscopic colorectal surgery.

Author/year	Colectomy	Skin incision length (cm)		Operative time (min)	Blood loss (mL)	Conversion (%)	Additional port (%)	Mortality (%)	Morbidity (%)	Reoperation (%)
		Initial	Final							
McNally et al. 2011 [19]	Right sigmoid transverse, and so on.	NA	NA (4–8)	114#	50#	18.5 (to LAC)	0	0	18.5 (ileus, arrhythmia, etc.)	3.7 (cecal ischemia)
Bulut et al. 2011 [20]	Low anterior resection, and so on.	2.5	NA	229# (185–318)	0# (0–100)	0	20.0	0	20.0 (fluid collection, etc.)	0 (two readmissions)
Gaujoux et al. 2011 [21]	Sigmoid right ileocolonic, and so on.	2.5	3.2# (2.5–5)	150# (100–240)	0# (0–350)	0	0	0	0	0
Ramos-Valadez et al. 2011 [22]	Sigmoid	2.5 or 4	3.3	159	58	5.0 (to LAC)	0	0	10.0 (wound complication)	0
Katsuno et al. 2011 [23]	Sigmoid right	2.5–3	2.7	156 (101–263)	27 (5–60)	0	NA	0	3.2 (wound infection)	NA
Wolthuis et al. 2011 [24]	Right sigmoid	3.5#	5# (4–6)	75# (70–105)	0# (0–20)	0	0	0	0	7.1 (negative relaparo-scopy)
van den Boezem and Sietses 2011 [25]	Right sigmoid low anterior resection, and so on.	3	NA (−4.5)	130	NA	4.0 (to LAC)	4.0	0	8.0 (wound infection) 4.0 (hernia) 4.0 (ileus) 2.0 (leakage)	2.0 (anastomotic leakage)
Gash et al. 2011 [26]	Restorative proctocolectomy	2.5	NA	185# (100–381)	NA	0	0	0	10.0 (surgical emphysema) 10.0 (panic attack)	NA
Champagne et al. 2011 [27]	Right left	2.5	3.8	134	NA	10.3 (to open/LAC)	6.9	0	17.2 (ileus, etc.)	0
Chew et al. 2011 [28]#	Right	2.5	5# (3–10)	85# (45–150)	NA	4.8 (to LAC)	0	0	4.8 (arrhythmia)	0
Chew et al. 2011 [28]##	Anterior resection	2.5	5# (3–7)	120# (65–235)	NA	36.4 (to LAC)	36.4	0	18.2 (leakage, bleed)	0
Fichera et al. 2011 [29]	Total	NA	NA	139 (110–180)	100 (20–400)	0	NA	0	0	0

Table 2: Continued.

Author/year	Colectomy	Skin incision length (cm)		Operative time (min)	Blood loss (mL)	Conversion (%)	Additional port (%)	Mortality (%)	Morbidity (%)	Reoperation (%)
		Initial	Final							
Chen et al. 2011 [30]	Right	3	4# (3–6)	175# (145–280)	75# (20–700)	16.7 (to open/LAC)	NA	0	16.6 (ileus, wound infection, arrhythmia)	0
Papaconstantinou et al. 2011 [31]	Right	NA	4.5 (2.5–7)	129 (53–187)	60 (20–150)	3.4 (to HALS)	NA	0	3.4 (leakage) 6.9 (SSI) 10.3 (minor wound complication)	3.4 (anastomotic leakage)
Ross et al. 2011 [32]	Right sigmoid ileocolic	NA	4.2 (2.5–8)	120 (68–210)	67 (0–250)	5.1 (to open)	7.7	0	7.7 (wound infection, anastomotic bleeding)	0
Gandhi et al. 2010 [33]	Right rectosigmoid	2.5	3.3 (2–6)	143	63	12.5 (to HALS/LAC)	NA	4.2 (metastatic disease)	8.3 (bleed, wound infection)	0
Keshava et al. 2010 [34]	Right	3	4# (3–6)	105# (85–140)	<100 except two	0	0	0	27.3 (ileus, bleed, wound hematoma)	9.1 (bleed, wound hematoma)
Waters et al. 2010 [35]	Right	2	(2.5–4.5)	106 (71–223)	54 (25–120)	0	0	0	18.8 (wound infection, etc.)	0
Adair et al. 2010 [36]	Right	3	3.8	139 (96–215)	NA	0	11.8	5.9 (pulmonary embolus)	29.4 (ileus, etc.)	NA
Gash et al. 2010 [37]	Right extended right anterior resection (TME), and so on.	2	NA	110# (45–240)	NA	10.0 (to LAC)	0	0	10.0 (ileus) 5.0 (wound infection) 5.0 (bleed) 5.0 (hypertension)	0 (one re-admission)
Vestweber et al. 2010 [38]	Sigmoid	2.5	NA	120# (79–156)	Minimal	10.0 (to open)	10.0	0	10.0 (subcutaneous hematoma)	0
Boni et al. 2010 [39]	Right	3–3.5	2.6[a] (2.1–3.1)	145 (110–172)	NA	0	NA	0	5.6 (UTI, ileus)	0

data of right colectomies, ## data of anterior resections, BMI: body mass index, NA: data not available, UC: ulcerative colitis, SSI: surgical site infection, TME: total mesorectal excision, LAC: multiport laparoscopic colectomy, HALS: hand assisted laparoscopic surgery, UTI: urinary tact infection, # median value, [a] measured on postoperative day 10.

Table 3: Required materials of single-incision laparoscopic colorectal surgery.

Author	Patient's position	Port system		Tip	Laparoscope diameter (mm)	Degree	Graspers/scissors
		Single port (diameter, mm)	Trocars (diameter, mm)				
McNally et al. 2011 [19]	NA	SILS port, Gelport, SSL port	NA	NA	NA	NA	NA
Bulut et al. 2011 [20]	Lloyd-Davis	SILS port	3 trocars (5, 5, 5)	Straight	5	0°	5 mm curved endoscopic grasper
Gaujoux et al. 2011 [21]	Modified lithotomy	SILS port	3 trocars (5, 5, 5)	NA	5	0°	Standard grasper
Ramos-Valadez et al. 2011 [22]	Modified lithotomy	SILS port, GelPOINT Gelport	3 trocars (5, 5, 5)	NA	5	30°	Standard nonarticulated laparoscopic instrumentation
Katsuno et al. 2011 [23]	Lithotomy	Trocar insertion method, SILS port	3 trocars (5, 5, 5 or 12)	Rigid	5	30°	NA
Wolthuis et al. 2011 [24]	Supine (right hemicolectomy) Modified Lloyd-Davies (sigmoid resection)	SILS port, Quard Port GelPOINT, SSL access system	3 trocars (5, 5, 5)	NA	5	30°	Endo grasp
van den Boezem and Sietses 2011 [25]	Supine (right hemicolectomy) Lithotomy (sigmoid resection)	SILS port	3 trocars (5, 5, 12)	Standard	10	30°	Straight atraumatic grasper
Gash et al. 2011 [26]	Dorsolithotomy	SILS port, TriPort	3 trocars (5, 5, 12)	NA	5 or 10	30°	NA
Champagne et al. 2011 [27]	NA	SILS port	3 trocars (NA)	NA	NA	NA	NA
Chew et al. 2011 [28]	Supine (rectum: lithotomy)	SILS port, SSL access system, TriPort	3 trocars (5, 5, 12)	NA	NA	NA	NA
Fichera et al. 2011 [29]	Lithotomy	Gelport	4 trocars (5, 5, 5, 12)	Rigid	5	30°	NA
Chen et al. 2011 [30]	NA	None#	3 trocars (5, 5, 5)	Rigid	5	30°	NA

Table 3: Continued.

Author	Patient's position	Port system		Tip	Laparoscope diameter (mm)	Degree	Graspers/scissors
		Single port (diameter, mm)	Trocars (diameter, mm)				
Papaconstantinou et al. 2011 [31]	NA	SILS port	NA	NA	NA	NA	NA
Ross et al. 2011 [32]	Supine	GelPOINT	3 trocars (5, 5, 12)	NA	NA	30°	NA
Gandhi et al. 2010 [33]	Supine (rectum: lithotomy)	SILS port, GelPOINT Gelport	3 trocars (5, 5, 5)	NA	5	30°	NA
Keshava et al. 2010 [34]	Modified Lloyd Davies	Gelport	4 trocars (5, 5, 12, 12)	NA	10	30°	NA
Waters et al. 2010 [35]	NA	SILS port	3 trocars (5, 5, 5)	Rigid	5	30°	NA
Adair et al. 2010 [36]	Low lithotomy	SILS port, GelPOINT Gelport, TriPort	3 trocars (NA)	Flexible	5	NA	NA
Gash et al. 2010 [37]	NA	TriPort	3 trocars (5, 5, 12)	NA	5 or 10	30°	Johan bowel grasper
Vestweber et al. 2010 [38]	Supine, steep Trendelenburg	SILS port	3 trocars (NA)	NA	5	30°	NA
Boni et al. [38]	Supine, left side down, and mild Trendelenberg	SILS port Endocone	3 trocars (NA)	NA	NA	NA	Articulating endograsper

NA: data not available, #surgical glove.

Table 4: Postoperative recovery of single-incision laparoscopic colectomy.

Author	Length of specimen (cm)	Margins (% of positive)	Dissected lymph nodes (n)	Postoperative analgesia (days)	Time to flatus/bowel movement (days)	Start regular diet (days)	Hospital stay (days)
McNally et al. [19]	NA	0	15# (3–32)	NA	NA	NA	3# (2–17)
Bulut et al. [20]	15.3 (10–32)	0	14# (3–20)	NA	NA	NA	7# (4–14)
Gaujoux et al. [21]	NA	NA	NA	NA	(2-3)	1	6# (4–10)
Ramos-Valadez et al. [22]	NA	0	20 in malignant cases	NA	NA	NA	3.2
Katsuno et al. [23]	NA	0	18	1.4 ± 1.2 analgesics times	NA	1.5 + 0.8	9.2
Wolthuis et al. [24]	17# (16–23)	0	12# (8–17)	Total 313 mg (198–650 mg) (levobupivacaine) total 250 μg (158–520 μg) (sufentanyl)	NA	NA	7# (5–9)
van den Boezem and Sietses [25]	NA	0	14 (10-)	NA	NA	NA	6# (3–30)
Gash et al. [26]	NA	NA	NA	NA	NA	36 h# (4–48 h)	3# (2–8)
Champagne et al. [27]	43.5	0	19.4 in malignant cases	NA	NA	NA	3.7
Chew et al. [28] (right hemicolectomy)	18.5# (10.5–34.0)	0	17# (10–30) in malignant cases	NA	NA	NA	6# (5–11)
Chew et al. 2011 [28] (anterior resection)	15.0# (11.0–38.0)	0	14# (6–16) in malignant cases	NA	NA	NA	6# (5–21)
Fichera et al. [29]	NA	NA	NA	NA	1.6 (1–3) ostomy output	3 (2–4)	5.1 (4–7)
Chen et al. [30]	NA	0	19.5# (3–42) in malignant cases	NA 10# (0–60) (Demerol equivalents (mg))	2# (1–7)	NA	5# (3–15)
Papaconstantinou et al. [31]	NA	NA	16.4 (4–38)	NA	NA	NA	3.4 (1–8)
Ross et al. [32]	NA	0	19 (12–39) in malignant cases	NA	2.2 (1–4) 2.9 (1–6)	NA	4.4 (2–8)

Table 4: Continued.

Author	Length of specimen (cm)	Margins (% of positive)	Dissected lymph nodes (*n*)	Postoperative analgesia (days)	Time to flatus/bowel movement (days)	Start regular diet (days)	Hospital stay (days)
Gandhi et al. [33]	NA	NA	24.6 in malignant cases	NA	NA	NA	2.7
Keshava et al. [34]	NA	0	17# (10–23)	NA	NA	NA	5# (3–35)
Waters et al. [35]	18 (14–35)	0	18 (13–22)	NA	NA	NA	5 (2–24)
Adair et al. [36]	NA	NA	20 (12–39)	NA	NA	NA	3.9 + 3.7 (1–18)
Gash et al. [37]	NA	NA	NA	NA (TAP blocks)	NA	4–6 h [7cases] 12–16 h [11cases]	46 h# (8–384 h)
Vestweber et al. [38]	18.5 (15–22)	NA	NA	NA	NA	NA	7# (6–15)
Boni et al. [39]	NA	0	24 (15–29)	NA (regular IV paracetamol infusion)	NA	2	5 (4–14)

NA: data not available, TAP: transvers abdominis plane, #median value.

Table 5: Comparison of intraoperative parameters between single-incision laparoscopic colectomy and other minimally invasive surgeries.

Author	Study type	No. of patients (groups)	Incision length (cm)	Operative time (min)	Blood loss (mL)	Conversion (%)
McNally et al. [19]	No case matched	27 versus 46 (SILC versus LAC)	NA	114# versus 135# ($P = 0.08$)	50# versus 50# ($P = 0.21$)	0 versus 13.0 (P = NA)
Ramos-Valadez et al. [22]	Case matched	20 versus 20 (SILC versus LAC)	3.3 versus 3.2 ($P < 0.70$)	159 versus 162 ($P < 0.80$)	58 versus 99 (**$P < 0.007$**)	0 versus 0
Wolthuis et al. [24]	Case matched	14 versus 14 (SILC versus LAC)	5# versus 5# ($P = 0.81$)	75# versus 83# ($P = 0.31$)	0# versus 10# ($P = 0.99$)	0 versus 0
Champagne et al. [27]	Case matched	29 versus 29 (SILC versus LAC)	3.8 versus 4.5 ($P = 0.098$)	134 versus 104 (**$P = 0.0002$**)	NA	17.2 versus 6.9 ($P = 0.11$)
Chen et al. [30]	Case matched	18 versus 21 (SILC versus LAC)	4# versus 4# ($P = 0.52$)	175# versus 165# ($P = 0.16$)	75# versus 50# ($P = 0.67$)	16.7 versus 0 ($P = 0.052$)
Papaconstantinou et al. [31]	Case matched	29 versus 29 versus 29 (SILC versus LAC versus HALS)	4.5 versus 5.1 versus 7.1 (**$P < 0.05$**)	129 versus 128 versus 116 ($P = 0.27$)	60 versus 90 versus 71 ($P = 0.19$)	3.4 versus 13.8 versus 13.8 ($P = 0.20$)
Gandhi et al. [33]	Case matched	24 versus 24 (SILC versus HALS)	3.3 versus 6.6 (**$P < 0.00001$**)	143 versus 113 (**$P = 0.0004$**)	63 versus 91 ($P = 0.06$)	12.5 versus 0 ($P = 0.083$)
Waters et al. [35]	No case matched	16 versus 27 (SILC versus LAC)	NA	106 versus 100 ($P = 0.64$)	54 versus 90 ($P = 0.07$)	0 versus 0
Adair et al. [36]	Case matched	17 versus 17 (SILC versus LAC)	3.8 versus 5.1 (extraction port size)	139 versus 134 ($P = 0.61$)	NA	NA

NA: data not available, SILC: single-incision laparoscopic colectomy, LAC: multiport laparoscopic colectomy, HALS: hand-assisted laparoscopic surgery (colectomy), #median value.

for the first 2 to 3 days as postoperative anesthesia and no patients required analgesics after the fourth postoperative day [23]. Wolthuis et al. reported that total consumption of levobupivacaine (313 versus 355 mg) and sufentanyl (250 versus 284 μg) provided by epidural infusion with a patients-controlled bolus capability was similar between SILC and LAC groups ($P = 0.94$) [24]. Chen et al. also found no difference in the postoperative usage of intravenous narcotics (Demerol) between SILC and LAC groups (10 versus 10 mg, $P = 0.82$) [30].

3.5.4. Postoperative Recovery of Gastrointestinal Function. Several reports [21, 23, 26, 29, 30, 37, 39] provided data regarding postoperative recovery of gastrointestinal function; Gash et al. [37], in their analysis of 20 SILC procedures, reported that a normal diet was tolerated in 4–6 hours by 7 patients and in 12–16 hours (overnight) by 11 patients. In 39 SILC cases [32] from multi-institutional studies reviewed, average time to flatus and bowel movement were Days 2.2 and 2.9, respectively, which is supported by 2 other reports (p.o. Day 2-3 of first flatus) [21, 30, 42, 43]. Chen et al., in their case-control study comparing SILS right hemicolectomy to traditional laparoscopic right hemicolectomy, also reported that there was no difference in time until flatus passage (median 2 versus 2 days) [30]. Concerning oral intake after surgeries, Boni et al. [39] reported p.o. Day 2 for first oral fluid intake. In early experience with 31 SILC cases for colon cancer, Katsuno et al. reported that the time to adequate oral intake was 1.5 ± 0.8 days [23].

3.6. Comparative Studies: SILC versus Other Minimally Invasive Surgeries. A total of 9 comparative studies [19, 22, 24, 27, 30, 31, 33, 35, 36] including 6 case-matched studies [22, 24, 27, 31, 33, 36] between SILC and other minimally invasive procedures are summarized in Tables 5 and 6. Ramos-Valadez et al., in their case-matched series (SILC versus LAC group), reported that mean estimated blood loss was significantly lower for the SILC group ($n = 20$) compared to the LAC group ($n = 20$) (58 versus 99 mL, $P < 0.007$) [22]. Champagne et al., in their case-controlled study comparing SILC ($n = 29$) versus laparoscopic-assisted ($n = 29$) segmental colectomy, reported that SILC is feasible and safe but takes longer time in surgery (134 versus 104 min $P = 0.0002$) [27]. There were no short-term outcome benefits associated with SILC. Chen et al. also did not find any significant benefits associated with right hemicolectomy by SILS approach compared to the same procedure by the multiport laparoscopic approach [30]. McNally et al., comparing 27 SILC cases with 46 LAC cases, reported relatively shorter LOS in SILC versus LAC cases (3 versus 5 days) but with no statistical significance ($P = 0.07$). Gandhi et al., comparing 24 case-matched patients undergoing right hemicolectomy or anterior rectosigmoidectomy between SILC and hand-assisted laparoscopic colectomy (HALC), reported that the average operative time was longer in SILC as compared to HALC (143 versus 113 min $P = 0.0004$) while there was no difference in conversion rate or perioperative complications [33]. Importantly, average LOS was significantly shorter in the SILC group compared with the HALC group (2.7 versus 3.3 days $P < 0.02$), which was also supported by another

Table 6: Comparison of pathological and surgical outcomes between single-incision laparoscopic colectomy and other minimally invasive surgeries.

Author	No. of patients (groups)	Margin (% positive)	Dissected lymph nodes (n)	Length of specimen (cm)	Mortality (%)	Morbidity (%)	Readmission (%)	Hospital stay (days)	Postoperative pain score
McNally et al. [19]	27 versus 46 (SILC versus LAC)	0 versus 0	15# versus 17# ($P = 0.33$)	NA	0 versus 4.3 (P = NA)	18.5 versus 34.8 (P= NA)	NA	3# versus 5# ($P = 0.07$)	NA
Ramos-Valadez et al. [22]	20 versus 20 (SILC versus LAC)	0 versus 0	20.3 versus 18.3 ($P < 0.68$)	NA	0 versus 0	10.0 versus 10.0 ($P < 1.0$)	0 versus 0	3.2 versus 3.8 ($P < 0.25$)	NA
Wolthuis et al. [24]	14 versus 14 (SILC versus LAC)	0 versus 0	12# versus 14# (P = NA)	17# versus 18# ($P = 0.47$)	0 versus 0	0 versus 0	0 versus 0	7# versus 6# ($P = 0.13$)	Overall mean1.00 versus 1.39 ($P = 0.25$)
Champagne et al. [27]	29 versus 29 (SILC versus LAC)	0 versus 0	19.4 versus 21.6 ($P = 0.81$)	44 versus 44 ($P = 0.54$)	NA	17.2 versus 24.1 ($P = 0.28$)	NA	3.7 versus 3.9 ($P = 0.44$)	NA
Chen et al. [30]	18 versus 21 (SILC versus LAC)	Distal free margin (cm) 16 versus 13.5 ($P = 0.094$)	19.5# versus 19# ($P = 0.98$)	NA	0 versus 0	16.6 versus 9.5 ($P = 0.51$)	0 versus 0	5# versus 5# ($P = 0.90$)	Demerol usage (mg) 10# versus 10# ($P = 0.82$)
Papaconstantinou et al. [31]	29 versus 29 versus 29 (SILC versus LAC versus HALS)	NA	16.4 versus 16.9 versus 18.1 ($P = 0.83$)	NA	0 versus 0 versus 0	(i) Leakage 3.4 versus 0 versus 0 ($P = 0.36$) (ii) SSI 6.9 versus 10.3 versus 6.9 ($P = 0.86$) (iii) Minor wound complication 10.3 versus 13.8 versus 17.2 ($P = 0.75$)	13.8 versus 6.9 versus 10.3 ($P = 0.69$)	3.4 versus 4.6 versus 4.9 (**P<0.05**)	Mean maximum Day 1: 4.7 versus 6.0 versus 6.0 (**P<0.05**) Day 2: 3.8 versus 5.2 versus 5.0 (**P<0.05**)
Gandhi et al. [33]	24 versus 24 (SILC versus HALS)	NA	24.6 versus 18.6 ($P = 0.22$)	NA	NA	8.3 versus 0 ($P = 0.15$)	NA	2.7 versus 3.3 (**P=0.02**)	NA
Waters et al. [35]	16 versus 27 (SILC versus LAC)	0 versus 0	18 versus 16 ($P = 0.10$)	18 versus 18 ($P = 0.92$)	0 versus 3.7 ($P = 0.44$)	18.8 versus 14.8 ($P = 0.99$)	6.3 versus 3.7 ($P = 0.99$)	5 versus 6 ($P = 0.53$)	NA
Adair et al. [36]	17 versus 17 (SILC versus LAC)	NA	20.1 versus 18.6 ($P = 0.70$)	NA	5.9 versus 0 (P = NA)	29.4 versus 23.5 (P = NA)	NA	3.9 versus 4.1 ($P = 0.87$)	NA

NA: data not available, SILC: single-incision laparoscopic colectomy, LAC: multiport laparoscopic colectomy, HALS: hand-assisted laparoscopic surgery (colectomy).
#Median value, SSI: surgical site infection.

case-matched study performing right colectomies where Papaconstantinou et al. [31] reported that LOS was significantly shorter in the SILC group ($n = 29$) compared to LAC ($n = 29$) and HALC ($n = 29$) groups (3.4 versus 4.6 versus 4.9 days, $P < 0.05$). In addition, maximum pain scores on p.o. Days 1 and 2 were significantly lower in the SILC group compared to LAC and HALC groups ($P < 0.05$). On the other hand, in comparison between 16 single-port and 27 conventional laparoscopic right hemicolectomies of similar clinical background, Waters et al. concluded that no significant difference of short-term outcomes was observed between the 2 groups [35]. Adair et al., in their case-matched analysis of 17 single-port and multiport laparoscopic right colectomy cases, also found similar short-term outcomes between the 2 groups [36]. Wolthuis et al., in their case-matched study between SILC ($n = 14$) and LAC ($n = 14$) examining postoperative inflammatory response, reported that C-reactive protein (CRP) levels changed similarly in both groups ($P = 0.34$).

4. Discussion

Potential advantages of SILC over other minimally invasive surgeries include a single small skin incision. The length of the skin incision is partly determined by the size of the resected specimen. Extraction difficulties may be encountered with large colon tumors or with obese patients with thick mesentery, omentum, or deep abdominal wall and colon filled with stool. In fact, our paper revealed that the final (at the end of operation) length of incision scar was longer than the initial one in all relevant reports, suggesting that cosmetic analysis on SILC should be based on final, not initial, scar length and objectively based on cosmesis scale or body image scale which has not yet been examined in any literature. In theory, a single midline fascial incision may minimizes trauma to the abdominal muscles, epigastric articles, and parietal nerves made by multiple trocars in LAC cases. This potentially leads to less postoperative pain and long-term additional port site complications; one out of two case-matched studies demonstrated significantly less postoperative pain score in SILC group as compared to LAC and HALS groups although another study failed to show less postoperative use of anesthesia in SILC group.

When introducing any new technology, one significant limitation is often the cost of the procedure. Generally, the initial increases in operative costs associated with laparoscopic techniques are mitigated by reduction in morbidity and duration of hospital stay as a result of the minimally invasive surgery. In fact, several studies which examined both short-term and long-term costs associated with laparoscopic colectomy showed an initial increase in the cost associated with laparoscopic colectomy but a long-term, overall saving. The potential challenge with SILC is that it will require purchase of proprietary instrumentation and additional equipments in some cases which increase overall operative cost. Although potential benefits including fewer conversions, a shorter postoperative recovery or LOS, and less morbidity would make SILC more cost effective, demonstration of any economic benefit over LAC can be difficult. Waters et al. [35] reported that the port itself was purchased at a cost of 550–650 USD compared with average cost of 80 USD of the ports used in the standard LAC cases. The marginal increase in direct operative cost was 310–410 USD per case. With similar operative time and LOS, it can be inferred that the total increase in cost is only that of the port device itself.

Concerning surgical instruments and techniques, SILS has several disadvantages compared with multiport laparoscopic surgery. Standard laparoscopic surgeries are performed through multiports allowing variation of scope placement and angling when met with obstructions. In SILS, no additional ports exist for placement of the scope and maneuvering is greatly restricted by nearby instruments. Therefore SILS requires an experienced surgeon to overcome the difficulties of triangulation, pneumoperitoneum leaks, and instrument crowding. In fact, according to our paper, as many as 9 cases needed to be converted to either open or multiports laparoscopic procedure to get better retraction or aid in colonic mobilization. Some investigators recommend utilizing articulating instruments or since obesity was found to be a common reason for conversion, variable length tools including a bariatric-length bowel grasper or an extra-long laparoscope to minimize external clashing are also recommended [19, 30]. One of the most challenging factors for SILC in attaining widespread use is the additional learning curve required for this technique. The SILC is essentially a one-operating surgeon technique which has a potentially detrimental impact upon resident education, affecting the training of future surgeons as well. Because most surgeons are still performing open colectomy (the prevalence of even standard LAC procedure is still under 25% in the US [44, 45]) or are on their own learning curve for laparoscopy, it requires further analysis to determine the impact that introducing a more technically demanding procedure has on training these surgeons.

5. Conclusions

SILC is a challenging procedure but seems to be feasible and safe when performed by surgeons highly skilled in laparoscopy. SILC may have potential benefits over other types of minimally invasive surgeries (LAC or HALC), however this has not yet been objectively shown. In the future, randomized controlled trials with a large number of cases are necessary to determine the role of SILC in cost benefit, cosmetic, and oncologic outcomes.

Conflict of Interests

The authors declare that they have no conflict of interests.

References

[1] H. J. Bonjer, W. C. Hop, H. Nelson et al., "Laparoscopically assisted vs open colectomy for colon cancer: a meta-analysis," *Archives of Surgery*, vol. 142, no. 3, pp. 298–303, 2007.

[2] H. Nelson, D. J. Sargent, H. S. Wieand et al., "A comparison of laparoscopically assisted and open colectomy for colon cancer," *The New England Journal of Medicine*, vol. 350, no. 20, pp. 2050–2114, 2004.

[3] C. Laurent, F. Leblanc, F. Bretagnol, M. Capdepont, and E. Rullier, "Long-term wound advantages of the laparoscopic approach in rectal cancer," *British Journal of Surgery*, vol. 95, no. 7, pp. 903–908, 2008.

[4] S. D. Wexner, P. Reissman, J. Pfeifer, M. Bernstein, and N. Geron, "Laparoscopic colorectal surgery: analysis of 140 cases," *Surgical Endoscopy*, vol. 10, no. 2, pp. 133–136, 1996.

[5] K. Okabayashi, H. Hasegawa, M. Watanabe et al., "Indications for laparoscopic surgery for Crohn's disease using the Vienna Classification," *Colorectal Disease*, vol. 9, no. 9, pp. 825–829, 2007.

[6] U. Hildebrandt, K. Kessler, T. Plusczyk, G. Pistorius, B. Vollmar, and M. D. Menger, "Comparison of surgical stress between laparoscopic and open colonic resections," *Surgical Endoscopy and Other Interventional Techniques*, vol. 17, no. 2, pp. 242–246, 2003.

[7] C. G. Schmedt, B. J. Leibl, P. Däubler, and R. Bittner, "Access-related complications—an analysis of 6023 consecutive laparoscopic hernia repairs," *Minimally Invasive Therapy and Allied Technologies*, vol. 10, no. 1, pp. 23–29, 2001.

[8] K. Nakajima, T. Nishida, T. Takahashi et al., "Partial gastrectomy using natural orifice translumenal endoscopic surgery (NOTES) for gastric submucosal tumors: early experience in humans," *Surgical Endoscopy and Other Interventional Techniques*, vol. 23, no. 12, pp. 2650–2655, 2009.

[9] C. Rolanda, E. Lima, J. M. Pêgo et al., "Third-generation cholecystectomy by natural orifices: transgastric and transvesical combined approach," *Gastrointestinal Endoscopy*, vol. 65, no. 1, pp. 111–117, 2007.

[10] A. A. Gumbs, D. Fowler, L. Milone et al., "Transvaginal natural orifice translumenal endoscopic surgery cholecystectomy: early evolution of the technique," *Annals of Surgery*, vol. 249, no. 6, pp. 908–912, 2009.

[11] S. Perretta, B. Dallemagne, D. Coumaros, and J. Marescaux, "Natural orifice transluminal endoscopic surgery: transgastric cholecystectomy in a survival porcine model," *Surgical Endoscopy and Other Interventional Techniques*, vol. 22, no. 4, pp. 1126–1130, 2008.

[12] J. Marescaux, B. Dallemagne, S. Perretta, A. Wattiez, D. Mutter, and D. Coumaros, "Surgery without scars: report of transluminal cholecystectomy in a human being," *Archives of Surgery*, vol. 142, no. 9, pp. 823–826, 2007.

[13] P. P. Rao, S. M. Bhagwat, A. Rane, and P. P. Rao, "The feasibility of single port laparoscopic cholecystectomy: a pilot study of 20 cases," *HPB*, vol. 10, no. 5, pp. 336–340, 2008.

[14] G. Rispoli, M. F. Armellino, and C. Esposito, "One-trocar appendectomy: sense and nonsense," *Surgical Endoscopy and Other Interventional Techniques*, vol. 16, no. 5, pp. 833–835, 2002.

[15] P. Bucher, F. Pugin, and P. Morel, "Single port access laparoscopic right hemicolectomy," *International Journal of Colorectal Disease*, vol. 23, no. 10, pp. 1013–1016, 2008.

[16] F. H. Remzi, H. T. Kirat, and D. P. Geisler, "Laparoscopic single-port colectomy for sigmoid cancer," *Techniques in Coloproctology*, vol. 14, no. 3, pp. 253–255, 2010.

[17] A. M. Merchant and E. Lin, "Single-incision laparoscopic right hemicolectomy for a colon mass," *Diseases of the Colon and Rectum*, vol. 52, no. 5, pp. 1021–1024, 2009.

[18] F. H. Remzi, H. T. Kirat, J. H. Kaouk, and D. P. Geisler, "Single-port laparoscopy in colorectal surgery," *Colorectal Disease*, vol. 10, no. 8, pp. 823–826, 2008.

[19] M. E. McNally, B. Todd Moore, and K. M. Brown, "Single-incision laparoscopic colectomy for malignant disease," *Surgical Endoscopy*, vol. 25, no. 11, pp. 3559–3565, 2011.

[20] O. Bulut, C. B. Nielsen, and N. Jespersen, "Single-port access laparoscopic surgery for rectal cancer: initial experience with 10 cases," *Diseases of the Colon & Rectum*, vol. 54, no. 7, pp. 803–809, 2011.

[21] S. Gaujoux, F. Bretagnol, M. Ferron, and Y. Panis, "Single-incision laparoscopic colonic surgery," *Colorectal Disease*, vol. 13, no. 9, pp. 1066–1071, 2011.

[22] D. I. Ramos-Valadez, M. Ragupathi, J. Nieto et al., "Single-incision versus conventional laparoscopic sigmoid colectomy: a case-matched series," *Surgical Endoscopy*, vol. 26, no. 1, pp. 96–102, 2011.

[23] G. Katsuno, M. Fukunaga, K. Nagakari, S. Yoshikawa, M. Ouchi, and Y. Hirasaki, "Single-incision laparoscopic colectomy for colon cancer: early experience with 31 cases," *Diseases of the colon and rectum*, vol. 54, no. 6, pp. 705–710, 2011.

[24] A. M. Wolthuis, F. Penninckx, S. Fieuws, and A. D'Hoore, "Outcomes for case-matched single port colectomy are comparable with conventional laparoscopic colectomy," *Colorectal Disease*, vol. 14, no. 5, pp. 634–641, 2012.

[25] P. B. van den Boezem and C. Sietses, "Single-incision laparoscopic colorectal surgery, experience with 50 consecutive cases," *Journal of Gastrointestinal Surgery*, pp. 1–6, 2011.

[26] K. J. Gash, A. C. Goede, B. Kaldowski, B. Vestweber, and A. R. Dixon, "Single incision laparoscopic (SILS) restorative proctocolectomy with ileal pouch-anal anastomosis," *Surgical Endoscopy*, vol. 54, no. 2, pp. 183–186, 2011.

[27] B. J. Champagne, E. C. Lee, F. Leblanc, S. L. Stein, and C. P. Delaney, "Single-incision vs straight laparoscopic segmental colectomy: a case-controlled study," *Diseases of the Colon and Rectum*, vol. 54, no. 2, pp. 183–186, 2011.

[28] M. H. Chew, M. T. C. Wong, B. Y. K. Lim, K. H. Ng, and K. W. Eu, "Evaluation of current devices in single-incision laparoscopic colorectal surgery: a preliminary experience in 32 consecutive cases," *World Journal of Surgery*, vol. 35, no. 4, pp. 873–880, 2011.

[29] A. Fichera, M. Zoccali, and R. Gullo, "Single Incision ("Scarless") laparoscopic total abdominal colectomy with end Ileostomy for ulcerative colitis," *Journal of Gastrointestinal Surgery*, vol. 15, no. 7, pp. 1247–1251, 2011.

[30] W. T. L. Chen, S. C. Chang, H. C. Chiang et al., "Single-incision laparoscopic versus conventional laparoscopic right hemicolectomy: a comparison of short-term surgical results," *Surgical Endoscopy*, vol. 25, no. 6, pp. 1887–1892, 2011.

[31] H. T. Papaconstantinou, N. Sharp, and J. S. Thomas, "Single-incision laparoscopic right colectomy: a case-matched comparison with standard laparoscopic and hand-assisted laparoscopic techniques," *Journal of the American College of Surgeons*, vol. 213, no. 1, pp. 72–80, 2011.

[32] H. Ross, S. Steele, M. Whiteford et al., "Early multi-institution experience with single-incision laparoscopic colectomy," *Diseases of the Colon and Rectum*, vol. 54, no. 2, pp. 187–192, 2011.

[33] D. P. Gandhi, M. Ragupathi, C. B. Patel, D. I. Ramos-Valadez, T. B. Pickron, and E. M. Haas, "Single-incision versus hand-assisted laparoscopic colectomy: a case-matched series," *Journal of Gastrointestinal Surgery*, vol. 14, no. 12, pp. 1875–1880, 2010.

[34] A. Keshava, C. J. Young, and S. MacKenzie, "Single-incision laparoscopic right hemicolectomy," *British Journal of Surgery*, vol. 97, no. 12, pp. 1881–1883, 2010.

[35] J. A. Waters, M. J. Guzman, A. D. Fajardo et al., "Single-port laparoscopic right hemicolectomy: a safe alternative to conventional laparoscopy," *Diseases of the Colon and Rectum*, vol. 53, no. 11, pp. 1467–1472, 2010.

[36] J. Adair, M. A. Gromski, R. B. Lim, and D. Nagle, "Single-incision laparoscopic right colectomy: experience with 17 consecutive cases and comparison with multiport laparoscopic right colectomy," *Diseases of the Colon and Rectum*, vol. 53, no. 11, pp. 1549–1554, 2010.

[37] K. J. Gash, A. C. Goede, W. Chambers, G. L. Greenslade, and A. R. Dixon, "Laparoendoscopic single-site surgery is feasible in complex colorectal resections and could enable day case colectomy," *Surgical Endoscopy and Other Interventional Techniques*, vol. 25, no. 3, pp. 835–840, 2011.

[38] B. Vestweber, A. Alfes, C. Paul, F. Haaf, and K. H. Vestweber, "Single-incision laparoscopic surgery: a promising approach to sigmoidectomy for diverticular disease," *Surgical Endoscopy and Other Interventional Techniques*, vol. 24, no. 12, pp. 3225–3228, 2010.

[39] L. Boni, G. Dionigi, E. Cassinotti et al., "Single incision laparoscopic right colectomy," *Surgical Endoscopy and Other Interventional Techniques*, vol. 24, no. 12, pp. 3233–3236, 2010.

[40] N. A. Rieger and F. F. Lam, "Single-incision laparoscopically assisted colectomy using standard laparoscopic instrumentation," *Surgical Endoscopy and Other Interventional Techniques*, vol. 24, no. 4, pp. 888–890, 2010.

[41] T. Makino, J. Milsom, and S. Lee, "Feasibility and safety of single incision laparoscopic colectomy: a systematic review," *Annals of Surgery*, vol. 255, no. 4, pp. 667–676, 2012.

[42] D. Pietrasanta, N. Romano, V. Prosperi, L. Lorenzetti, G. Basili, and O. Goletti, "Single-incision laparoscopic right colectomy for cancer: a single-centre preliminary experience," *Updates in Surgery*, vol. 62, no. 2, pp. 111–115, 2010.

[43] D. P. Geisler, H. T. Kirat, and F. H. Remzi, "Single-port laparoscopic total proctocolectomy with ileal pouch-anal anastomosis: initial operative experience," *Surgical Endoscopy and Other Interventional Techniques*, vol. 25, no. 7, pp. 2175–2178, 2011.

[44] U. Guller, N. Jain, S. Hervey, H. Purves, and R. Pietrobon, "Laparoscopic vs open colectomy: outcomes comparison based on large nationwide databases," *Archives of Surgery*, vol. 138, no. 11, pp. 1179–1186, 2003.

[45] S. R. Steele, T. A. Brown, R. M. Rush, and M. J. Martin, "Laparoscopic vs open colectomy for colon cancer: results from a large nationwide population-based analysis," *Journal of Gastrointestinal Surgery*, vol. 12, no. 3, pp. 583–591, 2008.

Hindawi Publishing Corporation
Minimally Invasive Surgery
Volume 2012, Article ID 232347, 5 pages
doi:10.1155/2012/232347

Review Article

Single-Port Laparoscopic Surgery in Children: Concept and Controversies of the New Technique

Felix C. Blanco[1] and Timothy D. Kane[1, 2, 3]

[1] *Sheikh Zayed Institute for Pediatric Surgical Innovation, Children's National Medical Center, Washington, DC 20010, USA*
[2] *The George Washington University School of Medicine and Health Sciences, Washington, DC 20052, USA*
[3] *Department of Surgery, Children's National Medical Center, 111 Michigan Avenue Northwest, Washington, DC 20010, USA*

Correspondence should be addressed to Timothy D. Kane, tkane@cnmc.org

Received 4 December 2011; Revised 30 March 2012; Accepted 11 April 2012

Academic Editor: Boris Kirshtein

Single-incision laparoscopic surgery (SILS) is emerging as an alternative technique to conventional laparoscopy for the treatment of common surgical diseases. Despite its wide use, the adoption of SILS in children has been slower since the broad application of minimally invasive techniques in children, in general, has historically lagged behind those in adults. This paper reviews the evolution of SILS from its original conception and its application in the field of pediatric surgery.

1. Introduction

The conception of laparoscopic surgery revolutionized the management of numerous surgical conditions and brought significant advantages over open surgery, beneficial for both the patient and the surgeon. Decreased postoperative pain, reduced operative times, faster recovery, and excellent cosmesis are now well-known attributes of minimal access surgery.

Laparoscopy had constantly evolved with the intent to make surgery "scarless." Two-port laparoscopic cholecystectomy, described by a group in Hong Kong in the late 90s, was perhaps the first sign of this new trend [1]. Without doubt, minimally invasive surgery is now inevitably moving towards even less invasive procedures which require a reduced number of access ports.

Single-incision laparoscopic surgery (SILS) originated from the concept of natural orifice transluminal endoscopic surgery (NOTES), which emerged as an option to laparoscopy. The access to the peritoneal cavity through normal viscerae and the risk for intra-abdominal contamination was, however, a troublesome concern with NOTES. To address these issues, surgeons began to use the umbilical scar as the portal of entry to the abdomen, giving origin to "transumbilical surgery" or SILS.

It was only a few years ago that SILS was applied to common surgical procedures, such as appendectomy and gastrostomy. Early reports of SILS describe the placement of multiple ports through a single incision with additional retraction utilizing transabdominal sutures. Retraction of the appendix with transabdominal "sling" sutures through the mesoappendix is an example of a commonly used strategy in the early stages of SILS appendectomy [2]. More recently, innovative techniques evolved into more complex laparoscopic procedures including nephrectomy, splenectomy, adrenalectomy, and bowel resection with intracorporeal anastomosis [3–6].

2. Single-Incision and Single-Port Laparoscopy

In the beginning of the SILS era, the lack of proper devices to gain access to the peritoneal cavity motivated surgeons to implement new techniques and to generate innovative ideas. Home-made devices were initially used as an alternative to the currently available multichannel ports [7, 8]. An example of this was the use of a single-access device made of a surgical glove introduced through an umbilical incision; each finger of the glove was used to fit a separate laparoscopic instrument [9].

More recently, access to the abdomen was accomplished by introducing three 3–5 mm trocars through separate but contiguous incisions in the fascia under the same skin incision, a technique commonly used in small children (Figure 1). The separate fascial incisions are connected into a single incision at the end of the procedure to facilitate the extraction of the resected specimen. When the working space is limited, as is the case in neonates, accessory laparoscopic instruments are inserted directly through fascial stab wounds to avoid trocar crowding [10]. As expected, carbon dioxide leak can be significant with this technique [11].

The increasing need for an optimal access platform in SILS led to the invention of a multichannel "cannula" by a group in Spain [12]. The idea of introducing multiple instruments through a single device or port was well received by surgeons making possible the development of sophisticated ports for laparoscopic and thoracoscopic procedures [13–18]. Modern *access ports* can carry multiple trocars; these include the R-port, Uni-X Single Port, TriPort, and Quadport systems and allow the simultaneous introduction of multiple laparoscopic instruments and permit insufflation with an airtight seal. However, the large size of these devices (which may require a 2-3 cm fascial incision) often precludes the use in small children.

Despite the development of improved single-access ports, the need for instrument triangulation remained a concern when using SILS. Our experience with standard straight laparoscopic instruments for cholecystectomy and other single-incision procedures was satisfactory; however, we observed that it requires expertise and demands longer operative times [10]. Hansen and colleagues emphasized the importance of using graspers of different lengths and upside-down grip of instruments to avoid instrument and hand clashing when working with straight conventional laparoscopic instruments [11]. Novel instruments with bent tips and roticulating mechanisms address, to some extent, this issue and have the benefit of avoiding in-line viewing and clashing of instruments [11, 19]. Unfortunately, the availability of these sophisticated instruments is restricted, its cost is high, and its applicability to young children is limited by their large size.

Some surgeons routinely place a thin grasper (2 mm Minilap Alligator-Stryker Endoscopy, San Jose, CA) through the same or a remote fascial incision to assist with retraction [20]. A group in Argentina designed laparoscopic magnetic graspers that allow organ retraction when coupled with external magnets during SILS [21]. These magnets effectively provide retraction and overcome the lack of adequate triangulation.

Harmonic scalpel and LigaSure (Covidien Norwalk, CT, USA) are coagulation/cutting devices commonly used in SILS. These devices seem to simplify the dissection of tissues and reduce operative times when comparing SILS to conventional laparoscopy in adults [22]. SIL splenectomy utilizing a combination of harmonic scalpel and LigaSure was safely performed in children [23].

Finally, as laparoscopic instruments evolve, newly developed angled light cord extensions and extralong endoscopes (>50 cm) allowed enhanced visualization and better maneuverability without interfering with the already hand-crowded single port [19].

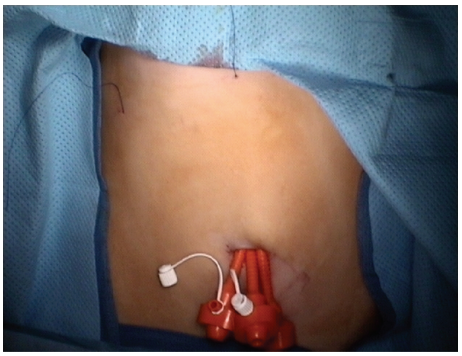

Figure 1: Single-incision multiple-trocar technique. Three low-profile trocars are inserted through separate contiguous incisions in the fascia. A transabdominal suture used to retract the gallbladder fundus is shown in the RUQ.

3. SILS in Children

SILS was introduced in children much later than in adults [4, 7, 24]. This delay may be due to the perception that the small scars left by pediatric laparoscopic instruments were acceptable. Most likely, use of SILS in children has been slower since the broad application of minimally invasive techniques in children, in general, has historically lagged behind those in adults. Moreover, there is a concern regarding the limited maneuverability of laparoscopic instruments in the small peritoneal cavity of children, which is already challenging even with multiple trocar laparoscopy.

In spite of these uncertainties, pediatric surgeons considered performing more complex procedures with less invasive techniques. Soon enough, single-port gastrostomy proved to be a suitable technique in children [24]. Later, Rothenberg and colleagues validated the use of SILS in the pediatric patient describing their experience on laparoscopic cholecystectomy. Their technique used an operating laparoscope, through which a single working instrument could be introduced. Often, they had to insert an additional instrument through a separate incision and use transabdominal sutures to retract the gallbladder [25].

Although popular among adult SIL procedures, the use of multichannel ports is limited in small children due to their large size. Instead, many pediatric surgeons often prefer to place several 3–5 mm ports through a single umbilical wound, (Figure 1) as well as transabdominal sutures. These sutures are used to encircle the round ligament for liver retraction and often include seromuscular bites through the wall of various hollow organs including the gallbladder, stomach, or mesoappendix [2, 10, 11]. These "retracting" stitches are a common practice among pediatric surgeons and are particularly useful in small children due to their thin abdominal wall (Figure 2).

An acceptable technique for retraction consists in the placement of thin graspers through remote stab incisions or through the same fascial opening [11].

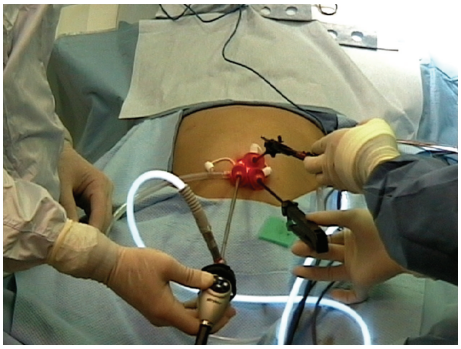

Figure 2: Multitrocar port inserted for single-incision laparoscopic cholecystectomy. An extralong endoscope and two instruments with different lengths were used to avoid hand clashing.

4. Single-Incision Laparoscopic Appendectomy

Two techniques of SIL appendectomy are currently available as follows.

4.1. Intracorporeal SIL Appendectomy. Intracorporeal SIL appendectomy is commonly performed with the three-trocar technique. Two 5 mm and one 3 mm low-profile trocars are introduced through separate fascial openings after a curvilinear infraumbilical incision is made in the skin. The trocars are generally positioned at 2, 6, and 10 o'clock position.

An angled 30° camera is introduced through one of the 5 mm ports and its tip kept close to the abdominal wall to avoid clashing with the working instruments. The appendix is retracted with a grasper and the mesoappendix followed to its base where it is divided with hook cautery. The appendix is then double ligated with endoloops, divided with scissors, and retrieved using one of the three following techniques: (1) direct removal through the umbilicus, (2) inserting the finger of a surgical glove and placing the specimen within this for retrieval, or (3) use of conventional endoscopic retrieval bag inserted alongside the camera and grasping instrument. To facilitate removal, the three small incisions are connected into one, and the wound closed in layers.

4.2. Extracorporeal SIL Appendectomy. In this technique, a single 10 mm trocar is inserted through the umbilicus with a semiopen technique. A blunt grasper is introduced through the single channel of an operating laparoscope to mobilize the appendix from inflammatory adhesions until the mesoappendix is exposed. It is then grabbed, gently pulled inside the trocar, and removed simultaneously with the scope. Once exteriorized, the appendix is ligated and divided outside the abdomen with a standard technique. The appendiceal stump is then returned to the peritoneal cavity and the incision closed.

5. Single-Incision Laparoscopic Cholecystectomy

SIL cholecystectomy (SILC) is one of the most popular procedures in both adults and children. Our technique of SILC includes the placement of an SILS port (Covidien, Norwalk, CT) in older children and the placement of three 5 mm ports through separate openings in the fascia with a technique similar to that of intracorporeal appendectomy. After the fascia is exposed, a Veress needle is introduced to achieve pneumoperitoneum.

In SILC, obtaining the critical view of safety to properly visualize the cystic duct and artery is perhaps of utmost importance. As mentioned previously, the limited instrument triangulation makes this task challenging, enforcing the use of additional ports. We often use transabdominal sutures to retract the gallbladder fundus or infundibulum and introduce a 2 mm Minilap Alligator grasper (Stryker Endoscopy, San Jose, CA, USA) through the umbilicus or a separate RUQ incision. Once the gallbladder is properly retracted, the cystic duct and artery are identified, double clipped, and divided. The gallbladder is then dissected off the liver bed with hook cautery and, when completely detached, it is extracted from the peritoneal cavity through the umbilical fascial defect, which is converted to a single incision of approximately 2 cm. The incision is closed with standard technique. If made, small incisions to fit 2 mm instruments are simply approximated with a single inverted subcuticular stitch.

Our initial experience with SILC had outcomes comparable to those of standard laparoscopy with no conversions to open cholecystectomy. Only seven percent of patients required at least one additional port [10].

6. Other SIL Procedures

Many centers with modern laparoscopic capability rapidly expanded the indications of SILS. In children, SIL pyloromyotomy, splenectomy, nephrectomy, inguinal hernia, fundoplication, diaphragmatic hernia repair, and bowel surgery have been described [10, 11, 26, 27]. Tormenti and colleagues recently reported a technique of SILS ventriculoperitoneal shunt placement in children with hydrocephalus [28]. The direct visualization of the shunt as it enters the peritoneal cavity and the avoidance of an abdominal incision contiguous to the shunt are attractive attributes of this novel technique.

Procedures not fully developed in children but available for adults include adrenalectomy, liver resections, colectomy with intracorporeal anastomosis, and single-incision thoracoscopy [18, 29–31].

7. Outcomes of SILS

Without doubt, the cosmetic appearance of a literally "scarless" procedure is one of the greatest attributes of SILS. The use of the umbilical scar as the single portal of entry for the instruments allows for a more conventional and safe option compared to NOTES. Yet, this cosmetic advantage may not be as relevant in children who usually outgrow the size of the routine 3 and 5 mm incisions used in conventional laparoscopy. As an additional benefit, the umbilical incision can, as it routinely is, be used for specimen retrieval and

converted to a circumumbilical incision when there is need for a larger incision.

Despite the limited number of incisions, no major differences exist in the recovery time or need for postoperative analgesia when SILS is compared to conventional laparoscopy. The postoperative length of stay after cholecystectomy was similar for children undergoing either technique in one series [32]. A recent randomized controlled trial showed that patients who underwent SIL cholecystectomy experienced less postoperative pain and required fewer analgesics compared to those who were treated with conventional laparoscopic cholecystectomy [33]. In spite of the encouraging outcomes of SILS [34], level 1 evidence showed that SIL appendectomy was associated with increased requirement of analgesics, longer operative times, and higher hospital charges compared to the standard approach [35].

Unfortunately, the need for specialized laparoscopic equipment reduces the cost-effectiveness of SILS. Though feasible in experienced hands, use of conventional laparoscopic instruments in SILS prolongs the operative times and makes the learning curve steeper. As the operative times are reduced with the utilization of specially designed equipment, this negatively affects the overall cost of surgery. We believe that longer operative times can be significantly reduced as experience is gained by the operating surgeon and with the use of roticulating instruments [36, 37]. The limited availability and high cost of angled graspers and multichannel ports significantly increase the operative costs, as we mentioned before.

Reported intraoperative SILS complications include bowel perforation, thermal injury, and bleeding [11]. In a series of 32 SIL pyloromyotomies, the reported complication rate was 6% including duodenal and pyloric mucosal perforations [11].

Ponsky and colleagues published their experience with more than 70 pediatric SILS cases including cholecystectomy, appendectomy, and gastrostomy. They reported an acceptable rate of conversion to conventional laparoscopy and a low incidence of postoperative complications [22]. In other series including adults and children, the outcomes of SILC were comparable to standard laparoscopic cholecystectomy with no major postoperative complications and a conversion rate of 2 to 11% [10, 38–40]. Conversion to standard laparoscopy or the addition of extra ports should not be considered a complication of SILS. Under no circumstances should the surgeon compromise patient safety and utilize sound judgment when considering adding extra ports or retraction stitches, when necessary.

Recent reports indicate that elective SILS cholecystectomy is safe when done in the outpatient setting.

8. The Future of SILS in Children

The development of sophisticated laparoscopic instruments with multidirectional roticulating and articulating capabilities will soon allow the pediatric surgeon perform complex laparoscopic procedures in a more efficient and easy way. With these, limited triangulation and tissue handling will no longer be an issue. In addition, the development of smaller, low-profile SILS ports will ease the maneuverability of laparoscopic instruments and avoid trocar crowding in the already reduced operative field of children.

In spite of the early reported success of SILS, we believe that there are still formidable obstacles which must be overcome in order to optimize this approach in children. Certainly, the boundless creativity of the surgeon in search for less invasive methods of performing operations may eventually evolve into the ideal "scarless" surgery.

Conflict of Interests

Drs. F. C. Blanco and T. D. Kane have no financial relationships with any commercial identities described in this paper nor conflict of interests to disclose.

References

[1] K. W. Lee, C. M. Poon, K. F. Leung, D. W. H. Lee, and C. W. Ko, "Two-port needlescopic cholecystectomy: prospective study of 100 cases," *Hong Kong Medical Journal*, vol. 11, no. 1, pp. 30–35, 2005.

[2] O. Ateş, G. Hakgüder, M. Olguner, and F. M. Akgür, "Single-port laparoscopic appendectomy conducted intracorporeally with the aid of a transabdominal sling suture," *Journal of Pediatric Surgery*, vol. 42, no. 6, pp. 1071–1074, 2007.

[3] M. M. Desai, P. P. Rao, M. Aron et al., "Scarless single port transumbilical nephrectomy and pyeloplasty: first clinical report," *BJU International*, vol. 101, no. 1, pp. 83–88, 2008.

[4] J. H. Kaouk and J. S. Palmer, "Single-port laparoscopic surgery: initial experience in children for varicocelectomy," *BJU International*, vol. 102, no. 1, pp. 97–99, 2008.

[5] E. R. Podolsky and P. G. Curcillo Jr., "Single port access (spa) surgery-a 24-month experience," *Journal of Gastrointestinal Surgery*, vol. 14, no. 5, pp. 759–767, 2010.

[6] S. Morales-Conde, J. García Moreno, J. Cañete Gómez et al., "Total intracorporeal anastomosis during single-port laparoscopic right hemicolectomy for carcinoma of colon: a new step forward," *Surgical Innovation*, vol. 17, no. 3, pp. 226–228, 2010.

[7] Y. H. Park, M. Y. Kang, M. S. Jeong, H. Choi, and H. H. Kim, "Laparoendoscopic single-site nephrectomy using a homemade single-port device for single-system ectopic ureter in a child: initial case report," *Journal of Endourology*, vol. 23, no. 5, pp. 833–835, 2009.

[8] H. S. Yu, W. S. Ham, K. H. Rha et al., "Laparoendoscopic single-site nephrectomy using a modified umbilical incision and a home-made transumbilical port," *Yonsei Medical Journal*, vol. 52, no. 2, pp. 307–313, 2011.

[9] H. J. Kim, J. I. Lee, Y. S. Lee et al., "Single-port transumbilical laparoscopic appendectomy: 43 consecutive cases," *Surgical Endoscopy and Other Interventional Techniques*, vol. 24, no. 11, pp. 2765–2769, 2010.

[10] N. Garcia-Henriquez, S. R. Shah, and T. D. Kane, "Single-incision laparoscopic cholecystectomy in children using standard straight instruments: a surgeon's early experience," *Journal of Laparoendoscopic and Advanced Surgical Techniques*, vol. 21, no. 6, pp. 555–559, 2011.

[11] E. N. Hansen, O. J. Muensterer, K. E. Georgeson, and C. M. Harmon, "Single-incision pediatric endosurgery: lessons

learned from our first 224 laparoendoscopic single-site procedures in children," *Pediatric Surgery International*, vol. 27, no. 6, pp. 643–648, 2011.

[12] E. Sánchez de Badajoz, A. Jiménez Garrido, A. Simón Mata, and F. García Vacas, "Multi-instruments cannula: a new concept of laparoscopy," *Archivos Espanoles de Urologia*, vol. 61, no. 6, pp. 667–672, 2008.

[13] R. J. Romanelli, L. Mark, and P. A. Omotosho, "Single port laparoscopic cholecystectomy with the triport system: a case report," *Surgical Innovation*, vol. 15, no. 3, pp. 223–228, 2008.

[14] M. Kroh and S. Rosenblatt, "Single-port, laparoscopic cholecystectomy and inguinal hernia repair: first clinical report of a new device," *Journal of Laparoendoscopic and Advanced Surgical Techniques*, vol. 19, no. 2, pp. 215–217, 2009.

[15] E. R. Podolsky, S. J. Rottman, H. Poblete, S. A. King, and P. G. Curcillo, "Single Port Access (SPA) cholecystectomy: a completely transumbilical approach," *Journal of Laparoendoscopic and Advanced Surgical Techniques*, vol. 19, no. 2, pp. 219–222, 2009.

[16] A. Chow, S. Purkayastha, and P. Paraskeva, "Appendicectomy and cholecystectomy using single-incision laparoscopic surgery (SILS): the first UK experience," *Surgical Innovation*, vol. 16, no. 3, pp. 211–217, 2009.

[17] A. A. Saber, T. H. El-Ghazaly, and D. B. Minnick, "Single port access transumbilical laparoscopic roux-en-y gastric bypass using the SILS port: first reported case," *Surgical Innovation*, vol. 16, no. 4, pp. 343–347, 2009.

[18] O. Gigirey Castro, L. Berlanga González, and E. Sánchez Gómez, "Single port thorascopic surgery using the SILS® tool as a novel method in the surgical treatment of pneumothorax," *Archivos de Bronconeumologia*, vol. 46, no. 8, pp. 439–441, 2010.

[19] T. A. Ponsky, "Single port laparoscopic cholecystectomy in adults and children: tools and techniques," *Journal of the American College of Surgeons*, vol. 209, no. 5, pp. e1–e6, 2009.

[20] T. A. Ponsky and D. M. Krpata, "Single-port laparoscopy: considerations in children," *Journal of Minimal Access Surgery*, vol. 7, no. 1, pp. 96–98, 2011.

[21] B. E. Padilla, G. Dominguez, C. Millan, and M. Martinez-Ferro, "The use of magnets with single-site umbilical laparoscopic surgery," *Seminars in Pediatric Surgery*, vol. 20, no. 4, pp. 224–231, 2011.

[22] T. A. Ponsky, J. Diluciano, W. Chwals, R. Parry, and S. Boulanger, "Early experience with single-port laparoscopic surgery in children," *Journal of Laparoendoscopic and Advanced Surgical Techniques*, vol. 19, no. 4, pp. 551–553, 2009.

[23] M. Joshi, S. Kurhade, M. S. Peethambaram, S. Kalghatgi, M. Narsimhan, and R. Ardhanari, "Single-incision laparoscopic splenectomy," *Journal of Minimal Access Surgery*, vol. 7, no. 1, pp. 65–67, 2011.

[24] T. A. Ponsky and J. R. Lukish, "Single site laparoscopic gastrostomy with a 4-mm bronchoscopic optical grasper," *Journal of Pediatric Surgery*, vol. 43, no. 2, pp. 412–414, 2008.

[25] S. S. Rothenberg, K. Shipman, and S. Yoder, "Experience with modified single-port laparoscopic procedures in children," *Journal of Laparoendoscopic and Advanced Surgical Techniques*, vol. 19, no. 5, pp. 695–698, 2009.

[26] M. Yamoto, Y. Morotomi, M. Yamamoto, and S. Suehiro, "Single-incision laparoscopic percutaneous extraperitoneal closure for inguinal hernia in children: an initial report," *Surgical Endoscopy and Other Interventional Techniques*, vol. 25, no. 5, pp. 1531–1534, 2011.

[27] P. D. Danielson and N. M. Chandler, "Single-port laparoscopic repair of a Morgagni diaphragmatic hernia in a pediatric patient: advancement in single-port technology allows effective intracorporeal suturing," *Journal of Pediatric Surgery*, vol. 45, no. 3, pp. E21–E24, 2010.

[28] M. J. Tormenti, M. A. Adamo, J. M. Prince, T. D. Kane, and T. J. Spinks, "Single-incision laparoscopic transumbilical shunt placement," *Journal of Neurosurgery*, vol. 8, pp. 390–393, 2011.

[29] S. I. Choi, K. Y. Lee, S. J. Park, and S. H. Lee, "Single port laparoscopic right hemicolectomy with D3 dissection for advanced colon cancer," *World Journal of Gastroenterology*, vol. 16, no. 2, pp. 275–278, 2010.

[30] A. G. Patel, A. P. Belgaumkar, J. James, U. P. Singh, K. A. Carswell, and B. Murgatroyd, "Single-incision laparoscopic left lateral segmentectomy of colorectal liver metastasis," *Surgical Endoscopy and Other Interventional Techniques*, vol. 25, no. 2, pp. 649–650, 2011.

[31] T. T. Goo, A. Agarwal, R. Goel et al., "Single-port access adrenalectomy: our initial experience," *Journal of Laparoendoscopic & Advanced Surgical Techniques A*, vol. 21, no. 9, pp. 815–819, 2011.

[32] C. N. Emami, D. Garrett, D. Anselmo, M. Torres, N. X. Nguyen et al., "Single-incision laparoscopic cholecystectomy in children: a feasible alternative to the standard laparoscopic approach," *Journal of Surgical Research*, vol. 46, no. 10, pp. 1909–1912, 2011.

[33] E. C. Tsimoyiannis, K. E. Tsimogiannis, G. Pappas-Gogos et al., "Different pain scores in single transumbilical incision laparoscopic cholecystectomy versus classic laparoscopic cholecystectomy: a randomized controlled trial," *Surgical Endoscopy and Other Interventional Techniques*, vol. 24, no. 8, pp. 1842–1848, 2010.

[34] S. B. Sesia, F. M. Haecker, R. Kubiak, and J. Mayr, "Laparoscopy-assisted single-port appendectomy in children: Is the postoperative infectious complication rate different?" *Journal of Laparoendoscopic and Advanced Surgical Techniques*, vol. 20, no. 10, pp. 867–871, 2010.

[35] S. D. St Peter, O. O. Adibe, D. Juang et al., "Single incision versus standard 3-port laparoscopic appendectomy: a prospective randomized trial," *Annals of Surgery*, vol. 254, no. 4, pp. 586–590, 2011.

[36] A. J. Kravetz, D. Iddings, M. D. Basson, and M. A. Kia, "The learning curve with single-port cholecystectomy," *Journal of the Society of Laparoendoscopic Surgeons*, vol. 13, no. 3, pp. 332–336, 2009.

[37] D. Solomon, R. L. Bell, A. J. Duffy, and K. E. Roberts, "Single-port cholecystectomy: small scar, short learning curve," *Surgical Endoscopy and Other Interventional Techniques*, vol. 24, no. 12, pp. 2954–2957, 2010.

[38] J. Erbella Jr. and G. M. Bunch, "Single-incision laparoscopic cholecystectomy: the first 100 outpatients," *Surgical Endoscopy and Other Interventional Techniques*, vol. 24, no. 8, pp. 1958–1961, 2010.

[39] P. G. Curcillo II, A. S. Wu, E. R. Podolsky et al., "Single-port-access (SPA) cholecystectomy: a multi-institutional report of the first 297 cases," *Surgical Endoscopy and Other Interventional Techniques*, vol. 24, no. 8, pp. 1854–1860, 2010.

[40] N. M. Chandler and P. D. Danielson, "Single-incision laparoscopic cholecystectomy in children: a retrospective comparison with traditional laparoscopic cholecystectomy," *Journal of Pediatric Surgery*, vol. 46, no. 9, pp. 1695–1699, 2011.

Hindawi Publishing Corporation
Minimally Invasive Surgery
Volume 2012, Article ID 492409, 5 pages
doi:10.1155/2012/492409

Research Article

Single-Port Transumbilical Laparoscopic Appendectomy: A Preliminary Multicentric Comparative Study in 87 Patients with Acute Appendicitis

Ramon Vilallonga,[1] Umut Barbaros,[2] Ahmed Nada,[3] Aziz Sümer,[2] Tuğrul Demirel,[2] José Manuel Fort,[1] Oscar González,[1] and Manuel Armengol[1]

[1] *General Surgery Department, Universitary Hospital Vall d'Hebron, Barcelona 08035, Spain*
[2] *General Surgery Department, Istanbul University, Istanbul Faculty of Medicine, Istanbul 34104, Turkey*
[3] *General Surgery Department, Cairo University, Cairo 11471, Egypt*

Correspondence should be addressed to Ramon Vilallonga, vilallongapuy@hotmail.com

Received 21 November 2011; Accepted 5 March 2012

Academic Editor: Boris Kirshtein

Introduction. Laparoscopic appendectomy (LA) has been performed in many approaches such as open, laparoscopic and recently Single Port Access (SPAA). In order to elucidate its potential advantages, we compared the two laparoscopic approaches. *Methods*. 87 patients were included in a multicentric study for suspected appendicitis in order to perform (SPAA) appendectomy or laparoscopic appendectomy (LA). All outcomes, including blood loss, operative time, complications, and length of stay and pain were recorded prospectively. *Results*. There were 46 patients in the SPAA group and 41 in the LAG with a mean operative time of 40,4 minutes in the SPAA group and 35,0 minutes in the LA group. Only one patient was converted to an open approach. We described only 2 complications. Pain was graded 2,8 in the SPAA group and 2,9 in the LA group, according to the AVS after 24 hours. Patients in the SPAA Group were more satisfied (7,5 versus 6,9) ($P < 0.05$). Same results were found for the cosmetic result (8,6 versus 7,4) ($P < 0.05$). *Conclusion*. Using the single port approach feasible and safe. The true benefit of the technique should be assessed by new randomised controlled trials.

1. Introduction

Nowadays, minimally invasive surgery has increased in its use [1]. A new era has been opened with recent innovations that have pioneered the use of single-incision laparoscopic surgery (SILS) or Single Port Access (SPA). This novel technique or approach may be placed between the pure NOTES surgery, the hybrid NOTES surgery, and the standard laparoscopic surgery [2–5]. Appendectomy is the most common abdominal emergency operation performed in the western world. Some reasons have made that more and more appendectomies are currently performed laparoscopically such as advantages to patients in terms of more accurate diagnosis, diminished wound infections, possibility to treat obese patients, and a more rapid recovery [6]. First report of single-puncture laparoscopic appendectomy technique was performed in 1992 and showed the new approach as a safe, inexpensive, and effective alternative to the currently used multiple-puncture method [7].

The new transumbilical approach seems to reduce the trauma of surgical access with its improvement of the post-operative pain and patient cosmesis compared to standard laparoscopic approach. However, other important issues must be critically analysed such as time consumed complications, and difficulties to perform this novel technique. This new technique has been introduced to the surgical community, and we have concentrated on knowing about the feasibility, safety, and clinical advantage of the method. For these reasons, in order to implement SPA appendectomy (SPAA), and know its difficulties, limitations, or advantages, we conducted this multicentre study. The aim of the study is to know if SPA would offer similar operative time, length of stay, and complication profile with improved cosmesis and

less postoperative pain in comparison to traditional multi-incision laparoscopic appendectomy or also called standard laparoscopic appendectomy (LA).

2. Patients and Methods

In this study, 92 patients (Table 1) underwent SPA appendectomy and standard laparoscopic appendectomy. Three different teams of surgeons in three different hospitals performed the interventions: Vall d'Hebron Hospital (Barcelona, Spain), Cairo University Hospital (Cairo, Egypt), and Istanbul Faculty of Medicine (Istanbul, Turkey). All the three surgeons were trained expert surgeons in laparoscopy and had already performed SILS cholecystectomy previously. All the patients were informed about the intervention technique and provided written informed consent. All the patients had a suggestive clinical diagnosis of acute appendicitis. All patients included in the study were from patients undergoing urgent surgery. Each patient in each hospital was included alternatively in each treatment group (SPAA group and LA group).

2.1. Operative Technique. The two surgical techniques were established in both the study and control groups according to a consensus approved by the authors previous to the beginning of the study and according to the different hospital possibilities. Patients were divided into two different groups: SPAA group (SPAAG) and LA group (LAG). For the SPAAG, a single intraumbilical 22 mm incision was made, and the umbilicus was pulled out, exposing the fascia in SPAAG. The surgeons in this study completely extroflexed the umbilicus and a skin incision was made longitudinally for about 1,5 to 2 cm. Two types of trocars were used in the SPAAG and that were currently manufactured for this purpose: the TriPort (Advanced Surgical Concepts, Wicklow, Ireland) and the SILS Port (Covidien, Inc., Norwalk, CT, USA). For the patients included in the LAG, standard trocars were used. All trocars were placed under direct vision. Pneumoperitoneum was maintained at 14 mmHg with carbon dioxide (CO_2). The abdominal cavity was explored with a 10 mm 30° standard scope in both groups. The patients were then put in a Trendelenburg position and rotated to the left.

In some patients in the SPAAG, reticulating instruments were used to create the necessary operative angle, according to technical difficulties (Reticulating Endo Mini-Shears; Autosuture and Reticulating Endograsp, 5 mm; Autosuture).

The appendicular artery was first exposed, and then clipped if necessary with a standard 5 mm clip applier or cauterized by bipolar grasper.

Two endoloops were used at the stump of the appendix and then divided.

Then, in both groups, a 5 mm 30° standard scope was used in order to extract the specimen. Careful control of homeostasis was then achieved, and drainage was left in place according to surgeon's personal criteria. The fascial incisions were closed with an absorbable suture, and the umbilicus was restored with absorbable cutaneous stitches to its anatomic position. The rest of skin incisions were closed with absorbable cutaneous stitches.

Table 1: Demographic data of the Single Port Access Appendectomy Group (SPAA Group) and the Laparoscopic Appendectomy Group (LA Group).

	SPAA group (SPAAG) $N = 46$	Laparoscopic appendectomy group (LAG) $N = 41$	P value
Age (years), mean (sd)	34,2 (13,3)	37,7 (13,2)	0,227
Gender, n (%)			0,287
Male	19 (41,3)	22 (53,7)	
Female	27 (58,7)	19 (46,3)	

Intraoperative complications such as bleeding, drain placement, surgical times (trocar(s) placement, and surgical dissection and closure) were calculated. The uniformity of anaesthetic technique could not be established because of the different teams involved in each case. Postoperative complications and time for discharge have also been analysed. Pain referred by patients after 12 hours was measured with VAS [8]. All patients received paracetamol 1 g/8 h i.v. as a standard analgesic treatment. During the followup in the outpatient clinic, other data such as hernia or other complications were evaluated. The patients in the outpatient clinic, at one month after surgery, answered two questions: "*How much satisfied with the surgery are you? (0–10)*" and "*How satisfied are you with the cosmetic result of the surgery? (1–10)*." These short questions pretended to know about the degree of satisfaction and the satisfaction with the cosmetic result.

2.2. Statistical Analysis. Treatments for acute appendicitis, LA versus SPAA, were compared using t-test for continuous variables (age, times, bleeding, oral intake, discharge, pain at 12 hours, degree of satisfaction, and satisfaction of cosmetic result) and Pearson's chi-square test for categorical variables (sex, appendix dissection and section, complications, and result pathology). $P < 0.05$ was considered significant. Analysis was performed using Stata (StataCorp. 2007. Stata Statistical Software: Release 10. College Station, TX: StataCorp LP)

3. Results

Between July 2009 and March 2010, 87 patients were randomized for suspected appendicitis into the SPAA group (SPAAG) or an LA group (LAG). There were 46 patients in the SPAA group and 41 in the LA group. The mean age of the patients was 34,2 (17–73) for the SPAA group and 37,7 (19–69) for the LA group. There were 19 males and 27 females in the SPAA group and 22 males and 19 females in the LA group (Table 1).

SILS Port was used in 38 patients and TriPort in 8 patients and there was no technical difference between them.

In spite of technical difficulties and disorientation specially in the first few cases, the mean operative time was 40,4

minutes in the SPAA group and 35, 0 minutes in the LA group ($P = 0,110$).

In only 1 patient of the SPAA group, the procedure was converted to an open approach due to technical difficulties in a colonic cancer diagnosed during the surgery. Complications occurred in 2 patients, all in the SPPA group. First patient presented with acute coronary syndrome during the surgery; another young woman suffered of an acute pulmonary oedema caused by an allergic reaction to Dexketoprofen who required 5 days endotracheal intubation. The two patients presented a long hospital stay (7 days, 11 days, and 10 days resp.). All these hospital stays have been included in the mean of the postoperative stay at hospital. Drains have been used in 8 and 5 patients in each group because of the local peritonitis found (Tables 2 and 3).

Oral intake was accomplished after 12,5 hours in the SPAA group and 10,7 hours in the LA group. The mean hospital stay was 44,4 hours in the SPAA group (mean 14–264) and 34,0 hours (mean 11–96) in the LA group. Pain was evaluated and was 2,8 in the SPAA group and 2,9 in the LA group, according to the AVS after 24 hours. The degree of satisfaction was higher in the SPAA group (7,5 versus 6,9) ($P < 0.05$). Same results were found for the cosmetic result (8,6 versus 7,4) ($P < 0.05$). At three-month followup, no hernia or other complications have appeared.

4. Discussion

Many surgical research groups have developed new surgical technique called Natural Orifice Transluminal Endoscopic Surgery (NOTES) [9]. Some appendectomies have even been performed through a vaginal approach, without visible scars [10]. However, many authors consider that umbilicus a natural orifice since its origin. For this reason, many authors have reported the feasibility of LA with a transumbilical approach, especially in children [11]. Also, some studies investigated the feasibility of SPAA in study populations ranging from 1 to 200 patients, and there is not a standard use of size port in the LAG [12]. As most surgeons, we used conventional ports with a variety of different-sized instruments.

Also, the umbilical access is a well-known and standardized site for access to the abdominal cavity for laparoscopic procedures [13]. However, many authors have described an SPA appendectomy as a step toward less invasive surgical procedures [14]. According to surgeon's experience, umbilical access does not add new risks, and it makes the operating view the same as in standard laparoscopic appendectomy. In this study no differences were found comparing the trocar placement time of each group, and all the trocars were placed under direct vision.

Once the pneumoperitoneum is performed, both techniques can allow making an intraoperative differential diagnosis with other pathologies [15]. In our series, examination of distal ileum, female genital organs including the tubes and the ovary, and other organs situated in pelvic area can be accomplished without difficulties. We had to reconvert to an open surgery approach in a cecal carcinoma misdiagnosed preoperatively.

When the fascia is exposed, it is possible to enter the abdominal cavity with various devices such as 10 mm trocar and two 5 mm trocars. The single-port technique allows easy use of a 10-mm instrument if needed without the burden of having to work with a 5 mm and a 10 mm port so close together.

Due to the vicinity of the ports at the fascial plane in the umbilicus, the operative technique can be more difficult. In some cases the crossing of the instruments (or specially designed instruments) makes the procedure more challenging and initiating new learning curve for surgeon. It has not been defined yet the number of cases needed to gain good experience in SPAA. But it seems that 10 cases should be the number in order to perform a correct learning curve with previous experience in laparoscopic surgery [16].

In our opinion appendectomy is relatively easy operation performed in a relatively safe abdominal area (no much vital organs). This novel approach should probably be the first one to be considered before beginning SPA cholecystectomies, which are more demanding.

When drain is required, right side placement is suitable and can be placed under direct vision.

A very important issue is to consider the conversion from single-incision (SPAA) technique to standard laparoscopic technique. Fear from intraoperative complications is due to inadequate visualization or mobilization of the appendix. For this reason, we consider that a two-port or three-port conversion should not be considered a failure or complication. This concept is very important and is absolutely mandatory in emergency surgeries. An optimum safe view must be achieved. If this is not achieved then the addition of ports is recommended. The opinion of the authors concerning the visualization in this series was not as optimal as with typical laparoscopy. However, a recent report shows that the suprapubic trocar placement shows better benefits in case of retrocecal or purulent or gangrenous acute appendicitis. Trocar placement via the suprapubic approach makes access to and dissection of the appendix easy, and it also enables exteriorization of a drain without adding new lateral incisions [17].

When the diagnosis was established, we found the appendix oedematous, gangrenous, perforated with varying degree of peritonitis, or even associated with peritoneal abscess. According to our short limited experience, we think SPAA technique seems to be suitable for the variety of appendicitis.

Because of the initial experience and the cosmetic research, SPAA has been performed in nonobese and obese patients. According to the literature especially obese patients benefit from LA compared to open one [6, 18]. Unfortunately, at the time of the randomization, the BMI was not calculated but retrospectively analysed, the BMI of the SPAAG is not different from LAG. This is probably because of the lack of experience in the first cases, the fear of umbilical closure, and the search of a better cosmetic result in young women. Many of our patients were adolescent females who may be very aware of their body image.

Table 2: Results concerning operative technique.

	SPAA group (SPAAG) $N = 46$	Laparoscopic appendectomy group (LAG) $N = 41$	P value
Trocar use			
(i) Covidien SILS	39	—	
(ii) Olympus TriPort	8	—	
Time of trocar(s) introduction (minutes), mean (SD)	5,9 (3,0)	5,8 (1,4)	0,788
Time of surgical dissection (minutes), mean (SD)	40,4 (17,5)	35,0 (13,6)	0,110
Time of closure (minutes), mean (SD)	6,5 (2, 3)	5,6 (1,3)	0,027
Conversion to laparoscopic or open	1 (colonic cancer)	0	0,342
Bleeding (mL), mean (SD)	7 (15,2)	5 (12,2)	0,763
Drainage, n (%)	4 (12,2)	5 (8,7)	0,729

Table 3: Postoperative results and outcomes.

	SPAA group (SPAAG) $N = 46$	Laparoscopic appendectomy group (LAG) $N = 41$	P value
Oral intake (after hours), mean (SD)	12,5 (20)	10,7 (21)	0,962
Discharge (hours), mean (SD)	44,4 (51)	34,0 (20)	0,225
Complications			
(i) One patient had acute coronary syndrome during the surgery; another had acute pulmonary oedema	2	0	0,178
(ii) Seroma	0	0	—
(iii) Hernia	0	0	—
Pain at 12 hours (AVS), mean (SD)	2,8 (0,90)	2,9 (0,78)	0,774
Degree of satisfaction, mean (SD)	7,5 (1,0)	6,9 (1,2)	0,009
Satisfaction of aesthetic result, mean (SD)	8,6 (0,9)	7,4 (1,3)	<0,001
Pathology, n (%)			1,000
(i) Acute appendicitis	29 (63)	28 (68)	
(ii) Perforated appendicitis	15 (33)	13 (32)	
(iii) Chronic appendicitis	1 (2)	0	
(iv) Colonic neoplasm	1 (2)	0	

It seems reasonable to think that the benefits of transition from standard laparoscopic approach to SPAA will be easier than the transition from open to laparoscopic appendectomy.

Accordingly, we believe that the use of this approach for appendectomy is worthwhile. SPAA can be performed properly by one straight instrument and one curved instrument, and even by two standard straight instruments, making the procedure easier compared to use of two curved instruments. New devices and new technology is now available at the time of writing that makes this technique easier.

Concerning the cosmetic result, at the end of the procedure, surgeons took time performing a careful reconstruction of the umbilicus in both groups. Cosmetic results show that there is a certain advantage of performing the single-incision surgery compared to standard one. Patients seem to be more satisfied with the overall result and with the cosmetic result. However, this is a difficult subjective opinion and difficult to measure. According to other authors, the issue of the influence of abdominal scar on the cosmetic and body image showed no difference between open and traditional laparoscopic appendectomies [19]. Our patients are more satisfied with the SPAA than LA ($P < 0,05$), but the importance of abdominal scar may be age and sex related. There is a feeling that young nurses would have scarless operation rather than LA or even open approach. Some authors suggest that suprapubic SILS appendectomy offers better, cosmetically appealing results than the standard umbilical access [17]. However, the data generated by the use of our questionnaire is of dubious quality and cannot be used to make any meaningful statements on satisfaction and cosmetics because it has not been validated.

Recent technologic development has enabled the wider acceptance of new approaches in laparoscopic surgery such as SPAA. All recent data show that the technique is feasible, safe, but will require new randomized studies in order to clarify its indications and a cost effectiveness study of this novel technique will seriously be required [20].

5. Conclusion

Single-incision laparoscopic surgery is a feasible way to perform appendectomy. This includes obese patients, uncomplicated and complicated appendicitis as well as exploratory laparoscopy. Conversion to a three-port operation should be done in any case when optimal or suboptimal conditions are not present. As patients' safety was the most important patients with acute appendicitis should be the ones in order to begin the SPAA technique.

The expense and added operative time should be evaluated if it provides the patients with minimal, if any, apparent scarring. Patients are more satisfied with SPAA than LA approach regarding the cosmetic result.

Refinements in instrumentation will enable wider use of this novel minimally invasive approach. The true benefit of the technique should be assessed by new randomised controlled trials.

References

[1] P. Lukovich and P. Kupcsulik, "NOTES and other minimally invasive surgical techniques (hybrid NOTES, NOTUS, SPS, SILS), and their effect on surgical approaches," *Magyar Sebészet*, vol. 62, no. 3, pp. 113–119, 2009.

[2] C. Palanivelu, P. S. Rajan, M. Rangarajan, R. Parthasarathi, P. Senthilnathan, and P. Praveenraj, "Transumbilical flexible endoscopic cholecystectomy in humans: first feasibility study using a hybrid technique," *Endoscopy*, vol. 40, no. 5, pp. 428–431, 2008.

[3] S. A. Giday, S. V. Kantsevoy, and A. N. Kalloo, "Principle and history of natural orifice translumenal endoscopic surgery (NOTES)," *Minimally Invasive Therapy and Allied Technologies*, vol. 15, no. 6, pp. 373–377, 2006.

[4] R. Seven and U. Barbaros, "Needloscopy-assisted transvaginal cholecystectomy," *Surgical Laparoscopy, Endoscopy and Percutaneous Techniques*, vol. 19, no. 2, pp. e61–e63, 2009.

[5] L. DeCarli, R. Zorron, A. Branco et al., "Natural orifice translumenal endoscopic surgery (NOTES) transvaginal cholecystectomy in a morbidly obese patient," *Obesity Surgery*, vol. 18, no. 7, pp. 886–889, 2008.

[6] S. Sauerland, R. Lefering, and E. A. Neugebauer, "Laparoscopic versus open surgery for suspected appendicitis," *Cochrane Database of Systematic Reviews*, vol. 18, no. 4, Article ID CD001546, 2004.

[7] M. A. Pelosi and M. A. Pelosi III, "Laparoscopic appendectomy using a single umbilical puncture (minilaparoscopy)," *Journal of Reproductive Medicine for the Obstetrician and Gynecologist*, vol. 37, no. 7, pp. 588–594, 1992.

[8] D. Benhamou, "Assessment of postoperative pain," *Annales Francaises d'Anesthesie et de Reanimation*, vol. 17, no. 6, pp. 555–572, 1998.

[9] C. Edwards, A. Bradshaw, P. Ahearne et al., "Single-incision laparoscopic cholecystectomy is feasible: inicial experience with 80 cases," *Surgical Endoscopy*, vol. 24, no. 9, pp. 2241–2247, 2010.

[10] R. Pugliese, A. Forgione, F. Sansonna, G. C. Ferrari, S. Di Lernia, and C. Magistro, "Hybrid NOTES transvaginal cholecystectomy: operative and long-term results after 18 cases," *Langenbeck's Archives of Surgery*, vol. 395, no. 3, pp. 241–245, 2010.

[11] J. S. Valla, R. M. Ordorica-Flores, H. Steyaert et al., "Umbilical one-puncture laparoscopic-assisted appendectomy in children," *Surgical Endoscopy*, vol. 13, no. 1, pp. 83–85, 1999.

[12] K. Ahmed, T. T. Wang, V. M. Patel et al., "The role of single-incision laparoscopic surgery in abdominal and pelvic surgery: a systematic review," *Surgical Endoscopy*, vol. 25, no. 2, pp. 378–396, 2010.

[13] R. Tacchino, F. Greco, and D. Matera, "Single-incision laparoscopic cholecystectomy: surgery without a visible scar," *Surgical Endoscopy and Other Interventional Techniques*, vol. 23, no. 4, pp. 896–899, 2009.

[14] R. Vilallonga, R. A. Stoica, A. Cotirlet, M. Armengol, and N. Iordache, "Single incision laparoscopic surgery (SILS) cholecystectomy. A novel technique.," *Chirurgia*, vol. 105, no. 2, pp. 239–241, 2010.

[15] J. Kössi and M. Luostarinen, "Initial experience of the feasibility of single-incision laparoscopic appendectomy in different clinical conditions," *Diagnostic and Therapeutic Endoscopy*, vol. 2010, Article ID 240260, 4 pages, 2010.

[16] A. Chow, S. Purkayastha, and P. Paraskeva, "Appendicectomy and cholecystectomy using single-incision laparoscopic surgery (SILS): the first UK experience," *Surgical Innovation*, vol. 16, no. 3, pp. 211–217, 2009.

[17] O. Vidal, C. Ginestà, M. Valentini, J. Martí, G. Benarroch, and J. C. García-Valdecasas, "Suprapubic single-incision laparoscopic appendectomy: a nonvisible-scar surgical option," *Surgical Endoscopy*, vol. 25, no. 4, pp. 1019–1023, 2010.

[18] M. G. Corneille, M. B. Steigelman, J. G. Myers et al., "Laparoscopic appendectomy is superior to open appendectomy in obese patients," *American Journal of Surgery*, vol. 194, no. 6, pp. 877–881, 2007.

[19] I. Sucullu, A. I. Filiz, A. E. Canda, E. Yucel, Y. Kurt, and M. Yildiz, "Body image and cosmesis after laparoscopic or open appendectomy," *Surgical Laparoscopy, Endoscopy and Percutaneous Techniques*, vol. 19, no. 5, pp. 401–404, 2009.

[20] F. Froghi, M. H. Sodergren, A. Darzi, and P. Paraskeva, "Single-incision laparoscopic surgery (SILS) in general surgery: a review of current practice," *Surgical Laparoscopy, Endoscopy and Percutaneous Techniques*, vol. 20, no. 4, pp. 191–204, 2010.

Hindawi Publishing Corporation
Minimally Invasive Surgery
Volume 2012, Article ID 347607, 9 pages
doi:10.1155/2012/347607

Review Article

Single-Incision Laparoscopic Cholecystectomy: Is It a Plausible Alternative to the Traditional Four-Port Laparoscopic Approach?

Juan Pablo Arroyo,[1] Luis A. Martín-del-Campo,[2] and Gonzalo Torres-Villalobos[2,3]

[1] *Molecular Physiology Unit, Instituto de Investigaciones Biomédicas, Universidad Nacional Autónoma de México and Instituto Nacional de Ciencias Médicas y Nutrición Salvador Zubirán, Zubirán, 14000 Mexico, df, Mexico*
[2] *Surgery Department, Instituto Nacional de Ciencias Médicas y Nutrición Salvador Zubirán, Zubirán, 14000 Mexico, DF, Mexico*
[3] *Experimental Surgery Department, Instituto Nacional de Ciencias Médicas y Nutrición Salvador Zubirán, Zubirán, 14000 Mexico, DF, Mexico*

Correspondence should be addressed to Gonzalo Torres-Villalobos, torresvgm@yahoo.com.mx

Received 4 December 2011; Accepted 23 February 2012

Academic Editor: Boris Kirshtein

The current standard-of-care for treatment of cholecystectomy is the four port laparoscopic approach. The development of single incision/laparoendoscopic single site surgery (SILC/LESS) has now led to the development of new techniques for removal of the gallbladder. The use of SILC/LESS is now currently being evaluated as the next step in treatment of cholecystectomy. This review is an attempt to consolidate the current knowledge and analyze the feasibility of world-wide implementation of SILC/LESS.

1. Introduction

The ultimate goal of surgery has always been providing the best and most effective procedure with the least amount of postoperative complications, and pain and the best possible aesthetic results. Surgery of the biliary tract is by no means the exception. The first reported elective cholecystectomy was carried out by Langenbuch in 1882 [1] and open cholecystectomy became the standard-of-care well into the 1980s with mortality rates at less than 1%, and bile duct injuries affecting 0.1-0.2% of patients [2, 3]. This approach however required a large abdominal incision associated with significant postoperative pain and a longer convalescence.

A revolution in the surgical treatment of biliary disease came in the 1980s with the introduction of laparoscopic surgery. The first laparoscopic cholecystectomy was performed by Mühe [4] however his approach did not become popular until both French and American groups popularized the four-port technique in the early 1990s. The idea of minimally invasive surgery for the removal of the gallbladder had now become a plausible technique that was rapidly accepted as the standard-of-care. Patients quickly learned of the new procedure and began to request it on the basis of a shorter hospital stay, less pain, and smaller scars [5]. The possibility of performing laparoscopic cholangiography, common bile duct exploration, and choledochotomy expanded the role of laparoscopic surgery in the treatment of biliary disease [6] and further advanced the idea of minimally invasive surgery as the gold-standard for surgery of the biliary tract.

Recently the development of natural orifice transluminal endoscopic surgery (NOTES) opened the field of incisionless surgery. The main goal of NOTES is to eliminate the need for skin incisions along with other theoretical advantages which include: decreased postoperative pain, performing procedures in the out-patient setting, reduced incidence of hernias, reduced hospital stay, and increased overall patient satisfaction [5, 7]. The idea of accessing internal organs through the wall of the vagina, colon, stomach, bladder, and so forth, with the use of rigid or flexible instruments is an attractive one. However, the challenge of obtaining a clean access site thereby preventing intra-abdominal spillage or infection from the incision has not been able to be fully avoided [7]. Additionally the concern over closure of the luminal incision and the lack of a single effective

closure technique for stomach, esophagus, or colon, so far limits the application of this technique. Moreover, the possibility of generating bowel-overdistention due to the pneumoperitoneum required for adequate visualization of intra-abdominal structures is still a concern [5]. With current ongoing research on the efficacy and safety of NOTES it is still premature to advocate it as an alternative to laparoscopic surgery of the biliary tract.

Single-incision laparoscopic surgery or SILS refers to the operative technique in which a surgical procedure is carried out through one incision, alternatively it is also known as laparoendoscopic single site (LESS) surgery. In 1997 Navarra et al. described a single-incision laparoscopic cholecystectomy as a plausible alternative procedure to the four-port laparoscopic cholecystectomy [8]. The use of a single umbilical incision to remove the gallbladder was an interesting innovation and, since Navarra's initial description, the single-incision laparoscopic cholecystectomy (SILC) procedure has gained momentum. The goals of SILC/LESS cholecystectomy are similar to the goals behind the development of NOTES: decreased pain, decreased length of hospital stay, better aesthetic results, and increased patient satisfaction among others [6, 9]. Multiple articles regarding the use of SILC/LESS cholecystectomy have been published since the initial two studies were published by Bresadola et al. [10] and Piskun and Rajpal [11], leading to a wealth of information regarding the possible adoption of the SILC/LESS cholecystectomy by surgeons worldwide, including a 2010 consensus statement by the Laparoendoscopic Single-Site Surgery Consortium for Assessment and Research (LESSCAR) [9]. It is our goal to review the different SILC/LESS cholecystectomy techniques reported so far along with the results associated with the most recent SILC/LESS cholecystectomy trials.

2. Technical Aspects of Laparoendoscopic Single Site Cholecystectomy

Due to the growing experience and development of ports and instrumentation, surgical technique for LESS cholecystectomy is rapidly evolving [21]. A particular technical challenge for the LESS approach is limited triangulation due to confinement of both optics and working instruments to a single axis. Researchers and the industry are pursuing solutions to this through the development of next-generation instruments (Angled, flexible, articulated, and motorized) [9].

Given this, there is a wide variation of methods regarding the type of ports, trocars, optics, instruments, and methods to expose and dissect the gallbladder (Table 1). Nevertheless, many LESS procedures (including cholecystectomy) have been successfully performed with conventional laparoscopic instruments.

Table 1: Commercially available multiport systems.

Port system	Manufacturer
AnchorPort	Surgiquest Inc (Orange, CT, USA)
GelPOINT	Applied Medical (Rancho Santa Margarita, CA, USA)
SILS Port	Covidien (Norwalk, CT, USA)
TriPort	Advanced Surgical Concepts (Wicklow, Ireland)
Uni-X Single Port	Pnavel Systems (Brooklyn, NY, USA)

2.1. Surgical Technique

2.1.1. Patient Position. The patient is placed in supine or the split-leg position, with the surgeon standing on the patient's left [22] or between the patient's legs [23]. According to the surgeon's position, the assistant is placed either on the patient's right or left. After access to the abdominal cavity is obtained, the patient will be placed in reverse Trendelenburg with a slight rotation to the left to clear abdominal organs from the gallbladder [24].

2.1.2. Abdominal Cavity Access. Access can be accomplished by two approaches [25]:

(i) LESS devices (Table 1) are designed to deploy through a single incision (typically at the umbilicus) and require a fascial incision of approximately 15 to 25 mm [14];

(ii) single incision with multiple trocars uses commercially available laparoscopic ports placed through a single incision with a bridge of fascia between them [26]. A particular concern about this approach is the risk for increased hernia rates given the unknown effect of multiple fascial punctures in proximity [25], although to this date, there are no reports of different hernia rates between these two approaches.

2.1.3. Gallbladder Exposure. Most of the initial experience in LESS cholecystectomy relies on gallbladder suspension using transparietal stitches [6, 27]. Although different approaches have been described, the principle is to place one to three stitches in the gallbladder fundus and/or infundibulum and apply different degrees of tension to expose the Calot's triangle while using another instrument to dissect [28].

Nevertheless, some authors advocate for abandoning transparietal stitches for exposure, as they may be associated with accidental puncture and a potential oncological risk [21]; therefore, they prefer an intracorporeal grasper placed through a transumbilical port or a SILS port to gain dynamic exposure. Also, the use of an additional 1.8 to 3 mm grasper introduced through the skin has been used to assist cephalad retraction and has not been considered as conversion in recent clinical trials [18, 19]. There is also a report of extracorporeal retraction using magnet forceps attached to the gallbladder [29].

2.1.4. Calot's Triangle Dissection. One should always consider that a less invasive procedure must also be safe. Therefore, every effort must be made to comply with the requirements of the critical view of safety for laparoendoscopic cholecystectomy [30], that comprises dissection of the neck of gallbladder off the liver bed to achieve conclusive identification

of the two structures to be divided: the cystic duct and the artery.

Instruments used for this purpose are very similar to those of 4-port laparoscopic cholecystectomy and include 5 mm hook, dissector scissor, and angle dissector. The cystic duct and artery are then dissected free, secured with clips, and divided [22].

2.1.5. Gallbladder Bed Dissection. Although gallbladder dissection can be accomplished with a fundus-first technique [19], we encourage to do it after preparation of the cystic duct and artery (Strasberg critical view). Dissection is usually performed with a hook type electrocautery device [24].

2.1.6. Extraction. After cholecystectomy has been completed, the gallbladder can be extracted through the LESS port, as it acts as a wound protector [17], or using a specimen bag that is introduced through the umbilical port when traditional laparoscopic instruments are being used. When using laparoscopic instruments, extraction through 5 mm ports is unfeasible and they will need to be increased to 10 or 12 mm [6].

2.1.7. Wound Closure. The fascial incision is closed with a figure of eight stitch [18]. Deep dermis of the umbilicus is reapproximated to ensure cosmesis [23].

2.2. Current Application. The current status of single-site surgery poses several technical difficulties for the surgeon [9], and cholecystectomy has not been the exception. Current consensus recommends that LESS procedures are only performed in centers with adequate laparoscopic experience and by surgeons with a certain amount of LESS surgical training [9].

Nevertheless, Mutter et al. have shown that LESS cholecystectomy can be safely implemented in a teaching hospital with both senior and junior laparoscopic surgeons [31]. For surgeons that are proficient with multi-incision laparoscopic cholecystectomy, the learning curve for LESS cholecystectomy begins near proficiency with infrequent complications and conversion rates [32].

2.3. Technical Strategies. In order to overcome the limitations of triangulation with the LESS approach, several approaches have been proposed. Curved and or articulated instruments have been used according to the surgeon's preference [14], as they may allow to work on the operative field without a straight approach from the access port. Using these instruments requires the instrument from the right hand to be on the left side of the screen and the left-hand instrument to be on the right side of the screen [6, 33].

One can choose an instrument with handles that are articulated so they are away from each other at the access port or use ports with a lower external or internal profile for a wider range of instrument motion. Also, instruments of variable lengths allow for external manipulation so that they are operated in different planes, thus avoiding collisions [25].

3. Patient Outcomes: SILC/LESS cholecystectomy versus Four-Port Cholecystectomy

In spite of numerous reports regarding the safety and efficacy of the SILS/LESS cholecystectomy approach, laparoscopic cholecystectomy (LC) still remains the gold-standard for the surgical removal of the gallbladder [6]. Thus the comparison of patient outcomes between both procedures is of key importance. In this respect several prospective studies comparing LC and SILC/LESS Cholecystectomy have now been published [12–20] (Table 2).

There are several blinded randomized trials comparing standard LC to SILC/LESS cholecystectomy with varied results regarding patient outcomes. An outcome that has had a significant difference in several studies comparing SILC/LESS cholecystectomy versus LC is the cosmetic result. Patients are more satisfied with the hidden or infraumbilical single surgical scar than the four scars created by the LC [13, 17, 19]. In an attempt to try and reduce the bias associated with cosmetic evaluation, Marks et al. and Bucher et al. used body image scale, a scar scale photo series 10-point scoring questionnaire in order to compare results between SILC/LESS and LC patients. However regardless of the scale used, there is still an element of personal preference and opinion involved with the evaluation of cosmetic results.

Aside from cosmetic perception, the only consistently reproducible and statistically significant result among series is a prolonged time of surgery for the SILC/LESS cholecystectomy groups versus standard LC groups [12–14, 16–20]. A study by Qiu et al. [34] focused specifically on the learning curve phenomenon associated with SILC/LESS cholecystectomy and saw an improvement in operative times as experience was gained [34] this was similar to what was observed by others [18–20]. The increased operating time may be a combination of factors among which the lack of surgeon experience and the technical difficulty behind SILC/LESS cholecystectomy could be involved. However, increased operating time means increased duration of general anesthesia and thus increased patient risk. Although no anesthesia-related complications were reported in the mentioned trials, a significant number of the studies used ASA class III or IV as a cut-off point for patients suitable for SILC/LESS cholecystectomy [13, 14, 19], thus the use of SILC/LESS cholecystectomy in patients in which there are foreseeable anesthesia-related complications remains limited.

One of the ultimate goals of the development of SILS/LESS cholecystectomy is a reduction in postoperative pain perception and a decreased used of analgesic medications [9]. The evaluation of postoperative pain is consistently included as a primary or secondary outcome in recent studies [12–20] but lacking in previous studies [6]. The outcome however remains obscure as there are reports in which there is no difference in pain perception between SILC/LESS cholecystectomy and LC groups [14, 16, 18], increased perception in the SILC/LESS cholecystectomy group [15, 19], and decreased pain perception in the SILC/LESS cholecystectomy groups [12, 17]. The lack of consistent evidence regarding

Table 2: Comparison of clinical trials comparing SILC versus 4PLC—SILC/LESSC (single-incision laparoscopic cholecystectomy/laparoendoscopic single-site cholecystectomy), 4PLC (four port laparoscopic cholecystectomy).

Study	Study type	Year	No. of patients	Inclusion criteria	Exclusion criteria	Primary outcomes	Secondary outcomes	Mean operative time (min)	
								SILC/LESSC	LC
Tsimoyiannis et al. [12]	Prospective, randomized	2010	40	BMI < 30, pain from cholelithiasis, ASA class I or II	BMI > 30, acute cholecystitis, choledocholithiasis or acute pancreatitis	Postoperative pain* (less pain in SILSC group)	NR	49.65 ± 9.02*	37.3 ± 9.16
Marks et al. and Phillips et al. (same cohort of patients) [13, 14]	Prospective, randomized,	2011	200	BMI < 45, diagnosis of biliary colic, with gallstones or polyps, biliary dyskinesia EF < 30%.	Pregnancy, acute cholecystitis, preoperative indication for cholangiogram, ASA class III or IV, peritoneal dialysis, umbilical hernia	Intraoperative, postoperative complications (up to 1 yr)*, operative time*, and estimated blood loss.	Pain evaluation* (less pain in 4PLC group), cosmesis*, quality of life, time required for insertion of SILS/LESSC port versus LC ports	57.2*	45.2
Lai et al. [15]	Prospective, randomized,	2011	51	Age 18–80 yrs, diagnosis of symptomatic gallstones or polyps scheduled for elective cholecystectomy	ASA class IV or V, contraindication to laparoscopy, the Mirizzi syndrome, suspected common duct stones, suspected malignancy, previous upper abdominal surgery, long-term anticoagulation, previous history of cholangi-tis/cholecystitis, gallstones >3 cm, contracted gallbladder or chronic cholecystitis	Postoperative pain* (less pain in LC group)	Open conversion rate, surgical complications, hospital stay, resumption of normal life, cosmesis	43.5 ± 15.4	46.5 ± 20.1

Table 2: Continued.

Study	Study type	Year	No. of patients	Inclusion criteria	Exclusion criteria	Primary outcomes	Secondary outcomes	Mean operative time (min)	
								SILC/LESSC	LC
Lee et al. [16]+	Prospective, randomized	2010	70	Symptomatic colelithiasis, ASA class I or II	Acute cholecystitis, common bile duct stones, severe obesity and previous upper abdominal surgery	Postoperative pain	Duration of surgery, complications, analgesic requirements, length of hospital stay*, cosmesis*, wound length*, time to return to work	71.7 ± 11.6*	48.4 ± 10.5
Bucher et al. [17]	Prospective, randomized	2011	150	Elective patients with symptomatic gallbladder stones, history of cholecystitis, history of common bile duct stone migration and/or biliary pancreatitis, age > 18 yrs	Acute gallbladder disease, contraindications to pneumoperi-toneum, cirrhosis, mental impairment	Cosmesis*	Postoperative pain* (less in SILC/LESSC group), analgesia requirement*, satisfaction*, morbidity, duration of operation, need for main port expansion for specimen retraction*, hospital stay, return to work* and operative costs*	66 (no SD reported)	64 (no SD reported)
Ma et al. [18]	Prospective, randomized	2011	43	Indications for LC with no evidence of choledocholithi-asis, age 18–85 yrs, BMI < 40, creatinine < 2 mg/dL, AST/ALT <5x upper limit of lab normal, normal total bilirubin	Acute cholecystitis, gallstones >2.5 cm	Postoperative pain	Operative time, length of hospital stay, postoperative morbidity, QOL, cosmesis	88.5*	44.8

Table 2: Continued.

Study	Study type	Year	No. of patients	Inclusion criteria	Exclusion criteria	Primary outcomes	Secondary outcomes	Mean operative time (min)	
								SILC/LESSC	LC
Lirici et al. [19]	Prospective, randomized	2011	40	age 18–75, BMI < 30, no previous abdominal surgery, gallstones on US exam. ASA class I–III, Nassar grade I–III	BMI > 30, previous abdominal surgery, acute cholecystitis, bile duct stones, pancreatitis, ASA class > III, Nassar grade IV	Length of stay, postoperative pain* (higher with SILC/LESSC on the day of surgery, rest NS), cosmetic results*, SF-36 questionnaire scores* (Role Emotional only, rest NS)	Operative time*, conversion to LC, difficulty of exposure*, difficulty to dissect, complication rate	76.75*	48.25
Gang et al. [20]	Prospective, matched pair analysis	2011	134	SILC/LESSC patients matched to LC controls		Completion rate, operating time, postoperative complications, length of stay, postoperative pain		77 ± 26*	68 ± 31

[+] SILC versus mini laparoscopic procedure.
* Statistically significant difference.

pain perception requires further evaluation in randomized clinical trials.

In comparing outcomes between procedures, one of the key points to evaluate is the presence or absence of intraoperative and postoperative complications. A procedure can be considered safe only if the rate of complications is similar to that of the current gold-standard. When comparing the rate of complications between SILC and LESS cholecystectomy numerous studies have reported both, no significant difference with regard to complication rate [6, 15, 17, 22] or an increased complication rate when comparing SILS/LESS cholecystectomy to LC [14, 18]. With regard to the study by Phillips et al. [14] it is interesting to note that this is the same cohort of patients as an initial report by Marks et al. In the original report by Marks et al. [13] there was no significant difference in complications. However in the report by Phillips et al. [14], the number of patients increased and so did the complications associated with single-incision surgery [14]. This is the largest case series published so far and in theory the learning curve has leveled off, indicating that the complications are inherent to the procedure itself, questioning the feasibility of widespread application of the SILC/LESS cholecystectomy. One of the complications that has been discussed the most is the increased risk of a postincisional hernia after SILS/LESS surgery due to an increase in size of the defect in the fascia. This complication has tried to be avoided by turning multiple fascial defects into a single incision, however, results have been inconclusive. [6, 14, 25, 35].

Previous data on patient outcomes after SILC/LESS cholecystectomy suggest that this new procedure is reproducible and safe [9], however this does not seem to agree with the results from the recent RCTs (see above). The literature on SILS/LESS cholecystectomy has been recently reviewed by Antoniou et al. [6]. They analyzed the results of 29 different articles reporting the realization of a SILC/LESS cholecystectomy with a total of 1166 patients. Among the reported results there is 9.3% of unsuccessful surgery, generally due to a lack of proper identification of Calot's triangle, along with a cumulative intraoperative complication rate of 2.7% (range 0–20%) with the most common being gallbladder perforation/bile spillage (2.2%) and hemorrhage (0.3%). The most common postoperative complications were wound infection and hematoma in 2.1% of patients [6].

In more recent articles Duron et al. and Mutter et al. reported series of 55 and 58 patients, respectively, who underwent SILC/LESS Cholecystectomy [31, 36]. Duron et al. [36] reported a series of 55 cases performed in a single institution, in which a "learning curve" effect was present with regard to shorter operating times and the inclusion of more technically difficult patients as surgeon experience increased [36]. Mutter et al. [31] analyzed the implementation of this type of surgery in a teaching hospital comparing six surgeons (3 senior surgeons and 3 junior surgeons) finding no significant difference between operating times or complication rates, thus advocating the safe implementation of SILC/LESS cholecystectomy in teaching hospitals [31]. These results however, include a limited number of surgeons and are applicable only to patients with programmed cholecystectomies without any foreseeable factors aggravating dissection of Calot's triangle as out of the 58 patients only 3 were diagnosed with acute cholecystitis, thereby limiting their applicability.

In a matched pair analysis that took place over 26 months, Gangl et al. [20] compared operating time, postoperative pain using the visual analogous scale (VAS) at 24 and 48 hrs, use of analgesics, length of hospital stay, and complications [20]. They performed the SILC/LESS patient data gathering prospectively, comparing them to matched controls from a group of 163 LC which were performed in the same time period, with no significant differences in age, gender, BMI, ASA classification, diagnosis of acute cholecystitis, or previous abdominal surgery. They reported a SILC/LESS cholecystectomy completion rate of 85.1%, with conversion to LC in 9 patients and open cholecystectomy in 1 patient due to inadequate visualization of the anatomy, versus a 100% completion rate in the LC group, with no significant difference with regard to postoperative pain, analgesic use, length of stay or complications. The only significant difference was the length of surgery with a longer operating time in the SILC/LESS cholecystectomy group (75 min versus 63 min). They conclude that SILC/LESS even though associated with a longer operating time is comparable to LC [20].

The incidence of biliary injury during standard LC varies from 0.5 to 0.8% [37]. In order to identify biliary injury the use of intraoperative cholangiogram is now considered a standard procedure to evaluate anatomy of the biliary tree. The possibility of carrying out a transoperative cholangiogram in SILC/LESS was recently evaluated by Yeo et al. [38]. They were able to observe that in the 55 patients in which a successful SILC was carried out, 53 received a transoperative cholangiogram out of which 48 were normal with 1 patient requiring endoscopic removal of a biliary stone [38]. This is the largest series of SILC/LESS which reports the routine evaluation of biliary anatomy with a cholangiogram performed through an umbilical port, however, whether these results are reproducible or not, requires further studies. A more pressing issue regarding biliary injury and SILC/LESS is an adequate exposure of Calot's triangle or "the Strasberg critical view." As described above, in order to achieve the "critical view," the use of transparietal sutures or magnetic forceps that allow extra corporeal traction on the gallbladder fundus can be carried out [6, 21, 29]. It is interesting to note that in the study carried out by Antoniou et al. [6], the two most common reasons for conversion from SILC/LESS to standard LC were: Inflammation/adhesions/unclear anatomy (47.4% of all conversions) and inadequate visualization of Calot's triangle (23.7% of all conversions) with a total rate of 5.2% and 2.6%, respectively [6]. The lack of an adequate identification of the anatomical landmarks be it by inflammation, adhesions, or normal anatomical variants is worrisome due to the increased incidence of bile duct injuries in the presence of a less than adequate exposure [39].

When comparing costs, the cost of SILS/LESS cholecystectomy was increased compared with that of LC in spite of the authors in the Bucher et al. [21] study reutilized as much material as possible. They hypothesized that the costs are

a reflection of product development, and that as of now costs are not comparable to those of a routine procedure such as LC [17]. In contrast, a study by Love et al. [40] in which cost comparison between 20 patients undergoing each procedure did not yield a significant cost difference [40]. Thus the issue of comparing cost is far from over, particularly if there are still a myriad of technical options available for the realization of a SILC/LESS cholecystectomy and there is no standardized instrumentation.

4. Conclusions

Current evidence suggests that even though patients prefer the cosmetic result of SILC/LESS cholecystectomy over a traditional laparoscopic approach [41], SILC/LESS cholecystectomy is still a long way off from replacing laparoscopic cholecystectomy as the gold-standard for surgical removal of the gallbladder. Insufficient evidence regarding the safety, complication rate, and costs seems to preclude the worldwide implementation of this minimally invasive procedure. Additional concerns exist regarding patient safety if it is not a programmed surgery, thus rendering SILC/LESS cholecystectomy unavailable to a large subset of patients. Initial data showing increased complication rate along with a longer operating time, lack of standardization, and instrumentation makes SILC/LESS cholecystectomy still an experimental procedure that requires further development in order to be applicable to general surgeons worldwide.

Authors' Contribution

All the authors contributed equally.

Conflict of Interests

The authors have no conflicting interests.

References

[1] N. J. Soper, "Cholecystectomy: from langenbuch to natural orifice transluminal endoscopic surgery," *World Journal of Surgery*, vol. 35, no. 7, pp. 1422–1427, 2011.

[2] L. Morgenstern, L. Wong, and G. Berci, "Twelve hundred open cholecystectomies before the laparoscopic era: a standard for comparison," *Archives of Surgery*, vol. 127, no. 4, pp. 400–403, 1992.

[3] J. J. Roslyn, G. S. Binns, E. F. X. Hughes, K. Saunders-Kirk -wood, M. J. Zinner, and J. A. Cates, "Open cholecystectomy: a contemporary analysis of 42,474 patients," *Annals of Surgery*, vol. 218, no. 2, pp. 129–137, 1993.

[4] E. Mühe, "Laparoscopic cholecystectomy—late results," *Langenbecks Archiv fur Chirurgie. Supplement. Kongressband. Deutsche Gesellschaft fur Chirurgie. Kongress*, pp. 416–423, 1991.

[5] J. Moreira-Pinto, E. Lima, J. Correia-Pinto, and C. Rolanda, "Natural orifice transluminal endoscopy surgery: a review," *World Journal of Gastroenterology*, vol. 17, no. 33, pp. 3795–3801, 2011.

[6] S. A. Antoniou, R. Pointner, and F. A. Granderath, "Single-incision laparoscopic cholecystectomy: a systematic review," *Surgical Endoscopy*, vol. 25, no. 2, pp. 367–377, 2011.

[7] B. M. Shafi, C. M. Mery, G. Binyamin, and S. Dutta, "Natural orifice translumenal endoscopic surgery (NOTES)," *Seminars in Pediatric Surgery*, vol. 15, no. 4, pp. 251–258, 2006.

[8] G. Navarra, E. Pozza, S. Occhionorelli, P. Carcoforo, and I. Donini, "One-wound laparoscopic cholecystectomy," *British Journal of Surgery*, vol. 84, no. 5, p. 695, 1997.

[9] I. S. Gill, A. P. Advincula, M. Aron et al., "Consensus statement of the consortium for laparoendoscopic single-site surgery," *Surgical Endoscopy*, vol. 24, no. 4, pp. 762–768, 2010.

[10] F. Bresadola, A. Pasqualucci, A. Donini et al., "Elective transumbilical compared with standard laparoscopic cholecystectomy," *European Journal of Surgery*, vol. 165, no. 1, pp. 29–34, 1999.

[11] G. Piskun and S. Rajpal, "Transumbilical laparoscopic cholecystectomy utilizes no incisions outside the umbilicus," *Journal of Laparoendoscopic and Advanced Surgical Techniques A*, vol. 9, no. 4, pp. 361–364, 1999.

[12] E. C. Tsimoyiannis, K. E. Tsimogiannis, G. Pappas-Gogos et al., "Different pain scores in single transumbilical incision laparoscopic cholecystectomy versus classic laparoscopic cholecystectomy: a randomized controlled trial," *Surgical Endoscopy*, vol. 24, no. 8, pp. 1842–1848, 2010.

[13] J. Marks, R. Tacchino, K. Roberts et al., "Prospective randomized controlled trial of traditional laparoscopic cholecystectomy versus single-incision laparoscopic cholecystectomy: report of preliminary data," *The American Journal of Surgery*, vol. 201, no. 3, pp. 369–373, 2011.

[14] M. S. Phillips, J. M. Marks, K. Roberts et al., "Intermediate results of a prospective randomized controlled trial of traditional four-port laparoscopic cholecystectomy versus single-incision laparoscopic cholecystectomy," *Surgical Endoscopy*. In press.

[15] E. C.H. Lai, G. P.C. Yang, C. N. Tang, P. C.L. Yih, O. C.Y. Chan, and M. K.W. Li, "Prospective randomized comparative study of single incision laparoscopic cholecystectomy versus conventional four-port laparoscopic cholecystectomy," *The American Journal of Surgery*, vol. 202, no. 3, pp. 254–258, 2011.

[16] P. C. Lee, C. Lo, P. S. Lai et al., "Randomized clinical trial of single-incision laparoscopic cholecystectomy versus mini-laparoscopic cholecystectomy," *British Journal of Surgery*, vol. 97, no. 7, pp. 1007–1012, 2010.

[17] P. Bucher, F. Pugin, N. C. Buchs, S. Ostermann, and P. Morel, "Randomized clinical trial of laparoendoscopic single-site versus conventional laparoscopic cholecystectomy," *British Journal of Surgery*, vol. 98, no. 12, pp. 1695–1702, 2011.

[18] J. Ma, M. A. Cassera, G. O. Spaun, C. W. Hammill, P. D. Hansen, and S. Aliabadi-Wahle, "Randomized controlled trial comparing single-port laparoscopic cholecystectomy and four-port laparoscopic cholecystectomy," *Annals of Surgery*, vol. 254, no. 1, pp. 22–27, 2011.

[19] M. M. Lirici, A. D. Califano, P. Angelini, and F. Corcione, "Laparo-endoscopic single site cholecystectomy versus standard laparoscopic cholecystectomy: results of a pilot randomized trial," *The American Journal of Surgery*, vol. 202, no. 1, pp. 45–52, 2011.

[20] O. Gangl, W. Hofer, F. Tomaselli, T. Sautner, and R. Függer, "Single incision laparoscopic cholecystectomy (SILC) versus laparoscopic cholecystectomy (LC)-a matched pair analysis," *Langenbeck's Archives of Surgery*, vol. 396, no. 6, pp. 819–824, 2011.

[21] P. Bucher, F. Pugin, N. Buchs, S. Ostermann, F. Charara, and P. Morel, "Single port access laparoscopic cholecystectomy (with video)," *World Journal of Surgery*, vol. 33, no. 5, pp. 1015–1019, 2009.

[22] S. E. Hodgett, J. M. Hernandez, C. A. Morton, S. B. Ross, M. Albrink, and A. S. Rosemurgy, "Laparoendoscopic single site (LESS) cholecystectomy," *Journal of Gastrointestinal Surgery*, vol. 13, no. 2, pp. 188–192, 2009.

[23] F. Brody, K. Vaziri, J. Kasza, and C. Edwards, "Single Incision Laparoscopic Cholecystectomy," *Journal of the American College of Surgeons*, vol. 210, no. 2, pp. e9–e13, 2010.

[24] K. E. Roberts, D. Solomon, A. J. Duffy, and R. L. Bell, "Single-incision laparoscopic cholecystectomy: a surgeon's initial experience with 56 consecutive cases and a review of the literature," *Journal of Gastrointestinal Surgery*, vol. 14, no. 3, pp. 506–510, 2010.

[25] J. R. Romanelli and D. B. Earle, "Single-port laparoscopic surgery: an overview," *Surgical Endoscopy*, vol. 23, no. 7, pp. 1419–1427, 2009.

[26] R. S. Chamberlain and S. V. Sakpal, "A Comprehensive review of single-incision laparoscopic surgery (SILS) and natural orifice transluminal endoscopic surgery (NOTES) techniques for cholecystectomy," *Journal of Gastrointestinal Surgery*, vol. 13, no. 9, pp. 1733–1740, 2009.

[27] G. Navarra, S. Ascanelli, D. Sortini et al., "Laparoscopic transabdominal suspension sutures [5] (multiple letters)," *Surgical Endoscopy*, vol. 16, no. 9, pp. 1378–1379, 2002.

[28] K. Ahmed, T. T. Wang, V. M. Patel et al., "The role of single-incision laparoscopic surgery in abdominal and pelvic surgery: a systematic review," *Surgical Endoscopy*, vol. 25, no. 2, pp. 378–396, 2011.

[29] G. Dominguez, L. Durand, J. De Rosa, E. Danguise, C. Arozamena, and P. A. Ferraina, "Retraction and triangulation with neodymium magnetic forceps for single-port laparoscopic cholecystectomy," *Surgical Endoscopy*, vol. 23, no. 7, pp. 1660–1666, 2009.

[30] S. M. Strasberg, M. Hertl, and N. J. Soper, "An analysis of the problem of biliary injury during laparoscopic cholecystectomy," *Journal of the American College of Surgeons*, vol. 180, no. 1, pp. 101–125, 1995.

[31] D. Mutter, C. Callari, M. Diana, B. Dallemagne, J. Leroy, and J. Marescaux, "Single port laparoscopic cholecystectomy: which technique, which surgeon, for which patient? A study of the implementation in a teaching hospital," *Journal of Hepato-Biliary-Pancreatic Sciences*, vol. 18, no. 3, pp. 453–457, 2011.

[32] J. Hernandez, S. Ross, C. Morton et al., "The learning curve of laparoendoscopic single-site (LESS) cholecystectomy: definable, short, and safe," *Journal of the American College of Surgeons*, vol. 211, no. 5, pp. 652–657, 2010.

[33] R. Tacchino, F. Greco, and D. Matera, "Single-incision laparoscopic cholecystectomy: surgery without a visible scar," *Surgical Endoscopy*, vol. 23, no. 4, pp. 896–899, 2009.

[34] Z. Qiu, J. Sun, Y. Pu, T. Jiang, J. Cao, and W. Wu, "Learning curve of transumbilical single incision laparoscopic cholecystectomy (SILS): a preliminary study of 80 selected patients with benign gallbladder diseases," *World Journal of Surgery*, vol. 35, no. 9, pp. 2092–2101, 2011.

[35] G. Navarra, G. La Malfa, G. Bartolotta, and G. Currò, "The invisible cholecystectomy: a different way," *Surgical Endoscopy*, vol. 22, no. 9, p. 2103, 2008.

[36] V. P. Duron, G. R. Nicastri, and P. S. Gill, "Novel technique for a single-incision laparoscopic surgery (SILS) approach to cholecystectomy: single-institution case series," *Surgical Endoscopy*, vol. 25, no. 5, pp. 1666–1671, 2011.

[37] A. Nordin, J. M. Grönroos, and H. Mäkisalo, "Treatment of biliary complications after laparoscopic cholecystectomy," *Scandinavian Journal of Surgery*, vol. 100, no. 1, pp. 42–48, 2011.

[38] D. Yeo, S. Mackay, and D. Martin, "Single-incision laparoscopic cholecystectomy with routine intraoperative cholangiography and common bile duct exploration via the umbilical port," *Surgical Endoscopy*, vol. 26, no. 4, pp. 1122–1127, 2012.

[39] S. Fransen, L. Stassen, and N. Bouvy, "Single incision laparoscopic cholecystectomy: a review on the complications," *Journal of Minimal Access Surgery*, vol. 8, no. 1, pp. 1–5, 2012.

[40] K. M. Love, C. A. Durham, M. P. Meara, A. C. Mays, and C. E. Bower, "Single-incision laparoscopic cholecystectomy: a cost comparison," *Surgical Endoscopy*, vol. 25, no. 5, pp. 1553–1558, 2011.

[41] A. Rao, J. Kynaston, E. R. MacDonald, and I. Ahmed, "Patient preferences for surgical techniques: should we invest in new approaches?" *Surgical Endoscopy*, vol. 24, no. 12, pp. 3016–3025, 2010.

Hindawi Publishing Corporation
Minimally Invasive Surgery
Volume 2012, Article ID 106878, 20 pages
doi:10.1155/2012/106878

Review Article

Single-Port Laparoscopic Surgery for Inflammatory Bowel Disease

Emile Rijcken, Rudolf Mennigen, Norbert Senninger, and Matthias Bruewer

Department of General and Visceral Surgery, Muenster University Hospital, Waldeyerstraße 1, 48149 Muenster, Germany

Correspondence should be addressed to Emile Rijcken, rijcken@uni-muenster.de

Received 4 December 2011; Revised 7 February 2012; Accepted 8 February 2012

Academic Editor: Boris Kirshtein

Background. Single Port Laparoscopic Surgery (SPLS) is being increasingly employed in colorectal surgery for benign and malignant diseases. The particular role for SPLS in inflammatory bowel disease (IBD) has not been determined yet. In this review article we summarize technical aspects and short term results of SPLS resections in patients with Crohn's disease or ulcerative colitis. *Methods*. A systematic review of the literature until January 2012 was performed. Publications were assessed for operative techniques, equipment, surgical results, hospital stay, and readmissions. *Results*. 34 articles, published between 2010 and 2012, were identified reporting on 301 patients with IBD that underwent surgical treatment in SPLS technique. Surgical procedures included ileocolic resections, sigmoid resections, colectomies with end ileostomy or ileorectal anastomosis, and restorative proctocolectomies with ileum-pouch reconstruction. There was a wide variety in the surgical technique and the employed equipment. The overall complication profile was similar to reports on standard laparoscopic surgery in IBD. *Conclusions*. In experienced hands, single port laparoscopic surgery appears to be feasible and safe for the surgical treatment of selected patients with IBD. However, evidence from prospective randomized trials is required in order to clarify whether there is a further benefit apart from the avoidance of additional trocar incisions.

1. Introduction

Single-Port Laparoscopic Surgery (SPLS) is a development in the field of minimally invasive surgery that aims to minimize the surgical access trauma by reducing the number of abdominal incisions to a single incision. The specimen can be extracted via the incision for the single port. Advocates of SPLS claimed potential advantages for this approach when compared to standard multitrocar laparoscopic surgery, such as better cosmetic results, decreased postoperative pain, or faster recovery, but proof for this is lacking. SPLS has been shown to be feasible in colorectal surgery in a rapidly increasing number of publications [1–4]. Various procedures in colonic surgery have been performed in SPLS technique: Both right and left hemicolectomies, sigmoid resections, and proctocolectomies with formation of an ileum-J-pouch have been reported (review in [5–7]). In these studies, indications for SPLS colonic operations included chronic diverticulitis, Crohn's disease, ulcerative colitis, familial adenomatous polyposis, large adenoma, and carcinoma of the colon. Most of these reports were limited to small patient series, demonstrating the technical feasibility of the SPLS procedure. In contrast, comparative studies of the SPLS technique with traditional laparoscopic or open surgery in larger series of patients are rare. Therefore, the true value of the SPLS technique in colonic surgery remains unclear at present. Nevertheless, the SPLS-technique might be interesting, especially in patients with benign disorders such as inflammatory bowel disease (IBD). However, the surgical treatment of patients with IBD remains challenging, since many patients present with fistulizing disease, abscesses, cachexia, recurrent disease, and compromised healing capacity following the application of immunosuppressive drugs. The aim of this systematic review was to analyze the currently available literature on single-port laparoscopic surgery in patients with IBD with respect to feasibility, reported techniques, and safety and to identify potential benefits of this new technique in this particular group of patients.

2. Methods

2.1. Article Identification and Selection. A systematic query was performed using the data bases Pubmed, Medline, and Web of Science. Articles published from January 2000 until January 2012 were considered. Search terms included "single-port laparoscopic surgery," "colorectal surgery," "single access," "single incision," "SPLS;" "SAS," "SPA;" "SILS," "LESS," "MISS," "SILC," "OPUS," "SIMPLE," "colon," "bowel," "small bowel," "Crohn's disease," "ulcerative colitis," and "IBD". There was no language restriction. Original articles, case reports, and technical notes were considered, whereas experimental studies in animal models, review articles, editorials, abstracts, and congress reports were excluded. Studies combining SPLS with other access routes or using a robotic approach were also excluded. Studies reporting SPLS in colorectal surgery in other conditions than IBD were excluded. Publications describing SPLS in a mixed cohort undergoing small or large bowel surgery were considered only for the reported IBD patients, whereas those patients with appendicitis, benign large, or small bowel conditions other than IBD, or with malignant colorectal disease were excluded from analysis.

2.2. Article Analysis. Data were extracted by one surgeon, experienced in both single-port and standard laparoscopic colorectal surgery. Suitable articles were divided into different study types such as case reports, case series, or case-controlled studies. The studies were assessed for the following criteria: indication, SPLS-procedure, SPLS-port used, SPLS-port position, incision length, specimen extraction site, technical equipment, previous abdominal surgery, operation time, conversions, complications, wound infections, length of hospital stay, reoperations, and readmissions.

3. Results

3.1. Study Retrieval. The primary search found 155 potentially relevant studies. After eliminating studies in which the access route to the abdomen was not per SPLS or the organ studied was not small or large bowel, 108 studies remained. Of these, 34 studies reported on SPLS in patients with IBD (Figure 1). These 34 studies met the inclusion criteria and were analyzed in detail. The selected studies were comprised of 5 case reports, 19 case series, and 10 case-controlled studies. There were no prospectively randomized studies available.

The 34 selected studies reported on 1023 SPLS patients in total, including 301 patients with IBD. Among these, there were 150 patients with Crohn's disease and 151 patients with ulcerative colitis. 8 studies described data of 10 or more IBD patients. However, since 5 groups of surgeons contributed more than one (2–4) publication to the final selection, quite a number of individuals might have been repeatedly reported, substantially reducing the actual number of reported IBD patients treated by SPLS technique. In contrast, 19 studies originated from researchers with only one publication on SPLS including IBD patients. 14 studies were restricted to SPLS in IBD patients only, whereas the other 20 studies included IBD patients in a mixed cohort of SPLS colorectal surgery. Among the 14 IBD-only studies, there were 5 case reports, 6 case series including more than one IBD patient, and 3 case-controlled studies. The selected studies were published in the years 2010 ($n = 8$) and 2011 ($n = 21$), and 2012 ($n = 5$), including those studies that were published online ahead of print.

3.2. Surgical Technique and Procedures. The reported SPLS procedures in IBD patients included 117 ileocolic resections (ileocecal resection, right hemicolectomy, and ileocolic resection for recurrent Crohn's disease), 13 sigmoid resections, 3 left hemicolectomies, 77 subtotal colectomies with end ileostomy, 3 colectomies with ileorectal anastomosis, and 52 restorative proctocolectomies with ileum-pouch reconstruction (Tables 1–3). Furthermore, SPLS small bowel resections and stricturoplasties for Crohn's disease were reported. Several studies that report on SPLS colorectal surgery in larger mixed cohorts did not specify whether the single procedures were performed in patients with IBD or in patients with other specific diagnoses [8–13]. 20 studies were restricted to a single type of resection, whereas 14 studies reported more than one kind of resection. 31 studies specified the type of port applied, of which 7 studies reported 2–4 different types of ports applied in their particular series. Applied SPLS-ports were SILS (Covidien, Norwalk, CT) in 20 studies, Triport (Olympus, Southend, UK and Advanced Surgical Concepts, Wicklow, Ireland) in 7 studies, Quadport (Olympus America, Center Valley, PA and Advanced Surgical Concepts, Wicklow, Ireland) in 3 studies, GelPort respectively GelPoint (Applied Medical, Rancho Santa Margarita, CA) in 11 studies, SSL (Ethicon Endosurgery, Cincinnati, OH) in 4 studies, and Spider surgical system (Transenterix, Durham, NC) in 1 study. 1 study inserted 3 trocars trough a single incision tightened by a purse string [14], whereas other authors placed multiple trocars through the fascia separately trough a single skin incision secured by soft tissue flaps [4, 10]. 14 studies reported the use of one or more additional trocars apart from the single port in some cases when difficulties occurred intraoperatively. The umbilicus was the most frequent site of abdominal access in SPLS procedures (20/34). Three authors used a paraumbilical access in patients with Crohn's disease [12, 15, 16]. In IBD patients undergoing a procedure with the need for an ileostomy, such as colectomy, the ileostomy site was used for insertion of the SPLS-port in 15 studies. Other authors reported the use of the left iliac fossa as access site [17], whereas four authors also reported a suprapubic insertion site for the SPLS port [8, 9, 12, 14]. 31/34 studies reported extraction of the specimen using the SPLS-port site, which had to be enlarged in several cases. Three authors also reported transanal specimen delivery in some cases [18–20] and one study reported transvaginal extraction of the excised colon [21]. Another study reported specimen delivery in a scar located at McBurney's site in a case of enterocutaneous fistula [22]. In studies reporting right-sided resections, ileocolic anastomoses were performed extracorporeally in most cases (19/22) and intracorporeally in one, while the method was

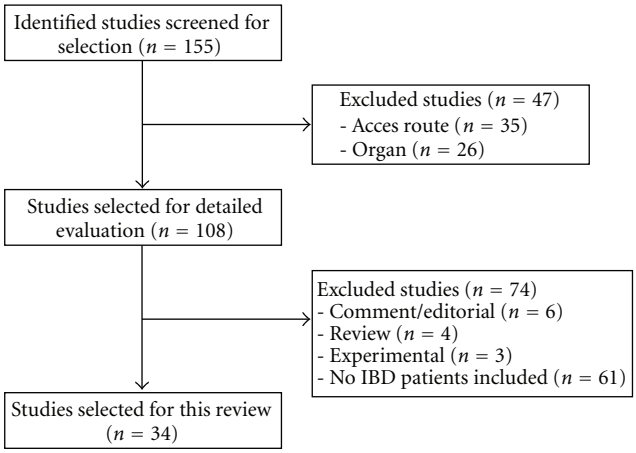

Figure 1: Single-Port Laparoscopic Surgery for inflammatory bowel disease: selection of analyzed studies.

not specified in two studies. Reconstruction after left-sided colonic resection was performed transanally (17/20) using double stapling in the vast majority of studies and was only in rare cases handsewn. 24 of 34 studies reported the use of standard laparoscopy instruments for SPLS-procedures, whereas only three authors stated the use of specially adjusted curved SPLS instruments [9, 21, 23]. The optical systems used were flexible tip cameras in 7 studies, straight 5 mm 30° optics in 15 studies, straight 10 mm 30° optics in 9 studies, straight 5 mm 0° optic in two studies, and a straight 10 mm 0° optic in 1 study. 10 studies reported routine preoperative bowel preparation for SPLS colorectal procedures. 19 studies included patients with previous abdominal surgery in SPLS procedures.

3.3. Exclusion Criteria for SPLS Procedures in IBD. The vast majority of the SPLS procedures in IBD were selected cases in a nonemergency setting. 13 studies reported exclusion criteria for SPLS procedures in patients with IBD: these were in particular: body habitus, respectively, BMI > 36 kg/m^2 [11–13, 23–27], ASA-classification >3 [23], respectively, significant associated comorbidities [24, 25, 28], hemodynamic instability [27], extensive previous abdominal surgery [23–30], previous history of peritonitis [12, 13], emergency surgery such as colonic perforation and toxic megacolon [8, 12, 13, 23, 26, 28, 30], colonic dysplasia or malignancy [11, 26], respectively, low rectal malignancy [30], and pregnancy [29].

3.4. Technique of SPLS Right Hemicolectomy. 22 studies described SPLS right hemicolectomies or ileocecal resections in patients with Crohn's disease (Table 1), including 4 case reports [8–17, 20–23, 27, 29, 31–36]. Most authors used the umbilicus for accessing the abdomen. The predominant technique was a medial-to-lateral approach with cephaled dissection of the mesentery to the duodenum with a thermal sealing device and/or an endoscopic stapler [9, 12, 23, 29, 30, 33, 36]. Subsequently, the ascending colon was mobilized past the right flexure. Other authors applied a posterior approach to mobilize the colon prior to mesenteric dissection [16, 35]. The ileum and the colon were transected either intra- [29] or extraperitoneally [9, 12, 16]. After extraction of the specimen at the SPLS port site, a side-to-side ileocolic anastomosis was performed using a stapling technique in an open extracorporeal fashion in the vast majority of the studies. Some authors created a loop ileostomy in cases of complicated Crohn's disease [34, 35].

3.5. Technique of SPLS Subtotal Colectomy. SPLS subtotal colectomies with terminal ileostomy in patients with IBD were reported in 14 studies (Table 2) [8, 11, 13, 17, 19, 20, 24–28, 30, 32, 37]. Two studies reported SPLS colectomy with ileorectal anastomosis [17, 30]. SPLS port insertion was usually accomplished at the previously marked ileostomy site [24, 25, 28, 37]. For SPLS colectomy, most authors commenced dissection at the right hemicolon, arguing this part to be the most difficult and associated with the highest risk for conversion, followed by further clockwise dissection [20, 24–26, 37]. Other authors, however, reported an early transsection of the distal sigmoid at the level of the promontory, followed by a distal to proximal dissection of the colon close to the bowel wall [28]. Dissection of the mesocolon was performed using sealing devices and endostaplers were applied for transsection of the rectum in all selected studies. Extraction of the colon occurred at the ileostomy site followed by extracorporeal transsection of the terminal ileum, which was then turned into a terminal stoma after correct orientation of the small bowel.

3.6. Technique of SPLS Restorative Proctocolectomy. SPLS restorative proctocolectomies in patients with ulcerative colitis were reported in 12 studies [4, 8, 13, 17–20, 26, 27, 38–40]. In most of these, the SPLS port was inserted at the site chosen for the loop ileostomy in the right iliac fossa [18], while other studies reported insertion of the SPLS port at the umbilicus, using the ileostomy site or drain site for additional 5–12 mm ports in some cases [20, 38]. In patients with previous subtotal colectomy, SPLS was successfully

Table 1: Perioperative results of SPLS ileoc resection-right hemicolectomy for Crohn's disease: included studies. Crohn-specific data were given wherever possible.

Author, year	Study type	Total number of SPLS patients	Disease (*n*, all SPLS patients)	SPLS ileocecal resection-Right hemicolectomy (Crohn/total)	Elective: emergency	Final incision length (cm)	Ileocolic anastomosis	Additional trocars (*n*/cases)	Conversion to open surgery	Operative time (min)	Mortality (*n*/cases)	Morbidity (*n*/cases)	Reoperations (*n*/cases)	Hospital stay (*d*)	Read missions (*n*/cases)
Adair et al., 2010 [29]	CC	17	CD: 1 Carcinoma: 11 Adenoma: 4 Other: 1	1/17	n.s.	3.8*§	Extracorporeal	2/17*	0/17*	139 ± 29.7*,§	1/17* (pulmonary embolism*)	4/17 (wound infection: 1, Ileus 2, delayed thermal bowel injury: 1)	n.s.	3.9 ± 3.7§	n.s.
Heeney et al., 2010 [31]	CR	1	CD: 1	1/1	1 : 0	2.5	Extracorporeal	0/1	0/1	86	0/1	0/1	0/1	n.s.	0/1
Kawahara et al., 2010 [14]	CR	1	CD: 1	1/1	1 : 0	4.0	Extracorporeal	0/1	0/1	130	0/1	0/1	0/1	10	n.s.
Keshava et al., 2010 [33]	CS	22	CD: 1 Carcinoma: 13 Adenoma: 5 Other: 3	1/22	21 : 1*	4.0*,#	Extracorporeal	0/22	0/22	105*,#	0/22	5/22 (wound infection: 1, ileus: 3, bleeding: 1)	2/22*	5#	n.s.
Champagne et al., 2011 [12]	CC	29	CD: 7 Carcinoma: 12 Adenoma: 4 Diverticulitis: 6	*/19	7 : 0	3.8*	Extracorporeal	1/7	0/7	134*,$	0/29	5/29* (n.s.)	0/29	3.7*	n.s.
Chaudhary et al., 2011 [34]	CC	4	CD: 4	4/4	n.s.	n.s.	n.s.	n.s.	1/4	n.s.	n.s.	n.s.	n.s.	n.s.	n.s.
Gaujoux et al., 2011 [32]	CS	13	CD: 3 Adenoma: 5 Diverticulitis: 3 Other: 2	2/6	n.s.	3.7	Extracorporeal	0/2	0/2	155§	0/2	0/2	0/2	5§	n.s.

Table 1: Continued.

Author, year	Study type	Total number of SPLS patients	Disease (*n*, all SPLS patients)	SPLS ileocecal resection-Right hemicolectomy (Crohn/total)	Elective: emergency	Final incision length (cm)	Ileocolic anastomosis	Additional trocars (*n*/cases)	Conversion to open surgery	Operative time (min)	Mortality (*n*/cases)	Morbidity (*n*/cases)	Reoperations (*n*/cases)	Hospital stay (*d*)	Read missions (*n*/cases)
Gaujoux et al., 2012 [11]	CC	25	CD: 6 UC: 2 Carcinoma: 3 Adenoma: 8 Diverticulitis: 4 Other: 2	*/13	24 : 1[$]	n.s.	Extracorporeal	1/25*	0/6	130*[#]	0/6	1/25* (acute urine retention)	0/6	6[#]	0/6
Gash et al., 2011 [17]	CS	20	CD: 4 UC: 3 Carcinoma: 8 Diverticulitis: 2 Other: 3	3/6	4 : 0	n.s.	n.s.	0/4	0/4	123[§]	0/4	5/20* (wound infection: 1, ileus: 2, anastomotic bleeding: 1, other: 1)	0/4	5.2[§]	1/20*
Geisler and Garrett, 2011 [8]	CS	102	CD: 14 UC: 51 Neoplasia: 23 Diverticulitis: 11 Other: 3	*/26	14 : 0	4.4*	Extracorporeal	18/102*	1/102*	77*	0/102*	39/102* (wound infection: 11, ileus: 12, pulmonary: 10, other: 6	0/26*	5.9*	0/26*
Karahasanoglu et al., 2011 [21]	CR	1	CD: 1	1/1	1 : 0	2.5	Intracorporeal	0/1	0/1	140	0/1	0/1	0/1	4	n.s.

Table 1: Continued.

Author, year	Study type	Total number of SPLS patients	Disease (*n*, all SPLS patients)	SPLS ileocecal resection-Right hemicolectomy (Crohn/total)	Elective: emergency	Final incision length (cm)	Ileocolic anastomosis	Additional trocars (*n*/cases)	Conversion to open surgery	Operative time (min)	Mortality (*n*/cases)	Morbidity (*n*/cases)	Reoperations (*n*/cases)	Hospital stay (*d*)	Read missions (*n*/cases)
Lee et al., 2011 [9]	CC	46	CD: 5 Neoplasia: 25 Diverticulitis: 16	*/24	n.s.	5.1*	Extracorporeal	2/24*	0/24*	122*	0/24	11/46* (wound infection: 4, anastomotic leak: 1, bleeding: 1, ileus: 1, other: 4	n.s.	4.6*	n.s.
Papaconstantinou et al., 2011 [15]	CC	29	CD: 2 Carcinoma: 15 Adenoma: 12	2/29	n.s.	4.5§	Extracorporeal	0/29*	0/29*	129*§	0/29*	6/29* (wound infection: 5, anastomotic leak: 1)	1/29*	3.4§	4/29*
Ross et al., 2011 [10]	CS	39	CD: 5 Carcinoma: 15 Adenoma: 12 Divertculitis: 7	*/30	n.s.	4.2§	n.s.	3/39*	0/5	120*	0/5	3/39* (wound infection: 1, bleeding: 2)	0/5	4.4*	0/5
Scaringi et al., 2011 [22]	CR	1	CD: 1	1/1	1 : 0	n.s.	Extracorporeal	0/1	0/1	115	0/1	0/1	n.s.	5	n.s.

Table 1: Continued.

Author, year	Study type	Total number of SPLS patients	Disease (*n*, all SPLS patients)	SPLS ileocecal resection-Right hemicolectomy (Crohn/total)	Elective: emergency	Final incision length (cm)	Ileocolic anastomosis	Additional trocars (*n*/cases)	Conversion to open surgery	Operative time (min)	Mortality (*n*/cases)	Morbidity (*n*/cases)	Reoperations (*n*/cases)	Hospital stay (*d*)	Read missions (*n*/cases)
Stewart and Messaris, 2012 [27]	CS	41	CD: 7 UC: 6 Carcinoma: 11 Adenoma: 4 Diverticultis: 10 Other: 3	4/13	29 : 12*	3.2*	Extracorporeal	1/7	5/41*	178*$	0/7	7/35* (anastomotic leak: 1, intraabd. abscess: 1, other: 5)	1/41	8.7*§	5/35*
Vestweber et al., 2011 [20]	CS	200	CD: 21 UC: 16 Diverticulitis: 120 Other: 43	21/26	200 : 0*	n.s.	Extracorporeal	n.s.$	n.s.§	n.s.§	0/200*	n.s.§	n.s.§	9*	n.s.
Wolthuis et al., 2011 [23]	CC	14	CD: 6 Carcinoma: 5 Adenoma: 1 Diverticulitis: 2	5/10	14 : 0	5*	Extracorporeal	0/6	0/6	75#*	0/5	0/5	1/5	7#*	0/6

Table 1: Continued.

Author, year	Study type	Total number of SPLS patients	Disease (n, all SPLS patients)	SPLS ileocecal resection-Right hemicolectomy (Crohn/total)	Elective: emergency	Final incision length (cm)	Ileocolic anastomosis	Additional trocars (n/cases)	Conversion to open surgery	Operative time (min)	Mortality (n/cases)	Morbidity (n/cases)	Reoperations (n/cases)	Hospital stay (d)	Read missions (n/cases)
Champagne et al., 2012 [13]	CC	165	CD: 26 UC: 13 Carcinoma: 64 Adenoma: 41 Diverticulitis: 15 Other: 6	*/117	n.s.	n.s.	n.s.	14/165*	n.s.	135*§	1/165*	42/165* (wound infection: 7, ileus: 15, delayed thermal injury: 1, bleeding: 1, cardiovascular: 4, other: 15	2/165*	4.3*§	8/165*
Rijcken et al., 2012 [16]	CC	20	CD: 20	20/20	20 : 0	3.8§	Extracorporeal	0/20	1/20	137§	0/20	4/20 (wound infection: 2, anastomotic leak: 1, intraabd. abscess: 1)	1/20	9§	1/20
Stewart and Messaris, 2012 [35]	CS	6	CD: 6	6/6	n.s.	3.5§	Extracorporeal	1/6	0/6	160§	0/6	2/6 (wound infection: 1, intraabd. abscess: 1)	0/6	4.8§	0/6

Table 1: Continued.

Author, year	Study type	Total number of SPLS patients	Disease (n, all SPLS patients)	SPLS ileocecal resection-Right hemicolectomy (Crohn/total)	Elective: emergency	Final incision length (cm)	Ileocolic anastomosis	Additional trocars (n/cases)	Conversion to open surgery	Operative time (min)	Mortality (n/cases)	Morbidity (n/cases)	Reoperations (n/cases)	Hospital stay (d)	Read missions (n/cases)
Waters et al., 2012 [36]	CS	100	CD: 5 Carcinoma: 57 Adenoma: 5	5/100	95 : 5	3.5§*	Extracorporeal	2/100*	4/100*	114§*	1/100* (bleeding)	14/100* (wound infection: 4, ileus: 4, bleeding: 3, anastomotic leak/abscess: 2, other: 1)	1/100*	5*	n.s.

* Not particularly specified for Crohn's disease
$ Not specified for SPLS ileocecal resection-right hemicolectomy
§ Mean value, # median value
n.s.: not specified
CC: case-controlled study, CR: case report, CS: case series
CD: Crohn's disease, UC: ulcerative colitis.

Table 2: Perioperative results of SPLS subtotal colectomy in IBD: included studies.

Author, year	Study type	Total number of SPLS patients	Disease (*n*, all SPLS patients)	Subtotal colectomy IBD/ reconstruction	Elective: emergency	Final incision length (cm)	Ileorectal anastomosis	Additional trocars (*n*/cases)	Conversion to open surgery	Operative time (min)	Mortality (*n*/cases)	Morbidity (*n*/cases)	Reoperations (*n*/cases)	Hospital stay (*d*)	Read missions (*n*/cases)
Cahill et al., 2010 [28]	CS	3	CD: 1 UC: 2	3/End ileostomy: 3	0 : 3	2.0	—	0/3	0/3	206[§]	0/3	1/3 (ileus: 1)	1/3	5.3[§]	0/3
Chambers et al., 2011 [19]	CS	7	CD: 0 UC: 2 Carci-noma: 3 Diverti-culitis: 1 Other: 1	1/End ileostomy: 1	n.s.	2.5	—	0/1	0/1	130	0/1	0/1	0/1	3	0/1
Fichera et al., 2011 [25]	CS	10	CD: 0 UC: 10	10/End ileostomy: 10	n.s.	n.s. (stoma site)	—	0/10	0/10	139[§]	0/10	n.s.	n.s.	5.1[§]	n.s.
Fichera et al., 2011 [37]	CC	10	CD: 0 UC: 10	10/End ileostomy: 10	n.s.	n.s. (stoma site)	—	0/10	0/10	139[§]	0/10	0/10	n.s.	5.1[§]	n.s.
Gaujoux et al., 2011 [32]	CS	13	CD: 3 Ade-noma: 5 Diverti-culitis: 3 Other: 2	1/End ileostomy: 1	n.s.	3.2[#]	—	0/1	0/1	150	0/1	0/1	n.s.	6	n.s.

Table 2: Continued.

Author, year	Study type	Total number of SPLS patients	Disease (*n*, all SPLS patients)	Subtotal colectomy IBD/ reconstruction	Elective: emergency	Final incision length (cm)	Ileorectal anastomosis	Additional trocars (*n*/cases)	Conversion to open surgery	Operative time (min)	Mortality (*n*/cases)	Morbidity (*n*/cases)	Reoperations (*n*/cases)	Hospital stay (*d*)	Read missions (*n*/cases)
Gaujoux et al., 2012 [11]	CC	25	CD: 6 UC: 2 Carci-noma: 3 Ade-noma: 8 Diverti-culitis: 4 Other: 2	2/End ileostomy: 2	24 : 1*	n.s.	—	0/2	0/2	130#*	0/2	1/25* (acute urine retention)	0/2	6#*	0/2
Gash et al., 2011 [17]	CS	20	CD: 4 UC: 3 Carci-noma: 8 Diverti-culitis: 2 Other: 3	2/End ileostomy: 1 Ileo-rectal Anastomis: 1	2 : 0	n.s.	transanal	0/2	0/2	120§	0/2	5/20* (wound infection: 1, ileus: 2, anasto-motic bleeding: 1, other: 1)	0/2	2§	1720*

Table 2: Continued.

Author, year	Study type	Total number of SPLS patients	Disease (*n*, all SPLS patients)	Subtotal colectomy IBD/ reconstruction	Elective: emergency	Final incision length (cm)	Ileorectal anastomosis	Additional trocars (*n*/cases)	Conversion to open surgery	Operative time (min)	Mortality (*n*/cases)	Morbidity (*n*/cases)	Reoperations (*n*/cases)	Hospital stay (*d*)	Read missions (*n*/cases)
Geisler and Garrett, 2011 [8]	CS	102	CD: 14 UC: 51 Neoplasia: 23 Diverticulitis: 11 Other: 3	19/End ileostomy: 19	19 : 0	n.s. (stoma site)	—	0/19	0/19	99*	0/19	39/102* (wound infection: 11, ileus: 12, pulmonary: 10, other: 6	0/19	5, 9*	0/19
Leblanc et al., 2011 [26]	CS	4	CD: 1 UC: 1	2/End ileostomy: 2	2 : 0	n.s. (stoma site)	—	0/2	0/2	162§	0/2	1/4* (ileus: 1)	0/2	4.5*	n.s.
Stewart and Messaris, 2012 [27]	CS	41	CD: 7 UC: 6 Carcinoma: 11 Adenoma: 4 Diverticultis: 10 Other: 3	6/End ileostomy: 6	29 : 12*	n.s. (stoma site)	—	0/6	1/6	155§*	0/6	7/35* (anastomotic leak: 1, intraabd. abscess: 1, other: 5)	0/6	4.2*	0/6
Van den Boezem and Sietses, 2011 [30]	CS	50	CD: 0 UC: 4 Carcinoma: 31 Adenoma: 7 Diverticulitis: 8	4/End ileostomy: 2 Ileo-rectal anastomosis: 2	4 : 0	n.s.	transanal	4/50*	0/4	130§*	0/4	10/50* (anastomotic leakage: 1, wound infections: 4, incisional hernia: 2, ileus: 2, other: 1)	0/4	6#*	n.s.

Table 2: Continued.

Author, year	Study type	Total number of SPLS patients	Disease (*n*, all SPLS patients)	Subtotal colectomy IBD/ reconstruction	Elective: emergency	Final incision length (cm)	Ileorectal anastomosis	Additional trocars (*n*/cases)	Conversion to open surgery	Operative time (min)	Mortality (*n*/cases)	Morbidity (*n*/cases)	Reoperations (*n*/cases)	Hospital stay (*d*)	Read missions (*n*/cases)
Vestweber et al., 2011 [20]	CS	200	CD: 21 UC: 16 Diverti-culitis: 120 Other: 43	10/End ileostomy: 10	10 : 0	n.s.	—	n.s.*	n.s.*	n.s.*	0/10	n.s.*	n.s.§	9*	n.s.
Champagne et al., 2012 [13]	CC	165	CD: 26 UC: 13 Carci-noma: 64 Ade-noma: 41 Diverti-culitis: 15 Other: 6	8/End ileostomy: 8	n.s.	n.s. (stoma site)	—	14/165*	n.s.	135*§	1/165*	42/165* (wound infection: 7, ileus: 15, delayed thermal injury: 1, bleeding: 1, cardio-vascular: 4, other: 15	2/165*	4.3*§	8/165*
Fichera and Zoccoli, 2012 [24]	CS	9	UC: 9	9/End ileostomy: 9	n.s.	n.s. (stoma site)	—	0/9	0/9	142§	0/9	0/9	0/9	5.2§	n.s.

* Not particularly specified for subtotal colectomy
§ Mean value, # median value
n.s.: not specified
CC: case-controlled study, CR: case report, CS: case series
CD: Crohn's disease, UC: ulcerative colitis.

performed using the stoma site after prior mobilization of the terminal stoma [18]. A medial to lateral approach was performed in most studies, and most authors began dissecting at the right hemicolon [18, 20, 38]. The entire colon was divided using sealing devices and divided at the level of the pelvic floor with an endo stapler in an anterior-posterior direction, introduced via the SPLS port. Extraction of the colon was carried out via the port site or transanally [18, 20]. The ileal J-pouch was constructed extracorporeally by linear staplers with a limb length of 15–20 cm and reinserted into the abdomen via the port site. Pouch-anal anastomosis was performed intracorporeally by double stapling [18, 38] or, in cases of proctomucosectomy, handsewn transanally [18, 20]. Virtually all authors reported a diverting loop ileostomy (Table 3).

3.7. Surgical Outcomes. Three main procedures in IBD were analyzed separately. Results from the literature for SPLS ileocecal resections and SPLS right hemicolectomies in Crohn's disease are depicted in Table 1. Results for SPLS subtotal colectomies for ulcerative colitis and Crohn's disease are shown in Table 2, and results for SPLS restorative proctocolectomies in ulcerative colitis are demonstrated in Table 3. It is noteworthy that authors reporting on mixed cohorts of different procedures in large series of patients often do not give data for specific procedures. Specific data were presented wherever possible and mixed data are indicated. Reported mean or median operation times for ileocolic resections varied from 77 to 155 min, for subtotal colectomy with end ileostomy from 112 to 206 min, and for reconstructive proctocolectomy with ileal pouch from 153 to 300 min. Reported median incision length was 35 (20–55) mm. Several authors reported widening the initial incision for extraction of the specimen in Crohn's disease patients with enlarged mesentery.

For all SPLS procedures in IBD, cases of conversions to multiport surgery were reported in 14 studies and cases of conversion to open surgery were reported in 10 studies. Reasons for conversions were medically related issues such as intraoperative bleeding [20], firm adhesions and previous surgery [12, 20, 27, 29], fistulizing disease (interenteric fistula, conglomerate tumors, or masses [8, 16, 20], friability of the inflamed mesentery [12], obesity [8, 30], or technically related aspects such as gas leak [30], instable port placement [17], inappropriate traction [8, 12, 29], difficulties in flexure mobilization [9], and time constraints [17].

Complications in SPLS procedures in IBD were reported in 22 studies. These complications included anastomotic leakage, bleeding, ileus, bowel obstruction, intraabdominal abscesses, wound infections, delayed thermal injury to bowel, peristomal emphysema, ejaculation dysfunction, acute urine retention, incisional hernia, stenoses, and cardiovascular, pulmonary, and thromboembolic events (Tables 1–3). Reoperations due to complications were stated in 8 studies. Mortality was reported in 4 studies [8, 12, 29, 36] and specified in 3 of them. One case of mortality was reported after substantial intraoperative bleeding during externalization of the colon for an extracorporeal anastomosis after right hemicolectomy [36]. Another case of mortality due to pulmonary embolism was found in one study, although it remains unclear whether this was a patient with IBD [29]. A third case of mortality due to cardiopulmonary failure was reported in a patient undergoing SPLS sigmoidectomy for complicated diverticulitis [8].

4. Discussion

The current review of the literature shows that single-port laparoscopic surgery has gained entrance into the surgical treatment of patients with inflammatory bowel disease. The number of publications on the subject is growing at a fast pace: whereas first case reports arose in 2010, larger case series from specialized centers are now available that demonstrate the feasibility of SPLS in IBD. Additionally, some comparative studies have been published lately, mostly comparing SPLS to historical cohorts of patients with traditional multiport laparoscopic surgery. Evidence from prospectively designed, randomized studies concerning SPLS in IBD is not presently available. Therefore, benefits of SPLS in IBD were not demonstrated so far. Most of the currently available studies on the application of SPLS in colorectal surgery which include IBD patients are not restricted to single procedures in single pathological conditions, but rather describe mixed cohorts. As a consequence, it is not yet possible to perform a proper meta-analysis in order to evaluate the techniques in detail. However, it appears that nearly all IBD-related procedures that can be performed by standard multiport laparoscopy have now been performed in single-port technique as well. Although this has mostly been done by specialized surgeons, it demonstrates the general feasibility of SPLS in IBD. The SPLS procedures include stricturoplasties, small bowel resections, ileocolic resections, sigmoid resections, subtotal colectomies with terminal ileostomies, and reconstructive proctocolectomies with ileal pouches. SPLS proctocolectomy for ulcerative colitis has been reported in minors, too [40]. However, from the available literature, it becomes apparent that most authors applied SPLS predominantly in selected patients, and therefore SPLS is currently still far from becoming a routine procedure in IBD patients. Emergency cases were excluded from SPLS in the vast majority of publications [16, 24–26, 30]. From a technical point of view, most authors favor regular laparoscopic instruments, although a special 5 mm optic with a flexible tip seems to be rewarding in SPLS colorectal procedures [8]. Most authors applied commercially available SPLS ports, which were inserted through the umbilicus, paraumbilically, at the ileostomy site, or suprapubically depending on the specific procedure and the surgeon's preference. SPLS was performed for IBD in patients with prior (limited) abdominal surgery, but also in patients with recurrent Crohn's disease [14, 34, 35] or enterocutaneous fistula and abscesses [22, 35]. SPLS—in experienced hands—may therefore be a feasible approach even in complex patients. Limitations of SPLS in IBD patients appear to be similar to those encountered in standard multitrocar laparoscopy. Reasons for conversions were stated

Table 3: Perioperative results of restorative proctocolectomy (IPAA) in ulcerative colitis: included studies.

Author, year	Study type	Total number of SPLS patients	Disease (*n*, all SPLS patients)	SPLS-IPAA	Elective: emergency	Final incision length (cm)	Anastomosis	Loop ileostomy	Additional trocars (*n*/cases)	Conversion to open surgery	Operative time (min)	Mortality (*n*/cases)	Morbidity (*n*/cases)	Reoperations (*n*/cases)	Hospital stay (*d*)	Read missions (*n*/cases)
Nagpal et al., 2010 [38]	CR	1	UC: 1	1	1 : 0	5.5	Stapler	1/1	1/1	0/1	256	0/1	n.s.	0/1	7	n.s.
Podolsky and Curcillo II, 2010 [4]	CS	13	UC: 1 Carci-noma: 8 Other: 4	1	n.s.	n.s.	n.s.	n.s.	n.s.	n.s.	300	0/13	3/13* (wound infection: 1, incisional hernia: 2)	n.s.	5	n.s.
Chambers et al., 2011 [19]	CS	7	CD: 0 UC: 2 Carci-noma: 3 Diverti-culitis: 1 Other: 1	1	1 : 0	n.s.	n.s.	1/1	0/1	0/1	195	0/1	0/1	0/1	4	n.s.
Gash et al., 2011 [18]	CS	10	UC: 10	10	n.s.	2.5 (stoma site)	Stapler: 8 Hand-sewn: 2	9/10	0/10	0/10	185#	0/10	2/10 (other: 2)	0/10	3#	0/10
Gash et al., 2011 [17]	CS	20	CD: 4 UC: 3 Carci-noma: 8 Diverti-culitis: 2 Other: 3	2	n.s.	n.s. (stoma site)	Stapler: 2	n.s.	1/2	0/2	177§	0/2	5/20* (wound infection: 1, ileus: 2, anasto-motic bleeding: 1, other: 1)	0/2	3§	1/20*
Geisler and Garrett, 2011 [8]	CS	102	CD: 14 UC: 51 Neopla-sia: 23 Diverti-culitis: 11 Other: 3	20	20 : 0	n.s. (stoma site)	Stapler: 20	20/20	15/20	1/20	160	0/20	39/102* (wound infection: 11, ileus: 12, pul-monary: 10, other: 6	0/20	5, 9*	0/20
Geisler et al., 2011 [39]	CS	5	UC: 4 FAP: 1	5	4 : 0	n.s. (stoma site)	Stapler	4/4	0/4	0/4	175§	0/4	2/5* (ileus: 2)	0/4	4#*	2/4

Table 3: Continued.

Author, year	Study type	Total number of SPLS patients	Disease (*n*, all SPLS patients)	SPLS-IPAA	Elective: emergency	Final incision length (cm)	Anastomosis	Loop ileostomy	Additional trocars (*n*/cases)	Conversion to open surgery	Operative time (min)	Mortality (*n*/cases)	Morbidity (*n*/cases)	Reoperations (*n*/cases)	Hospital stay (*d*)	Read missions (*n*/cases)
Leblanc et al., 2011 [26]	CS	4	CD: 1 UC: 2 FAP: 1	2	1 : 0	n.s. (stoma site)	Stapler	1/1	0/1	0/1	261*	0/1	0/1	0/1	4.5#*	n.s.
Mattioli et al., 2011 [40]	CS	5	UC: 5	5	n.s.	n.s. (stoma site)	Stapler	5/5	n.s.	n.s.	n.s.	0/1	n.s.*	0/5	n.s.*	n.s.
Stewart and Messaris, 2012 [27]	CS	41	CD: 7 UC: 6 Carcinoma: 11 Adenoma: 4 Diverticultis: 10 Other: 3	2	n.s.	n.s. (stoma site)	Stapler	n.s.	0/2	0/2	155$*	0/2	7/35* (anastomotic leak: 1, intraabd. abscess: 1, other: 5)	0/2	4.2*	0/2
Vestweber et al., 2011 [20]	CS	200	CD: 21 UC: 16 Diverticulitis: 120 Other: 43	6	6 : 0	n.s.	Hand-sewn	n.s.*	n.s.*	n.s.*	n.s.*	0/6	n.s.*	n.s.*	n.s*	n.s.*

Table 3: Continued.

Author, year	Study type	Total number of SPLS patients	Disease (*n*, all SPLS patients)	SPLS-IPAA	Elective: emergency	Final incision length (cm)	Anastomosis	Loop ileostomy	Additional trocars (*n*/cases)	Conversion to open surgery	Operative time (min)	Mortality (*n*/cases)	Morbidity (*n*/cases)	Reoperations (*n*/cases)	Hospital stay (*d*)	Read missions (*n*/cases)
Champagne et al., 2012 [13]	CC	165	CD: 26 UC: 13 Carcinoma: 64 Adenoma: 41 Diverticulitis: 15 Other: 6	8	n.s.	n.s. (stoma site)	n.s.	n.s.	14/165*	n.s.	135*§	1/165*	42/165* (wound infection: 7, ileus: 15, delayed thermal injury: 1, bleeding: 1, cardiovascular: 4, other: 15	2/165*	4.3*§	8/165*

* Not particularly specified for SPLS-IPAA in UC
§ Mean value, # median value
n.s.: not specified
CC: case-controlled study, CR: case report, CS: case series
CD: Crohn's disease, UC: ulcerative colitis, FAP: familial adenomatous polyposis
IPAA: Ileopouch-anal anastomosis.

as occurrence of intraoperative bleeding, bowel injury, firm adhesions, intraenteral fistula, and masses. These reasons were also stated in the literature for IBD patients undergoing conversion during standard laparoscopic resections [41–45]. In terms of patient safety, SPLS for IBD offers a risk profile similar to standard multitrocar laparoscopic surgery. Postoperative complications reported include anastomotic leakage, bleeding, bowel obstruction, and intraabdominal abscesses. These are typical complications of colorectal surgery in IBD as seen in both standard multitrocar laparoscopic and open surgery [46, 47]. In contrast, delayed thermal injury as reported in two studies indicates inappropriate instrument handling in SPLS. Wound infections at the site of the SPLS port were reported by several authors. A reduction of the frequency of wound infections by reducing the number of incisions using SPLS is not likely to occur. The incidence of late complications such as incisional hernia should be objectified in future studies on the long-term outcome of SPLS patients. Furthermore, IBD-specific long-term complications such as recurrence of stenoses in Crohn's disease or pouchitis in ulcerative colitis are not likely to be influenced by the technique used for access to the abdomen in the primary operation. A reduction of peritoneal adhesions and consecutive bowel obstruction was postulated to be achieved by SPLS, but there are no long-term studies available so far which confirm this hypothesis. Surgery in patients with IBD does not differ substantially from surgery for other conditions, but the patients undergoing these procedures are often complex and challenging due to a previous history of the disease, nutritional status, septic manifestations such as fistulas and abscesses, and/or immunosuppresive drugs. In the present review of the literature, no specific data on the patient's exposure to immunosuppressive drugs could be retrieved. Some of the selected studies, however, reported preoperative administration of azathioprine, steroids, or biologicals [8, 16, 24, 25, 28, 35, 37], indicating that the application of these drugs does not represent a contraindication for SPLS. In patients undergoing restorative proctocolectomy for medically refractory ulcerative colitis, a three-stage SPLS procedure was advocated when patients received more than 20 mg of prednisolone or anti-TNF-α agents such as infliximab or adalimumab [8]. In some studies, benefits of SPLS in colorectal procedures such as shorter hospital stays [11, 15], reduction of estimated blood loss [13], reduced time to flatus and bowel movement [9], or better cosmetic results [9] were claimed, but results from these studies appear to be limited by inhomogeneous cohorts, small sample size with low statistical power, or possible selection bias. A small randomized prospective study including 16 SPLS patients and 16 patients with standard laparoscopic surgery in colon cancer found no differences in terms of morbidity and operation time [48]. In the available literature on SPLS in IBD, potential benefits have yet to be demonstrated.

In conclusion, the present review of the literature shows the feasibility of SPLS in patients with IBD in selected cases. The patient selection however depends on the surgeon's experience and the patient's condition. Currently, the literature on SPLS techniques in IBD is shifting from case reports on single applications to reports on larger series. At present there are no technical standards for SPLS procedures in IBD. Evidence from prospectively randomized trials is required to clarify whether there is a true benefit compared to standard laparoscopic techniques.

Acknowledgment

E. Rijcken, N. Senninger, and M. Bruewer received lecture fees and travel grants from Covidien.

References

[1] P. Bucher, F. Pugin, and P. Morel, "Single port access laparoscopic right hemicolectomy," *International Journal of Colorectal Disease*, vol. 23, no. 10, pp. 1013–1016, 2008.

[2] F. H. Remzi, H. T. Kirat, J. H. Kaouk, and D. P. Geisler, "Single-port laparoscopy in colorectal surgery," *Colorectal Disease*, vol. 10, no. 8, pp. 823–826, 2008.

[3] J. Leroy, R. A. Cahill, M. Asakuma, B. Dallemagne, and J. Marescaux, "Single-access laparoscopic sigmoidectomy as definitive surgical management of prior diverticulitis in a human patient," *Archives of Surgery*, vol. 144, no. 2, pp. 173–179, 2009.

[4] E. R. Podolsky and P. G. Curcillo II, "Single port access (SPA) surgery-a 24-month experience," *Journal of Gastrointestinal Surgery*, vol. 14, no. 5, pp. 759–767, 2010.

[5] F. Leblanc, B. J. Champagne, K. M. Augestad et al., "Single incision laparoscopic colectomy: technical aspects, feasibility, and expected benefits," *Diagnostic and Therapeutic Endoscopy*, vol. 2010, Article ID 913216, 6 pages, 2010.

[6] M. Diana, P. Dhumane, R. A. Cahill, N. Mortensen, J. Leroy, and J. Marescaux, "Minimal invasive single-site surgery in colorectal procedures: current state of the art," *Journal of Minimal Access Surgery*, vol. 7, no. 1, pp. 52–60, 2011.

[7] T. Makino, J. W. Milsom, and S. W. Lee, "Feasibility and safety of single-incision laparoscopic colectomy: a systematic review," *Annals of Surgery*, vol. 255, no. 4, pp. 667–676, 2012.

[8] D. Geisler and T. Garrett, "Single incision laparoscopic colorectal surgery: a single surgeon experience of 102 consecutive cases," *Techniques in Coloproctology*, vol. 15, no. 4, pp. 397–401, 2011.

[9] S. W. Lee, J. W. Milsom, and G. M. Nash, "Single-incision versus multiport laparoscopic right and hand-assisted left colectomy: a case-matched comparison," *Diseases of the Colon and Rectum*, vol. 54, no. 11, pp. 1355–1361, 2011.

[10] H. Ross, S. Steele, M. Whiteford et al., "Early multi-institution experience with single-incision laparoscopic colectomy," *Diseases of the Colon and Rectum*, vol. 54, no. 2, pp. 187–192, 2011.

[11] S. Gaujoux, L. Maggiori, F. Bretagnol, M. Ferron, and Y. Panis, "Safety, feasibility, and short-term outcomes of single port access colorectal surgery: a single institutional case-matched study," *Journal of Gastrointestinal Surgery*, vol. 16, no. 3, pp. 629–634, 2012.

[12] B. J. Champagne, E. C. Lee, F. Leblanc, S. L. Stein, and C. P. Delaney, "Single-incision vs straight laparoscopic segmental colectomy: a case-controlled study," *Diseases of the Colon and Rectum*, vol. 54, no. 2, pp. 183–186, 2011.

[13] B. J. Champagne, H. T. Papaconstantinou, S. S. Parmar et al., "Single-incision versus standard multiport laparoscopic colectomy: a multicenter, case-controlled comparison," *Annals of Surgery*, vol. 255, no. 1, pp. 66–69, 2012.

[14] H. Kawahara, K. Watanabe, T. Ushigome, R. Noaki, S. Kobayashi, and K. Yanaga, "Single-incision laparoscopic right colectomy for recurrent Crohn's disease," *Hepato-Gastroenterology*, vol. 57, no. 102-103, pp. 1170–1172, 2010.

[15] H. T. Papaconstantinou, N. Sharp, and J. S. Thomas, "Single-incision laparoscopic right colectomy: a case-matched comparison with standard laparoscopic and hand-assisted laparoscopic techniques," *Journal of the American College of Surgeons*, vol. 213, no. 1, pp. 72–80, 2011.

[16] E. Rijcken, R. Mennigen, I. Argyris, N. Senninger, and M. Bruewer, "Single-incision laparoscopic surgery for ileocolic resection in Crohn's disease," *Diseases of the Colon and Rectum*, vol. 55, no. 2, pp. 140–146, 2012.

[17] K. J. Gash, A. C. Goede, W. Chambers, G. L. Greenslade, and A. R. Dixon, "Laparoendoscopic single-site surgery is feasible in complex colorectal resections and could enable day case colectomy," *Surgical Endoscopy*, vol. 25, no. 3, pp. 835–840, 2011.

[18] K. J. Gash, A. C. Goede, B. Kaldowski, B. Vestweber, and A. R. Dixon, "Single incision laparoscopic (SILS) restorative proctocolectomy with ileal pouch-anal anastomosis," *Surgical Endoscopy and Other Interventional Techniques*, vol. 25, no. 12, pp. 3877–3880, 2011.

[19] W. M. Chambers, M. Bicsak, M. Lamparelli, and A. R. Dixon, "Single-incision laparoscopic surgery (SILS) in complex colorectal surgery: a technique offering potential and not just cosmesis," *Colorectal Disease*, vol. 13, no. 4, pp. 393–398, 2011.

[20] B. Vestweber, E. Straub, B. Kaldowski et al., "Single-port colonic surgery: techniques and indications," *Der Chirurg*, vol. 82, no. 5, pp. 411–418, 2011.

[21] T. Karahasanoglu, I. Hamzaoglu, E. Aytac, and B. Baca, "Transvaginal assisted totally laparoscopic single-port right colectomy," *Journal of Laparoendoscopic and Advanced Surgical Techniques*, vol. 21, no. 3, pp. 255–257, 2011.

[22] S. Scaringi, F. Giudici, G. Liscia, C. Cenci, and F. Tonelli, "Single-port laparoscopic access for Crohn's disease complicated by enterocutaneous fistula," *Inflammatory Bowel Diseases*, vol. 17, no. 2, pp. E6–E7, 2011.

[23] A. M. Wolthuis, F. Penninckx, S. Fieuws, and A. D'Hoore, "Outcomes for case-matched single port colectomy are comparable with conventional laparoscopic colectomy," *Colorectal Disease*, vol. 14, no. 5, pp. 634–641, 2012.

[24] A. Fichera and M. Zoccali, "Single-incision laparoscopic total abdominal colectomy for refractory ulcerative colitis," *Surgical Endoscopy*, vol. 26, no. 3, pp. 862–868, 2012.

[25] A. Fichera, M. Zoccali, C. Felice, and D. T. Rubin, "Total abdominal colectomy for refractory ulcerative colitis. Surgical treatment in evolution," *Journal of Gastrointestinal Surgery*, vol. 15, no. 11, pp. 1909–1916, 2011.

[26] F. Leblanc, R. Makhija, B. J. Champagne, and C. P. Delaney, "Single incision laparoscopic total colectomy and proctocolectomy for benign disease: initial experience," *Colorectal Disease*, vol. 13, no. 11, pp. 1290–1293, 2011.

[27] D. B. Stewart and E. Messaris, "Outcomes for consecutive patients undergoing single-site laparoscopic colorectal surgery," *Journal of Gastrointestinal Surgery*, vol. 16, no. 4, pp. 849–856, 2012.

[28] R. A. Cahill, I. Lindsey, O. Jones, R. Guy, N. Mortensen, and C. Cunningham, "Single-port laparoscopic total colectomy for medically uncontrolled colitis," *Diseases of the Colon and Rectum*, vol. 53, no. 8, pp. 1143–1147, 2010.

[29] J. Adair, M. A. Gromski, R. B. Lim, and D. Nagle, "Single-incision laparoscopic right colectomy: experience with 17 consecutive cases and comparison with multiport laparoscopic right colectomy," *Diseases of the Colon and Rectum*, vol. 53, no. 11, pp. 1549–1554, 2010.

[30] P. B. van den Boezem and C. Sietses, "Single-incision laparoscopic colorectal surgery, experience with 50 consecutive cases," *Journal of Gastrointestinal Surgery*, vol. 15, no. 11, pp. 1989–1994, 2011.

[31] A. Heeney, D. B. O'Connor, S. Martin, and D. C. Winter, "Single-port access laparoscopic surgery for complex Crohn's disease," *Inflammatory Bowel Diseases*, vol. 16, no. 8, pp. 1273–1274, 2010.

[32] S. Gaujoux, F. Bretagnol, M. Ferron, and Y. Panis, "Single-incision laparoscopic colonic surgery," *Colorectal Disease*, vol. 13, no. 9, pp. 1066–1071, 2011.

[33] A. Keshava, C. J. Young, and S. MacKenzie, "Single-incision laparoscopic right hemicolectomy," *British Journal of Surgery*, vol. 97, no. 12, pp. 1881–1883, 2010.

[34] B. Chaudhary, D. Glancy, and A. R. Dixon, "Laparoscopic surgery for recurrent ileocolic Crohn's disease is as safe and effective as primary resection," *Colorectal Disease*, vol. 13, no. 12, pp. 1413–1416, 2011.

[35] D. B. Stewart and E. Messaris, "Early experience with single-site laparoscopic surgery for complicated ileocolic Crohn's disease at a tertiary-referral center," *Surgical Endoscopy*, vol. 26, no. 3, pp. 777–782, 2012.

[36] J. A. Waters, B. M. Rapp, M. J. Guzman et al., "Single-port laparoscopic right hemicolectomy: the first 100 resections," *Diseases of the Colon and Rectum*, vol. 55, no. 2, pp. 134–139, 2012.

[37] A. Fichera, M. Zoccali, and R. Gullo, "Single incision ("scarless") laparoscopic total abdominal colectomy with end ileostomy for ulcerative colitis," *Journal of Gastrointestinal Surgery*, vol. 15, no. 7, pp. 1247–1251, 2011.

[38] A. P. Nagpal, H. Soni, and S. Haribhakti, "Hybrid single-incision laparoscopic restorative proctocolectomy with ileal pouch anal anastomosis for ulcerative colitis," *Indian Journal of Surgery*, vol. 72, no. 5, pp. 400–403, 2010.

[39] D. P. Geisler, H. T. Kirat, and F. H. Remzi, "Single-port laparoscopic total proctocolectomy with ileal pouch-anal anastomosis: initial operative experience," *Surgical Endoscopy*, vol. 25, no. 7, pp. 2175–2178, 2011.

[40] G. Mattioli, E. Guida, A. Pini-Prato et al., "Technical considerations in children undergoing laparoscopic ileal-J-pouch anorectal anastomosis for ulcerative colitis," *Pediatric Surgery International*, vol. 28, no. 4, pp. 351–356, 2012.

[41] P. Reissman, B. A. Salky, J. Pfeifer, M. Edye, D. G. Jagelman, and S. D. Wexner, "Laparoscopic surgery in the management of inflammatory bowel disease," *American Journal of Surgery*, vol. 171, no. 1, pp. 47–50, 1996.

[42] J. W. Milsom, K. A. Hammerhofer, B. Böhm, P. Marcello, P. Elson, and V. W. Fazio, "Prospective, randomized trial comparing laparoscopic vs. conventional surgery for refractory ileocolic Crohn's disease," *Diseases of the Colon and Rectum*, vol. 44, no. 1, pp. 1–8, 2001.

[43] K. Moorthy, T. Shaul, and R. J. Foley, "Factors that predict conversion in patients undergoing laparoscopic surgery for Crohn's disease," *American Journal of Surgery*, vol. 187, no. 1, pp. 47–51, 2004.

[44] K. Okabayashi, H. Hasegawa, M. Watanabe et al., "Indications for laparoscopic surgery for Crohn's disease using the Vienna classification," *Colorectal Disease*, vol. 9, no. 9, pp. 825–829, 2007.

[45] M. Soop, D. W. Larson, K. Malireddy, R. R. Cima, T. M. Young-Fadok, and E. J. Dozois, "Safety, feasibility, and short-term outcomes of laparoscopically assisted primary ileocolic resection for Crohn's disease," *Surgical Endoscopy and Other Interventional Techniques*, vol. 23, no. 8, pp. 1876–1881, 2009.

[46] J. J. Y. Tan and J. J. Tjandra, "Laparoscopic surgery for Crohn's disease: a meta-analysis," *Diseases of the Colon and Rectum*, vol. 50, no. 5, pp. 576–585, 2007.

[47] S. Maartense, M. S. Dunker, J. F. M. Slors et al., "Laparoscopic-assisted versus open ileocolic resection for Crohn's disease: a randomized trial," *Annals of Surgery*, vol. 243, no. 2, pp. 143–149, 2006.

[48] C. G. Huscher, A. Mingoli, and G. Sgarzini, "Standard laparoscopic versus single-incision laparoscopic colectomy for cancer," *The American Journal of Surgery*. In press.