BioMed Research International

Endoscopic/External Approaches in Otorhinolaryngology and Head and Neck Surgery

Guest Editors: Jan Betka, Karl Hörmann, Manuel Bernal-Sprekelsen, and Jan Plzák

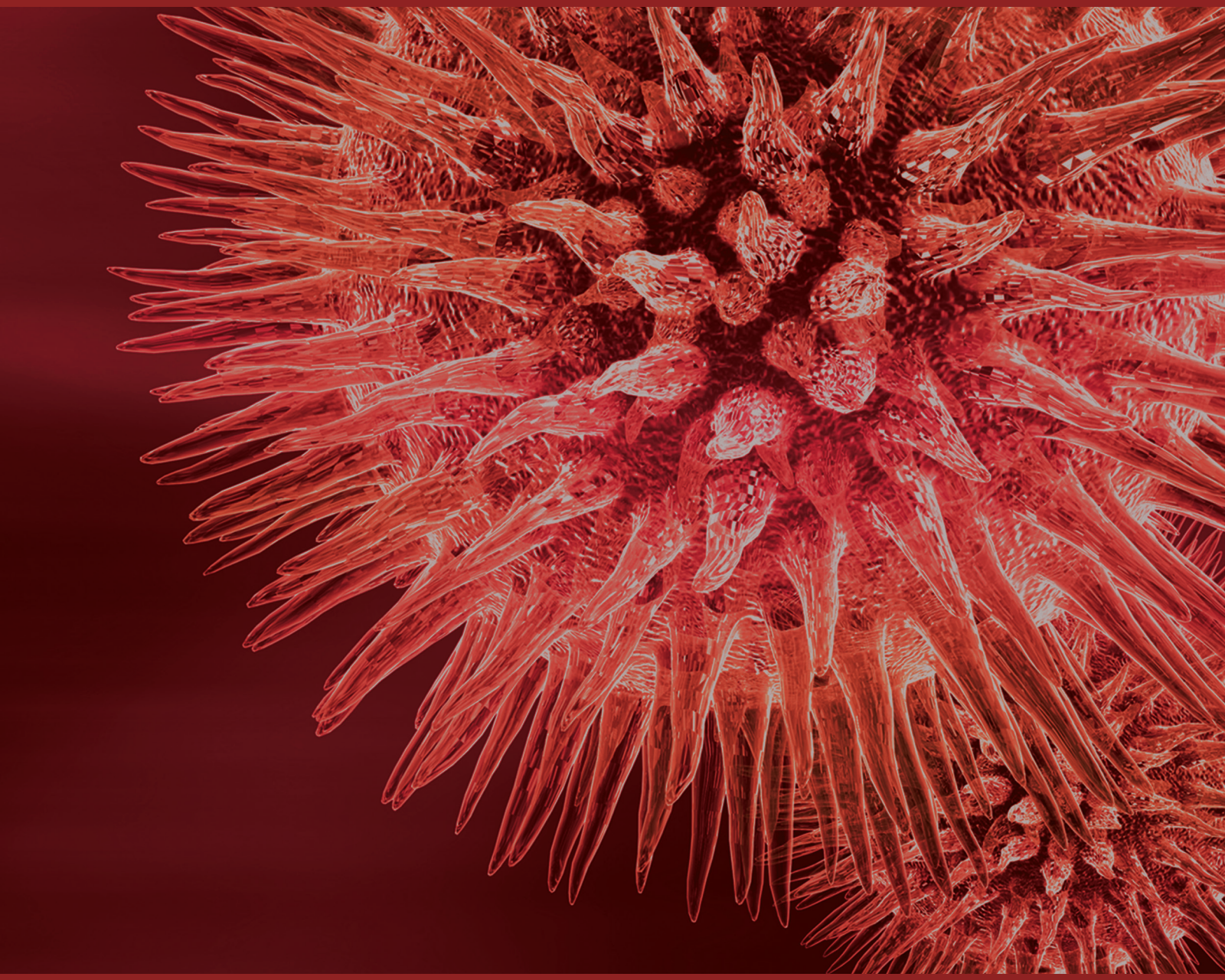

Endoscopic/External Approaches in Otorhinolaryngology and Head and Neck Surgery

BioMed Research International

Endoscopic/External Approaches in Otorhinolaryngology and Head and Neck Surgery

Guest Editors: Jan Betka, Karl Hörmann, Manuel Bernal-Sprekelsen, and Jan Plzák

Contents

Hindawi Publishing Corporation
BioMed Research International
Volume 2015, Article ID 958453, 2 pages
http://dx.doi.org/10.1155/2015/958453

Editorial

Endoscopic/External Approaches in Otorhinolaryngology and Head and Neck Surgery

Jan Betka,[1] Karl Hörmann,[2] Manuel Bernal-Sprekelsen,[3] and Jan Plzák[1]

[1] *Department of Otorhinolaryngology and Head and Neck Surgery, 1st Faculty of Medicine, University Hospital Motol, V Uvalu 84, 150 06 Prague 5, Czech Republic*
[2] *Department of Otorhinolaryngology and Head and Neck Surgery, University Hospital Mannheim, Theodor-Kutzer-Ufer 1-3, 68167 Mannheim, Germany*
[3] *Department of Otorhinolaryngology and Head and Neck Surgery, University of Barcelona Medical School, Carrer Villarroel 170, 08036 Barcelona, Spain*

Correspondence should be addressed to Jan Betka; jan.betka@fnmotol.cz

Received 15 September 2014; Accepted 15 September 2014

Minimally invasive surgery has successfully entered the field of our subspecialty during the last decades. Endoscopic approach is nowadays well established in surgery of chronic rhinosinusitis (FESS, functional endoscopic sinus surgery) as well as in treatment of benign sinonasal diseases. Having gained experience with the endoscopic reconstruction of the anterior skull base [1] now an increasing amount of sinonasal malignancy is being treated endoscopically. Recently, the 4-hand expanded endoscopic approach through the nose to address tumors arising endocranially, with or without skull base involvement, has become extended, proving the nose to be a perfect access for tumors localized centrally and thus avoiding external approaches associated with higher morbidity [2].

Endoscopic laser microsurgery is widely used for benign and malignant laryngeal diseases. Initially, only early glottic or supraglottic tumors were chosen. However, more recently, also locally advanced tumors have been approached transorally with the CO_2 laser [3, 4]. Also, tumors in the hypopharynx have been treated successfully, preserving the functional larynx and avoiding tracheotomies [5]. Compared to external approaches, transoral laser microsurgery has clearly shown reduced morbidity [6]; however, even in oncologically expert hands, a learning curve has to be expected [7].

Because of tendency to minimize invasiveness of surgery the endoscopy expands into other fields of otorhinolaryngology and head and neck surgery: neck soft tissue surgery (thyroid and parathyroid surgery), salivary gland surgery, skull base surgery, and so forth. But on the other side there are many examples when classical external approach is irreplaceable. There are even situations when both endoscopic and external approaches work effectively together.

The variety of indications and conditions that are now amenable to endoscopic approach underscores the substantial progress that has been made with endoscopic procedures in otorhinolaryngology, head and neck surgery. Just a few years ago, many of these cases still necessitated an external surgical approach.

Safe and effective endoscopy requires the use of a suitable endoscope (rigid, flexible, straight/angled, adjustable, equipped with camera/microscope, etc.) for adequate visualization of the operative field. An attached camera enables the assistant, nurse, and medical visitors to view the operative field and allows the procedure to be videotaped.

The inside diameter of the endoscope should conform to the size of the lumen in the patient. In the pediatric age group, the smaller caliber of the endoscope limits visualization of the surgical site and reduces the space available for instrument manipulations. Endoscopic procedures in infants are particularly difficult and require specialized training and experience [8].

Given the wide range of microinstruments now available, even extensive surgical procedures can be performed endoscopically. However, the surgeon should be prepared to

change to an external approach at any time if it becomes necessary. In particular, when faced with complications such as bleeding, unfavorable anatomy, and loss of orientation, the surgeon should switch to an external approach without delay [9].

In this special issue, a dozen of papers are devoted to these characteristics. It contains review articles and original researches mainly on laryngology (laryngocele, hypopharyngeal diverticulum, subglottic stenosis, papillomatosis, and glottic carcinoma), rhinology + skull base (new technology using piezoelectric device for transnasal craniotomy and management of anterior skull base defect), and head and neck (oral + oropharyngeal carcinoma).

We hope that readers of Endoscopic/External Approaches in Otorhinolaryngology and Head and Neck Surgery will find in this special issue not only accurate data and updated reviews on the different surgical approaches in treatment of ENT disease, but also important questions to be resolved such as: how far may we sufficiently and safely reach to operate endoscopically and what are the real advantages and/or disadvantages of endoscopic versus external surgery?

Acknowledgments

We thank the authors, the editors, and all the anonymous referees who have contributed to this special issue.

Jan Betka
Karl Hörmann
Manuel Bernal-Sprekelsen
Jan Plzák

References

[1] I. Alobid, J. Enseñat, F. Mariño-Sánchez et al., "Expanded endonasal approach using vascularized septal flap reconstruction for skull base tumors has a negative impact on sinonasal symptoms and quality of life," *American Journal of Rhinology and Allergy*, vol. 27, no. 5, pp. 426–431, 2013.

[2] V. J. Lund, H. Stammberger, P. Nicolai et al., "European position paper on endoscopic management of tumours of the nose, paranasal sinuses and skull base," *Rhinology. Supplement*, no. 22, pp. 1–143, 2010.

[3] J. Enseñat, M. de Notaris, M. Sánchez et al., "Endoscopic endonasal surgery for skull base tumours: technique and preliminary results in a consecutive case series report," *Rhinology*, vol. 51, no. 1, pp. 37–46, 2013.

[4] J.-L. Blanch, I. Vilaseca, M. Caballero, M. Moragas, J. Berenguer, and M. Bernal-Sprekelsen, "Outcome of transoral laser microsurgery for T2-T3 tumors growing in the laryngeal anterior commissure," *Head and Neck*, vol. 33, no. 9, pp. 1252–1259, 2011.

[5] I. Vilaseca, M. Bernal-Sprekelsen, and J. L. Blanch, "Transoral laser microsurgery for T3 laryngeal tumors: prognostic factors," *Head and Neck*, vol. 32, no. 7, pp. 929–938, 2010.

[6] I. Vilaseca, J. L. Blanch, and M. Bernal-Sprekelsen, "Transoral laser surgery for hypopharyngeal carcinomas," *Current Opinion in Otolaryngology & Head and Neck Surgery*, vol. 20, no. 2, pp. 97–102, 2012.

[7] I. Vilaseca, F. Ballesteros, B. M. Martínez-Vidal, E. Lehrer, M. Bernal-Sprekelsen, and J. L. Blanch, "Quality of life after transoral laser microresection of laryngeal cancer: a longitudinal study," *Journal of Surgical Oncology*, vol. 108, no. 1, pp. 52–56, 2013.

[8] M. Bernal-Sprekelsen, J.-L. Blanch, M. Caballero-Borrego, and I. Vilaseca, "The learning curve in transoral laser microsurgery for malignant tumors of the larynx and hypopharynx: parameters for a levelled surgical approach," *European Archives of Oto-Rhino-Laryngology*, vol. 270, no. 2, pp. 623–628, 2013.

[9] J. Astl, M. Chovanec, P. Lukeš et al., "Thyroid carcinoma surgery in children and adolescents—15 years experience surgery of pediatric thyroid carcinoma," *International Journal of Pediatric Otorhinolaryngology*, vol. 78, no. 7, pp. 990–994, 2014.

Hindawi Publishing Corporation
BioMed Research International
Volume 2014, Article ID 285486, 7 pages
http://dx.doi.org/10.1155/2014/285486

Research Article

The Role of NBI HDTV Magnifying Endoscopy in the Prehistologic Diagnosis of Laryngeal Papillomatosis and Spinocellular Cancer

Petr Lukes, Michal Zabrodsky, Eva Lukesova, Martin Chovanec, Jaromir Astl, Jaroslav A. Betka, and Jan Plzak

Department of Otorhinolaryngology, Head and Neck Surgery, First Faculty of Medicine, Charles University in Prague and University Hospital Motol, V Úvalu 84, 150 06 Prague 5, Czech Republic

Correspondence should be addressed to Petr Lukes; petr.lukes@fnmotol.cz

Received 2 February 2014; Accepted 19 April 2014; Published 17 June 2014

Academic Editor: Jan Betka

Narrow band imaging (NBI) HDTV (high definition television) magnifying endoscopy is considered to be superior for the accurate display of the microvascular patterns of superficial mucosal lesions. Observation of changes in intraepithelial papillary capillary loops (IPCL) can help distinguish benign from malignant lesions as part of an "optical biopsy." However, IPCL changes in papillomas may be mistaken for spinocellular cancer (SCC). The aim of the study was to determine whether observing microvascular changes alone is sufficient for discriminating between laryngeal SCC and papillomatosis. An additional aim was to identify associated characteristics that could clarify the diagnosis. The study included 109 patients with a suspected laryngeal tumor or papilloma. HDTV NBI magnifying endoscopy was performed during direct laryngoscopy. It was possible to visualize IPCL changes in 82 out of 109 patients (75.2%). In 71 (86.6%) patients, the diagnosis was correctly determined. In 4 (4.9%) cases, the diagnosis of SCC was expressed on the basis of finding pathologic IPCL, but histology did not demonstrate malignancy. To achieve a correct diagnosis using HDTV NBI magnifying endoscopy, it is important not only to observe changes in the shape of IPCL but also to note possible papillary structures with central-axis capillaries typical of papillomatosis.

1. Introduction

Narrow band imaging (NBI) is an optical image enhancement technology that enhances vessels in the surface of mucosa using the characteristics of the light spectrum [1]. The NBI system consists of the same components as conventional videoendoscopic systems: a light source, a camera unit, and a camera head or chip-equipped videoendoscope. Additionally, the NBI system contains a special image processor and a lighting unit with special filters that narrow the frequency range of emitted light to 400–430 nm (centered at 415 nm) and 525–555 nm (centered at 540 nm) bands. The emitted light has less penetration and less scattering and is highly absorbed in hemoglobin, thus enhancing the image resolution. The reflection is captured by a charge-coupled device chip (CCD), and an image processor creates a composite pseudocolor image, which is displayed on a monitor, enabling NBI to enhance mucosal contrast without the use of dyes [2, 3].

The detection of surface mucosal changes that are characteristic of neoplastic lesions (e.g., dysplasia, in situ carcinoma, and carcinoma), epithelial abnormalities (thickening and changes in the surface layer), and vascular changes can be best achieved with NBI. Changes in intraepithelial papillary capillary loops (IPCL), such as dilatation, weaving, and alterations in caliber and shape, occur in developing neoangiogenesis. These changes are visible as typical brown dots.

In the larynx, conventional (nonmagnifying) NBI endoscopy reaches a sensitivity of 61–91% and a specificity of 87–92% [4, 5]. The most frequent false positive results were reported in cases of laryngeal papillomatosis, where the microvascular pattern could be misinterpreted as malignant neoplasia [5].

Combination of NBI with HDTV (high definition television) and magnifying endoscopy is being used recently. Zooming flexible videoendoscopes are available for gastroenterology. Endoscopic systems can achieve ultrahigh (up to 150-fold) magnification. This magnification makes it possible to visualize the microstructure of the IPCL pattern [6, 7]. This approach is promising for better discrimination of malignant and benign lesions as part of "prehistologic diagnosis" or "optical biopsy" [8]. Nevertheless, there is no ultrathin, zooming, flexible videoendoscope available for ENT purposes; therefore, a combination of rigid telescopes and an HDTV camera head must be used to achieve sufficient resolution and ultrahigh magnification [9].

There are several papers dealing with the correlation of IPCL changes and the extent of cancer proliferation. They state that the depth of tumor invasion can be determined according to the degree of IPCL changes [7]. The first classifications of IPCL changes were created for the esophagus [6] and the oral cavity [10].

A new classification of the stages of IPCL changes was proposed for laryngeal superficial mucosal lesions [11]. The authors suggest that the in vivo differentiation of nonmalignant from malignant laryngeal lesions can be performed by evaluating the morphology of mucosal capillaries.

The classification is based solely on IPCL shape changes. Neoangiogenesis followed by corresponding IPCL changes may occur not only in cancers but also in inflammation, wound healing, and so on [12]. NBI was proven to be a useful method for the diagnosis of recurrent respiratory papillomatosis [13]. Nevertheless, IPCL changes that are observable in papillomatosis can often mimic changes in the tumor and thus their recognition may be difficult [9]. The presence of multiple papillae covered by squamous epithelium with a vessel along a central axis of each papilla is typical for laryngeal papillomatosis [14]. The question is whether the observation of IPCL changes as the only marker can be sufficient for achieving a "prehistologic diagnosis" in diagnostics of laryngeal lesions.

As the NBI endoscopy approach is based on the observation of the mucosal surface, situations where it is impossible to see the clear mucosal surface (e.g., ulceration, hyperkeratosis, blood, etc.) can prevent the valid evaluation of the findings [9].

The aim of this study was to determine the effectiveness of HDTV NBI magnifying endoscopy for the intraoperative differentiation between laryngeal carcinoma and laryngeal papillomatosis. An additional aim was to identify the associated endoscopic characteristics that could help clarify the diagnosis.

2. Materials and Methods

The present study was conducted between May 2010 and July 2013 at the Department of Otorhinolaryngology, Head and Neck Surgery, First Faculty of Medicine, Charles University in Prague, University Hospital Motol, Prague, Czech Republic. A total of 109 patients (95 males, 14 females, age of 21–83 years, and mean age of 61 years) were enrolled. All these patients were sent to the department with findings of a suspected laryngeal tumor or a suspected laryngeal papilloma. A biopsy was not previously taken in any of the patients. Patients with clearly benign lesions (nodules, polyps, edemas, or granulomas) were excluded. The study was approved by an authorized medical ethics committee, and informed consent was obtained from each patient prior to inclusion. All patients underwent direct laryngoscopy under general anesthesia. The NBI HDTV magnifying endoscopy was performed in all of the patients during the direct laryngoscopy.



Figure 1: Calibrated scale viewed by the endoscopic magnification system; the smallest segment represents 0.1 mm.

2.1. NBI HDTV Magnifying Endoscopy. The OLYMPUS EXERA II HDTV system was used in combination with the OLYMPUS OTV-S7ProH-HD-12E camera head and OLYMPUS rigid telescopes of 0°, 30°, and 70° (Olympus Medical Systems, Tokyo, Japan). To achieve the maximum magnification and resolution, the focus of the camera was set to maximum close-up, and the visualization was performed from a distance of less than 1 mm from the mucosal surface. When using the monitor OLYMPUS OEV-191H (Olympus Medical Systems, Tokyo, Japan), a 150-fold magnification can be achieved. This magnification was confirmed using a calibrated scale OBM-Stereo 40/400 0.1 mm (OLYMPUS CZECH GROUP, Prague, Czech Republic); see Figure 1.

2.2. Evaluation of Findings. The lesions were observed using a NBI mode. The primary goal was to observe the IPCL under maximum magnification. In the cases where IPCL were observable, the observations of irregular shapes, calibers, and courses of the IPCL were assessed for potential carcinomas (Figure 2). In cases where similar changes were observed in addition to the structures of papillae with a central capillary loop, the lesions were diagnosed to be papillomas (Figure 3).

To determine other signs that could further improve the diagnosis, the characteristics of the lesions were described as follows:

(a) surface of the lesion (smooth/rough/hyperkeratosis) (Figure 4),

(b) behavior (exophytic or ulcerative) (Figure 5),

(c) laterality (unilateral/bilateral) (Figure 6),

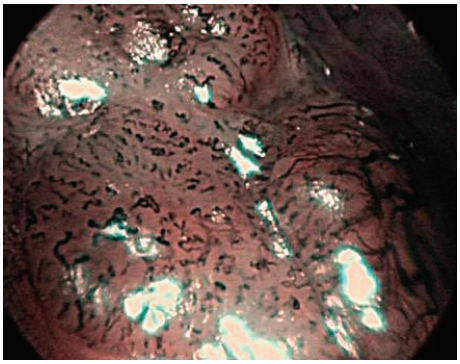

Figure 2: Features typical of a carcinoma: dilatation, weaving, changes in caliber, and variety of IPCL shapes, are visible.

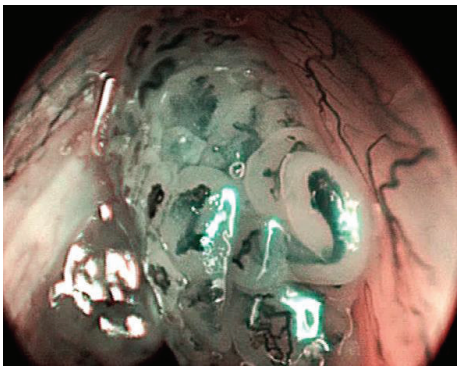

Figure 3: Features typical of a papilloma: irregular shapes, calibers, and IPCL courses with regular papillae with central vessels, are visible.

(d) multiplicity (single/multiple lesions) (Figure 7),

(e) branching feeding vessel (present/absent) (Figure 8).

In the cases of bleeding from the lesion, a cotton swab soaked in adrenaline was used to stop the bleeding and to cleanse the mucosa. In the cases of a thick layer of hyperkeratosis or fibrin covering the vascular pattern, the IPCL were observed at the edge of the lesion. Images and video sequences were recorded for further analysis. A biopsy of each lesion was performed. Tissue specimens were fixed in 10% formalin for histopathological analysis.

2.3. Statistical Analysis. Data analysis was performed with the R Project for Statistical Computing software environment, version 2.15.2 (http://www.r-project.org/).

3. Results

It was possible to clearly observe IPCL in 82 out of 109 patients (75.2%). In 27 patients (24.8%), it was impossible to observe IPCL structure due to hyperkeratosis, ulceration, bleeding, or fibrin. The diagnosis was correctly determined in 71 (86.6%) out of 82 patients with observable IPCL, according to the differentiation of IPCL changes and observations of papillary arrangement of the lesions. Of those, 39 were SCCs and 32 were papillomas. These results were confirmed using histology.

Table 1: Findings with the diagnoses performed by IPCL, associated endoscopic characteristics.

	SCC	Papillomatosis
Total	39	32
Exophytic lesion	34	32
Ulcerative lesion	5	0
Smooth surface	14	32
Rough surface	9	0
Hyperkeratosis	16	0
Feeding vessel present	8	10
Feeding vessel absent	31	22
Solitary lesion	39	15
Multiple lesion	0	17
Unilateral lesion	36	11
Bilateral lesion	3	21

Table 2: Findings with an unclear diagnosis using IPCL, associated endoscopic characteristics.

	SCC	Papillomatosis	Dysplasia
Total	4	2	1
Exophytic lesion	4	2	1
Ulcerative lesion	0	0	0
Smooth surface	3	2	1
Rough surface	1	0	0
Hyperkeratosis	0	0	0
Feeding vessel present	1	0	1
Feeding vessel absent	3	2	0
Solitary lesion	4	1	1
Multiple lesion	0	1	0
Unilateral lesion	2	1	0
Bilateral lesion	2	1	1

In 7 patients (8.5%), it was not possible to determine whether the findings supported a diagnosis of SCC or papillomatosis using observations of IPCL and papillary arrangement. In these 7 cases, histology showed that 4 were SCCs, 2 were papillomas, and 1 was a case of dysplasia. In 4 patients (4.9%), the diagnosis was a false positive. The lesions were identified as SCCs according to IPCL changes; however, histologically, 1 case was shown to be dysplasia, and the other 3 were benign lesions with no signs of malignant changes.

In the cases when IPCL were visible, the sensitivity and specificity for SCC were 100% and 82%, respectively, and for papillomatosis sensitivity and specificity were 94% and 100%, respectively.

Of 27 lesions with IPCL not observable, histology results revealed that 11 were SCCs, 10 were dysplasia, and 6 were benign lesions.

The results of the associated endoscopic characteristics analysis are displayed in Tables 1, 2, 3, and 4. In the group where the diagnosis was set by IPCL changes, statistically significant associated endoscopic characteristics were as follows:

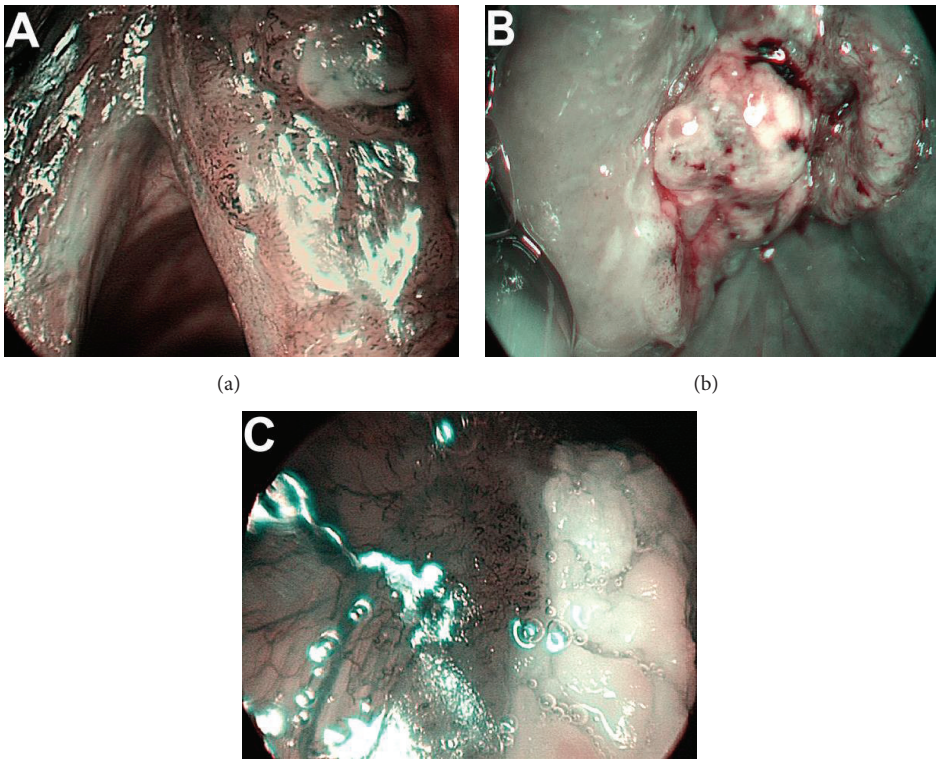

(a) (b)

(c)

Figure 4: Surface of the lesion: (a) smooth, (b) rough, and (c) hyperkeratotic.

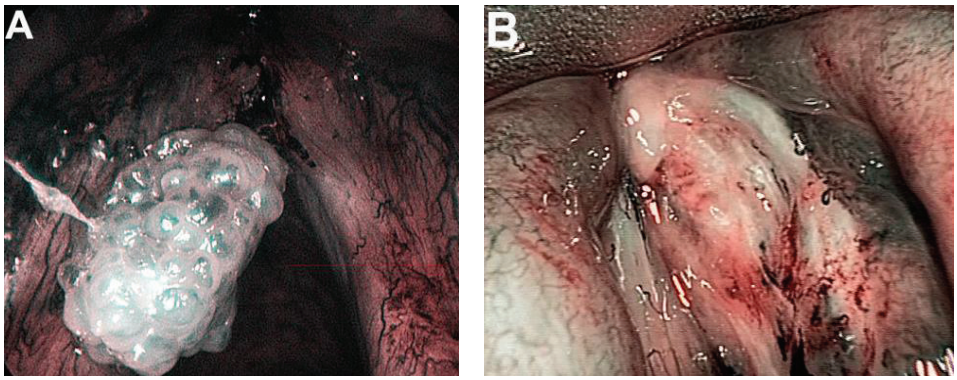

(a) (b)

Figure 5: Behavior of the lesion: (a) exophytic lesion and (b) ulcerative lesion.

(1) surface of the lesion (smooth/rough/hyperkeratosis) (Fisher's Exact Test, $P = 0.000000003641$);

(2) laterality (Fisher's Exact Test, $P = 0.0000002364$);

(3) multiplicity (Fisher's Exact Test, $P = 0.0000005575$).

In the group where the diagnosis was not possible using changes in IPCL and in the group of false positive results, no significant differences were found when evaluating associated endoscopic characteristics.

In the group where IPCL changes were not visible, a statistically significant associated endoscopic characteristic was the presence of a feeding vessel (Fisher's Exact Test, $P = 0.0004264$).

Statistical analysis of the frequency of associated endoscopic characteristics in the whole study cohort, without regard to the IPCL, yielded the following results:

(a) surface of the lesion (smooth/rough/hyperkeratosis); hyperkeratosis and rough surfaces were observed most frequently in SCCs, which was shown to be statistically significant (Fisher's Exact Test, $P = 0.00000000000357$),

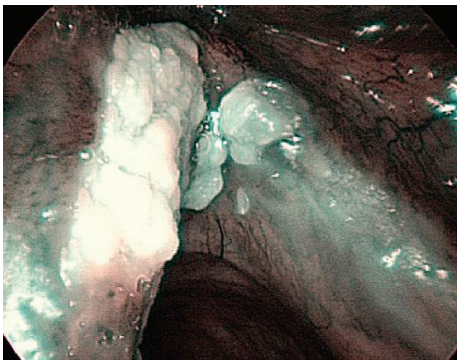

Figure 6: Lesion extending to both vocal folds.

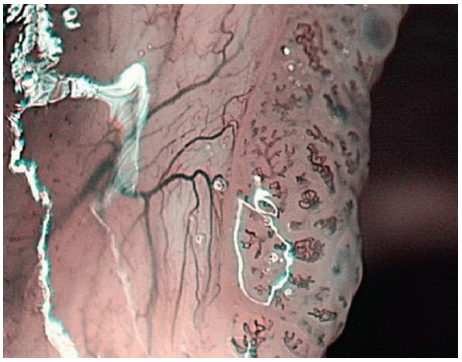

Figure 8: A branching feeding vessel.

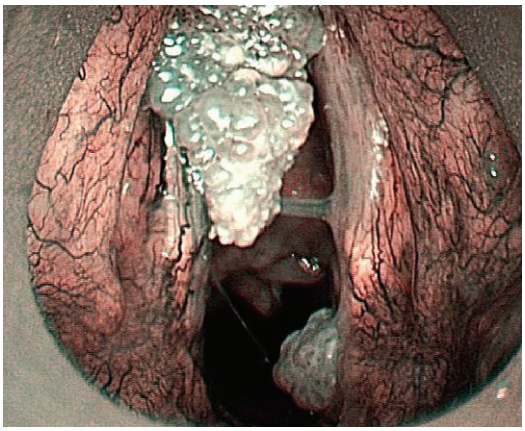

Figure 7: Multiple lesions.

Table 3: False positive findings using IPCL, associated endoscopic characteristics.

	Dysplasia	Benign
Total	1	3
Exophytic lesion	1	3
Ulcerative lesion	0	0
Smooth surface	0	1
Rough surface	0	0
Hyperkeratosis	1	2
Feeding vessel present	1	0
Feeding vessel absent	0	3
Solitary lesion	1	1
Multiple lesion	0	2
Unilateral lesion	0	2
Bilateral lesion	1	1

(b) behavior (exophytic or ulcerative); no statistically significant differences were found (Fisher's Exact Test, $P = 0.071$),

(c) laterality (unilateral/bilateral); bilateral lesions were most frequently observed in papillomatosis, which was statistically significant (Fisher's Exact Test, $P = 0.0000107$),

Table 4: Findings with nonvisible IPCL, associated endoscopic characteristics.

	SCC	Dysplasia	Benign
Total	11	10	6
Exophytic lesion	9	10	5
Ulcerative lesion	2	0	1
Smooth surface	0	2	1
Rough surface	4	0	1
Hyperkeratosis	7	8	4
Feeding vessel present	1	3	6
Feeding vessel absent	10	7	0
Solitary lesion	9	7	6
Multiple lesion	2	3	0
Unilateral lesion	7	6	5
Bilateral lesion	3	4	1

(d) multiplicity (single/multiple lesion); multiple lesions were observed most frequently in papillomatosis, which was statistically significant (Fisher's Exact Test, $P = 0.000000726$),

(e) branching feeding vessel (present/absent); feeding vessels were most frequently observed in benign lesions, which was statistically significant (Fisher's Exact Test, $P = 0.0171$).

4. Discussion

NBI is an endoscopic method with a high degree of sensitivity and specificity. Clinical discrimination of papillomatosis and early stage of laryngeal SCC can be difficult using conventional (nonmagnifying) NBI endoscopy. Recently, NBI endoscopy has been increasingly used in combination with magnification and high resolution systems (HDTV). It is known that the growth of epithelial tumors leads to escalated neoangiogenesis [12]. In practice, this phenomenon can be observed as changes in the IPCL arrangement, diameter, and shape and as a loss of regularity [6].

To visualize these changes successfully, the endoscopic system must achieve not only a sufficient resolution but also the required magnification. The method described in this

paper allows one to achieve up to 150-fold magnification intraoperatively and can therefore be described as magnifying endoscopy. The biological behavior of the lesion can be identified using the nature of IPCL changes. IPCL changes that are observable in laryngeal SCC may be, however, very similar to the changes that are apparent in recurrent respiratory papillomatosis, where there is also a potential for increased neoangiogenesis [15].

A new classification of the stages of IPCL changes was proposed for laryngeal superficial mucosal lesions [11]. This classification was only based on IPCL shape changes and seems to be insufficient to achieve the best results possible or to improve the potential of endoscopic "prehistologic diagnosis."

The usefulness of NBI in the detection of recurrent respiratory papillomatosis was described by Tjon Pian Gi et al. [13]. According to our results, the observation of not only the changes in the behavior of IPCL but also the structure of the epithelium surface, where, in most of the cases of papillomatosis, regular multiple papillae with vessels along the central axis of each papilla can be found, is the most important feature for distinguishing between papillomas and SCCs. On the other hand, the vascular pattern of SCC shows many irregularities and a partial or complete collapse of vascular microarchitecture can be frequently observed.

When all of these characteristics are taken into account, SCCs can be accurately distinguished from papillomas and the diagnosis can be made before histology results are available. Further development of HDTV NBI magnifying endoscopy is needed so that a real "prehistologic diagnosis" or "optical biopsy" can be achieved. It should be taken into consideration, however, that because NBI is a method based on the observation of vascular changes in the mucosa, in cases where the surface of the lesion prevents a direct view of the mucosa (ulcer, hyperkeratosis, etc.), this method is limited [9].

In this study, it was not possible to observe the IPCL in the lesions of 24.8% of the cases. In 75.2% of the cases, it was possible to accurately display the surface of the lesion, and 86.6% of the cases were diagnosed correctly before the histology results were obtained. Sensitivity and specificity for SCC were 100% and 82%, respectively, and for papillomatosis sensitivity and specificity were 94% and 100%, respectively. In papillomas, IPCL changes were similar to those visible in cancers. This finding is in accordance with data published by Bolontrade et al. [16], who found that an increase in the density and size of blood vessels can be observed in both late papillomas and carcinomas.

In this study, the observations of papilliform structures of the epithelium combined with observations of IPCL were shown to be crucial for setting the diagnosis. For the discrimination of laryngeal SCC from recurrent respiratory papillomatosis, both the changes in IPCL and the changes of the epithelium surface must be taken into account. For papillomatosis, the typical papillary arrangement of the epithelium with a central-axis capillary in each papilla is usually present. The shape of the capillaries, however, may undergo changes similar to those observed in cancer. This study was also focused on finding other associated, endoscopically observable characteristics that can improve the accuracy of endoscopic diagnosis.

Features significant for the improvement of endoscopic diagnosis were observation of surface of the lesions (in papillomas, a smooth surface was found in all cases, whereas carcinomas may show hyperkeratosis or a rough surface), laterality, and multiplicity of the lesions. Additionally, lesions affecting both vocal cords and multiple lesions were most frequently observed in papillomatosis.

Surprisingly, the presence of branching feeding blood vessels was most often visible in benign diagnoses. Nevertheless, this result may be influenced by very low numbers of benign lesions in the study group.

5. Conclusions

HDTV NBI magnifying endoscopy is a method with a high accuracy for the diagnosis of laryngeal lesions that can be available before the histology results. The most important observation for a correct diagnosis is that of the changes in the shape of IPCL. For distinguishing between SCC and papillomatosis, it is crucial to also focus on the epithelial surface and to observe the papillary structures with a central-axis capillary and a more or less regular arrangement. Some of the associated endoscopic characteristics, such as the surface, the presence of multiple lesions, and the spread to both vocal cords, may be taken as the criteria used for a more accurate diagnosis.

Conflict of Interests

The authors declare that there is no conflict of interests regarding the publication of this paper.

Acknowledgments

This paper was supported by Grants nos. NT11544 of the *Internal Grant Agency of the Ministry of Health of the Czech Republic* and by MH CZ-DRO, University Hospital Motol, Prague, Czech Republic, 00064203, PRVOUK P27, UNCE 204013, and SVV 266513.

References

[1] Y. Sano, M. Kobayashi, and Y. Hamamoto, "New diagnostic method based on color imaging using narrowband imaging (NBI) endoscopy system for gastrointestinal tract," *Gastrointestinal Endoscopy*, vol. 53, no. 5, Article ID AB125, 2001.

[2] C. Piazza, O. Dessouky, G. Peretti, D. Cocco, L. De Benedetto, and P. Nicolai, "Narrow-band imaging: a new tool for evaluation of head and neck squamous cell carcinomas. Review of the literature," *Acta Otorhinolaryngologica Italica* , vol. 28, no. 2, pp. 49–54, 2008.

[3] K. Gono, "An introduction to high-resolution endoscopy and narrowband imaging," in *Advanced Digestive Endoscopy: Comprehensive Atlas of High Resolution Endoscopy and Narrowband Imaging*, J. Cohen, Ed., pp. 9–22, Blackwell, 2007.

[4] C. Piazza, D. Cocco, L. De Benedetto, F. Del Bon, P. Nicolai, and G. Peretti, "Narrow band imaging and high definition television in the assessment of laryngeal cancer: a prospective study on 279 patients," *European Archives of Oto-Rhino-Laryngology*, vol. 267, no. 3, pp. 409–414, 2010.

[5] A. Watanabe, M. Taniguchi, H. Tsujie, M. Hosokawa, M. Fujita, and S. Sasaki, "The value of narrow band imaging for early detection of laryngeal cancer," *European Archives of Oto-Rhino-Laryngology*, vol. 266, no. 7, pp. 1017–1023, 2009.

[6] H. Inoue, M. Kaga, Y. Sato, S. Sugaya, and S. Kudo, "Magnifying endoscopic diagnosis of tissue atypia and cancer invasion depth in the area of pharyngo-esophageal squamous epithelium by NBI enhanced magnification image: IPCL pattern classification," in *Advanced Digestive Endoscopy: Comprehensive Atlas of High Resolution Endoscopy and Narrowband Imaging*, J. Cohen, Ed., pp. 49–66, Blackwell, Malden, Mass, USA, 2007.

[7] Y. Kumagai, H. Inoue, K. Nagai, T. Kawano, and T. Iwai, "Magnifying endoscopy, stereoscopic microscopy, and the microvascular architecture of superficial esophageal carcinoma," *Endoscopy*, vol. 34, no. 5, pp. 369–375, 2002.

[8] C. Piazza, F. del Bon, G. Peretti, and P. Nicolai, "Narrow band imaging in endoscopic evaluation of the larynx," *Current Opinion in Otolaryngology & Head and Neck Surgery*, vol. 20, no. 6, pp. 472–476, 2012.

[9] P. Lukeš, "Narrow Band Imaging (NBI)—endoscopic method for detection of head and neck cancer," in *Endoscopy*, S. Amornyotin, Ed., pp. 75–87, InTech, Rijeka, Croatia, 2013.

[10] J. H. Takano, T. Yakushiji, I. Kamiyama et al., "Detecting early oral cancer: narrowband imaging system observation of the oral mucosa microvasculature," *International Journal of Oral and Maxillofacial Surgery*, vol. 39, no. 3, pp. 208–213, 2010.

[11] X.-G. Ni, S. He, Z.-G. Xu et al., "Endoscopic diagnosis of laryngeal cancer and precancerous lesions by narrow band imaging," *Journal of Laryngology and Otology*, vol. 125, no. 3, pp. 288–296, 2011.

[12] D. Hanahan and J. Folkman, "Patterns and emerging mechanisms of the angiogenic switch during tumorigenesis," *Cell*, vol. 86, no. 3, pp. 353–364, 1996.

[13] R. E. Tjon Pian Gi, G. B. Halmos, B. M. van Hemel et al., "Narrow band imaging is a new technique in visualization of recurrent respiratory papillomatosis," *Laryngoscope*, vol. 122, no. 8, pp. 1826–1830, 2012.

[14] M. Andrea, O. Dias, and A. Santos, "Contact endoscopy during microlaryngeal surgery: a new technique for endoscopic examination of the larynx," *Annals of Otology, Rhinology and Laryngology*, vol. 104, no. 5, pp. 333–339, 1995.

[15] L. Rodríguez-Caso, A. Reyes-Palomares, F. Sánchez-Jiménez, A. R. Quesada, and M. Ángel Medina, "What is known on angiogenesis-related rare diseases? A systematic review of literature," *Journal of Cellular and Molecular Medicine*, vol. 16, no. 12, pp. 2872–2893, 2012.

[16] M. F. Bolontrade, M. C. Stern, R. L. Binder, J. C. Zenklusen, I. B. Gimenez-Conti, and C. J. Conti, "Angiogenesis is an early event in the development of chemically induced skin tumors," *Carcinogenesis*, vol. 19, no. 12, pp. 2107–2113, 1998.

Hindawi Publishing Corporation
BioMed Research International
Volume 2014, Article ID 397295, 4 pages
http://dx.doi.org/10.1155/2014/397295

Research Article

Balloon Dilatation of Pediatric Subglottic Laryngeal Stenosis during the Artificial Apneic Pause: Experience in 5 Children

J. Lisý,[1] D. Groh,[2] M. Chovanec,[3] M. Marková,[2] V. Suchánek,[1] P. Polášková,[1] and M. Trávníček[4]

[1] *Department of Imaging Methods, 2nd Medical Faculty, University Hospital Motol, Charles University, 150 06 Prague, Czech Republic*
[2] *Children ENT Department, 2nd Medical Faculty, University Hospital Motol, Charles University, 150 06 Prague, Czech Republic*
[3] *Department of Otorhinolaryngology and Head and Neck Surgery, 1st Medical Faculty, University Hospital Motol, Charles University, 150 06 Prague, Czech Republic*
[4] *Department of Anesthesiology, 2nd Medical Faculty, University Hospital Motol, Charles University, 150 06 Prague, Czech Republic*

Correspondence should be addressed to J. Lisý; jilisy@yahoo.com

Received 7 February 2014; Revised 28 April 2014; Accepted 26 May 2014; Published 12 June 2014

Academic Editor: Jan Plzak

Introduction. Balloon dilatation is a method of choice for treatment of laryngeal stenosis in children. The aim of procedure in apneic pause is to avoid new insertion of tracheostomy cannula. *Patients and Methods*. The authors performed balloon dilatation of subglottic laryngeal strictures (SGS) in 5 children (3 girls and 2 boys) without tracheotomy. Two of them with traumatic and inflammatory SGS had a tracheal cannula removed in the past. The other 3 children with postintubation SGS had never had a tracheostomy before. The need for tracheostomy due to worsening stridor was imminent for all of them. *Results*. The total of seven laryngeal dilatations by balloon esophagoplasty catheter in apneic pause was performed in the 5 children. The procedure averted the need for tracheostomy placement in 4 of them (80%). Failure of dilatation in girl with traumatic stenosis and concomitant severe obstructive lung disease led to repeated tracheostomy. *Conclusion*. Balloon dilatation of laryngeal stricture could be done in the absence of tracheostomy in apneic pause. Dilatation averted threatening tracheostomy in all except one case. Early complication after the procedure seems to be a negative prognostic factor for the outcome of balloon dilatation.

1. Introduction

Balloon dilatation is a method of choice in the treatment of laryngeal stenosis in children. When tracheostomy is present, dilatation is performed under general anesthesia; in this case, ventilation is ensured through the tracheostomy. The aim of the dilatation procedure is to allow subsequent removal of the tracheostomy.

Balloon dilatation during apneic pause is beneficial to children who had never had a tracheostomy as well as to children who had a tracheostomy previously removed and are experiencing worsening of clinical symptoms. In the former, balloon dilatation presents a noninvasive treatment option. In the latter, it can prevent the need for reinsertion.

2. Material and Methods

Balloon dilatation was used for treatment of five children with subglottic laryngeal stenosis (SGS) who suffered from worsening of dyspnea with stridor and would otherwise be indicated for tracheotomy or other optional surgical treatments. Two patients had a tracheostomy cannula previously removed followed by a plastic surgery of the tracheostomy site (one boy with inflammatory stenosis and one girl with traumatic stenosis). The other three children had never had a tracheostomy cannula (two girls and one boy with subglottic stricture after long lasting intubation).

Balloon dilatation of laryngeal stricture is a modification of a method used for esophageal strictures (3). Laryngeal

strictures are shorter; therefore, shorter balloon can be used. The catheter is guided under laryngoscopic control, sometimes with a help of Magill forceps. General anesthesia with deeper relaxation compared to esophageal dilatations is beneficial. Angiographic guide wire reinforces the catheter but is not used for the placement of balloon into the stricture. Ventilation during the procedure is usually possible through tracheostomy cannula which is applied to the majority of patients.

Balloon catheters with the balloon diameter ranging from 10 to 23 mm (Accent, Cook), identical to the ones used for esophageal dilation, were used. The catheter was introduced transorally under laryngoscopic control, eventually with the help of Magill's forceps.

The balloon was positioned into the center of the stenosis and patients were hyperventilated with oxygen delivered by assisted mask ventilation for one minute. During the following apneic pause the balloon was distended by water soluble nonionic contrast media. The apneic pause lasted no more than 45 seconds or until the patient's SpO2 dropped to 90%, at which point the airway was reassessed.

Later after the deflation of the balloon the patient was again hyperventilated for 1 minute. Balloon inflation was repeated six times. The time of laryngeal occlusion must be closely monitored in children without tracheotomy. Patients were monitored by pulse oximetry and ECG during the procedure. If the patient breathes and eats comfortably in the recovery unit, next day discharge home can be safely achieved. We did not use mitomycin C or local steroids in the management of SGS, as there are no prospective randomized studies demonstrating their benefit and there are concerns of potential local noxious effects.

The primary positive outcome was achieving a functional airway without the need of an open laryngotracheal surgery or ongoing need for a tracheostomy. The negative outcome was defined as the need for a new tracheostomy or optional open surgery.

3. Results

The total of seven laryngeal dilatations by standard balloon esophagoplasty catheter in apneic pause was performed in the 5 children (repeated dilatation was necessary in one boy with inflammatory SGS and girl with postintubation SGS). The procedure averted the need for tracheostomy placement in 4 of them (80%) (Table 1). None of the patients suffered a major complication related to balloon dilatation. Failure of dilatation in girl with traumatic stenosis and concomitant severe obstructive lung disease led to repeated tracheostomy.

3.1. Case 1. One-year-old girl suffered previously a trauma in a car accident. The traumatic impairment of bilateral laryngeal innervations resulted in development of SGS requiring tracheostomy placement. Repeated vaporizations by laser including lateral fixation of left ventricular plica allowed the removal of the cannula. However, immobility of glottis with laryngeal stricture resulted in breathing with a stridor.

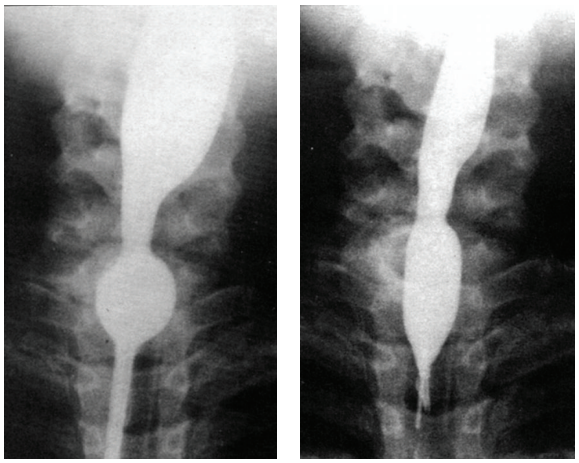

(a) (b)

Figure 1: (a) Balloon dilation in apneic pause was performed using 20 mm balloon with mild effect. (b) Replacement of catheters by another with 15 mm balloon allowed achieving more promising result.

Balloon dilatation in apneic pause was performed using 20 mm balloon with mild effect (Figure 1(a)). Replacement of the catheter by another with 15 mm balloon led to more promising result (Figure 1(b)).

The girl experienced respiratory insufficiency one hour after dilatation which required artificial ventilation for 1 day. Spirometry showed severe obstructive lung disease. The tracheostomy cannula had to be reinserted again 40 days after balloon dilatation.

3.2. Case 2. Girl, 13 years old, had a history of SGS lasting 10 years after repeated intubations following a cardiac surgery. She never had a tracheostomy cannula before. Worsening of dyspnea with stridor led to dilatation in the apneic pause by 18 mm balloon, followed by a second dilatation using 23 mm balloon. The girl has been symptoms-free since the second procedure.

4. Discussion

The incidence of subglottic laryngeal stenosis (SGS) has decreased in time to 1-2% in 2000 due to advances in airway management and guidelines for intubation [1]. However, the management of SGS in children continues to be a challenging problem for the otolaryngologist. Management options for SGS vary from observation to surgical intervention, with the goals being to either bypass the stenotic segment by tracheotomy or increase the diameter of the subglottic airway by cricoid split, laryngotracheal reconstruction, or partial cricotracheal resection. In the last years, balloon dilatation which offers the benefit of reduced invasiveness became an alternative to open laryngeal procedures. However, reported success rates are variable. The first description of balloon catheter technology used for tracheal stenosis appeared in

Table 1

Age (years)	1	8	9	11	13
Gender	F	F	M	M	F
Etiology	Trauma	Intubation	Intubation	Inflammation	Intubation
Previous tracheostomy	Yes	No	No	Yes	No
Dilatations (number)	1	1	1	2	2
Balloon width (mm)	20 and 15 (∗)	15 and 10 (∗)	18	18 and 18	18 and 23
Width of stenosis (mm)	5 and 8 (∗)	7 and 9 (∗)	9	8 and 10	10 and 12
Complications	Respiratory insufficiency	—	—	—	—
Follow-up (years)	Retracheostomy	12	2	4	3

(∗) Two balloons used during one dilatation.

1984 [2]. Balloon tracheoplasty for treatment of subglottic laryngeal stenosis was reported in 1991 by Hebra et al. [3].

Balloon laryngoplasty was proved as an effective, stand-alone procedure for the management of SGS in 70% of patients, obviating the need for tracheotomy or cricoid split [4]. Others showed 65% successful outcome of primary balloon dilatation of SGS, higher in acquired (70%) than in congenital (50%) stenosis [5]. Another study of primary balloon dilatation in the endoscopic management of pediatric SGS showed that in 60% of cases it was possible to avoid an open reconstruction or tracheotomy and 40% of patients had their symptoms temporarily improved until definitive open reconstruction. [6]. Success rate of balloon dilatation is decreasing in time as was shown by Bent et al., with stridor eliminated or greatly improved in all patients the first day after the procedure, which was lasting in 70% of patients during follow-up [7].

Large systematic review of the literature evaluated 22 relevant studies on balloon and rigid dilatation as primary therapy for laryngotracheal stenosis (LTS) in pediatric patients [8]. Although it showed that balloon dilatation alone is less successful (success rate 50%) than balloon dilatation with adjuvant therapy (the Carbon dioxide or KTP laser, topical or intralesional injected steroid; success rate ranged from 50% to 78%), success rate of balloon dilatation alone in our patients was 80%.

We have found only one case report about a balloon dilatation of subglottic stenosis with noninvasive ventilation [9]. Concomitant airway disorder was shown as a negative prognostic factor when 75% of failed balloon dilatations were in children who had concomitant airway disorders; in contrast, only 37.5% of successfully treated children had concomitant airway disorders ($P = 0.048$) [6]. This observation helps to understand the failure of balloon dilatation in one-year-old girl with traumatic subglottic laryngeal stenosis after a car accident who suffered from severe obstructive lung disease.

5. Conclusion

Balloon dilatation of a subglottic laryngeal stenosis can be safely performed in those patients where the worsening of dyspnea and stridor would lead to tracheostomy cannula insertion. Balloon dilatation of laryngeal stenosis in apneic pause allowed achieving sufficient diameter of laryngeal lumen in 80% of children with subglottic stenosis and avoiding threatening tracheostomy placement or alternative surgical method without any significant complication after the procedure. Balloon dilatation was unsuccessful in a girl with traumatic subglottic stenosis and concomitant severe obstructive lung disease. It seems that an occurrence of a complication early after the procedure is a negative prognostic factor of the outcome of treatment.

Conflict of Interests

The authors declare that there is no conflict of interests regarding the publication of this paper.

References

[1] S. S. Choi and G. H. Zalzal, "Changing trends in neonatal subglottic stenosis," *Otolaryngology: Head and Neck Surgery*, vol. 122, no. 1, pp. 61–63, 2000.

[2] M. D. Cohen, T. R. Weber, and C. C. Rao, "Balloon dilatation of tracheal and bronchial stenosis," *The American Journal of Roentgenology*, vol. 142, no. 3, pp. 477–478, 1984.

[3] A. Hebra, D. D. Powell, C. D. Smith, and H. B. Othersen Jr., "Balloon tracheoplasty in children: results of a 15-year experience," *Journal of Pediatric Surgery*, vol. 26, no. 8, pp. 957–961, 1991.

[4] F. Durden and S. E. Sobol, "Balloon laryngoplasty as a primary treatment for subglottic stenosis," *Archives of Otolaryngology: Head and Neck Surgery*, vol. 133, no. 8, pp. 772–775, 2007.

[5] C. Hautefort, N. Teissier, P. Viala, and T. Van Den Abbeele, "Balloon dilation laryngoplasty for subglottic stenosis in children: eight years'experience," *Archives of Otolaryngology: Head and Neck Surgery*, vol. 138, no. 3, pp. 235–240, 2012.

[6] A. S. Whigham, R. Howell, S. Choi, M. Peña, G. Zalzal, and D. A. Preciado, "Outcomes of balloon dilation in pediatric subglottic stenosis," *Annals of Otology, Rhinology and Laryngology*, vol. 121, no. 7, pp. 442–448, 2012.

[7] J. P. Bent, M. B. Shah, R. Nord, and S. R. Parikh, "Balloon dilation for recurrent stenosis after pediatric laryngotracheoplasty," *Annals of Otology, Rhinology and Laryngology*, vol. 119, no. 9, pp. 619–627, 2010.

[8] K. Chueng and N. K. Chadha, "Primary dilatation as a treatment for pediatric laryngotracheal stenosis: a systematic review,"

International Journal of Pediatric Otorhinolaryngology, vol. 77, no. 5, pp. 623–628, 2013.

[9] E. Rossetti, A. Germani, A. Onofri, and S. Bottero, "Non-invasive ventilation with balloon dilatation of severe subglottic stenosis in a 10-month infant," *Intensive Care Medicine*, vol. 37, no. 2, pp. 364–365, 2011.

Hindawi Publishing Corporation
BioMed Research International
Volume 2014, Article ID 464781, 7 pages
http://dx.doi.org/10.1155/2014/464781

Research Article

Oncological and Functional Outcome after Surgical Treatment of Early Glottic Carcinoma without Anterior Commissure Involvement

Jovica Milovanovic,[1,2] Ana Jotic,[1,2] Vojko Djukic,[1,2] Bojan Pavlovic,[1,2] Aleksandar Trivic,[1,2] Sanja Krejovic-Trivic,[1,2] Andjela Milovanovic,[1,3] Aleksandar Milovanovic,[1,4] Vera Artiko,[1,5] and Bojan Banko[6]

[1] *Medical Faculty Belgrade, University of Belgrade, Belgrade, Serbia*
[2] *Clinic for Otorhinolaryngology and Maxillofacial Surgery, Clinical Centre of Serbia, Pasterova 2, Belgrade, Serbia*
[3] *Clinic for Medical Rehabilitation, Clinical Center of Serbia, Belgrade, Serbia*
[4] *Institute for Occupational Health of Serbia "Dr Dragomir Karajovic," Belgrade, Serbia*
[5] *Institute for Nuclear Medicine, Clinical Centre of Serbia, Belgrade, Serbia*
[6] *Center for Radiology and Magnetic Resonance Imaging, Clinical Center of Serbia, Belgrade, Serbia*

Correspondence should be addressed to Ana Jotic; anajotic@yahoo.com

Received 5 February 2014; Revised 5 May 2014; Accepted 9 May 2014; Published 2 June 2014

Academic Editor: Jan Plzak

Introduction. Glottic carcinoma can be successfully diagnosed in its early stages and treated with high percentage of success. Organ preservation and optimal functional outcomes could be achieved with wide array of surgical techniques for early glottic cancer, including endoscopic approaches or open laryngeal preserving procedures, making surgery the preferred method of treatment of early glottic carcinoma in the last few years. *Material and Methods*. Prospective study was done on 59 patients treated for Tis and T1a glottic carcinoma over a one-year time period in a tertiary medical center. Patients were treated with endoscopic laser cordectomy (types II–IV cordectomies according to European Laryngological Society classification of endoscopic cordectomies) and open cordectomy through laryngofissure. Follow-up period was 60 months. Clinical and oncological results were followed postoperatively. Voice quality after the treatment was assessed using multidimensional voice analysis 12 months after the treatment. *Results*. There were no significant differences between oncological and functional results among two groups of patients, though complications were more frequent in patients treated with open cordectomy. *Conclusion*. Endoscopic laser surgery should be the first treatment of choice in treatment of early glottic carcinomas, though open approach through laryngofissure should be available for selected cases where anatomical factors present limiting adequate tumor removal.

1. Introduction

Glottic carcinoma can be successfully diagnosed in its early stages, with high percentage of success. Treatment options include open cordectomy through laryngofissure, endoscopic cordectomy, or radiotherapy, but treatment guidelines are still based on low-level evidence. Cochrane review concluded that there is currently insufficient evidence to guide management decisions on the most effective treatment [1]. In many European countries, radiotherapy was the first choice of treatment for patients with early glottic cancer, with its high local control rates and satisfactory functional results [2, 3]. Still, choosing the optimal treatment option remains a complicated issue. Factors that influence choice of treatment include tumor characteristics, patient's preference, cost, duration and availability of the treatment, and risk of complications [4]. In the last few years there have been a number of papers challenging the opinion of radiotherapy as modality of treatment with less morbidity and more effectiveness. Organ preservation and optimal functional outcomes could also be

achieved with wide array of surgical techniques, including endoscopic approaches or open laryngeal preserving procedures, making surgery good alternative and more preferred treatment choice to radiotherapy [5–7].

The aim of this study was to evaluate oncological and functional results of different surgical treatments for Tis and T1 glottic carcinoma and establish their effectiveness.

2. Material and Methods

This prospective study was conducted with 59 patients treated for Tis and T1a glottic carcinoma over a one-year time period (between November 1, 2006, and October 31, 2007) in the Institute of Otorhinolaryngology and Maxillofacial Surgery of the Clinical Centre of Serbia in Belgrade. This study was approved by the Institutional Review Board, and all patients provided their informed consent prior to inclusion in the study. Patients had no previous surgical or radiation treatment for malignancy.

Stroboscopic exam was conducted before surgery and on every follow-up control exam. Stroboscopy was performed with the Storz Endovision Telecam DX 20 Pal and Storz Pulsar 20 (Karl Storz GmbH & Co., Tuttlingen, Germany) during modal pitch at comfortable intensity on sustained vowel /*i*/. The following parameters were noted preoperatively and 12 months postoperatively on the operated vocal fold: (1) glottic occlusion (complete and incomplete), (2) phase symmetry (symmetrical, asymmetrical, or not assessable vocal fold vibration), (3) mucosal wave (normal, decreased, or absent), (4) nonvibratory segment (present, absent, or nonassessable), and (5) ventricular activity (present or absent). Stroboscopic assessment was done by two experienced otorhinolaryngologists.

Mucosal extension, depth of vocal fold infiltration, and size of the tumor were assessed with laryngomicroscopy. Group treated with endoscopic transoral cordectomy involved patients with tumor size up to 10 mm, localized on upper surface or free edge of one vocal fold with preserved mobility, without anterior commissure involvement. Patients with tumor localized on one vocal fold with preserved mobility, tumor diameter greater than 10 mm with deeper infiltration, or inadequate endoscopic tumor exposure due to anatomical limitations were treated with surgical cordectomy.

Endoscopic transoral cordectomy was done in 26 patients (types II–IV cordectomies according to recommended European Laryngological Society classification of endoscopic cordectomies) [8]. Endoscopic cordectomies were conducted with a Sharplan Lumenis 40C CO_2 laser, with a Carl Zeiss Surgical OPMI Sensera optical microscope and with patients under general endotracheal anesthesia. Open cordectomy was conducted in 33 patients. Patients were staged using the TNM clinical classification of the International Union Against Cancer (UICC, 2002) as TisN0 M0 and T1N0 M0 [9], based on clinical examination, laryngomicroscopy, and pathohistology. The open surgical approach involved laryngofissure with cordectomy in general endotracheal anesthesia. Patients with surgical margins that were positive of malignancy received postoperative radiotherapy and were not included in this study.

Multidimensional voice and speech analysis were performed with Tiger DRS software, preoperative and 12 months after the treatment. Acoustic parameters were determined with Vocal Assessment program by analyzing vocal results of patients pronouncing continuous vocal /*a*/. Fundamental frequency ($F0$, Hz), jitter, shimmer, and normalized noise energy (NNE, dB) were followed.

Follow-up period was 5 years. Patients were examined every month postoperatively during the first year, every three months during the second and third years, and every six months during the fourth and fifth years. Local recurrence was defined as carcinoma occurring after completion of primary treatment independent of the localization in any part of the glottis. Recurrent disease was confirmed by laryngomicroscopy and pathohistological analysis of biopsied lesion.

IBM SPSS Statistics 20 (IBM Corporation, New York, NY) was used for the data analysis. Overall, recurrence-free and disease-specific survival were calculated according to the Kaplan-Meier method; the Log-rank test was used to compare survival parameters between patient groups. Wilcoxon signed-rang test was used to compare stroboscopic parameters before and after the treatment between groups. Student's t-test was used to compare mean values for acoustic parameters between patients groups before and after the treatment. P values lower than 0.05 were considered statistically significant.

3. Results

The study included 53 males (89.8%) and 6 females (10.2%), with an average age of 56.73 years. Endoscopic laser cordectomy was done in 26 patients (24 males and 2 females) and open cordectomy through laryngofissure in 33 patients (29 males and 4 females). Most of the patients were staged as T1aN0 M0 (19 in endoscopic laser cordectomy group and 30 in open cordectomy group). Most of our patients were smokers (94.9%). Recurrent disease was noted in 7.7% of patients treated with endoscopic laser cordectomy and in 9.1% of patients treated with open cordectomy (Table 1).

Before treatment, all patients in both groups were complaining of dysphonia. Considering other symptoms, patients were complaining of pain, cough, dysphagia, and dyspnea, but the percentage of those patients was small in both groups (Table 2).

In endoscopic laser cordectomy group, in Tis patients, cordectomy type II was done in 4 patients and type III in 1 patient. In T1aN0 M0 patients cordectomy type III was done in 15 and type IV in 6 patients (according to recommended ELS classification for endoscopic cordectomies).

Stroboscopic signs described preoperatively and 12 months postoperatively were shown in Table 3. Preoperative stroboscopic signs were similar between groups. There was a significant difference only in the number of patients with a normal mucosal wave between groups (15.4% versus 0%, $P = 0.047$). Postoperative results varied significantly between groups. Comparing the stroboscopic signs between

Table 1: Demographic and clinical variables.

	Endoscopic laser cordectomy	Open cordectomy
Gender *n* (%)		
Male	24 (92.3)	29 (87.9)
Female	2 (7)	4 (12.1)
Age (mean ± SD)	57.65 ± 10.31	55.82 ± 8.78
T stage *n* (%)		
Tis	5 (19.2)	3 (9.1)
T1a	21 (80.8)	30 (90.9)
Smoking *n* (%)		
Yes	25 (96.2)	31 (93.9)
No	1 (3.8)	2 (6.1)
Recurrent carcinoma *n* (%)		
Yes	2 (7.7)	3 (9.1)
No	24 (92.3)	31 (90.9)

Table 2: Patients' symptoms in both treated groups.

n (%)	Endoscopic laser cordectomy	Open cordectomy
Dysphonia		
Yes	26 (100)	33 (100)
No	0 (0)	0 (0)
Pain		
Yes	2 (7.7)	3 (9.1)
No	24 (92.3)	30 (90.9)
Cough		
Yes	3 (11.5)	4 (12.1)
No	23 (88.5)	29 (87.9)
Dysphagia		
Yes	2 (7.7)	1 (3)
No	24 (92.3)	32 (97)
Dyspnea		
Yes	3 (8.1)	2 (6.1)
No	25 (96.2)	31 (93.9)

the groups, there were significantly more patients with completely absent mucosal wave (63.6% versus 23.1%, $P = 0.008$) and with nonvibratory segment that could not be assessed (42.4% versus 19.2%, $P = 0.003$) in open cordectomy group. In patients treated with endoscopic laser cordectomy, there were significant changes in phase symmetry (Wilcoxon signed-rang test, $P = 0.014$) and mucosal wave (Wilcoxon signed-rang test, $P = 0.023$) before and 12 months after treatment. In open cordectomy group, significant difference was noted in phase symmetry (Wilcoxon signed-rang test, $P = 0.001$), mucosal wave (Wilcoxon signed-rang test, $P = 0.00$), nonvibratory segment (Wilcoxon signed-rang test, $P = 0.00$), and ventricular activity (Wilcoxon signed-rang test, $P = 0.008$) before and 12 months after treatment.

Average duration of hospitalization for endoscopic laser cordectomy group was 3.3 days and for open cordectomy group 7.5 days. There was a significant difference between groups in postoperative complication occurrence ($\chi^2 = 5.67$, $P = 0.017$). In endoscopic laser cordectomy group, temporary tracheotomy was done postoperatively in only one patient (3.8%). In patients treated with open cordectomy, there was local wound infection in 6.1%. Temporary tracheotomy was done postoperatively in 9.1% of the cases. Postoperatively, subcutaneous emphysema was noted in 6.1% and wound dehiscence in 6.1% of the cases (Table 4).

Five-year overall survival and recurrence-free and disease-specific survival were calculated according to Kaplan-Meier method (Figure 1). The follow-up period for patients was 60 months. Five-year overall survival for open cordectomy patients was 91% and for endoscopic laser cordectomy 96%. The log rank test did not show significant difference between groups (log rank = 0.04; $P > 0.05$). Five patients died during the duration of the study: 3 from cardiovascular diseases and one from pulmonary malignancy and none related with laryngeal malignancy. One patient treated with open cordectomy had anterior commissure recurrence with thyroid cartilage infiltration which required total laryngectomy in further treatment. Postoperatively, radiotherapy was conducted, but 45 months after his first treatment that patient died from laryngeal malignancy. Five-year recurrence-specific survival for open cordectomy patients was 91% and for endoscopic laser cordectomy was 92%, without significant differences between groups (log rank = 0.17; $P > 0.05$). Five-year disease-specific survival for open cordectomy patients was 97% and for endoscopic laser cordectomy was 100%. In three patients with recurrent disease, total laryngectomy was done, mainly due to localization of the recurrent tumor. In these patients, anterior commissure was involved and thyroid cartilage infiltrated, according to control CT scans. Laryngeal preservation was done in two patients, with partial vertical laryngectomies. Deglutition was preserved in all patients. Unilateral resection of ventricular folds which was done in some of the patients treated with types III and IV endoscopic laser cordectomy had no impact on swallowing.

Average values of acoustic parameters with standard deviation before the treatment and 12 months after the treatment are shown in Table 5. Student's t-test was used to compare the difference of average values for each parameter between groups. Values of jitter significantly varied between the groups postoperatively ($Z = 9.941$, $P = 0.003$). Comparing mean values of acoustic parameters before and after treatment, in patients treated with endoscopic laser cordectomy, there were significant changes in values of $F0$ (Student's t-test, $P = 0.007$), jitter (Student's t-test, $P = 0.00$), and shimmer (Student's t-test, $P = 0.001$). Jitter (Student's t-test, $P = 0.00$) and shimmer (Student's t-test, $P = 0.016$) increased significantly postoperatively in patients treated with open cordectomy. NNR increased in both groups, but not significantly.

4. Discussion

Conservation surgery (open or endoscopic laser resection) and radiotherapy are valid options for treating T1a glottic

Table 3: Stroboscopic signs in both groups of patients before treatment and 12 months after the treatment.

Stroboscopic sign	Pretreatment		After 12 months	
	Endoscopic laser cordectomy	Open cordectomy	Endoscopic laser cordectomy	Open cordectomy
Glottic occlusion *n* (%)				
Complete	7 (26.9)	6 (18.2)	10 (38.5)	8 (24.2)
Incomplete	19 (73.1)	27 (81.8)	16 (62.5)	25 (75.8)
	P = 0.421		*P = 0.814*	
Phase symmetry *n* (%)				
Symmetrical	1 (3.8)	0 (0)	3 (11.5)	0 (0)
Asymmetrical	25 (96.2)	33 (100)	18 (69.2)	22 (66.7)
Not assessable	0 (0)	0 (0)	5 (19.3)	11 (33.3)
	P = 0.256		*P = 0.087*	
Mucosal wave *n* (%)				
Normal	4 (15.4)	0 (0)	2 (7.7)	0 (0)
Decreased	22 (84.6)	32 (97)	18 (69.2)	12 (36.4)
Absent	0 (0)	1 (3)	6 (23.1)	21 (63.6)
	*P = 0.047**		*P = 0.008**	
Nonvibratory segment *n* (%)				
Present	18 (69.2)	29 (87.9)	14 (53.9)	19 (57.6)
Absent	8 (30.8)	4 (12.1)	7 (26.9)	0 (0)
Not assessable	0 (0)	0 (0)	5 (19.2)	14 (42.4)
	P = 0.77		*P = 0.003**	
Ventricular activity *n* (%)				
Present	2 (7.7)	3 (9.1)	4 (15.4)	10 (30.3)
Absent	24 (92.3)	30 (90.9)	22 (84.6)	23 (69.7)
	P = 0.848		*P = 0.181*	

*$P < 0.05$.

Table 4: Postoperative complications.

Patient groups	Local infection *n* (%)	Tracheotomy *n* (%)	Emphysema *n* (%)	Wound dehiscence *n* (%)
Endoscopic laser cordectomy	0/26 (0)	1/26 (3.8)	0/26 (0)	0/26 (0)
Open cordectomy	2/33 (6.1)	3/33 (9.1)	2/33 (6.1)	2/33 (6.1)
Total *N* (%)	**2/59 (3.4)**	**4/59 (6.8)**	**2/59 (3.4)**	**2/59 (3.4)**

Table 5: Acoustic parameters in both groups of patients before treatment and 12 months after the treatment.

	Pretreatment (mean ± SD)		After 12 months (mean ± SD)	
	Endoscopic laser cordectomy	Open cordectomy	Endoscopic laser cordectomy	Open cordectomy
*F*0 (Hz)	149.49 ± 21.78	149.62 ± 28.2	144.32 ± 23.1	146.66 ± 26.69
Student's *t*-test	*P = 0.399*		*P = 0.757*	
Jitter (%)	0.52 ± 0.15	0.47 ± 0.15	0.71 ± 0.27	0.56 ± 0.16
Student's *t*-test	*P = 0.684*		*P = 0.003**	
Shimmer (%)	5.78 ± 0.98	5.6 ± 0.97	6.47 ± 1.22	6.02 ± 1.04
Student's *t*-test	*P = 0.341*		*P = 0.238*	
NNE (dB)	−5.41 ± 1.18	−5.92 ± 1.08	−5.6 ± 1.44	−6.05 ± 1.42
Student's *t*-test	*P = 0.127*		*P = 0.75*	

*$P < 0.05$.

lesions, but selection criteria are still subjective [10]. Though radiotherapy is considered the treatment of choice in many European countries, there are a number of recent studies emphasizing the importance of surgery in treatment of early glottic carcinoma [2–4, 11]. Both surgery and radiotherapy provide good locoregional control and satisfactory functional results, so other factors come into consideration when choosing the adequate treatment.

Technical aspects of both treatments are also a consideration. Endoscopic laser cordectomy may not be possible

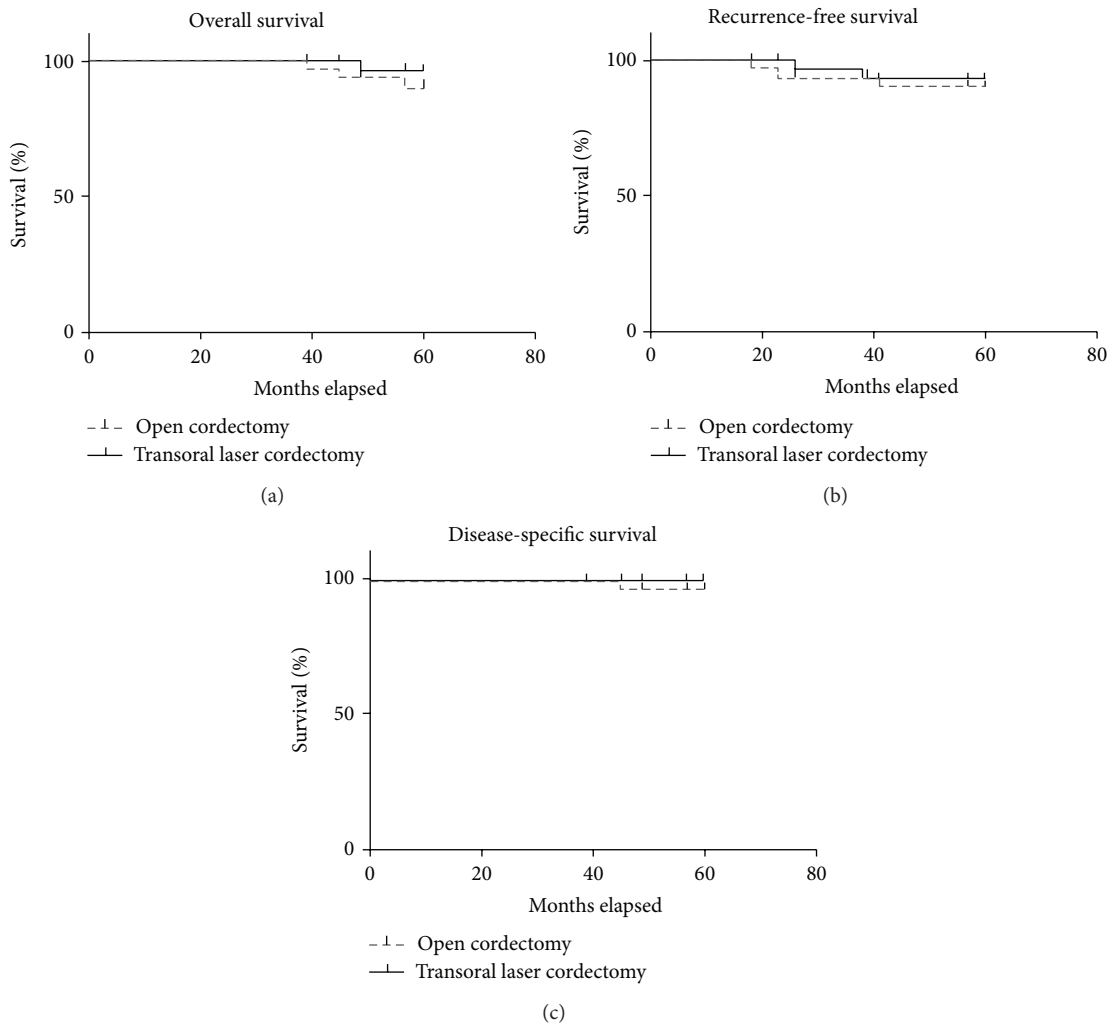

Figure 1: Five-year overall survival and recurrence-free and disease-specific survival.

because of patient morphology or comorbidities, or if a surgeon is inexperienced in the technique. Then, open surgery becomes a valid option. Alternatively, the availability and logistics of 6 to 7 weeks of radiotherapy also become a decision-making factor [7]. In countries with poorer health service, facts such as reliability of follow-up, distance from treatment facility, and significant time delay of radiotherapy because of small number of radiology centers must also be considered [4]. Duration of surgical treatment is considerably shorter comparing to radiotherapy and thus preferred by the patients. Also, surgical treatment, especially endoscopic surgery, is proven to be much more cost effective than radiotherapy [12–14]. From an oncological point of view, recurrent disease after radiotherapy must be treated surgically. In those cases, some authors consider that detection of recurred disease is difficult, due to postradiation edema [15]. This makes conservative surgery highly unlikely, and up to 50% of those patients require total laryngectomy due to the progression of the disease [16]. Larynx preservation, disease-specific survival, and overall survival were significantly less favorable in patients treated initially with radiotherapy [17–19]. Functional results after radiotherapy were poorer comparing to those treated with endoscopic laser resection; both perturbation measures (jitter and shimmer) and aerodynamic parameters were more satisfactory in patients after laser surgery [20–22]. All these facts promote surgical management as a preferable treatment of early glottic carcinoma.

Local disease control for surgical treatment of early glottic carcinoma varies in different studies, from 6% to 11.2% [20, 23, 24]. In our study, recurrent malignancy was noted in 7.7% patients in endoscopic laser cordectomy group and in 9.1% in open cordectomy group. Comparing different surgical approaches, Karatzanis et al. had 5-year disease-specific survival of 96.5% for T1a cases and no statistically significant differences noted between different types of procedures: cordectomy and transoral laser microsurgery [11]. Motta et al. published survival rate of 85% and adjusted survival rate of 97% in 432 T1aN0 M0 patients treated with transoral laser microsurgery. If the outcome was lethal, causes of death were other diseases (9.2%), secondary tumor (7.4%), local recurrence (3.5%), nodal recurrence (0.5%), and distant

metastasis (0.2%) [25]. In our study cause of death was other diseases in 8.47% cases and local recurrence in 1.7%. Five-year overall survival and recurrence-free and disease-specific survival were over 90% for both groups. Complications were more frequent in patients treated with open cordectomy. de Diego et al. [26] in the series of 104 patients treated with cordectomy through laryngofissure had serohematoma in 26.9%, wound infection in 6.7%, postoperative bleeding in 5.8%, wound dehiscence in 3.8%, and pharyngocutaneous fistula in 1% of the patients.

Regarding stroboscopic evaluation, there is a greater incidence of structural abnormalities (scar tissue, granuloma, and anterior commissure web) and functional problems (incomplete closure, abnormal mucosal wave, and vocal fold immobility) in greater resections than in lesser resections, leaving a bigger portion of functional muscle [7, 21]. Development of a vocal fold scar tissue was described 6 months after surgical injury [27]. Improvements in the amplitude of mucosal wave were visible 6 months after the procedure and continue to improve up to 14 months after the procedure [28]. Our clinical assessments by stroboscopy closely correlated with vocal analysis results. Studies examining the vocal parameters in patients treated with laser cordectomy noted that fundamental frequency ($F0$) tends to be higher in patients for more extended resections [22, 29–31]. Postoperatively, the voice changes significantly because of the removal of the vibrating tissue of the vocal cord in patients treated with open cordectomy and laser cordectomy, with lower mass leading to higher fundamental frequencies. In our study, $F0$ showed a tendency of decreasing postoperatively, but these values were still higher than those in normophonic speakers. Functional outcomes were related to the extent of necessary resection and vibratory pattern of the treated vocal fold detected by stroboscopy.

Jitter and shimmer are acoustic characteristics of voice signal and represent cycle-to-cycle variations of fundamental frequency and waveform amplitude, respectively. Values of jitter and shimmer above a certain threshold are considered being related to pathological voices, usually perceived as breathy, rough, or hoarse voices. Stroboscopy postoperatively indicated that vibration symmetry of treated vocal fold was asymmetric or not assessable in most of the cases. This is probably a result of irregular vibration pattern and patients' inability to compensate newly created incomplete glottis occlusion, confirmed by recorded values of jitter and shimmer which were higher in both groups 12 months after the treatment. Also, we detected a higher number of patients with ventricular activity postoperatively. Motta et al. [25] noted the appearance of nonglottal voicing in patients with type IV cordectomies, which was present in our study; out of 6 patients treated with type IV cordectomy, in 4 of them ventricular activity persisted 12 months postoperatively. This also influenced the values of examined vocal parameters postoperatively. Normalized noise energy (NNE, dB) is a parameter influenced by frequency and amplitude variations and highly sensitive to changes in jitter and shimmer. It was suggested that NNE is extremely helpful in assessing breathy voice [32]. Patients treated with open cordectomy had confirmed incomplete glottic occlusion in more cases than the ones treated with endoscopic laser cordectomy. Values of NNE, which directly correlated with the stroboscopically confirmed degree of incomplete glottic occlusion, improved in both groups 12 months after the treatment, with no significant difference between their values. Number of patients with incomplete glottic occlusion was reduced in both groups postoperatively, according to stroboscopic findings, confirmed by the values of NNE.

Open surgery offers very similar oncological and functional results, but with more probable postoperative complications, of which most are manageable. It should be stressed that open cordectomy through laryngofissure is a valuable option for patients not anatomically suitable for endoscopic surgery or for treatment of recurrent disease. In conclusion, endoscopic laser surgery is highly efficient and low-cost procedure and should be considered and proposed as a first choice treatment for early glottic carcinoma.

Conflict of Interests

The authors declare that there is no conflict of interests regarding the publication of this paper.

References

[1] P. Dey, D. Arnold, R. Wight, K. MacKenzie, C. Kelly, and J. Wilson, "Radiotherapy versus open surgery versus endolaryngeal surgery (with or without laser) for early laryngeal squamous cell cancer," *Cochrane Database of Systematic Reviews*, no. 2, Article ID CD002027, 2002.

[2] E. V. Sjögren, R. G. J. Wiggenraad, S. Le Cessie, S. Snijder, J. Pomp, and R. J. B. de Jong, "Outcome of radiotherapy in T1 glottic carcinoma: a population-based study," *European Archives of Oto-Rhino-Laryngology*, vol. 266, no. 5, pp. 735–744, 2009.

[3] C. D. van Gogh, I. M. Verdonck-de Leeuw, J. Wedler-Peeters, J. A. Langendijk, and H. F. Mahieu, "Prospective evaluation of voice outcome duringthe first two years in male patients treated by radiotherapy or laser surgery for T1a glottic carcinoma," *European Archives of Oto-Rhino-Laryngology*, vol. 269, no. 6, pp. 1647–1652, 2012.

[4] J. Milovanovic, V. Djukic, A. Milovanovic et al., "Clinical outcome of early glottic carcinoma in Serbia," *Auris Nasus Larynx*, vol. 40, no. 4, pp. 394–399, 2013.

[5] G. E. Davis, S. R. Schwartz, D. L. Veenstra, and B. Yueh, "Cost comparison of surgery vs organ preservation for laryngeal cancer," *Archives of Otolaryngology—Head and Neck Surgery*, vol. 131, no. 1, pp. 21–26, 2005.

[6] H. E. Eckel, W. F. Thumfart, M. Jungehülsing, C. Sittel, and E. Stennert, "Transoral laser surgery for early glottic carcinoma," *European Archives of Oto-Rhino-Laryngology*, vol. 257, no. 4, pp. 221–226, 2000.

[7] Y. van Loon, E. V. Sjögren, T. P. Langeveld, R. J. B. de Jong, J. W. Schoones, and M. A. van Rossum, "Functional outcomes after radiotherapy or laser surgery in early glottic carcinoma: a systematic review," *Head Neck*, vol. 34, no. 8, pp. 1179–1189, 2012.

[8] M. Remacle, C. van Haverbeke, H. Eckel et al., "Proposal for revision of the European Laryngological Society classification of endoscopic cordectomies," *European Archives of Oto-Rhino-Laryngology*, vol. 264, no. 5, pp. 499–504, 2007.

[9] L. H. Sobin and C. Wittekind, *TNM Classification of Malignant Tumors*, John Wiley & Sons, Hoboken, NJ, USA, 6th edition, 2002.

[10] D. M. Hartl, A. Ferlito, D. F. Brasnu et al., "Evidence-based review of treatment options for patients with glottic cancer," *Head and Neck*, vol. 33, no. 11, pp. 1638–1648, 2011.

[11] A. D. Karatzanis, G. Psychogios, J. Zenk et al., "Comparison among different available surgical approaches in T1 glottic cancer," *Laryngoscope*, vol. 119, no. 9, pp. 1704–1708, 2009.

[12] K. M. Higgins, "What treatment for early-stage glottic carcinoma among adult patients: CO_2 endolaryngeal laser excision versus standard fractionated external beam radiation is superior in terms of cost utility?" *Laryngoscope*, vol. 121, no. 1, pp. 116–134, 2011.

[13] J. H. Brandenburg, "Laser cordectomy versus radiotherapy: an objective cost analysis," *Annals of Otology, Rhinology, and Laryngology*, vol. 110, pp. 312–318, 2001.

[14] K. M. Goor, A. J. G. E. Peeters, H. F. Mahieu et al., "Cordectomy by CO_2 laser or radiotherapy for small T1a glottic carcinomas: costs, local control, survival, quality of life, and voice quality," *Head and Neck*, vol. 29, no. 2, pp. 128–136, 2007.

[15] S. W. Barthel and R. M. Esclamado, "Primary radiation therapy for early glottic cancer," *Otolaryngology—Head and Neck Surgery*, vol. 124, no. 1, pp. 35–39, 2001.

[16] I. Ganly, S. G. Patel, J. Matsuo et al., "Results of surgical salvage after failure of definitive radiation therapy for early-stage squamous cell carcinoma of the glottic larynx," *Archives of Otolaryngology—Head and Neck Surgery*, vol. 132, no. 1, pp. 59–66, 2006.

[17] S. J. Stoeckli, I. Schnieper, P. Huguenin, and S. Schmid, "Early glottic carcinoma: treatment according patient's preference?" *Head and Neck*, vol. 25, no. 12, pp. 1051–1056, 2003.

[18] D. Thurnher, B. M. Erovic, F. Frommlet et al., "Challenging a dogma—surgery yields superior long-term results for T1a squamous cell carcinoma of the glottic larynx compared to radiotherapy," *European Journal of Surgical Oncology*, vol. 34, no. 6, pp. 692–698, 2008.

[19] A. J. Remmelts, F. J. Hoebers, W. M. Klop, A. J. Balm, O. Hamming-Vrieze, and M. W. van den Brekel, "Evaluation of laser surgery and radiotherapy as treatment modalities in early stage laryngeal carcinoma: tumour outcome and quality of voice," *European Archives of Oto-Rhino-Laryngology*, vol. 270, no. 7, pp. 2079–2087, 2013.

[20] M. Policarpo, P. Aluffi, F. Brovelli, G. Borello, and F. Pia, "Oncological and functional results of CO_2 laser cordectomy," *Acta Otorhinolaryngologica Italica*, vol. 24, no. 5, pp. 267–274, 2004.

[21] W. F. McGuirt, D. Blalock, J. A. Koufman et al., "Comparative voice results after laser resection or irradiation of T1 vocal cord carcinoma," *Archives of Otolaryngology—Head and Neck Surgery*, vol. 120, no. 9, pp. 951–955, 1994.

[22] J. Wedman, J.-H. Heimdal, I. Elstad, and J. Olofsson, "Voice results in patients with T1a glottic cancer treated by radiotherapy or endoscopic measures," *European Archives of Oto-Rhino-Laryngology*, vol. 259, no. 10, pp. 547–550, 2002.

[23] H. E. Eckel, "Local recurrences following transoral laser surgery for early glottic carcinoma: frequency, management, and outcome," *Annals of Otology, Rhinology and Laryngology*, vol. 110, no. 1, pp. 7–15, 2001.

[24] M. Ansarin, M. Zabrodsky, L. Bianchi et al., "Endoscopic CO_2 laser surgery for early glottic cancer in patients who are candidates for radiotherapy: results of a prospective nonrandomized study," *Head and Neck*, vol. 28, no. 2, pp. 121–125, 2006.

[25] G. Motta, E. Esposito, S. Motta, G. Tartaro, and D. Testa, "CO_2 laser surgery in the treatment of glottic cancer," *Head and Neck*, vol. 27, no. 7, pp. 566–573, 2005.

[26] J. I. de Diego, M. P. Prim, J. M. Verdaguer, E. Pérez-fernández, and J. Gavilán, "Long-term results of open cordectomy for the treatment of T1a glottic laryngeal carcinoma," *Auris Nasus Larynx*, vol. 36, no. 1, pp. 53–56, 2009.

[27] B. Rousseau, S. Hirano, R. W. Chan et al., "Characterization of chronic vocal fold scarringin a rabbit model," *Journal of Voice*, vol. 18, no. 1, pp. 116–124, 2004.

[28] Y. Kishimoto, S. Hirano, I. Tateya, S.-I. Kanemaru, and J. Ito, "Temporal changes in vocal functions of human scarred vocal folds after cordectomy," *Laryngoscope*, vol. 120, no. 8, pp. 1597–1601, 2010.

[29] I. Vilaseca, P. Huerta, J. L. Blanch, A. M. Fernández-Planas, C. Jiménez, and M. Bernal-Sprekelsen, "Voice quality after CO_2 Laser cordectomy—what can we really expect?" *Head and Neck*, vol. 30, no. 1, pp. 43–49, 2008.

[30] G. P. Ledda, N. Grover, V. Pundir, E. Masala, and R. Puxeddu, "Functional outcomes after CO_2 laser treatment of early glottic carcinoma," *Laryngoscope*, vol. 116, no. 6, pp. 1007–1011, 2006.

[31] J.-L. Roh, D.-H. Kim, Y. K. Sang, and I. P. Chan, "Quality of life and voice in patients after laser cordectomy for Tis and T1 glottic carcinomas," *Head and Neck*, vol. 29, no. 11, pp. 1010–1016, 2007.

[32] P. Mitev and S. Hadjitodorov, "A method for turbulent noise estimation in voiced signals," *Medical and Biological Engineering and Computing*, vol. 38, no. 6, pp. 625–631, 2000.

Hindawi Publishing Corporation
BioMed Research International
Volume 2014, Article ID 738716, 6 pages
http://dx.doi.org/10.1155/2014/738716

Clinical Study

Primary Surgical Therapy for Locally Limited Oral Tongue Cancer

Konstantinos Mantsopoulos, Georgios Psychogios, Julian Künzel, Frank Waldfahrer, Johannes Zenk, and Heinrich Iro

Department of Otorhinolaryngology, Head and Neck Surgery, University of Erlangen-Nuremberg, Waldstraße 1, 91054 Erlangen, Germany

Correspondence should be addressed to Heinrich Iro; heinrich.iro@uk-erlangen.de

Received 31 January 2014; Accepted 26 April 2014; Published 20 May 2014

Academic Editor: Jan Plzak

Objectives. The aim of this study was to assess the efficacy of primary surgical treatment in the management of locally limited oral tongue carcinoma. *Methods*. A retrospective evaluation was carried out for all patients treated with primary surgery for pT1-pT2 oral tongue carcinomas at a tertiary referral center between 1980 and 2005. All cases were assessed for disease-specific survival and local control rates in relation to T classification, N classification, infiltration depth of the primary tumor, and decision making on neck management and adjuvant therapy. The cases were additionally evaluated for the incidence of major complications and tracheotomies. *Results*. 263 cases were assessed. The 5-year disease-specific survival rate was 75.2%. Positive neck disease was shown to be a significant negative prognostic factor. The occult metastasis rate was 20.2%. *Conclusions*. Primary surgical treatment is a very effective modality against T1-T2 oral tongue carcinoma, and a low rate of complications can be anticipated.

1. Introduction

The oral tongue is the subsite most frequently affected by carcinomas in the oral cavity [1]. It is well known that malignant lesions in this region have a strong propensity to develop neck metastases, [2] which are observed even in the early stages of the disease [3].

The management of a cN0 neck in patients with advanced (T3-T4) primary tumors is not an issue, as flap reconstruction and thus neck exploration are required in most cases. The tumors are irradiated in most cases, and the neck can be irradiated together with the oral cavity [2]. However, whether neck management is mandatory (with selective neck dissection or irradiation) in patients with T1-T2 lesions continues to be a matter of debate [1]. Patients with occult metastases may benefit from management of the neck, but the question has not yet been conclusively settled [1, 4].

The purpose of the present study was to evaluate experience in the primary surgical management of local early oral tongue squamous cell carcinomas at a single oncology referral center for head and neck cancers. An additional aim was to obtain information about the regional metastatic behavior of these carcinomas and the different factors influencing it, as this is relevant to decision making regarding neck management. Finally, an analysis of complications and the rate of tracheotomies needed was performed.

2. Materials and Methods

A retrospective study was conducted at an academic tertiary referral center (the Department of Otorhinolaryngology, Head and Neck Surgery, University of Erlangen-Nuremberg, Erlangen, Germany). The files for all patients treated with primary surgery for early (T1 and T2) local oral tongue carcinomas between 1980 and 2005 were evaluated. Patients, who had previously undergone treatment for the same reason and had systemic disease at the time of diagnosis, histological findings other than squamous cell carcinoma, or second primary tumors at the time of diagnosis, were excluded from the study.

All pathology reports were reviewed, and staging was conducted in accordance with the 2010 American Joint

Table 1: Demographic and tumor-specific characteristics of the study patients.

Characteristics	Results
Age (years)	Mean: 57.7, median: 56, and range: 31 to 92
Follow-up (months)	Mean: 73.3, range: 24–300
Gender	Male: 188 (71.5), female: 75 (28.5)
Surgical technique (%)	Transoral laser microsurgery: 30 (11.4), electrocautery: 213 (81), and combined transoral-transcervical approach: 20 (7.6)
Adjuvant treatment (%)	No adjuvant therapy: 109 (41.4), RT: 136 (51.7), and RCT: 18 (6.8)
PT classification (%)	pT1: 132 (50.2), pT2: 131 (49.8)
PN classification (%)	pN0: 133 (50.6), pN1: 25 (9.5), pN2: 48 (18.3), pN3: 12 (4.6), and no neck dissection: 45 (17.1)
Differentiation	Well: 66 (25), moderate: 155 (58.9), poor: 39 (14.8), and not differentiated: 3 (1.1)

Committee on Cancer (AJCC) and Union Internationale Contre le Cancer (UICC) classification [5]. In the TNM staging system, T1 lesions are defined as those in which the largest diameter is 2 cm or less, whereas T2 lesions are larger than 2 cm but not more than 4 cm in their largest diameter. Approval was obtained from the institutional review board of the hospital.

All of the cases were assessed for 5-year overall survival (OS), 5-year disease-specific survival (DSS), and local control (LC) rates in relation to the T classification, N classification, decision on adjuvant therapy, and depth of tumor infiltration. Adjuvant treatment in this series consisted of postoperative radiotherapy (interstitial or percutaneous), either alone or combined with chemotherapy. Typical indications for adjuvant treatment included the presence of positive surgical margins when further surgery was not feasible, advanced neck disease, a tumor infiltration depth of more than 5 mm, extracapsular tumor spread, and infiltration of lymph vessels or nerves on histology. The decision of whether to offer adjuvant therapy was also affected by the choice of surgical management of the neck. Percutaneous irradiation typically included the primary tumor site and both sides of the neck. Interstitial brachytherapy included only the primary tumor site.

OS was estimated from the time of diagnosis to the time of death. DSS was defined using the time from the date of diagnosis to death from the cancer or complications of treatment. The time to LC was calculated from the date of the initial diagnosis to the date of the most recent clinical review at which local recurrence was confirmed. Local recurrence was defined as invasive carcinoma developing at the anatomic site of the primary tumor after completion of the initial treatment. Statistical analysis was performed using the Kaplan-Meier method with 95% confidence intervals. SPSS version 19 for Windows (SPSS Inc., Chicago, IL, USA) was used for statistical analysis. A P value of <0.05 was considered statistically significant.

Major complications were defined as those that required prolonged hospitalization, blood transfusion, additional surgery, or admission to the intensive-care unit. Tracheotomies were considered to be transient when performed intraoperatively or in the immediate postoperative period but later closed. They were considered permanent in cases in which surgical closure was not possible at any time postoperatively.

3. Results

A total of 263 patients were finally included in the study. Among these, 188 were men and 75 women, with a male-female ratio of 2.51 : 1. Their mean age was 57.7 years (range: 31–92 years; SD 11.6). The mean follow-up period was 73.3 months (Table 1). The overall survival (OS) was 56.9%, the DSS was 75.2%, and the LC rate was 86.3% in this series. According to the pathology reports, negative surgical margins (R0 status) were achieved in 260 patients (98.8%). Three patients (1.2%) had positive surgical margins (R+ status) at the end of surgical treatment. These patients refused further surgery. Transoral resection of the tumor was performed in 243 cases (conventional 213, laser 30) and a transoral-transcervical approach was used in 20 cases (Table 1).

A total of 132 patients had pT1 oral tongue tumors (50.2%), while 131 (49.8%) had pT2 tumors. Considering only the group of N0 patients without adjuvant therapy, we found 93 cases (70 T1 and 23 T2 tumors) without any significant difference in the LC rates (81.5 versus 89.8% resp.; $P = 0.874$) (Figure 1). OS was 70.1% for patients with T1 oral tongue cancer and 40.4% for those with T2 tumors ($P = 0.4$). The DSS was 89.6% in the T1 group and 69.3% in the T2 group ($P = 0.189$). The LC rates were 83.5% and 81.8%, respectively ($P = 0.41$).

From the 263 patients of our study, 118 were cN0 and 145 were cN+. In the cN0 group, OS was 66.7% and DSS was 81.6%. In the cN+ group, OS was 49.4% and DSS was 70.2%. Positive lymph nodes (pN+) were found in 85 of the 263 patients (32.3%). If only the 218 cases with neck dissection are taken into account, the metastasis rate was higher (38.9%). In the subgroup of these 218 cases OS was 64.9% for patients with pN0 status and 43.4% for those with pN+ status ($P = 0.000$). The DSS was 86.0% in the pN0 group and 58.4% in the pN+ group ($P = 0.000$) (Figure 2).

Neck dissection was performed in 79 of the 118 patients with cN0 status (in 70 cases unilaterally and in 9 cases on both sides). Of these 79 patients, 16 had pN+ status (eight with pN1, one with pN2a, and seven with pN2b). The rate of occult metastasis was thus 20.2%. In the group with occult

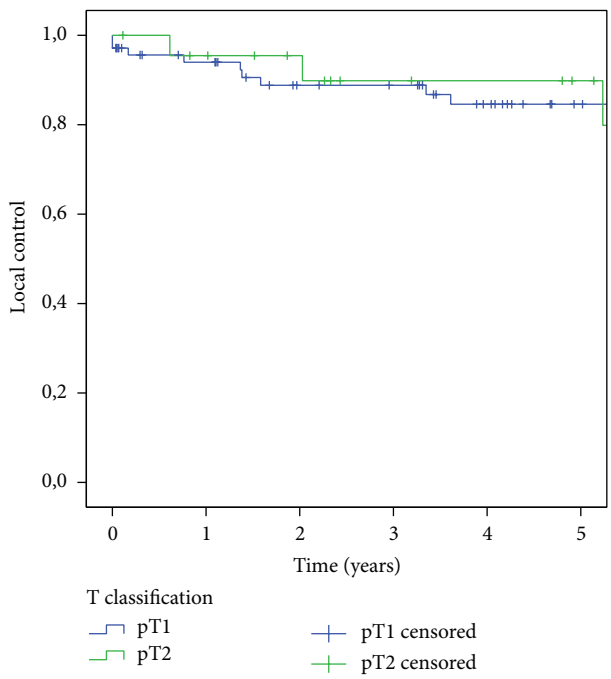

Figure 1: Kaplan-Meier analysis of disease-specific survival relative to T status in the group of N0 patients without adjuvant therapy.

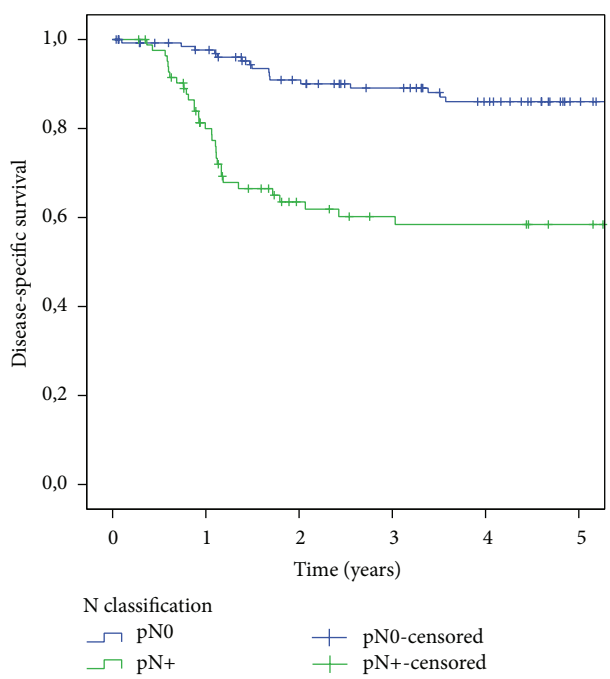

Figure 2: Kaplan-Meier analysis of disease-specific survival relative to N status.

metastases, OS and DSS were 68.2%. No significant influence of the T classification on the rate of occult metastases was noted ($P = 0.617$). Occult metastases on the contralateral neck side were found in one of the 9 patients receiving a bilateral neck dissection (11.1%).

Table 2: Incidence rate of positive nodal disease relative to the infiltration depth of small carcinomas of the mobile tongue.

Infiltration depth	Number of patients (%) with overall positive nodal disease by infiltration depth
<2 mm	3/15 (20)
<3 mm	8/30 (26.6)
<4 mm	16/54 (29.6)
<5 mm	20/68 (29.4)
<6 mm	28/92 (30.4)
<7 mm	32/106 (30.2)
<8 mm	42/128 (32.8)

Six patients had metastases on the contralateral neck side (two with pT1 tumors and four with pT2 tumors). An analysis of these patients' characteristics showed that five of the six (83.3%) had cN2c status preoperatively, while all of them (100%) already had metastases on the ipsilateral neck side. Five of them (83.3%) also had infiltration of the midline of the oral tongue; only one, thus, had a strictly contralateral metastasis.

Exclusively surgical treatment was carried out in 109 of the patients (41.4%), and 154 patients (58.6%) received combined therapy (primary surgery and adjuvant percutaneous radiotherapy/brachytherapy in 136 cases; primary surgery and chemoradiotherapy in 18 cases). The OS rate was 55.4% in the first group and 57.8% for those with combined therapy. The DSS rates were 74.8% and 75.4%, respectively. The LC rates were 82.3% and 89%, respectively ($P = 0.147$).

46 patients (17.5%) required reoperation (twice in 45 patients; three times in one case). Patients with one operation in the primary site had an OS of 61.7%, while the rate in those with more operations was 47.9% ($P = 0.072$). The DSS was 81.3% in the first group and 60.5% in the second ($P = 0.008$). The LC rates were 89.2% in the first group and 76.4% in the second (0.079).

Patients with an infiltration depth of less than 5 mm (68/263, 25.9%) had an OS of 70.8%, while the rate in those with an infiltration depth ≥5 mm (195/263, 74.1%) was 48.2% ($P = 0.013$). The DSS was 90.3% in the first group and 76.5% in the second ($P = 0.03$; Figure 3). The LC rates were 96.3% in the first group and 87.3% in the second ($P = 0.108$). In total, 16 patients (10 T2 and 6 T1) with an infiltration depth of 5 mm or less and cN0 status underwent neck dissection. In this group, three (2/10 T2 and 1/6 T1) had occult metastases (in total 18.8%). Of the 63 patients (43 T2 and 20 T1) with an infiltration depth of more than 5 mm and cN0 status who underwent neck dissection, 13 (20.6%) had occult metastases (9/43 T2 and 4/20 T1). This means that the incidence of occult metastases in the T1 group was 16.7% by an infiltration depth <5 mm and 20% over 5 mm. The incidence rates of positive nodal disease in the different patient groups relative to the infiltration depth are shown in Table 2. No statistically significant differences were observed between the different groups with regard to regional metastatic behavior.

Major complications in this series included bleeding, aspiration, fistula formation, wound healing problems, and

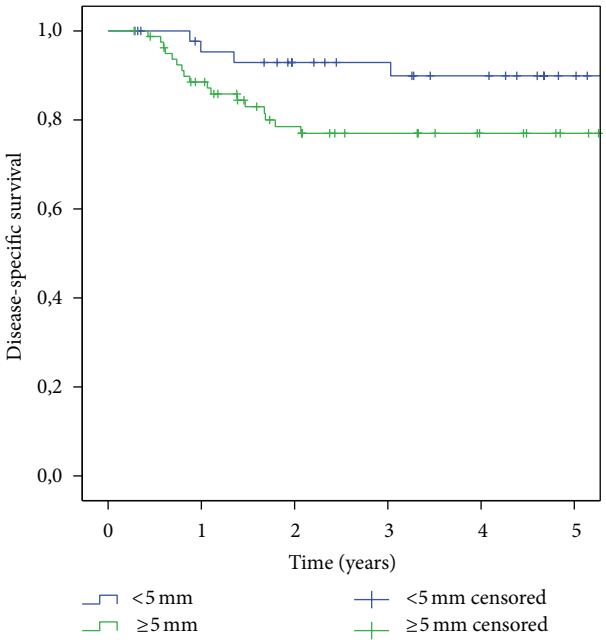

Figure 3: Kaplan-Meier analysis of disease-specific survival relative to infiltration depth.

Table 3: Specific types and incidence of surgical complications.

Complication	Number of complications (%)
Bleeding	10 (3.8)
Aspiration	2 (0.7)
Fistula	2 (0.7)
Wound healing disorders	1 (0.7)
Nerve lesions	3 (1.1)
Other complications	2 (0.7)

nerve injury. None of these complications was fatal. A detailed presentation is given in Table 3. The overall incidence of complications was 7.6%. Permanent tracheotomies were necessary in two cases (0.7%) and temporary tracheostomies in four cases overall (1.4%).

4. Discussion

A review of the relevant literature shows that early local oral tongue carcinomas present a clinical dilemma, due to the lack of prospective randomized trials [6]. To the best of our knowledge, the case series of surgically managed early local oral tongue carcinomas presented here is the largest in the literature to date. The relatively high rates of disease-specific survival (75.2%) and local control (86.3%) in the analysis, together with the low complication rate (7.6%) and the extremely low number of tracheotomies, support the hypothesis that surgery can provide an effective and safe cure for these cases without significant compromises in relation to the posttherapeutic quality of life.

Neck dissection was performed in 218 of the 263 patients in the study sample (82.9%). Forty-five patients (17.1%) did not receive surgical neck treatment, either because they declined therapy or because they had comorbid medical problems. According to the literature, positive nodal disease is one of the most influential prognostic factors in patients with head and neck carcinomas [7–9] This was confirmed by the present analysis: positive neck disease (pN+) was detected in 34.2% of our cases and was associated with a poorer prognosis, affecting the overall and disease-specific survival rates to a highly significant extent. Interestingly, according to the present analysis, a patient suffering from a small carcinoma of the oral tongue with regional metastases is 4.2 times more likely to die of the disease during the year following the completion of therapy in comparison with a patient with N0 status. This emphasizes the crucial need for management of the cervical lymph nodes with neck dissection or irradiation, even in patients with local early carcinomas.

The management of the neck in patients with cN0 status continues to be a matter of controversy [4, 10]. In general, the "principle of 15–20%" [4, 11, 12] (referring to the incidence of occult metastases) represents an acceptable compromise between the morbidity of elective neck dissection and the need for salvage treatment later on [13]. According to the relevant literature, the rate of occult metastases in patients with early local oral tongue carcinomas can be as high as 42% [14, 15]. An overall occult metastasis rate of 20.2% was noted in the present study, higher than the "threshold" mentioned above, and thus generally suggesting a need for elective neck management (in the form of neck dissection or irradiation) in all early local oral tongue carcinomas patients with cN0 status, in accordance with similar studies [16].

Our analysis showed that the majority of early local oral tongue carcinomas (97.3%) were strictly lateral lesions, with no involvement of the tip or midline of the tongue. Six of the 263 cases (2.3%) had metastases on the other side, and this was not influenced by the size of the primary tumor. All six patients already had suspect nodes preoperatively on the same side, all but one with infiltration of the midline. It might therefore be argued that management of the contralateral neck side in patients with early local oral tongue carcinomas could possibly be reserved for clinical N2c status or for lesions with infiltration of the tip or midline of the tongue.

Franceschi et al. suggested that treatment of the primary tumor site and ipsilateral elective neck management in patients with lingual carcinomas may predispose toward tumor cell migration to the opposite side of the neck [17]. Only sparse literature reports on this topic have been published to date. Lim et al. reported an occult nodal disease rate of 4% on the contralateral side, with no benefit from contralateral elective neck dissection in comparison with "watchful waiting" [16]. In the present series, occult metastases on the contralateral neck side were found in only one case (1.7%). If only the cases with bilateral neck dissection are examined, the occult contralateral metastases rate remains remarkably low (11.1%). Adequate examination of the neck region (with palpation and imaging studies) might possibly be able to reduce the incidence of occult neck disease on the contralateral side. Patient compliance should always be

taken into consideration, of course, and regular follow-up is essential.

In an effort to detect subgroups in the present study in which it might be possible to avoid ipsilateral neck management (the associated morbidity of which is not negligible), the incidence of occult nodal disease was investigated in relation to different primary tumor characteristics. A smaller primary tumor size (T1) was not associated with a significantly lower rate of occult metastases. Furthermore, almost 19% of the patients with an infiltration depth of 5 mm or less already had subclinical nodal disease. The number of T1 with an infiltration depth of 5 mm or less who underwent a neck dissection was extremely low in our study sample, so that no safe conclusions as to avoidance of neck management in this subgroup can be drawn. It is though remarkable that even the smallest primary tumors of our study sample had an occult metastasis rate of almost 17%! These data indicate the aggressiveness of the disease at this primary site and suggest that elective neck dissection cannot be avoided—particularly in view of the value of neck management as a staging procedure [8, 9].

With regard to the oncologic parameters of the study, no statistically significant differences were found between patients with and without adjuvant therapy. The absence of differences might be due to the fact that patients who received combined therapy usually had poorer prognostic characteristics, such as advanced neck disease or a tumor infiltration depth of more than 5 mm. Carrying out adjuvant therapy may therefore have contributed to eliminating possibly significant differences due to these negative prognostic factors. It should be emphasized that a lack of homogeneity with regard to different protocols of adjuvant treatment may be regarded as a limitation of the present analysis.

Interestingly, our analysis showed that patients with R0-situation after more than one surgical procedure on the primary site had significantly poorer oncologic parameters in comparison with "single-operation" patients. These data point to the fact that a subsequent reoperation, if dictated by permanent histology, will carry a negative effect on local disease control and survival of the patients. It is, therefore, highly recommended to take this aspect into consideration and always try to achieve R0-situation in local early oral tongue carcinomas by means of one operation.

Among head and neck cancers, the oral cavity is the location in which tumor parameters such as infiltration depth and tumor thickness have been most studied [6]. Some authors measure it from the deepest point of invasion to the most protruding tumor surface [18], whereas others define it as the distance from the deepest tumor invasion point to an imaginary line along the adjacent healthy mucosa [19, 20]. In the present authors' view, using a virtual line along the adjacent healthy mucosa and thus measuring only the endophytic part of the lesion could provide a more precise estimate of the aggressiveness of the tumor, as has also been proposed by Gonzalez-Moles et al. [6] With tumor infiltration depth defined as described above, it was found that a cut-off level of 5 mm is decisive for the course of the disease, with significantly poorer OS and DSS and a trend toward more frequent local recurrence in more deeply infiltrating carcinomas. The latter might possibly be explained by the difficulty of assessing the deep tumor margin accurately with palpation during tumor resection, potentially with a greater likelihood of inadequate resection margins in the deep layers of surgical dissection [21]. The gradual increase in the rate of regional metastases in deeper primary lesions might be explained by the fact that microinvasion or contraction of the lingual musculature promotes the entry of cancer cells into the lymphatics [21]. Even with superficial lesions (<5 mm), our analysis showed a remarkably high overall positive node rate (29.4%, Table 2) and a not negligible rate of occult metastases (18.8%), so that a primary aggressive approach toward neck management appears to be justified in all cases, irrespective of the infiltration depth. The analysis thus does not support the approach of waiting for the pathology report on the tumor specimen before a decision is made on neck management. The considerable advantages of treating the primary site and the regional lymphatic system in one surgical procedure (with less morbidity) should be emphasized [21]. According to our study results, preoperative estimation of the tumor infiltration depth (e.g., through palpation or imaging studies) does not appear to be crucial for the planning of neck management and could be possibly used only to assess the prognosis. This approach may, of course, involve a risk of overtreatment in some patients, [14] and individualization of treatment (ensuring a high level of patient compliance and regular follow-up) is therefore a reasonable and not suboptimal approach.

5. Conclusions

Critical analysis of our data supported the hypothesis that surgery can provide an effective and safe cure for these cases without significant compromises in relation to the posttherapeutic quality of life. Positive neck disease was associated with a significantly poorer prognosis. A noted overall occult metastasis rate of 20.2% generally suggested a need for elective neck management (in the form of neck dissection or irradiation) in cN0 cases. Furthermore, R0-situation after more than one surgical procedure was shown to have significantly poorer oncologic parameters in comparison with "single-operation" patients. Interestingly, it was found that a cut-off level of 5 mm is decisive for the course of the disease, with significantly poorer survival rates and a trend toward more frequent local recurrence in more deeply infiltrating carcinomas. Nevertheless, a primary aggressive approach toward neck management appears to be justified in all cases, irrespective of the infiltration depth.

Conflict of Interests

The authors declare that there is no conflict of interests regarding the publication of this paper.

Authors' Contribution

Konstantinos Mantsopoulos and Georgios Psychogios contributed equally to this paper.

Acknowledgment

The authors are grateful to Mr. Philipp Grundtner for statistical analysis of the data. The authors acknowledge the support of Deutsche Forschungsgemeinschaft and Friedrich-Alexander-Universität Erlangen-Nürnberg (FAU) within the funding programme Open Access Publishing.

References

[1] M. J. Veness, G. J. Morgan, Y. Sathiyaseelan, and V. Gebski, "Anterior tongue cancer and the incidence of cervical lymph node metastases with increasing tumour thickness: should elective treatment to the neck be standard practice in all patients?" *ANZ Journal of Surgery*, vol. 75, no. 3, pp. 101–105, 2005.

[2] A. P. W. Yuen, K. Y. Lam, L. K. Lam et al., "Prognostic factors of clinically stage I and II oral tongue carcinoma—a comparative study of stage, thickness, shape, growth pattern, invasive front malignancy grading, Martinez-Gimeno score, and pathologic features," *Head and Neck*, vol. 24, no. 6, pp. 513–520, 2002.

[3] A. P. W. Yuen, K. Y. Lam, A. C. L. Chan et al., "Clinicopathological analysis of elective neck dissection for no neck of early oral tongue carcinoma," *American Journal of Surgery*, vol. 177, no. 1, pp. 90–92, 1999.

[4] G. Psychogios, K. Mantsopoulos, C. Bohr, M. Koch, J. Zenk, and H. Iro, "Incidence of occult cervical metastasis in head and neck carcinomas: development over time," *Journal of Surgical Oncology*, vol. 107, no. 4, pp. 384–387, 2013.

[5] M. Gospodarowitz, C. Wittekind, and L. Sobin, "AJCC cancer staging manual," in *TNM Classification of Malignant Tumours*, John Wiley & Sons, New York, NY, USA, 2009.

[6] M. A. Gonzalez-Moles, F. Esteban, A. Rodriguez-Archilla, I. Ruiz-Avila, and S. Gonzalez-Moles, "Importance of tumour thickness measurement in prognosis of tongue cancer," *Oral Oncology*, vol. 38, no. 4, pp. 394–397, 2002.

[7] J. F. Teichgraeber and A. A. Clairmont, "The incidence of occult metastases for cancer of the oral tongue and floor of the mouth: treatment rationale," *Head and Neck Surgery*, vol. 7, no. 1, pp. 15–21, 1984.

[8] K. Mantsopoulos, G. Psychogios, F. Waldfahrer, J. Zenk, and H. Iro, "Surgical treatment of locally limited tonsillar cancer," *Surgical Oncology*, vol. 21, no. 1, pp. e13–e16, 2012.

[9] K. Mantsopoulos, G. Psychogios, C. Bohr et al., "Primary surgical treatment of T3 glottic carcinoma: long-term results and decision-making aspects," *The Laryngoscope*, vol. 122, no. 12, pp. 2723–2727, 2012.

[10] G. Psychogios, K. Mantsopoulos, M. Koch et al., "Elective neck dissection vs observation in transorally treated early head and neck carcinomas with cN0 neck," *Acta Oto-Laryngologica*, vol. 133, no. 3, pp. 313–317, 2013.

[11] M. H. Weiss, L. B. Harrison, and R. S. Isaacs, "Use of decision analysis in planning a management strategy for the stage NO neck," *Archives of Otolaryngology—Head and Neck Surgery*, vol. 120, no. 7, pp. 699–702, 1994.

[12] K. T. Pitman, "Rationale for elective neck dissection," *American Journal of Otolaryngology*, vol. 21, no. 1, pp. 31–37, 2000.

[13] A. Sparano, G. Weinstein, A. Chalian, M. Yodul, and R. Weber, "Multivariate predictors of occult neck metastasis in early oral tongue cancer," *Otolaryngology—Head and Neck Surgery*, vol. 131, no. 4, pp. 472–476, 2004.

[14] P. O-charoenrat, G. Pillai, S. Patel et al., "Tumour thickness predicts cervical nodal metastases and survival in early oral tongue cancer," *Oral Oncology*, vol. 39, no. 4, pp. 386–390, 2003.

[15] C. M. Ho, K. H. Lam, W. I. Wei, S. K. Lau, and L. K. Lam, "Occult lymph node metastasis in small oral tongue cancers," *Head and Neck*, vol. 14, no. 5, pp. 359–363, 1992.

[16] Y. C. Lim, J. S. Lee, B. S. Koo, S.-H. Kim, Y.-H. Kim, and E. C. Choi, "Treatment of contralateral N0 neck in early squamous cell carcinoma of the oral tongue: elective neck dissection versus observation," *Laryngoscope*, vol. 116, no. 3, pp. 461–465, 2006.

[17] D. Franceschi, R. Gupta, R. H. Spiro, and J. P. Shah, "Improved survival in the treatment of squamous carcinoma of the oral tongue," *American Journal of Surgery*, vol. 166, no. 4, pp. 360–365, 1993.

[18] B. Brown, L. Barnes, J. Mazariegos, F. Taylor, J. Johnson, and R. L. Wagner, "Prognostic factors in mobile tongue and floor of mouth carcinoma," *Cancer*, vol. 64, no. 6, pp. 1195–1202, 1989.

[19] J. N. Myers, T. Elkins, D. Roberts, and R. M. Byers, "Squamous cell carcinoma of the tongue in young adults: increasing incidence and factors that predict treatment outcomes," *Otolaryngology—Head and Neck Surgery*, vol. 122, no. 1, pp. 44–51, 2000.

[20] T. Asakage, T. Yokose, K. Mukai et al., "Tumor thickness predicts cervical metastasis in patients with stage I/II carcinoma of the tongue," *Cancer*, vol. 82, no. 8, pp. 1443–1448, 1998.

[21] A. P. W. Yuen, K. Y. Lam, W. I. Wei et al., "A comparison of the prognostic significance of tumor diameter, length, width, thickness, area, volume, and clinicopathological features of oral tongue carcinoma," *American Journal of Surgery*, vol. 180, no. 2, pp. 139–143, 2000.

Hindawi Publishing Corporation
BioMed Research International
Volume 2014, Article ID 346873, 7 pages
http://dx.doi.org/10.1155/2014/346873

Research Article

Management of Anterior Skull Base Defect Depending on Its Size and Location

Manuel Bernal-Sprekelsen,[1,2] Elena Rioja,[3] Joaquim Enseñat,[4] Karla Enriquez,[1] Liza Viscovich,[1] Freddy Enrique Agredo-Lemos,[2,5] and Isam Alobid[1]

[1] *Department of ORL-HNS, Hospital Clinic, University of Barcelona Medical School, 08036 Barcelona, Spain*
[2] *Department of ORL-HNS, Rhinology and Skull Base Unit, Hospital Clínic, University of Barcelona Medical School, 08036 Barcelona, Spain*
[3] *Department of ORL-HNS, Althaia Xarxa Assistencial de Manresa, 08243 Manresa, Spain*
[4] *Department of Neurosurgery, Hospital Clínic de Barcelona, 08036 Barcelona, Spain*
[5] *Universidad del Valle, 76000 Cali, Colombia*

Correspondence should be addressed to Manuel Bernal-Sprekelsen; mbernal@clinic.ub.es

Received 25 February 2014; Revised 11 April 2014; Accepted 13 April 2014; Published 7 May 2014

Academic Editor: Jan Plzák

Introduction. We present our experience in the reconstruction of these leaks depending on their size and location. *Material and Methods*. Fifty-four patients who underwent advanced skull base surgery (large defects, >20 mm) and 62 patients with CSF leaks of different origin (small, 2–10 mm, and midsize, 11–20 mm, defects) were included in the retrospective study. Large defects were reconstructed with a nasoseptal pedicled flap positioned on fat and fascia lata. In small and midsized leaks. Fascia lata in an *underlay* position was used for its reconstruction covered with mucoperiosteum of either the middle or the inferior turbinate. *Results*. The most frequent etiology for small and midsized defects was spontaneous (48.4%), followed by trauma (24.2%), iatrogenic (5%). The success rate after the first surgical reconstruction was 91% and 98% in large skull base defects and small/midsized, respectively. Rescue surgery achieved 100%. *Conclusions*. Endoscopic surgery for any type of skull base defect is the gold standard. The size of the defects does not seem to play a significant role in the success rate. Fascia lata and mucoperiosteum of the turbinate allow a two-layer reconstruction of small and midsized defects. For larger skull base defects, a combination of fat, fascia lata, and nasoseptal pedicled flaps provides a successful reconstruction.

1. Introduction

Cerebrospinal fluid (CSF) leaks may be continuous or intermittent. Dura and arachnoid membranes need to be interrupted and usually there is a bony defect too. Patients with a skull base defect are at risk of suffering ascending bacterial meningitis by over 10% per year, independently of the size or location of that defect [1, 2]. Intermittent leakage may be difficult to assess. Different reconstructive techniques have been described to close skull base defects and termed "onlay," "overlay," "underlay," and "inlay" procedures. Also, different materials, mainly autologous, have been used for the reconstruction. All of them seem to work well.

Among frequent symptoms one may find a watery rhinorrhea, mainly unilateral, and sometimes headaches when the fistula is associated with a meningocele or ascending meningitis [3]. The most frequent location of the leak is the cribriform plate followed by ethmoidal roof, sphenoid, frontal sinus, sella turcica, and clivus [1].

With the advent of extended endoscopic skull base resections, the need for large reconstructions has increased, including those of high pressure/high flow leaks communicating with the 3rd ventricle. For these CSF leaks the recurrence rate was above 30%, questioning the advantages of expanded endoscopic skull base approaches. Since the description of the pedicled nasoseptal flap [4] the incidence of

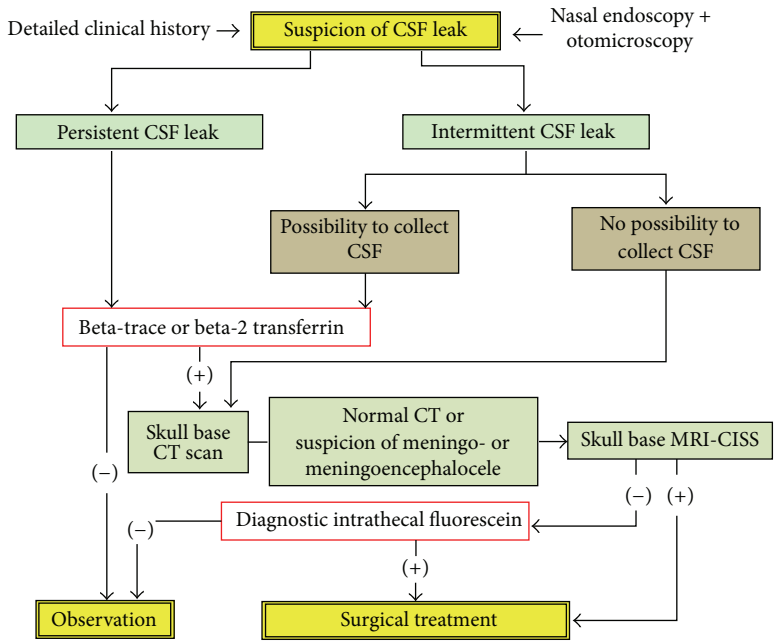

Figure 1: Algorithm of the management of CSF leaks. CISS = constructive interference in steady state.

postoperative CSF leaks could be considerably reduced down from 33% to 5.4% [5].

The goal of our retrospective study is to evaluate the rate of effective closure of our skull base defects depending on their size and location in order to establish an algorithm for the diagnosis and treatment.

2. Material and Methods

Patients that underwent an endoscopic skull base reconstruction between February 1998 and January 2013 were included. A retrospective chart review was performed to assess causes, location, type of presentation, preoperative studies, intraoperative findings, and surgical technique of reconstruction.

Patients were divided into two groups.

Group 1. Patients undergoing expanded endoscopic skull base surgery for intracranial pathology between 2007 and 2013 were included (large skull base defects, >20 mm). Patients undergoing pituitary surgery were excluded from evaluation.

Group 2. Patients with rhinoliquorrhea of other origins operated on between 1998 and 2013 were included (small defects, between 2 and 10 mm, and medium-sized defects ranging between 11 and 20 mm). For the diagnosis and management of these cases a protocol has been established (Figure 1).

In both groups antibiotic prophylaxis consisted in intravenous administration of ceftriaxone for 5–7 days. In allergic patients levofloxacin and trimethoprim/sulfamethoxazole were considered appropriate alternatives.

Group 1 undergoing expanded skull base surgery included 54 patients suffering from different tumors involving the skull base. All patients underwent CAT scan and MRI.

2.1. Technique of Surgical Reconstruction for Group 1. Lumbar drainage was carried out before starting the endoscopic surgery and harvesting of suprapubic fat, particularly in cases in which a high flow CSF leak was expected. A pedicled nasoseptal flap was created [4]. Side and size of the flap depended on the calculated defect. After tumor removal, the suprapubic fat served to fill dead spaces between the brain and the dura. The fat was then covered with lyophilized fascia lata (TSF, Barcelona, Spain) in an "*underlay*" position, that is, between the fat and on the bone of the remnant skull base in the epidural space. The nasoseptal flap covered the bony borders of the defect and was fixed either with blood and Surgicel© or with fibrin glue, the latter not being mandatory. A finger cot packing was used to avoid adherences (Figures 2(a) and 2(b)).

Patients stayed in bed for 72 h with an antithrombotic prophylaxis. Blowing the nose or sneezing with open mouth was forbidden. In order to avoid increased abdominal pressure diet rich in fibers was provided and sometimes a laxative was prescribed. Packing was withdrawn 24–48 hours after surgery, and the lumbar drainage took place after 72–96 hours in case no sign of an active fistula was observed. In case of suspicion of a CSF leak, intrathecal fluorescein application through the lumbar drainage was performed as a diagnostic procedure. CAT scan or MRI was scheduled after 24 hours to rule out intracranial bleeding or pneumoencephalus.

2.2. Technique of Surgical Reconstruction for Group 2. Group 2 underwent a more limited endoscopic revision of mainly the anterior skull base. All patients with a spontaneous

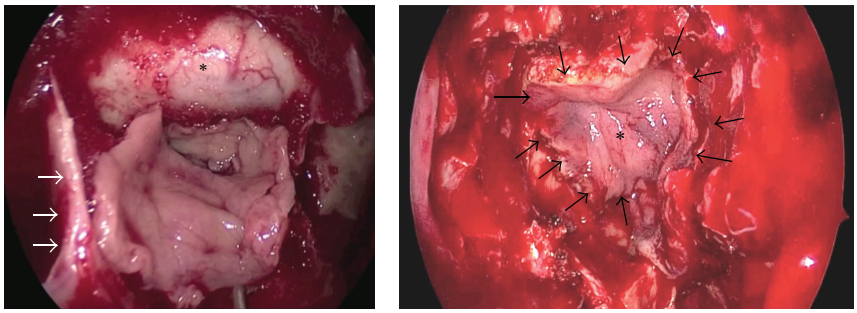

(a) (b)

Figure 2: (a) Nasoseptal pedicled flap dissected from the left side. Arrows pointing to remnant of the inferior aspect of the vomer and *dura. (b) Nasoseptal flap (∗) positioned over the skull base. Arrow pointing at the edges of the flap.

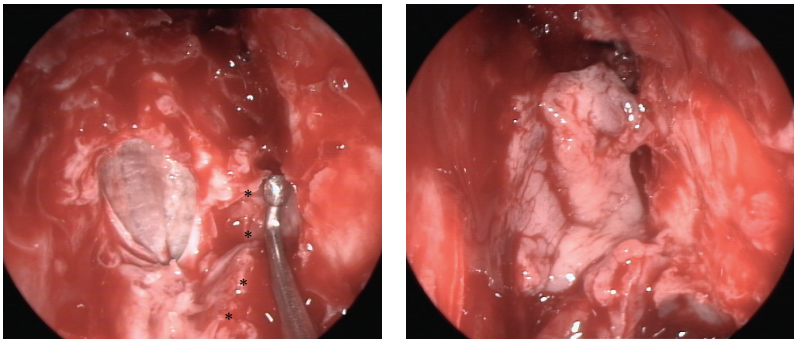

(a) (b)

Figure 3: Reconstruction of a defect at the left cribriform plate. (a) Fascia lata introduced in an overlay position. Intracranial pressure and pulsations end up pushing the fascia onto the dura. Middle turbinate resected (∗ indicating its original attachment). (b) Free mucosal graft from the middle turbinate.

CSF leak were submitted to an ophthalmologic exploration in order to rule out benign endocranial hypertension. All patients underwent a CAT scan of the paranasal sinuses and anterior skull base in 1 mm slices, which allowed assessment of the skull base defect preoperatively. In cases with suspicion of a meningocele or meningoencephalocele an additional cranial MRI was performed. Biochemical conformation of CSF was performed by means of beta-2 transferrin until 2005, and after that period the beta-trace protein kit was introduced. Measurement of the skull base defect was accomplished with the help of the CAT scans and, intraoperatively, with the branches of a 45° Blakesley forceps on the defect.

Around 1 hour before surgery 0.5–1 mL of 5% sodium fluorescein was applied intrathecally. Dilution was performed with distilled water. Fluorescein was found to be helpful in identifying the skull base defect and to confirm the watertight reconstruction. Once the bony borders of the defect were identified the surrounding mucosa was elevated. Meningoceles or meningoencephaloceles were reduced with bipolar forceps until the skull base level. Lyophilized fascia lata (TSF, Barcelona, Spain) was positioned "underlay" (between the bone and the dura) and covered with a free mucosal graft, usually harvested from the middle turbinate and occasionally from the inferior turbinate. At the cribriform plate, a true "underlay" technique is only feasible laterally. Thus, the fascia lata was positioned "onlay" (or "inlay") and the medial aspect rotated towards the crista galli. The mucosal or mucoperiosteal graft from the turbinate is around 30% larger than the defect and once introduced it is surrounded by Surgicel or similar material to promote granulation tissue formation (Figures 3(a) and 3(b)). A finger cot packing is used at the end. No lumbar drainage was used in any of these defects.

3. Results

3.1. Group with Expanded Skull Base Surgery (n = 54). This group included 66% female of mean age 47.7 ± 15.5, range 22–82 years. Table 1 displays the different surgical approaches. A pedicled nasoseptal flap was harvested in 42 cases (78%) from the left side and the remnant from the right side. Five patients (9%) displayed clear symptoms of meningitis or outbreak postoperatively. In all an active CSF leak was evidenced and surgically repaired (3 patients with a pedicled nasoseptal flap and 2 with a pedicled rescue flap from the floor of the nose). During the follow-up of a mean of 15.6 ± 12.4 months (range 6–62 months) no recurrence of the CSF leak could be observed.

Figures 4 and 5 show a postoperative result after skull base reconstruction with a pedicled nasoseptal flap.

Table 1: Type of skull base approach depending on the lesion.

Expanded endoscopic skull base approach	Final diagnosis
Transcribriform	Meningioma olfactory fossa ($n = 2$)
	Esthesioneuroblastoma ($n = 2$)
	Sinonasal carcinoma ($n = 4$)
Transtuberculum/transplanum	Meningioma planum sphenoidale ($n = 5$)
	Craniopharyngeoma ($n = 6$)
	Sarcoma ($n = 1$)
	Meningioma tuberculum sellae ($n = 4$)
	Rathke's cyst ($n = 2$)
	Suprasellar adenoma ($n = 1$)
	Polycystic astrocytoma ($n = 1$)
Transclival	Chordoma ($n = 7$)
	Chondrosarcoma ($n = 3$)
	Myxofibrosarcoma ($n = 1$)
	Fibrous dysplasia ($n = 1$)
	Inflammatory pseudotumor ($n = 1$)
	Petroclival meningioma ($n = 3$)
	Nasopharyngeal tumor x with extension to clivus ($n = 2$)
	Squamous cell carcinoma ($n = 2$)
Ethmoidal-pterigo-sphenoidal	Adenoma with extension to cavernous sinus ($n = 3$)
	Neurofibroma ($n = 1$)
Transorbital	Neurofibroma ($n = 1$)
Transpalatal	Congenital benign teratoma ($n = 1$)

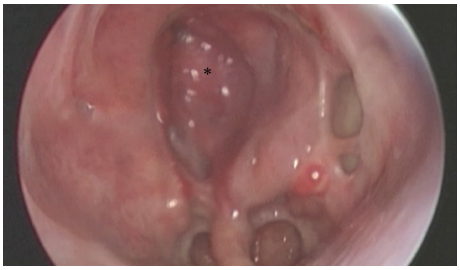

Figure 4: Same patient as in Figure 2(a) 4 months after reconstruction. Note the missing septum (vomer remnant inferiorly and the choanal border). *Reconstructed area of the nasoseptal flap.

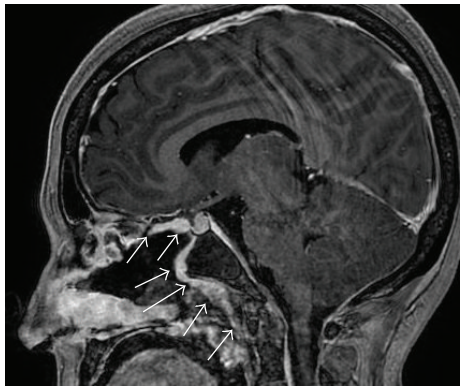

Figure 5: Sagittal view of the reconstructed planum sphenoidale, pituitary, and clivus. Note the enhancement of the perfusion of the pedicled nasoseptal flap (arrows).

3.2. Group with CSF Leaks of Other Origin ($n = 62$). Sixty-two patients (52% women of mean age 48.8 ± 14.1, range 20–80 years) presented with a CSF leak, with unilateral watery rhinorrhea being the most frequent symptom. Five patients had a bilateral watery rhinorrhea as their leak was located in the sphenoid sinus ($n = 4$) or because of a septal perforation ($n = 1$). History of ascending bacterial meningitis was positive in 20 cases (32%), and 2 patients suffered from repeated meningitis. The most frequent aetiology was "spontaneous" in almost half of the study group, followed by trauma and surgery (Table 2). The cribriform plate concentrated half of the cases, followed by the ethmoid roof, sphenoid, and frontal sinuses (Table 3). The size of the defects ranged from 2 to 20 mm. Intrathecal application of sodium fluorescein was performed in all cases. Two patients developed temporary intense headaches and another one temporary weakness and paresthesia of the legs. The "underlay" reconstruction (material positioned between the dura and the bone of the anterior skull base) was used in 59/62 cases (95%) and the "inlay" technique (positioning of the material on the dura from within) in the other cases.

Closure of the leaks was accomplished in 61 patients (98.4%) after primary surgery. One patient presented with signs compatible with ascending bacterial meningitis two

Table 2: Etiology of CSF leaks.

Etiology	Number of cases (%)
Spontaneous	30 (48.4)
Traumatic	15 (24.2)
Iatrogenic/postoperative (FESS)	5 (8.1)
Benign tumor (osteoma, mucocele, and inverted papilloma)	5 (8.1)
Meningocele	3 (4.8)
Iatrogenic/postoperative (rhinoseptoplasty)	2 (3.2)
Congenital (meningoencephalocele of Sternberg's canal)	2 (3.2)

Table 3: Localizations of the CSF leaks.

Localization	Number of cases (%)
Cribriform plate	31 (50)
Anterior ethmoid	13 (21)
Posterior ethmoid	7 (11.3)
Sphenoid sinus	8 (12.9)
Frontal sinus	3 (4.8)

weeks after surgery. A persistent CSF leak was confirmed and the defect closed with a revision surgery. The follow-up at 75.3 ± 51.3 months (range 6–177 months) showed no evidence of CSF leaks recurrence.

4. Discussion

Skull base defects created during the removal of tumors are expected and therefore do not need further diagnostic procedures. However, the method and technique of reconstruction are the first question posed when planning expanded endoscopic approaches, as a permanent CSF leak may lead to ascending bacterial meningitis [2].

On the other hand, CSF leaks of other origin need to be investigated in depth. A thorough clinical history evaluating potential traumas, even long time before, prior to surgery or a history of bacterial meningitis is suspicious of an active or intermittent leakage. Occasionally, nasal endoscopy may reveal some pulsatile light reflex at the skull base or a soft tissue mass indicating a meningocele or a meningoencephalocele. However, when intracranial pressure is low or the leakage is intermittent endoscopy may be completely normal.

CAT scan in one millimeter slices allows a high resolution in the coronal and sagittal reconstruction. It is helpful in measuring the skull base defect radiologically and in planning the surgical technique of reconstruction. Rendering an exact picture of the bony framework is basic for the topographical diagnosis and the planning of the surgical approach. In cases in which a larger mass of tissue is seen in the CAT scan an additional MRI helps to assess meningoceles or meningoencephaloceles.

In active leaks a biochemical assessment with either beta-2 transferrin or beta-trace protein is helpful to differentiate from rhinorrhea due to chronic rhinosinusitis or to allergic rhinitis. In a literature review of 39 papers on the utility of testing beta-trace protein or beta-2 transferrin Bachmann-Harildstad could show that any are useful to assess the presence of CSF. Beta-trace has a high specificity and sensitivity, its results being faster (20 minutes versus 120 minutes of beta-2 transferrin) and less expensive [6].

Demarco et al. [7] used hypodense fluorescein, which seems to reduce the time of staining CSF down to 30 minutes.

Since its introduction in 1961 [8] intrathecal application of fluorescein has been shown to be very useful in the intraoperative assessment of the leakage and to prove the watertight closure. In 2 cases with suspicious intermittent leakage and negative biochemistry fluorescein was intrathecally applied as a diagnostic procedure. Both cases resulted in a negative result being excluded from this study. No serious complication could be observed after intrathecal fluorescein application. In all three cases in which headaches or weakness of the lower extremities was observed, the complaints were temporary leaving no sequelae. In an enquiry performed among rhinologists the habitual amount of fluorescein used was 0.5 and 1.0 mL at a concentration of 10%, although Senior et al. [9] could show effectiveness at low concentration and dosage of 0.1 mL at 10%. Complications after intrathecal fluorescein injection are usually related to increased dosages or concentrations or to a high administration speed [10, 11]. Severe complications (seizure, opisthotonus, and peripheric palsy) have been linked to chemical irritation in overdosage, as could be shown by Syms III et al. in an experimental study [12].

It is important to highlight that intrathecal application of fluorescein is an off-label indication and as such needs to be included specifically in the informed consent [10].

Among small and midsized defects spontaneous CSF leaks were the most frequent ones (48.4%) followed by those of a traumatic origin (24.2%). The cribriform plate was identified as the most frequent location (50%) followed by the anterior and posterior ethmoidal roof (32.3%). In a review of 55 papers including 1778 CSF leaks repaired endoscopically, the distribution between those of traumatic (50.2%) and nontraumatic origin (49.8%) was very similar [3]. Here too, spontaneous CSF leaks were the most frequent ones (41.1%) followed by those after endoscopic surgery (30.1%), trauma (23.2%) or tumor (5%), and congenital origin (3%).

The "underlay" reconstruction technique has been used the most (95%). Here, the dura is elevated in order to fit material, usually fascia lata, between the bone and the dura. In our hands, this is the preferred way to reconstruct the small and midsized skull base defects as the position of the fascia lata is stabilized by the underlying bone. However, in defects at the cribriform plate, the "underlay" position is difficult to achieve, as it would imply to fracture the intact cribriform plate when trying to detach the dura. This can be achieved laterally towards the ethmoid, but medially we tend to position the fascia in an L-shape mode towards the crista galli. Then, we wait for the intracranial pressure and pulsations to "push" the fascia from within until it adapts in an "inlay" position to the surrounding intact dura. For very small defects (2-3 mm) the "bath plug" technique with fat has proven reliable.

It is interesting to know that, in a meta-analysis of 289 CSF fistulas, Hegazy et al. [13] could show that different reconstruction techniques have a similar outcome. It looks as if any material used to reconstruct the skull base seems to work well.

The additional mucosal graft renders at least a two-layer reconstruction and protection of the dura. The size of both, fascia lata and mucosal graft, needs to be 2–5 mm larger than the defect itself. Particularly the latter has shown to shrink during the scarring process, as demonstrated by Hosemann et al. [14].

For the reconstruction of large skull base defects, specifically during expanded approaches, the pedicled nasoseptal flap has rendered spectacular rates of postoperative CSF leaks compared to the period before its description. The rate of postoperative CSF fistulas had been superior to 30%, compared to the 4% when using the nasoseptal flap [5]. The choice of the side from which to harvest the flap strongly depends on the tumor side, the presence of septal spurs or deviations, or the vascular compromise if drilling or surgery needs to be performed along the anterior wall of the sphenoid sinuses. Recent investigations have shown a negative impact of the flaps on olfaction, mucociliary transport, and quality of life [15–17]. Therefore, the cranial incision when harvesting the flap is nowadays situated below the area of the olfactory epithelium. Also, a reverse rescue flap from the contralateral side is performed to cover the denuded cartilage [18].

The reconstruction techniques between small/midsized and large defects cannot be compared. First, the location is a different one, with more spontaneous defects at the cribriform plate in Group 2; second, the extension of larger defects after expanded endoscopic surgery is usually linked to a high flow CSF leak. This indicates another type of reconstruction, including a lumbar drainage for the first days.

The use of lumbar drainage is still controversial. It is an invasive procedure, which may produce headaches, nausea, meningitis, or pneumoencephalus [19]. In an enquiry, Senior et al. found that 67% of the rhinologists in the States were routinely using a lumbar drainage in the management of CSF fistulas [9]. In a meta-analysis on 1568 CSF leaks, 761 lumbar drainages were used for 1 up to 10 days, although most studies showed that it was left for about 2–5 days. However, there is no way to calculate the potential benefit of a lumbar drainage due to the scarce data provided in the studies [3]. For small or midsized defects we do not see any indication. However, in larger defects, particularly those with a high pressure or high flow CSF leak, we believe that the area of reconstruction is better spared with a lumbar drainage as described above.

The prophylactic administration of antibiotics has not proved any effectivity in randomized studies, although we believe there is an indication for endoscopic skull base surgeries lasting 3–67 hours, as the nose cannot be considered sterile. Prophylactic antibiotics were administered routinely in 23 of 24 reviewed papers, in 4 studies only during the perioperative period and in 19 between 2 and 14 days, particularly in cases with lumbar drainage or nasal packing [3].

Hegazy et al. studied the results of 14 papers published between 1990 and 1999. The success rate varied between 60% and 100% (mean 90%) after primary surgery [13]. In a recent review of 55 papers dealing with endoscopic repair of CSF leaks, Psaltis et al. [3] confirmed the success rate of 90% for primary surgery and of 97% for rescue procedures with a complication rate lower than 0.03%. In their meta-analysis, Harvey et al. [20] conclude that skull base reconstruction with pedicled flaps renders a low postoperative CSF rate of 6.7% compared to a 15.6% after reconstruction with free grafts.

Endoscopic repair of CSF leaks is to be considered the gold standard for the majority of cases, as it is safe and effective [21]. The endoscopic closure rate in our groups was 91% after primary surgery for large skull base defects and 98% in small and midsized defects. After revision surgery the success rate was 100%. Demarco et al. [7] achieve an 88% closure rate at first attempt and 100% with a revision surgery, while Meco et al. obtained a 91% closure rate after primary surgery [22].

Interestingly, the rate of occult CSF fluid leakage after paranasal sinus surgery was found with beta-trace in two cases (2.9%) [23].

The weakness of our study is its retrospective design, the surgical outcome measurements based on a clinical follow-up only. However, the absence of both, an active CSF leakage and bacterial meningitis postoperatively, allows evaluating the rate of effective closure.

5. Conclusions

Considering all potential weaknesses of a retrospective study, we may confirm that endoscopic surgery for repair of either large, small, or midsized defects of the skull base seems to be a safe and effective procedure. Basically, any defect size can be reconstructed from within the nose. In our hands, the "underlay" technique with lyophilized fascia lata and a mucoperiosteal graft from mainly the middle turbinate achieved excellent results after primary surgery of smaller defects. No lumbar drainage is indicated here. However, the theoretical possibility of missed intermittent postoperative CSF leakage has not been extensively investigated in the present study.

Pedicled nasoseptal flaps are most adequate for the reconstruction of larger defects which happen after tumor removal. A temporary lumbar drainage seems to be helpful to reduce the intracranial pressure during the first days for a better scarring, although a prospective randomized study would be needed to give proof of its true benefit.

Conflict of Interests

The authors declare that there is no conflict of interests regarding the publication of this paper.

References

[1] M. Bernal-Sprekelsen, C. Bleda-Vázquez, and R. L. Carrau, "Ascending meningitis secondary to traumatic cerebrospinal fluid leaks," *The American Journal of Rhinology*, vol. 14, no. 4, pp. 257–259, 2000.

[2] N. S. Jones and D. G. Becker, "Advances in the management of CSF leaks: new techniques will improve the management of unilateral clear nasal discharge," *British Medical Journal*, vol. 322, no. 7279, pp. 122–123, 2001.

[3] A. J. Psaltis, R. J. Schlosser, C. A. Banks, J. Yawn, and Z. M. Soler, "A systematic review of the endoscopic repair of cerebrospinal fluid leaks," *Otolaryngology—Head and Neck Surgery*, vol. 147, no. 2, pp. 196–203, 2012.

[4] G. Hadad, L. Bassagasteguy, R. L. Carrau et al., "A novel reconstructive technique after endoscopic expanded endonasal approaches: vascular pedicle nasoseptal flap," *Laryngoscope*, vol. 116, no. 10, pp. 1882–1886, 2006.

[5] A. B. Kassam, A. Thomas, R. L. Carrau et al., "Endoscopic reconstruction of the cranial base using a pedicled nasoseptal flap," *Neurosurgery*, vol. 63, no. 1, supplement 1, pp. ONS44–ONS52, 2008.

[6] G. Bachmann-Harildstad, "Diagnostic values of beta-2 transferrin and beta-trace protein as markers for cerebrospinal fluid fistula," *Rhinology*, vol. 46, no. 2, pp. 82–85, 2008.

[7] R. C. Demarco, E. Tamashiro, F. C. P. Valera, and W. T. Anselmo-Lima, "Use of a hypodense sodium fluorescein solution for the endoscopic repair of rhinogenic cerebrospinal fluid fistulae," *The American Journal of Rhinology*, vol. 21, no. 2, pp. 184–186, 2007.

[8] F. R. KIRCHNER, "Use of fluorescein for the diagnosis and localization of cerebrospinal fluid fistulas," *Surgical forum*, vol. 12, pp. 406–408, 1961.

[9] B. A. Senior, K. Jafri, and M. Benninger, "Safety and efficacy of endoscopic repair of CSF leaks and encephaloceles: a survey of the members of the american rhinologic society," *The American Journal of Rhinology*, vol. 15, no. 1, pp. 21–25, 2001.

[10] R. Keerl, R. K. Weber, W. Draf, A. Wienke, and S. D. Schaefer, "Use of sodium fluorescein solution for detection of cerebrospinal fluid fistulas: an analysis of 420 administrations and reported complications in europe and the United States," *Laryngoscope*, vol. 114, no. 2, pp. 266–272, 2004.

[11] D. G. Placantonakis, A. Tabaee, V. K. Anand, D. Hiltzik, and T. H. Schwartz, "Safety of low-dose intrathecal fluorescein in endoscopic cranial base surgery," *Neurosurgery*, vol. 61, no. 3, supplement, pp. 161–165, 2007.

[12] C. A. Syms III, M. J. Syms, T. R. Murphy, and S. O. Massey, "Cerebrospinal fluid fistulae in a canine model," *Otolaryngology—Head and Neck Surgery*, vol. 117, no. 5, pp. 542–546, 1997.

[13] H. M. Hegazy, R. L. Carrau, C. H. Snyderman, A. Kassam, and J. Zweig, "Transnasal endoscopic repair of cerebrospinal fluid rhinorrhea: A0 meta- analysis," *Laryngoscope*, vol. 110, no. 7, pp. 1166–1172, 2000.

[14] W. Hosemann, U. Goede, and M. Sauer, "Wound healing of mucosal autografts for frontal cerebrospinal fluid leaks—clinical and experimental investigations," *Rhinology*, vol. 37, no. 3, pp. 108–112, 1999.

[15] I. Alobid, J. Enseñat, F. Mariño-Sánchez et al., "Impairment of olfaction and mucociliary clearance after expanded endonasal approach using vascularized septal flap reconstruction for skull base tumors," *Neurosurgery*, vol. 72, no. 4, pp. 540–546, 2013.

[16] I. Alobid, J. Enseñat, F. Mariño-Sánchez et al., "Expanded endonasal approach using vascularised septal flap reconstruction for skull base tumors has a negative impact on sinonasal symptoms and quality of life," *The American Journal of Rhinology & Allergy*, vol. 27, no. 5, pp. 426–431, 2013.

[17] J. R. de Almeida, I. J. Witterick, P. J. Gullane et al., "Quality of life instruments for skull base pathology: systematic review and methodologic appraisal," *Head and Neck*, vol. 35, no. 9, pp. 1221–1231, 2013.

[18] P. Kasemsiri, R. L. Carrau, B. A. Otto et al., "Reconstruction of the pedicled nasoseptal flap donor site with a contralateral reverse rotation flap: technical modifications and outcomes," *Laryngoscope*, vol. 123, no. 11, pp. 2601–2604, 2013.

[19] J. T. Kerr, F. W. K. Chu, and S. W. Bayles, "Cerebrospinal fluid rhinorrhea: diagnosis and management," *Otolaryngologic Clinics of North America*, vol. 38, no. 4, pp. 597–611, 2005.

[20] R. J. Harvey, P. Parmar, R. Sacks, and A. M. Zanation, "Endoscopic skull base reconstruction of large dural defects: a systematic review of published evidence," *Laryngoscope*, vol. 122, no. 2, pp. 452–459, 2012.

[21] R. J. Komotar, R. M. Starke, D. M. Raper, V. K. Anand, and T. H. Schwartz, "Endoscopic endonasal versus open repair of anterior skull base CSF leak, meningocele, and encephalocele: a systematic review of outcomes," *Journal of Neurological Surgery A: Central European Neurosurgery*, vol. 74, no. 4, pp. 239–250, 2013.

[22] C. Meco, E. Arrer, and G. Oberascher, "Efficacy of cerebrospinal fluid fistula repair: sensitive quality control using the beta-trace protein test," *The American Journal of Rhinology*, vol. 21, no. 6, pp. 729–736, 2007.

[23] G. Bachmann, U. Djenabi, M. Jungehülsing, H. Petereit, and O. Michel, "Incidence of occult cerebrospinal fluid fistula during paranasal sinus surgery," *Archives of Otolaryngology—Head and Neck Surgery*, vol. 128, no. 11, pp. 1299–1302, 2002.

Hindawi Publishing Corporation
BioMed Research International
Volume 2014, Article ID 303929, 11 pages
http://dx.doi.org/10.1155/2014/303929

Research Article

High Level of Tregs Is a Positive Prognostic Marker in Patients with HPV-Positive Oral and Oropharyngeal Squamous Cell Carcinomas

E. Lukesova,[1,2] J. Boucek,[1,3] E. Rotnaglova,[1] M. Salakova,[2] E. Koslabova,[1,2] M. Grega,[4] T. Eckschlager,[5] B. Rihova,[3] B. Prochazka,[2] J. Klozar,[1] and R. Tachezy[2]

[1] *Department of Otorhinolaryngology and Head and Neck Surgery, 1st Faculty of Medicine, Charles University in Prague, University Hospital Motol, 150 06 Prague, Czech Republic*
[2] *Department of Experimental Virology, Institute of Hematology and Blood Transfusion, 128 20 Prague, Czech Republic*
[3] *Institute of Microbiology Academy of Sciences of the Czech Republic, Public Research Institution, 142 20 Prague, Czech Republic*
[4] *Department of Pediatric Hematology and Oncology, 2nd Faculty of Medicine, Charles University in Prague, University Hospital Motol, 150 06 Prague, Czech Republic*
[5] *Department of Pathology and Molecular Medicine, 2nd Faculty of Medicine, Charles University in Prague, 150 06 Prague, Czech Republic*

Correspondence should be addressed to R. Tachezy; rutach@uhkt.cz

Received 24 February 2014; Accepted 25 March 2014; Published 23 April 2014

Academic Editor: Jan Plzák

Background. Human papillomaviruses (HPVs) have been proved as one of the etiological factors of oropharyngeal squamous cell carcinoma (OPSCC). Patients with tumors of viral etiology have a lower recurrence rate and better prognosis. OPSCC is linked to an alteration in the immune system. Only a limited number of studies have correlated both the immunological parameters and HPV status with patient prognosis. The aim of this study was to determine whether HPV infection and the immunological status influence patient prognosis individually or in concurrence. *Material and Methods*. Sixty patients with oral and oropharyngeal carcinomas were enrolled. They were divided into HPV-positive and HPV-negative groups based on the expression of HPV 16 E6 mRNA. Basic lymphocyte subpopulations were determined in the peripheral blood by means of flow cytometry. *Results*. Significantly better disease-specific survival (DSS) was observed in patients with HPV-positive tumors. Nodal status, tumor grade, recurrence, and CD8+/Tregs ratio were identified as factors influencing DSS. A higher level of Tregs and a lower ratio of CD8/Tregs influenced overall survival (OS) independently of HPV status and age. Patients with HPV-positive tumors and high levels of Tregs survived significantly better than patients from the other groups. *Conclusion*. Better survival is associated with HPV positivity and elevated Tregs levels. Our data suggest that HPV infection and Tregs do not influence patient prognosis in concurrence.

1. Introduction

Head and neck squamous cell carcinoma (HNSCC) arising in the oral cavity, oropharynx, hypopharynx, and larynx is the sixth leading cancer by incidence worldwide, with more than 550,000 cases annually [1, 2]. The most important risk factors identified for these tumors are smoking and alcohol consumption. Large epidemiological studies in the United States and in Europe have shown that the incidence of oropharyngeal carcinoma has been gradually growing in the last 40 years, especially in younger aged groups [3, 4], while the incidence of head and neck tumors in other anatomical locations has been decreasing [5, 6]. The upward trend can be attributed to the increasing prevalence of high-risk (HR) types of human papillomaviruses (HPVs) in the younger sexually active population [7]. HR HPVs are being detected in 67% of oropharyngeal tumors and now are widely accepted as an etiological factor of 20–25% of head and neck squamous

cell carcinomas [7, 8]. As has been shown by us and others, patients with HPV-positive tumors have better prognosis which is an important observation of clinical relevance [9, 10].

HPV infection is controlled by the host immune system and most of the infections are cleared within two years [11]. HNSCC is associated with an alteration of the immune system [12]. In patients with HNSCC, functional defects and reduced numbers of T cells in the peripheral blood and tumor microenvironment were observed [13, 14]. Moreover, head and neck tumors utilize different mechanisms to evade and/or alter the host immune system [12].

Natural killer (NK) cells are part of the innate immune system and have been shown to participate mainly in the early control against virus infected cells and tumors. The activation of NK cells occurs via the integration of signaling molecules with activating or inhibitory receptors on the NK cell surface or can be mediated by proinflammatory cytokines, which are released in response to viral infection. A direct interaction between HPV infection and the innate immune system has been observed in patients with cervical cancer. The authors suggest that NK cells might be activated by HPV viral particles. It has been shown that NK cells are abundantly present in the tissue of preneoplastic cervical lesions but much less cells have been detected in cervical squamous cell carcinomas [15, 16]. In patients with HNSCC, decreased numbers of NK cells in the peripheral blood have been detected independently of the etiology of the tumor [17, 18]. Additionally, it has been shown that a lower number of NK cells in the blood of patients with HNSCC predict their poor outcome [19].

Regulatory T cells (Tregs) are able to suppress antitumor immunity and in many patients with solid tumors; their increased levels in the tumor tissue as well as in the peripheral blood have been documented [20–24]. Similarly, in cervical tumors associated with HPV infection, elevated levels of Tregs and IL-10, which activates Tregs, have been found [25]. The results of studies on HNSCC patients are contradictory. Some authors have found decreased numbers of Tregs in the peripheral blood [13] whereas others have not reproduced these results [26–29]. In the tumor tissue, elevated numbers of Tregs as well as subpopulations of CD4+ and CD8+ T cells have been observed by several authors [30–33]. A worse prognosis of HNSCC patients with elevated levels of Tregs in the peripheral blood in comparison with normal Tregs levels patients has been documented in a study [34]. In some reports, a positive correlation of the Tregs levels in the peripheral blood and tumor tissue has been reported [20, 26, 32, 35].

We have previously shown that in HNSCC patients, HPV positivity is a strong prognostic factor for both better survival and less frequent recurrent disease [9, 36]. Another study from our group on immunological markers in HNSCC patients has shown higher Tregs counts in the peripheral blood of these patients when compared to healthy controls and increased probability of early recurrence with higher Tregs counts in the peripheral blood [29]. Because we believe that HPV infection could modify immunological parameters of HNSCC patients, the study was aimed at comparing selected immunological parameters in HNSCC patients with HPV-associated tumors and HPV-negative tumors and with good and bad prognosis. Since our pilot data show better survival of patients with HPV-positive tumors and higher Tregs counts in the peripheral blood, we wanted to investigate if viral, demographic, and immunological factors influence the clinical outcome of patients individually or in concurrence and to correlate them with virological data.

2. Material and Methods

2.1. Study Population. Patients with primary squamous cell cancer of the oral cavity or oropharynx (ICD-10: C01–C06, C9-10) treated within a four-year interval at the Department of Otolaryngology and Head and Neck Surgery, 1st Medical Faculty Charles University and Motol University Hospital, Prague, who signed the informed consent form were enrolled into the study. The study received official institutional and ethical approval from the participating institutions. Data on demographics, risk factors for oral cavity and oropharyngeal cancer, and risks related to HPV exposure were collected by a questionnaire. The medical and pathology reports were completed for each patient. Altogether 60 patients were included in the study. From all patients, the tumor tissue and blood samples were obtained.

2.2. Tumor Samples. All but three patients underwent surgical treatment and the tumor tissue was sent on dry ice to the Pathology Department. In the three patients who had not been treated surgically, tumor biopsies were performed. The pathologist obtained two side-by-side sections of the tumor from the primary site. One of the paired sections from each anatomical location was then labeled, snap frozen in liquid nitrogen, and stored for future analysis. The other paired section from each anatomical site was fixed in 10% neutral formalin and paraffin embedded. From each paraffin block, the first and last sections were histologically analyzed to confirm that the sections in between—assigned for the detection of viral nucleic acids and immune histochemical (IHC) analysis—contained at least 10% of tumor cells in the entire volume of the sample. Nucleic acids, both DNA and RNA, were extracted from the tumor tissue by means of the Ambion Recover All TM Total Nucleic Acid Isolation Kit for FFPE Tissues (Applied Bioscience, Austin, TX, USA) as specified before [36]. Care was taken to avoid sample cross-contamination.

2.3. PCR. All procedures have been described in detail previously [9, 36]. HPV DNA detection was performed by PCR with primers specific for the L1 region (GP5+/GP6+) as described previously [37]. As an internal control, a 110-bp fragment of the human beta-globin gene was amplified [38]. HPV typing was performed by reverse line blot hybridization (RLB) with probes specific for 37 types as specified in detail by van den Brule et al. [39]. From total RNA, cDNA was prepared by reverse transcription. The absence of contaminating DNA was confirmed by amplification of the internal *GAPDH* internal control gene [40]. As a control of the integrity of mRNA, the beta-globin gene was amplified. Amplification

of HPV 16 E6*I mRNA oncoprotein was performed with primers that amplify the 86-bp fragment [41].

2.4. Immunohistochemical Analysis. IHC examination was performed as specified before [36]. Briefly, the antibodies p16INK4a (Purified Mouse Anti-Human p16, Clone G175-405, BD Pharmingen TM, dilution 1 : 100) were used. The intensity of staining (graded+ to +++) and the proportion of cells stained (scored in percentages) were evaluated. For p16 immunostaining, the location of the signal (cytoplasmic and/or nuclear) was also specified. A semiquantitative evaluation was performed. The sample positive for p16 expression had to show more than 50% of positive cells and reveal nuclear and/or cytoplasmic staining.

2.5. Flow Cytometry. In all studied patients, the following immunological parameters were determined: CD3+, CD4+, CD8+, Tregs, CD8+/Tregs ratio, CD4+/CD8+ ratio, CD4+ CD8+ sum, CD19, CD4+CD45RA+, and CD3−CD56+ CD16+ cells. Samples of peripheral blood were analyzed by flow cytometry (FACSCalibur, BD, San Jose, CA) after lysis of erythrocytes by FACS Lysing Solution (BD, San Jose, CA) and staining with antibody-fluorochrome conjugates. We strictly adhered to the instructions in the manufacturer's protocol for the respective reagents. Antibodies anti-CD45 FITC/CD14 PE (to correctly set the lymphocyte gate), anti-CD3 FITC/CD19 PE, anti-CD3 FITC/CD16CD56 PE, anti-CD4 FITC/CD8 PE, anti-CD45RA FITC/anti-CD4 PE, and anti-CD3 FITC/CD4 PE/CD25 APC (Beckmann Coulter, Nyon, Switzerland) were used. Ten thousand cells in the lymphocyte gate were acquired for analysis and the data were analyzed using the CellQuest software. Results are expressed as the percentages of the respective cell subpopulations of all lymphocytes and Tregs are expressed as the percentages of CD25+ cells of the CD3+CD4+ cells.

The mean values of these parameters were compared between the groups of HPV-positive and HPV-negative HNSCC cases and between patients with good and bad prognosis (see below). Elevated Tregs levels were those with more than 10% of Tregs in the peripheral blood. To exclude the influence of acute inflammation on the immunological parameters, the standard "inflammatory parameters" were established. White blood count (WBC) and C-reactive protein (CRP) were detected using a routine laboratory procedure with the respective cut-off values of $\leq 10^9$/L and ≤8 mg/L.

2.6. Statistical Analysis. The mean levels of the immunological parameters as measured in the peripheral blood were compared between the groups of patients with HPV-positive and HPV-negative tumors and between the groups of patients with good and bad prognosis. Patients with good prognosis were those who did not have any recurrence and were alive at the end of the followup, while patients with bad prognosis were those who either relapsed or died before the end of the followup. The peripheral blood lymphocytes were treated as continuous variables in all analyses. Additionally, for the Tregs cells, two groups were distinguished: Tregs-high patients of patients with more than 10% of Tregs in the peripheral blood and Tregs-low patients with less than 10% of Tregs in the peripheral blood. The comparison was performed by t-test with 95% confidence intervals (CI) and two-tailed P values. All tests were two-sided and the significance level was $\alpha = 0.05$.

Survival was measured in days from the date of diagnosis to the date of death or to the date the patient was last known to be alive. Patients who died of causes other than head and neck tumor were considered censored observations in the disease-specific survival (DSS) analyses. Time-to-event measures were analyzed by the Kaplan-Meier method, Log-rank test, and Cox multivariate regression. Ninety-five percent confidence intervals for odds ratios were based on the normal approximation. The variables considered in the Cox regression models were the presence of HPV, age, gender, smoking, alcohol consumption, tumor size, nodal status (T + N, according to the TNM Classification of the UICC, 1997), tumor grade, tumor location, peripheral blood Tregs level, CD4+, CD8+, CD4+ CD8+ sum, CD4+/CD8+ ratio, CD8+/Tregs ratio, CD19, and CD3−56+16+ cells. A forward stepwise procedure was performed to find significant covariates ($P < 0.1$). To compare the qualitative characteristics we used the Pearson χ^2 test for 2 × 2 contingency tables and to compare the quantitative characteristics, we applied the Mann-Whitney test. The analyses were performed using the statistical program SPSS (SPSS, Chicago, IL, USA). The Kappa statistics was calculated to measure the agreement for simultaneous positivity for HPV DNA and expression of HPV E6 mRNA.

3. Results

3.1. Demographic and Clinical Pathological Characteristics. Ninety percent (54/60) of HNSCC cases were males and 10.0% (6/60) were females (Table 1). The mean age was 56.5 years. The majority of patients (58.6%; 34/58) were current smokers, 29.3% (17/58) were exsmokers, and 12.0% (7/58) were nonsmokers. Most patients (78.3%; 47/60) drank alcohol, 8.3% (5/60) did so in the past, and 13.3% (8/60) never drank alcohol. Oropharyngeal location of the tumors was the most common (91.6%; 55/60): 52.7% (29/55) were tonsillar tumors, 34.5% (19/55) tumors of the base of the tongue, one patient (1.8%; 1/55) had carcinoma of the soft palate, and 10.9% (6/55) had nonspecified oropharyngeal carcinoma. Only 8.3% (5/60) of patients had tumor of the oral cavity. Positive tumor cell infiltrated lymph nodes were found in the majority of cases (N0 versus N1–3, 32.1.0% versus 67.8%). Smaller tumors occurred more often than larger tumors (T1 + 2 versus T3 + 4; 70.1% versus 29.8%), higher tumor stages were more frequent than lower tumor stages (I, II versus III, IV, 28.3% versus 71.6%), and tumors were also more commonly well differentiated (G1, 2 versus G3, 70.2% versus 29.8%).

3.2. HPV Footprints in the Tumor Tissue. Out of 60 patients, 50.0% (30/60) had HPV DNA detected in the tumor tissue (data not shown). Only HR HPV types were found. The most

Table 1: Demographic/epidemiological characteristic of the study subjects.

Characteristics	Number (%)
Age	
Mean age	56.5
≤55	24 (40.0%)
>55	36 (60.0%)
Gender	
Female	6 (10.0%)
Male	54 (90.0%)
Tobacco status	
Current smokers	34 (58.6%)
Exsmokers	17 (29.3%)
Nonsmokers	7 (12.0%)
Alcohol	
Current consumers	47 (78.3%)
Exconsumers	5 (8.3%)
Nonconsumers	8 (13.3%)
Tumor size	
T1 + T2	40 (70.1%)
T3 + T4	17 (29.8%)
Nodal status	
N0	18 (32.1%)
N1–N3	38 (67.8%)
Tumor stage	
I + II	17 (28.3%)
III + IV	43 (71.6%)
Tumor grade	
G1 + G2	40 (70.2%)
G3	17 (29.8%)
Tumor location	
Oropharyngeal	55 (91.6%)
Oral cavity	5 (8.3%)

frequently detected type in a single infection was HPV 16, found in 96.6% (29/30) of patients, followed by HPV 58 in 3.3% (1/30) of patients. Multiple infections were revealed in one patient (3.3%) who was positive for HPVs 16 and 18. HPV DNA was detected more often in oropharyngeal tumors than in tumors of the oral cavity (96.6% versus 3.3%). In the oropharyngeal location, tonsillar tumors were the most frequently positive, 68.9% (20/29). All but four HPV-DNA positive tumors expressed HPV 16 E6 mRNA and one sample was not available for RNA extraction. One of the samples negative for viral mRNA expression was positive for HPV type 58 and another one was copositive for HPVs 16 and 18. The correlation of the simultaneous positivity for HPV 16 DNA and expression of HPV 16 E6 mRNA was substantial (Kappa = 0.786). The samples positive for viral mRNA expression were considered HPV positive for future analyses.

3.3. Expression of p16 in Tumor Tissue. In 54.2% (32/59) of cases, the p16 oncoprotein was detected. Three samples positive for HPV 16 E6 mRNA were negative for p16 expression. One sample was not available for the analysis. The correlation of the expression of viral mRNA and p16 positivity was substantial (Kappa = 0.672) as well as the correlation of HPV DNA and p16 positivity (Kappa = 0.617). HPV DNA detection in this study had substantially higher sensitivity (93.0% versus 75.0%) and lower specificity (86.0% versus 88.0%) in comparison to the detection of p16 when samples positive for viral mRNA were considered positive (data not shown).

3.4. Increased Levels of NK Cells in HPV-Positive Tumor Patients. First, the percentages of the populations of different lymphocytes (CD4+, CD8+, Tregs, CD8+/Tregs ratio, CD4+/CD8+ ratio, CD8+ CD4+ sum, CD19, and CD3−CD56+CD16+) were compared in the peripheral blood of patients with HPV-positive and HPV-negative tumors. The analysis of these immunological parameters showed that patients with HPV-positive tumors had significantly higher levels of CD3−CD56+CD16+ NK cells (mean = 13.6%; $P = 0.005$) than patients with HPV-negative tumors (mean = 6.4%). No difference in other immunological parameters studied was detected between the two groups of patients. Then, to evaluate the prognostic value of immunological markers, we compared the prevalence of lymphocyte populations at enrollment between patients with good and bad prognosis (for definition, see materials and methods). No statistically significant differences were observed (Table 3). We also assessed the age specific prevalence of the immunological markers (Figure 1). The level of CD8+, Tregs, and CD3−CD56+CD16+ NK cells showed increasing tendency, while the level of CD4+ and CD19+ B cells showed decreasing tendency with age. However, except for CD3−CD56+CD16+ NK cells, the association of other immunological markers with age was not statistically significant. Finally, the difference in the prevalence of CD3−CD56+CD16+ NK cells between HPV-positive and HPV-negative patients was reduced after adjusting for age but it was still on the borderline of significance ($P = 0.052$) (Table 2). No patient with elevated levels of Tregs had increased level of the inflammatory parameters WBC and/or CRP.

3.5. Treg Levels in the Peripheral Blood Correlate with Tumor Location and Grade. Elevated Tregs levels were found in 61.6% (37/60) of the study patients. The mean rate of Tregs was 15.3% (data not shown). Higher numbers of Tregs were found more often in patients with tumors of the oral cavity (100%; 5/5) than in those with oropharyngeal tumors (58.1%; 32/55). Among patients with the oropharyngeal tumors, elevated Tregs were most frequently associated with tonsillar tumors (34.5%; 19/55). Elevated Tregs levels were more often detected in patients with well-differentiated tumors (G1, 2 versus G3; 69.4% versus 30.6%) and higher tumor stages (I, II versus III, IV; 35.2% versus 64.8%) but the differences were not statistically significant ($P = 0.373$ and $P = 1.000$).

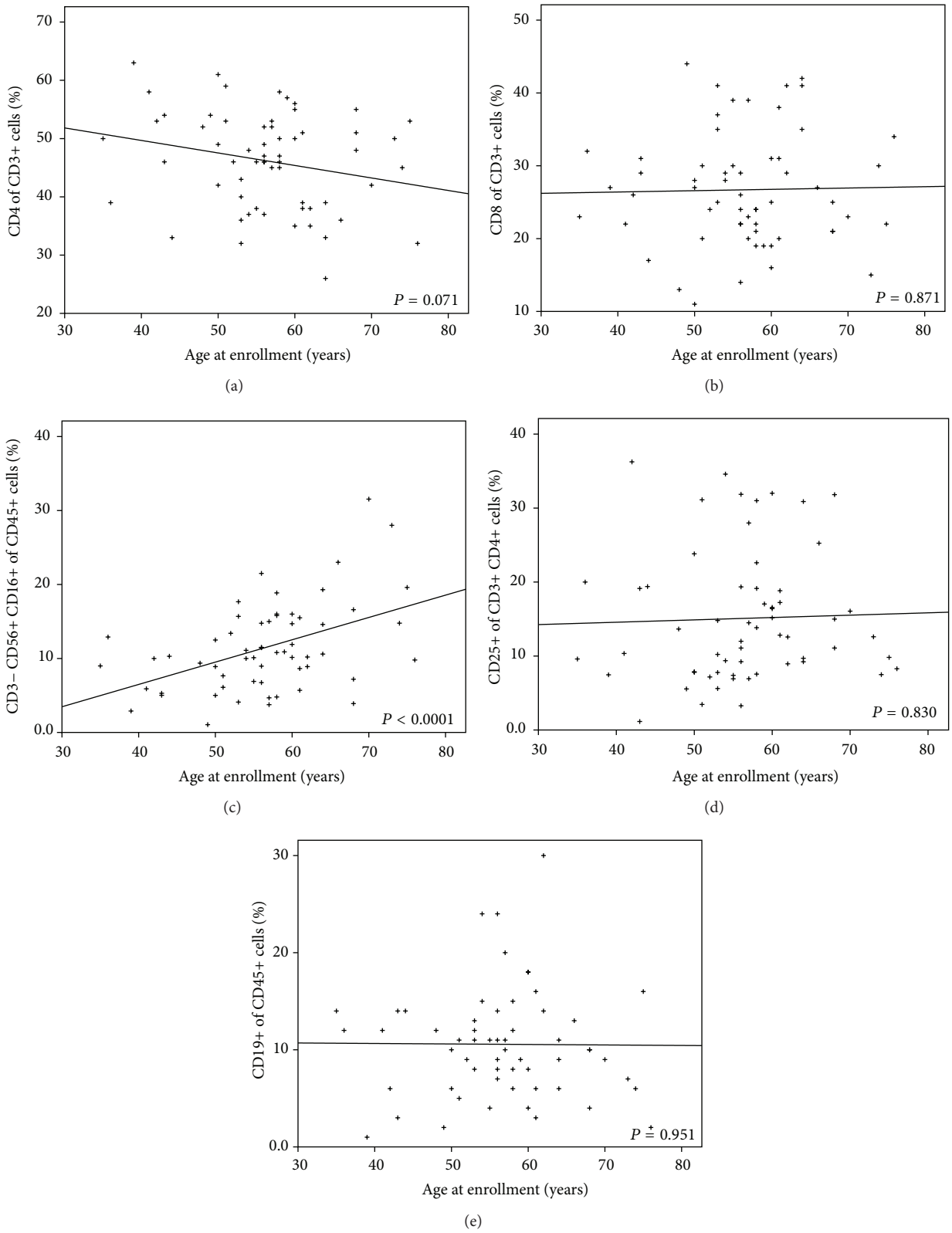

Figure 1: Age specific distribution of the immunological markers.

Table 2: Comparison of the mean values of immunological characteristics between patients with tumors positive or negative for HPV (for details see materials and methods).

Immunological characteristics	HPV + Mean	HPV − Mean	*P* value	95% CI	*P* value adj[a]	95% CI adj[a]
CD8+ (%)	26.6	26.8	0.896	−3.8; 4.3	0.846	0.9; 1.1
CD4+ (%)	44.3	48.0	0.085	−0.5; 7.9	0.199	0.9; 1.0
CD19+ (%)	11.3	4.7	0.332	−4.4; 1.5	0.305	1.0; 1.2
CD3−CD56+16+ (%)	13.6	6.4	0.005	−7.2; −1.3	0.052	1.0; 1.3
CD4+/CD8+	1.8	2.1	0.355	0.1; 7.8	0.451	0.4; 1.5
Tregs (%)	15.9	15.8	0.998	−4.6; 4.6	0.924	0.9; 1.1
CD8+CD4+sum	70.9	74.8	0.355	0.1; 7.8	0.116	0.9; 1.0
CD8+/Tregs	2.4	3.5	0.258	−0.8; 3.0	0.455	0.7; 1.1

[a]adjusted for age.
95% CI: confidence interval; *P*: probability.

Table 3: Comparison of the mean values of immunological characteristics between patients with good and bad prognosis (for specification see materials and methods).

Immunological Characteristics	Good Prognosis Mean	Bad Prognosis Mean	*P* value	95% CI
CD8+ (%)	26.9	26.0	0.729	−4.4; 6.2
CD4+ (%)	45.8	47.9	0.446	−7.8; 3.5
CD19+ (%)	9.9	13.6	0.222	−9.9; 2.6
CD3−CD56+16+ (%)	11.6	11.0	0.764	−3.5; 4.7
CD4+/CD8+	1.9	2.0	0.632	−7.1; 4.6
CD8+CD4+sum	72.7	73.9	0.779	−6.4; 3.9
Tregs (%)	13.0	10.5	0.417	−3.5; 8.4
CD8+/Tregs	2.8	3.9	0.613	−3.1; 1.9

95% CI: confidence interval; *P*: probability.

3.6. High Level of Tregs in the Peripheral Blood Correlates with a Better Survival of Patients with HPV-Positive HNSCC Tumors. The mean follow-up period was 4.3 years. At the end of the followup, 33 patients were free of the disease. Of 27 patients who died, 15 died of primary tumor and seven died of unrelated diseases and for five patients, data were not available for analyses. Significantly better DSS was observed in patients with HPV16 E6-positive tumors in comparison to HPV-negative tumors, using the Kaplan Meier analysis and Log Rank test ($P = 0.018$) (data not shown). Patients with elevated Tregs levels ($P = 0.039$) had significantly better overall survival (OS). Furthermore, the survival of patients was assessed depending on HPV16 E6 presence and Tregs level was assessed. Four groups of patients were compared: HPV+/Tregs high, HPV−/Tregs low, HPV−/Tregs high, and HPV+/Tregs low (Figure 2). In conclusion, patients with HPV-positive tumors and higher Tregs counts had significantly better both DSS and OS in comparison to other three groups (HPV−/Tregs low, HPV−/Tregs high, and HPV+/Tregs low) except for DSS in HPV+/Tregs low where the difference was not significant ($P = 0.087$). Better OS was also detected in patients with smaller tumors ($P = 0.019$) and in nonsmokers ($P = 0.023$) (data not shown).

Higher counts of Tregs did not affect the incidence of recurrence ($P = 0.909$) (data not shown).

No difference was found between the levels of Tregs and HPV status ($P = 0.929$), tumor size ($P = 0.780$), tumor grade ($P = 0.116$), and nodal status ($P = 0.253$), and occurrence of recurrence ($P = 0.251$) was found (data not shown). In the multivariate Cox regression analysis (Table 4), the following characteristics were tested for disease specific survival and overall survival: tumor size, nodal status, histological grading, smoking, alcohol intake, Tregs count, CD8+/Tregs ratio, counts of CD3+, CD4+, CD8+, CD4+, CD3−CD56+CD16+ (NK cells), and CD19 (B cells), and recurrence. Concerning DSS, significantly better survival was predictably found in patients with no recurrences (adjusted $P = 0.001$), lower tumor grade (adjusted $P = 0.046$), absence of lymph nodes metastases (adjusted $P = 0.041$), and lower CD8+/Tregs ratio (adjusted $P = 0.012$), with an advantage at the borderline of significance in patients with smaller tumors (T1 + T2) (adjusted $P = 0.058$). Improved overall survival

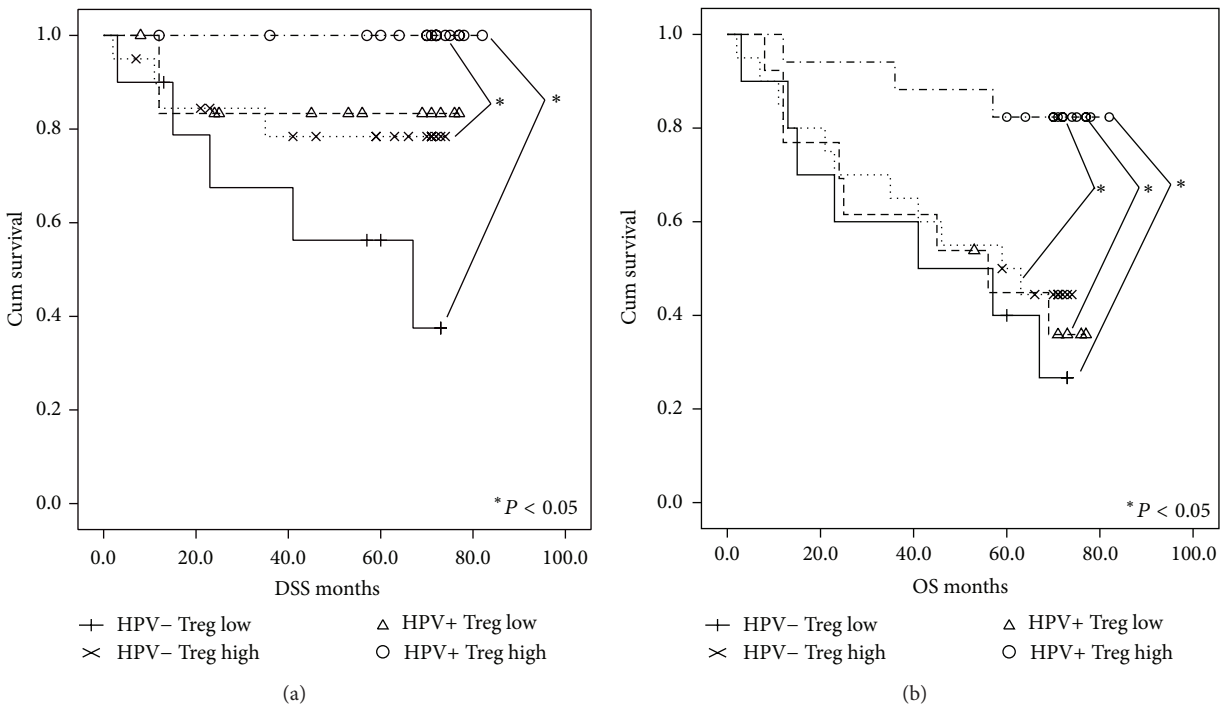

Figure 2: OS and DSS analysis (Kaplan-Meier method and Log Rank test) according to the detection of viral HPV 16 E6 specific mRNA expression and the level of Tregs. Patients with HPV-positive tumors and high levels of Tregs had significantly better both DSS (a) ($P = 0.001$) and OS (b) ($P = 0.005$).

was found in patients with smaller tumors (T1 + T2) (adjusted $P = 0.003$), absence of lymph node metastases (adjusted $P = 0.041$), no recurrences (adjusted $P = 0.0001$), higher Tregs counts (adjusted $P = 0.035$), and lower CD8+/Tregs ratio (adjusted $P = 0.011$).

4. Discussion

In this study, we identified higher level of Tregs and lower ratio of CD8/Tregs as factors positively influencing OS of patients independently of HPV status. We also confirmed our previous results, that is, that HPV positivity, tumor size, and recurrence are factors correlated with overall survival of HNSCC patients [9]. Additionally, we found that HPV-positive, lower histological grade tumors are characteristic for improved DSS in patients without recurrence and a lower ratio of CD8/Tregs. The accumulation of regulatory Tregs in various human carcinomas is generally associated with a poor prognosis, as expected from their capacity to inhibit antitumor immunity. However, a high Tregs infiltration is associated with a favorable prognosis in patients bearing colorectal carcinoma, malignant melanoma, or lymphoma [24, 42–45]. The role of Tregs in HNSCC is a matter of debate. In some clinical studies, increased levels of Tregs infiltrating HNSCC tumors were found prognostically favorable [30–33]. To explain the paradoxical role of Tregs in HNSCC, we emphasize a putative role of the translocation of microbial flora from the oropharynx to HNSCC tissues, similarly as suggested by Ladoire et al. [43] for colorectal tumors. This microbiological hazard provokes a T-cell-mediated antimicrobial inflammatory response that involves Th17 cells and can thereby promote cancer growth. The Th17-cell-dependent proinflammatory and tumor-enhancing response can be attenuated by Tregs, thus constituting a possible explanation for their favorable role in HNSCC prognosis. It is also possible that high levels of Tregs might be a part of the mechanism maintaining HPV-positive status of some HNSCC tumors.

In the study, immunological parameters from the peripheral blood were retrospectively evaluated and correlated to the virological status of HNSCC patients. Many studies have confirmed the transcription factor Forkhead box P3 (FoxP3) as a specific marker for human Tregs [46]. The collection of samples started before the specific monoclonal antibody detecting FoxP3 was available, which permitted to longitudinally follow a higher number of patients and to better evaluate statistical significance; moreover, it was not technically possible to detect FoxP3 by the reanalyzing frozen samples of the peripheral blood. The CD25 receptor is expressed not only by Tregs but also by activated effector T cells at some stage in their lifespan during an inflammatory process. Therefore, we examined WBC and CRP as the markers of inflammation, correlating them with the level of CD4+CD25+ cells. None of patients in our study had elevated WBC and CRP which indicates that probably most of the CD4+CD25+ cells were Tregs [47].

Lau et al. [26] and Green et al. [35] have observed a positive correlation between peripheral CD4+ $CD25^{high}$ Tregs and tumor infiltrating CD4+ $CD25^{high}$ Tregs in HNSCC

Table 4: Factors with impact on patients' survival (Cox regression analysis).

	Disease specific survival						Overall survival					
	P value	HR	95% CI	Adjusted[a] *P* value	Adjusted HR	95% CI	*P* value	HR	95% CI	Adjusted[a] *P* value	Adjusted HR	95% CI
Gender												
Female		Referent			Referent			Referent			Referent	
Male	0.277	0.326	0.043–2.458	0.356	0.385	0.051–2.929	0.099	0.300	0.072–1.253	0.126	0.327	0.078–1.370
Age	**0.035**	0.972	0.920–1.026		NA		0.892	1.003	0.963–1.044		NA	
Tobacco												
Nonsmoker		Referent			Referent			Referent			Referent	
Smoker	0.218	0.623	0.293–1.323	0.435	0.740	0.347–1.576	**0.019**	0.505	0.285–0.894	**0.021**	0.496	0.274–0.898
Alcohol												
No		Referent			Referent			Referent			Referent	
Yes	0.971	1.010	0.586–1.741	0.837	1.059	0.615–1.822	0.505	1.506	0.452–5.017	0.864	0.966	0.647–1.440
Tumor size												
T1 + T2		Referent			Referent			Referent			Referent	
T3 + T4	0.187	1.930	0.727–5.127	0.151	2.061	0.768–5.529	**0.027**	2.192	1.092–4.396	**0.021**	2.296	1.135–4.646
Nodal status												
N0		Referent			Referent			Referent			Referent	
N1–N3	0.091	3.565	0.959–1.033	**0.020**	6.035	1.334–27.305	0.188	1.700	0.771–3.747	0.064	2.228	0.995–5.194
Tumor grade												
G1		Referent			Referent			Referent			Referent	
G2 + G3	0.980	1.006	0.627–1.616	0.932	1.018	0.683–1.516	0.408	1.102	0.875–1.388	0.498	1.080	0.864–1.350
Tumor location												
Oropharyngeal		Referent			Referent			Referent			Referent	
Oral	0.631	1.363	0.386–4.814	0.993	1.006	0.277–3.653	0.812	0.881	0.309–2.51	0.508	0.697	0.239–2.029
Recurrence												
No		Referent			Referent			Referent			Referent	
Yes	**0.0001**	12.208	4.591–32.46	**0.001**	10.503	3.843–28.705	**0.0001**	6.936	3.372–14.268	**0.0001**	6.711	3.192–14.111
Tregs	**0.054**	0.917	0.840–1.001	0.061	0.920	0.843–1.004	0.459	0.984	0.943–1.027	0.525	0.986	0.956–1.029
Tregs												
Low		Referent			Referent			Referent			Referent	
High	0.098	0.428	0.157–1.171	0.085	0.413	0.151–1.129	0.097	0.563	0.286–1.109	0.103	0.568	0.269–1.123
CD4+	0.929	1.003	0.946–1.063	0.772	0.991	0.936–1.051	0.815	0.995	0.956–1.036	0.615	0.990	0.951–1.030
CD8+	0.260	1.032	0.956–1.105	1.091	1.027	0.972–1.085	0.199	1.026	0.987–1.066	0.236	10.023	0.985–1.063
CD4+CD8+sum	0.202	1.038	0.980–1.098	0.472	1.021	0.964–1.082	0.272	1.023	0.982–1.065	0.443	1.012	0.974–1.061
CD4+/CD8+	0.274	0.701	0.371–1.325	0.246	0.693	0.373–1.288	0.154	0.735	0.481–1.112	0.129	0.725	0.479–1.098
CD8+/Tregs	**0.001**	1.211	1.098–1.336	**0.001**	1.187	1.074–1.311	0.004	1.150	1.045–1.266	**0.012**	1.136	1.029–1.253
CD19	0.851	0.991	0.905–1.085	0.953	1.003	0.921–1.091	0.617	0.986	0.924–1.052	0.853	0.994	0.932–1.060
CD3−56+16+	**0.020**	0.885	0.798–0.981	0.062	0.905	0.815–1.005	0.295	0.986	0.911–1.029	0.409	0.974	0.915–1.037
HPV DNA												
Negative		Referent						Referent				
Positive	**0.057**	0.335	0.109–1.033		NA		0.125	0.582	0.292–1.162		NA	

[a]adjusted for HPV and age, HR: hazard ratio 95% CI: confidence interval; *P*: probability.

patients. In contrast, Wamsom et al. [32] who compared CD4+, CD8+, CD4+/CD8+, and FoxP3 T cell subsets have not found any correlation of the levels of these T cells types in the peripheral blood and in the tumor microenvironment between HPV-positive and HPV-negative head and neck tumors.

Human papillomaviruses are now, together with smoking and alcohol consumption, an established risk factor for head and neck cancer [48]. HPVs are present in 67.0% of oropharyngeal cancers, especially tonsillar carcinomas. In our study, HPV positivity was also the highest in tonsillar tumors (63.3%). To overcome the possible misclassification of tumors as HPV positive, we determined active viral infection by the detection of E6 mRNA expression and presence of p16 protein. The majority of samples (87.0%) positive for HPV type 16 DNA expressed viral HPV 16 E6 mRNA. Similar observation has been reported by our group before [9]. Some studies have found a slightly less frequent expression of viral oncogenes in HPV DNA-positive tumors [41, 49], which can be attributed to variation in the numbers of samples from the oropharynx or in other anatomical sites. In our study, most tumors were located in the oropharynx (87.0%).

We observed increased mean levels of NK cells and B cell lymphocytes in patients with HPV-positive tumors; however, only the former difference was marginally significant. No differences in the levels of immunological parameters in the peripheral blood were detected when comparing the patients without recurrence and/or those who died were compared. We have previously reported decreased numbers of NK cells in HNSCC patients in comparison to healthy controls [29]. In the present study, we further stratify HNSCC patients according to the etiology of their tumors and show that there is a significant difference in the level of NK cells between the groups of HPV-positive and HPV negative patients. We found higher levels of NK cells in HPV-positive patients with better prognosis.

While it has been shown that for the initial steps of HNSCC tumor development one of the known etiological factors, smoking, alcohol, and HR HPV infection, is necessary, the growth and tumor progression is associated with the local failure of the host immune system. NK cells are part of the innate immune defense against pathogens and cancer [50]. Recently, also reduced cytotoxic activity of NK cells has been observed in patients with cervical precancerous lesions and cancer due to decreased expression of the NK-activating receptors caused by HPV 16 [15].

Renoux et al. [15] have reported that NK cells are stimulated by the binding of HPV-specific VLPs via C16 receptor to higher cytotoxicity and increased cytokines production. We hypothesize that the activation of NK cells in HNSCC patients with HPV-positive tumors can lead to an improved survival in comparison to those with HPV-negative tumors. Further studies are needed to confirm our observation.

Our results are consistent with the findings of Schaefer et al. [27], Strauss et al. [28], and Boucek et al. [29] who reported that HNSCC patients have higher numbers of Tregs in the peripheral blood in comparison to healthy controls. Moreover, several studies have demonstrated higher numbers of Tregs in the peripheral blood of patients with solid tumors in other locations such as lung [22], pancreas [20], liver [23], and breast [20]. Other authors have found lower numbers of circulating Tregs in patients with HNSCC [13].

Only a limited number of studies have analyzed the relationship between HPV-associated HNSCC, the immune profile, and prognosis of these patients. Wamsom et al. [32] have detected increased levels of FoxP3 Tregs infiltrating tumors prognostically favorable and have observed improved DSS and OS, associated with increased tumor infiltrating lymphocytes independent of HPV status. Näsman et al. [33] have reported that increased number of tumor infiltrating CD8+ lymphocytes and higher CD8+/Tregs ratio may contribute to better clinical outcome in both HPV-positive and HPV-negative tonsillar squamous cell carcinoma patients. In our study, the association of Tregs with survival is significant when adjusted for HPV positivity and age. This important finding suggests that the level of Tregs in the peripheral blood is a marker of improved prognosis of HNSCC patients. However, we found the Tregs levels to be independent of other strong prognostic factors as is the etiology of the tumor. Not surprisingly, the multivariate analysis showed improved DSS and OS in patients with smaller tumors and no recurrences. The differences retained their statistical significance also after adjusting for HPV and age. We analyzed the survival of patients in relation to both HPV status and Tregs level. Patients with HPV-positive tumors and higher levels of Tregs had significantly better DSS and OS in comparison with the other three groups (HPV−/Tregs low; HPV−/Tregs high; HPV+/Tregs low), except for DSS in those with HPV+/Tregs low. Using the interaction test, we did not find a relationship between these two prognostic markers. Our data suggest that HPV infection and Tregs do not influence patient prognosis in concurrence.

5. Conclusion

Better survival of HNSCC patients is associated with HPV etiology of the tumor as well as with the elevated levels of regulatory T cells and lower CD8+/Tregs ratio. These virological and immunological parameters do not influence patient prognosis in concurrence. The combination of HPV positivity and increased levels of Tregs may have a prognostic value in patients with head and neck carcinoma.

Conflict of Interests

E. Lukesova, J. Boucek, E. Rotnaglova, M. Salakova, E. Koslabova, M. Grega, T. Eckschlager, B. Rihova, B. Prochazka, J. Klozar, R. Tachezy have no conflict of interests to disclose.

Acknowledgments

The paper was supported by the Grant Agency of the Ministry of Health of the Czech Republic, Grant nos. NT 12 483 and 11542 Ministry of Health; Granting Agency of the Czech Republic P304/12/2244, Czech Republic, conceptual development of research organization, University Hospital

Motol, Prague, Czech Republic, 00064203; SVV 266513; UNCE 204013; and PRVOUK 27-1.

References

[1] S. Warnakulasuriya, "Global epidemiology of oral and oropharyngeal cancer," *Oral Oncology*, vol. 45, no. 4-5, pp. 309–316, 2009.

[2] G. Zivile, D. Janina, M. Irina, C. Saulius, S. Raisa, and Z. Aliaksandr, "Prevalence of human papillomaviruses in patients with head and neck squamous cell carcinoma in Lithuania and Belarus," *Journal of Medical Virology*, vol. 86, no. 3, pp. 531–535, 2014.

[3] L. Hammarstedt, D. Lindquist, H. Dahlstrand et al., "Human papillomavirus as a risk factor for the increase in incidence of tonsillar cancer," *International Journal of Cancer*, vol. 119, no. 11, pp. 2620–2623, 2006.

[4] E. M. Genden, I. M. Sambur, J. R. de Almeida, M. Posner, A. Rinaldo, J. P. Rodrigo et al., "Human papillomavirus and oropharyngeal squamous cell carcinoma: what the clinician should know," *European Archives of Oto-Rhino-Laryngology*, vol. 270, no. 2, pp. 405–416, 2013.

[5] A. Näsman, P. Attner, L. Hammarstedt et al., "Incidence of human papillomavirus (HPV) positive tonsillar carcinoma in Stockholm, Sweden: an epidemic of viral-induced carcinoma?" *International Journal of Cancer*, vol. 125, no. 2, pp. 362–366, 2009.

[6] A. K. Chaturvedi, E. A. Engels, W. F. Anderson, and M. L. Gillison, "Incidence trends for human papillomavirus-related and -unrelated oral squamous cell carcinomas in the United States," *Journal of Clinical Oncology*, vol. 26, no. 4, pp. 612–619, 2008.

[7] E. M. Smith, J. M. Ritchie, K. F. Summersgill et al., "Age, sexual behavior and human papillomavirus infection in oral cavity and oropharyngeal cancers," *International Journal of Cancer*, vol. 108, no. 5, pp. 766–772, 2004.

[8] J. Sivasithamparam, C. A. Visk, E. E. Cohen, and A. C. King, "Modifiable risk behaviors in patients with head and neck cancer," *Cancer*, vol. 119, no. 13, pp. 2419–2426, 2013.

[9] E. Rotnaglova, R. Tachezy, M. Salakova, B. Prochazka, E. Kosl'abova, E. Vesela et al., "HPV involvement in tonsillar cancer: prognostic significance and clinically relevant markers," *International Journal of Cancer Journal International Du Cancer*, vol. 129, pp. 101–110, 2011.

[10] P. Attner, J. Du, A. Näsman et al., "Human papillomavirus and survival in patients with base of tongue cancer," *International Journal of Cancer*, vol. 128, no. 12, pp. 2892–2897, 2011.

[11] M. Plummer, M. Schiffman, P. E. Castle, D. Maucort-Boulch, and C. M. Wheeler, "A 2-year prospective study of human papillomavirus persistence among women with a cytological diagnosis of atypical squamous cells of undetermined significance or low-grade squamous intraepithelial lesion," *Journal of Infectious Diseases*, vol. 195, no. 11, pp. 1582–1589, 2007.

[12] S. Saussez, A. Duray, S. Demoulin, P. Hubert, and P. Delvenne, "Immune suppression in head and neck cancers: a review," *Clinical and Developmental Immunology*, vol. 2010, Article ID 701657, 15 pages, 2010.

[13] T. K. Hoffmann, G. Dworacki, T. Tsukihiro et al., "Spontaneous apoptosis of circulating T lymphocytes in patients with head and neck cancer and its clinical importance," *Clinical Cancer Research*, vol. 8, no. 8, pp. 2553–2562, 2002.

[14] T. L. Whiteside, "Immunobiology of head and neck cancer," *Cancer and Metastasis Reviews*, vol. 24, no. 1, pp. 95–105, 2005.

[15] V. M. Renoux, B. Bisig, I. Langers et al., "Human papillomavirus entry into NK cells requires CD16 expression and triggers cytotoxic activity and cytokine secretion," *European Journal of Immunology*, vol. 41, no. 11, pp. 3240–3252, 2011.

[16] S. Textor, M. Dürst, L. Jansen et al., "Activating NK cell receptor ligands are differentially expressed during progression to cervical cancer," *International Journal of Cancer*, vol. 123, no. 10, pp. 2343–2353, 2008.

[17] S. Wulff, R. Pries, K. Börngen, T. Trenkle, and B. Wollenberg, "Decreased levels of circulating regulatory NK cells in patients with head and neck cancer throughout all tumor stages," *Anticancer Research*, vol. 29, no. 8, pp. 3053–3057, 2009.

[18] W. P. Accomando, J. K. Wiencke, E. A. Houseman, R. A. Butler, S. Zheng, H. H. Nelson et al., "Decreased NK cells in patients with head and neck cancer determined in archival DNA," *Clinical Cancer Research*, vol. 18, pp. 6147–6154, 2012.

[19] J. W. Molling, J. A. E. Langius, J. A. Langendijk et al., "Low levels of circulating invariant natural killer T cells predict poor clinical outcome in patients with head and neck squamous cell carcinoma," *Journal of Clinical Oncology*, vol. 25, no. 7, pp. 862–868, 2007.

[20] U. K. Liyanage, T. T. Moore, H.-G. Joo et al., "Prevalence of regulatory T cells is increased in peripheral blood and tumor microenvironment of patients with pancreas or breast adenocarcinoma," *Journal of Immunology*, vol. 169, no. 5, pp. 2756–2761, 2002.

[21] P. Salama, M. Phillips, F. Grieu et al., "Tumor-infiltrating $FOXP3^+$ T regulatory cells show strong prognostic significance in colorectal cancer," *Journal of Clinical Oncology*, vol. 27, no. 2, pp. 186–192, 2009.

[22] B. Karagoz, O. Bilgi, M. Gümüs et al., "$CD8^+CD28^-$ cells and $CD4^+CD25^+$ regulatory T cells in the peripheral blood of advanced stage lung cancer patients," *Medical Oncology*, vol. 27, no. 1, pp. 29–33, 2010.

[23] J. Fu, Z. Zhang, L. Zhou, Z. Qi, S. Xing, J. Lv et al., "Impairment of $CD4(^+)$ cytotoxic T cells predicts poor survival and high recurrence rates in patients with hepatocellular carcinoma," *Hepatology*, vol. 58, no. 1, pp. 139–149, 2013.

[24] A. Ladányi, B. Somlai, K. Gilde, Z. Fejös, I. Gaudi, and J. Tímár, "T-cell activation marker expression on tumor-infiltrating lymphocytes as prognostic factor in cutaneous malignant melanoma," *Clinical Cancer Research*, vol. 10, no. 2, pp. 521–530, 2004.

[25] R. K. Bhairavabhotla, V. Verma, H. Tongaonkar, S. Shastri, K. Dinshaw, and S. Chiplunkar, "Role of IL-10 in immune suppression in cervical cancer," *Indian Journal of Biochemistry and Biophysics*, vol. 44, no. 5, pp. 350–356, 2007.

[26] K.-M. Lau, S. H. Cheng, K. W. Lo et al., "Increase in circulating $Foxp3^+$ $CD4^+$ $CD25^{high}$ regulatory T cells in nasopharyngeal carcinoma patients," *British Journal of Cancer*, vol. 96, no. 4, pp. 617–622, 2007.

[27] C. Schaefer, G. G. Kim, A. Albers, K. Hoermann, E. N. Myers, and T. L. Whiteside, "Characteristics of $CD4^+CD25^+$ regulatory T cells in the peripheral circulation of patients with head and neck cancer," *British Journal of Cancer*, vol. 92, no. 5, pp. 913–920, 2005.

[28] L. Strauss, C. Bergmann, W. Gooding, J. T. Johnson, and T. L. Whiteside, "The frequency and suppressor function of $CD4^+CD25^{high}Foxp3^+$ T cells in the circulation of patients with

squamous cell carcinoma of the head and neck," *Clinical Cancer Research*, vol. 13, no. 21, pp. 6301–6311, 2007.

[29] J. Boucek, T. Mrkvan, M. Chovanec et al., "Regulatory T cells and their prognostic value for patients with squamous cell carcinoma of the head and neck," *Journal of Cellular and Molecular Medicine*, vol. 14, no. 1-2, pp. 426–433, 2010.

[30] C. Badoual, S. Hans, J. Rodriguez et al., "Prognostic value of tumor-infiltrating $CD4^+$ T-cell subpopulations in head and neck cancers," *Clinical Cancer Research*, vol. 12, no. 2, pp. 465–472, 2006.

[31] Y.-L. Zhang, J. Li, H.-Y. Mo et al., "Different subsets of tumor infiltrating lymphocytes correlate with NPC progression in different ways," *Molecular Cancer*, vol. 9, article 4, 2010.

[32] D. Wamsom, E. Light, D. Thomas et al., "Infiltrating lymphocytes and human papillomavirus-16-associated oropharyngeal cancer," *Laryngoscope*, vol. 122, no. 1, pp. 121–127, 2012.

[33] A. Näsman, M. Romanitan, C. Nordfors, N. Grun, H. Johansson, L. Hammarstedt et al., "Tumor infiltrating $CD8^+$ and $Foxp3^+$ lymphocytes correlate to clinical outcome and human papillomavirus (HPV) status in tonsillar cancer," *PloS ONE*, vol. 7, Article ID e38711, 2012.

[34] H. J. Aarstad, J.-H. Heimdal, B. Klementsen, J. Olofsson, and E. Ulvestad, "Presence of activated T lymphocytes in peripheral blood of head and neck squamous cell carcinoma patients predicts impaired prognosis," *Acta Oto-Laryngologica*, vol. 126, no. 12, pp. 1326–1333, 2006.

[35] V. L. Green, A. Michno, N. D. Stafford, and J. Greenman, "Increased prevalence of tumour infiltrating immune cells in oropharyngeal tumours in comparison to other subsites: relationship to peripheral immunity," *Cancer Immunology, Immunotherapy*, vol. 62, pp. 863–873, 2013.

[36] E. Koslabova, E. Hamsikova, M. Salakova, J. Klozar, E. Foltynova, E. Salkova et al., "Markers of HPV infection and survival in patients with head and neck tumours," *International Journal of Cancer*, vol. 133, no. 8, pp. 1832–1839, 2013.

[37] J. Klozar, V. Kratochvil, M. Salakova et al., "HPV status and regional metastasis in the prognosis of oral and oropharyngeal cancer," *European Archives of Oto-Rhino-Laryngology*, vol. 265, no. 1, pp. S75–S82, 2008.

[38] R. Tachezy, J. Klozar, M. Saláková et al., "HPV and other risk factors of oral cavity/oropharyngeal cancer in the Czech Republic," *Oral Diseases*, vol. 11, no. 3, pp. 181–185, 2005.

[39] A. J. C. van den Brule, R. Pol, N. Fransen-Daalmeijer, L. M. Schouls, C. J. L. M. Meijer, and P. J. F. Snijders, "$GP5^+/6^+$ PCR followed by reverse line blot analysis enables rapid and high-throughput identification of human papillomavirus genotypes," *Journal of Clinical Microbiology*, vol. 40, no. 3, pp. 779–787, 2002.

[40] P. E. Gravitt, C. Peyton, C. Wheeler, R. Apple, R. Higuchi, and K. V. Shah, "Reproducibility of HPV 16 and HPV 18 viral load quantitation using TaqMan real-time PCR assays," *Journal of Virological Methods*, vol. 112, no. 1-2, pp. 23–33, 2003.

[41] S. J. Smeets, A. T. Hesselink, E.-J. M. Speel et al., "A novel algorithm for reliable detection of human papillomavirus in paraffin embedded head and neck cancer specimen," *International Journal of Cancer*, vol. 121, no. 11, pp. 2465–2472, 2007.

[42] S. Raghavan and M. Quiding-Jädierbrink, "Regulatory T cells in gastrointestinal tumors," *Expert Review of Gastroenterology and Hepatology*, vol. 5, no. 4, pp. 489–501, 2011.

[43] S. Ladoire, F. Martin, and F. Ghiringhelli, "Prognostic role of $FOXP3^+$ regulatory T cells infiltrating human carcinomas: the paradox of colorectal cancer," *Cancer Immunology, Immunotherapy*, vol. 60, no. 7, pp. 909–918, 2011.

[44] X. Ke, J. Wang, J. Li, I. H. Chen, H. Wang, and X.-F. Yang, "Roles of $CD4^+CD25^{high}$ $FOXP3^+$ Tregs in lymphomas and tumors are complex," *Frontiers in Bioscience*, vol. 13, no. 10, pp. 3986–4001, 2008.

[45] T. Álvaro, M. Lejeune, M. T. Salvadó et al., "Outcome in Hodgkin's lymphoma can be predicted from the presence of accompanying cytotoxic and regulatory T cells," *Clinical Cancer Research*, vol. 11, no. 4, pp. 1467–1473, 2005.

[46] G. Roncador, P. J. Brown, L. Maestre et al., "Analysis of FOXP3 protein expression in human $CD4^+CD25^+$ regulatory T cells at the single-cell level," *European Journal of Immunology*, vol. 35, no. 6, pp. 1681–1691, 2005.

[47] S. Sakaguchi, N. Sakaguchi, M. Asano, M. Itoh, and M. Toda, "Pillars article: immunologic self-tolerance maintained by activated T cells expressing IL-2 receptor alpha-chains (CD25). Breakdown of a single mechanism of self-tolerance causes various autoimmune diseases. J. Immunol. 1995," *Journal of Immunology*, vol. 186, pp. 3808–3821, 2011.

[48] E. M. Smith, L. M. Rubenstein, T. H. Haugen, M. Pawlita, and L. P. Turek, "Complex etiology underlies risk and survival in head and neck cancer human papillomavirus, tobacco, and alcohol: a case for multifactor disease," *Journal of Oncology*, vol. 2012, Article ID 571862, 9 pages, 2012.

[49] M. Hoffmann, S. Tribius, E. S. Quabius et al., "HPV DNA, $E6^*I$-mRNA expression and p16INK4A immunohistochemistry in head and neck cancer—how valid is p16INK4A as surrogate marker?" *Cancer Letters*, vol. 323, no. 1, pp. 88–96, 2012.

[50] E. Ames and W. J. Murphy, "Advantages and clinical applications of natural killer cells in cancer immunotherapy," *Cancer Immunology, Immunotherapy*, vol. 63, no. 1, pp. 21–28, 2014.

Hindawi Publishing Corporation
BioMed Research International
Volume 2014, Article ID 390825, 8 pages
http://dx.doi.org/10.1155/2014/390825

Research Article

Outcome and Prognostic Factors in T4a Oropharyngeal Carcinoma, Including the Role of HPV Infection

Georgios Psychogios,[1] Konstantinos Mantsopoulos,[1] Abbas Agaimy,[2] Kathrin Brunner,[2] Elisabeth Mangold,[1] Johannes Zenk,[1] and Heinrich Iro[1]

[1] *Department of Otorhinolaryngology, Head and Neck Surgery, Friedrich Alexander University of Erlangen-Nuremberg, Waldstraße 1, 91054 Erlangen, Germany*
[2] *Institute of Pathology, Friedrich Alexander University of Erlangen-Nuremberg, Krankenhausstraße 10, 91054 Erlangen, Germany*

Correspondence should be addressed to Georgios Psychogios; gpsychogios@gmail.com

Received 10 January 2014; Revised 12 February 2014; Accepted 14 February 2014; Published 31 March 2014

Academic Editor: Jan Plzák

Background. The prognosis of patients with advanced oropharyngeal carcinoma (OPSCC) is generally poor. The aim of this study is to investigate the different therapeutic approaches and identify prognostic factors associated with a worse outcome for patients treated for T4a OPSCC, in order to improve treatment selection for the individual. *Methods*. A retrospective study was conducted on 426 patients with T4a OPC treated between 1980 and 2010. Eleven prognostic factors including treatment modality, lymph node staging, and p16 status as a surrogate marker for human papillomavirus (HPV) infection were analyzed. *Results*. Univariate analysis showed a significant difference in DSS between N0 and N+ (57.1% versus 26.9%, $P < 0.001$), primary surgical and primary nonsurgical treatment (52.7% versus 31.4%, $P < 0.001$), and perinodal invasion (51.7% versus 19.9%, $P = 0.011$). P16-negative patients tended towards a worse DSS than p16-positive patients (40.2% versus 64.6%, $P = 0.126$) but responded better to primary surgery than to nonsurgical treatment (71.4% versus 34.0%, $P = 0.113$). Multivariate analysis identified the N category as an independent prognostic factor for survival. *Conclusion*. The survival of p16-negative patients was worse than p16-positive patients, although they seem to respond better to primary surgery. The strongest independent prognostic factor for T4a carcinomas proved to be the presence of lymph node metastases.

1. Introduction

The management of patients with locally advanced oropharyngeal squamous cell carcinoma (OPSCC) has evolved greatly. A decade ago, several studies showed that radiotherapy (RT) in combination with chemotherapy (CT) offers oncologic and functional results similar to those of surgery but with lower severe complication rates [1–3]. Furthermore, in the light of increasing importance of human papillomavirus (HPV) infection in OPSCC and better survival after radiochemotherapy (RCT) in this group of patients, primary RCT has emerged as treatment of choice for this subset of patients in many institutions [4, 5].

However, recent studies showed that both RT and CT can cause serious morbidity such as dysphagia, mandibular osteoradionecrosis, and pharyngeal strictures and may be associated with higher mortality rates [6, 7]. Furthermore the concept of organ preservation does not always coincide with function preservation. On the other hand, other studies have shown that the evolution of primary surgery, with the use of CO_2 laser, robotic surgery, and microvascular reconstruction, has reduced surgery-related morbidity and mortality and improved function with even better oncologic results in some cases [8–12]. The most appropriate treatment regimen is therefore still controversial.

Prognostic factors are important in helping physicians to select the best treatment modality for the individual patient and for better planning of prospective studies. T4a tumors were first defined in the 2002 TNM staging and represented a unique study group, because although the tumor has invaded critical structures it can still be resected surgically. To the best of our knowledge, this is the largest study to assess oncologic

outcome and prognostic factors in T4a OPC and also the first study to examine the role of p16 expression as a marker for HPV infection solely in this patient group [13].

2. Methods

A retrospective study was conducted at an academic tertiary referral center (Department of Otorhinolaryngology, Head and Neck Surgery, University of Erlangen-Nuremberg Medical School, Erlangen, Germany). Patients referred to our hospital between 1980 and 2010, who had received definitive treatment for previously untreated squamous cell carcinomas of the oropharynx, were considered for selection. The study included all patients who had a cT4a Nall M0 tumor if not treated with primary operation and pT4a if primary surgical treatment was applied (stage IVa or IVb). Exclusion criteria were previous treatment for head and neck carcinomas, distant metastases at the time of diagnosis, histology other than SCC, and patients with second primary tumors at the time of diagnosis. The institutional review board approved the study.

After reviewing the pretherapeutic imaging and the surgical and the pathology reports, staging was reevaluated according to the 2010 American Joint Committee on Cancer (AJCC) and Union Internationale Contre le Cancer (UICC) classification [14]. Since T4 carcinomas had been subdivided into T4a and T4b in 2002, the files of patients with T4 tumors treated prior to this date were carefully reassessed to differentiate between T4a and T4b. In 31 cases this differentiation was not possible and these patients were not included for further evaluation. Following clinical examination, standard diagnostic investigations included ultrasonography and computed tomography. Magnetic resonance imaging (MRI) was also used in a few cases. The appropriate treatment modality was decided by our interdisciplinary tumor board. Factors influencing the decision were the operability of the tumor, general health, and personal preference of each patient.

The endpoints for the analysis were disease-specific survival (DSS), local control (LC), and regional control (RC). DSS was defined as the time from the date of diagnosis to death from the cancer or complications of treatment. Duration of LC or RC was calculated from the date of initial diagnosis to the date of most recent clinical review when local or regional recurrence was confirmed. Local recurrence was defined as invasive carcinoma at the anatomic site of the primary tumor and regional recurrence as invasive carcinoma in the lymph nodes of the neck, developing after completion of the initial treatment. Calculations of five-year overall survival (OS), disease-specific survival (DSS), local control (LC), and regional control (RC) were made with Kaplan-Meier estimates and compared using the log-rank test. A P value of less than 0.05 was considered significant. Multivariate analysis was performed with backward stepwise Cox regression using significant variables from the univariate analysis. All statistical analyses were performed using SPSS Version 20 (SPSS Inc., Chicago IL, USA).

Any HPV infection in tumor tissue was determined retrospectively, using p16 immunohistochemistry as a highly sensitive and specific surrogate marker for HPV-associated carcinogenesis [15]. P16 immunohistochemistry was performed using a primary antibody from Santa Cruz Biotechnology (clone JC8, dilution: 1 : 100). Tumors were considered positive for p16 when strong nuclear and cytoplasmic staining was present in >60% of cells. The p16 oncoprotein expression was successfully determined using paraffin blocks available from 93 patients treated between 2000 and 2010. Characteristics of the two groups were controlled using the chi-square test.

3. Results

Initially 581 Patients were selected. Forty-five cases were excluded because of second primary tumors at the time of diagnosis, 53 patients because of distant metastases, and 57 patients because of incomplete treatment. The final study population consisted of 426 patients who met the inclusion criteria. There were 374 men and 52 women, with 7.2 : 1 male to female ratio. The median age at presentation was 54 years ranging from 32 to 82 (SD 9.9). Median follow-up was 1.64 years (range: 0–26.3). For surgically treated patients, median follow-up was 1.54 years (range: 0–17.2) and for nonsurgically treated patients follow-up was 2.11 years (range: 0–26.3). 245 (57.5%) patients were smokers, 51 (11.9%) exsmokers, and 21 (4.9%) nonsmokers. Information about smoking was not available for 109 (25.6%) patients. 237 (55.6%) patients drank alcohol, 48 (11.3%) were exdrinkers, and 28 (6.6%) teetotalers. No information was available for 115 patients.

The five-year OS was 21.6% (95% CI: 17–26%), DSS 35.6% (95% CI: 30–41%); LC was seen in 81.3% (95% CI: 77–86%) and RC in 89% (95% CI: 84–94%). There was a local recurrence in 65 (15.6%) patients, a regional one in 22 (5.16%), and distant metastasis in 27 (6.3%) of the 426 patients. Mean time to the first local recurrence was 0.47 years.

Two major groups were defined according to the type of management. The first group consisted of 316 patients who received radiotherapy with or without concomitant chemotherapy (RCT group) and salvage surgery in some cases. The second group of 83 patients received primary surgical treatment with or without adjuvant radio- (or chemo)therapy. Table 1 shows survival estimates in relation to treatment modality. The prognosis was found to differ significantly between the two groups. Univariate analysis showed that the surgery group had a significantly better DSS ($P < 0.001$) and OS ($P < 0.001$) in comparison with the RCT group. On the other hand, LC and RC were comparable in the two groups. Figure 1 presents the Kaplan-Meier curve of DSS in relation to the primary treatment group. A specific comparison of only those cases with combined treatment modalities showed that both DSS and OS were statistically better following surgery with adjuvant radio- or radiochemotherapy (64 patients) in comparison with combined primary chemoradiotherapy with or without salvage surgery (151 patients) (OS = 44.4% [95% CI: 32–57%] versus 18.6% [95% CI: 12–25%], $P < 0.001$) (DSS = 53.5% [95% CI: 40–67%] versus 33.8% [95% CI: 24–42], $P < 0.001$). Twenty-seven patients could not be included in either of the two groups because they had only palliative

Table 1: Oncologic results according to treatment group.

Treatment group	Number of patients	5-Y-KM-Estimate (%) (total number of events) (95% CI)				
		OS	DSS	LC	RC	DC
Primary surgical group	**83**	**41.2 (67) (30–52)**	**52.7 (35) (41–65)**	**74.2 (16) (63–86)**	***84.7 (8) (75–95)**	***86.5 (6) (76–97)**
Surgery	19	30.4 (16) (6–54)	*47.2 (8) (19–75)	*55.6 (5) (26–85)	*67.5 (2) (27–100)	No events*
Surgery + RT	38	38.9 (33) (21–52)	41.8 (20) (25–58)	*75.7 (8) (6–91)	*81.6 (5) (67–96)	*90.0 (2) (76–100)
Surgery + RCT	26	56.7 (18) (37–76)	*72.7 (7) (54–92)	*87.5 (3) (71–100)	*95.8 (1) (87–100)	56.7 (18) (37–76)
Primary conservative group	**316**	**17.3 (263) (13–22)**	**31.4 (184) (23–39)**	**83.8 (43) (79–89)**	**91.8 (11) (86–97)**	**80.4 (20) (71–89)**
RCT ± salvage	151	18.6 (129) (12–25)	33.8 (91) (24–42)	83.5 (21) (76–91)	*96.0 (4) (92–100)	76.8 (11) (62–91)
RT ± salvage	165	16.8 (134) (11–23)	29.6 (93) (21–38)	84.2 (22) (78–91)	*88.8 (7) (80–98)	83.0 (9) (71–95)

*Not enough events or patients for statistical analysis.

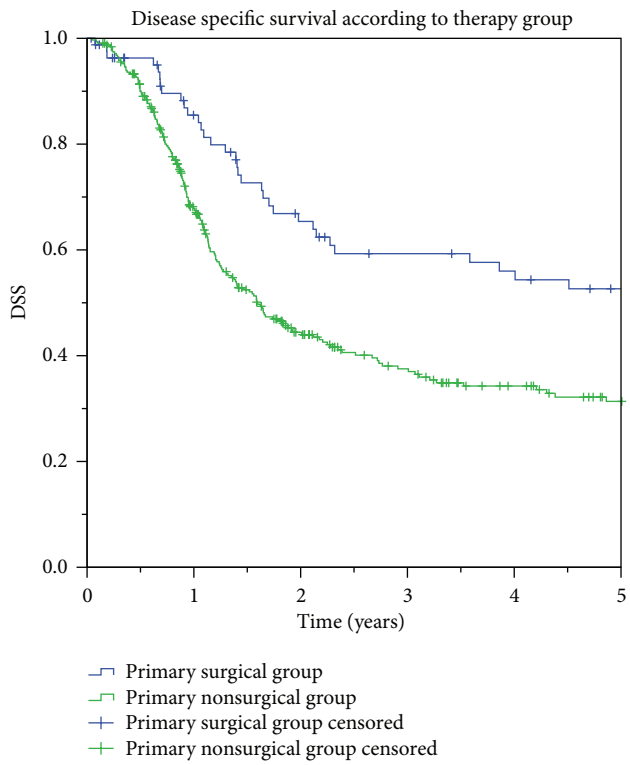

Figure 1: DSS (disease-specific survival) estimates according to treatment group (52.7% 95% CI 41–65% versus 31.4% 95% CI 23–39%, $P = 0.001$).

therapy (e.g., only chemotherapy or postchemotherapy salvage surgery).

Evidence of regional disease was found in 303 cases. Table 2 shows survival according to the clinical N category. For the statistical analysis, patients were grouped in cN0 and cN+ cases. As shown in Table 4, patients who were cN0 had significantly better DSS and OS. Of the patients classified as cN0 who underwent primary surgical therapy (13), 9 had an elective neck dissection. Three out of nine patients had evidence of regional metastases on histopathology, giving an occult metastasis rate of 33.3%.

Immunohistochemical p16 oncoprotein expression was determined in 93 patients. Fifteen proved to be p16-positive, while 78 were p16-negative, giving a rate of 16%. The mean age of the former group was 56.2 and that of the latter was 62.8 years. Univariate analysis revealed a better DSS (64.6% versus 40.2%, $P = 0.126$) and OS (40.2% versus 23.4%, $P = 0.388$) for p16-positive cases but the differences were not statistically significant. Table 3 shows the oncologic results in relation to the therapy group for p16-positive and p16-negative patients separately. Three cases could not be included in either of the treatment groups, so that 90 patients were analyzed. The small number of p16-positive patients did not allow for a statistical comparison of the two treatment groups. On the other hand, patients who were p16-negative showed a trend towards better survival following primary surgery than after primary conservative treatment. Figures for OS were 50.0% versus 19.1% ($P = 0.102$) and for DSS were 71.4% versus 34.0% ($P = 0.113$), respectively.

Of the 83 patients who underwent primary surgical treatment, clear surgical margins (R0) were achieved in 64 patients (77.1%), while resections had positive margins (R+) in the remaining 19 patients (22.9%). As Table 4 shows, patients with R0 resections had better DSS, OS, and distal metastasis rates. Nineteen of the surgical patients did not have a neck dissection, however, and they showed significantly worse DSS and OS.

Table 4 shows the results of univariate analysis of eleven potential prognostic factors. Statistical analysis of perinodal and lymphatic invasion was flawed because of the small number of cases in one group. Nevertheless, patients without perinodal invasion had better DSS and OS. Female patients showed a trend towards better DSS and OS. Lastly, age and

Table 2: Oncologic results according to cN category.

N category	Number of patients	5-Y-KM-Estimate (%) (Total number of events) (95% CI)				
		OS	DSS	LC	RC	DC
N0	115	40.3 (85) (31–50)	57.1 (43) (47–67)	83.5 (18) (76–91)	*91.5 (6) (84–99)	*85.7 (9) (77–95)
N1	35	17.1 (31) (5–30)	31.7 (22) (14–49)	*80.0 (7) (67–93)	*75.9 (3) (50–1)	No events*
N2	222	13.6 (191) (9–19)	27.7 (132) (20–35)	79.6 (31) (71–88)	*91.9 (8) (86–97)	79.3 (15) (68–91)
N3	46	15.8 (40) (5–27)	20.5 (32) (8–33)	*80.8 (7) (67–94)	*80.7 (5) (63–99)	*76.0 (3) (51–100)
N*x*	8	*25.0 (7) (0–55)	*33.3 (5) (0–71)	*72.9 (2) (41–1)	No events*	No events*

Table 3: Oncologic results according to HPV infection and treatment group.

p16	Treatment group (number of patients)	5-Y-KM-Estimate (%) (Total number of events) (95% CI)				
		OS	DSS	LC	RC	DC
*p16-positive	Primary surgical group (5)	*75.0 (2) (32–100)	No events	No events	No events	*75.0 (1) (32–100)
	RCT group (10)	*26.7 (7) (0–56)	*50.0 (5) (19–81)	*90.0 (1) (71–100)	No events	*88.9 (1) (68–100)
p16-negative	Primary surgical group (10)	50.0 (6) (15–85)	*71.4 (2) (38–100)	*62.5 (2) (21–100)	No events	*85.7 (1) (60–100)
	RCT group (65)	19.1 (43) (6–33) $P = 0.102$	34.0 (30) (15–53) $P = 0.113$	*86.2 (8) (77–95) $P = 0.79$	*97.0 (1) (90–100) $P = 0.67$	*67.5 (5) (35–100) $P = 0.81$
All (90)		26.9 (58) (15–38)	44.5 (37) (30–59)	79.6 (11) (65–94)	*97.9 (1) (94–100)	*76.8 (8) (58–95)

*Not enough events or patients for statistical analysis.

tumor differentiation did not affect survival. The base of the tongue and the tonsillar region (i.e., tonsil, tonsillar fossa, and pillars) were the most commonly affected subsites. As seen in Table 4, univariate analysis did not reveal any significant differences in survival according to the affected anatomic subsite.

A multivariate analysis of appropriate variables was then performed. The N category proved to be a statistically significant independent predictor of reduced DSS (OR = 2.662; P (Wald) = 0.001; 95% CI 1.709 to 4.145) and OS (OR = 2.255; P (Wald) = 0.003; 95% CI 1.327 to 3.834).

4. Discussion

The incidence of OPSCC has been increasing continuously in recent years, a development that has been attributed mainly to HPV infection [16, 17]. Although advances in high-precision radiotherapy and new systemic agents have made nonsurgical treatment of advanced OPSCC, the standard care in many centers, the most appropriate treatment regimen is still the subject of debate [18–20]. The prognostic value of HPV infection has gained importance in clinical research, especially of OPSCC [16, 21]. The expression of p16, which is a surrogate marker for HPV, is usually measured [17]. Nevertheless, a large proportion of patients have HPVnegative OPSCC and, for this reason, their optimal treatment modality should not be neglected [22].

In our study, OPSCC with probably HPV-related pathogenesis represented 16% of cases; this is lower than in recent studies [21] which showed proportions of 40.5–72.2% [23, 24]. There are two explanations for this phenomenon: first, the relatively low proportion of HPV-related oropharyngeal carcinoma in Germany compared to other regions [25] and second, the advanced T category. Patients with HPV-related carcinoma are younger and more discerning and therefore seek medical help before the tumor becomes locally advanced (T4a) [17]. In consequence, the majority of patients with T4a carcinoma treated in Germany are HPV-negative OPSCC. Our study is consistent with previous work that demonstrated worse survival rates for HPV-negative patients [5, 21, 25]. Although our results were not statistically significant, this can be attributed to the small number of p16-positive patients. In fact the low percentage of patients with information about p16 status (93/426) is a weakness of this study.

The poor survival of HPV-negative patients with locally advanced OPSCC makes it essential that treatment modalities be improved for this large patient group, as the optimal treatment regimen has yet to be found. This is in contrast to patients with HPV-positive tumor or with early OPSCC, for whom deescalation of treatment is being discussed [26, 27]. A prospective study comparing primary surgical treatment and primary conservative treatment is unlikely to be realized, since patient and clinician preferences would make recruitment almost impossible. As long as prospective randomized data are lacking, however, nonrandomized data, such as those presented in our study, may offer a basis for treatment decision making.

Our data show a trend toward better OS and DSS for the primary surgically treated patients with HPV-negative T4a OPSCC. Of course, it could be argued that there is a selection

Table 4: Univariate analysis of potential prognostic factors for DSS, OS, LC, RC and distant metastases.

Variable (number of patients)	KM estimates, total number of events, and 95% CI concerning defined events 5-Y-KM-Estimate % (total number of events) (95% CI)				
	Local control (LC)	Neck control (NC)	Distant metastases	Disease-specific survival (DSS)	Overall survival (OS)
Age (years)					
≤54 (223)	77.0 (39) (70–84)	90.1 (10) (83–97)	81.6 (18) (73–90)	31.3 (134) (24–38)	20.8 (190) (15–26)
>54 (203)	85.3 (26) (80–91)	87.6 (12) (80–95)	86.1 (9) (77–95)	41.0 (100) (33–49)	22.5 (164) (16–29)
	$P = 0.199$	$P = 0.495$	$P = 0.127$	$P = 0.165$	$P = 0.864$
Gender					
Male (374)	80.4 (59) (75–85)	87.6 (21) (82–93)	82.7 (23) (75–90)	34.0 (212) (28–40)	19.9 (313) (16–24)
Female (52)	*87.0 (6) (77–97)	*89.1 (1) (84–94)	*86.6 (4) (74–99)	47.5 (100) (42–73)	32.8 (41) (20–46)
	+$P = 0.392$	+$P = 0.207$	+$P = 0.942$	+$P = 0.074$	+$P = 0.188$
Tumor subsite					
Tonsillar region (173)	82.8 (26) (76–89)	83.5 (10) (73–94)	80.4 (14) (70–91)	32.0 (99) (24–40)	19.3 (147) (13–25)
Soft palate (25)	*72.2 (5) (49–95)	*95.0 (1) (85–100)	*635 (3) (25–100)	44.6 (13) (24–65)	21.0 (21) (04–38)
Base of the tongue (189)	81.4 (28) (74–89)	91.1 (10) (86–97)	*88.3 (8) (80–97)	36.2 (103) (28–44)	23.9 (154) (17–30)
Posterior wall (39)	*81.2 (6) (67–95)	*95.5 (1) (87–100)	*86.7 (2) (69–100)	43.3 (19) (26–61)	21.5 (32) (08–35)
R status					
R0 (64)	80.0 (12) (70–90)	82.2 (8) (71–94)	91.4 (3) (82–100)	60.9 (23) (48–74)	47.2 (52) (35–60)
R+ (19)	39.4 (4) (15–65)	— (0) (—; —)	65.5 (3) (33–98)	23.5 (12) (01–46)	20.1 (15) (01–40)
	+$P = 0.466$		+$P =$ **0.027**	+$P =$ **0.001**	+$P =$ **0.003**
N category					
N0 (115)	83.5 (18) (76–91)	*91.5 (6) (84–99)	*85.7 (9) (77–95)	57.1 (43) (47–67)	40.3 (85) (31–50)
N+ (303)	80.3 (45) (74–87)	87.2 (16) (80–94)	81.8 (18) (73–91)	26.9 (186) (21–33)	14.5 (262) (10–19)
	+$P = 0.715$	+$P = 0.269$	+$P = 0.352$	$P <$ **0.001**	$P <$ **0.001**
ND (surgical therapy)					
No (19)	*65.9 (5) (37–93)	*78.6 (2) (51–100)	*— (0) (—; —)	22.6 (13) (01–44)	15.8 (17) (00–32)
Yes (64)	79.4 (11) (68–91)	*86.0 (6) (75–97)	*84.5 (6) (73–96)	61.1 (22) (48–74)	49.3 (50) (37–62)
	+$P = 0.134$	+$P = 0.382$	+$P = 0.327$	+$P =$ **0.001**	+$P =$ **0.022**
Differentiation					
Well/moderate (264)	82.4 (39) (77–88)	88.8 (14) (83–95)	82.2 (16) (73–91)	34.1 (147) (27–41)	20.6 (221) (16–26)
Poor (125)	80.7 (19) (71–90)	*91.5 (6) (85–98)	83.2 (10) (73–93)	38.8 (59) (29–49)	22.5 (102) (15–30)
	$P = 0.966$	$P = 0.697$	$P = 0.649$	$P = 0.398$	$P = 0.368$
Perinodal invasion					
No (153)	78.3 (30) (71–86)	88.4 (11) (82–95)	84.7 (12) (76–93)	51.7 (62) (42–61)	34.6 (117) (27–43)
Yes (21)	*65.9 (3) (62–70)	*79.5 (2) (54–100)	*86.3 (2) (68–100)	19.9 (11) (01–43)	13.2; (16) (0–29)
	+$P = 0.814$	+$P = 0.275$	+$P = 0.262$	+$P =$ **0.011**	+$P =$ **0.052**
Lymphatic invasion					
No (164)	79.1 (31) (72–86)	88.2 (12) (82–95)	84.8 (13) (77–93)	50.8 (68) (42–60)	33.2 (128) (26–41)
Yes (17)	*64.3 (3) (25–100)	*87.5; (1) (65–100)	*91.7; (1) (76–100)	*30.0 (7) (00–63)	17.9 (11) (04–39)
	+$P = 0.836$	+$P = 0.682$	+$P = 0.733$	+$P = 0.126$	+$P = 0.292$
Treatment					
Primary surgery (83)	74.2 (16) (63–86)	*84.7 (8) (75–95)	*86.5 (6) (76–97)	52.7 (35) (41–65)	41.2 (67) (30–52)
Primary nonsurgical treatment (316)	83.8 (43) (79–89)	91.8 (11) (86–97)	80.4 (20) (71–89)	31.4 (184) (23–39)	17.3; (263) (13–22)
	+$P = 0.420$	+$P = 0.102$	+$P = 0.529$	+$P =$ **0.001**	+$P =$ **0.001**
HPV					
No (78)	76.6 (10) (59–94)	*97.4 (1) (93–100)	*75.3 (6) (53–98)	40.2 (33) (24–56)	23.4 (52) (11–35)
Yes (15)	*93.3 (1) (81–100)	*— (0) (—; —)	*82.1 (2) (59–100)	*64.6 (5) (40–90)	*40.2 (9) (13–68)
	+$P = 0.440$	+$P = 0.631$	+$P = 0.711$	+$P = 0.126$	$P = 0.388$

*Not enough events or patients for statistical interpretation.

+Too widely different group sizes or crossings for interpretation without a comment.

bias in the two treatment modalities. In fact the major weakness of the study is the selection bias in a historical cohort covering a 30-year era of various types and protocols in the treatment decision making. Therefore, this study should not be considered as a direct comparison between surgery and RCT. The study does, however, present evidence that primary surgery might have a clear role in advanced HPV-negative OPSCC. Other studies have also shown a survival benefit in surgical patients [19, 28]. In the case of primary surgery, our study confirmed the prognostic impact of clear resection margins (R0), emphasizing their importance in survival [29]. The high percentage of incomplete tumor resection in our study (22.9%) can partially be explained by inadequate pathologic assessment of frozen sections and surgical approach and emphasizes the need for the careful preoperative selection of patients and the painstaking surgical technique required to optimize oncologic results. Furthermore the high percentage of nonsurgically treated patients in this study (316/426) shows that primary radiochemotherapy remains the treatment of choice in most cases with advanced OPSCC.

Another promising therapeutic alternative currently being investigated for advanced OPSCC is the use of induction chemotherapy followed by concomitant chemoradiation or surgery [30–32]. In a recent phase III trial, the additional use of panitumumab in patients receiving primary radiotherapy and cisplatin significantly improved survival in HPV-negative patients [33].

Prognostic factors are important in selecting the appropriate treatment for the patient. Furthermore, prognostic factors can help proper stratification in future randomized trials. Our study investigated eleven possible prognostic factors for the oncologic outcome in T4a oropharyngeal carcinoma. The strongest prognostic factor for T4a carcinomas in univariate and multivariate analysis proved to be the presence of lymph node metastases. Perhaps future trials could investigate the oncologic safety of deescalation of treatment in HPV-positive patients with cN0 neck. The incidence of occult metastases was 33%, which is comparable to previous studies and confirms the need for elective treatment of the neck [34–36]. Perinodal invasion was also shown to be a significant prognostic factor but the widely different group sizes reduced the power of the statistical analysis. Interestingly, recent studies could not verify the prognostic importance of extracapsular spread in HPV-positive OPSCC, and the authors concerned suggest deescalating adjuvant therapy in this patient group, even if there is evidence of ECS [27].

In the present study, 155 of the initial 581 patients were excluded because they did not meet the inclusion criteria. Fifty-seven (19.8%) of them were excluded because they were not able to receive proper treatment. This percentage is comparable with the literature and shows that many patients with advanced OPSCC are not able to receive the intended curative treatment, a problem that is often ignored in many studies [37].

5. Conclusion

HPV-positive cases seem to account for a low proportion of T4a OPSCC in our patient cohort (16%) and further studies should investigate if this percentage increases with time. HPV-negative patients, on the other hand, had worse survival but performed better after primary surgical treatment. The strongest independent prognostic factor for T4a carcinomas in multivariate analysis proved to be the presence of cervical lymph node metastases (pN+).

6. Synopsis

The strongest independent prognostic factor for T4a carcinomas proved to be the presence of lymph node metastases. The survival of p16-negative patients was worse than p16-positive patients, although they seem to respond better to primary surgery.

Acronyms

OPSCC:	Oropharyngeal squamous cell carcinoma
RT:	Radiotherapy
RCT:	Radiochemotherapy
SCC:	Squamous cell carcinoma
AJCC:	American Joint Committee on Cancer
UICC:	Union Internationale Centre Contre Cancer
DSS:	Disease-specific survival
LC:	Local control
RC:	Regional control
OS:	Overall survival
HPV:	Human papillomavirus.

Conflict of Interests

The authors declare that they have no conflict of interests.

Acknowledgments

The authors would like to thank Philipp Grundtner for the statistical analysis of the data. The authors acknowledge support by Deutsche Forschungsgemeinschaft and Friedrich-Alexander-University Erlangen-Nuremberg (FAU) within the funding programme Open Access Publishing.

References

[1] J. T. Parsons, W. M. Mendenhall, S. P. Stringer et al., "Squamous cell carcinoma of the oropharynx: Surgery, radiation therapy, or both," *Cancer*, vol. 94, no. 11, pp. 2967–2980, 2002.

[2] A. S. Allal, K. Nicoucar, N. Mach, and P. Dulguerov, "Quality of life in patients with oropharynx carcinomas: assessment after accelerated radiotherapy with or without chemotherapy versus radical surgery and postoperative radiotherapy," *Head and Neck*, vol. 25, no. 10, pp. 833–840, 2003.

[3] S. E. Mowry, A. Ho, M. M. Lotempio, A. Sadeghi, K. E. Blackwell, and M. B. Wang, "Quality of life in advanced oropharyngeal carcinoma after chemoradiation versus surgery and radiation," *Laryngoscope*, vol. 116, no. 9, pp. 1589–1593, 2006.

[4] A. S. Ihloff, C. Petersen, M. Hoffmann, R. Knecht, and S. Tribius, "Human papilloma virus in locally advanced stage III/IV squamous cell cancer of the oropharynx and impact on

choice of therapy," *Oral Oncology*, vol. 46, no. 10, pp. 705–711, 2010.

[5] K. K. Ang, J. Harris, R. Wheeler et al., "Human papillomavirus and survival of patients with oropharyngeal cancer," *The New England Journal of Medicine*, vol. 363, no. 1, pp. 24–35, 2010.

[6] A. W. Pederson, D. J. Haraf, M.-E. Witt et al., "Chemoradiotherapy for locoregionally advanced squamous cell carcinoma of the base of tongue," *Head and Neck*, vol. 32, no. 11, pp. 1519–1527, 2010.

[7] A. Eisbruch, J. Harris, A. S. Garden et al., "Multi-institutional trial of accelerated hypofractionated intensity-modulated radiation therapy for early-stage oropharyngeal cancer (RTOG 00–22)," *International Journal of Radiation Oncology Biology Physics*, vol. 76, no. 5, pp. 1333–1338, 2010.

[8] G. S. Weinstein, B. W. O'Malley Jr., J. S. Magnuson et al., "Transoral robotic surgery: a multicenter study to assess feasibility, safety, and surgical margins," *Laryngoscope*, vol. 122, no. 8, pp. 1701–1707, 2012.

[9] A. Bozec, G. Poissonnet, E. Chamorey et al., "Quality of life after oral and oropharyngeal reconstruction with a radial forearm free flap: prospective study," *Journal of Otolaryngology*, vol. 38, no. 3, pp. 401–408, 2009.

[10] G. Psychogios, K. Mantsopoulos, J. Kuenzel et al., "Primary surgical treatment of T2 oropharyngeal carcinoma," *Journal of Surgical Oncology*, vol. 105, no. 7, pp. 719–723, 2012.

[11] J. Kunzel, H. Iro, G. Psychogios, J. Zenk, and M. Koch, "Closure of defects after resection of tumors of the oral cavity and the pharynx: medium- to long-term oncologic and functional results with the myocutaneous platysma flap," *European Archives of Oto-Rhino-Laryngology*, vol. 270, no. 9, pp. 2537–2545, 2013.

[12] D. F. Ryzek, J. Künzel, P. Grundtner, J. Zenk, H. Iro, and G. Psychogios, "Early stage oropharyngeal carcinomas: comparing quality of life for different treatment modalities," *BioMed Research International*, vol. 2014, Article ID 421964, 7 pages, 2014.

[13] B. H. Haughey and P. Sinha, "Prognostic factors and survival unique to surgically treated p16+ oropharyngeal cancer," *Laryngoscope*, vol. 122, supplement 2, pp. S13–S33, 2012.

[14] American Joint Committee on Cancer (AJCC), *Cancer Staging Manual*, Springer, New York, NY, USA, 2010.

[15] O. C. Ukpo, J. J. Flanagan, X. J. Ma, Y. Luo, W. L. Thorstad, and J. S. Lewis, "High-risk human papillomavirus E6/E7 mRNA detection by a novel in situ hybridization assay strongly correlates with p16 expression and patient outcomes in oropharyngeal squamous cell carcinoma," *The American Journal of Surgical Pathology*, vol. 35, no. 9, pp. 1343–1350, 2011.

[16] C. Wittekindt, S. Wagner, C. S. Mayer, and J. P. Klußmann, "Basics of tumor development and importance of human papilloma virus (HPV) for head and neck cancer," *Laryngo-Rhino-Otologie*, vol. 91, no. 1, pp. S1–S26, 2012.

[17] G. Psychogios, C. Alexiou, A. Agaimy et al., "Epidemiology and survival of HPV related tonsillar carcinoma," *Cancer Medicine*, 2014.

[18] M. Loewenthal, E. Vitez, S. Laban et al., "New aspects of current therapeutic strategies in oropharyngeal carcinoma: highlights of the 2012 ASCO meeting," *HNO*, vol. 60, no. 11, pp. 951–956, 2012.

[19] A. D. Karatzanis, G. Psychogios, K. Mantsopoulos et al., "Management of advanced carcinoma of the base of tongue," *Journal of Surgical Oncology*, vol. 106, no. 6, pp. 713–718, 2012.

[20] A. S. Garden, M. S. Kies, W. H. Morrison et al., "Outcomes and patterns of care of patients with locally advanced oropharyngeal carcinoma treated in the early 21st century," *Radiation Oncology*, vol. 8, article 21, 2013.

[21] H. Mehanna, O. Olaleye, and L. Licitra, "Oropharyngeal cancer—is it time to change management according to human papilloma virus status?" *Current Opinion in Otolaryngology and Head and Neck Surgery*, vol. 20, no. 2, pp. 120–124, 2012.

[22] L. Marklund, A. Nasman, T. Ramqvist, T. Dalianis, E. Munck-Wikland, and L. Hammarstedt, "Prevalence of human papillomavirus and survival in oropharyngeal cancer other than tonsil or base of tongue cancer," *Cancer Medicine*, vol. 1, no. 1, pp. 82–88, 2012.

[23] H. Mehanna, T. Beech, T. Nicholson et al., "Prevalence of human papillomavirus in oropharyngeal and nonoropharyngeal head and neck cancer-systematic review and meta-analysis of trends by time and region," *Head and Neck*, vol. 35, no. 5, pp. 747–755, 2013.

[24] A. Panwar, R. Batra, W. M. Lydiatt, and A. K. Ganti, "Human papilloma virus positive oropharyngeal squamous cell carcinoma: a growing epidemic," *Cancer Treatment Reviews*, vol. 40, no. 2, pp. 215–219, 2014.

[25] R. Semrau, H. Duerbaum, S. Temming et al., "Prognostic impact of human papillomavirus status, survivin, and epidermal growth factor receptor expression on survival in patients treated with radiochemotherapy for very advanced nonresectable oropharyngeal cancer," *Head and Neck*, vol. 35, no. 9, pp. 1339–1344, 2013.

[26] G. Psychogios, K. Mantsopoulos, A. Agaimy et al., "Prognostic factors in limited (T1-2, N0-1) oropharyngeal carcinoma treated with surgery +/- adjuvant therapy," *Head and Neck*, vol. 35, no. 12, pp. 1752–1758, 2013.

[27] P. Sinha, J. S. Lewis, J. F. Piccirillo, D. Kallogjeri, and B. H. Haughey, "Extracapsular spread and adjuvant therapy in human papillomavirus-related, p16-positive oropharyngeal carcinoma," *Cancer*, vol. 118, no. 14, pp. 3519–3530, 2012.

[28] D. Rades, N. D. Seibold, M. P. Gebhard, F. Noack, S. E. Schild, and C. Thorns, "Prognostic factors (including HPV status) for irradiation of locally advanced squamous cell carcinoma of the head and neck (SCCHN)," *Strahlentherapie und Onkologie*, vol. 187, no. 10, pp. 626–632, 2011.

[29] K. Mantsopoulos, G. Psychogios, F. Waldfahrer, J. Zenk, and H. Iro, "Surgical treatment of locally limited tonsillar cancer," *Surgical Oncology*, vol. 21, no. 1, pp. e13–e16, 2012.

[30] L. Masterson and F. Tanweer, "The role of sequential chemoradiation for local advanced oropharyngeal carcinoma," *International Journal of Clinical Oncology*, vol. 18, no. 5, pp. 808–816, 2013.

[31] K. Oertel, K. Spiegel, H. Schmalenberg et al., "Phase I trial of split-dose induction docetaxel, cisplatin, and 5-fluorouracil (TPF) chemotherapy followed by curative surgery combined with postoperative radiotherapy in patients with locally advanced oral and oropharyngeal squamous cell cancer (TISOC-1)," *BMC Cancer*, vol. 12, article 483, 2012.

[32] F. P. Worden, B. Kumar, J. S. Lee et al., "Chemoselection as a strategy for organ preservation in advanced oropharynx cancer: response and survival positively associated with HPV16 copy number," *Journal of Clinical Oncology*, vol. 26, no. 19, pp. 3138–3146, 2008.

[33] L. Licitra, C. Bergamini, A. Mirabile, and R. Granata, "Targeted therapy in head and neck cancer," *Current Opinion in Otolaryngology and Head and Neck Surgery*, vol. 19, no. 2, pp. 132–137, 2011.

[34] G. Psychogios, K. Mantsopoulos, C. Bohr, M. Koch, J. Zenk, and H. Iro, "Incidence of occult cervical metastasis in head and neck carcinomas: development over time," *Journal of Surgical Oncology*, vol. 107, no. 4, pp. 384–387, 2013.

[35] A. J. Fasunla, B. H. Greene, N. Timmesfeld, S. Wiegand, J. A. Werner, and A. M. Sesterhenn, "A meta-analysis of the randomized controlled trials on elective neck dissection versus therapeutic neck dissection in oral cavity cancers with clinically node-negative neck," *Oral Oncology*, vol. 47, no. 5, pp. 320–324, 2011.

[36] R. J. Kau, C. Alexiou, H. Stimmer, and W. Arnold, "Diagnostic procedures for detection of lymph node metastases in cancer of the larynx," *ORL*, vol. 62, no. 4, pp. 199–203, 2000.

[37] S. Lybak, P. G. Liavaag, O. R. Monge, and J. Olofsson, "Surgery and postoperative radiotherapy a valid treatment for advanced oropharyngeal carcinoma," *European Archives of Oto-Rhino-Laryngology*, vol. 268, no. 3, pp. 449–456, 2011.

Hindawi Publishing Corporation
BioMed Research International
Volume 2014, Article ID 516231, 5 pages
http://dx.doi.org/10.1155/2014/516231

Clinical Study

Zenker's Diverticulum: Carbon Dioxide Laser Endoscopic Surgery

Jan Plzák, Michal Zábrodský, and Petr Lukeš

Department of Otorhinolaryngology and Head and Neck Surgery, 1st Faculty of Medicine, Charles University, University Hospital Motol, V Úvalu 84, 150 06 Prague 5, Czech Republic

Correspondence should be addressed to Jan Plzák; jan.plzak@lf1.cuni.cz

Received 21 January 2014; Accepted 28 January 2014; Published 6 March 2014

Academic Editor: Jan Betka

Nowadays endoscopic diverticulotomy is the surgical approach of the first choice in treatment of Zenker's diverticulum. We report our experience with this procedure and try to sum up recent recommendations for management of surgery and postoperative care. Data of 34 patients with Zenker's diverticulum, treated by endoscopic carbon dioxide laser diverticulotomy at the Department of Otorhinolaryngology and Head and Neck Surgery, 1st Faculty of Medicine, Charles University, University Hospital Motol, Prague, Czech Republic, were prospectively stored and followed in relatively short period from May 2009 to December 2013. The average length of diverticulum was 32 mm. The average duration of surgery was 32 min. The patients were fed via feeding tube for 6.1 days and antibiotics were administered for 7 days. Mean hospitalization time was 7.4 days. We observed one transient recurrent laryngeal nerve paralysis and no other serious complications. Recurrence rate was 3%. We recommend complete transection of the diverticular septum in one procedure, systemic antibiotic treatment and exclusion of transoral intake for minimally 5 days, and contrast oesophagogram before resumption of oral intake to exclude fistula. Open diverticulectomy should be reserved for cases with inadequate endoscopic exposure and for revision surgery for multiple recurrences from endoscopic diverticulotomies.

1. Introduction

Hypopharyngeal diverticulum (Zenker's diverticulum) is a herniation of the posterior wall of the hypopharynx into a triangular shaped area between the oblique muscle fibers of the inferior pharyngeal constrictor muscle and the horizontal muscle fibers of the cricopharyngeal muscle. Although the exact etiology remains unclear, mostly accepted explanation of hypopharyngeal diverticulum development is an increased bolus pressure as a result of a malfunction of the upper oesophageal sphincter, including spasms, lack of relaxation during swallowing, or premature contraction.

Symptoms, related to the size of the diverticulum, range from complete absence of any complaints to life-threatening situation such as aspiration pneumonia and severe cachexia. Dysphagia is the main presenting symptom, sometimes associated with regurgitation of undigested food, choking, cough, and, in advanced cases, oesophageal obstruction. The diagnosis is confirmed by radiological examination.

The treatment of choice for Zenker's diverticulum is surgery. External diverticulectomy with cricopharyngeal myotomy, firstly performed by Kaplan in 1951 [1], is the key point of modern surgical management. To reduce rate of complications (e.g., mediastinitis, recurrent laryngeal nerve paralysis, and pharyngocutaneous fistulas) and to shorten hospitalization time, endoscopic approaches have been developed. The great expansion of endoscopic treatment started after introduction of carbon dioxide laser in 1981 by van Overbeek [2]. The great leap forward has been supported by endoscopic stapler-assisted diverticulotomy, introduced more recently in 1993 separately by Martin-Hirsch and Newbegin and Collard et al. [3, 4]. Nowadays endoscopic diverticulotomy is the surgical approach of the first choice in treatment of Zenker's diverticulum [5].

Up to now, a number of studies regarding both external and endoscopic approaches have been published, showing some differences in management and results such as complication rate, duration of hospitalization, exact treatment protocol, and followup. In this study, we present our experience with carbon dioxide laser endoscopic diverticulotomy in 34 patients in less than five-year period.

2. Material and Methods

Data of 34 patients with Zenker's diverticulum treated by endoscopic carbon dioxide laser diverticulotomy at the Department of Otorhinolaryngology and Head and Neck Surgery, 1st Faculty of Medicine, Charles University, University Hospital Motol, Prague, Czech Republic, were prospectively stored and followed from May 2009 to December 2013.The study was conducted with patient consent and approval of the Local Ethical Committee according to the principles of the Helsinki Declaration. Data were analyzed for age, sex, size of the diverticulum, duration of surgery, length of feeding tube nutrition, length of hospitalization stay, and complications.

Diagnosis was based on the patient's history, complete clinic otorhinolaryngological examination, and contrast oesophagogram. The size of diverticulum was defined by the maximal depth of the diverticular sac on the preoperative contrast oesophagogram. Duration of surgery was recorded as the time from when the surgeon initiates the procedure till the completion of the procedure. All patients with diagnosed Zenker's diverticulum were in this period indicated to endoscopic surgery except three ones, one patient with huge diverticulum of 8 cm length extended deep in the upper mediastinum; the second one because of patient's preference; the third one as a conversion from endoscopic approach due to unfavourable anatomy.

The surgery was performed under general anesthesia. Initially classic rigid oesophagoscopy was performed to prove typical location of diverticular inlet at the posterior wall of the hypopharynx, to clean the diverticular sac from any food debris, and to exclude cancer. Subsequently a Weerda distending diverticuloscope (Karl Storz, Tuttlingen, Germany) was used for diverticulum exposure. The anterior lip of the diverticuloscope was placed into the oesophagus while the posterior lip of the diverticuloscope was passed into the diverticulum. The diverticuloscope was advanced until the bottom of the diverticulum was exposed. The tissue bridge between the oesophagus anteriorly and the diverticulum posteriorly was set between the two lips of the diverticuloscope. An operating microscope Carl Zeiss OPMI Sensera (Carl Zeiss AG, Oberkochen, Germany) with attached carbon dioxide laser micromanipulator was set on working distance 400 mm with the laser beam focused on the tissue bridge. We used a carbon dioxide laser Lumenis AcuPulse (Lumenis, Santa Clara, California) with superpulse delivery in repeated mode, coupled to an AcuSpot micromanipulator, until 2009. Since March 2010, a robotic digital AcuBlade scanning micromanipulator system was used. The oesophageal mucosa was protected from accidental laser injury by a moist swab. Using the laser at 5–10 W, the septum was transected at the midline down to the bottom of diverticular sac. Occasionally electrocautery was used to control bleeding. Feeding tube was introduced in all patients.

Postoperative oesophagogram was performed at 5-6th day followed by a removal of the feeding tube and the discharge from the hospital at the same day or one day later. Antibiotic treatment was routinely administered for one week following the surgery (cefuroxime axetil). Control contrast oesophagogram and subjective evaluation of swallowing were performed at least three months after the treatment.

3. Results

The group of 34 patients with Zenker's diverticulum treated by endoscopic carbon dioxide laser diverticulotomy by three surgeons, who are the authors of this article, included 25 males and 9 females, mean age 63 years (range 36–91). One male patient required a revision endoscopic surgery 18 months after the first diverticulotomy of 28 mm sac due to a deterioration of swallowing accompanied by progressing recurrent diverticulum showed at X-ray (Figure 1). Therefore, data of 35 procedures are presented. In one female patient diverticular septum could not be exposed well due to unfavourable anatomy obesity, short neck, enlargement of the base of the tongue, and high upper teeth. The successful diverticulectomy was performed using transcervical approach three days after the endoscopic attempt. Two patients had been previously treated by external transcervical approach. One patient initially preferred external approach at our department, but the surgery was not successful with complicated course with fistula. Revision endoscopic surgery was uneventful. The second patient underwent external approach at another institution. Fistula and transient recurrent nerve paralysis was complication of this surgery with minimal release of swallowing difficulties and unchanged X-ray picture. Also in this case revision endoscopic surgery was uneventful and successful. One patient also had a resection of recurrent glottic papillomas performed by carbon dioxide laser, in addition to the diverticulotomy.

The average length of diverticulum was 32 mm (range 22–52 mm). According to the Brombat classification [6], 3 cases were classified stage III, and 31 cases stage IV. The average duration of surgery was 32 min (range 17–45 min). Mean hospitalization time was 7.4 days (range 7–14 days). All cases had hospitalization time between 7 and 9 days, except one that was admitted one week before the surgery for preoperative workup, because of complicated comorbid conditions. All but one patient were fed by a nasogastric feeding tube on average for 6.1 days (range 6-7 days). The one patient removed the feeding tube accidentally by himself during the first postoperative night and hence he was subsequently fed parenteraly for 7 days.

No case of fistula, mediastinitis, neck emphysema, mucosal perforation or tearing, tooth fracture, postoperative bleeding, and aspiration pneumonia was observed. One patient suffered from transient left recurrent laryngeal nerve paralysis that spontaneously resolved within one month.

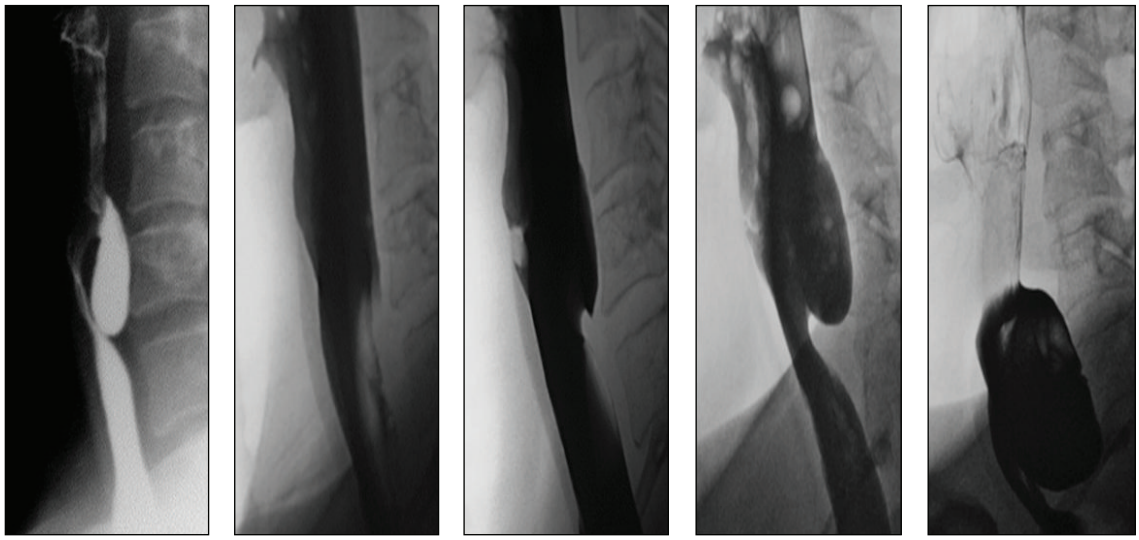

(a) (b) (c) (d) (e)

Figure 1: Failure case. Contrast oesophagograms before the first laser endoscopic diverticulotomy (a), 5th postoperative day (b), 3 months postoperatively (c), 6 months postoperatively (d), and 15 months postoperatively (e) show slow recurrence to the preoperative size of the Zenker's diverticulum.

Once we observed oedema of the laryngeal inlet and left pyriform sinus that required intravenous application of corticosteroids for one day, five patients (14%) presented in 24 hours after the surgery a temperature peak > 38°C that resolved with antipyretic treatment. Elevated CRP (C-reactive protein) was observed in all cases. The average maximum CRP was 52 (range 17–224).

All contrast oesophagograms at 5-6th postoperative day showed no leakage and no presence of extraoesophageal air in the neck and mediastinum. In 25 cases (71%) it was possible to identify previous location of the pouch inlet as an evagination at the posterior pharyngooesophageal wall. Contrast oesophagogram three months after the surgery revealed radiographic recurrence of Zenker's diverticulum in 4 patients (11%). Two of them evaluated their swallowing as satisfying and improved, with size of recurrent pouch of 4 and 5 mm, respectively. They were recommended for control radiogram in case of deterioration of swallowing but no one required it. One patient described complete regression of swallowing problems immediately after the surgery with some deterioration later on. Control X-ray showed progression of recurrent diverticulum to preoperative diameter accompanied by a deterioration of dysphagia that was graded by the patient as slighter than preoperative one. The patient underwent revision endoscopic diverticulotomy. One patient suffered from persistent postoperative dysphagia but without previously presented regurgitation of undigested food, gurgling in the throat, and other typical symptoms of a Zenker's diverticulum. Moreover, the length of recurrent diverticulum was only 6 mm with horizontal course of a pouch and no retention of contrast medium in it. Revision surgery was not recommended since problems of the patient could not be solved by diverticular surgery. All other patients evaluated their swallowing function as normal or much lighter symptoms.

We assessed as a failure one patient with recurrent both dysphagia and X-ray finding that required revision surgery. Total success rate was 97% (33/34 patients) including two revision procedures after previous open surgery. Only the first (i.e., unsuccessful) endoscopic procedure of patient with failure is counted in the success rate since there is a short time from revision surgery to evaluate it correctly.

4. Discussion

The treatment of choice for Zenker's diverticulum is surgery. Both the open transcervical and endoscopic approach are associated with complications and potential risks. The principle of the external approach is an excision of the pouch and a cricopharyngeal myotomy. The endoscopic approach, on the other hand, is based on a full-length mucosal incision and complete myotomy of the tissue bridge between the diverticular pouch and the oesophagus. Usually laser or stapling device is used thus providing wide opening of the diverticulum into the oesophagus, preventing any further retention of food. Nowadays endoscopic surgery is the approach of the first choice [5]. In favour of endoscopy comparing to open surgery, speaks these arguments: no external scar, lower complication rate (fistula, recurrent laryngeal nerve palsy, and oesophageal stenosis), shorter surgical time, shorter hospitalization time, and nonincreasing risk of revision surgery. Both approaches are highly effective (more than 90%), with slightly better results of open surgery [5, 7, 8].

Failure to expose sufficiently the oesophagus, diverticular septum and diverticulum may preclude safe transection of the septum between the oesophagus and diverticulum. In

such case, conversion to transcervical procedure is indicated. Short necks, decreased hyomental distance, and/or a high BMI are anatomic factors proven to be associated with failed endoscopic exposure of Zenker's diverticulum. An open approach should be considered in this patient population [9]. The introduction of diverticuloscope in correct position enabling sufficient and safe exposure of surgical field is often, in fact, the most difficult and time consuming part of the procedure.

In our patient series, we used radiological swallowing examination in all patients 5-6th postoperative day and three months postoperatively. The first examination is aimed to exclude a fistula before resumption of oral intake. In compliance with Helmstaedter et al. we prefer to feed patients via feeding tube for around 6 days, as scar and granulation tissue need five days to seal the cut edges [10]. The second radiological examination three months after the surgery depicts final functional results. But it was shown by Mantsopoulos et al. that postoperative oesophagogram cannot predict subjective symptoms [11]. They found only 12.5% patients with pouch remnants on postoperative oesophagogram developing symptomatic recurrent Zenker's diverticulum. Therefore, for evaluation of success rate of the surgery the most important factor is subjective assessment of swallowing function done by the patient. Both primary and revision indications for surgery are guided by the patient's symptoms [12]. Based on these findings supported by our own present experience, we intend to reserve delayed postoperative oesophagogram for symptomatic cases only in future to avoid unnecessary examination.

Postoperative fever and elevation of CRP were frequent in our study (14 and 100%, resp.). Even in one case CRP peak reached 224 at 2nd postoperative day. But there were no other alerting symptoms or findings (no fewer, no chill, no thoracic pain, etc.) so we continued in standard postoperative care and CRP decreased below 20 at the date of discharge. It is considered to be due to mediastinal irritation rather than mediastinal infection. In presence of other subjective symptoms of mediastinitis like increasing chest pain, chills, general discomfort, and shortness of breath we recommend to perform thoracic CT to exclude mediastinitis.

The reason of temporary recurrent nerve palsy after endoscopic diverticulotomy is not clearly explained. We suggest that it is because of compression by the diverticuloscope and/or endotracheal tube.

Our failure case had no parameter appearing to discriminate this case from those with a good outcome. It is interesting to follow four postoperative oesophagograms. The first one showed ideal situation on the 5th day after endoscopic diverticulotomy with no residual sac. The examinations 3 and 6 months postoperatively showed recurrent pouch of 3 and 8 mm, respectively, accompanied by recurrence of dysphagia. The forth oesophagogram 15 months postoperatively reveals almost the same picture as before primary surgery with typical Zenker's diverticulum of size equal to preoperative one accompanied by further deterioration of swallowing function (Figure 1). But the patient assessed dysphagia before primary surgery as more serious than before revision surgery. This case is in accordance with a statistical analysis of a huge group of 155 cases made by Mantsopoulos et al. showing that early postoperative oesophagogram does not have any prognostic value [11]. They concluded that the presence of a residual diverticulum on immediate postoperative oesophagogram does not justify early surgical revision, even when dysphagia persists. In many cases, there may be a slow process of gradual fibrosis of the residual dysfunctional cricopharyngeal muscle or atrophy of the pouch remnant over the course of time. Our case may support their result from the other point of view: even normal postoperative oesophagogram probably cannot predict a persistent good outcome.

So far published recurrence rate of endoscopic laser diverticulotomy is around 5–25% [5, 8, 12–14]. Our recurrence rate is 3%. This low number may be explained by smaller group of patients and short followup. On the other hand we found only one report with higher rate of endoscopic laser diverticulotomies per year than ours. Adam et al. performed 148 surgeries in 10 years (14.8/year), Koch et al. performed 101 surgeries in 18 years (5.6/year), Rizzetto et al. performed 51 surgeries in 14 years (3.6/year), Verhaegen et al. performed 72 surgeries in 20 years (3.6/year), Helmstaedter et al. performed 40 surgeries in 20 years (2/year), and Peretti et al. performed 28 surgeries in 15 years (1.9/year) [8, 10, 12–15]. We performed 35 surgeries in 4.67 years (7.5/year). This relatively high frequency of endoscopic laser diverticulotomy per year is in favour of us since the positive correlation of high frequency and high efficacy/low complication rate of any surgery due to increased familiarity is well known. Our other advantage is that we report a group of patients from very recent period, that is, after 2009. Thus we may utilize up-to-date knowledge. In the past some authors advocated transecting the diverticular septum for only 2–4 cm irrespective of the size of the diverticulum to avoid risk of opening of the mediastinum and subsequent mediastinitis. [16, 17]. But it has been already demonstrated that complete transection of the diverticular septum does not increase the risk of complication [5, 10]. Therefore, we performed complete transection in all cases irrespective of the size of diverticulum.

In accordance with the recent literature we recommend endoscopic procedure also for revision surgery. All our three revision cases (two cases after primary external surgery with complications, one after our primary endoscopic surgery that is discussed in more detail; see above) passed uneventfully, with standard course of surgery and no complications. The great advantage compared to external approach is that endoscopic revision treatment is technically feasible and relatively easy, no more difficult than the primary endoscopic procedure, with no increase of risk. Moreover, patient satisfaction was higher in those who underwent endoscopic revision surgery compared to those who underwent open revision surgery [5, 12, 18].

5. Conclusions

Endoscopic carbon dioxide laser diverticulotomy in consecutive series of 34 patients was safe, fast, and successful treatment of patients with Zenker's diverticulum. Recurrence rate of 3% and morbidity rate of 3% (1x transient recurrent

laryngeal nerve palsy, no fistula, and no mediastinitis) support the protocol we used. We recommend maximal effort to reach complete transection of the diverticular septum in one procedure, systemic antibiotic treatment, and exclusion of transoral intake for minimally 5 days. We recommend contrast oesophagogram before resumption of oral intake to exclude fistula. Unfortunately there is currently no radiologic prognostic marker of recurrence of the disease. Open transcervical diverticulectomy should be reserved for cases with inadequate endoscopic exposure of the operation field due to unfavourable anatomy and for revision surgery for multiple recurrences from endoscopic diverticulotomies.

Conflict of Interests

The authors declare that there is no conflict of interests regarding the publication of this paper.

Acknowledgments

This research is supported by Charles University in Prague Projects nos. PRVOUK 27 and UNCE 204013 and Grant no. NT 13488.

References

[1] S. Kaplan, "Paralysis of deglutition, a post-poliomyelitis complication treated by section of the cricopharyngeus muscle," *Annals of Surgery*, vol. 133, no. 4, pp. 572–573, 1951.

[2] J. J. M. van Overbeek, "Meditation on the pathogenesis of hypopharyngeal (Zenker's) diverticulum and a report of endoscopic treatment in 545 patients," *Annals of Otology, Rhinology and Laryngology*, vol. 103, no. 3, pp. 178–185, 1994.

[3] D. P. Martin-Hirsch and C. J. R. Newbegin, "Autosuture GIA gun: a new application in the treatment of hypopharyngeal diverticula," *Journal of Laryngology and Otology*, vol. 107, no. 8, pp. 723–725, 1993.

[4] J. M. Collard, J. B. Otte, and P. J. Kestens, "Endoscopic stapling technique of esophagodiverticulostomy for Zenker's diverticulum," *Annals of Thoracic Surgery*, vol. 56, no. 3, pp. 573–576, 1993.

[5] E. Prisman and E. M. Genden, "Zenker diverticulum," *Otolaryngologic Clinics of North America*, vol. 46, no. 6, pp. 1101–1111, 2013.

[6] M. Brombart, "Zenker's pharyngo-esophageal diverticulum, pathogenic considerations on radiological studies on 26 cases (23 cases in initial stage)," *Journal Belge de Radiologie*, vol. 36, pp. 166–197, 1953.

[7] C. W. Chang, B. B. Burkey, J. L. Netterville, M. S. Courey, C. G. Garrett, and S. W. Bayles, "Carbon dioxide laser endoscopic diverticulotomy versus open diverticulectomy for Zenker's diverticulum," *Laryngoscope*, vol. 114, no. 3, pp. 519–527, 2004.

[8] C. Rizzetto, G. Zaninotto, M. Costantini et al., "Zenker's diverticula: feasibility of a tailored approach based on diverticulum size," *Journal of Gastrointestinal Surgery*, vol. 12, no. 12, pp. 2057–2065, 2008.

[9] J. D. Bloom, B. S. Bleier, N. Mirza, A. A. Chalian, and E. R. Thaler, "Factors predicting endoscopic exposure of Zenker's diverticulum," *Annals of Otology, Rhinology and Laryngology*, vol. 119, no. 11, pp. 736–741, 2010.

[10] V. Helmstaedter, A. Engel, K. Huttenbrink, and O. Guntinas-Lichius, "Carbon dioxide laser endoscopic diverticulotomy for Zenker's diverticulum: results and complications in a consecutive series of 40 patients," *ORL*, vol. 71, no. 1, pp. 40–44, 2008.

[11] K. Mantsopoulos, G. Psychogios, A. Karatzanis et al., "Clinical relevance and prognostic value of radiographic findings in Zenker's diverticulum," *European Archives of Oto-Rhino-Laryngology*, vol. 271, no. 3, pp. 583–588, 2014.

[12] V. J. O. Verhaegen, T. Feuth, F. J. A. van den Hoogen, H. A. M. Marres, and R. P. Takes, "Endoscopic carbon dioxide laser diverticulostomy versus endoscopic staple-assisted diverticulostomy to treat Zenker's diverticulum," *Head and Neck*, vol. 33, no. 2, pp. 154–159, 2011.

[13] M. Koch, K. Mantsopoulos, S. Velegrakis, H. Iro, and J. Zenk, "Endoscopic laser-assisted diverticulotomy versus open surgical approach in the treatment of Zenker's diverticulum," *Laryngoscope*, vol. 121, no. 10, pp. 2090–2094, 2011.

[14] S. I. Adam, B. Paskhover, and C. T. Sasaki, "Laser versus stapler: outcomes in endoscopic repair of Zenker diverticulum," *Laryngoscope*, vol. 122, no. 9, pp. 1961–1966, 2012.

[15] G. Peretti, C. Piazza, F. del Bon, D. Cocco, L. de BeneDetto, and S. Mangili, "Endoscopic treatment of Zenker's diverticulum by carbon dioxide laser," *Acta Otorhinolaryngologica Italica*, vol. 30, no. 1, pp. 1–4, 2010.

[16] B. Benjamin and R. Gallagher, "Microendoscopic laser diverticulotomy for hypopharyngeal diverticulum," *Annals of Otology, Rhinology and Laryngology*, vol. 102, no. 9, pp. 675–679, 1993.

[17] P. Zbaren, P. Schar, L. Tschopp, M. Becker, and R. Hausler, "Surgical treatment of Zenker's diverticulum: transcutaneous diverticulectomy versus microendoscopic myotomy of the cricopharyngeal muscle with CO_2 laser," *Otolaryngology—Head and Neck Surgery*, vol. 121, no. 4, pp. 482–487, 1999.

[18] A. Aly, P. G. Devitt, and G. G. Jamieson, "Evolution of surgical treatment for pharyngeal pouch," *The British Journal of Surgery*, vol. 91, no. 6, pp. 657–664, 2004.

Hindawi Publishing Corporation
BioMed Research International
Volume 2014, Article ID 819453, 6 pages
http://dx.doi.org/10.1155/2014/819453

Review Article

Treatment of Laryngoceles: What Is the Progress over the Last Two Decades?

Karol Zelenik,[1] Lucia Stanikova,[1] Katarina Smatanova,[2] Michal Cerny,[2] and Pavel Kominek[1]

[1] *Department of Otorhinolaryngology, University Hospital Ostrava, 17. listopadu 1790, 708 52 Ostrava, Czech Republic*
[2] *Department of Otorhinolaryngology and Head and Neck Surgery, Faculty of Medicine in Hradec Kralove, University Hospital Hradec Kralove, Charles University in Prague, Sokolska 581, 50 005 Hradec Kralove, Czech Republic*

Correspondence should be addressed to Karol Zelenik; karol.zelenik@fno.cz

Received 10 January 2014; Accepted 2 February 2014; Published 6 March 2014

Academic Editor: Jan Plzák

Objectives. To review surgical techniques used in the treatment of laryngoceles over the last two decades and point out developments and trends. *Materials and Methods*. PubMed, the Cochrane Library, and the JBI Library of Systematic Reviews were searched using the term "laryngocele." Demographic data, type of laryngocele, presence of a laryngopyocele, type of treatment and need for a tracheotomy were assessed. *Results*. Overall, data on 86 patients were analyzed, culled from 50 articles, of which 41 were case reports and 9 were case series. No single systematic review or meta-analysis or randomized controlled trial has been published on the topic. Altogether, 71 laryngoceles in 63 patients met the criteria for further analysis focusing on surgical treatment. An external approach was selected in 25/29 (86.2%) cases of combined laryngoceles. Microlaryngoscopic resection using a CO_2 laser was performed in three cases and endoscopic robotic surgery in one case. The majority of patients with an internal laryngocele, 31/42 (73.8%), were treated using the microlaryngoscopy approach. *Conclusions*. Microlaryngoscopy involving the use of a CO_2 laser has become the main therapeutic procedure for the treatment of internal laryngoceles during the past 20 years. An external approach still remains the main therapeutic approach for the treatment of combined laryngoceles.

1. Introduction

A laryngocele is an abnormal dilation of the laryngeal saccule that extends upward within the false vocal fold, is filled with air, and is in communication with the laryngeal lumen [1, 2]. The term laryngocele should be used only when the lesion is symptomatic, palpable, or visible during laryngoscopy or when it is found to extend above the upper border of thyroid cartilage [1].

There are currently three main theories regarding the etiology of laryngoceles: congenital factors, increased laryngeal pressure, and mechanical obstruction [3, 4]. It has been stated that prolonged periods of increased laryngeal pressure (e.g., in glass blowers and wind instrument players) could result in gradual dilation of the saccule [5]. The use of a laryngeal mask during general anaesthesia can have the same effect [6]. Moreover, mechanical obstruction of the ventricle as a result of acquired laryngeal disease (carcinoma, chondroma, amyloidosis, and others) can cause increased intraventricular pressure and promote dilatation of the saccule [3, 7–10].

Laryngoceles are categorized as internal (Figure 1) or combined (Figure 2) [11]. The formerly used classification into internal, external, and combined laryngoceles is being abandoned because purely external laryngoceles cannot exist, as laryngoceles originate at the laryngeal saccule. An internal laryngocele is confined within the false vocal fold, medial to the thyrohyoid membrane. A combined laryngocele extends upward and protrudes through the thyrohyoid membrane to the neck [11]. If the neck of the laryngocele becomes obstructed (causes of which include tumours and chronic inflammation of the larynx), the mucus produced by the mucous glands of the lining epithelium can accumulate, leading to a laryngomucocele. When it is infected, a laryngopyocele forms [12].

Laryngoceles are uncommon entities and currently there is no consensus regarding their surgical treatment. Various

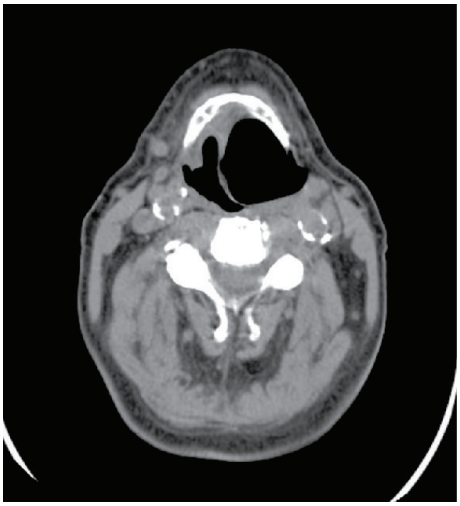

Figure 1: Right internal laryngocele.

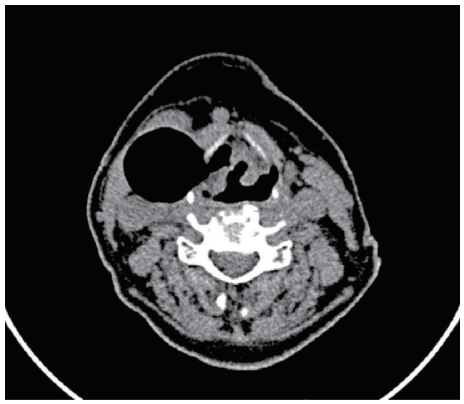

Figure 2: Left combined laryngocele.

modalities of treatment have been utilized [11, 13–18]. An external approach, the traditional treatment, is still being advocated by some authors [11, 13] However, endoscopic management of laryngoceles has gained popularity during the last two decades, following the advent of microlaryngoscopic surgery and CO_2 lasers [14, 17, 18].

The objective of this paper is to review the existing body of literature on the subject, find out which surgical techniques have been used for the treatment of laryngoceles within the last two decades, and point out developments and trends. To our knowledge, a review article summarizing laryngocele treatment has not been published to date.

2. Materials and Methods

PubMed, the Cochrane Library, and the JBI Library of Systematic Reviews were searched using the term "laryngocele" to identify articles published on the topic within the period 1994–2013. All articles were reviewed by two independent reviewers and only those written in the English language, dealing with adult patients and with a stated therapeutic approach, were selected for the study. Data on patients who did not undergo surgery and on those with laryngoceles and associated tumors which required specific surgical treatments were excluded from further analysis of surgical methods.

Demographic data (sex, age), type of laryngocele (internal, combined, unilateral, and bilateral), presence of a laryngopyocele, type of treatment, the inclusion of a tracheotomy as part of the treatment, and recurrence were assessed.

Laryngoceles formerly claimed to be external were reclassified as combined for the purpose of this study, because purely external laryngoceles cannot exist, as laryngoceles originate at the laryngeal saccule [11].

The following types of external surgery were ascertained to have been performed: transthyrohyoid membrane approach, thyrotomy with resection of the upper 1/3 of thyroid cartilage, and V-shaped thyrotomy. The following types of endolaryngeal surgery were ascertained to have been performed: microlaryngoscopy using a CO_2 laser or cold instruments, marsupialization, and robotic surgery.

Descriptive statistics using Microsoft Excel were used to analyze the results.

3. Results

Using the term "laryngocele" a total of 123 articles published within the period 1994–2013 were found on PubMed. Searches of the Cochrane Library and the JBI Library of Systematic Reviews did not yield any systematic reviews or meta-analyses on the topic. Overall, data on 86 patients culled from 50 articles [6, 8–56], of which 41 were case reports and 9 were case series, met the inclusion criteria. No single systematic review or meta-analysis or randomized controlled trial had been published on the topic.

Data on up to 23 patients were excluded from further analysis focusing on surgical treatment, because 15 of them did not undergo surgery and 8 had an associated tumor that required a specific surgical treatment.

Overall, data on 63 patients were included for further analysis focusing on surgical treatment. Demographic data and results are summarized in Tables 1 and 2. Of the 63 patients, 35 (55.6%) were male and 28 (44.4%) female. Average age of the patients was 50.75 years. 55 had unilateral laryngoceles and 8 had bilateral laryngoceles, so surgical treatment of a total of 71 laryngoceles, 42 (59.2%) internal, and 29 (40.8%) combined was analyzed. Laryngopyocele was listed in 12 (16.9%) cases. Tracheotomy as a part of the surgery was done in 11/63 (17.5%) patients. In 6/63 (9.5%) patients a tracheotomy was performed as an urgent surgery to preempt the risk of suffocation.

An external approach was selected in 25/29 (86.2%) cases of combined laryngoceles. Surgical procedures included the transthyrohyoid membrane approach (an approach that does not involve resection of the thyroid cartilage) in 17/29 (58.6%) cases, thyrotomy with resection of the upper 1/3 of thyroid cartilage in four cases, and V-shaped thyrotomy in four cases. Microlaryngoscopic resection using a CO_2 laser was performed in three cases and endoscopic robotic surgery in one case.

Table 1: Summary of demographic data and basic results.

Number of patients	63
Sex	Men = 35 (55.6%), women = 28 (44.4%)
Average age	50.75 years
Number of unilateral and bilateral laryngoceles	Unilateral = 55 (87.3%), bilateral = 8 (12.7%)
Type of laryngocele	Internal = 42 (59.2%), combined = 29 (40.8%)
Laryngopyocele	12 (16.9%)
Tracheotomy	11 patients (17.5%)
Recurrence	None reported

The majority of patients with internal laryngoceles, 31/42 (73.8%), were treated using the microlaryngoscopy approach. Resection using a CO_2 laser was done in 24 cases, resection using cold instruments in two cases and marsupialization in five cases. An external approach was selected in nine cases, among which were one transthyrohyoid membrane approach and eight V-shaped thyrotomies.

4. Discussion

The incidence of laryngocele is estimated to be 1 per 2.5 million of the population per year [57] and laryngoceles have been reported to be five times more frequent in men, with a peak incidence in the sixth decade of life [3, 58]. In contrast, our review had a male-to-female ratio of 1.25 : 1 and peek incidence in the fifth decade. These results are similar to the results of Devesa et al. [18], who reported a male-to-female ratio of 7 : 5 and a peak incidence in the fifth decade in their series. 87% of the laryngoceles in our data were unilateral, which is consistent with previously published data [18, 58].

Laryngocele is a rare condition that presents a surgical dilemma. As a result, many types of surgery have been used in its treatment. Excision of both types, combined and internal, was traditionally done using an external approach [13]. However, with the advent of microlaryngoscopic surgery and the CO_2 laser during the last two decades, the endolaryngeal technique has gained popularity and many of the authors reviewed have begun to use this technique for the treatment of internal laryngoceles [17, 18]. Moreover, some authors have begun to use a microlaryngoscopy technique for the treatment of combined laryngoceles as well [18]. On the other hand, the external approach is still being advocated by some authors [11, 13].

When discussing surgical procedures used for the treatment of laryngoceles during the last 20 years, which was the main goal of our review, it is necessary to consider combined and internal laryngoceles separately.

Most of the patients with combined laryngoceles (86.2%) were treated using an external approach. The reported advantages of external approaches are good exposure of the laryngocele, a more precise procedure and a low recurrence rate. Disadvantages are skin scarring, higher morbidity, longer duration of surgery, longer hospitalization period, and higher costs [11]. Three types of external procedures have been used during the past 20 years—the transthyrohyoid membrane approach, thyrotomy with resection of the upper 1/3 of the thyroid cartilage, and V-shaped thyrotomy [11, 13, 27, 30, 35, 46, 50]. The transthyrohyoid membrane approach was the one used most often, in 68% of the cases treated using external techniques. The advantage of this procedure when compared with the other two is that no resection of the thyroid cartilage is done. The disadvantage is limited exposure of the paraglottic space. Thyrotomy with resection of the upper 1/3 of the thyroid cartilage and V-shaped thyrotomy were used in a minority of patients [11, 13, 50]. As part of these techniques, a portion of the thyroid cartilage is resected. This enables better exposure ofparaglottic space [11].

Interestingly, four patients with combined laryngoceles were treated using the endolaryngeal approach [18]. Devesa et al. reported on 12 patients with laryngoceles treated using the microlaryngoscopic approach and a CO_2 laser, of whom three had combined laryngoceles. The authors describe how they deal with the external part of the combined laryngoceles. Once the internal component is isolated, any lateral external component can be drawn into the laryngeal lumen gradually by a mixture of laser mobilization, traction, and blunt microsurgical dissection. If the bulk of the mobilized laryngocele becomes too large for ease of handling endoscopically, it is a simple matter to excise the more medial and superior component and then to continue with the remainder [18].

The first endolaryngeal resection of a combined laryngocele using robotic surgery was reported in 2013 [16]. According to the authors, this technique seems to have several advantages when compared with microlaryngoscopy. For instance, optics are placed in the oral cavity, thus allowing closer, angulated vision of the surgical field. In addition, rather than using traditional laryngoscopes, instruments are introduced through mouth gags, which offer a wider view and range of motion. Furthermore, miniaturized, angulated, and "tremor-filtered" robotic instruments with "wristed-tips" enable one to reach far lateral (hidden) areas [16].

An interesting procedure was described by Szwarc and Kashima in 1997 [14]. The authors put their patient with a combined laryngocele on intravenous antibiotics for two weeks. As a supportive treatment they used "warm throat irrigations" and prohibited smoking. As a result, the external part of the combined laryngocele vanished and the internal part was then resected using a CO_2 laser via the microlaryngoscopy approach [14].

The majority of internal laryngoceles in our review, 31 out of 42 (73.8%), were treated using the endolaryngeal (microlaryngoscopy) approach. Resection using a CO_2 laser is currently the preferred and most frequently used type of surgery for internal laryngoceles. It was performed in 24 cases. This technique is considered by many authors to be a quick, precise, and safe alternative to an external approach excision, with fewer complications than its external counterparts, resulting in speedier rehabilitation of both the patient and his or her voice [14, 17, 18, 21, 38, 41]. Moreover Devesa et al. advocate using this technique for the treatment of combined laryngoceles [18].

Table 2: Surgical treatment of 63 combined and internal laryngoceles.

Type of laryngocele	Treatment	Specific type of surgery
Combined = 29	External = 25	Transthyrohyoid membrane approach = 17 Thyrotomy with resection of the upper 1/3 thyroid cartilage = 4 V-shaped thyrotomy = 4
	Endolaryngeal = 4	Microlaryngoscopic CO_2 laser resection = 3 Endoscopic robotic surgery = 1
Internal = 42	External = 9	Transthyrohyoid membrane approach = 1 V-shaped thyrotomy = 8
	Endolaryngeal = 31	Microlaryngoscopic CO_2 laser resection = 24 Microlaryngoscopic resection using cold instruments = 2 Marsupialization = 5

On the other hand, the endolaryngeal management of laryngoceles has the disadvantages of providing limited surgical exposure, causing endolaryngeal scarring and requiring experience with special instruments [11]. Furthermore, the probability of incomplete resection of large laryngoceles limits use of the endoscopic approach [11]. However, the last seems not to be of clinical significance, since no recurrence has been reported to date following the use of endolaryngeal techniques.

Two patients with internal laryngoceles were operated on via microlaryngoscopy using cold instruments [9, 32]. A risk of more severe bleeding is associated with this type of surgery, which prolongs the duration of surgery as well. A decreased incidence of bleeding is the main advantage of the introduction of a CO_2 laser into microlaryngeal surgery, which is why most microlaryngoscopy resections are currently done using a CO_2 laser [17].

Marsupialization of the laryngocele was performed in five cases. This technique entails a longer healing period and the risk of recurrence, since during the process of healing mucosa can form a new mucocele or cyst over the residual sack [18].

An external approach was selected in nine (26.2%) patients with internal laryngoceles, of which a transthyrohyoid membrane approach was adopted in one case and V-shaped thyrotomies in eight cases. This number seems to be quite high, given that the endoscopic approach has been advocated as the appropriate treatment for internal laryngoceles. However, after detailed examination, the following fact came to light. The transthyrohyoid membrane approach was adopted by Myssiorek et al. in 2001 in one case [13] and the performance of V-shaped thyrotomies was reported by Thomé et al. in 2000 in eight cases [11], which means that no single external approach has been reported in the treatment of internal laryngoceles during the past 12 years.

Tracheotomies were part of the surgery done on 11/63 (17.5%) patients. In six (9.5%) patients, a tracheotomy was done as an urgent surgery to preempt the risk of suffocation. This means that almost 10% of laryngoceles present as emergencies, something that is important to keep in mind. Moreover, two fatal cases of laryngocele were reported. In one case a 55-year-old woman with an obstructing combined laryngocele refused acute treatment and hospitalization and died suddenly a few minutes after leaving the hospital [53]. The other patient, a 70-year-old man, died during the night while waiting for surgery scheduled for the next day [51]. In light of the above mentioned cases, acute resection of the laryngocele or tracheotomy should be done as a "lege artis" action in patients at risk of suffocation, particularly in patients with a laryngocele having an extensive internal part.

5. Conclusion

The traditional treatment of a laryngocele was excision using an external approach. Advances in endoscopic techniques and the development and further applications of the laser in surgery have generated a new philosophy in the management of laryngeal diseases. Microlaryngoscopy with use of a CO_2 laser has become the main therapeutic procedure for the treatment of internal laryngoceles during the past 20 years. Moreover, microlaryngoscopy has been used in all reported cases of internal laryngoceles during the last 12 years. An external approach still remains the main therapeutic approach for the treatment of combined laryngoceles. But endolaryngeal surgery has begun to be used too. Robotic surgery seems a promising method in the treatment of combined laryngoceles, but its potential advantages have yet to be proved.

Conflict of Interests

The authors declare that there is no actual or potential conflict of interest in relation to this paper. No benefits in any form have been received or will be received from a commercial party related directly or indirectly to the subject of this paper.

Acknowledgment

This work is supported by a Grant of Czech Ministry of Health no. NT13725-4/2012.

References

[1] L. D. Holinger, D. R. Barnes, L. J. Smid, and P. H. Holinger, "Laryngocele and saccular cysts," *Annals of Otology, Rhinology and Laryngology*, vol. 87, no. 5, part 1, pp. 675–685, 1978.

[2] L. W. DeSanto, "Laryngocele, laryngeal mucocele, large saccules, and laryngeal saccular cysts: a developmental spectrum," *Laryngoscope*, vol. 84, no. 8, pp. 1291–1296, 1974.

[3] M. Amin and A. G. D. Maran, "The aetiology of laryngocele," *Clinical Otolaryngology*, vol. 13, pp. 267–272, 1988.

[4] R. F. Canalis, D. S. Maxwell, and W. G. Hemenway, "Laryngocele—an updated review," *Journal of Otolaryngology*, vol. 6, no. 3, pp. 191–199, 1977.

[5] D. D. Macfie, "Asymptomatic laryngoceles in wind-instrument bandsmen," *Archives of Otolaryngology*, vol. 83, no. 3, pp. 270–275, 1966.

[6] N. Gonik, S. Setty, E. Delphin, T. Straker, and B. A. Schiff, "Intraoperative inflation of laryngocele with LMA," *American Journal of Otolaryngology*, vol. 34, no. 6, pp. 746–748, 2013.

[7] S. E. Celin, J. Johnson, H. Curtin, and L. Barnes, "The association of laryngoceles with squamous cell carcinoma of the larynx," *Laryngoscope*, vol. 101, no. 5, pp. 529–536, 1991.

[8] M. Mitroi, A. Căpitănescu, F. C. Popescu et al., "Laryngocele associated with laryngeal carcinoma," *Romanian Journal of Morphology and Embryology*, vol. 52, no. 1, pp. 183–185, 2011.

[9] I. Papila, E. Acioğlu, E. Karaman, and C. Akman, "Laryngeal chondroma presenting as a laryngopyocele," *European Archives of Oto-Rhino-Laryngology*, vol. 262, no. 6, pp. 473–476, 2005.

[10] W. V. B. S. Ramalingam, S. Nair, A. V. Ramesh, D. K. Gupta, and A. Kumar, "Combined laryngocele secondary to localized laryngeal amyloidosis," *Indian Journal of Otolaryngology and Head and Neck Surgery*, vol. 64, no. 2, pp. 193–196, 2012.

[11] R. Thomé, D. C. Thomé, and R. A. C. De La Cortina, "Lateral thyrotomy approach on the paraglottic space for laryngocele resection," *Laryngoscope*, vol. 110, no. 3, part 1, pp. 447–450, 2000.

[12] R. C. Helmberger, B. P. Croker, and A. A. Mancuso, "Leiomyosarcoma of the larynx presenting as a laryngopyocele," *American Journal of Neuroradiology*, vol. 17, no. 6, pp. 1112–1114, 1996.

[13] D. Myssiorek, D. Madnani, and M. D. Delacure, "The external approach for submucosal lesions of the larynx," *Otolaryngology—Head and Neck Surgery*, vol. 125, no. 4, pp. 370–373, 2001.

[14] B. J. Szwarc and H. K. Kashima, "Endoscopic management of a combined laryngocele," *Annals of Otology, Rhinology and Laryngology*, vol. 106, no. 7, part 1, pp. 556–559, 1997.

[15] G. Vengerovich, E. D. McCoul, D. H. Burstein, F. B. Yao, and J. W. Lim, "Excision of laryngocele via transcervical midline approach," *Laryngoscope*, vol. 120, no. 4, p. S189, 2010.

[16] P. G. Ciabatti, G. Burali, and L. D'Ascanio, "Transoral robotic surgery for large mixed laryngocoele," *The Journal of Laryngology and Otology*, vol. 127, no. 4, pp. 435–437, 2013.

[17] G. Dursun, O. B. Ozgursoy, S. Beton, and H. Batikhan, "Current diagnosis and treatment of laryngocele in adults," *Otolaryngology—Head and Neck Surgery*, vol. 136, no. 2, pp. 211–215, 2007.

[18] P. M. Devesa, K. Ghufoor, S. Lloyd, and D. Howard, "Endoscopic CO_2 laser management of laryngocele," *Laryngoscope*, vol. 112, no. 8, part 1, pp. 1426–1430, 2002.

[19] Y. Akbas, M. Ünal, and Y. S. Pata, "Asymptomatic bilateral mixed-type laryngocele and laryngeal carcinoma," *European Archives of Oto-Rhino-Laryngology*, vol. 261, no. 6, pp. 307–309, 2004.

[20] O. Akdogan, O. Ibrahim, A. Selcuk, and H. Dere, "The association of laryngoceles with squamous cell carcinoma of the larynx presenting as a deep neck infection," *B-ENT*, vol. 3, no. 4, pp. 209–211, 2007.

[21] E. A. Aksoy, C. Elsürer, G. M. Serin, and O. F. Unal, "Bilateral internal laryngoceles mimicking asthma," *Journal of Research in Medical Sciences*, vol. 18, no. 5, pp. 453–456, 2013.

[22] Z. Andreou, P. S. Randhawa, P. O'Flynn, and F. M. Vaz, "Endoscopic management of an internal laryngopyocele presenting with acute airway obstruction," *Case Reports in Surgery*, vol. 2011, Article ID 873613, 3 pages, 2011.

[23] O. Araz, A. Turan, O. Yoruk, F. Alper, and M. Akgun, "Laryngocele and epiglottic cyst as rare causes of obstructive sleep apnea," *Sleep and Breathing*, vol. 13, no. 3, pp. 285–287, 2009.

[24] A. Arslan, N. Ceylan, A. Çetin, and A. Demirci, "Laryngeal amyloidosis with laryngocele: MRI and CT," *Neuroradiology*, vol. 40, no. 6, pp. 401–403, 1998.

[25] O. Aydin, E. Ustündağ, M. Işeri, H. Ozkarakaş, and A. Oğuz, "Laryngeal amyloidosis with laryngocele," *The Journal of Laryngology and Otology*, vol. 113, no. 4, pp. 361–363, 1999.

[26] H. Çankaya, E. Egeli, Ö. Unal, and M. Kiris, "Laryngeal amyloidosis. A rare cause of laryngocele," *Clinical Imaging*, vol. 26, no. 2, pp. 86–88, 2002.

[27] L. Cassano, P. Lombardo, R. M. Ragona, and A. Pastore, "Laryngopyocele: three new clinical cases and review of the literature," *European Archives of Oto-Rhino-Laryngology*, vol. 257, no. 9, pp. 507–511, 2000.

[28] B. Erdogmus, B. Yazici, O. Ozturk, S. Ataoglu, and S. Yazici, "Laryngocele in association with ankylosing spondylitis," *Wiener Klinische Wochenschrift*, vol. 117, no. 19-20, pp. 718–720, 2005.

[29] S. L. Ettema, D. G. Carothers, and H. T. Hoffman, "Laryngocele resection by combined external and endoscopic laser approach," *Annals of Otology, Rhinology and Laryngology*, vol. 112, no. 4, pp. 361–364, 2003.

[30] J. A. D. P. Felix, F. Felix, and L. F. P. De Mello, "Laryngocele: a cause of upper airway obstruction," *Brazilian Journal of Otorhinolaryngology*, vol. 74, no. 1, pp. 143–146, 2008.

[31] L. Fraser, B. Pittore, S. Frampton, P. Brennan, and R. Puxeddu, "Laryngeal debridement: an alternative treatment for a laryngopyocele presenting with severe airway obstruction," *Acta Otorhinolaryngologica Italica*, vol. 31, no. 2, pp. 113–117, 2011.

[32] K. L. Fredrickson and A. J. D'Angelo Jr., "Internal laryngopyocele presenting as acute airway obstruction," *Ear, Nose and Throat Journal*, vol. 86, no. 2, pp. 104–106, 2007.

[33] A. R. Gafton, S. M. Cohen, J. D. Eastwood, M. K. Dang, and J. K. Hoang, "Recurrent laryngopyocele: CT-guided hookwire localization for re-excision surgery," *American Journal of Neuroradiology*, vol. 34, no. 4, pp. E39–E42, 2013.

[34] K. H. Gallivan and G. J. Gallivan, "Bilateral mixed laryngoceles: simultaneous strobovideolaryngoscopy and external video examination," *Journal of Voice*, vol. 16, no. 2, pp. 258–266, 2002.

[35] S. C. Gupta, A. Goel, and P. A. Singh, "External laryngocele," *Indian Journal of Otolaryngology and Head and Neck Surgery*, vol. 50, no. 3, pp. 298–301, 1998.

[36] M. Harney, N. Patil, R. Walsh, P. Brennan, and M. Walsh, "Laryngocele and squamous cell carcinoma of the larynx," *Journal of Laryngology and Otology*, vol. 115, no. 7, pp. 590–592, 2001.

[37] M. Herrag, S. Lahmiti, H. Sajiai et al., "A laryngocele revealing a small cell lung carcinoma," *B-ENT*, vol. 6, no. 3, pp. 215–217, 2010.

[38] T. P. Hirvonen, "Endoscopic Co_2 laser surgery for large internal laryngocele," *ORL*, vol. 63, no. 1, pp. 58–60, 2001.

[39] E. Keles, H. C. Alpay, I. Orhan, and H. Yildirim, "Combined laryngocele: a cause of stridor and cervical swelling," *Auris Nasus Larynx*, vol. 37, no. 1, pp. 117–120, 2010.

[40] A. Lancella, G. Abbate, and R. Dosdegani, "Mixed laryngocele: a case report and review of the literature," *Acta Otorhinolaryngologica Italica*, vol. 27, no. 5, pp. 255–257, 2007.

[41] T. Marom, Y. Roth, and U. Cinamon, "Laryngocele: a rare long-term complication following neck surgery?" *Journal of Voice*, vol. 25, no. 3, pp. 272–274, 2011.

[42] S. E. McDonald, D. K. Pinder, C. Sen, and M. A. Birchall, "Oncocytic cyst presenting as laryngocele with surgical emphysema," *European Archives of Oto-Rhino-Laryngology*, vol. 263, no. 3, pp. 237–240, 2006.

[43] E. Mensiz, M. Tüz, O. Oyar, H. Doğru, and H. Yasan, "A case of orbital emphysema associated with internal laryngocele," *Auris Nasus Larynx*, vol. 30, no. 2, pp. 197–200, 2003.

[44] S. P. Murray, L. P. A. Burgess, D. M. Burton, C. Gonzalez, G. S. Wood, and J. T. Zajtchuk, "Laryngocele associated with squamous carcinoma in a 20-year-old nonsmoker," *Ear, Nose and Throat Journal*, vol. 73, no. 4, pp. 258–261, 1994.

[45] H. Nazaroğlu, M. Ozateş, A. Uyar, E. Değer, and M. Simşek, "Laryngopyocele: signs on computed tomography," *European Journal of Radiology*, vol. 33, no. 1, pp. 63–65, 2000.

[46] C. Özcan, Y. Vayisoglu, N. Güner, S. Türkili, and K. Görür, "External laryngopyocele: a rare cause of upper airway obstruction," *Journal of Craniofacial Surgery*, vol. 21, no. 6, pp. 2022–2024, 2010.

[47] R. J. E. Pennings, F. J. A. van den Hoogen, and H. A. M. Marres, "Giant laryngoceles: a cause of upper airway obstruction," *European Archives of Oto-Rhino-Laryngology*, vol. 258, no. 3, pp. 137–140, 2001.

[48] K. C. Prasad, S. Vijayalakshmi, and S. C. Prasad, "Laryngoceles—presentations and management," *Indian Journal of Otolaryngology and Head and Neck Surgery*, vol. 60, no. 4, pp. 303–308, 2008.

[49] A. Prasai, J. Phillips, and P. Jani, "Spontaneous resolution of a traumatic laryngocele," *The Journal of Otolaryngology*, vol. 36, no. 3, pp. E5–E8, 2007.

[50] M. V. V. Reddy, C. Ramakrishna, M. Gupta et al., "Laryngocele—a case report and review of literature," *Indian Journal of Otolaryngology and Head and Neck Surgery*, vol. 60, no. 3, pp. 281–283, 2008.

[51] T. Satou, T. Naito, Y. Hayashi, S. Hashimoto, and S. Sugiyama, "A sudden death case of laryngocele accompanied by infarction of the dorso-lateral portion of the medulla oblongata," *Legal Medicine*, vol. 1, no. 4, pp. 257–261, 1999.

[52] D. J. Stocker, W. F. Kelly, T. M. Fitzpatrick, V. J. Bernet, and H. B. Burch, "Bilateral external laryngoceles following radioiodine ablation for Graves disease," *Archives of Internal Medicine*, vol. 162, no. 17, pp. 2007–2009, 2002.

[53] K. Töro, M. Kardos, and G. Dunay, "Fatal asphyxia due to laryngomucocele," *Forensic Science International*, vol. 190, no. 1–3, pp. e1–e4, 2009.

[54] T. Upile, W. Jerjes, F. Sipaul et al., "Laryngocele: a rare complication of surgical tracheostomy," *BMC Surgery*, vol. 6, article 14, 2006.

[55] I. Vasileiadis, S. Kapetanakis, A. Petousis, A. Stavrianaki, A. Fiska, and E. Karakostas, "Internal laryngopyocele as a cause of acute airway obstruction: an extremely rare case and review of the literature," *Acta Otorhinolaryngologica Italica*, vol. 32, no. 1, pp. 58–62, 2012.

[56] S. Vedasalam, F. Sipaul, and G. Porter, "Internal laryngocoele and referred otalgia," *BMJ Case Reports*, 2010.

[57] P. M. Stell and A. G. D. Maran, "Laryngocele," *The Journal of Laryngology and Otology*, vol. 89, pp. 915–924, 1975.

[58] D. Ingrams, D. Hein, and N. Marks, "Laryngocele: an anatomical variant," *Journal of Laryngology and Otology*, vol. 113, no. 7, pp. 675–677, 1999.

Hindawi Publishing Corporation
BioMed Research International
Volume 2014, Article ID 421964, 7 pages
http://dx.doi.org/10.1155/2014/421964

Clinical Study

Early Stage Oropharyngeal Carcinomas: Comparing Quality of Life for Different Treatment Modalities

Don-Felix Ryzek, Konstantinos Mantsopoulos, Julian Künzel, Philipp Grundtner, Johannes Zenk, Heinrich Iro, and Georgios Psychogios

Department of Otorhinolaryngology, Head and Neck Surgery, Friedrich Alexander University of Erlangen-Nuremberg, Waldstraße 1, 91054 Erlangen, Germany

Correspondence should be addressed to Georgios Psychogios; gpsychogios@gmail.com

Received 20 November 2013; Accepted 8 January 2014; Published 25 February 2014

Academic Editor: Jan Plzák

Objective. To compare long-term quality of life outcomes after treating early stage oropharyngeal carcinoma either with surgery, surgery combined with radiotherapy, or surgery combined with chemoradiotherapy. *Methods*. Questionnaire based method: 111 eligible patients agreed to fill out a quality of life questionnaire. *Results*. Of the 32 scales contained in the EORTC's combined QLQ-C30 and HN35, 11 scales show significantly better results for the surgery-only treatment group when compared to either surgery combined with radiotherapy or surgery combined with any type of adjuvant therapy. These eleven scales are role function ($P = 0.019/0.008$), social function ($P = 0.01/0.034$), nausea ($P = 0.017/0.025$), pain ($P = 0.014/0.023$), financial problems ($P = 0.030/0.012$), speech ($P = 0.02/0.015$), social eating ($P = 0.003/<0.001$), mouth opening ($P = 0.033/0.016$), sticky saliva ($P = 0.001/<0.001$), swallowing ($P < 0.001/<0.001$), and dry mouth ($P < 0.001/0.001$). *Conclusion*. Treatment of early stage oropharyngeal carcinoma with surgery alone has definite advantages over treatments including any form of adjuvant therapy when considering quality of life. Advantages manifest themselves especially in functional aspects of the head and neck realm; however general health aspects as well as psychosocial aspects show improvements as well. This study does not show any indication of QOL-related drawbacks of surgery-only treatment approaches.

1. Introduction

Oropharyngeal Carcinomas (OPCs) represent up to 3% of all new cancer diagnoses in the United States and are a commonly occurring cancer of the head and neck region [1, 2]. Usually, these OPCs are diagnosed in more advanced stages and have poor prognosis. However, when they are diagnosed early on (at stages T1 and T2), they have good five-year survival estimates [3, 4]. Upon diagnosis in their early stages, transoral tumor resection alone or in combination with adjuvant radiotherapy or chemoradiotherapy offers very good oncologic results [5, 6]. All of these treatment modalities have showed their effectiveness in increasing survival estimates [7–9]. Since oncologic results are excellent, impact on quality of life becomes important when choosing treatment modality for the individual patient [10].

The uniqueness of the oropharyngeal anatomical region stems from its functional importance in activities such as eating and speaking. In addition, its highly exposed nature allows potential aesthetic defects to have a strong stigmatizing effect. Given these key functional and social aspects, and the fact that OPC as well as the different treatment options can have severe effects on all of these factors, it should be of no surprise that the patients' subjective quality of life (QOL) could be severely affected on social, physical, and psychological levels.

Considering the potentially different effect on QOL stemming from methodically different but comparably effective treatment methods, expected QOL outcomes should be an important factor when choosing the appropriate therapeutic approach [11]. Publicly, nonsurgical treatment methods are perceived as less invasive and thus are often favored due to the assumption that there may be a better QOL outcome [12, 13]. There is little conclusive data to support this conclusion and this study aims to shed light with regard to this issue. Furthermore, the aim of this study is to compare the QOL in patients

after transoral resection of a small OPC with or without adjuvant treatment, in order to better understand the impact of the various parts of a multimodal treatment (surgery, radiotherapy, and chemotherapy) in long-term QOL.

2. Methods

The Ethics Commission of the FAU Erlangen-Nürnberg reviewed and subsequently approved the intended patient selection process and the study protocol as well as the required patient consent form. In order to be considered for the study, patients had to meet the following inclusion criteria: (1) tumor was located within the oropharynx, (2) primary tumor was of early stage (pT1 or pT2, N0-2), (3) no distant metastasis were detected (M0), (4) tumor was successfully treated with a minimum tumor free interval of 18 months after treatment, and (5) tumor was not a relapse of a previously existing tumor. The different forms of treatment considered were surgery alone (OP) or a combination of surgery and radio- and/or chemotherapy (OPRT/OPRCT). Excluded were all patients with a recurrent disease. For the purpose of this study, OPCs are defined as all carcinomas falling under the following groups of the ICD-10: C01, C05 without C05.0, C09, and C10.

An existing database comprised of follow-up patients with treated primary oropharyngeal carcinoma combined with a thorough screening of patients coming in for routine posttreatment follow-up was used to identify 160 eligible candidates.

Patients' QOL was evaluated in detail using German-language versions of two standardized questionnaires from the European Organization for Research and Treatment of Cancer (EORTC), specifically the Core Module [14] (EORTC-QLQ-C30) and the Head and Neck Cancer Module [15] (EORTC-QLQ-H&N35). The Core Module is designed as an assessment tool for cancer patients. It evaluates a total of nine multi-item scales including five functional scales (physical, role, cognitive, emotional, and social) and three symptom scales (fatigue, pain, and nausea and vomiting) as well as a global health and QOL-scale. Additionally, a number of single-item symptom measures are included. This Core Module is supplemented by the Head and Neck Cancer Module consisting of six multi-item scales designed to capture issues associated with cancers of the specified region and their treatment (pain, swallowing, speech, social eating, social contacts, and sexuality). In both modules, achievable scores for each scale range from zero to one hundred. Higher scores represent higher response levels; that is, in functional scales, a high score implicates more positive outcomes while high scores in symptom scales are congruent with more negative outcomes. Statistical analysis of the acquired data was done according to EORTC-QLQ scoring instructions. The resulting, dichotomized and grouped scores were compared and checked for significance using chi-square independence tests or Fischer tests when necessary for OP versus OPRT as well as for OP versus patients who received surgery and any form of adjuvant therapy (OP + adj). The latter group consists of OPRT as well as OPRCT. The phi-coefficient was used as a measure of association for significant results.

Missing items within the EORTC-QLQ were a minor issue when reviewing the questionnaires. Seven questionnaires that were sent out for home answering were missing items 9–19 of EORTC-QLQ-H&N35 due to a systematic error. Since the omissions were caused by a systematic error and not by patients' refusal to answer certain questions (because they felt uncomfortable to do so for instance) considering these single items as lost should have no further impact on the statistical proceedings. These single missing items were considered lost and not processed further.

The use of adjuvant therapy in form of RT or RCT was decided in our tumor board. Irradiation typically included the primary tumor site and the involved side of the neck. Various changes in treatment protocols, as well as technical developments, have been noted over the years. Today, however, typical indications for RCT include the presence of positive surgical margins when further surgery was not feasible, advanced neck disease, and extracapsular tumor spread. Typical indications for adjuvant RT include close margins, solitary cervical metastasis, and infiltration of lymph vessels or nerves in permanent histology. Sometimes a combination of soft criteria such as poor differentiation, large tumor dimension, or large tumor depth can result in offering the patient an adjuvant RT.

The standard tumor follow-up protocol of the ENT department was used to examine patients' medical status. This consisted of a patient interview and inspecting the treated regions visually (with aid of scopes), by palpation and, in indicated circumstances, by ultrasound. Results that were relevant to this study were documented on a form separate from the patient questionnaire.

3. Results

Of all eligible candidates, 111 volunteered to participate in the study anonymously between June 2011 and June 2012. 85 participants were males and 26 females. 80 patients were seen in person while 31 individuals preferred to participate by answering the questionnaire via mail. 26 patients were treated with surgery as their only form of treatment (OP-Group) while 33 patients received additional radiotherapy (OPRT-Group) and 52 patients had additional radiotherapy as well as chemotherapy (OPRCT-Group). Treated tumor sizes in all three groups were comparable. Detailed patient demographics according to therapy group are presented in Table 1.

The results of the EORTC-QLQ-C30 and the EORTC-QLQ/H&N35 for treatment groups OP, OPRT, and OPRCT are shown in Tables 2 and 3, respectively.

Table 4 contains four questionnaire scales (2 from EORTC-QLQ-C30 and 2 from EORTC-QLQ-HN35). For each item comparisons are made with regard to the percentage of patients that report a full score versus the percentage of patients that report a less than maximum score. A score of "100" can be equated with an optimal outcome. Items "role function" as well as "social function" (marked with italic font) show that the percentage of patients without any loss of function in these aspects is significantly higher when compared to OPRT or OP + adj treatment groups.

Table 1: Detailed description of demographics, treatment modalities, and histological differentiation according to therapy.

Characteristics	OP	OPRT	OPRCT
Gender	Male: 20 (76.9%) Female: 6 (23.1%)	Male: 24 (70.6%) Female: 10 (29.4%)	Male: 42 (82.4%) Female: 9 (17.6%)
Age (years)	Median: 55 Range: 40–69	Median: 54 Range: 37–78	Median: 54 Range: 36–73
Smoking	Smokers: 12 (15.4%), Nonsmokers: 4 (32.7%) n.a.: 10 (38.5%)	Smokers: 13 (38.2%), Nonsmokers: 3 (8.8%) n.a.: 18 (49%)	Smokers: 18 (35.3%), Nonsmokers: 4 (7.8%) n.a.: 29 (56.8%)
Follow-up (years)	Median: 2.99 Range: 0.28–10.69	Median: 4.44 Range: 0.93–15.85	Median: 4.77 Range: 0.22–13.05
Localization	Base of the tongue: 5 (19.2%) Palatine tonsil: 9 (34.6%) Palatal arch 11 (42.3%) Oropharynx NOS: 1 (3.8%)	Base of the tongue: 8 (23.5%) Palatine tonsil: 18 (52.9%) Palatal arch 5 (14.7%) Oropharynx NOS: 3 (8.8%)	Base of the tongue: 13 (25.5%) Palatine tonsil: 31 (60.8%) Palatal arch 2 (3.9%) Oropharynx NOS: 5 (9.8%)
T-category	pT1: 17 (65.3%) pT2: 9 (34.6%)	pT1: 15 (44.1%) pT2: 19 (55.9%)	pT1: 21 (41.2%) pT2: 30 (58.8%)
Tumor-depth (mm)*	Median: 4 Range: 1–35	Median: 5 Range: 2–25	Median: 5 Range: 1–19
Tumor-size (mm)	Median: 21 Range: 6–37	Median: 22 Range: 5–40	Median: 22 Range: 7–38
N-category (pooled)	0: 69.2% 1: 19.2% 2: 11.5%	0: 44.1% 1: 20.6% 2: 35.3%	0: 9.8% 1: 23.5% 2: 66.7%
Neck dissection	Yes: 20 (76.9%) No: 6 (23.1%)	Yes: 34 (100%)	Yes: 51 (100%)
Surgical technique	TLM: 3 (11.5%) Electrocautery: 33 (89.5%)	TLM: 6 (17.6%) Electrocautery: 27 (79.5%) Combined: 1 (2.9%)	TLM: 10 (19.6%) Electrocautery: 40 (78.4%) Combined: 1 (2.0%)
Histological differentiation	G2: 20 (76.9%) G3: 6 (23.1%)	G1: 1 (2.9%) G2: 20 (61.8%) G3: 6 (35.3%)	G2: 27 (52.9%) G3: 24 (47.1%)

*Tumor-depth is a calculated function of tumor extent and depth of infiltration.
TLM: transoral laser microsurgery, RT: radiotherapy, and RCT: radiochemotherapy.

Table 5 is comprised of twenty-two scales (EORTC-QLQ-C30: 9, EORTC-QLQ-HN35: 13). These scales are compared as to how many patients reported scores of zero versus how many patients reported scores above zero. For all items, a response of "0" represented a better outcome for the patient. Seven of these scales (EORTC-QLQ-C30: 3, EORTC-QLQ-HN35: 4) show significant correlation with $P \leq 0.05$. For all seven scales (nausea, pain, financial problems, HN speech, HN social eating, HN opening mouth, and HN sticky saliva), a surgery-only approach yielded more patients who reported optimal results when compared to OPRT and OP + adj. Five items of the scale HN social eating are missing answers due to the aforementioned systematic error, however, only to a negligible extent such that there is no effect on the trend.

The six final items (EORTC-QLQ-C30: 3, EORTC-QLQ-HN35: 3) as well as the overall Quality of Life score are compared in Table 6. The table reflects how many patients of each treatment group reported above- versus below-average outcomes. Notably, higher scores in the EORTC-QLQ-C30 items represent better outcomes, whereas lower scores in EORTC-QLQ-HN35 items are better. Items "HN swallowing" and "HN dry mouth" have significant results ($P \leq 0.05$) illustrating that an above-average number of members of the surgery-only treatment group reported below-average scores, that is, above-average outcomes.

4. Discussion

Quality of life (QOL) is a complex, multifaceted construct that is challenging to accurately measure. With the advent of tools, such as the EORTC's set of QOL-questionnaires some two decades ago, the possibility of comparing medically influenced outcomes on QOL allowed researchers to look beyond survival as the sole measure of successful medical intervention. This becomes especially valuable when faced with medical interventions that generate similar survival estimates and may primarily differ in terms of patients' perceived QOL. Currently, there are few studies comparing QOL outcomes in different treatment modalities of OPC [11, 13]. Many of these focus on the aftermath of advanced OPC while little research about early stage OPCs has surfaced [12]. Tschiesner et al. and Mowry et al. both come to the conclusion that treatments involving surgery have more desirable QOL-outcomes for advanced stage OPCs [4, 16]. In this particular

Table 2: EORTC-QLQ-C30 scores for all three treatment groups.

Item	OP Median (95%-confidence interval of mean)	OPRT Median (95%-confidence interval of mean)	OPRCT Median (95%-confidence interval of mean)
Global health status	75.00 (62.79–80.16)	66.67 (56.85–72.95)	66.67 (59.22–70.91)
Functional scales			
Physical	100 (87.33–97.28)	86.67 (75.34–88.30)	93.33 (79.68–91.66)
Role	100 (85.28–98.05)	83.33 (58.70–82.71)	83.33 (64.70–81.46)
Emotional	83.33 (72.59–88.95)	75.00 (59.79–80.79)	83.33 (66.66–80.99)
Cognitive	100 (80.90–96.02)	83.33 (68.77–87.80)	100 (76.23–89.79)
Social	100 (78.80–98.13)	83.33 (64.59–85.92)	100 (71.26–86.43)
Symptom scales			
Fatigue	16.67 (13.25–31.20)	22.22 (20.16–41.45)	27.78 (22.09–39.02)
Nausea and vomiting	0 (−0.68–1.96)	0 (2.39–11.75)	0 (1.78–9.76)
Pain	0 (5.16–21.77)	16.67 (18.31–39.26)	16.67 (17.18–34.75)
Dyspnea	0 (9.79–33.80)	0 (8.53–29.86)	0 (11.15–27.31)
Insomnia	0 (14.64–41.77)	0 (11.24–35.23)	0 (16.52–37.33)
Appetite loss	0 (−1.08–16.47)	0 (8.12–30.26)	0 (8.68–27.22)
Constipation	0 (2.26–20.82)	0 (5.68–28.66)	0 (3.16–16.07)
Diarrhea	0 (1.94–18.57)	0 (2.15–14.01)	0 (1.37–10.16)
Financial problems	0 (−2.17–20.11)	0 (7.74–24.58)	0 (12.26–28.76)

Table 3: EORTC-QLQ-H&N35 scores for all three treatment groups.

Item	OP Median (95%-confidence interval of mean)	OPRT Median (95%-confidence interval of mean)	OPRCT Median (95%-confidence interval of mean)
HN pain	0 (3.37–13.97)	8.33 (8.37–24.39)	8.33 (12.40–24.76)
HN swallowing	0 (3.78–20.88)	25.00 (19.34–32.39)	20.83 (18.82–29.44)
HN senses	0 (2.72–15.94)	0 (8.15–29.78)	0 (11.69–27.20)
HN speech	0 (0.58–16.31)	11.11 (11.67–28.18)	0 (9.39–22.56)
HN social eating	0 (2.25–22.42)	25.00 (16.18–37.65)	20.833 (18.97–35.20)
HN social contact	0 (0.48–6.45)	0 (3.21–19.32)	0 (4.21–13.29)
HN sexuality	0 (8.08–31.92)	0 (12.14–39.58)	0 (17.08–37.78)
HN teeth	0 (6.54–36.13)	0 (16.11–48.25)	0 (17.59–40.74)
HN opening mouth	0 (5.68–34.32)	33.33 (22.67–50.89)	33.33 (25.58–46.64)
HN dry mouth	0 (14.30–44.36)	100 (66.78–89.54)	66.67 (49.93–72.29)
HN sticky saliva	0 (3.60–23.06)	66.67 (37.11–66.33)	66.67 (37.50–59.72)
HN coughed	0 (12.41–35.59)	33.33 (16.65–40.82)	33.33 (23.38–41.89)
HN felt ill	0 (3.03–15.64)	0 (1.71–23.58)	0 (8.20–25.14)
HN pain killers	0 (19.36–60.64)	0 (10.28–44.89)	0 (17.65–44.85)
HN nutritional supplements	0 (−4.26–12.26)	0 (7.57–40.70)	0 (5.73–27.60)
HN feeding tube	0 (−1.69–25.69)	0 (−2.91–16.71)	0 (0.22–16.44)
HN weight loss	0 (6.01–41.99)	0 (0.44–27.14)	0 (2.80–22.20)
HN weight gain	0 (9.08–46.92)	0 (0.44–27.14)	0 (−0.85–13.35)

study, long-term outcomes of different treatment modalities for early stage OPC are considered the deciding factor when choosing a course of treatment for patients.

As shown in previous studies, individuals with limited OPC make up a group of patients with excellent oncologic result [5, 17]. A transoral resection of the tumor is possible in most cases. The development of laser microsurgery and transoral robotic surgery improves the effectiveness of surgical treatment [18]. In a recently published study we were able to show that in the absence of certain prognostic factors

Table 4: Comparing OP with OPRT and OP + adj—scale group 1 (percent within therapy group).

Item	OP		OPRT		OP + adj		OP versus OPRT	OP versus OP + adj
	Score 100	>100	100	>100	100	>100	*P*/Phi	*P*/Phi
Role function	*73.1*	*26.9*	*42.4*	*57.6*	*43.5*	*56.5*	*0.019/0.268*	*0.008/0.250*
Social function	*73.1*	*26.9*	*39.4*	*60.6*	*49.4*	*50.6*	*0.01/0.336*	*0.034/0.201*
HN sexuality	61.5	38.5	51.5	48.5	54.1	45.9	NS	NS
HN nutritional supplements	*96.2*	*3.8*	*76.7*	*23.3*	80.0	20.0	*0.038/0.278*	NS

NS: Results are statistically not significant.

Table 5: Comparing OP with OPRT and OP + adj—scale group 2 (percent within therapy group).

Item	OP		OPRT		OP + adj		OP versus OPRT	OP versus OP + adj
	Score 0	>0	0	>0	0	>0	*P*/Phi	*P*/Phi
Fatigue	30.8	69.2	30.3	69.7	32.9	67.1	NS	NS
Nausea	*96.2*	*3.8*	*72.7*	*27.3*	*76.5*	*23.5*	*0.017/0.310*	*0.025/0.213*
Pain	*65.4*	*34.6*	*33.3*	*66.7*	*40.0*	*60.0*	*0.014/0.319*	*0.023/0.216*
Dyspnea	57.7	42.3	66.7	33.3	64.7	35.3	NS	NS
Insomnia	53.8	46.2	60.0	40.0	60.0	40.0	NS	NS
Appetite loss	84.6	15.4	69.7	30.3	71.8	28.2	NS	NS
Constipation	76.9	23.1	72.7	27.3	78.8	21.2	NS	NS
Diarrhea	76.9	23.1	78.8	21.2	83.5	16.5	NS	NS
Financial problems	*88.5*	*11.5*	*63.6*	*36.4*	*62.4*	*37.6*	*0.030/0.283*	*0.012/0.238*
HN pain	53.8	46.2	42.4	57.6	40.0	60.0	NS	NS
HN speech	*73.1*	*26.9*	*33.3*	*66.7*	*45.9*	*54.1*	*0.002/0.395*	*0.015/0.231*
HN social eating	*65.4*	*34.6*	*27.3*	*72.7*	*25.9*	*74.1*	*0.003/0.381*	*<0.001/0.350*
HN social contact	76.9	23.1	51.5	48.2	60.0	40.0	*0.045/0.261*	NS
HN teeth*	68.0	32.0	53.3	46.7	57.0	43.0	NS	NS
HN opening mouth*	*72.0*	*28.0*	*43.3*	*56.7*	*44.3*	*55.7*	*0.033/0.288*	*0.016/0.237*
HN sticky saliva*	*72.0*	*28.0*	*26.7*	*73.3*	*29.1*	*70.9*	*0.001/0.470*	*<0.001/0.375*
HN coughed*	52.0	48.0	50.0	50.0	*41.8*	*58.2*	NS	NS
HN felt ill*	72.0	28.0	80.0	20.0	73.4	26.6	NS	NS
HN pain killers	61.5	38.5	66.7	33.3	54.1	45.9	NS	NS
HN feeding tube	88.5	11.5	90.0	10.0	91.8	8.2	NS	NS
HN weight loss	76.9	23.1	83.3	16.7	85.9	14.1	NS	NS
HN weight gain	*73.1*	*26.9*	83.3	16.7	*89.4*	*10.6*	NS	*0.045/−0.200*

*Items were calculated with a total of 7 missings. This is due to a systematic error described more closely in Materials and Methods section.
NS: results are statistically not significant.

Table 6: Comparing OP with OPRT and OP + adj—scale group 3 (percent within therapy group).

Item	Median score	OP		OPRT		OP + adj		OP versus OPRT	OP versus OP + adj
		<Median	≥Median	<Median	≥Median	<Median	≥Median	*P*/Phi	*P*/Phi
Overall QOL	66.667	19.2	80.8	27.3	72.7	35.3	64.7	NS	NS
Physical function	93.33	*26.9*	*73.1*	*63.6*	*36.4*	48.2	51.8	*0.005/−0.307*	NS
Emotional function	83.33	30.8	69.2	51.5	48.5	48.2	51.8	NS	NS
Cognitive function	83.33	15.4	84.6	30.3	69.7	27.1	72.9	NS	NS
HN swallowing	*16.667*	*69.2*	*30.8*	*21.2*	*78.8*	*25.3*	*74.7*	*<0.001/0.482*	*<0.001/0.398*
HN senses	12.5	72.0	28	53.6	46.4	54.4	45.6	NS	NS
HN dry mouth	*66.67*	*72.0*	*28*	*16.7*	*83.3*	*29.1*	*70.9*	*<0.001/0.559*	*<0.001/0.375*

NS: results are statistically not significant.

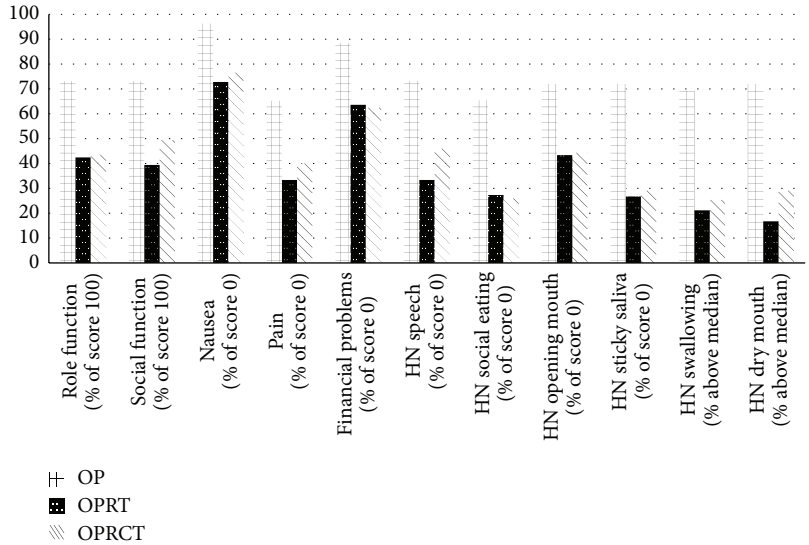

Figure 1: Statistically significant results.

such as tumor dimension of less than 2 cm and tumor depth of less than 5 mm surgery as a single modality treatment offers very good results in patients with pT1-2N0-1 OPC [3]. Another important aspect is the role of HPV infection in OPC. Since these patients are usually younger and have a better prognosis, desintensification of treatment is currently being discussed for this patient group [19, 20]. Therefore data on QOL of these patients compared to patients treated with surgery and adjuvant radio(chemo)therapy could play an important role in choosing the optimal treatment modality [11]. We hypothesized that the expected improvements in reported QOL when choosing surgery as the sole treatment option were due to not exposing patients to the side effects that may have been a consequence of additional treatments with radio- and/or chemotherapy. Furthermore this therapeutic tool could be preserved for cases of recurrence of second primary tumors, which are known to occur in up to 25% of patients. In particular, this study was aimed to look at surgery-only treatment versus two distinct groups: surgery combined with radiotherapy alone and surgery plus adjuvant therapies in general. For the purpose of this study, adjuvant therapies were either radiotherapy alone or in combination with chemotherapy.

Regardless of treatment modality, most patients report acceptable QOL outcomes. As is expected, the vast majority of complaints that do exist from long-term survivors of head and neck cancers focus on that specific region. Funk et al. identified that the functional aspects of eating and swallowing were most impacted by the disease [21]. The trend of these findings is supported by this study as well [22]. Patients treated with adjuvant therapies in particular show a similar complaint profile that highlights loss of oral functions. It is notable however that a large majority of OP-only patients do not express any complaints regarding the head and neck region in this particular sample set.

Using the general and H&N specific QOL-questionnaires of the EORTC to facilitate comparison between outcomes showed us statistically significant differential outcomes within nine of the measured scales, as illustrated in Figure 1. Six of these scales (HN speech, HN social eating, HN opening mouth, HN sticky saliva, HN swallowing, and HN dry mouth) are specific to the head and neck region while three (pain, nausea, and financial problems) are identified with the general section of the QOL-questionnaire. Scores in all nine mentioned scales favor surgery-only treatment as having the better outcome. The results for the physical function scale are less conclusive, but there is a clear trend towards significance.

Apart from a small cohort size, the main limitation of this study is the existence of numerous confounding factors, which cannot be eliminated. Treatment modality is only one variable that is responsible for patients' perceived QOL. Other factors that have been identified to impact QOL of OPC survivors are age, gender, marital status, comorbidities, malnutrition, and staging of the tumor [23]. These problems should be addressed with a prospective follow-up study with a larger cohort size.

5. Conclusion

Regardless of the treatment modality chosen for early stage OPC, overall quality of life as determined by "Global Health Status" of the QLQ-C30 can be considered good. Nonetheless, it becomes apparent that treatment via surgery alone has definite advantages over treatments including any form of adjuvant therapy. Even though these advantages manifest themselves especially in functional aspects of the head and neck realm, they are not exclusive to this region. General health aspects as well as psychosocial functions seem to be improved as well. In this study, there are no hints of a potential QOL-related drawback of surgery-only treatment approaches.

A continuation of this study to achieve larger sample sizes over the coming year is advisable in order to corroborate above findings and potentially discover further statistically significant differences between the treatment methods named.

Conflict of Interests

The authors declare that there is no conflict of interests regarding the publication of this paper.

Acknowledgment

The authors would like to extend their gratitude to Mr. Philipp Grundtner, Medical Data Manager, for the statistical analysis of the data. The authors acknowledge support by Deutsche Forschungsgemeinschaft and Friedrich-Alexander-Universität Erlangen-Nürnberg (FAU) within the funding programme Open Access Publishing.

References

[1] M. L. Gillison, "Current topics in the epidemiology of oral cavity and oropharyngeal cancers," *Head and Neck*, vol. 29, no. 8, pp. 779–792, 2007.

[2] R. Siegel, D. Naishadham, and A. Jemal, "Cancer statistics, 2012," *Cancer Journal for Clinicians*, vol. 62, no. 1, pp. 10–29, 2012.

[3] G. Psychogios, K. Mantsopoulos, A. Agaimy et al., "Prognostic factors in limited (T1-2, N0-1) oropharyngeal carcinoma treated with surgery +/- adjuvant therapy," *Head & Neck*, vol. 35, no. 12, pp. 1752–1758, 2013.

[4] S. E. Mowry, A. Ho, M. M. LoTempio, A. Sadeghi, K. E. Blackwell, and M. B. Wang, "Quality of life in advanced oropharyngeal carcinoma after chemoradiation versus surgery and radiation," *Laryngoscope*, vol. 116, no. 9, pp. 1589–1593, 2006.

[5] A. D. Karatzanis, G. Psychogios, F. Waldfahrer, J. Zenk, G. A. Velegrakis, and H. Iro, "Surgical management of T1 oropharyngeal carcinoma," *Head and Neck*, 2011.

[6] G. Psychogios, K. Mantsopoulos, J. Kuenzel et al., "Primary surgical treatment of T2 oropharyngeal carcinoma," *Journal of Surgical Oncology*, vol. 105, no. 7, pp. 719–723, 2012.

[7] A. S. Denittis, M. Machtay, D. I. Rosenthal et al., "Advanced oropharyngeal carcinoma treated with surgery and radiotherapy: oncologic outcome and functional assessment," *American Journal of Otolaryngology*, vol. 22, no. 5, pp. 329–335, 2001.

[8] P. Friedlander, S. Caruana, B. Singh et al., "Functional status after primary surgical therapy for squamous cell carcinoma of the base of the tongue," *Head and Neck*, vol. 24, no. 2, pp. 111–114, 2002.

[9] M. L. Robertson, L. L. Gleich, W. L. Barrett, and J. L. Gluckman, "Base-of-tongue cancer: survival, function, and quality of life after external-beam irradiation and brachytherapy," *Laryngoscope*, vol. 111, no. 8, pp. 1362–1365, 2001.

[10] A. C. Nichols, J. Yoo, J. A. Hammond et al., "Early-stage squamous cell carcinoma of the oropharynx: radiotherapy vs. trans-oral robotic surgery (ORATOR)—study protocol for a randomized phase II trial," *BMC Cancer*, vol. 13, article 133, 2013.

[11] M. A. Broglie, A. Soltermann, S. R. Haile et al., "Quality of life of oropharyngeal cancer patients with respect to treatment strategy and p16-positivity," *The Laryngoscope*, vol. 123, pp. 164–170, 2013.

[12] P. Boscolo-Rizzo, M. Stellin, R. Fuson, C. Marchiori, A. Gava, and M. C. D. Mosto, "Long-term quality of life after treatment for locally advanced oropharyngeal carcinoma: surgery and postoperative radiotherapy versus concurrent chemoradiation," *Oral Oncology*, vol. 45, no. 11, pp. 953–957, 2009.

[13] S. Tribius and C. Bergelt, "Intensity-modulated radiotherapy versus conventional and 3D conformal radiotherapy in patients with head and neck cancer: is there a worthwhile quality of life gain?" *Cancer Treatment Reviews*, vol. 37, no. 7, pp. 511–519, 2011.

[14] N. K. Aaronson, S. Ahmedzai, B. Bergman et al., "The European Organization for Research and Treatment of Cancer QLQ-C30: a quality-of-life instrument for use in international clinical trials in oncology," *Journal of the National Cancer Institute*, vol. 85, no. 5, pp. 365–376, 1993.

[15] K. Bjordal, E. Hammerlid, M. Ahlner-Elmqvist et al., "Quality of life in head and neck cancer patients: validation of the European Organization for Research and Treatment of Cancer Quality of Life Questionnaire-H and N35," *Journal of Clinical Oncology*, vol. 17, no. 3, pp. 1008–1019, 1999.

[16] U. Tschiesner, L. Schuster, S. Strieth, and U. Harréus, "Functional outcome in patients with advanced head and neck cancer: surgery and reconstruction with free flaps versus primary radiochemotherapy," *European Archives of Oto-Rhino-Laryngology*, vol. 269, no. 2, pp. 629–638, 2012.

[17] R. R. Walvekar, R. J. Li, W. E. Gooding et al., "Role of surgery in limited (T1-2, N0-1) cancers of the oropharynx," *Laryngoscope*, vol. 118, no. 12, pp. 2129–2134, 2008.

[18] H. Iro, K. Mantsopoulos, J. Zenk, F. Waldfahrer, and G. Psychogios, "Results of transoral laser resection in T1-2 oropharyngeal, hypopharyngeal and laryngeal carcinomas," *Laryngo-Rhino-Otologie*, vol. 90, no. 8, pp. 481–485, 2011.

[19] K. K. Ang and E. M. Sturgis, "Human Papillomavirus as a marker of the natural history and response to therapy of head and neck squamous cell carcinoma," *Seminars in Radiation Oncology*, vol. 22, no. 2, pp. 128–142, 2012.

[20] G. Psychogios, C. Alexiou, A. Agaimy et al., "Epidemiology and survival of HPV related tonsillar carcinoma," *Cancer Medicine*. In press.

[21] G. F. Funk, L. H. Karnell, and A. J. Christensen, "Long-term health-related quality of life in survivors of head and neck cancer," *Archives of Otolaryngology*, vol. 138, no. 2, pp. 123–133, 2012.

[22] T. Gunzel and M. Schimmer, "Quality of life after primary radiation/radiochemotherapy vs. operation therapy in an oropharyngeal cancer," *Laryngo-Rhino-Otologie*, vol. 91, pp. 451–459, 2012.

[23] K. Bjordal, M. Ahlner-Elmqvist, E. Hammerlid et al., "A prospective study of quality of life in head and neck cancer patients. Part II: longitudinal data," *Laryngoscope*, vol. 111, no. 8, pp. 1440–1452, 2001.

Hindawi Publishing Corporation
BioMed Research International
Volume 2014, Article ID 341876, 6 pages
http://dx.doi.org/10.1155/2014/341876

Research Article

Feasibility of Piezoelectric Endoscopic Transsphenoidal Craniotomy: A Cadaveric Study

Peter Valentin Tomazic,[1,2] Verena Gellner,[2,3] Wolfgang Koele,[1,2] Georg Philipp Hammer,[1] Eva Maria Braun,[1] Claus Gerstenberger,[1,2] Georg Clarici,[2,3] Etienne Holl,[2,3] Hannes Braun,[1,2] Heinz Stammberger,[1,2] and Michael Mokry[2,3]

[1] *Department of General Otorhinolaryngology, Head and Neck Surgery, Medical University of Graz, Auenbruggerplatz 26/28, 8036 Graz, Austria*
[2] *Rhinoneurosurgery Group, Medical University of Graz, 8036 Graz, Austria*
[3] *Department for Neurosurgery, Medical University of Graz, Auenbruggerplatz 29, 8036 Graz, Austria*

Correspondence should be addressed to Peter Valentin Tomazic; peter.tomazic@medunigraz.at and Verena Gellner; verena.gellner@medunigraz.at

Received 14 December 2013; Accepted 2 January 2014; Published 9 February 2014

Academic Editor: Jan Plzák

Objective. Endoscopic transsphenoidal approach has become the gold standard for surgical treatment of treating pituitary adenomas or other lesions in that area. Opening of bony skull base has been performed with burrs, chisels, and hammers or standard instruments like punches and circular top knives. The creation of primary bone flaps—as in external craniotomies—is difficult.The piezoelectric osteotomes used in the present study allows creating a bone flap for endoscopic transnasal approaches in certain areas. The aim of this study was to prove the feasibility of piezoelectric endoscopic transnasal craniotomies. *Study Design*. Cadaveric study. *Methods*. On cadaveric specimens ($N = 5$), a piezoelectric system with specially designed hardware for endonasal application was applied and endoscopic transsphenoidal craniotomies at the sellar floor, tuberculum sellae, and planum sphenoidale were performed up to a size of 3–5 cm^2. *Results*. Bone flaps could be created without fracturing with the piezoosteotome and could be reimplanted. Endoscopic handling was unproblematic and time required was not exceeding standard procedures. *Conclusion*. In a cadaveric model, the piezoelectric endoscopic transsphenoidal craniotomy (PETC) is technically feasible. This technique allows the surgeon to create a bone flap in endoscopic transnasal approaches similar to existing standard transcranial craniotomies. Future trials will focus on skull base reconstruction using this bone flap.

1. Introduction

Over the last two decades endoscopic transsphenoidal skull base approaches have become the gold standard in the surgical treatment of selected cases of pituitary adenomas and many other lesions in that area like meningiomas, chordomas, or craniopharyngiomas. However, there are still some indications for other surgical routes (transcranial, combined, etc.) in the treatment of such lesions. Extended approaches to the suprasellar and parasellar regions, planum sphenoidale, and the clivus were developed and the cooperation between ENT surgeons and Neurosurgeons was intensified [1–4]. After opening the sphenoid sinus through both natural ostia the bone of the skull base can be removed to expose and open the dura if required. The extent of bone removal is tailored to the size and localization of the lesion and can be modified for transtubercular, transplanum, and transcribiform approaches. For thick bone, burrs are used whereas thinner bone can be excised by classical punches. In our department the defect in skull base is reconstructed with hemostyptic material only or with fascia lata or even nasoseptal flaps in case of intraoperative CSF leak [5, 6]. Reconstruction as in transcranial craniotomies with osseous flaps cannot be achieved due to the preceding resection of the bone.

Figure 1: Piezoelectric handpiece suitable for endoscopic application.

Especially in endoscopic pituitary surgery a craniotomy harvesting a bone flap which can later be used for skull base reconstruction could be desirable to facilitate defect closure. Until now this was rarely possible, because with standard instruments the bone would either be excised, fractured, or turned to bone dust by burrs and drills.

The advent of piezosurgical techniques could also be implied in endoscopic transsphenoidal skull base surgery. The piezoelectric effect was first described by Jacques and Pierre Curie in 1880 implying that under a mechanical force certain crystalline minerals become electrically polarized. Gabriel Lippmann later described the converse piezoelectric effect: when one of these crystalline minerals is exposed to an electric field (alternating current, AC) it is lengthened and shortened according to the polarity of the field in proportion to the field strength (Volt/meter) and frequency (Hertz, Hz) [7]. High frequency oscillations of the piezoelectric crystals are used to "cut" bone that way like microsaws [8]. The advantage of this technique is that the cutting effect is reserved to hard, crystalline mineral that is structured like bone, soft tissue like dura would not be affected because of its elasticity, as long as no additional pressure is applied [9, 10].

Initially, Piezosurgery was mainly used by maxillofacial surgeons, but nowadays it is more frequently applied for craniotomies [9–11]. Nordera et al. used it for external orbital decompression in Basedow's disease [9].

As of today piezosurgery was never used in endoscopic transsphenoidal approaches to the pituitary or anterior skull base. To our knowledge, this is the first study on the feasibility of piezoelectric endoscopic transsphenoidal craniotomies (PETC) in cadaveric specimens.

2. Material and Methods

On five cadaveric specimens the piezoelectric osteotome (Synthes Gmbh Piezoelectric System, Satelec, Merignac cedex, France, CE 0459) with specially designed slim handpiece and tips for endoscopic approaches was used (Figure 1). The tip is 9 mm long and has a semicircular shape. with small prongs at its top. First, a classical endoscopic approach to the sphenoid sinus through the natural ostia with resection of the anterior sphenoid wall and the posterior superior septum was performed. After visualization and identification of the sellar floor, a mucosal flap was created to expose the bone. The flap was lateralized for later reposition. Then with a frequency of 28 kHz a bone flap in the sellar floor was created using the piezoelectric device under constant irrigation and endoscopic visualization. The mucosa or thinned out bone at one margin of the flap can be preserved to act as a fixation like in a swinging door and to further maintain nutrition of the bone flap (Figures 2(a)–2(d)). After the access to the sella, an extension of the approach to the sellar tuberculum and the sphenoidal plane was performed (Figures 3(a)–3(d)). Finally, a rectangular or hourglass shaped bone flap was created.

The device makes micromovements between 60 and 200 μm/s [10]. The tip was targeted in a 90° angle to the surface of the bone. Gentle longitudinal movements were performed with slight pressure. Duration for creating the bone flap was measured as well as temperature at the areas where the device had contact to the mucosa (thermal probes by (OMEGA HH501AJK, Sensotec, Feldkirchen/Graz, Austria).

The study was performed in accordance with the local institutional review board and the Institute of Anatomy of the Medical University of Graz.

3. Results

In 5 cadaveric specimens a bone flap could be created with appropriate size (~1 cm^2) for accessing the intrasellar space. Enlarging the flap for extended transtubercular/transplanum approaches up to a size of 3–5 cm^2 was possible without breaking the bone, which was repositioned after the intervention and covered by mucosa (Figure 4). In case of sellar access only, a mucosal or bony bridge (with bone thinned out by the piezotome) was preserved serving as a "swinging door." The dura was not injured by the piezoelectric osteotome. The loss of bone in the incision lines (<1 mm) was minimal. Throughout the procedure excellent endoscopic visualization could be achieved as constant irrigation had a cleansing effect of the surgical field. Both, the suction and the piezoelectric device could be maneuvered by a single surgeon with enough space for movements intranasally while a second surgeon was guiding the endoscope. No limitations regarding maneuverability were experienced and surgical freedom was not impaired as long as the endoscope's lens remained clean. The mucosal temperature at contact areas did not rise above the cadavers' original temperature (26°C). Duration for creating the bone flap in the sellar floor was around 3-4 minutes.

4. Discussion

Endoscopic transsphenoidal skull base surgery has become the gold standard for treating pituitary adenomas and various other pathological entities [2]. In most cases ENT surgeons and Neurosurgeons work together in a four-handed technique guiding the endoscope and manipulating instruments at the same time. The nose and paranasal sinuses are used as a corridor to access skull base. Until now exposure of the intracranial lesions requires resection of the bony skull base up to the required extent and incision of the dura. After the resection of the lesion the skull base needs to be reconstructed. In intra- and suprasellar pituitary adenomas where the sellar diaphragm stays intact reconstruction with with hemostyptic material only is sufficient in the majority of cases. In the forthcoming weeks the nasal mucosa will regrow

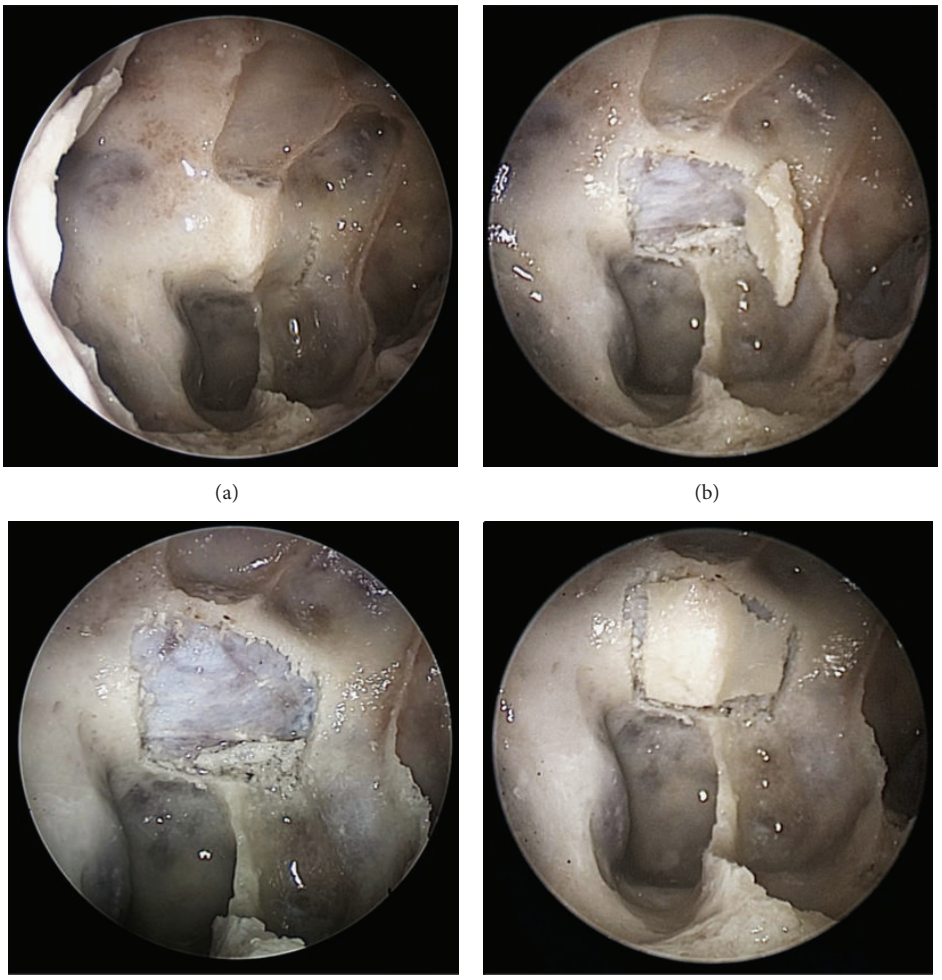

Figure 2: (a) Endoscopic view onto the sellar floor with the primary vertical incision performed on the left. (b) All four incisions are performed with a small bony bridge left for the bone flap to be tilted away like a swinging door. (c) Sellar floor with bone flap removed for demonstration of intact dura. (d) Repositioned bone flap.

over the defect. On occasions where the sellar diaphragm or the dura at skull base needs to be incised or even resected, reconstruction can be a problem and postoperative CSF leaks may occur. An elegant way to close large skull base defects is the creation of a nasoseptal flap described by Kassam et al. [6] and Fortes et al. [12]. However, the reconstruction as in external craniotomies by means of bone flaps is difficult to accomplish until now.

Apart from malignancies or meningiomas where infiltration of bone is possible and thus its resection is mandatory to obtain safe margins the solution would not be to resect the bone at skull base, but to create flaps as in external craniotomies. The only possibility to create bone flaps as of today would be by means of circular top knives in case of thin bone or hammer and chisel in thicker bone bearing the risk of uncontrolled bone fracturing and accidental injury of vascular and cerebral structures. Contrary to these instruments piezoelectric osteotomes with especially designed tips for endoscopic approaches could be used. This technology allows 28.000 micromovements per second of the piezocrystals that cut bone leaving soft tissue unharmed [9, 10]. The technique was mainly applied in maxillofacial surgery but was recently used for transcranial craniotomies too. Hollstein et al. [8] proved the feasibility of a variety of ultrasonic osteotomes on rabbits' skulls. With all devices thin, straight resection lines could be achieved which is a prerequisite for skull base craniotomies. Gleizal et al. [11] compared injuries of dura with piezosurgery and mechanical saws after craniotomy. Despite the fact that dural injury was reported in the past, the modification of tip design towards rounded edges overcomes this problem, and thus piezosurgery can be considered as safe in experienced hands. Nordera et al. [9] described external orbital decompression with piezosurgery which is advantageous in the vicinity of critical structures like optic nerve and bulb.

Another advantage described was the "cavitation effect" which creates bubbles and saturated steam in the irrigation liquid enhancing the mechanical properties of the device. Furthermore, this has a cleaning effect of the bone margins from blood [9].

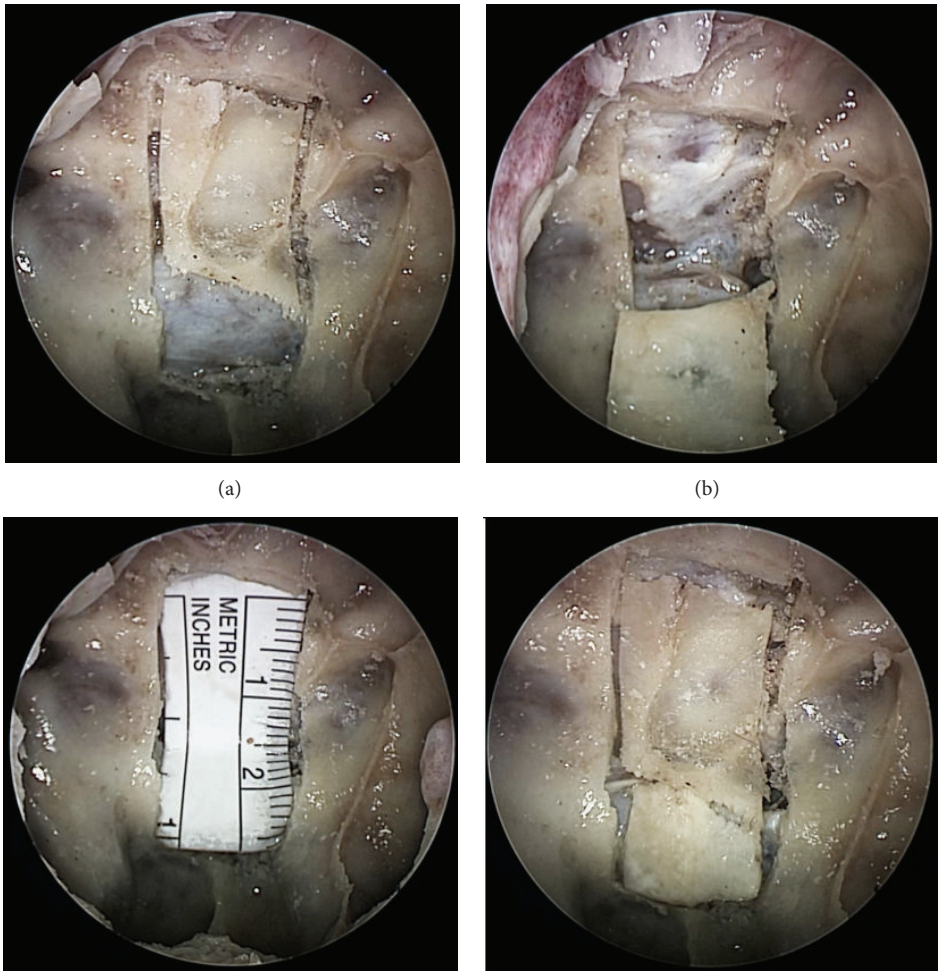

Figure 3: (a) Endoscopic view onto bone flap extended to a transplanum approach with all incisions performed, the sellar bone flap has. (b) Transplanum bone flap tilted inferiorly, a thinned out bone bridge was left at the inferior left corner to act as a door swing. (c) The transplanar bone flap is removed and a measuring scale was put as an "underlay" epidurally to visualize the size of the flap. (d) Both bone flaps are repositioned in the sella and sphenoidal plane, respectively.



Figure 4: Extracorporal view of the sellar bone flap (a) and both flaps (b) with a measuring scale.

A disadvantage of the technology is that the osteotomies take longer as compared to classical saws. This applies to thick bone whereas at skull base the bone is usually thin which would not have a negative effect on operating time [11]. Above this, saws up to now cannot be used endonasally alongside an endoscope. Moreover, the time spent for creation of a nasoseptal flap in large skull base defect reconstruction must be considered. However, after having undergone a learning curve for handling the instrument properly—which at the beginning was time consuming—the time measured in the present study did not relevantly prolong the procedure. Surgical freedom and maneuverability of instruments were not impaired in this series. Possible problems due to individual anatomical variations need to be assessed once this technique is applied clinically on large case series.

To rule out any thermal injury to the nasal mucosa along the corridor caused by the uncovered metal shaft of the piezoelectric instrument, temperature was measured in our study. It did not rise above physiological levels. Any temperature sensation perceived by the surgeon's hand was due to high frequency oscillations provoking a stimulus to temperature receptors of the skin and seized instantly after stopping the system. Measuring the handpiece did not reveal elevated temperatures.

To our knowledge this study is the first to use piezosurgery for endoscopic transnasal craniotomies and proves its feasibility in five cadaveric specimens. We created bone flaps with straight margins which stayed intact and could later be repositioned (Figure 2). The advantage is a reconstruction of the skull base comparable to standard transcranial craniotomies.

Further studies should be designed as an "in vivo" experiment to further evaluate the technique's safety and particularly postoperative healing a well as CSF leak rates. Hence, future trials will be targeted to clinical application of piezoelectric endoscopic transnasal craniotomies (PETCs) and the development of fixation techniques of the bone flap by means of, for example, microscrews, resorbable "rivets," or the application of the "gasket seal" procedure described by Garcia-Navarro et al. [13].

Once this technique is established for endoscopic transnasal skull base approaches a better stability of reconstruction and potential reduction of postoperative CSF leaks could be provided for the future.

5. Conclusion

The piezoelectric endoscopic transsphenoidal craniotomy (PETC) is feasible in a cadaveric model. By this technique a reconstruction of the anterior skull base comparable to transcranial approaches can be achieved. Clinical studies will be performed to prove this hypothesis and future developments should be targeted onto fixation of the bony graft in situ by means of novel fixation devices.

Disclosure

Heinz Stammberger and Michael Mokry should be considered as senior authors.

Conflict of Interests

The authors declare that there is no conflict of interests regarding the publication of this paper.

Authors' Contribution

Peter Valentin Tomazic and Verena Gellner contributed equally to this paper.

Acknowledgment

The authors would like to thank Vianney Ruellan from Satelec-Acteon Group, Merignac, France, for technical advice.

References

[1] D. S. Sethi and J.-L. Leong, "Endoscopic pituitary surgery," *Otolaryngologic Clinics of North America*, vol. 39, no. 3, pp. 563–583, 2006.

[2] V. J. Lund, H. Stammberger, P. Nicolai et al., "European position paper on endoscopic management of tumours of the nose, paranasal sinuses and skull base," *Rhinology. Supplement*, no. 22, pp. 1–143, 2010.

[3] S. Kurschel, V. Gellner, G. Clarici, H. Braun, H. Stammberger, and M. Mokry, "Endoscopic rhino-neurosurgical approach for non-adenomatous sellar and skull base lesions," *Rhinology*, vol. 49, no. 1, pp. 64–73, 2011.

[4] A. Alfieri, H.-D. Jho, and M. Tschabitscher, "Endoscopic endonasal approach to the ventral cranio-cervical junction: Anatomical study," *Acta Neurochirurgica*, vol. 144, no. 3, pp. 219–225, 2002.

[5] F. Tosun, R. L. Carrau, C. H. Snyderman, A. Kassam, S. Celin, and B. Schaitkin, "Endonasal endoscopic repair of cerebrospinal fluid leaks of the sphenoid sinus," *Archives of Otolaryngology*, vol. 129, no. 5, pp. 576–580, 2003.

[6] A. B. Kassam, A. Thomas, R. L. Carrau et al., "Endoscopic reconstruction of the cranial base using a pedicled nasoseptal flap," *Neurosurgery*, vol. 63, no. 1, supplement 1, pp. ONS44–ONS52, 2008.

[7] S. H. Jung, A. D. Ferrer, J. S. Vela, and F. A. Granados, "Spheno-orbital meningioma resection and reconstruction: the role of piezosurgery and premolded titanium mesh," *Cranial Maxillofac Trauma Reconstruction*, vol. 4, pp. 193–200, 2011.

[8] S. Hollstein, E. Hoffmann, J. Vogel, F. Heyroth, N. Prochnow, and P. Maurer, "Micromorphometrical analyses of five different ultrasonic osteotomy devices at the rabbit skull," *Clinical Oral Implants Research*, vol. 23, no. 6, pp. 713–718, 2012.

[9] P. Nordera, S. Spanio Di Spilimbergo, A. Stenico, U. Fornezza, L. Volpin, and E. Padula, "The cutting-edge technique for safe osteotomies in craniofacial surgery: the piezosurgery bone scalpel," *Plastic and Reconstructive Surgery*, vol. 120, no. 7, pp. 1989–1995, 2007.

[10] B. Kotrikova, R. Wirtz, R. Krempien et al., "Piezosurgery-a new safe technique in cranial osteoplasty?" *International Journal of Oral and Maxillofacial Surgery*, vol. 35, no. 5, pp. 461–465, 2006.

[11] A. Gleizal, J.-C. Bera, B. Lavandier, and J.-L. Beziat, "Piezoelectric osteotomy: a new technique for bone surgery—advantages in craniofacial surgery," *Child's Nervous System*, vol. 23, no. 5, pp. 509–513, 2007.

[12] F. S. G. Fortes, R. L. Carrau, C. H. Snyderman et al., "Transpterygoid transposition of a temporoparietal fascia flap: a new method for skull base reconstruction after endoscopic expanded endonasal approaches," *Laryngoscope*, vol. 117, no. 6, pp. 970–976, 2007.

[13] V. Garcia-Navarro, V. K. Anand, and T. H. Schwartz, "Gasket seal closure for extended endonasal endoscopic skull base surgery: efficacy in a large case series," *World Neurosurgery*, vol. 80, pp. 563–568, 2013.