Advances in Orthopedics

Degenerative Cervical Spondylosis: Natural History, Pathogenesis, and Current Management Strategies

Guest Editors: Joseph S. Butler, F. Cumhur Öner, Ashley R. Poynton, and John M. O'Byrne



Degenerative Cervical Spondylosis: Natural History, Pathogenesis, and Current Management Strategies

Advances in Orthopedics

Degenerative Cervical Spondylosis: Natural History, Pathogenesis, and Current Management Strategies

Guest Editors: Joseph S. Butler, F. Cumhur Öner, Ashley R. Poynton, and John M. O'Byrne

Editorial Board

Contents

Hindawi Publishing Corporation
Advances in Orthopedics
Volume 2012, Article ID 916987, 3 pages
doi:10.1155/2012/916987

Editorial

Degenerative Cervical Spondylosis: Natural History, Pathogenesis, and Current Management Strategies

Joseph S. Butler,[1] F. Cumhur Öner,[2] Ashley R. Poynton,[3] and John M. O'Byrne[1]

[1] *Department of Trauma and Orthopaedic Surgery, Royal College of Surgeons in Ireland, Cappagh National Orthopaedic Hospital, Finglas, Dublin 11, Ireland*
[2] *Department of Orthopaedic Surgery, University Medical Centre Utrecht, Heidelberglaan 100, 3584 CX Utrecht, The Netherlands*
[3] *Department of Orthopaedic & Spinal Surgery, Mater Private Hospital, Eccles Street, Dublin 7, Ireland*

Correspondence should be addressed to Joseph S. Butler, josephsbutler@hotmail.com

Received 29 July 2012; Accepted 29 July 2012

Degenerative cervical spondylosis is a common, mostly asymptomatic condition, occurring as a result of age-related degenerative changes in the cervical spine. Symptoms caused by cervical spondylosis can be categorized broadly into three clinical syndromes: axial neck pain, cervical radiculopathy, and cervical myelopathy; with patients commonly having a combination of these syndromes. This special issue contains eleven papers summarizing our present knowledge and understanding of the natural history, pathogenesis, and current management strategies for degenerative cervical spondylosis.

In the paper entitled "*The natural history and clinical syndromes of degenerative cervical spondylosis*," J. C. Kelly et al. outline the three clinical syndromes of axial neck pain, cervical radiculopathy, and cervical myelopathy. Radiographic evidence of spondylotic changes is frequently found in many asymptomatic adults. The majority of symptomatic patients present between the ages of 40 and 60, with men more commonly affected than women at a ratio of 3 : 2. Disc degeneration and bulging, osteophyte and spur formation, ligamentous hypertrophy, vertebral subluxation, decreased disc height, and facet joint arthropathy may all contribute to narrowing of the spinal canal and intervertebral foramina. Radiculopathy is a result of intervertebral foramina narrowing. Narrowing of the spinal canal results in spinal cord compression, ultimately resulting in cervical myelopathy. The course of disease development and the ultimate prognosis for patients with cervical spondylosis is highly variable and extremely difficult to predict.

In the paper entitled "*The natural history and clinical presentation of cervical spondylotic myelopathy*," C. K. Yarbrough et al. describe cervical spondylotic myelopathy as an impaired function of the spinal cord caused by degenerative changes of the cervical spine resulting in spinal cord compression. While many patients with mild signs of cervical spondylotic myelopathy will stabilize or improve over time with conservative management, the clinical course of a specific individual patient cannot be predicted. Asymptomatic patients with cervical stenosis and abnormalities on electrophysiologic studies may be at higher risk for developing myelopathy.

L. A. Ferrara identifies aging as the major risk factor contributing to the onset of cervical spondylosis in the paper "*The biomechanics of cervical spondylosis*." Several acute and chronic symptoms can occur that start with neck pain and may progress into cervical radiculopathy. Eventually, the degenerative cascade causes desiccation of the intervertebral disc resulting in height loss of the cervical spine. This causes ventral angulation and eventual loss of lordosis, with compression of the neural and vascular structures. The altered posture of the cervical spine progresses into kyphosis if the load balance and lordosis is not restored.

C. Green et al. in their paper entitled "*Imaging modalities for cervical spondylotic stenosis and myelopathy*," highlight the

central role of diagnostic imaging in clinical diagnosis and preoperative planning. Magnetic resonance imaging (MRI) provides the greatest range of information compared with other radiological studies available to evaluate the spine. It provides an accurate morphological assessment of both osseous and soft tissue structures including intervertebral discs, spinal ligaments, and the neural elements. Dynamic weight-bearing MRI has recently been championed as the preferred technique for pathology-specific diagnosis. Computed tomography in isolation lacks the soft tissue detail achieved with MRI scanning, however, is still a useful modality when there is a contraindication to MRI and where metal artefact is obstructing the anatomy. CT myelography is an invasive procedure, associated with a number of risks, and is only used for patients with contraindications, equivocal findings, or failed MR imaging because of metal artefact.

In the paper entitled "*Nonoperative modalities to treat symptomatic cervical spondylosis*," K. M. Hirpara et al. state that cervical spondylosis is a common and disabling condition. It is generally felt that the initial management should be nonoperative, and these modalities include physiotherapy, analgesia, and selective nerve root injections. Surgery should be reserved for moderate to severe myelopathy patients who have failed a period of conservative treatment and patients whose symptoms are not adequately controlled by nonoperative means. The authors conclude that effective, nonoperative treatment is labour intensive, requiring regular review and careful selection of medications and physical therapy on a case-by-case basis.

Yalamanchili et al. describe in their paper "*Cervical spondylotic myelopathy: factors in choosing the surgical approach*," the variety of surgical options that exist, including anterior and posterior approaches with and without fusion. Systematic review does not clearly show one technique to be clinically superior to another. Therefore decision-making depends on individual patient factors and associated approach-related complications. Factors to consider include location of cord compression, number of levels involved, sagittal alignment, instability, associated axial neck pain, and risk factors for pseudoarthrosis.

The paper entitled "*Operative techniques for cervical radiculopathy and myelopathy*," R. G. Kavanagh et al. state that surgical decompression can be achieved through a multitude of procedures using either an anterior or posterior approach. The main procedures that are performed through an anterior approach are anterior cervical discectomy and corpectomy, and those carried out through a posterior approach are laminoplasty, laminectomy, and posterior cervical discectomy. The type of procedure carried out is dependent on a number of different variables including extent and location of pathology, previous surgery, congenital canal stenosis, and the presence of preoperative axial neck pain. Satisfactory surgical outcome will result in long-term amelioration of cervical radiculopathic and myelopathic symptoms with few postoperative complications.

The paper entitled "*Operative techniques for cervical radiculopathy and myelopathy*," C. Moran and C. Bolger. suggest that surgical outcome is dependent on selecting the appropriate treatment for the appropriate patient and pathology. Once the decision is made to manage the patient operatively, the principal decision is whether to choose the ventral or the dorsal approach. In cervical spondylosis, several variables including the location of pathology (ventral, dorsal, circumferential), extent of pathology (limited to interspace, extensive behind vertebral body), the number of levels affected, the presence of instability or the presence of kyphotic deformity require consideration. In general, any procedure chosen should decompress the affected spinal cord or nerve roots, maintain or restore stability, and correct or prevent kyphotic deformity.

B. A. Braly et al. describe the technique of laminoplasty as a motion-sparing posterior decompressive method in "*Operative treatment of cervical myelopathy: cervical laminoplasty*." The authors describe the techniques of open-door or "hinged" laminoplasty. Laminoplasty or decompression, with retention of the posterior elements, offers the surgeon multiple advantages as a treatment option. The idea of a motion-sparing technique is the largest benefit when comparing laminoplasty to laminectomy and posterior fusion. Although complications may still occur and special care must be paid to patient selection, laminoplasty is a viable option to consider when treating patients with cervical myelopathy.

In the paper entitled "*Laminoplasty techniques for the treatment of multilevel cervical stenosis*," L. K. Mitsunaga et al. state that laminoplasty is becoming an increasingly popular technique for the treatment of multilevel cervical stenosis due to cervical spondylotic myelopathy, OPLL, and other causes. It minimizes the risk of certain complications associated with other surgical options, such as graft and fusion-related complications, postoperative kyphosis and instability, and the morbidity of an anterior approach. It does, however, have its own set of potential complications, including laminar closure, axial neck pain, nerve root palsies, and loss of cervical motion and alignment. Laminoplasty techniques are continuously being refined to address such potential shortcomings. Outcomes from laminoplasty are at least as good as anterior decompression and fusion or laminectomy and fusion. In the appropriate patient and with proper surgical technique, laminoplasty is a good option for patients with multilevel cervical stenosis and myeloradiculopathy.

In the paper entitled "*Operative outcomes for cervical myelopathy and radiculopathy*," J. G. Galbraith et al. state that when considering surgical outcomes for cervical myelopathy, it is important to remember that regardless of surgical technique employed, results of operative treatment generally are better in patients who undergo early decompression. Patients with less than a one-year duration of symptoms show significantly greater motor recovery following operation than did those with a longer duration of symptoms. Conversely, the symptoms for most patients with degenerative cervical radiculopathy will be self-limited and will resolve spontaneously over a variable length of time without specific treatment. Surgical intervention, however, can lead to rapid relief of symptoms of cervical radiculopathy compared to conservative measures alone. At present, there is insufficient evidence to indicate whether anterior or posterior surgery

yields superior short- and long-term results for either cervical myelopathy or radiculopathy.

We expect that this special issue will help the surgeons to make sound decisions on the treatment of these increasingly common problems in our rapidly aging population.

Joseph S. Butler
F. Cumhur Öner
Ashley R. Poynton
John M. O'Byrne

Hindawi Publishing Corporation
Advances in Orthopedics
Volume 2012, Article ID 508534, 5 pages
doi:10.1155/2012/508534

Review Article

Operative Treatment of Cervical Myelopathy: Cervical Laminoplasty

Brett A. Braly,[1] David Lunardini,[1] Chris Cornett,[2] and William F. Donaldson[1]

[1] *Univeristy of Pittsburgh Medical Center, Pittsburgh, PA, USA*
[2] *University of Nebraska Medical Center, Omaha, NE, USA*

Correspondence should be addressed to Brett A. Braly, brett.braly@gmail.com

Received 2 August 2011; Accepted 28 March 2012

Academic Editor: Joseph S. Butler

Cervical spondylotic myelopathy (CSM) is a degenerative process which may result in clinical signs and symptoms which require surgical intervention. Many treatment options have been proposed with various degrees of technical difficulty and technique sensitive benefits. We review laminoplasty as a motion-sparing posterior decompressive method. Current literature supports the use of laminoplasty for indicated decompression. We also decribe our surgical technique for an open-door, or "hinged", laminoplasty.

1. Introduction

Cervical spondylotic myelopathy (CSM) is the natural result of degenerative compression on the cervical spinal cord. The result may be a progressive and stepwise deterioration of neurological function in patients. The chronic debilitating nature of this process justifies surgical decompression. Posterior decompression has been described as a treatment for CSM since the 1940s. Laminectomy was the initial surgical option used. The decompression was performed by rongeurs. However, the insertion of the rongeur in an already limited space available for the cord led often to a decrease in neurological function postoperatively [1–3]. Even with modern approaches to laminectomy using high speed burs, development of postoperative instability has led surgeons to explore more efficacious ways of decompression.

In 1977, Hirabayashi and Satomi published their results on multisegment decompression by means of an open-door laminoplasty [4]. This technique allows for adequate posterior decompression of the spinal cord while retaining the posterior elements. This avoids the postoperative instability seen with laminectomy as well as the stiffness and risks of posterior cervical fusion. Additionally, motion is spared due to the absence of a fusion. There have since been multiple techniques for performing a cervical laminoplasty described with supporting literature [4–8]. These techniques include the expansive "open door," a midline "French Door," *En Bloc* resection, spinous process splitting, and Z-Plasty [4, 9]. Outcome studies have supported laminoplasty as a valid treatment for CSM however, no definitive literature shows its superiority to laminectomy in conjunction with a posterior cervical fusion. All surgical strategies appear to be equal in yielding neurologic outcomes, though differences are found in complication reports.

Patient selection is crucial prior to proceeding with cervical laminoplasty. Special attention must be paid to sagittal alignment for optimal outcomes. Laminoplasty is ideal for multilevel stenosis (AP canal diameter < 13 mm) due to spondylosis or ossification of the posterior longitudinal ligament (OPLL) [10].

Posterior cervical decompression, either by laminoplasty or laminectomy/fusion, carries inherent risks. Laminoplasty has been associated with postoperative C5 palsy, persistent axial neck pain, and some loss of range of motion [10–13].

2. Patient Selection, Indications, and Contraindications

Several factors must be considered in selecting the appropriate patient for laminoplasty. As mentioned, cervical laminoplasty is indicated for multilevel stenosis (AP canal

Figure 1: Lateral radiograph of the cervical spine in a patient who underwent laminoplasty. Note that there is an overall lordotic alignment which will allow for posterior drift once a posterior decompression is performed.

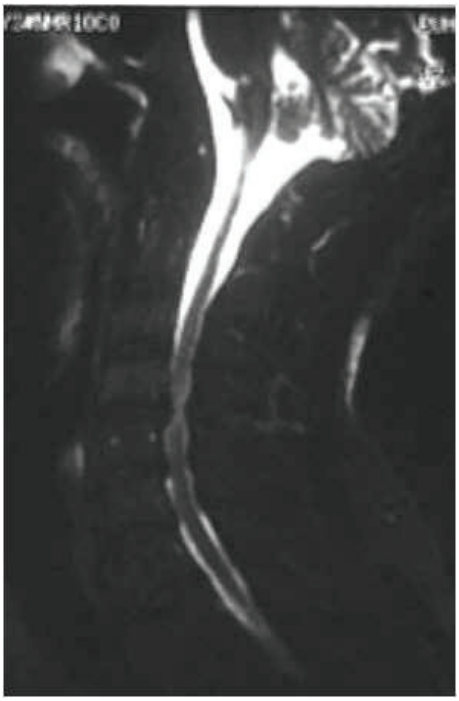

Figure 2: Lateral T2-weighted MRI of the cervical spine denoting significant spondylotic changes.

diameter < 13 mm) due to spondylosis or OPLL (Figures 1, 2, and 3). The procedure is generally contraindicated in kyphotic cervical pathology as there is less room for posterior drift of the cord; however, up to 10 degrees of cervical kyphosis has been shown to have acceptable results [11, 12, 14]. Further contraindications include previous

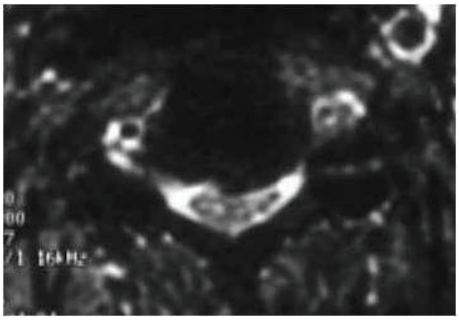

Figure 3: Axial T2 cervical spine denoting spondylotic changes and cord impingement.

posterior cervical surgery, ossification of the ligamentum flavum (OLF), and epidural fibrosis. Preservation of the posterior elements allows for reinsertion of the nuchal muscles and spinal ligaments, allowing for better preservation of lordosis. Single- or two-level stenosis may best be treated from an anterior approach.

Although there is a resultant loss of cervical ROM, it is less incumbent than that seen with laminectomy and fusion, and therefore preservation of ROM in young patients may lead surgeons to recommend laminoplasty. If significant arthritis and/or axial neck pain is present, however, laminoplasty may not be the best option as a fusion may provide better relief through stability. Additionally, any preoperative evidence of cervical instability may be a contraindication to laminoplasty.

A final disadvantage to laminoplasty is that nerve root decompression is more readily done successfully on the side of the open door and much more difficult to complete on the hinge side. Therefore, patients with myelopathy and bilateral radiculopathy may be better treated by other decompression options.

3. Surgical Technique

Of the various techniques described for achieving decompression by means of laminoplasty, no one technique has been shown to have better results over others. The technique we employ is similar to the originally described expansive open-door of Hirabayashi and will be described here.

4. Room Setup/Patient Preparation

As a posterior exposure of the cervical spine requires that patients lie prone, the anesthesia team must be experienced in managing access and endotracheal intubation in this position. Neurophysiologic monitoring should be considered for patients undergoing posterior cervical decompression. We use somatosensory-evoked potentials with care to determine baselines prior to prone positioning. Most patients receive arterial line monitoring, and we try to keep the patients mean arterial pressure at around 80–85 mm Hg to safely maintain cord perfusion.

Once anesthesia is prepared, Mayfield tongs are applied to the patients head, the patient is transferred prone to the surgical bed, and the tongs secured to the Mayfield attachment. The neck is flexed to a position which is comfortable by the patient as demonstrated preoperatively. This limits overlap in the posterior laminae and aids in reducing the facets. We prefer to tuck the arms and tape down the shoulders to improve visualization with intraoperative radiographs; however, care must be taken not to overly stretch the brachial plexus. The bed is placed in 10–20 degrees of reverse trendelenburg to allow for improved access as well as decreased intraoperative bleeding.

5. Surgical Technique

The patient is then prepped and draped in sterile fashion, the spinous processes are palpated to estimate levels, and a midline incision is made. Electrocautery is used to carry the incision deeply and expose the spinous processes, laminae and lateral masses of the desired levels, with care to preserve the facet capsules as well as the supraspinous and interspinous ligaments, as well as the interspinalis muscles. Localization can be confirmed by a lateral radiograph intraoperatively.

The junction of the laminae with the lateral mass is identified bilaterally. The hinge is placed at this level. We prefer to place the hinge on the less symptomatic side, allowing for better decompression and easier foraminotomies of the more symptomatic side. The ligamentum flavum is taken down at the proximal and distal ends of the laminoplasty, usually C3 and C7, but left intact throughout the other levels. Using a fine tip bipolar, usually the epidural veins can be carefully coagulated as you take down the ligamentum flavum. A high speed burr is used to create a bicortical defect on the open door side just medial to the junction of the lamina and lateral mass. Completing the open side first gives the surgeon feedback as to the thickness of the lamina for preparation of the hinge side. The burr is then used to make a unicortical defect in each lamina on the hinge side. The spinous processes are tilted gently toward the hinge allowing for opening of the door, and a Kerrison rongeur is used to take down the remaining ligamentum flavum at each level.

Fixating the door open can be done by a variety of techniques including bone block, suture, suture anchors, facial trauma plates, or laminoplasty specific plates (Figure 4). We then prefer to shorten the spinous processes with a rongeur, especially at the C6-7 level, to facilitate skin closure and decrease a postoperative prominence. The spinous processes can be shortened earlier in the procedure, though they may be helpful in opening the hinge.

A meticulous closure is done prior to leaving the operative field. We thoroughly irrigate the wound and stop all visable bleeding with cautery. A subfascial drain is placed, and the fascia is approximated with number 2 absorbable figure of eight stitches. The dermis is closed with 2–0 absorbable buried interrupted stitches, and the final skin is closed with a running subcuticular absorbable stitch. This technique should allow for adequated creating of space available for the cord (Figures 5 and 6).

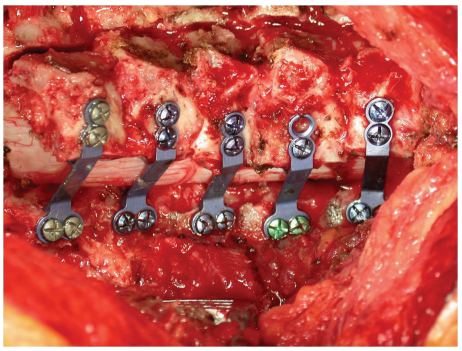

Figure 4: Post-laminoplasty view using plate fixation to hold the posterior hinge open.

Figure 5: Post-laminoplasty MRI showing the space available for the cord created by the posterior decompression.

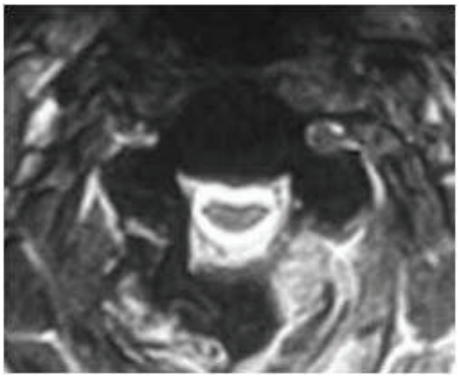

Figure 6: Post-laminoplasty MRI showing the open hinge and space available for the cord created by the decompression.

Postoperatively, we place patients in a cervical orthosis for 4 weeks. The type of orthosis, or need for one at all, is a matter of surgeon preference. A soft collar for comfort only can be appropriate, and long-term rigid bracing certainly is not required. Current evidence suggests that a shorter period of immobilization and quicker return to motion may decrease the postoperative neck discomfort and help prevent range of motion loss [15].

6. Outcomes

Although it has limitations, the most comprehensive method of assessing the degree of impairment secondary to myelopathy is likely the Japanese Orthopaedic Association (JOA) score, with higher scores indicating better patient status and lower scores representing poorer patient status. Multiple studies reviewing laminoplasty have shown increases in the JOA by 55–65% [4–8]. Handa et al. [16] reported on 61 patients treated with the open-door technique which showed increase in recovery as well as JOA scores at one year. Their group was stratified by age (older versus younger than 70 years), and both groups showed improvement (62% and 59%, resp.). When cohorts are stratified by diagnosis, there is also a difference. Miyazaki and colleagues [17] reported more improvement when laminoplasty was performed for OPLL than for CSM (87% versus 76%, resp.). Interestingly, when laminoplasty was combined with a posterolateral fusion, the improvement scores for CSM surpassed those for OPLL, indicating that postoperative instability has some effect on outcomes.

When compared with other operative techniques for CSM, laminoplasty has been shown to be as effective in relieving symptoms. Heller et al. [18] reported no statistical difference in outcomes between laminoplasty or laminectomy and fusion, but noted a 2-fold decrease in the range of motion after laminectomy and fusion. Our series found no statistical difference between laminectomy and fusion and laminoplasty; however, there was a trend toward better functional and subjective scores in the laminectomy/fusion cohort [19].

Long-term results have further shown the effectiveness of laminoplasty. Miyazaki et al. [17] reported on patients at greater than 12-year followup and showed that the benefits of laminoplasty were maintained. Seichi et al. [20] further confirmed this in their report of 91% stability in their outcomes over 10 years in patients with CSM decompressed by laminoplasty. This was in contrast to an 81% maintenance of outcomes in patients diagnosed with OPLL decompressed with laminoplasty.

7. Complications

The postoperative complications for laminoplasty are similar to those of other posterior decompression techniques. Some have advocated that there is a larger incidence of wound complications and poor healing presumably due to the increased tension created by the mass effect of elevating the posterior structures [15]. It is for this reason that we commonly debulk the more pronounced spinous processes prior to wound closure.

Literature review of laminoplasty reveals two main issues associated with laminoplsty: nerve root palsy (specifically C5) and axial neck pain.

A motor dominant C5 root palsy may result after laminoplasty in 5–11% of cases [10, 11, 13]. This usually occurs on post-operative day two or three and is not commonly seen immediately postoperatively. C5 is most often involved, though C6, C7, and rarely C8 root palsies have been described [15]. These motor root palsies are not unique to laminoplasty. This complication has also been reported after laminectomy and fusion or anterior decompression and fusion procedures for the same diagnoses. Sodeyama and associates reported on postlaminoplasty patients evaluated with CT myelograms who showed a mean posterior drift of 3 mm [21, 22] at the level of C5. It is hypothesized that a mechanical tethering of the nerve root in the foramina in the presence of posterior cord migration may put the C5 root under stretch and cause the palsy [23–25], though this theory does not fully explain why a C5 palsy may occur after an anterior decompression as well.

Though range of motion may decrease by 17–50%, the loss is less than that after laminectomy and fusion [10, 11], although stiffness postlaminectomy/fusion is often downplayed as a complication as it is a goal of fusion surgery.

8. Summary

Cervical spondylotic myelopathy is a progressive decline in the ability of the cervical spine to function properly. The natural history would suggest a continuous decline in neurological function which can ultimately become debilitating for patients. Current treatment theory suggests that a thorough decompression of the spinal canal can aid in preventing this decline.

Laminoplasty, or decompression with retention of the posterior elements, offers a surgeon multiple advantages as a treatment option. The idea of a motion-sparing technique is the largest benefit when comparing laminoplasty to a laminectomy and posterior fusion. Although complications may still occur and special care must be paid to patient selection, laminoplasty is a viable option to consider when treating patients with CSM.

References

[1] H. H. Bohlman, "Cervical spondylosis with moderate to severe myelopathy," *Spine*, vol. 2, no. 2, pp. 151–162, 1977.

[2] J. J. Graham, "Complications of cervical spine surgery," in *The Cervical Spine*, H. H. Shard et al., Ed., pp. 831–837, J. B. Lippincott, Philadelphia, Pa, USA, 2nd edition, 1989.

[3] F. H. Mayfield, "Complications of laminectomy," *Clinical Neurosurgery*, vol. 23, pp. 435–439, 1976.

[4] K. Hirabayashi and K. Satomi, "Operative procedure and results of expansive open-door laminoplasty," *Spine*, vol. 13, no. 7, pp. 870–876, 1988.

[5] C. C. Edwards, J. G. Heller, and D. H. Silcox, "T-saw laminoplasty for the management of cervical spondylotic myelopathy: clinical and radiographic outcome," *Spine*, vol. 25, no. 14, pp. 1788–1794, 2000.

[6] M. Iwasaki, S. Ebara, S. Miyamoto, E. Wada, and K. Yonenobu, "Expansive laminoplasty for cervical radiculomyelopathy due to soft disc herniation: a comparative study of laminoplasty and anterior arthrodesis," *Spine*, vol. 21, no. 1, pp. 32–38, 1996.

[7] S. I. Kihara, T. Umebayashi, and M. Hoshimaru, "Technical improvements and results of open-door expansive laminoplasty with hydroxyapatite implants for cervical myelopathy," *Neurosurgery*, vol. 57, no. 4, pp. 348–355, 2005.

[8] Y. Saruhashi, S. Hukuda, A. Katsuura, K. Miyahara, S. Asajima, and K. Omura, "A long-term follow-up study of cervical spondylotic myelopathy treated by 'French window' laminoplasty," *Journal of Spinal Disorders*, vol. 12, no. 2, pp. 99–101, 1999.

[9] J. K. Ratliff and P. R. Cooper, "Cervical laminoplasty: a critical review," *Journal of Neurosurgery*, vol. 98, no. 3, pp. 230–238, 2003.

[10] P. G. Matz, P. A. Anderson, M. W. Groff et al., "Cervical laminoplasty for the treatment of cervical degenerative myelopathy," *Journal of Neurosurgery*, vol. 11, no. 2, pp. 157–169, 2009.

[11] M. P. Steinmetz and D. K. Resnick, "Cervical laminoplasty," *Spine Journal*, vol. 6, no. 6, pp. S274–S281, 2006.

[12] K. S. Suk, K. T. Kim, J. H. Lee, S. H. Lee, Y. J. Lim, and J. S. Kim, "Sagittal alignment of the cervical spine after the laminoplasty," *Spine*, vol. 32, no. 23, pp. E656–E660, 2007.

[13] S. Imagama, Y. Matsuyama, Y. Yukawa et al., "C5 palsy after cervical laminoplasty: a multicentre study," *Journal of Bone and Joint Surgery—Series B*, vol. 92, no. 3, pp. 393–400, 2010.

[14] K. Uchida, H. Nakajima, R. Sato et al., "Cervical spondylotic myelopathy associated with kyphosis or sagittal sigmoid alignment: outcome after anterior or posterior decompression—clinical article," *Journal of Neurosurgery*, vol. 11, no. 5, pp. 521–528, 2009.

[15] K. Yoneunobu, E. Wada, and K. Ono, "Treatment of cervical myelopathy. Part B: laminoplasty," in *The Cervical Spine*, C. R. Clark et al., Ed., pp. 1057–1071, Lippincott Williams & Wilkins, Philadelphia, Pa, USA, 4th edition, 2005.

[16] Y. Handa, T. Kubota, H. Ishii, K. Sato, A. Tsuchida, and Y. Arai, "Evaluation of prognostic factors and clinical outcome in elderly patients in whom expansive laminoplasty is performed for cervical myelopathy due to multisegmental spondylotic canal stenosis. A retrospective comparison with younger patients," *Journal of Neurosurgery*, vol. 96, no. 2, pp. 173–179, 2002.

[17] K. Miyazaki, E. Hirohuji, S. Ono et al., "Extensive simultaneous multisegmental laminectomy and posterior decompression with posterolateral fusion," *The Journal of the Japanese Spine Research Society*, vol. 5, article 167, 1994 (Japanese).

[18] J. G. Heller, C. C. Edwards, H. Murakami, and G. E. Rodts, "Laminoplasty versus laminectomy and fusion for multilevel cervical myelopathy: an independent matched cohort analysis," *Spine*, vol. 26, no. 12, pp. 1330–1336, 2001.

[19] B. I. Woods, J. Hohl, J. Lee, W. Donaldson, and J. Kang, "Laminoplasty versus laminectomy and fusion for multilevel cervical spondylotic myelopathy," *Clinical Orthopaedics and Related Research*, vol. 469, no. 3, pp. 688–695, 2011.

[20] A. Seichi, K. Takeshita, I. Ohishi et al., "Long-term results of double-door laminoplasty for cervical stenotic myelopathy," *Spine*, vol. 26, no. 5, pp. 479–487, 2001.

[21] I. Aita, K. Hayashi, Y. Wadano, and T. Yabuki, "Posterior movement and enlargement of the spinal cord after cervical laminoplasty," *Journal of Bone and Joint Surgery—Series B*, vol. 80, no. 1, pp. 33–37, 1998.

[22] T. Sodeyama, S. Goto, M. Mochizuki, J. Takahashi, and H. Moriya, "Effect of decompression enlargement laminoplasty for posterior shifting of the spinal cord," *Spine*, vol. 24, no. 15, pp. 1527–1532, 1999.

[23] N. Tsuzuki, L. Zhogshi, R. Abe, and K. Saiki, "Paralysis of the arm after posterior decompression of the cervical spinal cord. I. Anatomical investigation of the mechanism of paralysis," *European Spine Journal*, vol. 2, no. 4, pp. 191–196, 1993.

[24] N. Tsuzuki, R. Abe, K. Saiki, and K. Okai, "Paralysis of the arm after posterior decompression of the cervical spinal cord. II. Analyses of clinical findings," *European Spine Journal*, vol. 2, no. 4, pp. 197–202, 1993.

[25] K. Yonenobu, N. Hosono, M. Iwasaki, M. Asano, and K. Ono, "Neurologic complications of surgery for cervical compression myelopathy," *Spine*, vol. 16, no. 11, pp. 1277–1282, 1991.

Hindawi Publishing Corporation
Advances in Orthopedics
Volume 2012, Article ID 307916, 15 pages
doi:10.1155/2012/307916

Review Article

Laminoplasty Techniques for the Treatment of Multilevel Cervical Stenosis

Lance K. Mitsunaga, Eric O. Klineberg, and Munish C. Gupta

Department of Orthopaedic Surgery, University of California Davis Medical Center, 4860 Y Street, Suite 1700, Sacramento, CA 95817, USA

Correspondence should be addressed to Lance K. Mitsunaga, lance.mitsunaga@ucdmc.ucdavis.edu

Received 15 July 2011; Accepted 14 November 2011

Academic Editor: Joseph S. Butler

Laminoplasty is one surgical option for cervical spondylotic myelopathy. It was developed to avoid the significant risk of complications associated with alternative surgical options such as anterior decompression and fusion and laminectomy with or without posterior fusion. Various laminoplasty techniques have been described. All of these variations are designed to reposition the laminae and expand the spinal canal while retaining the dorsal elements to protect the dura from scar formation and to preserve postoperative cervical stability and alignment. With the right surgical indications, reliable results can be expected with laminoplasty in treating patients with multilevel cervical myelopathy.

1. Introduction

While multilevel cervical stenosis may occur for a variety of reasons, it is usually due to cervical spondylosis or ossification of the posterior longitudinal ligament (OPLL). Options for decompression of the canal include either anterior or posterior approaches. For multilevel disease, most surgeons prefer posterior decompression. Posterior decompression has the advantage of addressing multiple levels with one incision. However, this approach is hindered by the late complication of kyphosis with decompression alone or the loss of motion and adjacent segment degeneration if posterior decompression is performed in conjunction with fusion [1, 2]. Laminoplasty is a technique that indirectly decompresses the spinal cord and preserves neck motion by avoiding fusion. This is accomplished by hinging the laminae open on one or both sides to allow the spinal cord to migrate posteriorly away from anterior compressive structures. Laminoplasty was initially described by the Japanese in the early 1970s to treat ossification of posterior longitudinal ligament [3]. By leaving the dorsal structures in situ, laminoplasty was developed to avoid the problems associated with laminectomy, such as kyphosis, instability, and delayed neurologic problems due to scar invasion. Laminoplasty has become increasingly popular in North America as experience with laminoplasty techniques has grown and its application has expanded to treat other causes of multilevel cervical stenosis besides OPLL, such as cervical spondylotic myelopathy (CSM). The goals of this chapter are to discuss the advantages and disadvantages of laminoplasty, key technical points regarding different laminoplasty techniques, along with the complications and outcomes of laminoplasty.

2. Advantages of Laminoplasty

Laminoplasty allows the spinal cord and the neuroforamen to be decompressed without directly removing anterior pathology. By preserving the dorsal elements of the spine, laminoplasty preserves spine stability and alignment and decreases the risk of postlaminectomy kyphosis and instability [1, 4–23]. Additionally, since fusion is not required, complications such as fixation failure, pseudarthrosis, loss of motion, and adjacent segment degeneration do not occur. This may allow earlier mobilization and rehabilitation compared to other surgical options. In addition, laminoplasty can avoid graft-related complications such as graft extrusion, settling, collapse, dislodgement, and fracture. The financial

costs associated with laminoplasty are potentially minimized, as well, without the need for lateral mass screws and rods used during fusion. With laminectomy, epidural scar formation can form between the dura and muscle leading to postoperative pain and neurologic compression [24–26]. However, with laminoplasty, the lamina is preserved and it protects the dura from this "postlaminectomy membrane." Preserving the lamina also makes revision procedures requiring posterior approaches safer. Finally, laminoplasty has the advantage of avoiding the potential morbidity that can accompany anterior approaches, such as dysphagia, recurrent laryngeal nerve injury, dysphonia, and injury to the esophagus or carotid sheath contents.

3. Disadvantages of Laminoplasty

Laminoplasty does not address neck pain, if that is a component of a patient's symptomatology. Laminoplasty may even cause worse neck pain than anterior procedures, especially in the early postoperative period, due to the extensive muscle stripping that accompanies this procedure. This has been shown to be especially true if the dissection and laminoplasty is carried down to C7 [27, 28]. Although laminoplasty does not require fusion, range of motion is still reduced following laminoplasty [4, 8, 18, 20, 29–37]. Once the laminoplasty hinge has been opened, it requires some stabilization to maintain the expanded position during healing. This fixation is associated with some cost, bone graft may be required, and there is the potential for nonunion or failure. In addition, the longitudinal incision associated with laminoplasty may be less cosmetic than anterior incisions.

4. Indications

Cervical laminoplasty is indicated for cases of cervical myelopathy or myeloradiculopathy due to central stenosis extending more than three intervertebral disc spaces. This can be due to multilevel degenerative cervical spondylosis, OPLL, multilevel disc herniations, certain spinal cord tumors, neuromuscular disorders, acute traumatic central cord syndrome, or developmental cervical stenosis.

5. Contraindications

Kyphotic deformity is a contraindication for laminoplasty. In the kyphotic spine, laminoplasty does not address the cord compression anteriorly and leads to decreased canal expansion and dorsal migration of the cord [38]. In addition, laminoplasty can contribute to spine instability and worsen the kyphosis in these cases. Ideal laminoplasty patients have lordotic cervical spine alignment and no instability on dynamic radiographs. Laminoplasty can be done in neutral spines (generally defined as less than 4 degrees of either kyphotic or lordotic angulation) but lordotic alignment is preferable since multiple studies have documented loss of lordosis after laminoplasty [12, 20, 29, 30, 39–51]. In patients with radiographic evidence of instability, laminoplasty alone may worsen the instability and should be accompanied by fusion. The ideal laminoplasty patient also has minimal complaints of neck pain. Laminoplasty may not address neck pain and, in fact, may even worsen neck pain. However, the presence of mild neck pain is not a contraindication to laminoplasty, provided the patient accepts the risk of postoperative neck pain. Stenosis at one or two levels is not an indication for laminoplasty since the short length of decompression achieved in these cases does not yield the same amount of spinal cord migration away from anterior structures. Post-laminoplasty instability may also be an issue in patients with rheumatoid arthritis, which is a relative contraindication for laminoplasty [52].

6. Preoperative Considerations

As always, a thorough history and physical exam, especially a thorough neurologic exam, are imperative prior to performing a laminoplasty. Radicular symptoms may suggest the need for a foraminotomy, while significant neck pain may indicate the patient for posterior fusion in combination with laminoplasty. AP/lateral views of the cervical spine and CT myelogram or MRI of the cervical spine is also critical. These imaging modalities can be used to correlate with clinical findings and to assist with surgical planning. They are also important if cervical foraminotomy is needed as they can be used to help assess the level(s) and location of nerve root compression. Upright plain films are used to determine preoperative kyphosis and one's ability to perform posterior surgery. Flexion-extension films should be evaluated for any evidence of instability that may need to be addressed with a posterior fusion.

7. Patient Positioning

We prefer to use the 180-degree operating room setup and a Mayfield tong attachment with gelfoam bolster pads on a standard table. The Mayfield tongs allow control and stability of the cervical spine during positioning. Other alternative operating room table and positioning options include a Jackson frame with a Mayfield tong attachment or a Stryker or Jackson frame with Gardner tong traction.

Intubation must be achieved cautiously. In cases involving severe myelopathy, awake fiberoptic intubation is often recommended to minimize the risk of spinal cord injury with neck extension and to allow monitoring of neurologic status after intubation. Neuromonitoring electrodes are placed and baseline somatosensory and transcranial motor evoked potentials are recorded prior to commencement of the case. Mayfield tong retractors are placed and the patient is placed prone.

The table should be placed in reverse Trendelenburg position at about 20–30 degrees to help with venous drainage and visualization. The shoulders are taped down to provide more complete radiographic visualization of the lower cervical spine. The head should be in maximum capital flexion and the cervical spine in a neutral position to maximize interlaminar and interspinous space and to open the facet joints during foraminotomy. The exception to this is if posterior

fusion is planned, in which case slight extension of the neck during positioning or prior to fusion is necessary. The preferred patient positioning setup is shown in Figure 1. After patient positioning, SSEP and MEP signals are again checked to see if there is any change from baseline that might require repositioning. The posterior cervical spine is then prepped and draped in the usual sterile fashion, including the occipital protuberance rostrally to the T3 spinous process caudally.

Figure 1: Photo demonstrating proper patient positioning. Patient is prone and the head is secured by Mayfield tongs without traction. The table is placed in the reverse Trendelenburg position. Shoulders are taped down and the neck is in slight flexion.

8. Laminoplasty Techniques

Oyama et al. first described cervical laminoplasty in Japanese in 1973 as a treatment for OPLL [3]. In this initial expansive laminoplasty procedure, the "Z-plasty" of the cervical spine, the spinous processes are removed, the lamina is thinned to the lamina-facet junction, and a Z-shaped cut is made between the laminae which are opened and fixed with suture or wire (Figure 2). Since its initial description by Oyama, laminoplasty techniques have been constantly refined. Most of these changes relate to how the cuts in the lamina or spinous process are made and how the laminae are secured in an open position—with wires or heavy sutures, bone anchors or bone blocks, hydroxyapatite blocks, miniplates, local spinous process autograft, and combinations thereof. All variations in laminoplasty techniques maintain the common theme, however, of repositioning the laminae, expanding the canal, and preserving the dorsal elements to maintain stability. In general, none of these technical variations have proven to be any safer or efficacious than the other. There are generally three categories of laminoplasty techniques: the "open door" laminoplasty, the "double door" laminoplasty, and the various muscle-sparing laminoplasty techniques. We will describe these techniques in detail in the following sections.

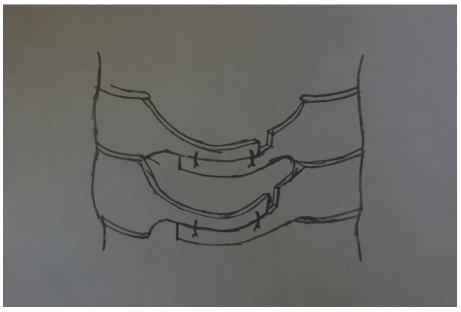

Figure 2: In the original "Z-plasty," after troughs are drilled at the junction between the lamina and lateral mass, the laminae are thinned, a "Z" is cut in the laminae with a drill, and, as shown here, the laminae are spread apart and held with wire or suture to maintain the expanded canal position.

9. Expansive Open-Door Laminoplasty (Also Known as the Hirabayashi, Open-Hinged, or Single-Door Technique)

Hirabayashi et al. simplified the Z-plasty described by Oyama in the early 1980s with his unilateral expansive open-door laminoplasty [4, 34]. In this technique, a hinge is created on one side of the lamina-spinous process-ligamentum flavum complex. This allows the roof of the canal to be opened on the contralateral side leading to an expansion of the spinal canal.

Most commonly, laminoplasty is performed from C3 to C7 and all these levels need to be exposed. This starts with a midline longitudinal posterior incision from the occipital protuberance down to the T1 spinous process. With electrocautery, dissection proceeds through the midline fascia and ligamentum nuchae and the spinous processes from C2 to T1 are exposed. Levels can be identified by palpation and visualization of the prominent, bifid C2 spinous process. Preserve the supraspinous and interspinous ligaments at the proximal and distal extents of the exposure during this approach but Bovie electrocautery can be used to incise these ligaments in the midline at the planned laminoplasty and foraminotomy levels. Also preserve the muscular attachments to C2 as much as possible to minimize risk of postoperative kyphotic deformity between C2 and C3. This is facilitated by first exposing the C7 lamina, retracting the paravertebral muscles at this level, and continuing this dissection rostrally to the upper part of the C3 lamina. Complete this midline, subperiosteal dissection of the paravertebral muscles for the C3 to C7 spinous processes and retract these muscles laterally off the spinous processes, laminae, and medial aspect of the facets. Staying in the natural, avascular, subperiosteal plane prevents damage to the paraspinal muscles and minimizes blood loss. Figure 3 shows the exposure required to perform a laminoplasty. This dissection needs to be extended as far as the lateral masses but the facet capsules must be preserved unless fusion is being performed. Hemostasis at all times can be achieved with monopolar or bipolar electrocautery.

Again, the C2 extensor muscular attachments do not need to be released. If, however, a decompression is necessary at the C2 level and undercutting of the lamina with a burr is not adequate, a laminoplasty can be done at C2 as well. In this case, the C2 extensor muscles can be released or taken off with a thin osseous sleeve and subsequently sutured back down to the C2 dorsal structures. If a foraminotomy is planned at C2-C3, the extensors on the inferior half of C2

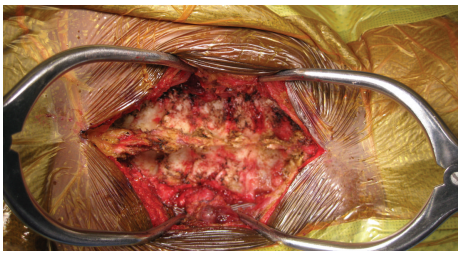

Figure 3: Intraoperative photo showing laminoplasty exposure. Following midline dissection along the avascular subperiosteal plane, paraspinal muscles are retracted laterally and the spinous processes, lamina, and medial aspect of the facets should be completed denuded of soft tissue.

are released so the facets can be visualized adequately. At this point, once the soft tissues have been reflected off the spinous processes and laminae, retractors can be placed on the sides of the wound and, if necessary, rostrally and caudally, to facilitate visualization. The microscope may also be extremely helpful for visualization, especially during foraminotomy, decompression, and creation of the laminar osteotomies.

In the expansive open-door laminoplasty, the opening side of the lamina should be cut before the hinged side to minimize blood loss. The opening side is usually placed on the side with worse radicular symptoms or more stenosis because, on this side, it is technically easier to perform a foraminotomy to decompress the neuroforamen. If it is necessary to perform a foraminotomy on the hinged side, this should be done first to prevent detachment of the lamina and because this is technically more demanding. Using controlled, side-to-side brushing motions with a 2 or 3 mm cutting burr or high-speed microdrill, a trough is made at the junction of the lamina and lateral mass from C3 to C7 by decorticating the posterior aspect of the lamina (see Figure 4(a)). Extra caution should be used at the superior aspect of the lamina, where there is no ligamentum flavum to protect the dural sac. The troughs, created rostral to caudal from one level above to one level below the stenotic levels, should be perpendicular to the lamina. The facets should not be violated. Following thinning of the lamina down to a thin cortical layer, use a curette to free the ligamentum flavum off the inferior aspect of the C7 lamina. Complete the laminar cuts just medial to the pedicles with a 2 or 3 mm Kerrison punch by removing the thin rim of remnant lamina and associated ligamentum flavum from caudal to rostral. Epidural venous bleeding can be controlled with thrombin gel and bipolar electrocautery.

Next, for the "hinged" side of the laminoplasty, another trough is made at the junction of the lamina and lateral mass with minimal disruption of the facet capsule to prevent postoperative instability. While a 2 mm cutting burr or high-speed drill can be employed for this portion of the procedure, we find that a 6 mm diamond burr is useful to cut the outer cortex in the process of creating a greenstick fracture on the hinged side as it minimizes the risk of completely breaking through the inner cortex of the lamina. This large burr tip also helps create a slightly wider trough on this hinged side so the walls of the trough do not contact each other when the door is opened which would limit the amount of decompression. Again, the lamina is thinned with a burr by removing the outer cortex and approximately one half of the cancellous bone. Do not violate the inner cortex which will act as a hinge. To prevent excessive thinning of the lamina on the hinged side and complete dissociation of the entire lamina, it is helpful to periodically assess the amount of "give" in the spinous process when it is manipulated and to use the depth of the lamina on the opened side as a reference for how deep the trough should be on the hinged side. Additionally, a curette can be placed on the open side and pulled upwards. When motion in the lamina is seen with this maneuver, the trough on the hinged side is complete. The top and bottom laminae of the open side which will be included in the laminoplasty can be separated from adjacent levels with a Kerrison Rongeur to cut the lamina and attached ligamentum flavum. This creates three free borders for the "door" which can now hinge open.

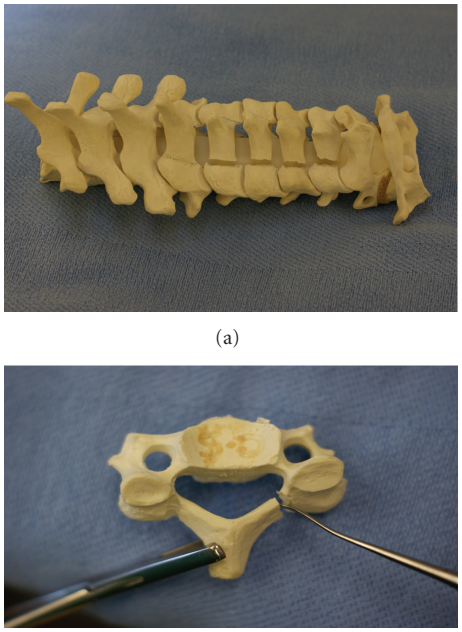

(a)

(b)

Figure 4: Sawbones model of an open-door laminoplasty. A trough has been drilled in the lamina at the lamina-lateral mass junction with a burr until there is a thin remnant of lamina left. This cut has been completed with a Kerrison punch (a). After the complete trough on the open side, a second trough is drilled on the hinge side. Expand the canal and the opening on the open side with a curette on the open side between the laminae and lateral mass while rotating the lamina towards the hinged side with a Kocher, as shown in (b).

Once the laminae are thinned sufficiently, the posterior elements are more flexible and the lamina can be opened very gradually and carefully by additional thinning of the hinged bone, pulling the spinous process toward the hinged side, and lifting the lamina off the spinal cord with a curet on the opening side. Opening the laminae as a single unit preserves the intraspinous ligaments and dorsal structures that help

stabilize the spine. This can be accomplished by opening the lamina at each level gradually and to the same degree as the other. In this way, the gap on the open side between the lamina and facet is increased and a greenstick fracture is established along the trough on the hinged side. If this step is performed with too much force or speed, the inner cortex on the hinged side can fracture. In this case, laminectomy with fusion or stabilization of the hinged side is required. Additionally, if control of the lamina is lost and the door inadvertently snaps closed, this can injure the spinal cord. A Penfield dissector or curette can be helpful to expand the opening and the lamina can be rotated towards the hinged side with a Kocher (see Figure 4(b)). A Woodsen probe or elevator can be used to release any adhesions between the dura and ventral lamina on the opened side. Laminar opening is made easier with posterior elements that are more pliable, and this can be achieved with division of the supraspinous and interspinous ligaments at C2-C3 and C7-T1 and/or release of the ligamentum flavum on the opening side of the lamina. Once pulsatile flow in the dura is noted, which is usually at about 8–10 mm of opening, adequate canal expansion has been achieved. Hemostasis is achieved with gelfoam or surgicel and epidural bleeders are controlled with bipolar electrocautery. Bony bleeding is controlled with bone wax on a kittner or other local hemostatic agents.

In his initial description, Hirabayashi stabilized the laminae in an open position with sutures through the facet capsule and spinous processes on the hinged side. Titanium miniplates with or without allograft or autograft, allograft stabilized with CG clips, stainless steel wiring, facet cables with and without allograft, various suture techniques, ceramic implants, bone anchors placed through the lateral mass, and various structural wedge allografts and autografts are other modified techniques that have been described to keep the door propped in the open position [6, 46, 47, 53–58]. The senior authors prefer either a suture anchor or miniplate for initial stabilization.

Suture anchors are a simple way to maintain the opening of the laminae. We find them to be a safe and time-efficient method that minimizes the risk of disrupting the facet joints and nerve roots. In addition, this technique does not require grafting or fixation of the lamina to the lateral mass. The suture anchors are placed into the lateral masses on the hinged side (Figures 5(a) and 5(b)). We make a hole in the base of the spinous process using a right-angle dental drill with a 2 mm burr tip. Once the laminae are hinged open, a Keith needle is used to bring the nonabsorbable suture from the suture anchor in the lateral mass through the drill hole in the spinous process (Figure 5(c)). Appropriate tension on the suture is achieved with a slip knot and then square knots are tied under tension to maintain the laminar opening (Figure 5(d)).

Our other preferred fixation method involves using titanium miniplates and allograft spacers to hold the laminae open, as shown in Figure 7. Once the laminae are expanded, the appropriate allograft size is ascertained by inserting a trial spacer into the laminar opening (Figure 6). We then choose a double pre-bent miniplate of appropriate length which can be fixed to the allograft via a center screw hole. The miniplate-allograft construct is then placed in the laminar opening such that the cut laminar edges are wedged securely in the ends of the allograft that are prenotched. The graft should fit securely in the laminar gap. We then secure the miniplate with one or two self-tapping 2.0 mm cortex screws on both the laminar and lateral mass side.

We have found both suture anchors and miniplate fixation to be reasonable methods of maintaining the laminar opening, as shown in Figure 9.

10. Double-Door Laminoplasty (Also Known as French Door, Spinous Process-Splitting, Midline Opening, or T-Saw Laminoplasty)

In Hirabayashi's expansive open-door laminoplasty, the spinal cord is decompressed asymmetrically since the door opens on one side and hinges on the other. In contrast, the double-door laminoplasty, described by Kurokawa in 1982, expands the canal symmetrically as the opening is created in the midline [59]. This is accomplished by splitting the spinous processes in the midline with the left and right hemilaminae hinging on the lamina-spinous process-ligamentum flavum complex bilaterally (Figure 10(a)). In the double-door technique, the same positioning, draping, and midline posterior exposure as the open-door technique is performed. This exposure is carried out laterally to the middle of the lateral masses. Preserve the semispinalis muscle attachments to the C2 spinous process as much as possible. Troughs are drilled bilaterally with a high-speed drill or burr at the lamina-lateral mass junction from C3 to C7, just medial to the pedicle (Figures 10(b) and 10(c)). The inner cortex, as with the open-door technique, is only thinned. The spinous processes are then split down the middle. A drill or burr is used to thin the lamina and a Kerrison punch is used to open the lamina in the midline. The midline laminar splits can be opened with laminar spreaders (Figure 10(d)). The laminae are lifted off the spinal cord in the midline and held open like a French door. This allows the spinal cord to drift posteriorly in the enlarged canal.

One purported advantage of the double-door technique is that the decompression occurs directly posterior to the cord so there is less bleeding from the lateral epidural veins that often accompanies the open-door technique. Adhesions between the dura and ventral side of the lamina are freed. The laminar opening can be fixed with suture passing through the facet capsules and lamina. In the initial description of the double-door procedure, the canal was left open. However, several techniques have been proposed to span the space between the gapped lamina and to protect the spinal cord. These include the use of ceramic/hydroxyapatite spacers, iliac crest bone graft, rib autograft (Figure 10(e)), or, as described by Kurokawa, resected spinous process autograft fixed between the lamina with wires [59–61].

In the Tomita modification of the double-door laminoplasty (also known as the "T-saw laminoplasty"), the spinous processes and laminae are split with a Gigli-like wire-saw [29, 62] (Figure 11). After the ligamentum flavum is resected down the midline above and below the levels to be

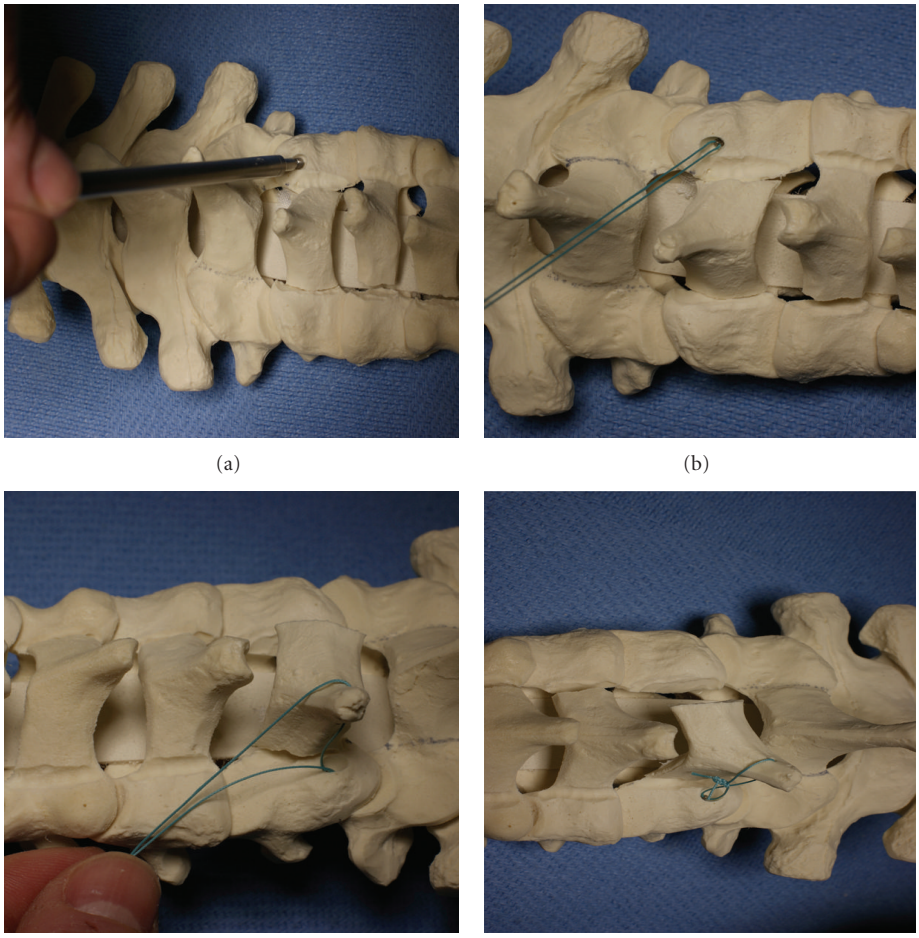

(a) (b) (c) (d)

Figure 5: Once the door is opened, the laminae can be held in the open position with suture anchors. Suture anchors are placed into the lateral masses of the hinge as shown in (a) and (b). Next, the suture anchor is brought through a drill hole in the spinous process (c). The suture is tied to prevent closure of the laminoplasty (d).

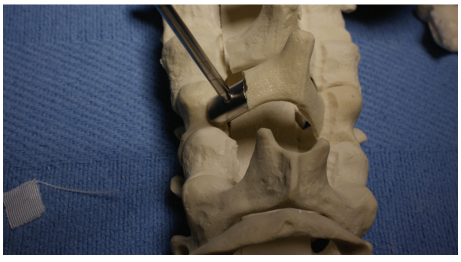

Figure 6: For titanium miniplate fixation, once the laminae are expanded, use a trial spacer to determine the appropriate allograft size.

decompressed, a polyethylene sleeve that encompasses a T-saw is passed superiorly along the epidural space. Grab hold of the sleeve tip as it comes into view in the C2-C3 interspace. Advance the saw through the sleeve and remove the sleeve over the saw. After verifying adequate cervical lordotic alignment to minimize the risk of cord injury, a reciprocating sawing motion is used to saw through the midline of the laminar arch. Irrigate periodically to minimize thermal damage. Greenstick fractures are then created by using a high-speed burr to create bilateral troughs at the medial one-third of the lateral masses. The split laminae are then opened as with the double-door technique. Carefully free up any epidural adhesions. Foraminotomies can be done prior to opening the hinges. The opened canal can be stabilized with various grafts, including rib or fibula allograft spacers, autologous spinous process, or iliac crest [29, 63].

The primary disadvantage of the double-door technique is that it can be technically challenging. This technique also potentially puts the spinal cord more at risk than the open-door technique as the dura is just deep to the spinous process that is split with a burr or saw. Foraminotomy is also technically demanding and may cause disruption of the hinge.

11. Muscle-Sparing Laminoplasty Techniques

Many problems associated with laminoplasty such as axial neck pain, postoperative kyphosis, and segmental instability are thought to be related to neck muscle disruption [12, 33, 64–66]. Various techniques have been described to minimize

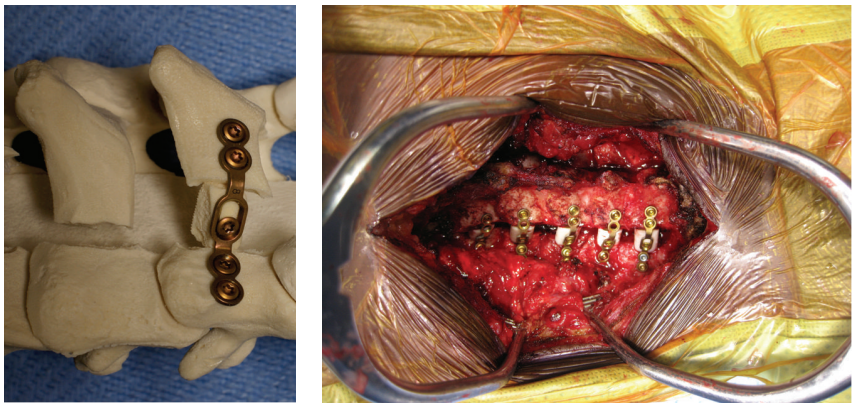

(a) (b)

Figure 7: Sawbones model (a) and intraoperative photo (b) showing miniplate and allograft placed in the laminar opening. The miniplate has been fixed with 2 screws on both the laminar and lateral mass side.

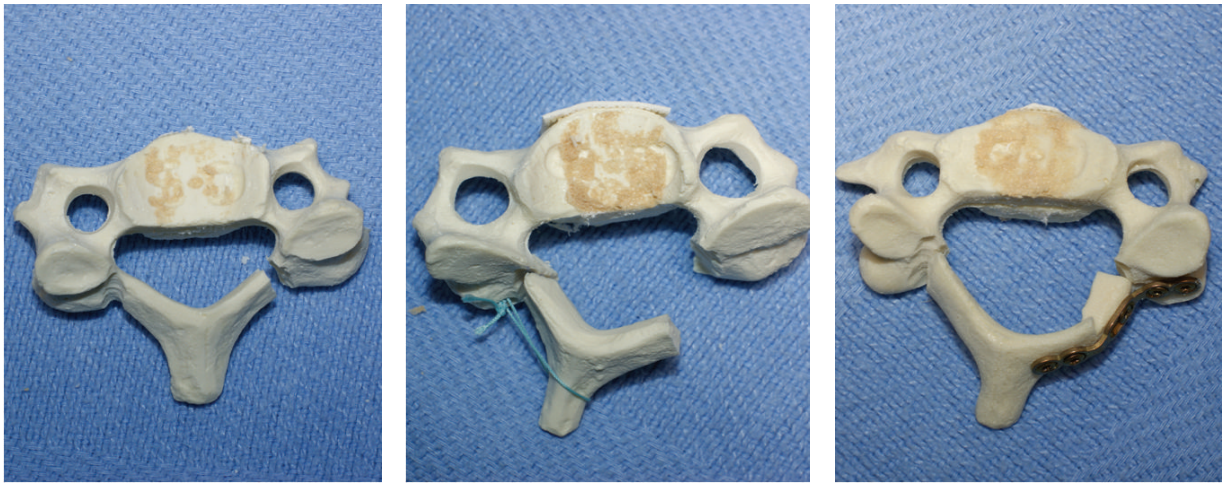

(a) (b) (c)

Figure 8: Sawbones model showing an increase in A-P diameter of the canal between the preexpanded status (a), after suture anchor laminoplasty (b), and after laminoplasty with miniplate fixation (c).

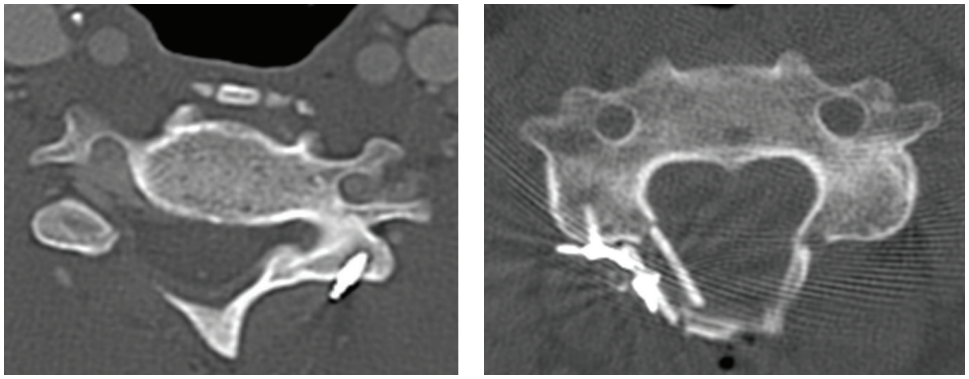

(a) (b)

Figure 9: Axial CT scans of patients following expansive open-door laminoplasty. The laminar opening has been maintained with suture anchors (a) and miniplate fixation (b).

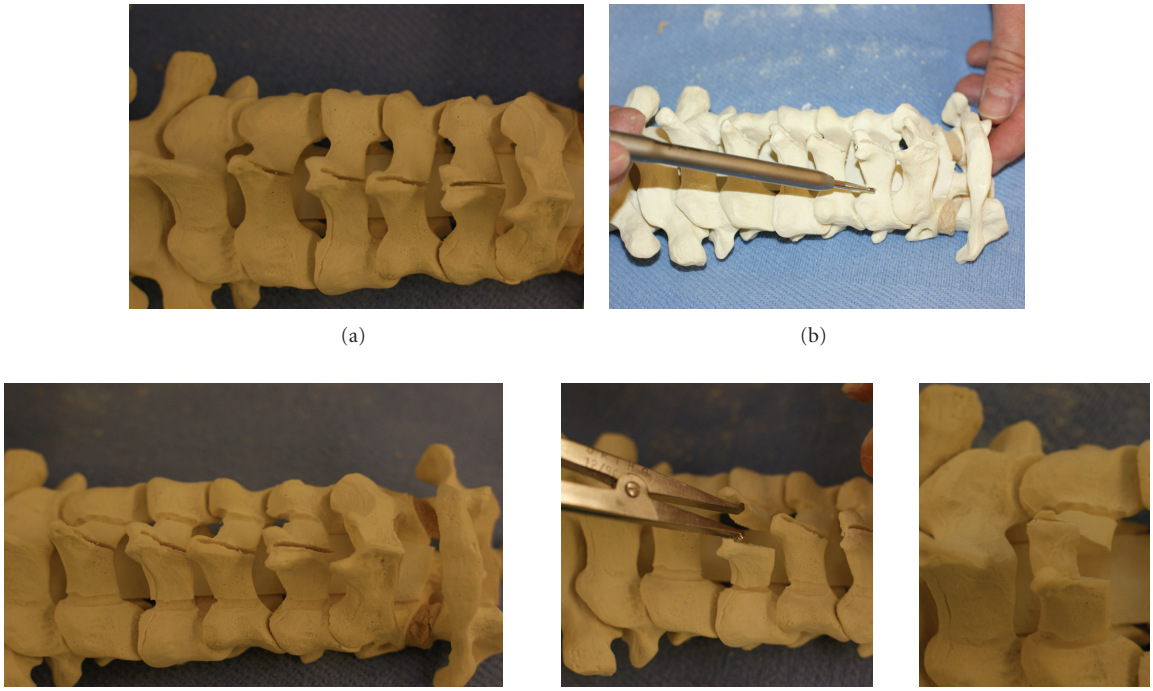

(a) (b) (c) (d) (e)

Figure 10: In the double-door laminoplasty technique, a high-speed burr is used to split the spinous processes in the midline (a). The burr is then used to create troughs bilaterally at the junction of the lamina and lateral mass, as shown in (b) and (c). The hemilaminae are separated at the midline with a laminar spreader and elevated (d). The expanded canal is then held in the open position with either bone graft or ceramic/hydroxyapatite spacers (e).

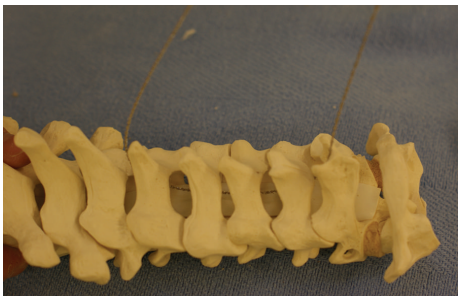

Figure 11: Instead of using a burr for the double-door laminoplasty technique, with the Tomita modification of the double-door laminoplasty, the spinous processes are split in the midline with a Gigli-like T-saw.

disruption of muscular and ligamentous attachments to the lamina and spinous processes.

Shiraishi described a technique designed to minimize damage to the deep extensor muscles of the cervical spine, and, in particular, the attachments of the semispinalis cervicis (SSC) and multifidus muscles to the spinous processes [65] (Figure 12). An operating microscope is recommended for this minimally invasive exposure. A longitudinal midline incision is made overlying the spinous processes of the planned laminoplasty levels. For instance, for a C4 and C5 laminoplasty, the incision would overlie the C4 and C5 spinous processes. The nuchal ligament is incised in line with this incision. Identify the interval between the tips of the C4-C5 spinous processes, which separates the insertions of the interspinalis muscles, SSC, and multifidus muscles to the C4 spinous process from the left and right side. This interval is opened with a nerve retractor such that the muscles attached to the C4 spinous process on the left are retracted to the left and vice versa for those muscles attaching on the right side of the C4 spinous process. The ligamentum flavum and superior half of the C5 lamina should be visible. Sever the interspinalis muscles where they attach to the C5 spinous process. The attachments of the SSC and multifidus muscles on the C5 spinous process are pulled distally so that the attachments of the rotator muscles inserting on the inferior half of the C5 lamina can be seen and dissected off the C5 lamina. By retracting the muscles attached to the C5 spinous process even more distally and those to the C4 spinous process laterally, the C5 lamina, the superior border of the C6 lamina, and the C5-C6 intervertebral joint are exposed without taking down any of the SSC or multifidus attachments to the C4, C5, or C6 spinous processes. Following this exposure that preserves the attachments of the SSC and multifidus to the spinous processes, a double-door laminoplasty can be performed similar to its application with the standard midline posterior approach.

Others, however, have suggested that it is not disruption of the extensor muscles that causes axial pain, but disruption of the musculoligamentous structures attached to the C7 spinous process, such as the trapezius, rhomboid minor, and

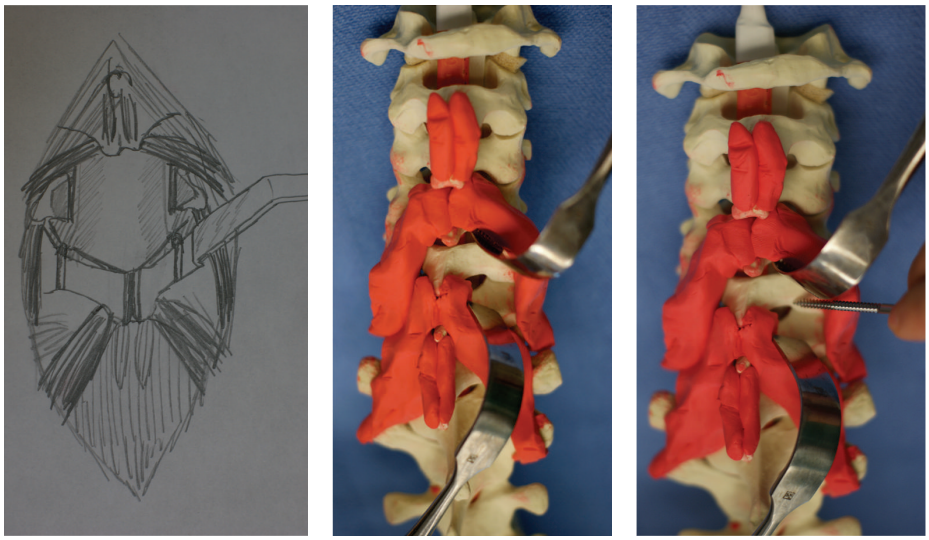

(a) (b) (c)

Figure 12: Illustration (a) and sawbones model (b) showing how a muscle-sparing exposure can be applied to a double-door laminoplasty. The deep extensor muscles attaching to the C4 spinous process are pulled laterally and those attaching to the C5 spinous process are pulled distally. The double-door laminoplasty can then be done as with the standard posterior midline exposure with sagittal splitting of the spinous processes and the creation of bilateral laminar troughs which serve as hinges on which the double-door can open, as shown in (c).

the nuchal ligament [27, 28, 67]. This has led to the recommendation that C7 should be excluded, if possible, from the laminoplasty procedure. This may minimize postoperative neck pain by preserving the C7 spinous process as a fulcrum for neck muscles and it maintains the stabilizing role the C7 lamina plays in the cervical spine [27, 28, 67]. Alternatively, if the epidural space at the ventral aspect of the C7 lamina is tight upon probing, a laminotomy at the superior half of C7 can be done [67].

Others, still, have focused not on disruption of the C7 musculoligamentous attachments as a major source of axial neck pain, loss of extensor power, and loss of cervical alignment, but, instead, disruption of the extensor musculature and, in particular, the semispinalis cervicis muscle attachments on C2 [21, 32, 33, 68–75]. A traditional C3-C7 laminoplasty usually requires disrupting and reattaching the extensor muscle insertions onto C2. Takeuchi, however, proposed a C3 laminectomy with a C4-C7 laminoplasty to preserve these muscles and minimize axial neck pain [69]. In another muscle-sparing modification, some recommend a C3 laminectomy, a laminoplasty from C4 to C6, and an undercutting of the inferior two-thirds of the lamina of C2 and superior half of the lamina of C7. The goal of this technique is to achieve an adequate decompression at C3-C7 but to minimize the incision, the potential for instability, and the amount of bony work and muscle disruption. In another muscle-sparing modification aimed at preventing post-laminoplasty cervical malalignment, Shiraishi and Yato proposed a variation of the double-door laminoplasty procedure that expands the C2 spinal canal while preserving all the muscular attachments to each half of the split C2 spinous process [70].

12. Foraminotomy

Performing a foraminotomy in association with laminoplasty is indicated in cases of significant radiculopathy or if there is radiographic evidence of neuroforaminal stenosis regardless of symptoms. This is done both to prevent the development of nerve root compression postoperatively and, possibly, to minimize postop neck pain due to nerve root stretch and compression. Some also recommend performing a foraminotomy based on abnormal neuromonitoring signals, especially those involving the C5 nerve root, which is particularly vulnerable to traction injury. Others, still, routinely perform bilateral C4-C5 foraminotomies to minimize the risk of a C5 root palsy.

The use of an operating microscope can be helpful for visualization purposes during the foraminotomy. The opening side of the laminoplasty should be placed on the side of the radiculopathy since this is the side that neuroforaminal decompression is easiest. Foraminotomies are usually done once the lamina is raised and the ligamentum flavum is removed. Foraminotomy is done by deroofing the foramen—that is, removing the superior articular facet of the caudal segment that covers the foramen, which is generally the medial third of the facet. This posterior decompression allows the nerve root to migrate posteriorly, away from the uncovertebral osteophytes. If a foraminotomy is to be performed on the hinge side, it should be completed before the laminoplasty to prevent complete disruption of the lamina.

A high-speed burr is used to remove about 50%, medial to lateral, of the inferior articular facet which overlies the superior articular facet dorsally. This exposes the articular surface of the superior articular facet. Thin the facet with

a combination of cutting and diamond burrs and then a 1 mm Kerrison punch is used to remove the roof of the foramen, thus exposing the exiting nerve root. Adequate decompression requires resection of the superior articular facet overlying the inferior pedicle but not lateral to it, as this may lead to instability. Verify adequate decompression by probing the foraminal opening with a nerve hook. The lateral wall of the superior and inferior pedicles should be easily palpable. Hemostasis is facilitated with gelfoam and thrombin.

13. Fusion

Fusion is indicated with laminoplasty for patients with severe axial neck pain, evidence of instability, or bilateral radicular symptoms in addition to myelopathy. If fusion is planned, the exposure needs to be carried out laterally to the lateral aspect of the facet joints. Additionally, excision of facet capsules from C3 to C7 should be performed during the exposure. After the laminoplasty is complete, place lateral mass screws at C3 to C7. The start point is 1 mm medial to the center of the lateral mass with a 15-degree rostral and 30-degree lateral trajectory [76]. Some prefer a pedicle screw at C7 for additional stability. After lateral mass decortication, allograft or cancellous iliac crest autograft is packed into the decorticated fusion bed.

14. Wound Closure

After copious irrigation of the wound with normal saline, retractors are removed, hemostasis is achieved, and a deep drain is placed. A standard layered closure is then performed. We close the fascia covering the paravertebral musculature with a No. 0 vicryl suture in a Figure 8 fashion, followed by a No. 0 PDS running stitch. The subcutaneous layer is closed with No. 2-0 vicryl in an interrupted buried fashion. We close the skin with either a No. 3-0 monocryl suture using a running subcuticular technique or a No. 3-0 nylon baseball stitch.

15. Postoperative Management

The head of the bed should be kept at greater than 45 degrees for the first couple days after surgery to minimize venous bleeding. Patients are immobilized in a rigid cervical collar, such as an Aspen collar, for 3-4 weeks. Mobilization with physical therapy starts on postoperative day one, including bed transfers and ambulation. We obtain AP and lateral plain films of the cervical spine prior to patient discharge. Patients typically are discharged 24 to 48 hours after surgery and return for their first follow-up visit 3-4 weeks later, at which point we obtain repeat AP and lateral cervical spine films. We encourage patients to return to their day-to-day activities as soon as possible. At 3-4 weeks, patients can discontinue the use of their collar and initiate isometric neck exercises.

16. Complications

16.1. Wound Complications. Some argue that wound complications, such as infection or dehiscence, is a greater risk with laminoplasty compared to laminectomy as the lamina are rotated and held open [77]. This is an inherent complication for all posterior cervical approaches due to the strong muscular attachments. We have found the rate of infection and dehiscence to be extremely low in our laminoplasty patients. Avoidance of soft tissue complications is facilitated by paying meticulous attention to soft tissue handling, copious irrigation, thorough hemostasis, excision of necrotic soft tissue prior to closure, a watertight closure, subfascial drain placement, and perioperative antibiotics.

16.2. Neurologic Complications. One of the advantages of laminoplasty, compared to laminectomy, is the theoretical decreased risk of neurologic complications as laminoplasty does not involve placing any instruments between the lamina and dural sac. Neurologic deterioration is, however, still a potential risk with laminoplasty. This may be due to hematoma, inadequate decompression, traumatic surgical technique, restenosis or persistent stenosis due to inadequate raising of the lamina, fracture of the hinged lamina, or closure or dislodgment of the laminar opening [46, 51]. Laminar closure can be related to inadequate stabilization of the opening or hardware issues, such as broken miniplates. The incidence of canal restenosis is challenging to ascertain as CT and MRI scans are not routinely obtained and, when they are, long-term radiographic assessment of space available for the cord is rarely reported.

As with laminectomy, nerve roots can be mechanically injured during laminoplasty procedures, particularly during decompression with a drill or punch. Isolated nerve root injuries are a particular concern with laminoplasty, however, and they occur around five to 11% of the time [4, 20, 78, 79]. This complication presents primarily with motor weakness. Sensory deficits are a less common presentation. C5 is the most common nerve root affected. Although C5 palsies usually present 1–3 days after surgery with deltoid weakness and shoulder pain, the presentation can occur as late as 20 days postop [80]. It is not clear what causes the C5 nerve root palsy but some postulate it is related to a traction injury to the nerve root. Not only are the C5 roots shorter and less forgiving to traction injuries, C5 is also at the apex of the lordotic cervical curve and, in general, it is at the center of the laminoplasty [20, 37, 79–81]. Thus, the cord drifts posteriorly at C5 moreso than at other levels, which preferentially stretches the C5 nerve root. Other potential mechanisms of injury to the C5 nerve root with laminoplasty include intraoperative trauma to the C5 nerve root, dislodging of the lamina on the hinge side, preoperative neuroforaminal stenosis not adequately addressed intraoperatively, and preexisting spinal cord pathology [20, 78, 81–83]. Some recommend intraoperative transcranial motor evoked potential and spontaneous EMG monitoring to prevent C5 root injuries by performing a C5 foraminotomy if there are any abnormal signals to indicate the need to do so.

Treatment of nerve root palsies involves physical therapy and nonsteroidal anti-inflammatory medication. In general, complete or near complete recovery from the C5 palsy occurs spontaneously within one year but it can take up to six years to recover [37]. Some have recommended prophylactic

foraminotomy and facetectomy to prevent a C5 palsy but this recommendation has not been borne out in the literature.

16.3. Axial Neck Pain. The true incidence of axial neck pain or stiffness following laminoplasty is variable in the literature. Yoshida et al., in their series, found that laminoplasty did not improve or cause neck or shoulder pain [84]. Hosono et al., however, demonstrated that axial neck pain was present in 60% of patients following laminoplasty in the postop period, a significantly higher incidence rate than that of his anterior fusion patients [66, 84]. This variation in the literature with regards to the true incidence of post-laminoplasty axial neck pain is also evidenced by Sani's meta-analysis of outcomes in 71 laminoplasty series including more than 2000 patients: he found that postoperative axial neck pain occurred in anywhere from 6 to 60% of patients and did not depend on the type of laminoplasty performed [50]. Postoperative neck pain is thought to be related to dissection around the facets and soft-tissue retraction, necrosis, and scarring [66, 77]. The neck pain begins in the early postop period and usually goes away within a year. Preventing postoperative neck pain and stiffness is the basis for recommending early neck range of motion. Nonsteroidal anti-inflammatory medications and physical therapy can be of benefit, although this has not been studied in the literature.

16.4. Loss of Cervical Motion. Although one advantage of laminoplasty is that it allows for decompression without fusion, studies have reported a decrease in cervical range of motion after laminoplasty. This loss of motion is in the range of 17–75% but, usually, a global loss of cervical motion of approximately 50% is seen [4, 29, 33–37, 41, 46, 48, 49, 53, 55, 85–87]. There is some controversy over the clinical significance of this loss of cervical motion. Some argue that range of motion after laminoplasty is crucial to addressing mechanical stress and avoiding adjacent segment degeneration and axial neck pain [47]. On the other hand, some propose that post-laminoplasty stiffness contributes to resolution of OPLL, protects the spinal cord by limiting dynamic motion, and maximizes the potential for neurologic recovery [41, 51, 88].

16.5. Loss of Cervical Alignment. No laminoplasty technique can prevent the development of some kyphosis postoperatively. The range of worsening cervical alignment in the literature varies from 22 to 53%, a complication that is not avoided with fusion [12, 20, 29, 30, 40–51, 88]. There is a paucity of literature on the correlation between kyphotic deformity and clinical or neurologic outcomes and even some data suggesting there is no such correlation [36, 48, 51, 88]. Augmenting a laminoplasty with modern instrumentation, however, has been shown to help preserve lordosis [6].

17. Clinical Outcomes

Multiple studies have shown that patients with cervical myelopathy due to cervical spondylosis or OPLL do reliably benefit from neurologic improvement following laminoplasty. Most studies report outcomes using the Japanese Orthopedic Association (JOA) scoring system, documenting mean preop and postop scores and rate of recovery. Recovery rates following laminoplasty of at least 50–70% are consistently reported in the literature, though recovery rates as high as 90% have been reported [8, 18, 20, 29, 36, 37, 44, 46, 47, 78, 86, 89–92].

Multiple authors have verified the reliable outcomes of laminoplasty in the short to midterm, but there only a few series that have been able to show that improvement in neurologic status following laminoplasty is maintained in the long-term. Kawaguchi et al. reviewed long term outcomes (greater than 10 years) in 133 patients with cervical myelopathy treated with laminoplasty [43]. The average preoperative JOA score was 9.1 points, and, postoperatively, it improved to 13.7 within one year. Although he did note some cases of neurologic decline, postoperative radiculopathy, kyphotic deformity, and loss of motion, JOA scores and recovery rates were maintained at 13.4 points and 55% at last followup, respectively. Seichi et al. performed a long-term retrospective study looking at the results of double-door laminoplasty in 35 patients with OPLL and 25 patients with CSM, including 5 patients with athetoid cerebral palsy [36]. Average followup was about 13 years. In 32/35 patients with OPLL and 23/25 patients with CSM, myelopathy improved. Improvements in JOA scores were maintained at last follow up in 26/35 patients with OPLL and 21/25 patients with CSM. Late neurologic deterioration occurred in 10 patients with OPLL at a mean of eight years after surgery and in four patients with CSM (including 3 patients with athetoid cerebral palsy) at a mean of 11 years postop. Overall, short-term results of laminoplasty were maintained at 10 years and Seichi's group concluded that double-door laminoplasty is a reliable procedure for patients with cervical myelopathy (except in those with athetoid cerebral palsy).

Neurologic recovery is most likely related more to preoperative neurologic status and degree of myelopathy than the specific laminoplasty technique performed. No significant difference has been demonstrated with one laminoplasty technique compared to the other. The etiology of stenosis, however, does appear to have an effect on prognosis following laminoplasty. The benefits of surgery in patients with CSM appear to last in the long term, but there is a slightly higher rate of late clinical deterioration in patients with OPLL. Age greater than 60 and a history of symptoms preoperatively for more than one year are also poor prognostic indicators [42, 78].

There are very few studies directly comparing surgical options for cervical myelopathy. Kaminsky's group compared outcomes in patients treated with laminoplasty versus laminectomy without fusion for CSM using the modified Nurick grading scale [93]. Both groups improved to a similar degree. The patients who underwent laminoplasty, however, had less postoperative cervical pain and less cervical range of motion. Other earlier studies also found no difference in long-term neurologic outcomes between patients treated with laminectomy without fusion and laminoplasty [12, 56, 63]. However, Heller et al. performed a retrospective review of two matched groups of patients with multilevel cervical myelopathy who underwent either laminectomy with fusion

or laminoplasty [94]. Compared to the laminectomy and fusion cohort, the laminoplasty cohort showed greater rates of objective improvement in function as judged by Nurick scores and greater subjective improvement in strength, dexterity, sensation, pain, and gait. In addition, no complications were noted in the laminoplasty cohort compared to 14 complications in nine patients who underwent laminectomy and fusion. Heller et al. concluded that the differences he found in terms of complications and functional improvement between the two cohorts suggest that laminoplasty may be more effective and safer than laminectomy with fusion for multilevel cervical myelopathy.

Edwards et al. compared laminoplasty and anterior decompression and fusion in a matched cohort of 13 patients in each group and found higher rates of neurologic improvement, less pain medication needs, and fewer complications in the laminoplasty cohort [95]. They concluded that though both multilevel corpectomy and laminoplasty effectively arrest progression of myelopathy and lead to neurologic improvement, laminoplasty is a better option. Wada's group also retrospectively compared long-term outcomes between 23 patients treated with subtotal corpectomy and 24 patients treated with laminoplasty for multilevel CSM over 10–14 years [48]. Neurologic recovery was identical between the two groups and was usually maintained for more than ten years. However, the subtotal corpectomy group had longer surgeries, more blood loss, and a 26% pseudarthrosis rate. Axial pain was significantly more common in the laminoplasty group compared to the corpectomy group, at 40% and 15%, respectively. Loss of cervical motion was more severe in the laminoplasty group as well: range of motion was 29% of what it was preoperatively in this group, compared to 49% in the corpectomy group. Finally, Yonenobu et al. also compared the results of 41 patients with CSM undergoing either subtotal corpectomy with strut grafting and 42 patients who underwent laminoplasty with a minimum followup of 2 years [44]. There was no significant difference in recovery rate and final score in terms of JOA scores. Complications were more frequent in the subtotal corpectomy group, however, and these were usually due to bone-graft-related issues. Yonenobu's group concluded that in terms of neurologic results, complications, and the potential for immediate mobilization that laminoplasty affords, it is the preferred surgical technique for patients with CSM.

18. Conclusion

Laminoplasty is becoming an increasingly popular treatment for multilevel cervical stenosis due to cervical spondylotic myelopathy, OPLL, and other causes. Laminoplasty minimizes the risk of certain complications associated with other surgical options, such as graft and fusion-related complications, postoperative kyphosis and instability, and the morbidity of an anterior approach. Laminoplasty does have its own set of potential complications, including laminar closure, axial neck pain, nerve root palsies, and loss of cervical motion and alignment. However, laminoplasty techniques are continuously being refined to address such potential shortcomings. Indeed, further prospective data with longer-term followup comparing laminoplasty techniques to other surgical options is necessary. Yet, outcomes in laminoplasty patients that are at least as good as anterior decompression and fusion and laminectomy can be expected. In the appropriate patient and with proper surgical technique, laminoplasty can be an excellent option for patients with multilevel cervical stenosis and myeloradiculopathy.

References

[1] J. Lonstein, R. Winter, J. Moe et al., "Post laminectomy spine deformity," *Journal of Bone and Joint Surgery*, vol. 58-A, no. 5, p. 727, 1976.

[2] J. K. Houten, P. R. Cooper, E. C. Benzel, V. K. H. Sonntag, V. C. Traynelis, and U. Batzdorf, "Laminectomy and posterior cervical plating for multilevel cervical spondylotic myelopathy and ossification of the posterior longitudinal ligament: effects on cervical alignment, spinal cord compression, and neurological outcome," *Neurosurgery*, vol. 52, no. 5, pp. 1081–1088, 2003.

[3] M. Oyama, S. Hattori, and N. Moriwaki, "A New method of cervical laminoplasty," *The Central Japan Journal of Orthopaedic Surgery*, vol. 16, pp. 792–794, 1973.

[4] K. Hirabayashi, K. Watanabe, and K. Wakano, "Expansive open-door laminoplasty for cervical spinal stenotic myelopathy," *Spine*, vol. 8, no. 7, pp. 693–699, 1983.

[5] J. A. Epstein, "The surgical management of cervical spinal stenosis, spondylosis, and myeloradiculopathy by means of the posterior approach," *Spine*, vol. 13, no. 7, pp. 864–869, 1988.

[6] M. F. O'Brien, D. Peterson, A. T. H. Casey, and H. A. Crockard, "A novel technique for laminoplasty augmentation of spinal canal area using titanium miniplate stabilization: a computerized morphometric analysis," *Spine*, vol. 21, no. 4, pp. 474–483, 1996.

[7] G. J. Kaptain, N. E. Simmons, R. E. Replogle, and L. Poberezskin, "Incidence and outcome of kyphotic deformity following laminectomy for cervical spondylotic myelopathy," *Journal of Neurosurgery*, vol. 93, no. 2, pp. 199–204, 2000.

[8] H. N. Herkowitz, "Cervical laminaplasty: its role in the treatment of cervical radiculopathy," *Journal of Spinal Disorders*, vol. 1, no. 3, pp. 179–188, 1988.

[9] S. Yasuoka, H. A. Peterson, and C. S. MacCarty, "Incidence of spinal column deformity after multilevel laminectomy in children and adults," *Journal of Neurosurgery*, vol. 57, no. 4, pp. 441–445, 1982.

[10] M. Crandell and F. K. Gregorious, "Long term follow-up of surgical treatment of cervical spondylotic myelopathy," *Spine*, vol. 2, pp. 139–146, 1977.

[11] Y. Mikawa, J. Shikata, and T. Yamamuro, "Spinal deformity and instability after multilevel cervical laminectomy," *Spine*, vol. 12, no. 1, pp. 6–11, 1987.

[12] S. Hukuda, M. Ogata, T. Mochizuki, and K. Shichikawa, "Laminectomy versus laminoplasty for cervical myelopathy: brief report," *Journal of Bone and Joint Surgery - Series B*, vol. 70, no. 2, pp. 325–326, 1988.

[13] G. J. Kaptain, N. E. Simmons, R. E. Replogle, and L. Poberezskin, "Incidence and outcome of kyphotic deformity following laminectomy for cervical spondylotic myelopathy," *Journal of Neurosurgery*, vol. 93, no. 2, pp. 199–204, 2000.

[14] H. Baba, S. Imura, N. Kawahara, S. Nagata, and K. Tomita, "Osteoplastic laminoplasty for cervical myeloradiculopathy secondary to ossification of the posterior longitudinal ligament," *International Orthopaedics*, vol. 19, no. 1, pp. 40–45, 1995.

[15] D. H. R. Jenkins, "Extensive cervical laminectomy: long term results," *British Journal of Surgery*, vol. 60, no. 11, pp. 852–854, 1973.

[16] Y. Kato, M. Iwasaki, T. Fuji, K. Yonenobu, and T. Ochi, "Long-term follow-up results of laminectomy for cervical myelopathy caused by ossification of the posterior longitudinal ligament," *Journal of Neurosurgery*, vol. 89, no. 2, pp. 217–223, 1998.

[17] L. Rogers, "The surgical treatment of cervical spondylotic myelopathy: mobilization of the complete cervical cord into an enlarged canal," *Journal of Bone and Joint Surgery*, vol. 43, pp. 3–6, 1961.

[18] K. Hirabayashi and K. Satomi, "Operative procedure and results of expansive open-door laminoplasty," *Spine*, vol. 13, no. 7, pp. 870–876, 1988.

[19] Y. Mikawa, J. Shikata, and T. Yamamuro, "Spinal deformity and instability after multilevel cervical laminectomy," *Spine*, vol. 12, no. 1, pp. 6–11, 1987.

[20] K. Hirabayashi, Y. Toyama, and K. Chiba, "Expansive laminoplasty for myelopathy in ossification of the longitudinal ligament," *Clinical Orthopaedics and Related Research*, no. 359, pp. 35–48, 1999.

[21] A. Inoue, T. Ikata, and S. Katoh, "Spinal deformity following surgery for spinal cord tumors and tumorous lesions: analysis based on an assessment of the spinal functional curve," *Spinal Cord*, vol. 34, no. 9, pp. 536–542, 1996.

[22] P. Narayan and R. W. Haid, "Treatment of degenerative cervical disc disease," *Neurologic Clinics*, vol. 19, no. 1, pp. 217–229, 2001.

[23] T. J. Albert and A. Vacarro, "Postlaminectomy kyphosis," *Spine*, vol. 23, no. 24, pp. 2738–2745, 1998.

[24] Y. Ishida, K. Suzuki, K. Ohmori, Y. Kikata, and Y. Hattori, "Critical analysis of extensive cervical laminectomy," *Neurosurgery*, vol. 24, no. 2, pp. 215–222, 1989.

[25] P. Guigui, M. Benoist, and A. Deburge, "Spinal deformity and instability after multilevel cervical laminectomy for spondylotic myelopathy," *Spine*, vol. 23, no. 4, pp. 440–447, 1998.

[26] M. P. Steinmetz and D. K. Resnick, "Cervical laminoplasty," *Spine Journal*, vol. 6, no. 6, pp. S274–S281, 2006.

[27] N. Hosono, H. Sakaura, Y. Mukai, and H. Yoshikawa, "The source of axial pain after cervical laminoplasty-C7 is more crucial than deep extensor muscles," *Spine*, vol. 32, no. 26, pp. 2985–2988, 2007.

[28] N. Hosono, H. Sakaura, Y. Mukai, R. Fujii, and H. Yoshikawa, "C3-6 laminoplasty takes over C3-7 laminoplasty with significantly lower incidence of axial neck pain," *European Spine Journal*, vol. 15, no. 9, pp. 1375–1379, 2006.

[29] C. C. Edwards, J. G. Heller, and D. H. Silcox, "T-saw laminoplasty for the management of cervical spondylotic myelopathy: clinical and radiographic outcome," *Spine*, vol. 25, no. 14, pp. 1788–1794, 2000.

[30] H. N. Herkowitz, "A comparison of anterior cervical fusion, cervical laminectomy, and cervical laminoplasty for the surgical management of multiple level spondylotic radiculopathy," *Spine*, vol. 13, no. 7, pp. 774–780, 1988.

[31] K. Hirabayashi and H. H. Bohlman, "Multilevel cervical spondylosis: laminoplasty versus anterior decompression," *Spine*, vol. 20, no. 15, pp. 1732–1734, 1995.

[32] A. Inoue, T. Ikata, and S. Katoh, "Spinal deformity following surgery for spinal cord tumors and tumorous lesions: analysis based on an assessment of the spinal functional curve," *Spinal Cord*, vol. 34, no. 9, pp. 536–542, 1996.

[33] Y. Kawaguchi, H. Matsui, H. Ishihara, R. Gejo, and O. Yoshino, "Axial symptoms after en bloc cervical laminoplasty," *Journal of Spinal Disorders*, vol. 12, no. 5, pp. 392–395, 1999.

[34] K. Hirabayashi, J. Miyakawa, K. Satomi, T. Maruyama, and K. Wakano, "Operative results and postoperative progression of ossification among patients with ossification of cervical posterior longitudinal ligament," *Spine*, vol. 6, no. 4, pp. 354–364, 1981.

[35] K. Kohno, Y. Kumon, Y. Oka, S. Matsui, S. Ohue, and S. Sakaki, "Evaluation of prognostic factors following expansive laminoplasty for cervical spinal stenotic myelopathy," *Surgical Neurology*, vol. 48, no. 3, pp. 237–245, 1997.

[36] A. Seichi, K. Takeshita, I. Ohishi et al., "Long-term results of double-door laminoplasty for cervical stenotic myelopathy," *Spine*, vol. 26, no. 5, pp. 479–487, 2001.

[37] K. Satomi, Y. Nishu, T. Kohno, and K. Hirabayashi, "Long-term follow-up studies of open-door expansive laminoplasty for cervical stenotic myelopathy," *Spine*, vol. 19, no. 5, pp. 507–510, 1994.

[38] H. Baba, K. Uchida, Y. Maezawa, N. Furusawa, M. Wada, and S. Imura, "Three-dimensional computed tomography for evaluation of cervical spinal canal enlargement after en bloc open-door laminoplasty," *Spinal Cord*, vol. 35, no. 10, pp. 674–679, 1997.

[39] S. Kawai, K. Sunago, K. Doi, M. Saika, and T. Taguchi, "Cervical laminoplasty (Hattori's method). Procedure and follow-up results," *Spine*, vol. 13, no. 11, pp. 1245–1250, 1988.

[40] K. Sasai, T. Saito, S. Akagi, I. Kato, and R. Ogawa, "Cervical curvature after laminoplasty for spondylotic myelopathy—involvement of yellow ligament, semispinalis cervicis muscle, and nuchal ligament," *Journal of Spinal Disorders*, vol. 13, no. 1, pp. 26–30, 2000.

[41] I. Kimura, H. Shingu, and Y. Nasu, "Long-term follow-up of cervical spondylotic myelopathy treated by canal-expansive laminoplasty," *Journal of Bone and Joint Surgery B*, vol. 77, no. 6, pp. 956–961, 1995.

[42] T. T. Lee, G. R. Manzano, and B. A. Green, "Modified open-door cervical expansive laminoplasty for spondylotic myelopathy: operative technique, outcome, and predictors for gait improvement," *Journal of Neurosurgery*, vol. 86, no. 1, pp. 64–68, 1997.

[43] Y. Kawaguchi, M. Kanamori, H. Ishihara, K. Ohmori, H. Nakamura, and T. Kimura, "Minimum 10-year followup after en bloc cervical laminoplasty," *Clinical Orthopaedics and Related Research*, no. 411, pp. 129–139, 2003.

[44] K. Yonenobu, N. Hosono, M. Iwasaki, M. Asano, and K. Ono, "Laminoplasty versus subtotal corpectomy: a comparative study of results in multisegmental cervical spondylotic myelopathy," *Spine*, vol. 17, no. 11, pp. 1281–1284, 1992.

[45] S. Matsunaga, T. Sakou, and K. Nakanisi, "Analysis of the cervical spine alignment following laminoplasty and laminectomy," *Spinal Cord*, vol. 37, no. 1, pp. 20–24, 1999.

[46] J. Mochida, T. Nomura, M. Chiba, K. Nishimura, and E. Toh, "Modified expansive open-door laminoplasty in cervical myelopathy," *Journal of Spinal Disorders*, vol. 12, no. 5, pp. 386–391, 1999.

[47] C. I. Shaffrey, G. C. Wiggins, C. B. Piccirilli, J. N. Young, and L. R. Lovell, "Modified open-door laminoplasty for treatment of neurological deficits in younger patients with congenital spinal stenosis: analysis of clinical and radiographic data," *Journal of Neurosurgery*, vol. 90, no. 4, pp. 170–177, 1999.

[48] E. Wada, S. Suzuki, A. Kanazawa, T. Matsuoka, S. Miyamoto, and K. Yonenobu, "Subtotal corpectomy versus laminoplasty for multilevel cervical spondylotic myelopathy: a long-term

follow-up study over 10 years," *Spine*, vol. 26, no. 13, pp. 1443–1447, 2001.

[49] S. Kawai, K. Sunago, K. Doi, M. Saika, and T. Taguchi, "Cervical laminoplasty (Hattori's method). Procedure and follow-up results," *Spine*, vol. 13, no. 11, pp. 1245–1250, 1988.

[50] S. Sani, J. K. Ratliff, and P. R. Cooper, "A Critical Review of Cervical Laminoplasty," *Neurosurgery Quarterly*, vol. 14, no. 1, pp. 5–16, 2004.

[51] Y. Morio, K. Yamamoto, R. Teshima, H. Nagashima, and H. Hagino, "Clinicoradiologic study of cervical laminoplasty with posterolateral fusion or bone graft," *Spine*, vol. 25, no. 2, pp. 190–196, 2000.

[52] Y. Mukai, N. Hosono, H. Sakaura et al., "Laminoplasty for cervical myelopathy caused by subaxial lesions in rheumatoid arthritis," *Journal of Neurosurgery*, vol. 100, no. 1, pp. 7–12, 2004.

[53] T. Morimoto, T. Matsuyama, H. Hirabayashi, T. Sakaki, and T. Yabuno, "Expansive laminoplasty for multilevel cervical OPLL," *Journal of Spinal Disorders*, vol. 10, no. 4, pp. 296–298, 1997.

[54] G. R. Gillett, A. M. Erasmus, and C. R. P. Lind, "CG-clip expansive open-door laminoplasty: a technical note," *British Journal of Neurosurgery*, vol. 13, no. 4, pp. 405–408, 1999.

[55] T. Itoh and H. Tsuji, "Technical improvements and results of laminoplasty for compressive myelopathy in the cervical spine," *Spine*, vol. 10, no. 8, pp. 729–736, 1985.

[56] N. Nakano, T. Nakano, and K. Nakano, "Comparison of the results of laminectomy and open-door laminoplasty for cervical spondylotic myeloradiculopathy and ossification of the posterior longitudinal ligament," *Spine*, vol. 13, no. 7, pp. 792–794, 1988.

[57] H. Baba, N. Furusawa, Q. Chen, and S. Imura, "Cervical laminoplasty in patients with ossification of the posterior longitudinal ligaments," *Paraplegia*, vol. 33, no. 1, pp. 25–29, 1995.

[58] S. I. Kihara, T. Umebayashi, and M. Hoshimaru, "Technical improvements and results of open-door expansive laminoplasty with hydroxyapatite implants for cervical myelopathy," *Neurosurgery*, vol. 57, no. 4, pp. S-348–S-355, 2005.

[59] T. Kurokawa, "Enlargement of the spinal canal by the sagittal splitting of spinous processes," *Bessatsu Seikeigeka*, vol. 2, pp. 249–252, 1982.

[60] H. Hase, T. Watanabe, Y. Hirasawa et al., "Bilateral open laminoplasty using ceramic laminas for cervical myelopathy," *Spine*, vol. 16, no. 11, pp. 1269–1276, 1991.

[61] K. Nakano, S. Harata, F. Suetsuna, T. Araki, and J. Itoh, "Spinous process-splitting laminoplasty using hydroxyapatite spinous process spacer," *Spine*, vol. 17, no. 3, pp. S41–S43, 1992.

[62] K. Tomita, N. Kawahara, Y. Toribatake, and J. G. Heller, "Expansive midline T-saw laminoplasty (Modified spinous process-splitting) for the management of cervical myelopathy," *Spine*, vol. 23, no. 1, pp. 32–37, 1998.

[63] K. Tomita, S. Nomura, S. Umeda, and H. Baba, "Cervical laminoplasty to enlarge the spinal canal in multilevel ossification of the posterior longitudinal ligament with myelopathy," *Archives of Orthopaedic and Traumatic Surgery*, vol. 107, no. 3, pp. 148–153, 1988.

[64] H. Baba, Y. Maezawa, N. Furusawa, S. Imura, and K. Tomita, "Flexibility and alignment of the cervical spine after laminoplasty for spondylotic myelopathy. A radiographic study," *International Orthopaedics*, vol. 19, no. 2, pp. 116–121, 1995.

[65] T. Shiraishi, "A new technique for exposure of the cervical spine laminae. Technical note," *Journal of Neurosurgery*, vol. 96, no. 1, pp. 122–126, 2002.

[66] N. Hosono, K. Yonenobu, and K. Ono, "Neck and shoulder pain after laminoplasty: a noticeable complication," *Spine*, vol. 21, no. 17, pp. 1969–1973, 1996.

[67] T. Takeuchi and Y. Shono, "Importance of preserving the C7 spinous process and attached nuchal ligament in French-door laminoplasty to reduce postoperative axial symptoms," *European Spine Journal*, vol. 16, no. 9, pp. 1417–1422, 2007.

[68] A. N. Vasavada, S. Li, and S. L. Delp, "Influence of muscle morphometry and moment arms on the moment-generating capacity of human neck muscles," *Spine*, vol. 23, no. 4, pp. 412–422, 1998.

[69] K. Takeuchi, T. Yokoyama, S. Aburakawa et al., "Axial symptoms after cervical laminoplasty with C3 laminectomy compared with conventional C3-C7 laminoplasty: a modified laminoplasty preserving the semispinalis cervicis inserted into axis," *Spine*, vol. 30, no. 22, pp. 2544–2549, 2005.

[70] T. Shiraishi and Y. Yato, "New double-door laminoplasty procedure for the axis to preserve all muscular attachments to the spinous process: technical note," *Neurosurgical Focus*, vol. 12, no. 1, p. E9, 2002.

[71] M. S. Conley, R. A. Meyer, J. J. Bloomberg, D. L. Feeback, and G. A. Dudley, "Noninvasive analysis of human neck muscle function," *Spine*, vol. 20, no. 23, pp. 2505–2512, 1995.

[72] H. Iizuka, T. Shimizu, K. Tateno et al., "Extensor musculature of the cervical spine after laminoplasty: morphologic evaluation by coronal view of the magnetic resonance image," *Spine*, vol. 26, no. 20, pp. 2220–2226, 2001.

[73] T. Shiraishi, K. Fukuda, Y. Yato, M. Nakamura, and T. Ikegami, "Results of skip laminectomy: minimum 2-year follow-up study compared with open-door laminoplasty," *Spine*, vol. 28, no. 24, pp. 2667–2672, 2003.

[74] J. P. Nolan Jr. and H. H. Sherk, "Biomechanical evaluation of the extensor musculature of the cervical spine," *Spine*, vol. 13, no. 1, pp. 9–11, 1988.

[75] H. Matsuzaki, M. Hoshino, T. Kiuchi, and S. Toriyama, "Dome-like expansive laminoplasty for the second cervical vertebra," *Spine*, vol. 14, no. 11, pp. 1198–1203, 1989.

[76] H. S. An, R. Gordin, and K. Renner, "Anatomic considerations for plate-screw fixation of the cervical spine," *Spine*, vol. 16, no. 10, pp. S548–S551, 1991.

[77] K. Yonenobu, E. Wada, and K. Ono, "Laminoplasty," in *The Cervical Spine*, C. R. Clark, Ed., pp. 1057–1071, Lippincott Williams and Wilkins, Philadelphia, Pa, USA, 2005.

[78] K. Satomi, J. Ogawa, Y. Ishii, and K. Hirabayashi, "Short-term complications and long-term results of expansive open-door laminoplasty for cervical stenotic myelopathy," *Spine Journal*, vol. 1, no. 1, pp. 26–30, 2001.

[79] K. Yonenobu, N. Hosono, M. Iwasaki, M. Asano, and K. Ono, "Neurologic complications of surgery for cervical compression myelopathy," *Spine*, vol. 16, no. 11, pp. 1277–1282, 1991.

[80] Y. Uematsu, Y. Tokuhashi, and H. Matsuzaki, "Radiculopathy after laminoplasty of the cervical spine," *Spine*, vol. 23, no. 19, pp. 2057–2062, 1998.

[81] N. Tsuzuki, R. Abe, K. Saiki, and L. Zhongshi, "Extradural tethering effect as one mechanism of radiculopathy complicating posterior decompression of the cervical spinal cord," *Spine*, vol. 21, no. 2, pp. 203–211, 1996.

[82] N. Tsuzuki, R. Abe, K. Saiki, and K. Okai, "Paralysis of the arm after posterior decompression of the cervical spinal cord. II. Analyses of clinical findings," *European Spine Journal*, vol. 2, no. 4, pp. 197–202, 1993.

[83] N. Tsuzuki, L. Zhogshi, R. Abe, and K. Saiki, "Paralysis of the arm after posterior decompression of the cervical spinal cord. I. Anatomical investigation of the mechanism of paralysis," *European Spine Journal*, vol. 2, no. 4, pp. 191–196, 1993.

[84] M. Yoshida, T. Tamaki, M. Kawakami et al., "Does reconstruction of posterior ligamentous complex with extensor musculature decrease axial symptoms after cervical laminoplasty?" *Spine*, vol. 27, no. 13, pp. 1414–1418, 2002.

[85] Y. Saruhashi, S. Hukuda, A. Katsuura, K. Miyahara, S. Asajima, and K. Omura, "A long-term follow-up study of cervical spondylotic myelopathy treated by 'French window' laminoplasty," *Journal of Spinal Disorders*, vol. 12, no. 2, pp. 99–101, 1999.

[86] M. Yoshida, K. Otani, K. Shibasaki, and S. Ueda, "Expansive laminoplasty with reattachment of spinous process and extensor musculature for cervical myelopathy," *Spine*, vol. 17, no. 5, pp. 491–497, 1992.

[87] M. Takayasu, T. Takagi, T. Nishizawa, K. Osuka, T. Nakajima, and J. Yoshida, "Bilateral open-door cervical expansive laminoplasty with hydroxyapatite spacers and titanium screws," *Journal of Neurosurgery*, vol. 96, no. 1, pp. 22–28, 2002.

[88] K. Miyazaki, K. Tada, Y. Matsuda, M. Okuno, T. Yasuda, and H. Murakami, "Posterior extensive simultaneous multisegment decompression with posterolateral fusion for cervical myelopathy with cervical instability and kyphotic and/or S-shaped deformities," *Spine*, vol. 14, no. 11, pp. 1160–1170, 1989.

[89] S. Kokubun, T. Sato, Y. Ishii, and Y. Tanaka, "Cervical myelopathy in the Japanese," *Clinical Orthopaedics and Related Research*, no. 323, pp. 129–138, 1996.

[90] M. Kawakami, T. Tamaki, H. Iwasaki, M. Yoshida, M. Ando, and H. Yamada, "A comparative study of surgical approaches for cervical compressive myelopathy," *Clinical Orthopaedics and Related Research*, no. 381, pp. 129–136, 2000.

[91] S. Hukuda, T. Mochizuki, and M. Ogata, "Operations for cervical spondylotic myelopathy. A comparison of the results of anterior and posterior procedures," *Journal of Bone and Joint Surgery B*, vol. 67, no. 4, pp. 609–615, 1985.

[92] W. M. Yue, C. T. Tan, S. B. Tan, S. K. Tan, and B. K. Tay, "Results of cervical laminoplasty and a comparison between single and double trap-door techniques," *Journal of Spinal Disorders*, vol. 13, no. 4, pp. 329–335, 2000.

[93] S. B. Kaminsky, C. R. Clark, and V. C. Traynelis, "Operative treatment of cervical spondylotic myelopathy and radiculopathy. A comparison of laminectomy and laminoplasty at five year average follow-up," *The Iowa orthopaedic journal*, vol. 24, pp. 95–105, 2004.

[94] J. G. Heller, C. C. Edwards II, H. Murakami, and G. E. Rodts, "Laminoplasty versus laminectomy and fusion for multilevel cervical myelopathy: an independent matched cohort analysis," *Spine*, vol. 26, no. 12, pp. 1330–1336, 2001.

[95] C. C. Edwards II, J. G. Heller, and H. Murakami, "Corpectomy versus laminoplasty for multilevel cervical myelopathy: an independent matched-cohort analysis," *Spine*, vol. 27, no. 11, pp. 1168–1175, 2002.

Hindawi Publishing Corporation
Advances in Orthopedics
Volume 2012, Article ID 493605, 5 pages
doi:10.1155/2012/493605

Review Article

The Biomechanics of Cervical Spondylosis

Lisa A. Ferrara

OrthoKinetic Testing Technologies, LLC, Southport, NC 28461, USA

Correspondence should be addressed to Lisa A. Ferrara, lisa@orthokintech.com

Received 23 July 2011; Accepted 20 October 2011

Academic Editor: Joseph S. Butler

Aging is the major risk factor that contributes to the onset of cervical spondylosis. Several acute and chronic symptoms can occur that start with neck pain and may progress into cervical radiculopathy. Eventually, the degenerative cascade causes desiccation of the intervertebral disc resulting in height loss along the ventral margin of the cervical spine. This causes ventral angulation and eventual loss of lordosis, with compression of the neural and vascular structures. The altered posture of the cervical spine will progress into kyphosis and continue if the load balance and lordosis is not restored. The content of this paper will address the physiological and biomechanical pathways leading to cervical spondylosis and the biomechanical principles related to the surgical correction and treatment of kyphotic progression.

1. Introduction

Cervical spondylosis is a common progressive degenerative disorder of the human spine often caused by the natural aging process. It is defined as "vertebral osteophytosis secondary to degenerative disc disease" due to the osteophytic formations that occur with progressive spinal segment degeneration [1–3]. Early spondylosis is associated with degenerative changes within the intervertebral disc where desiccation of the disc occurs, thus causing overall disc height loss and a reduction in the ability of the disc to maintain or bear additional axial loads along the cervical spine [3, 4]. At birth, the intervertebral discs are healthy, with the proteoglycan matrix within the nucleus pulposus maintaining a 70% to 90% water content which declines with aging [4]. As the water content declines within the nucleus pulposus, the once healthy glistening gelatinous appearance changes into a darkened and discolored fibrous "crabmeat" consistency with a loss in water content and a loss in the structural integrity.

Once the disc starts to degenerate and a loss in disc height occurs, the soft tissue (ligamentous and disc) becomes lax, resulting in ventral and/or dorsal margin disc bulge and buckling of the ligaments surrounding the spinal segment, accompanied by a reduction in the structural and mechanical integrity of the supportive soft tissues across a cervical segment. As the ventral column becomes compromised, there is greater transfer of the axial loads to the uncovertebral joints and also along the dorsal column, resulting in greater loads borne by the facet joints. As axial loads are redistributed to a greater extent along the dorsal column of the cervical spine, the facet joints are excessively loaded resulting in hypertrophic facets with possible long-term ossification of the posterior longitudinal ligament [1]. When the load balance of the cervical spine is altered and disrupted, as is the situation with cervical degeneration, the remaining functional and supportive structures along the cervical spinal column will absorb the added stress that is transferred to the surrounding structures and adjacent levels along the spine. Eventually these structures will also be excessively loaded, resulting in a cascade of events of further degeneration and tissue adaptation. Overloading the soft tissues and bone eventually causes osteophytes to form in response to excessive loading in order to compensate for greater stresses to the surrounding bone and soft tissue (Figure 1).

Cervical spondylosis presents itself in three symptomatic forms as neck pain, cervical radiculopathy, and cervical myelopathy. Neck pain and cervical radiculopathy (nerve root involvement) can be acute, subacute, or chronic conditions resulting from various stages along the degenerative cascade [1]. Cervical myelopathy is less frequent in the spondylotic patient and occurs in older patients with symptoms such as neck, subscapular, or shoulder pain, accompanied by shock

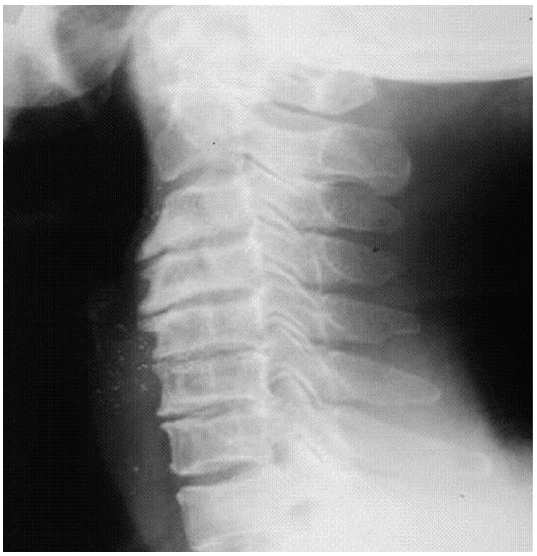

Figure 1: Radiographic representation of cervical spondylosis.

sensations and numbness in the extremities [1, 5–7]. Cervical myelopathy involves motor and reflex changes indicative of a more chronic condition and can eventually result in spastic weakness and numbness of the extremities, loss of dexterity, spastic gait, dorsal column function loss, and painful paresthesias [1, 6, 8, 9]. These chronic symptoms can eventually become permanent with poor prognosis.

2. Pathogenesis and Etiology of Cervical Spondylosis

The primary cause of cervical spondylosis is age-related degeneration. However, there are some exceptions where spinal injuries to the disc can augment the degenerative process in the younger patient. A secondary manifestation of spondylosis is related to the compression of the vascular and neural structures caused by a loss in the disc height and impinging osteophytes that contribute to the numbness, shock-like sensations, pain, and chronic motor and sensory affects, which if not corrected may lead to permanent disabilities.

It is this physiological degenerative cascade that contributes to the biomechanical changes that can cause neural and vascular compression, pain, and loss of function. Figure 2 illustrates the chain of events of cervical spondylosis starting with the biomechanical changes that can result in neural and vascular compression. Early changes in the proteoglycan matrix cause an increase in the ratio of keratin sulfate to chondroitin sulfate resulting in the loss of water within the disc. This desiccation causes the nucleus pulposus to lose elasticity, shrink in size, and lose the ability to bear axial loads. Since the dorsal fibers of the annulus are thinner than the ventral aspect, there is a path of least resistance through the annulus for a nucleus pulposus herniation. The annular fibers become mechanically compromised with further disc desiccation and are unable to effectively maintain axial loads, causing buckling of the spinal ligaments and annular fibers under compressive loads, which are further exacerbated with eccentric loads (i.e., flexion, torsion, and bending) [1–3]. The resultant loss in disc height causes the discs to bulge, the ligamentous tissue to become lax and buckle, and the ventral aspect of the cervical spine to compress. At this point, there are significant alterations in the load distribution along the cervical spinal column, with an end result of kyphosis of the cervical spine. If not reversed, the kyphosis will continue to progress, the annular and Sharpey's fibers will separate from the vertebral periphery and bony endplates, resulting in reactive bone formation where the fibers have been separated. These resultant bone spurs can be formed along the ventral or dorsal margin of the cervical spine and within the canals in response to the altered biomechanical loads, causing compression of the neural and vascular structures.

The unique properties of bone and soft tissue are the ability to regenerate and remodel the tissue along the lines of loading and stress application, thus regaining the structural integrity. However, if the load balance along the spinal column is altered and is not restored, the tissue will remodel along the altered load and stress planes, causing the tissue to remodel along new planes of loading. Since osteophyte or bone spur formation will occur in response to excessive eccentric loads, new bone will form in areas of greater stress and will be resorbed in areas of less stress.

The loss in the axial load bearing capabilities of the degenerative segment leads to a disruption in the load transfer along the neutral axis of the spinal column, also known as a change in the overall load balance, thereby transferring greater loads to the uncovertebral and facet joints, further accelerating the formation of spurs and osteophytes into the surrounding foramen, with greater angulation of the cervical spinal column ventrally. The ventral angulation along the cervical spine is a continuous cascade of mechanical events. As the lordotic angle is reduced, the moment arm about the center of rotation or instantaneous axis of rotation (IAR) is increased, therefore, changing the overall sagittal angulation and reducing the spinal canal diameter [1, 3, 4, 9].

3. Histologic and Immunohistochemical Findings with the Spondylotic Disc

Elegant studies have been performed to characterize the histological and immunohistochemical differences between cervical disc herniation and spondylosis. Disc herniation can be an early contributor to spondylosis, as herniation creates a loss in the mechanical integrity of the intervertebral disc due to the extrusion or bulging of the nucleus pulposus through compromised annular fibers. The herniation often occurs dorsally, as the dorsal annular fibers are thinner and provide a less resistant pathway for the compromised nucleus pulposus matter. The intervertebral discs with surrounding tissues, subchondral vertebral bone, cartilaginous endplate, and posterior longitudinal ligaments were collected en bloc during decompression surgeries in 198 patients presenting with cervical intervertebral disc herniation resulting in 248 discs for evaluation. An additional 252 discs were harvested

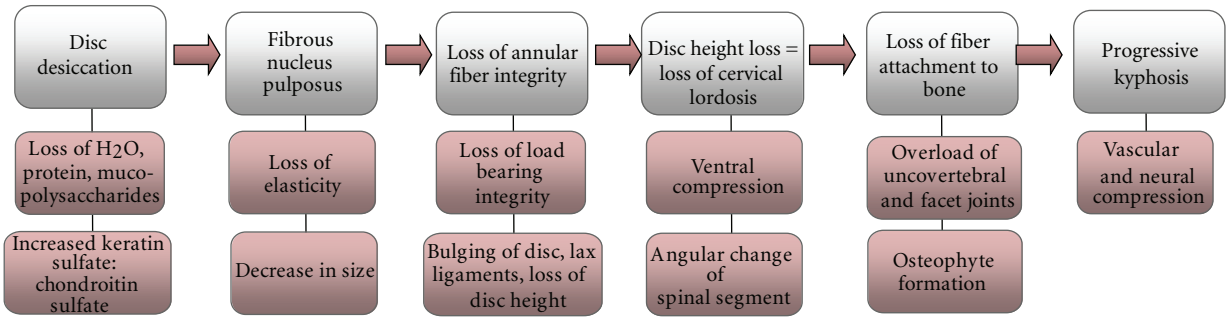

Figure 2: Pathophysiological and biomechanical pathway of cervical spondylosis.

in a similar manner from 166 patients presenting with cervical spondylosis to provide a histological and immunohistochemical assessment between cervical spondylosis and disc herniation [10]. The disc-herniated patients were younger (49.9 years, range 25–78 years) than the cervical spondylosis (mean age of 59.6 years, ranging from 32 to 83 years), with all patients presenting with signs and symptoms of radiculopathy, myelopathy, or myeloradiculopathy with an average duration of symptoms prior to surgery of 3.2 months. The control discs (free from cervical radiculopathy and myelopathy) were harvested during autopsies taken from eight donors with a mean age of 73 years. Chondrocyte proliferation, a change in the granular matrix, fibrocartilage degeneration of the annulus fibrosus and nucleus pulposus, cell proliferation, cartilage disorganization, cracks, microfractures, sclerotic endplates, and vascularization of the disc were parameters used to grade the level of disc degeneration. The herniated cervical discs demonstrated granulation tissue with new vascularization and an infiltration of CD68-positive macrophages surrounding the herniated tissue with greater advanced degeneration in the outer layer of the annulus [10]. The spondylotic discs demonstrated thicker bony endplates and tumor necrosis factor and matrix metalloproteinase with greater advanced degeneration in the cartilaginous endplates and inner layer of the annulus. In essence, there were distinct differences and markers for distinguishing herniated discs from spondylotic discs.

4. Biomechanics of the Spondylotic Spine

Kyphotic deformity with neural and vascular compression often accompanies cervical spondylotic myelopathy. Initially the loss of disc height as a consequence of disc desiccation and altered load transmission along the cervical spine can lead to postural changes (Figure 3(b)). As spinal cycling continues during activities of daily living, the disc will continue to lose height ventrally. This altered posture will result in an increased moment arm about the point of central rotation or the IAR. In the healthy spine, axial loads are applied along the IAR and the loads are supported along the ventral column of the spine. However, with altered posture, the axial load profile along the cervical spine changes as the ventral column (vertebral bodies, disc, and ligamentous tissue) can no longer maintain these loads, and there is a transfer of the loads and stresses to the surrounding bony elements. Loss of the lordotic posture induces a greater moment arm at the point of rotation (point d in Figures 3(b) and 3(c)) when an axial load is applied. Without restoration of the native lordotic posture which will restore the "load balance" along the cervical spine, further axial loading will induce further progression of the kyphotic posture (Figure 3(c)).

Halting the progression of kyphosis related to cervical spondylosis is the main objective for surgical intervention and can be treated through ventral surgical fixation or through a combined ventral and dorsal approach of stabilizing fixation. Ventral approaches for surgical correction of this disorder provide the necessary ventral column support to resist further compression and angulation of the cervical spine and can provide improved decompression of the neural and vascular structures.

Numerous in vitro and in vivo studies have confirmed that approximately 80% of the axial load is transmitted along the ventral column of the human spine with improved resistance to higher axial loads and better biomechanical stability when ventral column stabilization is employed [1, 3, 4, 11]. A biomechanically challenging kyphotic posture may require 360° of correction which provides both ventral and dorsal column support to the degenerative sites. However, the disadvantages with ventral fixation occur when suboptimal bone quality is present, as is often the case with these patients. For both the ventral and dorsal surgical approaches used for kyphotic deformity correction, poor bone quality contributes to suboptimal screw purchase into the surrounding bone, compromising the long-term stability. Furthermore, a long strut graft across a corpectomy for ventral fixation provides a long lever arm with one strut of bone that does not conform to the native lordotic posture of the patient's cervical spine and has an increased risk to subsidence and dislodgment out of the site, resulting in a loss of the lordotic correction. Therefore, multisegmental ventral fixation, such as consecutive intervertebral fusion grafts supplemented with ventral plate fixation, provides multiple points of fixation for better load distribution across each fixation point along the cervical spine. Multiple interbody fusions with multiple screw fixation of the plate will provide better restoration and long-term stability of the lordotic posture, while also

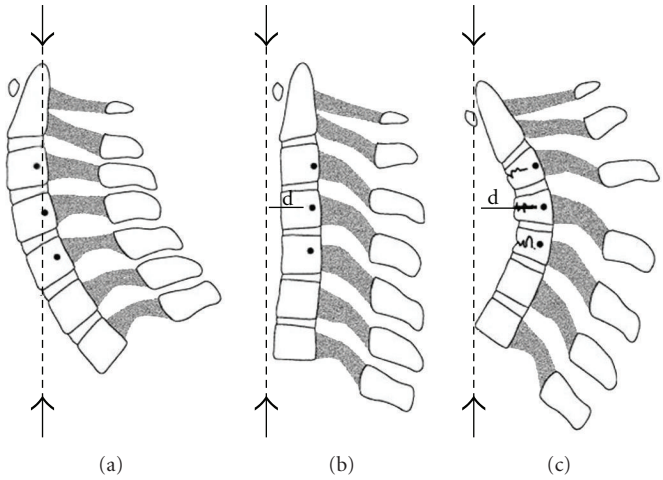

Figure 3: Cervical spine postural changes related to the degenerative process will lead to the spondylotic spine. In the normal lordotic posture of the cervical spine, the axial force is applied along the instantaneous axis of rotation (IAR) with no deviation from this neutral point of rotation (a). However, with early disc height loss, the lordotic posture is reduced and the axial force is now offset from the instantaneous axis of rotation (d) causing a moment arm at this point of rotation. If an axial force is placed at a particular distance from the center of rotation or the IAR, a bending moment is applied about this point (b), and it will take less force to induce injury to the apical spinal segment. The larger a moment arm, the greater the bending moment, which will cause further progression of the kyphosis (c). (Taken from Benzel EC: Biomechanics of Spine Stabilization. Rolling Meadows, American Association of Neurological Surgeons Publications, 2001 [6].)

providing neural decompression (Figure 4). Mechanically, this configuration provides a three-point bend application of opposing forces to the compromised spinal segment(s) to provide improved maintenance of the lordotic posture and greater resistance to translational loads (arrows in Figure 4). Posterior fixation can also accompany segmental ventral fusions, provided the posterior fixation does not offload the interbody fusion grafts. Posterior fixation combined with ventral support can provide similar translational resistance and three-point bend stability for kyphotic correction.

5. Summary

Fusion of the degenerative unstable spine is often a final alternative to alleviate a painful spinal segment. Ventral interbody fusion is incorporated in a fusion construct to maximize the axial load bearing capacity of the spine while limiting the pathologic motion across a spinal segment. In situations such as kyphotic deformity correction, multisegmental ventral interbody fusions can provide the necessary ventral column support incorporating multiple points of fixation to resist the demanding translational, rotational, and bending loads placed upon on the degenerative kyphotic cervical spine and will provide ample strength to maintain the restored lordotic posture. Ventral support using multiple interbody fusion grafts supplemented with dorsal fixation across each level will also provide similar mechanical attributes as that of ventral support, where both approaches towards kyphotic deformity will allow for better force distribution across many points of fixation, thus minimizing the risk of stress risers that can cause graft subsidence, expulsion, screw loosening, or loss of fixation. Biomechanically, these strategies will improve the restoration of the lordotic posture for long-term

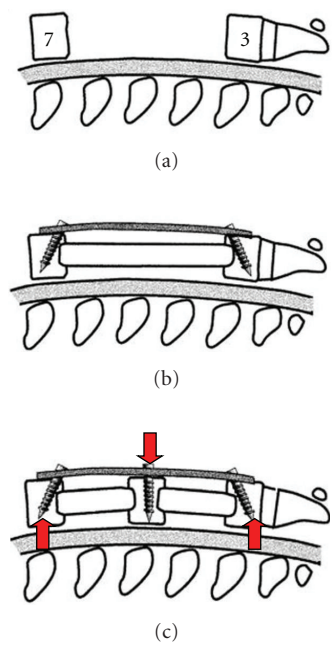

Figure 4: Ventral corpectomy approach with one large strut grafts and two points of screw fixation for kyphotic deformity correction. A large strut graft without multiple points of fixation may not maintain the lordotic posture and can subside into the vertebral endplates, resulting in loss of fixation and loss of the lordotic restoration. However, multiple interbody fusions with supplemental plate fixation and multiple points of screw fixation distribute the loads over greater points of fixation, thereby reducing the risk to localized stress risers, providing improved resistance to translation, loss of lordosis, and subsidence. (Taken from Benzel EC: Biomechanics of Spine Stabilization. Rolling Meadows, American Association of Neurological Surgeons Publications, 2001 [6].)

fixation and stability. By restoring the lordotic posture of the cervical spine, the load balance is restored, where 80% of the axial loads transmitted along the ventral column is aligned at the IAR of the spinal column, effectively, halting the progression of the kyphotic curvature. Segmental fixation results in reduced localized forces and stresses at each spinal level and across the instrumentation, with reduced stresses on each screw and across each graft site for improved long-term fixation.

References

[1] D. Shedid and E. C. Benzel, "Cervical spondylosis anatomy: pathophysiology and biomechanics," *Neurosurgery*, vol. 60, no. 1, supplement 1, pp. 7–13, 2007.

[2] P. R. Weinstein, G. Ehni, and C. B. Wilson, *Lumbar Spondylosis: Diagnosis, Management, and Surgical Treatment*, Year Gook Medical Publishers, Chicago, Ill, USA, 1997.

[3] E. C. Benzel, *Biomechanics of Spine Stabilization*, chapters 1-2, American Association of Neurological Surgeons, Rolling Meadows, Ill, USA, 2001.

[4] A. White and M. M. Panjabi, *Clinical Biomechanics of the Spine*, J.B. Lippincott, Philadelphia, Pa, USA, 2nd edition, 1990.

[5] O. Arnasson, C. A. Carlsson, and L. Pellettieri, "Surgical and conservative treatment of cervical spondylotic radiculopathy and myelopathy," *Acta Neurochirurgica*, vol. 84, no. 1-2, pp. 48–53, 1987.

[6] S. Asgari, "Cervical spondylotic myelopathy," in *Neurosurgery '96:Manual of Neurosurgery*, J. D. Palmer, Ed., pp. 750–754, Churchill Livingstone, New York, NU, USA, 1996.

[7] P. H. Crandall and U. Batzdorf, "Cervical spondylotic myelopathy," *Journal of Neurosurgery*, vol. 25, no. 1, pp. 57–66, 1966.

[8] M. D. Connell and S. W. Wiesel, "Natural history and pathogenesis of cervical disk disease," *Orthopedic Clinics of North America*, vol. 23, no. 3, pp. 369–380, 1992.

[9] M. J. Ebersold, M. C. Pare, and L. M. Quast, "Surgical treatment for cervical spondylitic myelopathy," *Journal of Neurosurgery*, vol. 82, no. 5, pp. 745–751, 1995.

[10] Y. Kokubo, K. Uchida, S. Kobayashi et al., "Herniated and spondylotic intervertebral discs of the human cervical spine: histological and immunohistological findings in 500 en bloc surgical samples. Laboratory investigation," *Journal of Neurosurgery: Spine*, vol. 9, no. 3, pp. 285–295, 2008.

[11] M. P. Steinmetz, T. J. Stewart, C. D. Kager, E. C. Benzel, and A. R. Vaccaro, "Cervical deformity correction," *Neurosurgery*, vol. 60, no. 1, supplement 1, pp. 90–97, 2007.

Hindawi Publishing Corporation
Advances in Orthopedics
Volume 2012, Article ID 783762, 6 pages
doi:10.1155/2012/783762

Review Article

Cervical Spondylotic Myelopathy: Factors in Choosing the Surgical Approach

Praveen K. Yalamanchili, Michael J. Vives, and Saad B. Chaudhary

Department of Orthopaedics, University of Medicine and Dentistry-New Jersey Medical School, 140 Bergen Street, Suite D1619, Newark, NJ 07103, USA

Correspondence should be addressed to Michael J. Vives, vivesmj@umdnj.edu

Received 16 July 2011; Accepted 20 October 2011

Academic Editor: Joseph S. Butler

Cervical spondylotic myelopathy is a progressive disease and a common cause of acquired disability in the elderly. A variety of surgical interventions are available to halt or improve progression of the disease. Surgical options include anterior or posterior approaches with and without fusion. These include anterior cervical discectomy and fusion, anterior cervical corpectomy and fusion, cervical disc replacement, laminoplasty, laminectomy with and without fusion, and combined approaches. Recent investigation into the ideal approach has not found a clearly superior choice, but individual patient characteristics can guide treatment.

1. Introduction

Cervical degenerative disease, or cervical spondylosis, is an age-related change affecting the cervical spinal column. Radiographic evidence of cervical spondylosis can be found in 85% of individuals over sixty years of age [1]. Certain occupations and activities that place increased loads on the head may have a predisposition for cervical degenerative disease. Cervical myelopathy is a clinical syndrome that may result from cervical spondylosis. When cervical myelopathy is a result of spondylosis, it is referred to as cervical spondylotic myelopathy (CSM).

Cervical spondylotic myelopathy manifests as long-tract clinical findings in the upper and lower extremities caused by spinal cord compression [2]. Patients present with a variety of findings, including clumsiness, loss of manual dexterity, difficulty with gait or balance, urinary complaints, motor weakness, sensory changes, and abnormal or pathologic reflexes. Appropriate initial imaging of CSM consists of plain static radiographs and flexion extension views to evaluate for instability. The advancing imaging of choice is magnetic resonance imaging (MRI) of the cervical spine to evaluate the soft tissues about the spine and the spinal cord. Clinical correlation is important when evaluating MRI changes as MRI can be overly sensitive and reveal abnormalities in asymptomatic adults [3]. Electrodiagnostic studies may be helpful to exclude other causes of upper extremity symptoms, such as suspected peripheral nerve entrapment syndromes.

The natural history of CSM is a progression of symptoms in a stepwise fashion over time [4]. Patients with mild myelopathy (that does not interfere with function) may be offered a trial of nonoperative management, whereas progressive, long-standing, or severe myelopathy is candidates for surgical decompression of the spinal cord in the affected areas [5, 6]. Operative intervention may be via anterior, posterior, or combined approaches and with or without fusion. Anterior options include single or multilevel anterior cervical discectomy and fusion (ACDF), anterior cervical corpectomy and fusion (ACCF), and cervical disc replacement (CDR). Posterior options include laminectomy without fusion, laminectomy and instrumented fusion, and laminoplasty. Factors to consider when selecting the operative approach include location of cord compression, number of levels involved, sagittal alignment, instability, associated axial neck pain, and risk factors for pseudoarthrosis.

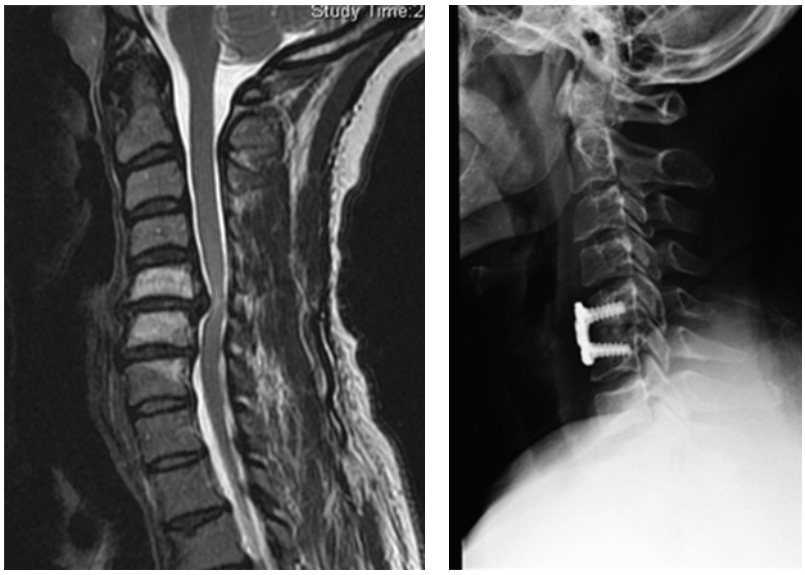

(a) (b)

Figure 1: (a) Sagittal MRI demonstrating C5-6 extruded disc herniation. (b) Lateral radiograph of same patient after undergoing anterior cervical discectomy and fusion.

2. Anterior Surgical Options

The anterior surgical options can be used for both single level and multilevel disease. The anterior approach is generally favored with soft disc herniations, concomitant severe axial neck pain, kyphosis, and with 1-2 levels of involvement (Figure 1).

ACDF utilizes a Smith-Robinson approach to access the anterior surface of the cervical spine. After incision of the platysma, this approach involves little muscle disruption but opening of the pretracheal and prevertebral fascial planes to mobilize the midline structures of the neck. The decompression involves a thorough discectomy with removal of cartilaginous end plates and posterior osteophytes. A left-sided approach is preferred by some due to a more favorable course of the recurrent laryngeal nerve. Adequate decompression of the spinal cord may require removal of posterior osteophytes, partial corpectomy, or removal of the posterior longitudinal ligament (PLL); however all of these procedures increase the risk of injury to the spinal cord. ACCF is an alternative to multilevel ACDF and utilizes a similar approach, with either a transverse or longitudinal incision depending on number of levels. In this technique a central trough of vertebral body is progressively removed with a combination of a high-speed burr and rongeurs (Figure 2).

The trough is centered between the uncovertebral joints, which helps orient the trough over the spinal cord and ensure complete decompression. Care must be taken to avoid eccentric bone removal laterally, endangering the vertebral arteries. A thin shell of the remaining posterior wall and posterior longitudinal ligament can then be removed with microcurrettes and Kerrisons. Fusion with ACDF and ACCF may be achieved with various graft options, including autologous tricortical iliac crest graft, allograft, polyetheretheketone (PEEK), or metal cages or a combination of morsellized bone from the corpectomy plus a structural allograft or cage. Plating is now common, especially with multilevel ACDF and ACCF [7, 8]. Complications with the anterior approach include vertebral artery injury (0.3%), esophageal injury (0.2–0.4%), wound infection (0.2–1.4%), and dysphagia (28–57%) [9]. The cause of dysphagia appears to be multifactorial, including traction on the superior laryngeal nerve, pharyngeal plexus, recurrent laryngeal nerve, and esophageal retraction. Risk factors for dysphagia include age >60, multiple levels, revisions, females, thick plates, and longer preop pain [10].

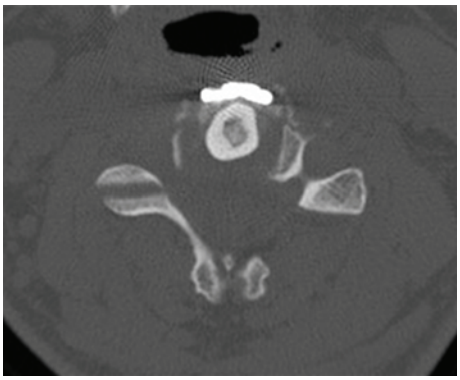

Figure 2: Axial CT scan demonstrating fibula strut graft placed in central corpectomy trough.

Advantages of ACDF or ACCF include ability to directly decompress offending structures, decompress the anterior spinal artery, restore cervical lordosis, and address axial neck pain. Multilevel ACDF is preferred in certain situations over ACCF where the compression is confined to the level of the disc spaces. Also, it is associated with a less blood loss and has a lower risk of graft kick out and catastrophic failure [11].

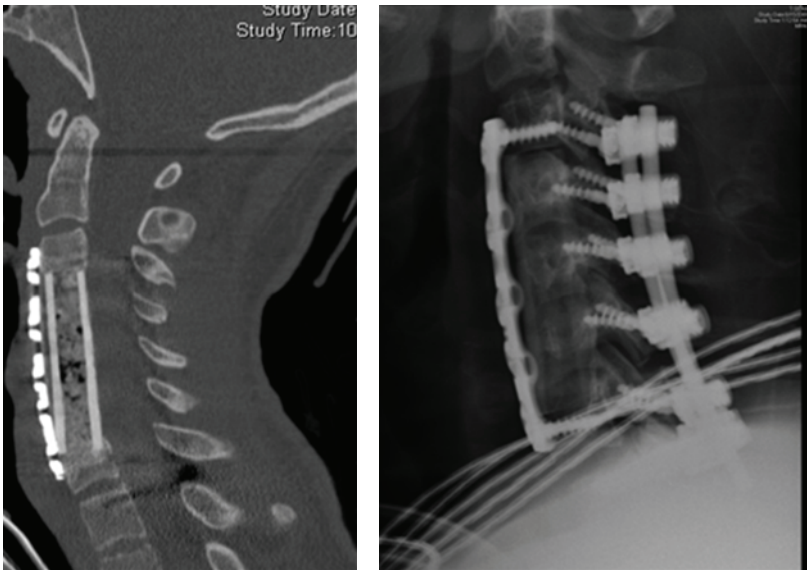

(a) (b)

Figure 3: (a) Sagittal reconstructed CT scan of patient who underwent 3-level corpectomy. (b) Lateral radiograph of same patient. Posterior fusion was performed to increase stability of the construct.

However multilevel ACDF is associated with an increased risk of pseudarthrosis, as high as 54% in three-level fusions [12]. Some surgeons use off-label recombinant human bone morphogenetic protein-2 (rhBMP-2) in these situations, but this should be undertaken with caution as there have been reports of airway compromise due to swelling [13]. ACCF is preferred when compression extends behind the vertebral bodies to ensure that all areas of compression are addressed. When multilevel corpectomies are performed, there is potential for significant plate failure and graft extrusion, so supplemental posterior instrumentation should be considered [14] (Figure 3).

Some have suggested that a potential benefit of ACCF is that fewer graft surfaces are required to fuse than multilevel ACDF (i.e., for a decompression at C4-5/C5-6, ACDF would require 4 surfaces to fuse versus 2 surfaces if treated with ACCF). Multiple studies have compared the fusion rates of ACCF and ACDF in an attempt to verify this benefit. Nirala et al. investigated 201 patients with multilevel noninstrumented anterior fusion and found that with more levels ACCF had a higher fusion rate than ACDF [15]. Another study investigated 52 patients with multilevel anterior fusion with autograft and plate fixation and found similar clinical and fusion rates between ACCF and ACDF [16]. With modern plating techniques, it appears that fusion rates are similar between the two techniques [17]. A hybrid technique, combining selected corpectomies and discectomies, can be utilized where there is both retrodiscal and retrovertebral compression. Such a construct can increase stability and obviate the need for posterior supplementation. Shen et al. investigated the pseudarthrosis rate of multilevel anterior cervical fusion with rhBMP-2 and allograft using a hybrid technique in 127 patients [18]. Overall pseudarthrosis rate was 10%, with 4% for three levels, 17% for four levels, and 22% for five levels. Nonunions typically occurred at the lowest level.

CDR is another anterior option in cases where cord compression is confined to the retrodiscal region. As a nonfusion option, this may provide the theoretical benefit of decreasing adjacent segment degeneration. Buchowski et al. compared ACDF with CDR for myelopathy at a single level disc space [19]. These authors found similar improvement in neurologic status between the two groups at two years. Recently two-level CDR has come under investigation [20].

3. Posterior Surgical Options

The posterior surgical options are generally utilized for multilevel compression, such as in cases of congenital stenosis, older patients with advanced multilevel spondylosis, and certain cases of ossification of the posterior longitudinal ligament (OPLL) [21, 22]. The posterior approach relies on decompression through both direct removal of offending posterior structures and indirectly, through spinal cord translation posteriorly [23]. Therefore when spinal cord compression is from anterior structures, patients should have maintenance of lordosis or correctable kyphosis to permit adequate indirect decompression [24]. Posterior approaches utilize a midline approach through the posterior cervical skin and musculature followed by subperiosteal dissection of the selected levels. Extent of dissection laterally over the facets is dependent on whether a concomitant fusion is to be performed.

Laminoplasty increases the effective diameter of the spinal canal while preserving the posterior elements of the cervical spine as a biologic covering over the spinal canal. Laminoplasty requires at least 10 degrees of lordosis to allow

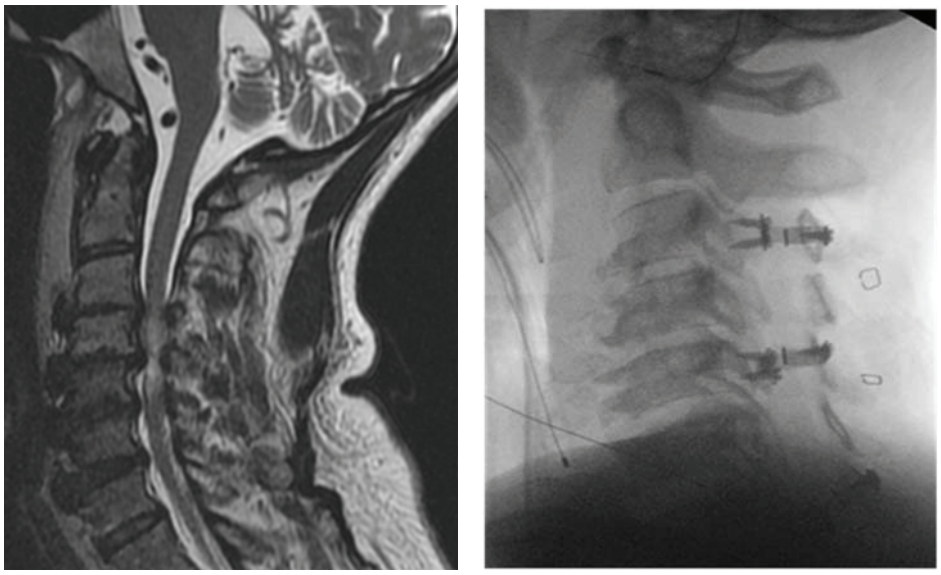

(a) (b)

Figure 4: (a) Sagittal MRI of a patient with multilevel stenosis and preserved lordosis. (b) Lateral radiograph of same patient after canal-expanding laminoplasty.

posterior shift of the spinal cord for indirect decompression [25]. In the open-door technique, two troughs are created at the junction of the lateral masses and lamina with the use of a high-speed burr. One side is completed with microcurrettes or Kerrison rongeurs, the other side left with a thin shell of bone that is then "greensticked" creating a hinge. Once opened, the door can be kept patent with a variety of techniques including suture or wiring of the spinous process to the facet joint, by insertion of a spacer within the opening, or with miniplate and screw fixation (Figure 4).

The main advantage of laminoplasty is the avoidance of fusion. Despite this, patients do experience decreased range of motion postoperatively of up to 50% [26]. Since fusion is not performed, the patient requires preexisting cervical stability, and upright and/or flexion-extension radiographs should be considered to confirm this preoperatively. Laminoplasty has been compared to corpectomy and laminectomy with fusion and has been shown to have similar clinical outcomes to both [27, 28]. Complications include C5 nerve root palsy, kyphosis, wound complications, and persistent or new axial neck pain [26, 29].

Laminectomy involves removal of the lamina and ligamentum flavum over the desired levels and can be performed with or without fusion and instrumentation. Laminectomy without fusion is generally restricted to patients with preserved lordosis who are poor candidates for fusion, since significant rates of progressive postoperative kyphosis have been reported [30, 31]. Instrumented fusion should be utilized for most cases, especially in circumstances of correctable kyphosis and instability. A multitude of instrumentation and screw techniques as well as graft choices exist and can be utilized at the discretion of the individual surgeon. Complications of multilevel laminectomy and fusion include C5 nerve root palsy, wound complications, and hardware failure [2]. In cases of long multilevel laminectomy and fusion, caudal fixation in the C7 lateral masses is suboptimal due to their small size. Pedicle screws at either C7 or the top 2 thoracic vertebrae decrease the chance of distal fixation failure in these long constructs (Figure 5).

With the aforementioned considerations in mind, the primary indication for a combined anterior and posterior approach is multilevel compression in the setting of fixed kyphosis, especially if 2 or more corpectomies must be performed. It can also be considered in patients with localized disease and poor bone quality or high risk for pseudarthrosis. Konya et al. reported on 40 patients treated with combined anterior and posterior approaches for CSM [32]. All patients had three- to four-level disease. At one-year follow-up neurologic function was improved in all patients with a 97.5% fusion rate with no reported instrumentation complications. The exact number of levels to consider combined approach is still debated.

4. Comparative Efficacy

Recently a systematic review sponsored by the American Association of Neurological Surgeons (AANS)/the Congress of Neurological Surgeons (CNS) was performed to develop evidence-based guidelines for choosing among the available surgical options for treatment of CSM [17]. The National Library of Medicine and Cochrane Databases were queried using MeSH headings and keyword regarding anterior and posterior surgery and CSM. An evidentiary table was assembled to summarize the quality of evidence from I to III (lowest). Recommendations were formulated containing degree of strength based on Scottish Intercollegiate Guidelines. Most of the manuscripts were found to be Class III. The results of the paper were that ACDF, ACCF, laminoplasty,

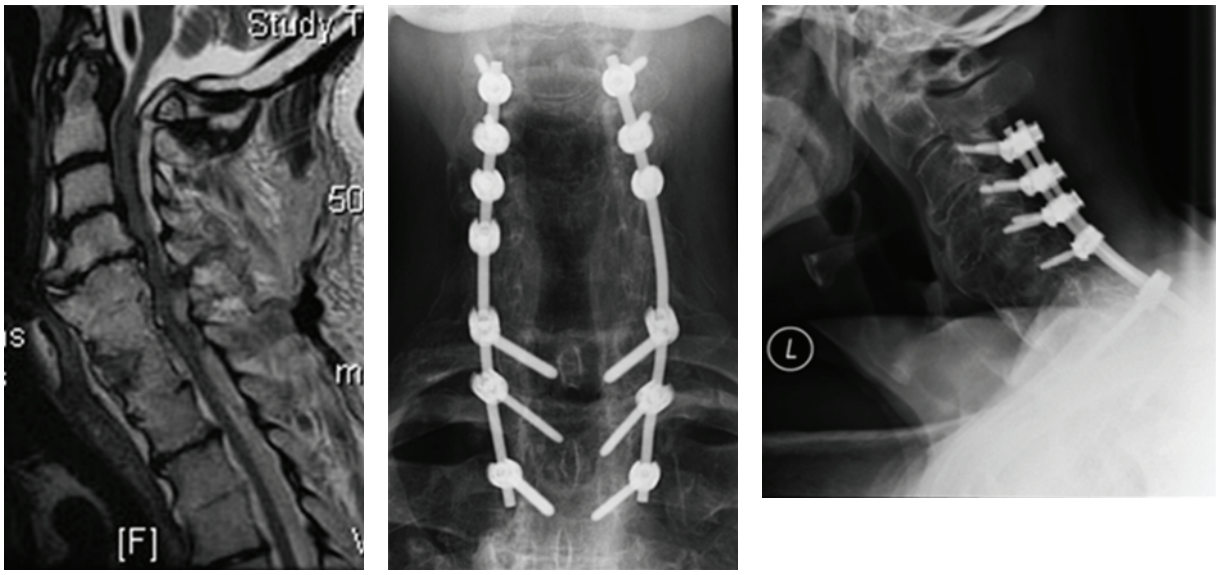

(a) (b) (c)

Figure 5: (a) Sagittal MRI of a patient with severe multilevel spondylosis and stenosis. (b-c) Anteroposterior (b) and lateral (c) radiographs of same patient after multilevel laminectomy and fusion. Note that distal fixation was achieved with pedicle screws which have increased pullout resistance compared with lateral mass fixation.

laminectomy, and laminectomy with fusion all yielded similar near term functional improvements for CSM. Laminectomy without fusion, however, is associated with late deterioration. Another recent systematic review of retrospective cohort studies showed that ACCF, ACDF, laminoplasty, and laminectomy and fusion yielded similar neurologic recovery [33]. The major differences between the groups were the associated complications. Therefore it appears that, given the available literature, the choice of surgical approach will be more dependent on the individual patient factors described previously than the superiority of any one surgical option. This clinical equipoise has been the motivating factor for interest in pursuing a prospective randomized clinical trial and for the distinction of CSM as one of the national health research priorities for comparative effectiveness research by the Institute of Medicine (Medicine Io; Initial National Priorities for Comparative Effectiveness Research; http://www.iom.edu/. Accessed May 31, 2011).

5. Conclusions

Cervical spondylotic myelopathy is a progressive disease that often requires surgical intervention. A variety of surgical options exist, including anterior and posterior approaches with and without fusion. Evidence-based review has not clearly shown one technique to be clinically superior to another. Therefore decision-making will depend on individual patient factors and associated approach-related complications. Factors to consider include location of cord compression, number of levels involved, sagittal alignment, instability, associated axial neck pain, and risk factors for pseudoarthrosis.

References

[1] M. Matsumoto, Y. Fujimura, N. Suzuki et al., "MRI of cervical intervertebral discs in asymptomatic subjects," *The Journal of Bone and Joint Surgery B*, vol. 80, no. 1, pp. 19–24, 1998.

[2] R. D. Rao, B. L. Currier, T. J. Albert et al., "Degenerative cervical spondylosis: clinical syndromes, pathogenesis, and management," *The Journal of Bone and Joint Surgery A*, vol. 89, no. 6, pp. 1360–1378, 2007.

[3] L. M. Teresi, R. B. Lufkin, and M. A. Reicher, "Asymptomatic degenerative disk disease and spondylosis of the cervical spine: MR imaging," *Radiology*, vol. 164, no. 1, pp. 83–88, 1987.

[4] S. Nurick, "The natural history and the results of surgical treatment of the spinal cord disorder associated with cervical spondylosis," *Brain*, vol. 95, no. 1, pp. 101–108, 1972.

[5] M. Matsumoto, K. Chiba, M. Ishikawa, H. Maruiwa, Y. Fujimura, and Y. Toyama, "Relationships between outcomes of conservative treatment and magnetic resonance imaging findings in patients with mild cervical myelopathy caused by soft disc herniations," *Spine*, vol. 26, no. 14, pp. 1592–1598, 2001.

[6] P. G. Matz, L. T. Holly, P. V. Mummaneni et al., "Anterior cervical surgery for the treatment of cervical degenerative myelopathy," *Journal of Neurosurgery: Spine*, vol. 11, no. 2, pp. 170–173, 2009.

[7] J. C. Wang, P. W. McDonough, K. K. Endow, and R. B. Delamarter, "Increased fusion rates with cervical plating for two-level anterior cervical discectomy and fusion," *Spine*, vol. 25, no. 1, pp. 41–45, 2000.

[8] J. C. Wang, P. W. McDonough, K. Endow, L. E. A. Kanim, and R. B. Delamarter, "The effect of cervical plating on single-level anterior cervical discectomy and fusion," *Journal of Spinal Disorders*, vol. 12, no. 6, pp. 467–471, 1999.

[9] A. H. Daniels, K. D. Riew, J. U. Yoo et al., "Adverse events associated with anterior cervical spine surgery," *Journal of*

the American Academy of Orthopaedic Surgeons, vol. 16, no. 12, pp. 729–738, 2008.

[10] L. H. Riley III, R. L. Skolasky, T. J. Albert, A. R. Vaccaro, and J. G. Heller, "Dysphagia after anterior cervical decompression and fusion: prevalence and risk factors from a longitudinal cohort study," *Spine*, vol. 30, no. 22, pp. 2564–2569, 2005.

[11] J. C. Wang, R. A. Hart, S. E. Emery, and H. H. Bohlman, "Graft migration or displacement after multilevel cervical corpectomy and strut grafting," *Spine*, vol. 28, no. 10, pp. 1016–1021, 2003.

[12] M. L. Swank, G. L. Lowery, A. L. Bhat, and R. F. McDonough, "Anterior cervical allograft arthrodesis and instrumentation: multilevel interbody grafting or strut graft reconstruction," *European Spine Journal*, vol. 6, no. 2, pp. 138–143, 1997.

[13] J. B. Stachniak, J. D. Diebner, E. S. Brunk, and S. M. Speed, "Analysis of prevertebral soft-tissue swelling and dysphagia in multilevel anterior cervical discectomy and fusion with recombinant human bone morphogenetic protein-2 in patients at risk for pseudarthrosis: clinical article," *Journal of Neurosurgery: Spine*, vol. 14, no. 2, pp. 244–249, 2011.

[14] A. R. Vaccaro, S. P. Falatyn, G. J. Scuderi et al., "Early failure of long segment anterior cervical plate fixation," *Journal of Spinal Disorders*, vol. 11, no. 5, pp. 410–415, 1998.

[15] A. P. Nirala, M. Husain, and D. K. Vatsal, "A retrospective study of multiple interbody grafting and long segment strut grafting following multilevel anterior cervical decompression," *British Journal of Neurosurgery*, vol. 18, no. 3, pp. 227–232, 2004.

[16] J. C. Wang, P. W. McDonough, K. K. Endow, and R. B. Delamarter, "A comparison of fusion rates between single-level cervical corpectomy and two-level discectomy and fusion," *Journal of Spinal Disorders*, vol. 14, no. 3, pp. 222–225, 2001.

[17] P. V. Mummaneni, M. G. Kaiser, P. G. Matz et al., "Cervical surgical techniques for the treatment of cervical spondylotic myelopathy," *Journal of Neurosurgery: Spine*, vol. 11, no. 2, pp. 130–141, 2009.

[18] H. X. Shen, J. M. Buchowski, J. S. Yeom, G. Liu, N. Lin, and K. D. Riew, "Pseudarthrosis in multilevel anterior cervical fusion with rhBMP-2 and allograft: analysis of one hundred twenty-seven cases with minimum two-year follow-up," *Spine*, vol. 35, no. 7, pp. 747–753, 2010.

[19] J. M. Buchowski, P. A. Anderson, L. Sekhon, and K. D. Riew, "Cervical disc arthroplasty compared with arthrodesis for the treatment of myelopathy. Surgical technique," *The Journal of Bone and Joint Surgery*, vol. 91, supplement 2, pp. 223–232, 2009.

[20] Y. Wang, Z. Xuesong, X. Songhua, L. Ning, W. Zheng, and Z. Mi, "Clinical report of cervical arthroplasty in management of spondylotic myelopathy in Chinese," *Journal of Orthopaedic Surgery and Research*, vol. 1, no. 1, article 13, 2006.

[21] S. Hukuda, T. Mochizuki, and M. Ogata, "Operations for cervical spondylotic myelopathy. A comparison of the results of anterior and posterior procedures," *The Journal of Bone and Joint Surgery B*, vol. 67, no. 4, pp. 609–615, 1985.

[22] P. G. Matz, P. A. Anderson, M. W. Groff et al., "Cervical laminoplasty for the treatment of cervical degenerative myelopathy," *Journal of Neurosurgery: Spine*, vol. 11, no. 2, pp. 157–169, 2009.

[23] T. Sodeyama, S. Goto, M. Mochizuki, J. Takahashi, and H. Moriya, "Effect of decompression enlargement laminoplasty for posterior shifting of the spinal cord," *Spine*, vol. 24, no. 15, pp. 1527–1532, 1999.

[24] K. Suda, K. Abumi, M. Ito, Y. Shono, K. Kaneda, and M. Fujiya, "Local kyphosis reduces surgical outcomes of expansive open-door laminoplasty for cervical spondylotic myelopathy," *Spine*, vol. 28, no. 12, pp. 1258–1262, 2003.

[25] A. Yamazaki, T. Homma, S. Uchiyama, Y. Katsumi, and H. Okumura, "Morphologic limitations of posterior decompression by midsagittal splitting method for myelopathy caused by ossification of the posterior longitudinal ligament in the cervical spine," *Spine*, vol. 24, no. 1, pp. 32–34, 1999.

[26] J. K. Ratliff and P. R. Cooper, "Cervical laminoplasty: a critical review," *Journal of Neurosurgery*, vol. 98, no. 3, supplement, pp. 230–238, 2003.

[27] C. C. Edwards II, J. G. Heller, and H. Murakami, "Corpectomy versus laminoplasty for multilevel cervical myelopathy: an independent matched-cohort analysis," *Spine*, vol. 27, no. 11, pp. 1168–1175, 2002.

[28] P. A. Anderson, P. G. Matz, M. W. Groff et al., "Laminectomy and fusion for the treatment of cervical degenerative myelopathy," *Journal of Neurosurgery: Spine*, vol. 11, no. 2, pp. 150–156, 2009.

[29] N. Hosono, K. Yonenobu, and K. Ono, "Neck and shoulder pain after laminoplasty: a noticeable complication," *Spine*, vol. 21, no. 17, pp. 1969–1973, 1996.

[30] S. Matsunaga, T. Sakou, and K. Nakanisi, "Analysis of the cervical spine alignment following laminoplasty and laminectomy," *Spinal Cord*, vol. 37, no. 1, pp. 20–24, 1999.

[31] T. C. Ryken, R. F. Heary, P. G. Matz et al., "Cervical laminectomy for the treatment of cervical degenerative myelopathy," *Journal of Neurosurgery: Spine*, vol. 11, no. 2, pp. 142–149, 2009.

[32] D. Konya, S. Ozgen, A. Gercek, and M. N. Pamir, "Outcomes for combined anterior and posterior surgical approaches for patients with multisegmental cervical spondylotic myelopathy," *Journal of Clinical Neuroscience*, vol. 16, no. 3, pp. 404–409, 2009.

[33] M. R. A. Cunningham, S. Hershman, and J. Bendo, "Systematic review of cohort studies comparing surgical treatments for cervical spondylotic myelopathy," *Spine*, vol. 35, no. 5, pp. 537–543, 2010.

Hindawi Publishing Corporation
Advances in Orthopedics
Volume 2012, Article ID 480643, 4 pages
doi:10.1155/2012/480643

Review Article

The Natural History and Clinical Presentation of Cervical Spondylotic Myelopathy

Chester K. Yarbrough, Rory K. J. Murphy, Wilson Z. Ray, and Todd J. Stewart

Department of Neurosurgery, Washington University School of Medicine, St. Louis, MO 63110, USA

Correspondence should be addressed to Todd J. Stewart, stewartt@wudosis.wustl.edu

Received 15 July 2011; Accepted 28 October 2011

Academic Editor: Joseph S. Butler

Cervical spondylotic myelopathy (CSM) refers to impaired function of the spinal cord caused by degenerative changes of the cervical spine resulting in spinal cord compression. It is the most common disorder in the United States causing dysfunction of the spinal cord. A literature review of the natural history of mild cervical myelopathy is undertaken. Clinical presentation and current concepts of pathophysiology are also discussed. While many patients with mild signs of CSM will stabilize or improve over time with conservative treatment, the clinical course of a specific individual patient cannot be predicted. Asymptomatic patients with cervical stenosis and abnormalities on electrophysiologic studies may be at higher risk for developing myelopathy.

1. Natural History of Mild Cervical Spondylotic Myelopathy

Cervical spondylosis refers to osteoarthritic degeneration of the cervical spine. Brain et al. suggested symptomatology, whether radiculopathy or myelopathy, resulted from disc protrusion and associated soft tissue abnormalities [1, 2]. Although degeneration can occur secondary to various causes, years of motion and activity, commonly referred to as "wear and tear," is the most common etiology. Several studies have shown in animal models and in humans that excessive motion and repetitive micro-trauma accelerates degenerative changes [3–9]. The accumulation of degenerative changes affects both canal diameter and sagittal mobility of the cervical spine [10]. Additionally, a congenitally narrow spinal canal may predispose one to formation of CSM [11–14]. In current understanding, cervical spondylosis encompasses degenerative changes affecting the uncovertebral joints, facet joints, intervertebral discs, and the other soft tissue and bony components of the cervical spine. While it may affect only a single level, spondylosis has been shown to commonly begin at lower levels with subsequent progressive involvement of multiple spinal levels [15].

While the recommendation for surgical treatment of patients with severe, progressive myelopathy seems straightforward, it is less clear how to properly manage patients with cervical spondylosis and very subtle signs of myelopathy. Several authors have described the clinical course of patients with symptomatic cervical spondylosis. Initial authors supported clinical stability in this patient population. Clarke and Robinson retrospectively described 120 patients with CSM, 26 of whom were treated conservatively [16]. Nearly 80% of these patients presented with weakness or sensory loss in one or more limbs, while 18% presented with pain. Clarke and Robinson showed that approximately 75% of patients showed episodic progression of symptoms with intervening stability, though approximately two-thirds of patients showed subtle clinical decline during periods of stability. In 20% of patients, slow and steady deterioration occurred. In 5%, onset of symptoms and signs was followed by a long period of stability without any additional deterioration. Overall, approximately half of the conservatively managed patients improved at some point in the clinical course [16]. Lees and Turner described 44 patients with CSM and 51 patients with spondylosis without myelopathy [17]. Of the 44 patients with CSM, 28 patients were managed conservatively with a cervical collar, with 17 showing improvement over time [17]. In contrast to the authors listed above, several other groups have suggested that CSM has a largely progressive course over time [18, 19]. Matsumoto et al. described a case series in which one-third of patients with mild CSM

had progression of symptoms while undergoing conservative management [20]. Sadasivan et al. reported 22 patients with CSM of several years duration, all of whom suffered clinical progression of disease over time [21]. It is important to note that the studies described above tended towards patients with mild and moderate disease processes, although some severely affected individuals were also included.

With the creation and subsequent modification of the Japanese Orthopedic Association score for myelopathy [22–24], a statistically valid and reproducible method of assessing CSM allowed further characterization of this patient population. Kada ňka et al. suggested that 80% of patients with mild myelopathy will improve with or without surgery [25, 26]. Shimomura et al. produced similar results, with 80% of patients showing clinically stable myelopathy over a 3-year period [27]. Other authors have found similar results with conservative management [28, 29]. However, subjective self-assessment and general health may decline over time, affecting the recommendation of conservative versus surgical intervention [30].

Because of the varied nature of progression in mild myelopathy, several authors have investigated other methods for identifying patients with either cervical spondylosis or mild cervical spondylotic myelopathy with higher risk of progression to moderate or severe myelopathy. Asymptomatic spondylotic patients with abnormal somatosensory evoked potentials and radiculopathy have shown increased propensity to progress towards clinical myelopathy [31–34]. Interestingly, in their study regarding electrophysiologic findings affecting progression from asymptomatic stenosis to CSM, the degree of compression as measured by the anterior-posterior diameter divided by transverse diameter did not affect development of CSM [32].

Review of the literature shows that the clinical course of cervical myelopathy is variable and that conservative management may result in stability or improvement of symptoms in the majority of patients with mild symptoms [25–29]. Predicting the clinical course of a single patient remains difficult, though some evidence suggests that younger patients and those with mild symptoms are more likely to improve [35].

2. Pathology of CSM

Several authors have described pathologic findings associated with CSM in cadaveric studies of patients with CSM [36–38]. Pathologic findings include atrophy, neuronal loss in gray matter, and demyelination in the surrounding white matter. Interestingly, these findings are similar to those found in patients with transient hypoperfusion. The magnitude of pathologic findings correlates with the length of myelopathy and directly relates to the degree of canal stenosis [36–38]. Several authors have found that imaging findings including diffusion tensor imaging and apparent diffusion coefficient maps also show white-matter tract changes at the corresponding levels of compression [39–41].

3. Clinical Presentations

CSM may present with divergent clinical findings depending on the levels affected, involvement of the neural foramina, and long tract involvement. A variety of neurological signs and symptoms may be present, including sensory changes, reflex abnormalities, decreased dexterity, weakness, gait instability, bowel and bladder dysfunction, spasticity, presence of Hoffman's and/or Babinski's sign, axial neck pain, radiculopathy, and even acute spinal cord injury [42–44]. The variation in symptoms caused by involvement of the various cervical levels results in a large possibility of clinical presentations affecting almost any muscle of the body.

Some authors have attempted to distinguish the various presentations into a categorization schema. Crandall and Batzdorf suggested clinical grounds for classifying patients into transverse lesion syndrome, motor system syndrome, central cord syndrome, Brown-Sequard syndrome, and brachialgia and cord syndrome [45]. Other authors have separated the varying presentations: anatomic involvement, with a lateral or radicular syndrome, medial or myelopathy syndrome, a combined medial and lateral syndrome, a vascular syndrome, and an anterior syndrome [46, 47]. Most frequently, clinicians rely on clinical signs and symptoms of myelopathy rather than the syndrome names above to describe a patient's condition. Severity of symptoms, functional impairment, and progression of symptoms rather than clinical syndrome classification drive decision-making for therapeutic interventions.

As radiographic studies have improved and expanded in use, more patients will likely come for evaluation with radiographic diagnosis of cervical stenosis. Secondary to the explosion of imaging technology and utilization, the patient population seen in spine clinics today may represent a slightly different population than in the past. Given the variability of symptom progression, clinical experience and care should guide management of these patients towards conservative management.

4. Conclusion

Cervical spondylotic myelopathy occurs in age-dependent fashion as degenerative changes occur in the cervical spinal cord. Presenting signs and symptoms are highly variable and may stabilize or improve over time with conservative management. Abnormal electrophysiology and presence of radiculopathy may portend an increased chance of progression from asymptomatic cervical spondylosis to myelopathy.

Abbreviations

CSM: Cervical Spondylotic Myelopathy.

References

[1] W. R. Brain, G. C. Knight, and J. W. D. Bull, "Discussion of rupture of the intervertebral disc in the cervical region," *Proceedings of the Royal Society of Medicine*, vol. 41, no. 8, pp. 509–28, 1948.

[2] W. R. Brain, D. Northfield, and M. Wilkinson, "The neurological manifestations of cervical spondylosis," *Brain*, vol. 75, no. 2, pp. 187–225, 1952.

[3] J. Berge, B. Marque, J. M. Vital, J. Sénégas, and J. M. Caillé, "Age-related changes in the cervical spines of front-line rugby

players," *American Journal of Sports Medicine*, vol. 27, no. 4, pp. 422–429, 1999.

[4] S. Ebara, Y. Yamazaki, T. Harada et al., "Motion analysis of the cervical spine in athetoid cerebral palsy. Extension-flexion motion," *Spine*, vol. 15, no. 11, pp. 1097–1103, 1990.

[5] R. S. El-Mallakh, K. Rao, and M. Barwick, "Cervical myelopathy secondary to movement disorders: case report," *Neurosurgery*, vol. 24, no. 6, pp. 902–905, 1989.

[6] P. M. Olive, T. S. Whitecloud 3rd, and J. T. Bennett, "Lower cervical spondylosis and myelopathy in adults with Down's syndrome," *Spine*, vol. 13, no. 7, pp. 781–784, 1988.

[7] L. Pollak, J. Schiffer, C. Klein, Y. Mirovsky, L. Copeliovich, and J. M. Rabey, "Neurosurgical intervention for cervical disk disease in dystonic cerebral palsy," *Movement Disorders*, vol. 13, no. 4, pp. 713–717, 1998.

[8] K. L. Quarrie, R. C. Cantu, and D. J. Chalmers, "Rugby Union injuries to the cervical spine and spinal cord," *Sports Medicine*, vol. 32, no. 10, pp. 633–653, 2002.

[9] E. Wada, S. Ebara, S. Saito, and K. Ono, "Experimental spondylosis in the rabbit spine: overuse could accelerate the spondylosis," *Spine*, vol. 17, no. 3, supplement, pp. S1–S6, 1992.

[10] Y. Morishita, M. Naito, and J. C. Wang, "Cervical spinal canal stenosis: the differences between stenosis at the lower cervical and multiple segment levels," *International Orthopaedics*, vol. 35, no. 10, pp. 1–6, 2011.

[11] W. C. Edwards and H. LaRocca, "The developmental segmental sagittal diameter of the cervical spinal canal in patients with cervical spondylosis," *Spine*, vol. 8, no. 1, pp. 20–27, 1983.

[12] D. R. Gore, "Roentgenographic findings in the cervical spine in asymptomatic persons: a ten-year follow-up," *Spine*, vol. 26, no. 22, pp. 2463–2466, 2001.

[13] H. Hayashi, K. Okada, and M. Hamada, "Etiologic factors of myelopathy. A radiographic evaluation of the aging changes in the cervical spine," *Clinical Orthopaedics and Related Research*, vol. 214, pp. 200–209, 1987.

[14] J. S. Torg, R. J. Naranja, H. Pavlov, B. J. Galinat, R. Warren, and R. A. Stine, "The relationship of developmental narrowing of the cervical spinal canal to reversible and irreversible injury of the cervical spinal cord in football players," *Journal of Bone and Joint Surgery. Series A*, vol. 78, no. 9, pp. 1308–1314, 1996.

[15] H. Hayashi, K. Okada, J. Hashimoto, K. Tada, and R. Ueno, "Cervical spondylotic myelopathy in the aged patient. A radiographic evaluation of the aging changes in the cervical spine and etiologic factors of myelopathy," *Spine*, vol. 13, no. 6, pp. 618–625, 1988.

[16] E. Clarke and P. K. Robinson, "Cervical myelopathy: a complication of cervical spondylosis," *Brain*, vol. 79, no. 3, pp. 483–510, 1956.

[17] F. Lees and J. W. Turner, "Natural history and prognosis of cervical spondylosis," *British Medical Journal*, vol. 2, no. 5373, pp. 1607–1610, 1963.

[18] D. G. Phillips, "Surgical treatment of myelopathy with cervical spondylosis," *Journal of Neurology, Neurosurgery & Psychiatry*, vol. 36, no. 5, pp. 879–884, 1973.

[19] L. Symon and P. Lavender, "The surgical treatment of cervical spondylotic myelopathy," *Neurology*, vol. 17, no. 2, pp. 117–127, 1967.

[20] M. Matsumoto, K. Chiba, M. Ishikawa, H. Maruiwa, Y. Fujimura, and Y. Toyama, "Relationships between outcomes of conservative treatment and magnetic resonance imaging findings in patients with mild cervical myelopathy caused by soft disc herniations," *Spine*, vol. 26, no. 14, pp. 1592–1598, 2001.

[21] K. K. Sadasivan, R. P. Reddy, and J. A. Albright, "The natural history of cervical spondylotic myelopathy," *Yale Journal of Biology and Medicine*, vol. 66, no. 3, pp. 235–242, 1994.

[22] E. C. Benzel, J. Lancon, L. Kesterson, and T. Hadden, "Cervical laminectomy and dentate ligament section for cervical spondylotic myelopathy," *Journal of Spinal Disorders*, vol. 4, no. 3, pp. 286–295, 1991.

[23] A. Fujiwara, N. Kobayashi, K. Saiki, T. Kitagawa, K. Tamai, and K. Saotome, "Association of the Japanese orthopaedic association score with the oswestry disability index, roland-morris disability questionnaire, and short-form 36," *Spine*, vol. 28, no. 14, pp. 1601–1607, 2003.

[24] S. Hukuda, T. Mochizuki, and M. Ogata, "Operations for cervical spondylotic myelopathy. A comparison of the results of anterior and posterior procedures," *Journal of Bone and Joint Surgery. Series B*, vol. 67, no. 4, pp. 609–615, 1985.

[25] Z. Kadaňka, M. Mareš, J. Bednaříka et al., "Predictive factors for mild forms of spondylotic cervical myelopathy treated conservatively or surgically," *European Journal of Neurology*, vol. 12, no. 1, pp. 16–24, 2005.

[26] Z. Kadaňka, M. Mareš, J. Bednarík et al., "Approaches to spondylotic cervical myelopathy: Conservative versus surgical results in a 3-year follow-up study," *Spine*, vol. 27, no. 20, pp. 2205–2210, 2002.

[27] T. Shimomura, M. Sumi, K. Nishida et al., "Prognostic factors for deterioration of patients with cervical spondylotic myelopathy after nonsurgical treatment," *Spine*, vol. 32, no. 22, pp. 2474–2479, 2007.

[28] J. A. Epstein, Y. Janin, R. Carras, and L. S. Lavine, "A comparative study of the treatment of cervical spondylotic myeloradiculopathy. Experience with 50 cases treated by means of extensive laminectomy, foraminotomy, and excision of osteophytes during the past 10 years," *Acta Neurochirurgica*, vol. 61, no. 1–3, pp. 89–104, 1982.

[29] P. Sampath, M. Bendebba, J. D. Davis, and T. B. Ducker, "Outcome of patients treated for cervical myelopathy: a prospective, multicenter study with independent clinical review," *Spine*, vol. 25, no. 6, pp. 670–676, 2000.

[30] R. Murphy, I. Moledina, L. McEvoy et al., "The natural history of cervical myelopathy," *European Spine Journal*, vol. 19, no. 3, p. 517, 2009.

[31] J. Bednarik, Z. Kadanka, L. Dusek et al., "Presymptomatic spondylotic cervical myelopathy: an updated predictive model," *European Spine Journal*, vol. 17, no. 3, pp. 421–431, 2008.

[32] J. Bednarik, Z. Kadanka, L. Dusek et al., "Presymptomatic spondylotic cervical cord compression," *Spine*, vol. 29, no. 20, pp. 2260–2269, 2004.

[33] J. Bednařík, Z. Kadaňka, S. Voháňka et al., "The value of somatosensory and motor evoked potentials in pre-clinical spondylotic cervical cord compression," *European Spine Journal*, vol. 7, no. 6, pp. 493–500, 1998.

[34] Z. Kadaňka, J. Bednařík, S. Voháňka, L. Stejskal, V. Smrčka, and O. Vlach, "Spondylotic cervical myelopathy: three aspects of the problem," *Supplements to Clinical Neurophysiology*, vol. 53, pp. 409–418, 2000.

[35] K. Nakamura, T. Kurokawa, Y. Hoshino, K. Saita, K. Takeshita, and H. Kawaguchi, "Conservative treatment for cervical spondylotic myelopathy: Achievement and sustainability of a level of "no disability"," *Journal of Spinal Disorders*, vol. 11, no. 2, pp. 175–179, 1998.

[36] T. Ito, K. Oyanagi, H. Takahashi, H. E. Takahashi, and F. Ikuta, "Cervical spondylotic myelopathy: Clinicopathologic study on the progression pattern and thin myelinated fibers of the lesions of seven patients examined during complete autopsy," *Spine*, vol. 21, no. 7, pp. 827–833, 1996.

[37] H. Ogino, K. Tada, K. Okada et al., "Canal diameter, anteroposterior compression ratio, and spondylotic myelopathy of the cervical spine," *Spine*, vol. 8, no. 1, pp. 1–15, 1983.

[38] K. Ono, H. Ota, K. Tada, and T. Yamamoto, "Cervical myelopathy secondary to multiple spondylotic protrusions; a clinicopathologic study," *Spine*, vol. 2, no. 2, pp. 109–125, 1977.
[39] Y. Aota, T. Niwa, M. Uesugi, T. Yamashita, T. Inoue, and T. Saito, "The correlation of diffusion-weighted magnetic resonance imaging in cervical compression myelopathy with neurologic and radiologic severity," *Spine*, vol. 33, no. 7, pp. 814–820, 2008.
[40] A. Demir, M. Ries, C. T. W. Moonen et al., "Diffusion-weighted MR imaging with apparent diffusion coefficient and apparent diffusion tensor maps in cervical spondylotic myelopathy," *Radiology*, vol. 229, no. 1, pp. 37–43, 2003.
[41] M. Xiangshui, C. Xiangjun, Z. Xiaoming et al., "3 T magnetic resonance diffusion tensor imaging and fibre tracking in cervical myelopathy," *Clinical Radiology*, vol. 65, no. 6, pp. 465–473, 2010.
[42] P. G. Matz, P. A. Anderson, L. T. Holly et al., "The natural history of cervical spondylotic myelopathy," *Journal of Neurosurgery: Spine*, vol. 11, no. 2, pp. 104–111, 2009.
[43] R. D. Sung and J. C. Wang, "Correlation between a positive Hoffmann's reflex and cervical pathology in asymptomatic individuals," *Spine*, vol. 26, no. 1, pp. 67–70, 2001.
[44] J. A. Tracy and B. J. Bartleson, "Cervical spondylotic myelopathy," *Neurologist*, vol. 16, no. 3, pp. 176–187, 2010.
[45] P. H. Crandall and U. Batzdorf, "Cervical spondylotic myelopathy," *Journal of Neurosurgery*, vol. 25, no. 1, pp. 57–66, 1966.
[46] M. Bernhardt, R. A. Hynes, H. W. Blume, and A. A. White 3rd, "Cervical spondylotic myelopathy," *Journal of Bone and Joint Surgery, American Volume*, vol. 75, no. 1, pp. 119–128, 1993.
[47] R. J. L. Ferguson and L. R. Caplan, "Cervical spondylitic myelopathy," *Neurologic Clinics*, vol. 3, no. 2, pp. 373–382, 1985.

Hindawi Publishing Corporation
Advances in Orthopedics
Volume 2012, Article ID 916149, 5 pages
doi:10.1155/2012/916149

Review Article

Operative Techniques for Cervical Radiculopathy and Myelopathy

C. Moran and C. Bolger

National Centre for Neurosurgery, Beaumont Hospital, Dublin, Ireland

Correspondence should be addressed to C. Moran, catherinemoran@rcsi.ie

Received 14 July 2011; Accepted 20 October 2011

Academic Editor: Joseph S. Butler

The surgical treatment of cervical spondylosis and resulting cervical radiculopathy or myelopathy has evolved over the past century. Surgical options for dorsal decompression of the cervical spine includes the traditional laminectomy and laminoplasty, first described in Asia in the 1970's. More recently the dorsal approch has been explored in terms of minimally invasive options including foraminotomies for nerve root descompression. Ventral decompression and fusion techniques are also described in the article, including traditional anterior cervical discectomy and fusion, strut grafting and cervical disc arthroplasty. Overall, the outcome from surgery is determined by choosing the correct surgery for the correct patient and pathology and this is what we hope to explain in this brief review.

1. Introduction

Cervical spondylosis is a common pathology, and the surgical treatment of the resulting radiculopathy, myelopathy, or myeloradiculopathy has evolved over the past century. The basic aim of all techniques is to decompress the affected neural structure. Advances in fixation techniques [1–3] and motion-preserving options [4–7] are more recent elements of this evolution. Once the decision is made to manage the patient operatively the principal decision is whether to choose the ventral or the dorsal approach. In cervical spondylosis several variables including the location of pathology (ventral, dorsal, circumferential); extent of pathology (limited to interspace, extensive behind vertebral body); the number of levels affected; the presence of instability or the presence of kyphotic deformity require consideration.

In general, any procedure chosen should decompress the affected spinal cord or nerve roots, maintain or restore stability, and correct or prevent kyphotic deformity.

2. Dorsal Decompression

A range of posterior surgical procedures exist, including laminectomy, laminoplasty, and laminectomy with posterior fusion. Until the 1960's the traditional way to decompress the cervical spine in spondylotic patients was via a dorsal approach and a decompressive laminectomy. This surgery effectively enlarges the spinal canal area, allowing the spinal canal to drift away from ventral compression, however, while doing this it also destabilizes the dorsal structures and can lead to progressive kyphotic deformity.

3. Laminectomy

A high speed drill is used to create a gutter, through the outer cortical bone and cancellous bone to the thin inner cortical bone at the junction of the lamina and the medial aspect of the lateral mass. Using a 1 mm Kerrison rongeur the lamina and ligamentum flavum is then transacted laterally. Two Kocher clamps are then used to remove the dorsal elements en bloc. In patients with loss of lordosis or abnormal segment motion, at this stage once decompression is completed, then instrumentation can be performed. Many wiring techniques are not suitable as the posterior elements have been removed. Options for fixation include interfacet wiring, which is unpopular due to postoperative pain caused by violating an intact facet joint. Lateral mass fixation techniques are the most popular and include fixation of a plate or rod to the lateral masses using screws [8–11].

4. Laminoplasty

Cervical laminoplasty, posterior decompression of the cord with reconstruction of the laminae, was a technique developed in Asia from the 1970's onwards, Hattori first described the Z-shaped laminoplasty [12–14]. The rationale was to leave the dorsal stabilizing structures in situ, allowing for fusion after decompression and therefore prevent the subsequent development of kyphotic deformity [15–18]. It is today used for multiple level spondylosis without kyphosis. In the Hirabayashi method osteotomies of cervical lamina to be included are performed on one side to create an "open" and a "hinged" side. The open side is chosen according to the most symptomatic side and whether or not foraminotomies will also be performed. High speed drill creates troughs at the level of the lamina-facet junction. The procedure ranges from the laminar level one above to the level below the stenotic site. Both the outer and inner cortical margins are drilled through on the "open" side, while the inner cortical margin is kept intact on the "hinge" side. After the excision on the open side is completed the spinous processes and laminae are pushed laterally as if opening a door, any adhesions to the dura are divided. The ligamentum flavum and deep muscles around the facets of the hinged side are then supported by sutures to prevent closing of the laminae. Alternatively allograft tricortical iliac crest or manufactured bone spacers can be placed in the open-door portion of the laminoplasty and stabilized using 2.0 mm titanium miniplates. Nakano et al. [18] reviewed patients who had undergone laminoplasty for OPLL with more than 10 years of followup. Long-term outcomes were good, with 64% mean neurological recovery in the first 10 years and 60% at the final followup.

5. Ventral versus Dorsal Decompression

Ventral decompression is most appropriate in patients who have ventral compression limited to one or two vertebral body levels, but in the setting of multilevel disease decompression from the front is complicated by lower fusion rate, adjacent level disease, and hardware failure [19]. The degenerative process includes hypertrophic changes circumferentially, and enlarged facet joints and thickened ligaments can contribute significantly to the narrowing of the spinal canal diameter throughout the entire cervical spine. Ventral approaches are often inadequate, especially when long-segment decompression is required. Dorsal approaches, including laminectomy with or without fusion and laminoplasty, provide surgical expansion to the spinal canal.

Sagittal balance is an important factor in determining whether a dorsal approach is suitable treatment; if the c-spine is kyphotic the cord will remain draped over the ventral compressive elements after dorsal decompression and the surgery will be unsuccessful.

Advantages of dorsal surgery include less surgical effort and time to decompress multiple levels and less frequent need for instrumentation and fusion, thereby helping decrease the chance of adjacent level disease, and it also affords direct visualisation of nerve roots when decompressing, and there is little risk to anterior neck structures such as the recurrent laryngeal nerve and the oesophagus.

6. Anterior Cervical Discectomy and Fusion

The ventrolateral approach for decompression of the cervical spine and nerve roots has become a well-practised technique among spinal surgeons. It was first described by Cloward [20] and Smith and Robinson [21] over forty years ago and has evolved to one of the most popular spinal surgery operations. The approach allows for safe and direct decompression of the spinal cord at the site of compression. The technique is used to treat radiculopathy due to disc herniation and osteophyte formation as well as cervical myelopathy or myeloradiculopathy. The most common levels affected are C5 to C6, then C6 to C7, then C4 to C5 in order of frequency.

The operation is performed in a supine position, with the neck in a moderately hyperextended position. The approach is routinely from the right; the incision can be centered on anatomical landmarks, including the hyoid at C3, the thyroid cartilage at C4, and the cricoid at C6, alternatively fluoroscopy can be obtained using a metal object taped to skin. A transverse incision is preferred, in a skin crease for good cosmesis, the incision is 5-6 cm extending to the medial border of the sternocleidomastoid. Dissection is performed down to platysma, this is then sharply incised transversely across the length of the skin incision and elevated. The cervical fascia is then opened vertically just anterior to the sternocleidomastoid, blunt dissection is then used to separate the soft-tissue plane between the lateral aspect of the laryngeal strap muscles and the medial aspect of the SCM. An avascular plane is developed down to the vertebral bodies by retracting the trachea and oesophagus medially and the carotid sheath laterally, 7the carotid artery is palpated for behind the sternocleidomastoid. Close attention should be paid to avoid dividing any structure crossing from the carotid sheath medially. The prevertebral fascia is then opened in the midline. A spinal needle is placed in the disc space and the level is checked with a lateral radiograph. Once the correct level is confirmed the longus colli muscles are cauterised, using bi-polar diathermy and reflected laterally; dissection continues out to the uncinate processes and self-retaining retractors are then placed beneath the medial edges of the reflected longus colli muscles. These retractors should not be displaced for the remainder of the surgery. Vertebral body posts are then placed in the vertebral bodies above and below the disc to be removed and the bodies are distracted gently. The anterior longitudinal ligament is removed. The annulus fibrosus is incised and superficial disc and cartilaginous end plates can then be removed, using rongeurs, drill, and curettes. Posts inserted into the vertebral body at this stage can be spread again, thus increasing the disc height. The remainder of the disc is then removed, as well as the posterior annulus and osteophytic ridges. The removal of the posterior longitudinal ligament is also routinely performed. Each neural foramen is cleared and palpated afterwards to ensure adequate nerve root decompression. The interbody graft is then placed after the adjacent end plates have been drilled to promote fusion.

The graft is then tapped into position and the distraction is released.

7. Fusion Techniques

There are three different types of anterior cervical fusions, described by Cloward [20] Smith and Robinson [21], and Simmons et al. [22] which employ bone-grafting techniques. Iliac corticocancellous graft is used in the Cloward technique; these grafts are typically 12–16 mm in diameter and 10 to 14 mm in height, and the bone is seated into the softer cancellous portion of the midvertebral body. A horseshoe-shaped graft is used in the Smith Robinson technique, and less bony resection is performed in this operation, as opposed to Cloward, where the lateral exposure is greater, the graft is seated on the stronger subchondral bone end plate.

8. Artificial Cervical Disc Arthroplasty

Alternatives to anterior cervical discectomy and fusion have been developed that attempt to address some of the kinematic and biomechanical issues associated with fusing two spinal levels. It has been shown that twenty-five percent of patients undergoing cervical fusion will have new onset symptoms within ten years of that fusion due to degenerative changes at adjacent levels [23]. Total intervertebral disc replacement was introduced to preserve motion and restore disc height after removing the pathology. The Bryan cervical disc prosthesis was first introduced in the USA in 2002. It was used for the treatment of both radiculopathy and myelopathy, and in recent studies comparing the two for single-level disease and comparing artificial disc versus fusion have shown both groups to have comparable improvement in all outcome measures [24].

9. Cervical Corpectomy and Strut Grafting

Cervical corpectomy can be used for a variety of spinal disorders, including infection, neoplastic disease, and trauma, but it is most commonly used for multilevel cervical spondylosis. Single-level vertebrectomy can be carried out on patients with signs and symptoms of myelopathy, who are found on imaging to have spinal cord compression by osteophyte formation and soft-disc herniation at two adjacent levels. Three-level disease and compression can be treated by a two-level vertebrectomy or a multilevel laminectomy. A vertebrectomy should be performed if there is straightening of the spine, as progressive kyphosis is likely after laminectomy or kyphotic deformity as the cord is unlikely to move posteriorly away from the compression in the presence of kyphosis. When compression stretches four motion segments a posterior decompression is preferred, but again, in situations of kyphotic deformity a three-level vertebrectomy is suitable, and then supplemented with a posterior instrumentation to decrease the risk of graft and plate dislodgement. OPLL also usually requires at least a one-level vertebrectomy.

Regarding the operative procedure, the same approach as the ACDF described above is used. Once the correct level is confirmed the anterior longitudinal ligament over the disc spaces above and below the level to be resected is incised; the most anterior portions of the underlying discs are then removed, as is the anterior longitudinal ligament covering the front of the vertebrae. The extent of bone to be removed is then marked, the width of bony resection is usually 18 mm, but can be decreased to 15 mm at C4 or C5 level surgery to decrease the incidence of C5 nerve root dysfunction [24]. An operating microscope is used as bony resection proceeds using a diamond burr; care is taken once the superficial portion of the body is removed as the vertebral artery lies in the middle third of the AP diameter of the vertebral body. As bony resection proceeds, the end plates of the adjacent vertebrae are also resected. The posterior longitudinal ligament is then opened taking care to lift it away from the dura, and Kerrison rongeurs are then used to resect it as far as the bony exposure. Bony reconstruction can be accomplished using an allograft, autograft, or cage system. The graft should be 2 mm longer than the length of the vertebrectomy, the AP depth is 13 mm. Distraction pins are used above and below in order to insert the construct; using a graft holder it is then hammered into place until it is flush with the anterior aspect of the adjacent vertebral bodies.

Anterior plating is then performed, and the screws are placed under fluoroscopic guidance, as this ensures accurate screw placement avoiding both the graft and the adjacent disc spaces; engagement of the posterior cortex has been shown unnecessary [25, 26].

10. Multiple Level Discectomy and Fusion versus Corpectomy

Cervical corpectomy is an alternative technique for the removal of ventral compressive pathology and stabilization of the cervical spine, and it allows for decompression behind the midportion of the vertebral body. It has been shown that by using ventral instrumentation in two-level discectomy, the fusion rate is comparable with single-level corpectomy [27, 28]. Comparison between three-level discectomy with two-level corpectomy also showed similar rates of fusion. Graft displacement after corpectomy is proportionate to graft length and is increased with fusion ending at the C7 vertebral body. After placing a long corpectomy graft under distraction there tends to be a general straightening of the spine, however, multiple level discectomy and fusion allows for increasing the ventral column height and restoration of lordosis by pulling the vertebral body segments toward the lordotic ventral instrumentation. Also multilevel discectomy and fusion provides more fixation points to hold the construct rigidly, compared with corpectomy and strut grafting which has only two points of fixation and allows for more translational movement [29].

11. Multiple Level Discectomy versus Dorsal Procedures

Cervical radiculopathy is caused by compression at multiple levels; if lordosis is maintained and the compressive pathology is primarily foraminal then dorsal foraminotomies

are a reasonable alternative. However dorsal foraminotomy cannot correct kyphosis and may predispose to it.

Cervical Myelopathy is best treated using a dorsal approach when the compression is primarily dorsal, that is, congenital stenosis; dorsal fusion should be considered if there is a straightening of the spine, kyphosis, or instability.

12. Minimally Invasive Surgery and Laminoforaminotomy

Dorsal surgical approaches for the management of cervical spondylosis are well established and in recent years have undergone a host of modifications in order to make the surgeries minimally invasive. The rationale behind these advances is to cause less tissue injury on exposure, thereby decreasing postoperative pain, but most importantly the aim is to decompress the neural structures with minimal disruption of dorsal structures, thereby preserving motion and decreasing adjacent level disease and the incidence of postdecompression kyphosis.

Laminoforaminotomy can be used for nerve root and central canal decompression [30]. Patients with a unilateral monoradiculopathy are best candidates. This is performed using a tubular retractor system, (Met Rx system), a microendoscope, with the patient in a sitting position. Fluoroscopy is used to mark a point 1.5 cm off the midline directly over the desired disc space. A stab incision is made in the skin and a guide pin is docked onto the superior facet at the desired level using fluoroscopic guidance. The stab incision is then widened to 2 cm and the underlying fascia is divided sharply with scissors. The first tissue dilator is then passed over the guide pin and it is removed, further dilators are passed in sequence, the final port is the working channel to which the endoscope is attached. A high speed drill can be used to thin out the medial aspect of the superior facet and a Kerrison rongeur used to perform a foraminotomy. In disc herniation, the nerve root can be gently retracted using a suction tip, allowing space to explore the ventral epidural space. Any epidural plexus bleeding is controlled with electrocautery and hemostatic agents. Two adjacent levels can be decompressed through a single incision by centering the initial incision halfway between the neural foramina.

13. Facet Distraction

Recently the technique of facet distraction was published as a treatment option for single or multilevel cervical spondylotic radiculopathy and myelopathy [31]. In this study the authors described facet distraction by manual implantation of metal spacers within the articular cavity after wide removal of the articular cartilage; structural changes resulting from these spacers included an increase in interlaminar and interspinous process distance and restoration of buckled ligaments of the region as well as an increase in spinal canal diameter.

14. Summary

Both cervical spondylosis and its most common clinical manifestations, radiculopathy and myelopathy, are common clinical conditions. It occurs in the aging population as a result of disc degeneration, consequent degenerative changes of the uncovertebral joints, ligamentum flavum, and facet complex. Surgical outcome is dependent on selecting the appropriate treatment for the appropriate patient and pathology. In recent years much effort has been focused on modifying the dorsal approaches in an effort to achieve similar results with less tissue injury and less postoperative pain. However, despite the numerous surgical options available, the optimal procedure can still be difficult to choose.

References

[1] C. Faldini, D. Leonetti, M. Nanni et al., "Cervical disc herniation and cervical spondylosis surgically treated by Cloward procedure: a 10-year-minimum follow-up study," *Journal of Orthopaedics and Traumatology*, vol. 11, no. 2, pp. 99–103, 2010.

[2] B. Lied, P. A. Roenning, J. Sundseth, and E. Helseth, "Anterior cervical discectomy with fusion in patients with cervical disc degeneration: a prospective outcome study of 258 patients (181 fused with autologous bone graft and 77 fused with a PEEK cage)," *BMC Surgery*, vol. 10, article 10, 2010.

[3] P. K. Narotam, S. M. Pauley, and G. J. McGinn, "Titanium mesh cages for cervical spine stabilization after corpectomy: a clinical and radiological study," *Journal of neurosurgery*, vol. 99, no. 2, pp. 172–180, 2003.

[4] S. D. Boden, R. A. Balderston, J. G. Heller, E. N. Hanley Jr., and J. E. Zigler, "An AOA critical issue: disc replacements: this time will we really cure low-back and neck pain?" *Journal of Bone and Joint Surgery—Series A*, vol. 86, no. 2, pp. 411–422, 2004.

[5] M. J. Cardoso and M. K. Rosner, "Multilevel cervical arthroplasty with artificial disc replacement," *Neurosurgical Focus*, vol. 28, no. 5, p. E19, 2010.

[6] E. L. Lin and J. C. Wang, "Total disc arthroplasty," *Journal of the American Academy of Orthopaedic Surgeons*, vol. 14, pp. 705–714, 2006.

[7] D. H. Yoon, S. Yi, H. C. Shin, K. N. Kim, and S. H. Kim, "Clinical and radiological results following cervical arthroplasty," *Acta Neurochirurgica*, vol. 148, no. 9, pp. 943–950, 2006.

[8] H. S. An, R. Gordin, and K. Renner, "Anatomic considerations for plate-screw fixation of the cervical spine," *Spine*, vol. 16, supplement 10, pp. S548–S551, 1991.

[9] W. B. Cherney, V. K. Sonntag, and R. A. Douglas, "Lateral mass posterior plating and facet fusion for cervical spine instability," *Barrow Neurological Institute*, vol. 7, pp. 2–11, 1991.

[10] P. R. Cooper, A. Cohen, A. Rosiello, and M. Koslow, "Posterior stabilization of cervical spine fractures and subluxations using plates and screws," *Neurosurgery*, vol. 23, no. 3, pp. 300–306, 1988.

[11] R. Roy-Camille, G. Saillant, and C. Mazel, "Internal fixation of the unstable cervical spine by a posterior osteosynthesis with plates and screws," in *The Cervical Spine*, Cervical Spine Research Society, Ed., pp. 390–306, J. B. Lippincott, Philadelphia, Pa, USA, 1989.

[12] S. Hattori, "Cervical myelopathy," *Journal of the Japanese Orthopaedic Association*, vol. 52, p. 581, 1978 (Japanese).

[13] S. Hattori and S. Kawai, "Diagnosis of cervical spondylosis," *Orthopaedic Mook*, vol. 6, p. 13, 1979 (Japanese).

[14] S. Hattori, "Pathogenesis and surgical treatment of cervical spondylotic myelopathy," in *Proceedings of the Annual Meeting of the Japanese Orthopaedic Association*, Tokyo, Japan, April 1980.

[15] M. Oyama, S. Hattori, and N. Moriwaki, "A new method of cervical laminoplasty," *Central Japan Journal of Orthopaedic Surgery and Traumatology*, vol. 16, pp. 792–794, 1973 (Japanese).

[16] W. M. Yue, C. T. Tan, S. B. Tan, S. K. Tan, and B. K. Tay, "Results of cervical laminoplasty and a comparison between single and double trap-door techniques," *Journal of Spinal Disorders*, vol. 13, no. 4, pp. 329–335, 2000.

[17] S. Kokubun, T. Sato, Y. Ishii, and Y. Tanaka, "Cervical myelopathy in the Japanese," *Clinical Orthopaedics and Related Research*, no. 323, pp. 129–138, 1996.

[18] N. Nakano, T. Nakano, and K. Nakano, "Comparison of the results of laminectomy and open-door laminoplasty for cervical spondylotic myeloradiculopathy and ossification of the posterior longitudinal ligament," *Spine*, vol. 13, no. 7, pp. 792–794, 1988.

[19] A. S. Hilibrand, G. D. Carlson, M. A. Palumbo, P. K. Jones, and H. H. Bohlman, "Radiculopathy and myelopathy at segments adjacent to the site of a previous anterior cervical arthrodesis," *Journal of Bone and Joint Surgery—Series A*, vol. 81, no. 4, pp. 519–528, 1999.

[20] R. B. Cloward, "Lesions of the intervertebral disks and their treatment by interbody fusion methods. The painful disk," *Clinical orthopaedics and related research*, vol. 27, pp. 51–77, 1963.

[21] G. W. Smith and R. A. Robinson, "The treatment of certain cervical-spine disorders by anterior removal of the intervertebral disc and interbody fusion," *Journal of Bone and Joint Surgery—Series A*, vol. 40, pp. 607–624, 1958.

[22] E. H. Simmons and S. K. Bhalla, "Anterior cervical discectomy and fusion. A clinical and biomechanical study with eight-year follow-up," *Journal of Bone and Joint Surgery—Series B*, vol. 51, no. 2, pp. 225–237, 1969.

[23] A. S. Hilibrand, G. D. Carlson, M. A. Palumbo, P. K. Jones, and H. H. Bohlman, "Radiculopathy and myelopathy at segments adjacent to the site of a previous anterior cervical arthrodesis," *Journal of Bone and Joint Surgery—Series A*, vol. 81, no. 4, pp. 519–528, 1999.

[24] R. L. Saunders, "On the pathogenesis of the radiculopathy complicating multilevel corpectomy," *Neurosurgery*, vol. 37, no. 3, pp. 408–413, 1995.

[25] J. F. Cusick, "Pathophysiology and treatment of cervical spondylotic myelopathy," *Clinical Neurosurgery*, vol. 37, pp. 661–681, 1991.

[26] D. J. Maiman, F. A. Pintar, N. Yoganandan et al., "Pull-out strength of Caspar cervical screws," *Neurosurgery*, vol. 31, no. 6, pp. 1097–1101, 1992.

[27] V. Seifert, "Anterior decompressive microsurgery and osteosynthesis for the treatment of multi-segmental cervical spondylosis," *Acta Neurochirurgica*, vol. 135, no. 3-4, pp. 105–121, 1995.

[28] J. C. Wang, P. W. McDonough, K. K. Endow, and R. B. Delamarter, "A comparison of fusion rates between single-level cervical corpectomy and two-level discectomy and fusion," *Journal of Spinal Disorders*, vol. 14, no. 3, pp. 222–225, 2001.

[29] T. A. Zdeblick and T. B. Ducker, "The use of freeze-dried allograft bone for anterior cervical fusions," *Spine*, vol. 16, no. 7, pp. 726–729, 1991.

[30] J. Lu, N. A. Ebraheim, Y. Nadim, and M. Huntoon, "Anterior approach to the cervical spine: surgical anatomy," *Orthopedics*, vol. 23, no. 8, pp. 841–845, 2000.

[31] D. Samartzis, F. H. Shen, D. K. Matthews, S. T. Yoon, E. J. Goldberg, and H. S. An, "Comparison of allograft to autograft in multilevel anterior cervical discectomy and fusion with rigid plate fixation," *Spine Journal*, vol. 3, no. 6, pp. 451–459, 2003.

Hindawi Publishing Corporation
Advances in Orthopedics
Volume 2012, Article ID 393642, 5 pages
doi:10.1155/2012/393642

Review Article

The Natural History and Clinical Syndromes of Degenerative Cervical Spondylosis

John C. Kelly, Patrick J. Groarke, Joseph S. Butler, Ashley R. Poynton, and John M. O'Byrne

Department of Trauma and Orthopaedic Surgery, Cappagh National Orthopaedic Hospital, The Royal College of Surgeons in Ireland, Finglas, Dublin 11, Ireland

Correspondence should be addressed to John C. Kelly, johncokelly@gmail.com

Received 12 April 2011; Revised 8 September 2011; Accepted 26 September 2011

Academic Editor: F. Cumhur Öner

Cervical spondylosis is a broad term which describes the age related chronic disc degeneration, which can also affect the cervical vertebrae, the facet and other joints and their associated soft tissue supports. Evidence of spondylitic change is frequently found in many asymptomatic adults. Radiculopathy is a result of intervertebral foramina narrowing. Narrowing of the spinal canal can result in spinal cord compression, ultimately resulting in cervical spondylosis myelopathy. This review article examines the current literature in relation to the cervical spondylosis and describes the three clinical syndromes of axial neck pain, cervical radiculopathy and cervical myelopathy

1. Introduction

Cervical spondylosis is a broad term which describes the age-related chronic disc degeneration, which can also affect the cervical vertebrae, the facet, and other joints and their associated soft tissue supports. Chronic disc degeneration results in increased mechanical stressors passing through the cervical spinal column, resulting in osteophyte formation and secondary degenerative changes in surrounding structures, such as the facet joints, the posterior longitudinal ligament (PLL), and the ligamentum flavum. These degenerative changes and their associated nerve impingement are then responsible for the three clinical syndromes in which cervical spondylosis presents. Cervical spondylosis is generally classified according to these three clinical syndromes or means of presentation: axial neck pain, cervical radiculopathy, and cervical myelopathy. Patients can have a combination of any of the three syndromes. Evidence of spondylotic change is frequently found in many asymptomatic adults [1], with 25% of adults under the age of 40, 50% of adults over the age of 40, and 85% of adults over the age of 60 showing some evidence of disc degeneration [2, 3]. Another study of asymptomatic adults showed significant degenerative changes at 1 or more levels in 70% of women and 95% of men at age 65 and 60 [4]. The most common evidence of degeneration is found at C5-6 followed by C6-7 and C4-5 [3]. Treatment for mild and moderate disease is typically conservative with surgical intervention advised for those with severe intractable pain, progressive disease, and for those with associated weakness and neurological deficits.

2. Natural History

Cervical spondylosis can present itself in a multitude of ways. It can often be asymptomatic, it can can cause neck pain, regional pain, and can cause neurologic deficits of the sphincters, torso, or the extremities if there is spinal cord involvement [5].

In the majority of cases patients present between the ages of 40 and 60, with men being more commonly affected than women at a ratio of 3 : 2.

Disc degeneration and bulging, osteophyte and spur formation, ligamentous hypertrophy, vertebral subluxation, decreased disc height, and facet joint arthropathy all combine to cause narrowing of the spinal canal and intervertebral foramina. Radiculopathy is a result of intervertebral foramina narrowing. Narrowing of the spinal canal can result in spinal cord compression, ultimately resulting in cervical spondylosis myelopathy.

Factors which contribute to an acceleration in the disease process include having a congenitally narrow vertebral canal, certain athletic endeavors such as soccer, rugby, and horse riding, exposure to significant trauma, and having dystonic cerebral palsy which includes the cervical muscles [6–11].

The course of disease development and the ultimate prognosis for patients with cervical spondylosis is highly variable and extremely difficult to predict. In 1956 Clarke and Robinson longitudinally followed up 120 patients with cervical spondylosis myelopathy and a mean age of 53 years. They reported that in 75% of cases the disease deteriorated in an episodic manner, in 20% of cases there was a steady progression of symptoms, and in 5% of cases there was a rapid onset of symptoms followed by a long respite in disease progression [12].

In 1963 Lees and Turner longitudinally followed 44 patients with cervical spondylosis myelopathy from 3–40 years and again highlighted the disease's unpredictable nature. They found that "long periods of nonprogressive disability are the rule and a progressively deteriorating course is exceptional" and that "exacerbations can occur at long or shorter intervals for many years" [13].

Roberts reported on 24 patients and found that a long duration and severe symptoms were predictive of a poor outcome following operative intervention [14]. Nurick found in his study of 37 patients that there was an initial phase of deterioration followed by a longer nonprogressive phase which extended for many years, with older patients more likely to experience disease deterioration [8]. Epstein found that just over a third of patients improved, 38% remained stable, and 26% deteriorated [15]. Three studies from the same randomised controlled trials of conservative and operative treatment by Kadanka over 3 years, by Bedarnik over 2 years, and by Kadanka over 2 years found no difference between either group [16–18].

Based on these and other studies it seems that the progression of cervical spondylosis to cervical spondylosis myelopathy is highly variable and difficult to predict, with many patients experiencing a relatively benign form of the disease; however, a significant proportion of those presenting with neurological deficits do not experience spontaneous improvements and are subject to deterioration in their neurologic status over time [19].

3. Clinical Syndromes

3.1. Axial Neck Pain. Axial neck pain is the most common syndrome seen in clinical practice [20]. Improper posture, muscle fatigue, and poor ergonomics which occur as a consequence of muscular and ligamentous factors are major contributing factors to axial neck pain [21]. The aetiology of axial neck and shoulder pain is poorly understood and oftentimes there is no associated neurological deficit, making the disorder more difficult to treat. Many possible explanations have been given but their relative contribution has been difficult to quantify. In one study of patients with fibromyalgic neck pain, chemical analysis of the trapezius muscle from symptomatic adults found low levels of the high-energy phosphates, adenosine triphosphate, adenosine diphosphate and phosphoryl creatine, and an increase in the levels of adenosine monophosphate and creatine [22]. They concluded based on those results that muscle was the primary source of pain in those patients [22]. Larsson et al. demonstrated that patients with chronic trapezius myalgia had a lower muscle blood flow and higher intramuscular tension on their symptomatic side when compared to their asymptomatic side and when compared to asymptomatic controls [23]. Other factors such as a previous neck injury have been shown to be an independent and distinct risk factor for developing neck pain [24]. Facet joint arthropathy and cervical disc disease can also contribute to symptomatic neck pain. The synovium of facet joints and the peripheral portions of the intervertebral disc have been demonstrated to possess nerve fibres and nociceptive nerve endings [25–27]. Facet joint injection and discography have also assisted in providing evidence of their role in the aetiology of neck pain [28, 29]. One-third of patients with axial neck pain due to degenerative cervical spondylosis also present with headache, and greater than two-thirds present with shoulder pain which can either be unilateral or bilateral [30]. Many of these patients also present with arm, forearm, and hand pain. Another feature of this syndrome is chronic suboccipital pain which can radiate to the back of the ear, occiput, or neck and can be indicative of occipitoatlantal and atlantoaxial degeneration [30]. Restricted rotation of the head to one side can suggest involvement of the ipsilateral atlantoaxial joint [21].

3.2. Cervical Radiculopathy. The most commonly involved nerve roots in cervical radiculopathy are the sixth and seventh nerve roots which occur as a result of spondylosis of C5-C6 or C6-C7. Patients can present with arm pain, sensory deficits, neck pain, paraesthesia, reflex deficits, motor deficits, scapular pain, anterior chest pain, and, rarely, with left-sided chest and arm pain (cervical angina) [31, 32]. The symptoms of cervical radiculopathy are usually aggravated by performing the Spurling maneuver which describes extension or lateral rotation of the head to the side of the pain [21]. Davidson et al. demonstrated that relief from cervical monoradiculopathies due to extradural compressive disease may be obtained by performing the shoulder abduction sign, which involves elevating the arm overhead [33]. Radicular pain is thought to occur due to compression of an inflamed or irritated nerve root. In an animal model of chronic nerve root compression, Cornefjord et al. showed an increased concentration of the neurogenic chemical mediator of pain, substance P, in the dorsal root ganglia and the nerve root after 1 and 4 weeks [34]. Cooper et al. also demonstrated that chronic oedema and fibrosis within the nerve caused by compression can also increase the sensitivity of the nerve root to pain [35]. It has also been postulated that mechanical deformation of the dorsal root ganglia as occurs with a herniated disc causes a reduction in blood flow to the sensory nerve cell bodies resulting in pain [36]. Compression changes axonal flow which alters the metabolism of neurotransmitters within the axons and can then cause a decline in nerve function [37]. A prolapsed nucleus pulposus also initiates a local inflammatory response

which results in the release of numerous inflammatory mediators such as tumour necrosis factor alpha (TNF-α), causing increased pain [38].

3.3. Cervical Myelopathy. Cervical myelopathy as a result of spondylosis is the most common cause of nontraumatic paraparesis and quadriparesis. It typically has an insidious onset and presents with clumsiness or reduced fine motor skills in the hands [20]. Patients complain of urinary urgency, hesitation, and frequency but rarely incontinence, and an increasingly awkward gait or difficulty maintaining balance, is frequently observed by family members [21]. Patients often present with neck stiffness and sometimes experience a stabbing pain in the preaxial or postaxial border of the arms [39]. Extension and flexion of the neck often elicits electric shock like sensations in the extremities with this known as Lhermitte's sign [20]. A more specific sign for CSM is Hoffman's sign. This sign is elicited by flipping either the volar or dorsal surfaces of the middle finger and observing the reflex contraction of the thumb and index finger. In particular, a dynamic Hoffman's sign may accentuate the reflex [40]. This is achieved by performing the test in different degrees of flexion and extension. Sung et al. reported that a positive Hoffman's sign strongly correlates with a cervical pathology [41].

Patients also demonstrate spasticity with exaggerated reflexes below the level of cord compression, motor weakness, sensory loss, and extensor plantar responses [20]. Some patients develop "myelopathy hand" which refers to a series of hand pathologies which include, loss of dexterity, diffuse numbness, intrinsic muscle wasting, ulnar and flexor drift of the ulnar two digits when trying to keep the fingers adducted and extended, and an inability to grasp and release the fist [21, 42, 43]. Mechanical compression of the spinal cord is thought to be the primary aetiological factor which results in myelopathy. In normal adults the anteroposterior diameter of the subaxial spine measures 17 to 18 mm. Those who have a diameter less than 13 mm are thought to have developmental stenosis and are predisposed to developing myelopathy [44].

There is a lot of evidence that suggests congenital narrow vertebral canals are related to developing cervical spondylosis myelopathy (CSM) [45]. The Torg-Pavlov ratio is a relativity straightforward measurement that is taken from lateral radiographs of the cervical spine. It is calculated by dividing the width of the spinal canal at a level (taken from the midpoint of posterior surface of the vertebral body to the closest point in the junction of the lamina and spinous process), by the diameter of the vertebral body at that level. Yue et al. in a study measuring the Torg-Pavlov ratio of 1130 individuals, showed that the ratio is significantly lower in patients with cervical spondylotic myelopathy compared with a nonspondylotic, nonmyelopathic control group, irrespective of sex and age [46].

Other factors which play a part in myelopathy development include a cross-sectional area less than 60 mm^2 and a banana-shaped cord [47, 48]. Another important factor in the development of significant neurologic deficit is having an anteroposterior cord compression ration of less than 40% and this is suggestive of significant flattening of the cord and a worse prognosis [43]. Normal neck movements can change the dimensions of the spinal canal and can assist in myelopathy development by causing cord compression [21]. The volume of the cervical spinal canal and the anteroposterior diameter have been shown to be reduced in extension [49, 50]. The spinal cord has also been shown to stretch with flexion of the cervical spine and shorten and thicken with extension [51]. This thickening in extension then exposes the cord to increase compressive forces from the lamina or the ligamentum flavum.

Instability is another important consideration in patients with CSM. Some authors consider severe disc degeneration as being equivalent to "autofusion" as a compensation process for segmental instability. Wang et al. recommend multilevel anterior cervical decompression and fusion (ACDF) or expansive laminoplasty as a surgical management of CSM with severe disc degeneration because of the associated instability [52].

Cervical spondylotic myelopathy has also been shown to affect patients' quality of life with over one-third of patients having increased anxiety or depression as a result of their reduced mobility [53].

References

[1] S. D. Boden, P. R. McCowin, D. O. Davis, T. S. Dina, A. S. Mark, and S. Wiesel, "Abnormal magnetic-resonance scans of the cervical spine in asymptomatic subjects. A prospective investigation," *Journal of Bone and Joint Surgery—Series A*, vol. 72, no. 8, pp. 1178–1184, 1990.

[2] I. J. Lehto, M. O. Tertti, M. E. Komu, H. E. K. Paajanen, J. Tuominen, and M. J. Kormano, "Age-related MRI changes at 0.1 T in cervical discs in asymptomatic subjects," *Neuroradiology*, vol. 36, no. 1, pp. 49–53, 1994.

[3] M. Matsumoto, Y. Fujimura, N. Suzuki et al., "MRI of cervical intervertebral discs in asymptomatic subjects," *Journal of Bone and Joint Surgery—Series B*, vol. 80, no. 1, pp. 19–24, 1998.

[4] D. R. Gore, S. B. Sepic, and G. M. Gardner, "Roentgenographic findings of the cervical spine in asymptomatic people," *Spine*, vol. 11, no. 6, pp. 521–524, 1986.

[5] J. A. Tracy and B. J. Bartleson, "Cervical spondylotic myelopathy," *Neurologist*, vol. 16, no. 3, pp. 176–187, 2010.

[6] M. Bernhardt, R. A. Hynes, H. W. Blume, and A. A. White III, "Cervical spondylotic myelopathy," *Journal of Bone and Joint Surgery—Series A*, vol. 75, no. 1, pp. 119–128, 1993.

[7] H. Ogino, K. Tada, and K. Okada, "Canal diameter, anteroposterior compression ratio, and spondylotic myelopathy of the cervical spine," *Spine*, vol. 8, no. 1, pp. 1–15, 1983.

[8] S. Nurick, "The pathogenesis of the spinal cord disorder associated with cervical spondylosis," *Brain*, vol. 95, no. 1, pp. 87–100, 1972.

[9] K. L. Quarrie, R. C. Cantu, and D. J. Chalmers, "Rugby Union injuries to the cervical spine and spinal cord," *Sports Medicine*, vol. 32, no. 10, pp. 633–653, 2002.

[10] J. Berge, B. Marque, J. M. Vital, J. Sénégas, and J. M. Caillé, "Age-related changes in the cervical spines of front-line rugby players," *American Journal of Sports Medicine*, vol. 27, no. 4, pp. 422–429, 1999.

[11] L. Pollak, J. Schiffer, C. Klein, Y. Mirovsky, L. Copeliovich, and J. M. Rabey, "Neurosurgical intervention for cervical disk

disease in dystonic cerebral palsy," *Movement Disorders*, vol. 13, no. 4, pp. 713–717, 1998.

[12] E. Clarke and P. K. Robinson, "Cervical myelopathy: a complication of cervical spondylosis," *Brain*, vol. 79, no. 3, pp. 483–510, 1956.

[13] F. Lees and J. W. Turner, "Natural history and prognosis of cervical spondylosis," *British Medical Journal*, vol. 2, no. 5373, pp. 1607–1610, 1963.

[14] A. Roberts, "Myelopathy due to cervical spondylosis treated by collar immobillization," *Neurology*, vol. 16, pp. 951–954, 1966.

[15] J. A. Epstein, Y. Janin, R. Carras, and L. S. Lavine, "A comparative study of the treatment of cervical spondylotic myeloradiculopathy. Experience with 50 cases treated by means of extensive laminectomy, foraminotomy, and excision of osteophytes during the past 10 years," *Acta Neurochirurgica*, vol. 61, no. 1–3, pp. 89–104, 1982.

[16] Z. Kadanka, M. Mareš, J. Bednarík et al., "Approaches to spondylotic cervical myelopathy: conservative versus surgical results in a 3-year follow-up study," *Spine*, vol. 27, no. 20, pp. 2205–2210, 2002.

[17] J. Bednařík, Z. Kadaňka, S. Voháňka, L. Stejskal, O. Vlach, and R. Schröder, "The value of somatosensory- and motor-evoked potentials in predicting and monitoring the effect of therapy in spondylotic cervical myelopathy: prospective randomized study," *Spine*, vol. 24, no. 15, pp. 1593–1598, 1999.

[18] Z. Kadaňka, J. Bednařík, S. Voháňka et al., "Conservative treatment versus surgery in spondylotic cervical myelopathy: a prospective randomised study," *European Spine Journal*, vol. 9, no. 6, pp. 538–544, 2000.

[19] C. C. Edwards, K. D. Riew, P. A. Anderson, A. S. Hilibrand, and A. F. Vaccaro, "Cervical myelopathy: current diagnostic and treatment strategies," *Spine Journal*, vol. 3, no. 1, pp. 68–81, 2003.

[20] B. M. Mccormack and P. R. Weinstein, "Cervical spondylosis—an update," *Western Journal of Medicine*, vol. 165, no. 1-2, pp. 43–51, 1996.

[21] R. D. Rao, B. L. Currier, T. J. Albert et al., "Degenerative cervical spondylosis: clinical syndromes, pathogenesis, and management," *Journal of Bone and Joint Surgery—Series A*, vol. 89, no. 6, pp. 1360–1378, 2007.

[22] A. Bengtsson, K. G. Henriksson, and J. Larsson, "Reduced high-energy phosphate levels in the painful muscles of patients with primary fibromyalgia," *Arthritis and Rheumatism*, vol. 29, no. 7, pp. 817–821, 1986.

[23] R. Larsson, P. A. Oberg, and S. E. Larsson, "Changes of trapezius muscle blood flow and electromyography in chronic neck pain due to trapezius myalgia," *Pain*, vol. 79, no. 1, pp. 45–50, 1999.

[24] P. R. Croft, M. Lewis, A. C. Papageorgiou et al., "Risk factors for neck pain: a longitudinal study in the general population," *Pain*, vol. 93, no. 3, pp. 317–325, 2001.

[25] R. F. McLain, "Mechanoreceptor endings in human cervical facet joints," *Spine*, vol. 19, no. 5, pp. 495–501, 1994.

[26] C. Chen, Y. Lu, S. Kallakuri, A. Patwardhan, and J. M. Cavanaugh, "Distribution of A-δ and C-fiber receptors in the cervical facet joint capsule and their response to stretch," *Journal of Bone and Joint Surgery—Series A*, vol. 88, no. 8, pp. 1807–1816, 2006.

[27] S. Inami, T. Shiga, A. Tsujino, T. Yabuki, N. Okado, and N. Ochiai, "Immunohistochemical demonstration of nerve fibres in the synovial fold of the human cervical facet joint," *Journal of Orthopaedic Research*, vol. 19, no. 4, pp. 593–596, 2001.

[28] S. A. Grubb and C. K. Kelly, "Cervical discography: clinical implications from 12 years of experience," *Spine*, vol. 25, no. 11, pp. 1382–1389, 2000.

[29] A. Dwyer, C. Aprill, and N. Bogduk, "Cervical zygapophyseal joint pain patterns I: a study in normal volunteers," *Spine*, vol. 15, no. 6, pp. 453–457, 1990.

[30] J. G. Heller, "The syndromes of degenerative cervical disease," *Orthopedic Clinics of North America*, vol. 23, no. 3, pp. 381–394, 1992.

[31] M. R. Ellenberg, J. C. Honet, and W. J. Treanor, "Cervical radiculopathy," *Archives of Physical Medicine and Rehabilitation*, vol. 75, no. 3, pp. 342–352, 1994.

[32] C. M. Henderson, R. G. Hennessy, H. M. Shuey, and E. G. Shackelford, "Posterior-lateral foraminotomy as an exclusive operative technique for cervical radiculopathy: a review of 846 consecutively operated cases," *Neurosurgery*, vol. 13, no. 5, pp. 504–512, 1983.

[33] R. I. Davidson, E. J. Duun, and J. N. Metzmaker, "The shoulder abduction test in the diagnosis of radicular pain in cervical extradural compressive monoradiculopathies," *Spine*, vol. 6, no. 5, pp. 441–446, 1981.

[34] M. Cornefjord, K. Olmarker, D. B. Farley, J. N. Weinstein, and B. Rydevik, "Neuropeptide changes in compressed spinal nerve roots," *Spine*, vol. 20, no. 6, pp. 670–673, 1995.

[35] R. G. Cooper, A. J. Freemont, J. A. Hoyland et al., "Herniated intervertebral disc-associated periradicular fibrosis and vascular abnormalities occur without inflammatory cell infiltration," *Spine*, vol. 20, no. 5, pp. 591–598, 1995.

[36] B. L. Rydevik, R. R. Myers, and H. C. Powell, "Pressure increase in the dorsal root ganglion following mechanical compression: closed compartment syndrome in nerve roots," *Spine*, vol. 14, no. 6, pp. 574–576, 1989.

[37] S. Kobayashi, Y. Kokubo, K. Uchida et al., "Effect of lumbar nerve root compression on primary sensory neurons and their central branches: changes in the nociceptive neuropeptides substance P and somatostatin," *Spine*, vol. 30, no. 3, pp. 276–282, 2005.

[38] Y. Murata, A. Onda, B. Rydevik, I. Takahashi, K. Takahashi, and K. Olmarker, "Changes in pain behavior and histologic changes caused by application of tumor necrosis factor-alpha to the dorsal root ganglion in rats," *Spine*, vol. 31, no. 5, pp. 530–535, 2006.

[39] W. F. Young, M. Weaver, and B. Mishra, "Surgical outcome in patients with coexisting multiple sclerosis and spondylosis," *Acta Neurologica Scandinavica*, vol. 100, no. 2, pp. 84–87, 1999.

[40] J. J. Denno and G. R. Meadows, "Early diagnosis of cervical spondylotic myelopathy: a useful clinical sign," *Spine*, vol. 16, no. 12, pp. 1353–1355, 1991.

[41] R. D. Sung and J. C. Wang, "Correlation between a positive Hoffmann's reflex and cervical pathology in asymptomatic individuals," *Spine*, vol. 26, no. 1, pp. 67–70, 2001.

[42] S. Ebara, K. Yonenobu, K. Fujiwara, K. Yamashita, and K. Ono, "Myelopathy hand characterized by muscle wasting. A different type of myelopathy hand in patients with cervical spondylosis," *Spine*, vol. 13, no. 7, pp. 785–791, 1988.

[43] K. Ono, S. Ebara, and T. Fuji, "Myelopathy hand. New clinical signs of cervical cord damage," *Journal of Bone and Joint Surgery—Series B*, vol. 69, no. 2, pp. 215–219, 1987.

[44] H. H. Bohlman, "Cervical spondylosis and myelopathy," *Instructional course lectures*, vol. 44, pp. 81–97, 1995.

[45] Y. Morishita, M. Naito, H. Hymanson, M. Miyazaki, G. Wu, and J. C. Wang, "The relationship between the cervical spinal canal diameter and the pathological changes in the cervical

spine," *European Spine Journal*, vol. 18, no. 6, pp. 877–883, 2009.

[46] W. M. Yue, S. B. Tan, M. H. Tan, D. C. S. Koh, and C. T. Tan, "The Torg-Pavlov ratio in cervical spondylotic myelopathy: a comparative study between patients with cervical spondylotic myelopathy and a nonspondylotic, nonmyelopathic population," *Spine*, vol. 26, no. 16, pp. 1760–1764, 2001.

[47] O. W. Houser, B. M. Onofrio, G. M. Miller, W. N. Folger, and P. L. Smith, "Cervical spondylotic stenosis and myelopathy: evaluation with computed tomographic myelography," *Mayo Clinic Proceedings*, vol. 69, no. 6, pp. 557–563, 1994.

[48] L. Penning, J. T. Wilmink, H. H. Van Woerden, and E. Knol, "CT myelographic findings in degenerative disorders of the cervical spine: clinical significance," *American Journal of Roentgenology*, vol. 146, no. 4, pp. 793–801, 1986.

[49] A. Holmes, Z. H. Han, G. T. Dang et al., "Changes in cervical canal spinal volume during in vitro flexion-extension," *Spine*, vol. 21, no. 11, pp. 1313–1319, 1996.

[50] R. Gu, Q. Zhu, Y. Lin, X. Yang, Z. Gao, and Y. Tanaka, "Dynamic canal encroachment of ligamentum flavum: an in vitro study of cadaveric specimens," *Journal of Spinal Disorders and Techniques*, vol. 19, no. 3, pp. 187–190, 2006.

[51] A. Breig, I. Turnbull, and O. Hassler, "Effects of mechanical stresses on the spinal cord in cervical spondylosis. A study on fresh cadaver material," *Journal of Neurosurgery*, vol. 25, no. 1, pp. 45–56, 1966.

[52] B. Wang, H. Liu, H. Wang, and D. Zhou, "Segmental instability in cervical spondylotic myelopathy with severe disc degeneration," *Spine*, vol. 31, no. 12, pp. 1327–1331, 2006.

[53] M. R. Stoffman, M. S. Roberts, and J. T. King, "Cervical spondylotic myelopathy, depression, and anxiety: a cohort analysis of 89 patients," *Neurosurgery*, vol. 57, no. 2, pp. 307–313, 2005.

Hindawi Publishing Corporation
Advances in Orthopedics
Volume 2012, Article ID 919153, 8 pages
doi:10.1155/2012/919153

Review Article

Operative Outcomes for Cervical Myelopathy and Radiculopathy

J. G. Galbraith,[1] J. S. Butler,[2] A. M. Dolan,[1] and J. M. O'Byrne[2]

[1] *Department of Trauma and Orthopaedic Surgery, Cork University Hospital, Wilton, Cork, Ireland*
[2] *Department of Trauma and Orthopaedic Surgery, Cappagh National Orthopaedic Hospital, Finglas, Dublin 11, Ireland*

Correspondence should be addressed to J. G. Galbraith, johng442@hotmail.com

Received 28 March 2011; Accepted 16 August 2011

Academic Editor: F. Cumhur Öner

Cervical spondylotic myelopathy and radiculopathy are common disorders which can lead to significant clinical morbidity. Conservative management, such as physical therapy, cervical immobilisation, or anti-inflammatory medications, is the preferred and often only required intervention. Surgical intervention is reserved for those patients who have intractable pain or progressive neurological symptoms. The goals of surgical treatment are decompression of the spinal cord and nerve roots and deformity prevention by maintaining or supplementing spinal stability and alleviating pain. Numerous surgical techniques exist to alleviate symptoms, which are achieved through anterior, posterior, or circumferential approaches. Under most circumstances, one approach will produce optimal results. It is important that the surgical plan is tailored to address each individual's unique clinical circumstance. The objective of this paper is to analyse the major surgical treatment options for cervical myelopathy and radiculopathy focusing on outcomes and complications.

1. Introduction

Spondylosis is the most common cause of neural dysfunction in the cervical spine and is becoming more prevalent as the average life-expectancy increases [1]. The degenerative changes associated with ageing include disc herniation, osteophyte formation, hypertrophy of osteoarthritic facet joints, and hypertrophy of ligaments. This condition is often asymptomatic, but in 10% to 15% of cases it compresses the cervical spinal cord and roots to present symptomatically as myelopathy or radiculopathy [2, 3]. Conservative management, such as physical therapy, cervical immobilisation, or anti-inflammatory medications are the preferred and often only required intervention [4]. Surgical intervention is reserved for those patients who have intractable pain or progressive neurological symptoms. Herniated cervical discs and spondylosis causing radiculopathy may be treated from an anterior or posterior approach. Likewise, decompression of the spinal cord can be achieved from either approach. The goals of surgical treatment are decompression of the spinal cord and nerve roots and deformity prevention by maintaining or supplementing spinal stability and alleviating pain.

Many surgical techniques have been described to decompress the spinal cord and roots which can employ an anterior, posterior, or circumferential approach. Under most circumstances, one approach will produce optimal results [5–10]. Designing the most effective surgical plan is dependent on numerous factors, including the location of the compressive pathology, stability of the spinal column, extent of the disease, medical comorbidity, and the surgeon's experience and comfort level with specific procedures. The objective of this paper is to analyse the major surgical treatment options for cervical myelopathy and radiculopathy focusing on outcomes and complications.

2. Treatment Outcomes for Cervical Spondylotic Myelopathy

2.1. Posterior Surgical Techniques. A posterior approach is best utilised when pathology is present dorsally in the spinal canal. It avoids extensive dissection of vital neck structures and graft-related complications encountered with anterior approaches. Major approach-related complications include postoperative pain from injury to paraspinal

muscles, epidural haematoma, and neurological injury. It is contraindicated in a kyphotic deformity, and there is limited potential for open deformity reduction with the more common posterior fixation techniques [6, 11–14].

2.1.1. Laminectomy. Laminectomy has been proven to be a safe and effective technique for multilevel decompression for cervical spondylotic myelopathy (CSM) [12, 15]. Laminectomy without fusion has demonstrated comparable immediate postoperative results to laminoplasty and anterior procedures [6]. There is a body of evidence, however, demonstrating late deterioration, with rates as high as 40% [6, 10, 16].

Miyazaki and Kirita described 155 patients who underwent multilevel laminectomy [17]. They reported an improvement in JOA (Japanese Orthopaedic Association) outcome scale for 82% of patients at a mean followup of 1 year. Eleven percent reported worsening symptoms and 7% remained the same. Ebersold et al. reported outcomes in 51 patients who underwent laminectomy for myelopathy [6]. At 6 months, 69% showed improvement on the Nurick scale but only 37% sustained the improvement at long-term followup (range 3 to 9.5 years).

Neurological injury is a rare but serious complication of this procedure. The incidence of spinal cord injury is from 0% to 3%, whereas injury to an individual nerve root can be as high as 15% [18, 19]. Nerve root injury occurs due to direct manipulation or dorsal migration of the spinal cord after decompression [19]. Epidural haematoma occurs in 0.08 to 1.3% of cases [13]. Postlaminectomy kyphosis and segmental instability are well-documented complications which have led to the limited indication of laminectomy alone as a surgical option for CSM. This postlaminectomy spinal instability is reported to occur in 14–47% of patients [9, 10, 20]. This has not been shown to be associated with the observed delayed neurological deterioration [9, 10, 20, 21]. Kato et al. described the JOA outcome in 44 patients who underwent laminectomy. There was 44.2% recovery rate at 1 year that decreased to 43% at 5 years and 33% at 10 years. There was a 47% rate of postoperative kyphosis and a 23% incidence of late deterioration (mean 9.5 years). The development of kyphosis did not appear to correlate with neurological deterioration in these cases [10].

Laminectomy can be augmented to include posterior instrumentation to address instability which leads to lower rates of kyphosis and segmental instability. Despite this increased stability, addition of instrumentation can lead to complications such as hardware failure with loss of alignment and neurological damage from misplaced lateral mass screws. Heller et al. from their series reported a 1% risk of nerve root injury per screw placed [22]. Adjacent segment degeneration can also occur due to alterations to cervical biomechanics and force distribution following a fusion procedure [10]. Houten et al. evaluated 38 patients who underwent laminectomy and lateral mass plating for CSM [8]. Significant improvement in neurological function occurred in 97% of patients. The modified JOA score improved from 12.9 to 15.6 at a mean followup of 30.2 months (minimum 6-months). Radiographic alignment by the cervical index was maintained postoperatively. Complications included a C-5 nerve root palsy, a radiculopathy from a misplaced screw, and one wound infection. Huang et al. reviewed 31 patients who underwent laminectomy and lateral mass plating for CSM or OPLL [23]. Twenty-two (71%) of 31 patients had improvement in Nurick score of ≥ 1 point at a minimum of 6 months of followup (mean 15 months). Perez-Lopez et al. compared 19 patients that underwent laminectomy to 17 that underwent laminectomy and fusion [24]. They found similar improvement in Nurick scores but, there was an increase in postoperative kyphosis with in the laminectomy alone cohort (24%) compared to the laminectomy and fusion group (7%).

2.1.2. Laminoplasty. Laminoplasty was developed to allow cord decompression while preserving motion with less substantial alteration to the natural biomechanics of the cervical spine. Multiple studies have demonstrated its effectiveness using the JOA outcome scale, with approximately 55–65% achieving recovery [25–30].

In the short term, Kihara et al. reported on 151 patients with CSM who underwent laminoplasty [28]. The mean JOA scale score increased from 8.1 to 15.2 at 1-year followup. Similarly, Suda et al. reported on 154 patients with CSM who underwent French-window laminoplasty [29]. The JOA scale score improved from 9.9 to 14.0 (60% improvement) at a mean followup of 5 years. In the longer term, Seichi et al. reviewed 60 patients (35 with OPLL and 25 with CSM) who underwent French-window laminoplasty [27]. In the OPLL group, the JOA scale score increased from 8.6 to 12.1; similar increases were seen in the patients with CSM (improvement from 8.3 to 12.0) at followup of 10 years. Late clinical worsening was observed in 11 patients (7 with OPLL and 4 with CSM).

Several variations of laminoplasty have been described in order to minimise complications [11]. Okada et al. recently carried out a prospective randomised clinical study comparing open-door laminoplasty to French-door laminoplasty in 40 patients [26]. JOA scores and recovery rates were similar at long-term followup (mean 26.9 months). However, French-door laminoplasty had less complications, increased cervical lordotic angle, and significantly less axial neck pain postoperatively suggesting that this may be a better procedure for CSM.

Decreased range of movement and axial neck pain are frequently reported complications. Ratliff and Cooper performed a meta-analysis evaluating the outcomes after laminoplasty in 71 retrospective reports [30]. They determined the overall incidence of postoperative axial neck pain ranged from 6% to 60% without apparent dependence on the specific variation of laminoplasty. Cervical range of movement decreased substantially after laminoplasty (mean decrease 50%, range 17–80%). Wada et al. performed a study comparing subtotal corpectomy and laminoplasty Axial pain was observed in 15% of the corpectomy group and in 40% of the laminoplasty group [25]. The aetiology of neck pain remains unclear, but has been postulated to occur secondary to neck muscle disruption, particularly detachment of muscle insertions to the C2 and C7 spinous processes

[31, 32]. Other authors have reported that preservation of subaxial deep extensor muscles, including the semispinalis cervicis groups, reduces these adverse effects after cervical laminoplasty [33]. However, a recent study by Sakaura et al. suggests that preservation of subaxial deep extensor muscles plays no significant role in reducing axial neck pain supporting the idea that axial pain after laminoplasty largely results from detachment of muscles attached to the C2 and C7 spinous processes [34].

2.2. Anterior Surgical Techniques. This approach allows direct decompression of ventral pathology but can also be used to restore lordosis to a kyphotic spine. The anterior approach comes in proximity with many vital structures in the neck. Complications resulting from this approach include, dysphagia, recurrent laryngeal nerve damage, dural tears, and rarely tracheal or oesophageal perforation (less than 0.25%) [35, 36].

Postoperative dysphagia has been reported to have an overall average incidence of 12.3% [37, 38]. This dysphagia is usually transient with residual symptoms decreasing to 4.8% after 6 months [39].

2.2.1. Anterior Cervical Discectomy. Anterior Cervical Discectomy with or without fusion is effective for ventral pathology that is confined to the cervical interspaces such as osteophyte or disc complexes. Most of the recent literature has focused on outcomes for Anterior Cervical Discectomy with Fusion (ACDF). Short- and long-term clinical success in the range of 67% to 100% has been extensively reported in the literature [6, 40–47]. Despite the increasing popularity of ACDF, it has not been proven to produce better clinical outcomes than anterior cervical discectomy without fusion (ACD) [48, 49].

Ebersold et al. reported Nurick scale outcomes in 33 patients with ACDF at 1 or 2 levels [6]. Six-month outcomes showed improvements of 73% and long-term improvement of 55% (range 3 to 9.5 years). Yue et al. reviewed 71 patients, after an average of 7.2 years, who had anterior cervical discectomy and fusion with allograft and plating [43]. Patients reported improvement in axial neck pain (95.5%), radicular arm pain (95.4%), upper extremity weakness (82.7%), upper extremity numbness (85.1%), and gait problems (100%). Fusion occurred in 92.6% of the disc spaces operated on and no graft extrusion or migration occurred. Clinical improvements were not related to the occurrence of union.

Autograft from either the iliac crest or fibula is traditionally gold standard for fusion [46]. Donor site morbidity, which occurs in 0.6% to 36% of cases, is a complication of its use [50–52]. This can be avoided with the use of allograft. However, their use comes with potential problems, including risk of infections and graft rejection, higher rates of collapse and nonunion, especially in multilevel fusions, and prolonged period required for graft incorporation [46]. Ryken et al. in a comprehensive review concluded that there appears to be equivalency regarding the use of harvested autogenous bone graft, allograft, polyetheretherketone, and titanium cages in anterior fusion [53].

ACDF of 1 to 3 levels has been reported to be effective and safe in decompressing ventral pathology. The rate of fusion following single-level ACDF generally ranges from 80% to 95% [54–57]. However, applying this procedure to greater than 3 levels can often result in complications, including graft extrusion, subsidence, fracture, and pseudoarthrosis [40].

Nirala et al. reviewed 69 patients that underwent multilevel ACDF using autograft iliac crest without fixation. Fusion was assessed on dynamic radiographs. The overall fusion rate for multilevel ACDF was 69.6%, The fusion rate was 86.7% for 2 levels, 57.6% for 3 levels, and 50% for 4 levels. The outcome score using Odom's criteria was good or excellent in 81.1%. Graft dislodgements were noted in 1.4% [54]. Fraser and Härtl performed a systematic review comparing ACDF with anterior cervical corpectomy with fusion (ACCF) [58]. They analyzed a combined group of 2682 patients. They found similar fusion rates (>90%) for 2-level disc disease treated with either 2-level ACDF plus fixation or 1-level ACCF plus fixation. For 3-level disc disease, fusion rates for ACDF with plate fixation (82.5% fusion rate) were significantly lower than for ACCF with plate fixation (96.2% fusion rate).

The use of plating remains a controversial issue. In multilevel ACDFs, studies have demonstrated that rigid plate fixation dramatically increases fusion rates [44, 46, 47]. The aim is to promote solid bone fusion, maintain cervical alignment, decrease need for external orthosis, and prevent graft subsidence, extrusion, or collapse. However, the efficacy of rigid plate fixation on interbody fusion in one-level ACDF is not as clear. Some reports suggest that it can decrease fusion rates due to stress shielding and poor graft settling [42, 45]. Some studies advocate better fusion rates with dynamic plating [59]. Plating can also lead to complications including adjacent level degeneration, soft tissue injury, and implant failure [41].

2.2.2. Anterior Cervical Corpectomy. Anterior cervical corpectomy with fusion (ACCF) is effective in addressing ventral pathology that extends beyond the cervical spine interspaces [58]. ACCF has the potential to allow reduction of kyphotic deformities that exacerbate CSM. Stabilisation after corpectomy is achieved with or without instrumentation using tricortical autogenous iliac bone graft, autogenous, or allogenous fibular graft, and more recently titanium mesh cages (TMC), stackable PEEK (polyetheretherketone), and CFRP (carbon-fibre-reinforced polymer) cages [60, 61].

ACCF compares favourably when compared to other decompression techniques in terms of stability and clinical outcomes [58]. Hilibrand et al. reviewed a series of 190 patients with a mean followup of 68 months [62]. There were 131 patients that underwent ACDF using autograft without fixation and 59 patients that underwent ACCF using iliac or fibula strut autograft. The fusion, which was assessed on dynamic radiographs, was higher in patients who underwent ACCF but clinical outcomes using Robinson's criteria were not statistically different between the groups. Wada et al. reviewed 23 patients that underwent ACCF. The average JOA score was 7.9 before surgery, 13.3 at the 1-year follow-up visit, and 13.9 at the 5-year followup visit

[25]. Similarly, Yonenobu et al. compared the results of corpectomy, laminectomy, and discectomy and concluded that ACCF provided a better neurologic recovery [63]. They suggested that ACCF should be used for treatment of CSM for up to 3 levels and posterior laminectomy for 4 levels or more.

Single-level corpectomy is generally considered safe and associated with successful outcomes for CSM [64]. However, increasing the number of vertebral bodies resected during a corpectomy is associated with an increase in graft-related complications and pseudoarthrosis [19, 61]. Wang et al. reported 249 consecutive patients underwent one- to five-level anterior cervical corpectomies and autogenous strut grafting [61]. During the follow-up period (mean 4.7 years), 16 patients experienced migration of their grafts. The graft migration rates increased with more levels of fusion. Ikenaga et al. reported a much lower rate of pseudoarthrosis. They reviewed 31 patients that had anterior corpectomy and fibular strut grafting for 4-disc levels or greater for CSM for over 10 years [65]. There were 1 patient that developed pseudoarthrosis and 3 patients who had deterioration of JOA score of 1 point.

Plating has been shown to reduce multilevel corpectomy but also in single level corpectomy [46, 47, 60, 61, 66]. Epstein found that plating can decrease the prevalence of graft-related complications following single level ACCF [66]. He reviewed 48 patients undergoing ACCF, 8 of who had plating. Overall there was a 73% fusion rate but 10.3% of cases required revision surgery for graft-related complications or pseudoarthrosis. Of the 8 patients that had plating there were no graft related complications.

Several articles have evaluated effectiveness of titanium mesh cage for reconstruction following anterior cervical corpectomy. Narotam et al. prospectively evaluated 37 patients over a 4-year period, and noted a stability rate of 100% at 1 year after ACCF with a TMC cage. Cage-related complication rate was low (2.7%). Excellent neurological outcome was documented in 95% of the patients. Similarly, Daubs and Kabir et al. reported similar good short-term results with spinal fusion observed in 100% of patients [60, 67].

3. Treatment Outcomes for Cervical Radiculopathy

The objective of operative treatment in cervical radiculopathy is to alleviate pain, decrease sensorimotor deficits, and improve quality of life. This can be achieved by the permanent decompression of the compressed nerve root [5]. Similarly to CSM surgical treatment, treatment options can utilise a posterior or an anterior approach. The procedures achieved through these approaches differ in complexity, duration, and complications [68]. The choice of procedure should depend on the patient's symptoms and the morphology of the pathology.

3.1. Posterior Laminoforaminotomy. Posterior laminoforaminotomy is used for decompression of the nerve root in cases of foraminal stenosis or removal of posterolateral soft disc fragments. It maintains the motion in the affected segment and does not cause major instability [69]. Due to the nature of the approach it also has a lower complication rate when compared to anterior procedures [7, 68]. There is a large body of evidence which suggests that it is an effective procedure for cervical monoradiculopathy [70].

Kumar et al. reviewed 89 patients treated with laminoforaminotomy for cervical spondylotic radiculopathy caused by osteophytes [71]. Patients with disc herniation were excluded. Good or excellent results were obtained in 95.5% of patients, a mean followup of 8.6 months using Odom's criteria. Repeat surgery for recurrence was required in 6.7% of cases. Davis reviewed 170 patients who underwent laminoforaminotomy for cervical radiculopathy [72]. Followup, at a mean of 15 years, revealed good or excellent outcomes in 86% of patients, based on Prolo score. There was a 6% recurrence rate with most occurring within the first 3 years of the index surgery. Herkowitz et al. performed a comparison of laminoforaminotomy with ACDF to treat of cervical herniated discs causing radiculopathy in 33 patients [7]. Good and excellent results were reported in 94% of the ACDF group and 75% of the laminoforaminotomy group at a mean followup of 4.2 years. The difference, however, was not statistically significant.

Shorter duration of the operation and fewer complications, compared to anterior surgery, have been reported as major advantages of posterior laminoforaminotomy [68]. However, complications of this technique include neurological damage, infection, and recurrence of symptoms [71, 72]. A major limitation is that it does not allow removal of offending lesions located medioventral to the nerve root [68].

3.2. Anterior Cervical Discectomy. Anterior cervical discectomy and fusion (ACDF) is suggested for the treatment of single-level degenerative cervical radiculopathy for compressive lesions medioventral to the nerve root [5]. Despite providing better access to certain compressive pathologies this technique has the potential for many complications [73]. These relate to the anterior approach itself, graft-related complications, and spinal instability as discussed in the previous section. Despite these complications, many of studies have demonstrated ACDF to be an effective way of alleviating radicular symptoms.

Peolsson et al. reported 34 patients that underwent anterior decompression for cervical radiculopathy with 3-year followup [74]. All patients had an improvement in Visual Analogue Scale, Neck Disability Index scores, and sensory deficit. Korinth et al. reviewed 292 patients with cervical soft disc disease causing radiculopathy at a single level [68]. They compared anterior cervical discectomy using a polymethylacrylate spacer with a posterior laminoforaminotomy procedure. Good and excellent results were found to be statistically different between the anterior (93.6%) and posterior (85.1%) groups in favour of the anterior approach using Odom's criteria at a mean followup of 6.1 years.

As previously discussed, iliac crest autograft is the gold standard but other fusion techniques may be utilised,

each with their own benefits and complications [46]. In the treatment of single-level cervical radiculopathy, ACDF with plate fixation demonstrates similar clinical outcomes and fusion rates to ACDF without plate fixation [75–77]. However, the use of a cervical plate can improve sagittal alignment after ACDF [75–77]. Evidence suggests that plate stabilization may be indicated for some patients undergoing multilevel ACDF for radiculopathy. There is a paucity of evidence linking this practice to significant improvement in clinical outcomes [5].

In recent times, much attention has been focused on the use of cervical disc arthroplasty in an attempt to preserve motion segments. Short-term outcomes suggested comparable efficacy to ACDF for the treatment of single-level degenerative cervical radiculopathy [78, 79]. In the longer-term, Quam et al. reported on 21 patients who underwent 1 or 2 level cervical disc arthroplasty for radiculopathy [80]. At 8 years followup, the Bryan cervical disc arthroplasty maintained favourable clinical and radiological results, with preservation of movement and satisfactory clinical outcome in the majority of cases. However, 48% operated segments developed heterotopic ossification causing restricted range of movement of the prosthesis.

4. Conclusion

Cervical spondylotic myelopathy and radiculopathy are common disorders which can lead to significant clinical morbidity. Numerous surgical techniques exist to alleviate symptoms, which are achieved through anterior, posterior, or circumferential approaches. Under most circumstances, one approach will produce optimal results. The surgical plan should be tailored to address each individual's unique clinical circumstance.

When considering surgical outcomes for CSM, it is important to remember that regardless of surgical technique employed, results of operative treatment generally are better in patients who undergo early decompression. In a prospective study of 146 patients with cervical spondylotic myelopathy, Suri et al. noted that patients with less than a one-year duration of symptoms showed significantly greater motor recovery following operation than did those with a longer duration of symptoms [81]. This finding is supported by numerous other studies [82, 83]. Conversely, the symptoms for most patients with degenerative cervical radiculopathy will be self-limited and will resolve spontaneously over a variable length of time without specific treatment [5]. Surgical intervention, however, can lead to rapid relief of symptoms of cervical radiculopathy compared to conservative measures alone [84, 85].

An extensive review of the current peer-reviewed literature does not provide an evidence base to indicate whether anterior or posterior surgery yields superior short- and long-term results for both CSM and cervical radiculopathy. Well-designed prospective randomised-control trials involving patients with these clinical scenarios could help to properly evaluate this.

References

[1] W. F. Young, "Cervical spondylotic myelopathy: a common cause of spinal cord dysfunction in older persons," *American Family Physician*, vol. 62, no. 5, pp. 1064–1070, 2000.

[2] J. Bednarik, Z. Kadanka, L. Dusek et al., "Presymptomatic spondylotic cervical cord compression," *Spine*, vol. 29, no. 20, pp. 2260–2269, 2004.

[3] L. M. Teresi, R. B. Lufkin, and M. A. Reicher, "Asymptomatic degenerative disk disease and spondylosis of the cervical spine: MR imaging," *Radiology*, vol. 164, no. 1, pp. 83–88, 1987.

[4] I. Nikolaidis, I. P. Fouyas, P. A. Sandercock, and P. F. Statham, "Surgery for cervical radiculopathy or myelopathy," *Cochrane Database of Systematic Reviews*, no. 1, Article ID CD001466, 2010.

[5] C. M. Bono, G. Ghiselli, T. J. Gilbert et al., "An evidence-based clinical guideline for the diagnosis and treatment of cervical radiculopathy from degenerative disorders," *Spine Journal*, vol. 11, no. 1, pp. 64–72, 2011.

[6] M. J. Ebersold, M. C. Pare, and L. M. Quast, "Surgical treatment for cervical spondylitic myelopathy," *Journal of Neurosurgery*, vol. 82, no. 5, pp. 745–751, 1995.

[7] H. N. Herkowitz, L. T. Kurz, and D. P. Overholt, "Surgical management of cervical soft disc herniation: a comparison between the anterior and posterior approach," *Spine*, vol. 15, no. 10, pp. 1026–1030, 1990.

[8] J. K. Houten, P. R. Cooper, E. C. Benzel, V. K. H. Sonntag, V. C. Traynelis, and U. Batzdorf, "Laminectomy and posterior cervical plating for multilevel cervical spondylotic myelopathy and ossification of the posterior longitudinal ligament: effects on cervical alignment, spinal cord compression, and neurological outcome," *Neurosurgery*, vol. 52, no. 5, pp. 1081–1088, 2003.

[9] G. J. Kaptain, N. E. Simmons, R. E. Replogle, and L. Pobereskin, "Incidence and outcome of kyphotic deformity following laminectomy for cervical spondylotic myelopathy," *Journal of Neurosurgery*, vol. 93, no. 2, pp. 199–204, 2000.

[10] Y. Kato, M. Iwasaki, T. Fuji, K. Yonenobu, and T. Ochi, "Long-term follow-up results of laminectomy for cervical myelopathy caused by ossification of the posterior longitudinal ligament," *Journal of Neurosurgery*, vol. 89, no. 2, pp. 217–223, 1998.

[11] J. J. Hale, K. I. Gruson, and J. M. Spivak, "Laminoplasty: a review of its role in compressive cervical myelopathy," *Spine Journal*, vol. 6, no. 6, pp. S289–S298, 2006.

[12] M. G. Fehlings, P. R. Cooper, and T. J. Errico, "Posterior plates in the management of cervical instability: long-term results in 44 patients," *Journal of Neurosurgery*, vol. 81, no. 3, pp. 341–349, 1994.

[13] C. M. Halvorsen, B. Lied, M. E. Harr et al., "Surgical mortality and complications leading to reoperation in 318 consecutive posterior decompressions for cervical spondylotic myelopathy," *Acta Neurologica Scandinavica*, vol. 123, no. 5, pp. 358–365, 2011.

[14] R. J. Komotar, J. Mocco, and M. G. Kaiser, "Surgical management of cervical myelopathy: indications and techniques for laminectomy and fusion," *Spine Journal*, vol. 6, no. 6, pp. S252–S267, 2006.

[15] P. A. Anderson, M. B. Henley, M. S. Grady, P. X. Montesano, and H. R. Winn, "Posterior cervical arthrodesis with AO reconstruction plates and bone graft," *Spine*, vol. 16, no. 3, pp. S72–S79, 1991.

[16] R. B. Snow and H. Weiner, "Cervical laminectomy and foraminotomy as surgical treatment of cervical spondylosis: a follow-up study with analysis of failures," *Journal of Spinal Disorders*, vol. 6, no. 3, pp. 245–251, 1993.

[17] K. Miyazaki and Y. Kirita, "Extensive simultaneous multisegment laminectomy for myelopathy due to the ossification of the posterior longitudinal ligament in the cervical region," *Spine*, vol. 11, no. 6, pp. 531–542, 1986.

[18] K. Yonenobu, N. Hosono, M. Iwasaki, M. Asano, and K. Ono, "Neurologic complications of surgery for cervical compression myelopathy," *Spine*, vol. 16, no. 11, pp. 1277–1282, 1991.

[19] R. L. Saunders, H. J. Pikus, and P. Ball, "Four-level cervical corpectomy," *Spine*, vol. 23, no. 22, pp. 2455–2461, 1998.

[20] Y. Mikawa, J. Shikata, and T. Yamamuro, "Spinal deformity and instability after multilevel cervical laminectomy," *Spine*, vol. 12, no. 1, pp. 6–11, 1987.

[21] S. Matsunaga, T. Sakou, and K. Nakanisi, "Analysis of the cervical spine alignment following laminoplasty and laminectomy," *Spinal Cord*, vol. 37, no. 1, pp. 20–24, 1999.

[22] J. G. Heller, D. H. Silcox, and C. E. Sutterlin, "Complications of posterior cervical plating," *Spine*, vol. 20, no. 22, pp. 2442–2448, 1995.

[23] R. C. Huang, F. P. Girardi, A. R. Poynton, and F. P. Cammisa, "Treatment of multilevel cervical spondylotic myeloradiculopathy with posterior decompression and fusion with lateral mass plate fixation and local bone graft," *Journal of Spinal Disorders and Techniques*, vol. 16, no. 2, pp. 123–129, 2003.

[24] C. Perez-Lopez, A. Isla, F. Alvarez, M. A. Sarmiento, P. Garcia-Raya, and M. Perez-Alvarez, "Efficacy of arthrodesis in the posterior approach of cervical myelopathy: comparative study of a series of 36 cases," *Neurocirugia*, vol. 12, no. 4, pp. 316–324, 2001.

[25] E. Wada, S. Suzuki, A. Kanazawa, T. Matsuoka, S. Miyamoto, and K. Yonenobu, "Subtotal corpectomy versus laminoplasty for multilevel cervical spondylotic myelopathy: a long-term follow-up study over 10 years," *Spine*, vol. 26, no. 13, pp. 1443–1447, 2001.

[26] M. Okada, A. Minamide, T. Endo et al., "A prospective randomized study of clinical outcomes in patients with cervical compressive myelopathy treated with open-door or french-door laminoplasty," *Spine*, vol. 34, no. 11, pp. 1119–1126, 2009.

[27] A. Seichi, K. Takeshita, I. Ohishi et al., "Long-term results of double-door laminoplasty for cervical stenotic myelopathy," *Spine*, vol. 26, no. 5, pp. 479–487, 2001.

[28] S. I. Kihara, T. Umebayashi, and M. Hoshimaru, "Technical improvements and results of open-door expansive laminoplasty with hydroxyapatite implants for cervical myelopathy," *Neurosurgery*, vol. 57, no. 4, supplement, pp. S-348–S-355, 2005.

[29] K. Suda, K. Abumi, M. Ito, Y. Shono, K. Kaneda, and M. Fujiya, "Local kyphosis reduces surgical outcomes of expansive open-door laminoplasty for cervical spondylotic myelopathy," *Spine*, vol. 28, no. 12, pp. 1258–1262, 2003.

[30] J. K. Ratliff and P. R. Cooper, "Cervical laminoplasty: a critical review," *Journal of Neurosurgery*, vol. 98, no. 3, supplement, pp. 230–238, 2003.

[31] K. Takeuchi, T. Yokoyama, S. Aburakawa et al., "Axial symptoms after cervical laminoplasty with C3 laminectomy compared with conventional C3-C7 laminoplasty: a modified laminoplasty preserving the semispinalis cervicis inserted into axis," *Spine*, vol. 30, no. 22, pp. 2544–2549, 2005.

[32] T. Takeuchi and Y. Shono, "Importance of preserving the C7 spinous process and attached nuchal ligament in French-door laminoplasty to reduce postoperative axial symptoms," *European Spine Journal*, vol. 16, no. 9, pp. 1417–1422, 2007.

[33] T. Shiraishi, K. Fukuda, Y. Yato, M. Nakamura, and T. Ikegami, "Results of skip laminectomy—minimum 2-year follow-up study compared with open-door laminoplasty," *Spine*, vol. 28, no. 24, pp. 2667–2672, 2003.

[34] H. Sakaura, N. Hosono, Y. Mukai, T. Fujimori, M. Iwasaki, and H. Yoshikawa, "Preservation of muscles attached to the C2 and C7 spinous processes rather than subaxial deep extensors reduces adverse effects after cervical laminoplasty," *Spine*, vol. 35, no. 16, pp. E782–E786, 2010.

[35] K. E. Newhouse, R. W. Lindsey, C. R. Clark, J. Lieponis, and M. J. Murphy, "Esophageal perforation following anterior cervical spine surgery," *Spine*, vol. 14, no. 10, pp. 1051–1053, 1989.

[36] K. N. Fountas, E. Z. Kapsalaki, L. G. Nikolakakos et al., "Anterior cervical discectomy and fusion associated complications," *Spine*, vol. 32, no. 21, pp. 2310–2317, 2007.

[37] J. L. Netterville, M. J. Koriwchak, M. Winkle, M. S. Courey, and R. H. Ossoff, "Vocal fold paralysis following the anterior approach to the cervical spine," *Annals of Otology, Rhinology and Laryngology*, vol. 105, no. 2, pp. 85–91, 1996.

[38] E. M. Baron, A. M. S. Soliman, L. Simpson, J. P. Gaughan, and W. F. Young, "Dysphagia, hoarseness, and unilateral true vocal fold motion impairment following anterior cervical diskectomy and fusion," *Annals of Otology, Rhinology and Laryngology*, vol. 112, no. 11, pp. 921–926, 2003.

[39] R. Bazaz, M. J. Lee, and J. U. Yoo, "Incidence of dysphagia after anterior cervical spine surgery: a prospective study," *Spine*, vol. 27, no. 22, pp. 2453–2458, 2002.

[40] M. J. Bolesta, G. R. Rechtine II, and A. M. Chrin, "Three- and four-level anterior cervical discectomy and fusion with plate fixation: a prospective study," *Spine*, vol. 25, no. 16, pp. 2040–2044, 2000.

[41] A. R. Vaccaro and R. A. Balderston, "Anterior plate instrumentation for disorders of the subaxial cervical spine," *Clinical Orthopaedics and Related Research*, no. 335, pp. 112–121, 1997.

[42] G. R. Zaveri and M. Ford, "Cervical spondylosis: the role of anterior instrumentation after decompression and fusion," *Journal of Spinal Disorders*, vol. 14, no. 1, pp. 10–16, 2001.

[43] W. M. Yue, W. Brodner, and T. R. Highland, "Long-term results after anterior cervical discectomy and fusion with allograft and plating: a 5- to 11-year radiologic and clinical follow-up study," *Spine*, vol. 30, no. 19, pp. 2138–2144, 2005.

[44] M. G. Kaiser, R. W. Haid, B. R. Subach, B. Barnes, and G. E. Rodts, "Anterior cervical plating enhances arthrodesis after discectomy and fusion with cortical allograft," *Neurosurgery*, vol. 50, no. 2, pp. 229–236, 2002.

[45] D. Samartzis, F. H. Shen, C. Lyon, M. Phillips, E. J. Goldberg, and H. S. An, "Does rigid instrumentation increase the fusion rate in one-level anterior cervical discectomy and fusion?" *Spine Journal*, vol. 4, no. 6, pp. 636–643, 2004.

[46] J. C. Wang, P. W. McDonough, K. K. Endow, and R. B. Delamarter, "Increased fusion rates with cervical plating for two-level anterior cervical pas and fusion," *Spine*, vol. 25, no. 1, pp. 41–45, 2000.

[47] J. C. Wang, P. W. McDonough, L. E. A. Kanim, K. K. Endow, and R. B. Delamarter, "Increased fusion rates with cervical plating for three-level anterior cervical discectomy and fusion," *Spine*, vol. 26, no. 6, pp. 643–646, 2001.

[48] W. C. Jacobs, P. G. Anderson, J. Limbeek, P. C. Willems, and P. Pavlov, "Single or double-level anterior interbody fusion techniques for cervical degenerative disc disease," *Cochrane Database of Systematic Reviews*, no. 4, Article ID CD004958, 2004.

[49] W. C. Jacobs, P. G. Anderson, J. Limbeek, P. C. Willems, and P. Pavlov, "Single or double-level anterior interbody fusion techniques for cervical degenerative disc disease," *Cochrane Atabase of Systematic Reviews*, no. 4, Article ID CD004958, 2004.

[50] C. A. Brown and F. J. Eismont, "Complications in spinal fusion," *Orthopedic Clinics of North America*, vol. 29, no. 4, pp. 679–699, 1998.

[51] K. M. Malloy and A. S. Hilibrand, "Autograft versus allograft in degenerative cervical disease," *Clinical Orthopaedics and Related Research*, no. 394, pp. 27–38, 2002.

[52] R. C. Bishop, K. A. Moore, and M. N. Hadley, "Anterior cervical interbody fusion using autogeneic and allogeneic bone graft substrate: a prospective comparative analysis," *Journal of Neurosurgery*, vol. 85, no. 2, pp. 206–210, 1996.

[53] T. C. Ryken, R. F. Heary, P. G. Matz et al., "Techniques for cervical interbody grafting," *Journal of Neurosurgery: Spine*, vol. 11, no. 2, pp. 203–220, 2009.

[54] A. P. Nirala, M. Husain, and D. K. Vatsal, "A retrospective study of multiple interbody grafting and long segment strut grafting following multilevel anterior cervical decompression," *British Journal of Neurosurgery*, vol. 18, no. 3, pp. 227–232, 2004.

[55] J. C. Cauthen, R. E. Kinard, J. B. Vogler et al., "Outcome analysis of noninstrumented anterior cervical discectomy and interbody fusion in 348 patients," *Spine*, vol. 23, no. 2, pp. 188–192, 1998.

[56] G. J. Martin Jr., R. W. Haid Jr., M. Macmillan, G. E. Rodts Jr., and R. Berkman, "Anterior cervical discectomy with freeze-dried fibula allograft: overview of 317 cases and literature review," *Spine*, vol. 24, no. 9, pp. 852–858, 1999.

[57] T. A. Zdeblick and T. B. Ducker, "The use of freeze-dried allograft bone for anterior cervical fusions," *Spine*, vol. 16, no. 7, pp. 726–729, 1991.

[58] J. F. Fraser and R. Härtl, "Anterior approaches to fusion of the cervical spine: a metaanalysis of fusion rates," *Journal of Neurosurgery: Spine*, vol. 6, no. 4, pp. 298–303, 2007.

[59] S. W. Hong, S. H. Lee, L. T. Khoo et al., "A comparison of fixed-hole and slotted-hole dynamic plates for anterior cervical discectomy and fusion," *Journal of Spinal Disorders and Techniques*, vol. 23, no. 1, pp. 22–26, 2010.

[60] S. M. R. Kabir, J. Alabi, K. Rezajooi, and A. T. H. Casey, "Anterior cervical corpectomy: review and comparison of results using titanium mesh cages and carbon fibre reinforced polymer cages," *British Journal of Neurosurgery*, vol. 24, no. 5, pp. 542–546, 2010.

[61] J. C. Wang, R. A. Hart, S. E. Emery, and H. H. Bohlman, "Graft migration or displacement after multilevel cervical corpectomy and strut grafting," *Spine*, vol. 28, no. 10, pp. 1016–1021, 2003.

[62] A. S. Hilibrand, M. A. Fye, S. E. Emery, M. A. Palumbo, and H. H. Bohlman, "Increased rate of arthrodesis with strut grafting after multilevel anterior cervical decompression," *Spine*, vol. 27, no. 2, pp. 146–151, 2002.

[63] K. Yonenobu, T. Fuji, and K. Ono, "Choice of surgical treatment for multisegmental cervical spondylotic myelopathy," *Spine*, vol. 10, no. 8, pp. 710–716, 1985.

[64] R. L. Saunders, P. M. Bernini, T. G. Shirreffs, and A. G. Reeves, "Central corpectomy for cervical spondylotic myelopathy: a consecutive series with long-term follow-up evaluation," *Journal of Neurosurgery*, vol. 74, no. 2, pp. 163–170, 1991.

[65] M. Ikenaga, J. Shikata, and C. Tanaka, "Long-term results over 10 years of anterior corpectomy and fusion for multilevel cervical myelopathy," *Spine*, vol. 31, no. 14, pp. 1568–1574, 2006.

[66] N. E. Epstein, "The management of one-level anterior cervical corpectomy with fusion using atlantis hybrid plates: preliminary experience," *Journal of Spinal Disorders*, vol. 13, no. 4, pp. 324–328, 2000.

[67] M. D. Daubs, "Early failures following cervical corpectomy reconstruction with titanium mesh cages and anterior plating," *Spine*, vol. 30, no. 12, pp. 1402–1406, 2005.

[68] M. C. Korinth, A. Kruger, M. F. Oertel, and J. M. Gilsbach, "Posterior foraminotomy or anterior discectomy with polymethyl methacrylate interbody stabilization for cervical soft disc disease: results in 292 patients with monoradiculopathy," *Spine*, vol. 31, no. 11, pp. 1207–1214, 2006.

[69] T. A. Zdeblick, D. Zou, K. E. Warden, R. McCabe, D. Kunz, and R. Vanderby, "Cervical stability after foraminotomy. A biomechanical in vitro analysis," *Journal of Bone and Joint Surgery—Series A*, vol. 74, no. 1, pp. 22–27, 1992.

[70] R. F. Heary, T. C. Ryken, P. G. Matz et al., "Cervical laminoforaminotomy for the treatment of cervical degenerative radiculopathy," *Journal of Neurosurgery: Spine*, vol. 11, no. 2, pp. 198–202, 2009.

[71] G. R. V. Kumar, R. S. Maurice-Williams, and R. Bradford, "Cervical foraminotomy: an effective treatment for cervical spondylotic radiculopathy," *British Journal of Neurosurgery*, vol. 12, no. 6, pp. 563–568, 1998.

[72] R. A. Davis, "A long-term outcome study of 170 surgically treated patients with compressive cervical radiculopathy," *Surgical Neurology*, vol. 46, no. 6, pp. 523–533, 1996.

[73] P. G. Matz, T. C. Ryken, M. W. Groff et al., "Techniques for anterior cervical decompression for radiculopathy," *Journal of Neurosurgery: Spine*, vol. 11, no. 2, pp. 183–197, 2009.

[74] A. Peolsson, L. Vavruch, and B. Öberg, "Can the results 6 months after anterior cervical decompression and fusion identify patients who will have remaining deficit at long-term?" *Disability and Rehabilitation*, vol. 28, no. 2, pp. 117–124, 2006.

[75] D. Grob, J. V. Peyer, and J. Dvorak, "The use of plate fixation in anterior surgery of the degenerative cervical spine: a comparative prospective clinical study," *European Spine Journal*, vol. 10, no. 5, pp. 408–413, 2001.

[76] B. Zoëga, J. Kärrholm, and B. Lind, "One-level cervical spine fusion: a randomized study, with or without plate fixation, using radiostereometry in 27 patients," *Acta Orthopaedica Scandinavica*, vol. 69, no. 4, pp. 363–368, 1998.

[77] R. J. Mobbs, P. Rao, and N. K. Chandran, "Anterior cervical discectomy and fusion: analysis of surgical outcome with and without plating," *Journal of Clinical Neuroscience*, vol. 14, no. 7, pp. 639–642, 2007.

[78] D. Murrey, M. Janssen, R. Delamarter et al., "Results of the prospective, randomized, controlled multicenter Food and Drug Administration investigational device exemption study of the ProDisc-C total disc replacement versus anterior discectomy and fusion for the treatment of 1-level symptomatic cervical disc disease," *Spine Journal*, vol. 9, no. 4, pp. 275–286, 2009.

[79] A. Nabhan, F. Ahlhelm, K. Shariat et al., "The ProDisc-C prothesis: clinical and radiological experience 1 year after surgery," *Spine*, vol. 32, no. 18, pp. 1935–1941, 2007.

[80] G. M. Y. Quan, J. M. Vital, S. Hansen, and V. Pointillart, "8 year clinical and radiological follow-up of the Bryan cervical disc arthroplasty," *Spine*, vol. 36, no. 8, pp. 639–646, 2010.

[81] A. Suri, R. P. S. Chabbra, V. S. Mehta, S. Gaikwad, and R. M. Pandey, "Effect of intramedullary signal changes on the surgical outcome of patients with cervical spondylotic myelopathy," *Spine Journal*, vol. 3, no. 1, pp. 33–45, 2003.

[82] J. Tanaka, N. Seki, F. Tokimura, K. Doi, and S. Inoue, "Operative results of canal-expansive laminoplasty for cervical spondylotic myelopathy in elderly patients," *Spine*, vol. 24, no. 22, pp. 2308–2312, 1999.

[83] T. T. Lee, G. R. Manzano, and B. A. Green, "Modified open-door cervical expansive laminoplasty for spondylotic myelopathy: operative technique, outcome, and predictors for gait improvement," *Journal of Neurosurgery*, vol. 86, no. 1, pp. 64–68, 1997.

[84] L. C. G. Persson, U. Moritz, L. Brandt, and C. A. Carlsson, "Cervical radiculopathy: pain, muscle weakness and sensory loss in patients with cervical radiculopathy treated with surgery, physiotherapy or cervical collar: a prospective, controlled study," *European Spine Journal*, vol. 6, no. 4, pp. 256–266, 1997.

[85] P. Sampath, M. Bendebba, J. D. Davis, and T. Ducker, "Outcome in patients with cervical radiculopathy prospective, multicenter study with independent clinical review," *Spine*, vol. 24, no. 6, pp. 591–597, 1999.

Hindawi Publishing Corporation
Advances in Orthopedics
Volume 2012, Article ID 794087, 5 pages
doi:10.1155/2012/794087

Review Article

Operative Techniques for Cervical Radiculopathy and Myelopathy

R. G. Kavanagh, J. S. Butler, J. M. O'Byrne, and A. R. Poynton

Department of Orthopaedic Surgery, Cappagh National Orthopaedic Hospital, Finglas, Dublin 11, Ireland

Correspondence should be addressed to R. G. Kavanagh, richkavanagh@rcsi.ie

Received 31 March 2011; Accepted 3 July 2011

Academic Editor: F. Cumhur Öner

Cervical spondylosis is a common problem encountered in modern orthopaedic practice. It is associated with significant patient morbidity related to the consequent radiculopathic and myelopathic symptoms. Operative intervention for this condition is generally indicated if conservative measures fail; however there are some circumstances in which urgent surgical intervention is necessary. Planning any surgical intervention must take into account a number of variables including, but not limited to, the nature, location and extent of the pathology, a history of previous operative interventions, and patient co-morbidities. There are many different surgical options and a multitude of different procedures have been described using both the anterior and posterior approaches to the cervical spine. The use of autograft to achieve cervical fusion is still the gold standard with allograft showing similar results; however fusion techniques are constantly evolving with novel synthetic bone graft substitutes now widely available.

1. Introduction

Cervical spondylosis is a common problem that is increasing in incidence in our aging population. Presentation is usually with neck pain, cervical radiculopathy, cervical myelopathy, or a combination of these.

The pathogenesis of cervical spondylosis is age-related degeneration with loss of disc height and posterior or posterolateral disc herniation. Degenerative changes also result in bulging of the ligamentum flavum which can impinge on the spinal cord posteriorly, osteophyte formation, and ossification of the posterior longitudinal ligament which can compress the spinal cord anteriorly [1].

Cervical radiculopathy has an incidence of 83.2 per 100,000 [2] with a prevalence of 3.5 per 1,000 population [3]. As cervical myelopathy is a rarer condition, there is little reliable epidemiological data.

Radiculopathy is caused by nerve root compression and presents with dermatomal and myotomal dysfunction in the upper limbs with general lower motor neuron signs of weakness, wasting, flaccid paralysis, and hyporeflexia. Specific tests used in the setting of cervical radiculopathy include Spurling's test and manual cervical distraction; both of which may help to distinguish neurological pathology from other causes of a similar clinical picture. Myelopathy can present with a variety of symptoms: general upper motor neuron signs of weakness, spasticity, and hyperreflexia in both upper and lower limbs with Hoffmann's and Babinski's signs in the upper and lower limbs, respectively, as well as bowel and bladder dysfunction, clonus, myelopathic gait, sensory disturbances, and rarely a history of Lhermitte's sign. On examining the patient one may also elicit a positive inverted radial reflex and the finger escape sign.

2. Indications for Surgery

There are no strict guidelines on the indications for surgery in cervical spondylosis. The decision to proceed with surgery is taken after detailed consultation, physical examination, and imaging and is based on a number of variables including the severity of symptoms, duration of symptoms, progression of symptoms, radiological changes, and the patient's fitness for surgery. The failure of conservative management strategies, such as physiotherapy, analgesia, nonsteroidal anti-inflammatory drugs, and epidural injections, is another indication for surgical intervention.

It is generally accepted that in the setting of myelopathy, a shorter duration of symptoms before surgical intervention

is associated with better neurological recovery, and this has been borne out in a number of studies [4, 5]. Indications for urgent surgery include new-onset gait disturbances, bowel/bladder dysfunction, and rapid progression of disease.

3. Planning Surgery

Both the anterior and posterior approaches can be utilised in accessing the cervical spine. The approach is dictated by a number of different variables including the location of pathology and type of procedure to be undertaken, previous surgeries to the area, extent of disease (single or multilevel), preoperative neck pain, the presence of congenital stenosis, sagittal alignment of cervical spine, and patient comobidities [6].

The exact nature and location of the pathology plays an important role in deciding which approach to take to the cervical spine. Posterolateral herniation of the intervertebral discs lends itself to either an anterior or posterior approach [7]; however central posterior herniation is better accessed through the anterior approach with fewer postoperative complications [8]. Whatever approach is taken, it is important to minimise working around the spinal cord so as to minimise the risk of spinal cord injury.

Previous surgery using the anterior approach can make subsequent surgeries more difficult due to the presence of scar tissue which increases the risk of damage to structures in the anterior neck. Contralateral anterior approach is possible, but preoperative laryngoscopy should be performed beforehand to outrule the presence of subclinical vocal cord paralysis due to previous injury to the recurrent laryngeal nerve on that side. Repeated surgeries to the posterior neck increase the risk of postoperative axial pain and paraspinal muscle dysfunction. [9–11].

The extent of the disease and the number of levels to be operated on are other important considerations in the planning of any surgery to the cervical spine. For one- or two-level disease that is accessible from the anterior, it is that approach that is generally favoured by surgeons. Patients with pathology at multiple levels should be considered for posterior approach as studies have shown similar neurological outcomes compared to anterior approaches but decreased operating time and complications in patients undergoing posterior surgery for multilevel pathology [12–15].

The presence of preoperative neck pain is a relative contraindication to posterior approach given the increased incidence and possible worsening of axial neck pain in patients undergoing a posterior approach [12, 16]. Therefore in patients with a significant degree of neck pain preoperatively an anterior approach is indicated if the pathology can be accessed through that approach. Studies have also shown that if a posterior approach is taken the incidence of postoperative axial neck pain is reduced with reduced number of laminoplasty levels [17, 18].

A normal mid sagittal cervical spinal canal diameter is 17-18 mm with congenital cervical canal stenosis defined as an AP diameter of <13 mm. Congenital stenosis increases the risk of developing cervical myelopathy or radiculopathy later in life due to even mild spondylosis and therefore is an important consideration in those presenting for evaluation [19–21]. Patients with developmental canal stenosis are often not suitable for anterior cervical discectomy and fusion (ACDF) due to high rates of postoperative clinical deterioration in this group after ACDF [22]; however laminoplasty has been shown to improve outcomes in patients with cervical spondylosis and concomitant congenital canal stenosis [23].

Sagittal alignment of the cervical spine is another consideration with mounting evidence to suggest that better outcomes are achieved by using the anterior approach compared to the posterior approach in patients with a kyphotic cervical spine [24, 25].

Spinal cord signal changes on preoperative MRI are another factor that affects postoperative outcomes with many studies showing poorer outcomes in patients with preoperative intramedullary hypointense signal changes on T1-weighted MRI [26–28].

4. Operative Techniques

The main procedures that are performed through an anterior approach are anterior cervical discectomy and corpectomy, and those carried out through a posterior approach are laminoplasty, laminectomy, and posterior cervical discectomy.

4.1. Anterior Cervical Discectomy. Anterior cervical discectomy is performed with the patient in the supine position with neck in slight extension. A transverse incision is made in the anterolateral aspect of the neck with dissection through the natural fascial planes of the neck between the carotid sheath laterally and the trachea and oesophagus medially. This allows good access to the cervical intervertebral spaces. Through this approach the surgeon can achieve decompression by discectomy or corpectomy. Additional procedures that can be carried out include removal of ossified posterior longitudinal ligament, osteophyte removal, and foraminotomy. ACDF is the procedure of choice for single-level disc disease and is also commonly performed for two-level disease. Studies have shown that for adjacent two-level disc disease, ACDF is superior to single-level corpectomy in terms of operating time and blood loss, but the two procedures have similar neurological outcomes [29, 30]. Postoperative dysphagia is a common complication after anterior surgery and has been reported to persist at one-year followup in 13–21% of cases and is higher in females and after multilevel surgery [31].

4.2. Corpectomy. Corpectomy is the removal of a central portion of the body of a vertebra. It can be used for the treatment of multilevel disease that is amenable to the anterior approach. It is used as an alternative if multiple discectomies and fusions are required and in cases where a large access area is required to completely decompress the spinal cord [6]. Symptoms due to short segment ossification of the posterior longitudinal ligament can be treated with corpectomy also [32]. Following corpectomy there are a number of options for filling the defect: iliac crest autograft is still the method of choice for one- and two-level corpectomy, but following

multilevel corpectomy the use of a fibular strut allograft or metallic cages are reconstructive options. As for ACDF these can all be supplemented with anterior plating to provide extra stability and increase fusion rates. Newer techniques that have shown promising results include skip corpectomy and combined corpectomy and adjacent level discectomy [33, 34].

4.3. Laminoplasty. A laminoplasty is performed with the patient in the prone position through a posterior midline incision. The paraspinal muscles are stripped from the vertebrae before laminoplasty is performed. A laminoplasty can be performed using a single-door or double-door technique, and this can be supplemented by bone graft or instrumentation to keep the "door" open. For a single-door laminoplasty the junction of the lateral masses and the laminae is divided completely on one side while the other is divided to the anterior cortex; this side is then used as a hinge to rotate the other side open. For a double-door laminoplasty a midline osteotomy through the spinous processes and laminae is performed, and bilateral hinges are created by a similar technique as for the single-door laminoplasty. The laminae are then opened in the midline using the lateral hinges as axes of rotation. As with the single-door laminoplasty the double-door laminoplasty can be supplemented by instrumentation to maintain the decompression. Overall, results of single- and double-door laminoplasty show similar neurological outcomes [35] with canal expansion slightly more in the single-door group [36]; however, there may be certain subsets of patients that would benefit more from one procedure over the other (e.g., patients with myelopathy and bilateral radiculopathy will benefit more from double-door laminoplasty) [36]. Standard laminoplasty is performed from C3–C7; however, some studies suggest that decreasing the number of levels and surgical techniques to preserve the paraspinal musculature will improve postoperative axial pain [17, 37].

4.4. Laminectomy. Laminectomy is an alternative for posterior approaches to the cervical spine. This involves decompression by removal of the spinous processes and laminae at the levels to be decompressed. Laminectomy is often carried out with concomitant fusion to increase the stability of the cervical spine. This can also be supplemented with instrumentation to provide immediate stability and increase fusion rates. Laminectomy has been shown to provide excellent neurological and functional outcomes in multilevel cervical myelopathy [38, 39]; however, compared to laminoplasty it does show increased operating time and increased complications rates [40, 41].

4.5. Posterior Cervical Discectomy. Cervical discectomy is most commonly performed through an anterior approach; however, there are some circumstances where a posterior discectomy is performed. This includes where the anterior approach would be associated with an unacceptable complication risk and where a posterolateral herniated disc is easily accessible by a posterior approach [7]. The advantage of the posterior approach is that potential complications associated with the anterior approach are avoided, and fusion is not necessary so full cervical range of motion is maintained [42]. One disadvantage of this approach is the increased risk of nerve root and spinal cord injury.

5. Fusion Techniques

Fusion is performed with the placement of graft between the fusion surfaces followed by a period of immobilisation to allow the fusion to occur. Bone graft can be autograft, allograft, or synthetic bone graft substitutes. Autograft is still the gold standard with its long established safety and efficacy. Bone is usually harvested from the iliac crest which introduces the risk of complications relating to nerve or arterial injury, hematoma, infection, and chronic pain at the harvest site [43]. Allograft is usually readily available and avoids the morbidity associated with autograft harvest. Recent studies show comparable fusion rates with allograft and autograft [44, 45]. The disadvantages of using allograft include the risk of disease transmission and the increased cost. Fibular strut allografts can be used to reconstruct the defect following multilevel corpectomy. Synthetic bone graft substitutes are relatively new agents that have been used alone and in combination with autograft or allograft. When used alone synthetic graft substitutes avoid the complications of harvesting and disease transmission associated with autograft and allograft. One such agent, recombinant human bone morphogenetic protein-2 (rhBMP-2), has shown promising results in clinical trials [46]; however, there are still some concerns over its safety with a number of studies showing increased complications related to local and systemic inflammatory responses [47, 48] and reports of clinically significant neck swelling leading to acute airway compromise and dysphagia [49]. Synthetic bone graft substitutes are also relatively expensive.

6. Summary

Cervical spondylosis is a common problem encountered by the orthopaedic surgeon. Surgical decompression can be achieved through a multitude of procedures using either an anterior or posterior approach. The type of procedure carried out is dependent on a number of different variables including extent and location of pathology, previous surgery, congenital canal stenosis, and the presence of preoperative axial neck pain. Satisfactory surgical outcome will result in long-term amelioration of cervical radiculopathic and myelopathic symptoms with few postoperative complications.

References

[1] R. D. Rao, B. L. Currier, T. J. Albert et al., "Degenerative cervical spondylosis: clinical syndromes, pathogenesis, and management," *Instructional Course Lectures*, vol. 57, pp. 447–469, 2008.

[2] K. Radhakrishnan, W. J. Litchy, W. M. O'Fallon, and L. T. Kurland, "Epidemiology of cervical radiculopathy: a population-based study from Rochester, Minnesota, 1976 through 1990," *Brain*, vol. 117, no. 2, pp. 325–335, 1994.

[3] G. Salemi, G. Savettieri, F. Meneghini et al., "Prevalence of cervical spondylotic radiculopathy: a door-to-door survey in a Sicilian municipality," *Acta Neurologica Scandinavica*, vol. 93, no. 2-3, pp. 184–188, 1996.

[4] A. Suri, R. P. S. Chabbra, V. S. Mehta, S. Gaikwad, and R. M. Pandey, "Effect of intramedullary signal changes on the surgical outcome of patients with cervical spondylotic myelopathy," *Spine Journal*, vol. 3, no. 1, pp. 33–45, 2003.

[5] J. Tanaka, N. Seki, F. Tokimura, K. Doi, and S. Inoue, "Operative results of canal-expansive laminoplasty for cervical spondylotic myelopathy in elderly patients," *Spine*, vol. 24, no. 22, pp. 2308–2312, 1999.

[6] R. D. Rao, K. Gourab, and K. S. David, "Operative treatment of cervical spondylotic myelopathy," *Journal of Bone and Joint Surgery Series A*, vol. 88, no. 7, pp. 1619–1640, 2006.

[7] F. Aldrich, "Posterolateral microdiscectomy for cerivcal monoradiculopathy caused by posterolateral soft cervical disc sequestration," *Journal of Neurosurgery*, vol. 72, no. 3, pp. 370–377, 1990.

[8] H. N. Herkowitz, L. T. Kurz, and D. P. Overholt, "Surgical management of cervical soft disc herniation: a comparison between the anterior and posterior approach," *Spine*, vol. 15, no. 10, pp. 1026–1030, 1990.

[9] Y. Kotani, K. Abumi, M. Ito et al., "Minimum 2-year outcome of cervical laminoplasty with deep extensor muscle-preserving approach: impact on cervical spine function and quality of life," *European Spine Journal*, vol. 18, no. 5, pp. 663–671, 2009.

[10] J. K. Ratliff and P. R. Cooper, "Cervical laminoplasty: a critical review," *Journal of Neurosurgery*, vol. 98, no. 3, pp. 230–238, 2003.

[11] S.-J. Wang, S.-D. Jiang, L.-S. Jiang, and L.-Y. Dai, "Axial pain after posterior cervical spine surgery: a systematic review," *European Spine Journal*, vol. 20, no. 2, pp. 185–194, 2011.

[12] H. Sakaura, N. Hosono, Y. Mukai, T. Ishii, M. Iwasaki, and H. Yoshikawa, "Long-term outcome of laminoplasty for cervical myelopathy due to disc herniation: a comparative study of laminoplasty and anterior spinal fusion," *Spine*, vol. 30, no. 7, pp. 756–759, 2005.

[13] J. K. Houten, P. R. Cooper, E. C. Benzel, V. K. H. Sonntag, V. C. Traynelis, and U. Batzdorf, "Laminectomy and posterior cervical plating for multilevel cervical spondylotic myelopathy and ossification of the posterior longitudinal ligament: effects on cervical alignment, spinal cord compression, and neurological outcome," *Neurosurgery*, vol. 52, no. 5, pp. 1081–1088, 2003.

[14] C. C. Edwards II, J. G. Heller, and H. Murakami, "Corpectomy versus laminoplasty for multilevel cervical myelopathy: an independent matched-cohort analysis," *Spine*, vol. 27, no. 11, pp. 1168–1175, 2002.

[15] E. Wada, S. Suzuki, A. Kanazawa, T. Matsuoka, S. Miyamoto, and K. Yonenobu, "Subtotal corpectomy versus laminoplasty for multilevel cervical spondylotic myelopathy: a long-term follow-up study over 10 years," *Spine*, vol. 26, no. 13, pp. 1443–1447, 2001.

[16] H. Ohnari, K. Sasai, S. Akagi, H. Iida, S. Takanori, and I. Kato, "Investigation of axial symptoms after cervical laminoplasty, using questionnaire survey," *Spine Journal*, vol. 6, no. 3, pp. 221–227, 2006.

[17] M. Kato, H. Nakamura, S. Konishi et al., "Effect of preserving paraspinal muscles on postoperative axial pain in the selective cervical laminoplasty," *Spine*, vol. 33, no. 14, pp. E455–E459, 2008.

[18] N. Hosono, H. Sakaura, Y. Mukai, and H. Yoshikawa, "The source of axial pain after cervical laminoplasty-C7 is more crucial than deep extensor muscles," *Spine*, vol. 32, no. 26, pp. 2985–2988, 2007.

[19] H. Shigematsu, Y. Ueda, M. Koizumi et al., "Does developmental canal stenosis influence surgical results of bilateral open-door laminoplasty for cervical spondylotic myelopathy? Clinical article," *Journal of Neurosurgery*, vol. 9, no. 4, pp. 358–362, 2008.

[20] T. Sasaki, S. Kadoya, and H. Iizuka, "Roentgenological study of the sagittal diameter of the cervical spinal canal in normal adult Japanese," *Neurologia Medico-Chirurgica*, vol. 38, no. 2, pp. 83–89, 1998.

[21] W. F. Lestini and S. W. Wiesel, "The pathogenesis of cervical spondylosis," *Clinical Orthopaedics and Related Research*, no. 239, pp. 69–93, 1989.

[22] E. Shoda, M. Sumi, O. Kataoka, H. Mukai, and M. Kurosaka, "Developmental and dynamic canal stenosis as radiologic factors affecting surgical results of anterior cervical fusion for myelopathy," *Spine*, vol. 24, no. 14, pp. 1421–1424, 1999.

[23] M. Yoshida, T. Tamaki, M. Kawakami, N. Hayashi, and M. Ando, "Indication and clinical results of laminoplasty for cervical myelopathy caused by disc herniation with developmental canal stenosis," *Spine*, vol. 23, no. 22, pp. 2391–2397, 1998.

[24] K. Uchida, H. Nakajima, R. Sato et al., "Cervical spondylotic myelopathy associated with kyphosis or sagittal sigmoid alignment: outcome after anterior or posterior decompression," *Journal of Neurosurgery*, vol. 11, no. 5, pp. 521–528, 2009.

[25] M. Cabraja, A. Abbushi, D. Koeppen, S. Kroppenstedt, and C. Woiciechowsky, "Comparison between anterior and posterior decompression with instrumentation for cervical spondylotic myelopathy: sagittal alignment and clinical outcome," *Neurosurgical focus*, vol. 28, no. 3, p. E15, 2010.

[26] M. Yagi, K. Ninomiya, M. Kihara, and Y. Horiuchi, "Long-term surgical outcome and risk factors in patients with cervical myelopathy and a change in signal intensity of intramedullary spinal cord on magnetic resonance imaging," *Journal of Neurosurgery*, vol. 12, no. 1, pp. 59–65, 2010.

[27] A. Suri, R. P. S. Chabbra, V. S. Mehta, S. Gaikwad, and R. M. Pandey, "Effect of intramedullary signal changes on the surgical outcome of patients with cervical spondylotic myelopathy," *Spine Journal*, vol. 3, no. 1, pp. 33–45, 2003.

[28] L. Mastronardi, A. Elsawaf, R. Roperto et al., "Prognostic relevance of the postoperative evolution of intramedullary spinal cord changes in signal intensity on magnetic resonance imaging after anterior decompression for cervical spondylotic myelopathy," *Journal of Neurosurgery*, vol. 7, no. 6, pp. 615–622, 2007.

[29] Y. Park, T. Maeda, W. Cho, and K. D. Riew, "Comparison of anterior cervical fusion after two-level discectomy or single-level corpectomy: sagittal alignment, cervical lordosis, graft collapse, and adjacent-level ossification," *Spine Journal*, vol. 10, no. 3, pp. 193–199, 2010.

[30] M. C. Oh, H. Y. Zhang, J. Y. Park, and K. S. Kim, "Two-level anterior cervical discectomy versus one-level corpectomy in cervical spondylotic myelopathy," *Spine*, vol. 34, no. 7, pp. 692–696, 2009.

[31] L. H. Riley III, A. R. Vaccaro, J. R. Dettori, and R. Hashimoto, "Postoperative dysphagia in anterior cervical spine surgery," *Spine*, vol. 35, pp. S76–S85, 2010.

[32] J. Mizuno and H. Nakagawa, "Ossified posterior longitudinal ligament: management strategies and outcomes," *Spine Journal*, vol. 6, supplement, no. 6, pp. S282–S288, 2006.

[33] S. Dalbayrak, M. Yilmaz, and S. Naderi, ""Skip" corpectomy in the treatment of multilevel cervical spondylotic myelopathy

and ossified posterior longitudinal ligament," *Journal of Neurosurgery*, vol. 12, no. 1, pp. 33–38, 2010.

[34] E. Ashkenazi, Y. Smorgick, N. Rand, M. A. Millgram, Y. Mirovsky, and Y. Floman, "Anterior decompression combined with corpectomies and discectomies in the management of multilevel cervical myelopathy: a hybrid decompression and fixation technique," *Journal of Neurosurgery*, vol. 3, no. 3, pp. 205–209, 2005.

[35] W. M. Yue, C. T. Tan, S. B. Tan, S. K. Tan, and B. K. Tay, "Results of cervical laminoplasty and a comparison between single and double trap-door techniques," *Journal of Spinal Disorders*, vol. 13, no. 4, pp. 329–335, 2000.

[36] S. Hirabayashi, H. Yamada, T. Motosuneya et al., "Comparison of enlargement of the spinal canal after cervical laminoplasty: open-door type and double-door type," *European Spine Journal*, vol. 19, no. 10, pp. 1690–1694, 2010.

[37] N. Hosono, H. Sakaura, Y. Mukai, and H. Yoshikawa, "The source of axial pain after cervical laminoplasty-C7 is more crucial than deep extensor muscles," *Spine*, vol. 32, no. 26, pp. 2985–2988, 2007.

[38] L. H. S. Sekhon, "Posterior cervical decompression and fusion for circumferential spondylotic cervical stenosis: review of 50 consecutive cases," *Journal of Clinical Neuroscience*, vol. 13, no. 1, pp. 23–30, 2006.

[39] J. K. Houten, P. R. Cooper, E. C. Benzel, V. K. H. Sonntag, V. C. Traynelis, and U. Batzdorf, "Laminectomy and posterior cervical plating for multilevel cervical spondylotic myelopathy and ossification of the posterior longitudinal ligament: effects on cervical alignment, spinal cord compression, and neurological outcome," *Neurosurgery*, vol. 52, no. 5, pp. 1081–1088, 2003.

[40] S. B. Kaminsky, C. R. Clark, and V. C. Traynelis, "Operative treatment of cervical spondylotic myelopathy and radiculopathy. A comparison of laminectomy and laminoplasty at five year average follow-up," *The Iowa Orthopaedic Journal*, vol. 24, pp. 95–105, 2004.

[41] J. G. Heller, C. C. Edwards II, H. Murakami, and G. E. Rodts, "Laminoplasty versus laminectomy and fusion for multilevel cervical myelopathy: an independent matched cohort analysis," *Spine*, vol. 26, no. 12, pp. 1330–1336, 2001.

[42] P. Kunert, M. Prokopienko, and A. Marchel, "Posterior microlaminoforaminotomy for cervical disc herniation," *Neurologia i Neurochirurgia Polska*, vol. 44, no. 4, pp. 375–384, 2010.

[43] B. L. Fowler, B. E. Dall, and D. E. Rowe, "Complications associated with harvesting autogenous iliac bone graft," *American Journal of Orthopedics*, vol. 24, no. 12, pp. 895–903, 1995.

[44] D. Samartzis, F. H. Shen, D. K. Matthews, S. T. Yoon, E. J. Goldberg, and H. S. An, "Comparison of allograft to autograft in multilevel anterior cervical discectomy and fusion with rigid plate fixation," *Spine Journal*, vol. 3, no. 6, pp. 451–459, 2003.

[45] D. Samartzis, F. H. Shen, E. J. Goldberg, and H. S. An, "Is autograft the gold standard in achieving radiographic fusion in one-level anterior cervical discectomy and fusion with rigid anterior plate fixation?" *Spine*, vol. 30, no. 15, pp. 1756–1761, 2005.

[46] D. S. Mulconrey, K. H. Bridwell, J. Flynn, G. A. Cronen, and P. S. Rose, "Bone Morphogenetic Protein (RhBMP-2) as a substitute for iliac crest bone graft in multilevel adult spinal deformity surgery: minimum two-year evaluation of fusion," *Spine*, vol. 33, no. 20, pp. 2153–2159, 2008.

[47] B. N. Robin, C. D. Chaput, S. Zeitouni, M. D. Rahm, V. A. Zerris, and H. W. Sampson, "Cytokine-mediated inflammatory reaction following posterior cervical decompression and fusion associated with recombinant human bone morphogenetic protein-2: a case study," *Spine*, vol. 35, no. 23, pp. E1350–E1354, 2010.

[48] C. H. Crawford III, L. Y. Carreon, M. D. McGinnis, M. J. Campbell, and S. D. Glassman, "Perioperative complications of recombinant human bone morphogenetic protein-2 on an absorbable collagen sponge versus iliac crest bone graft for posterior cervical arthrodesis," *Spine*, vol. 34, no. 13, pp. 1390–1394, 2009.

[49] L. B. E. Shields, G. H. Raque, S. D. Glassman et al., "Adverse effects associated with high-dose recombinant human bone morphogenetic protein-2 use in anterior cervical spine fusion," *Spine*, vol. 31, no. 5, pp. 542–547, 2006.

Hindawi Publishing Corporation
Advances in Orthopedics
Volume 2012, Article ID 294857, 5 pages
doi:10.1155/2012/294857

Review Article

Nonoperative Modalities to Treat Symptomatic Cervical Spondylosis

Kieran Michael Hirpara,[1] Joseph S. Butler,[1] Roisin T. Dolan,[2] John M. O'Byrne,[1] and Ashley R. Poynton[1]

[1] *Cappagh National Orthopaedic Hospital, Finglas, Dublin 11, Ireland*
[2] *Waterford Regional Hospital, Waterford, Ireland*

Correspondence should be addressed to Kieran Michael Hirpara, kie_hirpara@hotmail.com

Received 28 March 2011; Accepted 8 June 2011

Academic Editor: F. Cumhur Öner

Cervical spondylosis is a common and disabling condition. It is generally felt that the initial management should be nonoperative, and these modalities include physiotherapy, analgesia and selective nerve root injections. Surgery should be reserved for moderate to severe myelopathy patients who have failed a period of conservative treatment and patients whose symptoms are not adequately controlled by nonoperative means. A review of the literature supporting various modalities of conservative management is presented, and it is concluded that although effective, nonoperative treatment is labour intensive, requiring regular review and careful selection of medications and physical therapy on a case by case basis.

1. Introduction

Spondylosis refers to age-related degenerative changes within the spinal column [1], which in the cervical spine may be asymptomatic or can present as pure axial neck pain, cervical radiculopathy, cervical myelopathy, or cervical myeloradiculopathy. Radiological evidence of asymptomatic cervical spondylosis is seen frequently [1, 2], with an incidence of 50% over the age of 40 and 85% over the age of sixty [2, 3]. Unfortunately, neck pain and radiculopathy are relatively common, with about two thirds of the UK population having neck pain at some point in their lives [4, 5], and 34% of responders in a Norwegian survey of 10,000 adults having experienced neck pain in the previous year [6]. Nonsurgical treatment is usually the most appropriate course of initial management [7, 8], with operative intervention being reserved for moderate to severe myelopathy, or cases with unremitting and progressive symptoms that have failed medical treatment [7, 9, 10]. Despite the high incidence of symptomatic cervical degeneration and the widespread use of nonoperative techniques to treat this condition, the number of comparative trials in the literature is small and usually of poor quality [11]. In this paper we attempt to summarise the recommendations of the literature with regards to treating symptomatic cervical spondylosis, including cervical radiculopathy and mild myelopathy.

2. Pathophysiology

2.1. Neck Pain. In the vast majority of patients axial neck pain is related to muscular and ligamentous factors related to injury, poor posture, stress, or chronic muscle fatigue [12]. The cervical discs and facet joint scan are also sources of pain secondary to degenerative disease. The pathway whereby a degenerate disc causes neck pain is disputed, however the nerve supply to the peripheral portion of the intervertebral disc may be responsible for the direct sensation of pain [13, 14]. The sinuvertebral nerve is formed from branches of the ventral nerve root and the sympathetic plexus [14] and supplies nerve endings to the annulus, posterior longitudinal ligament, periosteum of the vertebral body and pedicle, and the adjacent epidural veins. Direct stimulation of each disc by discography produces reliable patterns of pain [15], and

this would suggest that the degeneration of the disc may be responsible for axial neck pain. Provocative injection of the facet joint also produces reliable patterns of axial neck pain and pain in the shoulder girdle [16], indicating that the facet joint may also be responsible for axial neck pain. This is further confirmed when pain is removed by injection of anaesthetic into the facet joint [17] around the dorsal primary rami [18]. Degeneration of the upper cervical joints can cause severe suboccipital pain radiating to the neck or ear, and injection of the atlanto-occipital and atlantoaxial joints results in a reproducible pain pattern in this region [19].

2.2. Cervical Radiculopathy and Myelopathy. Age-related degeneration of the intervertebral disc results in loss of viscoelasticity and a loss of height with associated posterior bulging. As the disc height decreases the ligamentum flavum folds, as does the facet joint capsule, causing a decrease in the dimensions of the canal and exit foramina. Osteophytes form posteriorly around the disc, and these combined with the disc bulge and the aforementioned in folding of ligament and joint capsule cause pressure on the exiting nerve roots or the spinal cord itself.

The underlying mechanism of radicular pain is not clearly understood, but it is generally believed that an inflamed nerve root will produce pain when compressed. This inflammation is most likely a result of neurogenic chemical mediators released from the cell bodies of sensory neurons and nonneurogenic mediators released from the degenerate disc [20, 21]. It may also be that the dorsal root ganglion is the culprit, as it is very sensitive to deformation [22].

Myelopathy is invariably caused by compression of the spinal cord. Animal studies have demonstrated that the spinal cord must be subjected to at least 40% compression to produce reversible neurological deficits [23]. To achieve this compression ratio in patients there would usually be associated factors, such as developmental stenosis (an anteroposterior canal diameter of <13 mm) or instability of a motion segment leading to dynamic compression [24].

3. Treatment

3.1. Medications

3.1.1. Non-Steroidal Anti-Inflammatory Drugs (NSAID's). Despite an absence of clinical trials in the use of NSAIDs in the treatment of cervical spondylosis, their use is widespread. Theoretically in addition to a purely analgesic effect NSAIDs will reduce inflammation around the nerve route decreasing its sensitivity to compression. There is no evidence that NSAIDs are more effective than pure analgesics such as acetaminophen; however their efficacy has been shown in hip and knee arthritis [25, 26], and meta-analysis of the use of NSAID's in acute low back pain demonstrates greater efficacy than placebo [27–29].

3.1.2. Opioid Analgesics. The use of opioid analgesics in spondylotic syndromes has been limited by the possibility of their ineffectiveness in neuropathic pain [30] in addition to the fear of their addictive nature. Despite this, there is evidence that oxycodone can be effective in the treatment of spondylosis [31, 32]. Opioid analgesics are indicated in the management of carefully selected patients with moderate to severe symptoms of axial neck pain with significant underlying structural spondylosis that are refractory to nonopioid agents and nonpharmacological therapies [33].

3.1.3. Muscle Relaxants. The use of muscle relaxants in cervical spondylosis is aimed at relieving any associated spasm of the trapezius and paraspinal muscles, as well improved sleep from sedative effects of these medications. This has been demonstrated using the agent carbobenzaprine in mixed back and neck pain populations [34, 35], though the greatest gains appear to be within the first week of treatment [36]. It should be noted that because of their habit-forming properties the duration of treatment with muscle relaxants should be tapered quickly and last for a maximum of two weeks [33].

3.1.4. Antidepressants. There is little evidence to support the use of antidepressants for the treatment of cervical spondylosis, but there is evidence of a modest improvement in pain severity with minimal functional improvement in low back pain [37, 38].

3.1.5. Anticonvulsants. Gabapentin has been shown to improve pain in the treatment of diabetic neuropathy and has therefore become widely used for the treatment of other sources of neuropathic pain. Again there is no evidence to support its use in cervical radiculopathy, but there is evidence of small improvements in pain scores when used in lumbar radiculopathy [39, 40]. A trial of the anticonvulsant Topiramate found a small improvement in pain score but no improvement in function when used to treat lumbar radiculopathy [41].

3.1.6. Corticosteroids. There is limited evidence to support the use of systemic corticosteroids in the treatment of cervical radiculopathy. If used the general advice is that a 1-2-week course (tapered after 3 days) of steroid such as prednisone should be used only in carefully selected patients refractory to other medication [8]. There is stronger evidence supporting the use of steroids selectively, in the form of cervical epidurals with moderate improvement of symptoms [42, 43], though cervical epidurals are not without risk [44], and a recent randomised blinded study (albeit with small numbers) has demonstrated no effect [45].

3.1.7. Botulinum-A. There is moderate evidence that botulinum-A injections are of no benefit [46].

3.1.8. Physiotherapy. There have been several trials and systematic reviews into the use of a structured physical therapy programme for the treatment of cervical spondylosis and its

sequelae. The overall message or the prospective randomised trials appears to be that surgically treated patients receive greater improvements in pain, muscle strength, and sensory function in the early follow-up period, but at 1 year there is no difference between groups either objectively or in terms of patient satisfaction. This applies to pure axial neck pain, cervical radiculopathy [47, 48], or mild cervical myelopathy [49]. Typically the therapy regime requires 15–20 sessions of between 30- and 45- minute duration over a 3-month period. The treatment should be tailored to individual patients but includes supervised isometric exercises, proprioceptive reeducation, and manual therapy. Thermal therapy provides symptomatic relief only, and ultrasound appears to be ineffective [50].

3.2. Alternative Medicine

3.2.1. Chinese Herbal Medicine. Chinese herbal medicine is a popular method of alternative medical therapy. The literature is sparse regarding the effectiveness of Chinese medicine for any condition, and what little literature does exist is in Chinese and is not easy to search. There is one meta-analysis that investigated the effectiveness of Chinese herbal medicine, finding only 4 studies (two of which were unpublished). This study concluded that there was weak evidence to suggest that Compound Qishe Tablet was superior to placebo and that topical Compound Extractum Nucis Vomicae was more effective than topical diclofenac gel.

3.2.2. Accupuncture. Accupuncture has been shown to be effective for pain relief in the immediate and short term posttreatment period; however there is no medium to long-term benefit in pain control or functional improvement [51–54].

4. Conclusions

Cervical spondylosis is a common and disabling condition. The initial management should be nonoperative for the first 3 months. Surgery should be reserved for moderate to severe myelopathy patients who have failed a period of conservative treatment and patients whose symptoms are not adequately controlled by nonoperative means. Nonoperative treatment is labour intensive, requiring regular review and careful selection of medications and physical therapy on a case by case basis. More invasive treatments such as epidurals may be of benefit in a select group of patients that do not respond to simpler measures.

References

[1] R. D. Rao, B. L. Currier, T. J. Albert et al., "Degenerative cervical spondylosis: clinical syndromes, pathogenesis, and management," *Journal of Bone and Joint Surgery—Series A*, vol. 89, no. 6, pp. 1360–1378, 2007.

[2] I. J. Lehto, M. O. Tertti, M. E. Komu, H. E. K. Paajanen, J. Tuominen, and M. J. Kormano, "Age-related MRI changes at 0.1 T in cervical discs in asymptomatic subjects," *Neuroradiology*, vol. 36, no. 1, pp. 49–53, 1994.

[3] M. Matsumoto, Y. Fujimura, N. Suzuki et al., "MRI of cervical intervertebral discs in asymptomatic subjects," *Journal of Bone and Joint Surgery—Series B*, vol. 80, no. 1, pp. 19–24, 1998.

[4] M. Måkelå, M. Heliovaara, K. Sievers, O. Impivaara, P. Knekt, and A. Aromaa, "Prevalence, determinants, and consequences of chronic neck pain in Finland," *American Journal of Epidemiology*, vol. 134, no. 11, pp. 1356–1367, 1991.

[5] P. Côté, J. D. Cassidy, and L. Carroll, "The Saskatchewan health and back pain survey: the prevalence of neck pain and related disability in Saskatchewan adults," *Spine*, vol. 23, no. 15, pp. 1689–1698, 1998.

[6] M. Urwin, D. Symmons, T. Allison et al., "Estimating the burden of musculoskeletal disorders in the community: the comparative prevalence of symptoms at different anatomical sites, and the relation to social deprivation," *Annals of the Rheumatic Diseases*, vol. 57, no. 11, pp. 649–655, 1998.

[7] W. Dillin, R. Booth, J. Cuckler, R. Balderston, F Simeone, and R. Rothman, "Cervical radiculopathy (review)," *Spine*, vol. 11, pp. 988–991, 1986.

[8] J. S. Saal, J. A. Saal, and E. F. Yurth, "Nonoperative management of herniated cervical intervertebral disc with radiculopathy," *Spine*, vol. 21, no. 16, pp. 1877–1883, 1996.

[9] B. D. Ahlgren and S. R. Garfin, "Cervical radiculopathy," *Orthopedic Clinics of North America*, vol. 27, no. 2, pp. 253–263, 1996.

[10] R. M. Chesnut, J. J. Abitbol, and S. R. Garfin, "Surgical management of cervical radiculopathy: indication, techniques, and results," *Orthopedic Clinics of North America*, vol. 23, no. 3, pp. 461–474, 1992.

[11] E. L. Hurwitz, E. J. Carragee, G. van der Velde et al., "Treatment of neck pain: noninvasive interventions. Results of the bone and joint decade 2000—2010 task force on neck pain and its associated disorders," *Journal of Manipulative and Physiological Therapeutics*, vol. 32, no. 2, pp. S141–S175, 2009.

[12] R. Rao, "Neck pain, cervical radiculopathy, and cervical myelopathy: pathophysiology, natural history, and clinical evaluation," *Journal of Bone and Joint Surgery—Series A*, vol. 84, no. 10, pp. 1872–1881, 2002.

[13] D. C. Ferlic, "The nerve supply of the cervical intervertebral discs in man," *Bulletin of the Johns Hopkins Hospital*, vol. 113, pp. 347–351, 1963.

[14] N. Bogduk, M. Windsor, and A. Inglis, "The innervation of the cervical intervertebral discs," *Spine*, vol. 13, no. 1, pp. 2–8, 1988.

[15] S. A. Grubb and C. K. Kelly, "Cervical discography: clinical implications from 12 years of experience," *Spine*, vol. 25, no. 11, pp. 1382–1389, 2000.

[16] A. Dwyer, C. Aprill, and N. Bogduk, "Cervical zygapophyseal joint pain patterns I: a study in normal volunteers," *Spine*, vol. 15, no. 6, pp. 453–457, 1990.

[17] C. Aprill, A. Dwyer, and N. Bogduk, "Cervical zygapophyseal joint pain patterns II: a clinical evaluation," *Spine*, vol. 15, no. 6, pp. 458–461, 1990.

[18] N. Bogduk and A. Marsland, "The cervical zygapophysial joints as a source of neck pain," *Spine*, vol. 13, no. 6, pp. 610–617, 1988.

[19] P. Dreyfuss, M. Michaelsen, and D. Fletcher, "Atlanto-occipital and lateral atlanto-axial joint pain patterns," *Spine*, vol. 19, no. 10, pp. 1125–1131, 1994.

[20] M. C. Chabot and D. M. Montgomery, "The pathophysiology of axial and radicular neck pain," *Seminars in Spine Surgery*, vol. 7, no. 1, pp. 2–8, 1995.

[21] M. Cornefjord, K. Olmarker, D. B. Farley, J. N. Weinstein, and B. Rydevik, "Neuropeptide changes in compressed spinal nerve roots," *Spine*, vol. 20, no. 6, pp. 670–673, 1995.

[22] B. L. Rydevik, R. R. Myers, and H. C. Powell, "Pressure increase in the dorsal root ganglion following mechanical compression: closed compartment syndrome in nerve roots," *Spine*, vol. 14, no. 6, pp. 574–576, 1989.

[23] S. Hukuda, T. Mochizuki, and M. Ogata, "Operations for cervical spondylotic myelopathy. A comparison of the results of anterior and posterior procedures," *Journal of Bone and Joint Surgery—Series B*, vol. 67, no. 4, pp. 609–615, 1985.

[24] B. Wang, H. Liu, H. Wang, and D. Zhou, "Segmental instability in cervical spondylotic myelopathy with severe disc degeneration," *Spine*, vol. 31, no. 12, pp. 1327–1331, 2006.

[25] T. Pincus, G. G. Koch, T. Sokka et al., "A randomized, double-blind, crossover clinical trial of diclofenac plus misoprostol versus acetaminophen in patients with osteoarthritis of the hip or knee," *Arthritis and Rheumatism*, vol. 44, no. 7, pp. 1587–1598, 2001.

[26] D. T. Felson, "The verdict favors nonsteroidal antiinflammatory drugs for treatment of osteoarthritis and a plea for more evidence on other treatments," *Arthritis and Rheumatism*, vol. 44, no. 7, pp. 1477–1480, 2001.

[27] B. W. Koes, R. J. P. M. Scholten, J. M. A. Mens, and L. M. Bouter, "Efficacy of non-steroidal anti-inflammatory drugs for low back pain: a systematic review of randomised clinical trials," *Annals of the Rheumatic Diseases*, vol. 56, no. 4, pp. 214–223, 1997.

[28] M. W. van Tulder, R. J. P. M. Scholten, B. W. Koes, and R. A. Deyo, "Nonsteroidal anti-inflammatory drugs for low back pain: a systematic review within the framework of the Cochrane Collaboration Back Review Group," *Spine*, vol. 25, no. 19, pp. 2501–2513, 2000.

[29] P. D. D. M. Roelofs, R. A. Deyo, B. W. Koes, R. J. P. M. Scholten, and M. W. van Tulder, "Nonsteroidal anti-inflammatory drugs for low back pain: an updated cochrane review," *Spine*, vol. 33, no. 16, pp. 1766–1774, 2008.

[30] R. K. Portenoy and K. M. Foley, "Chronic use of opioid analgesics in non-malignant pain: report of 38 cases," *Pain*, vol. 25, no. 2, pp. 171–186, 1986.

[31] J. R. Caldwell, M. E. Hale, R. E. Boyd et al., "Treatment of osteoarthritis pain with controlled release oxycodone or fixed combination oxycodone plus acetaminophen added to nonsteroidal antiinflammatory drugs: a double blind, randomized, multicenter, placebo controlled trial," *Journal of Rheumatology*, vol. 26, no. 4, pp. 862–869, 1999.

[32] K. Ma, W. Jiang, Q. Zhou, and D. P. Du, "The efficacy of oxycodone for management of acute pain episodes in chronic neck pain patients," *International Journal of Clinical Practice*, vol. 62, no. 2, pp. 241–247, 2008.

[33] D. Mazanec and A. Reddy, "Medical management of cervical spondylosis," *Neurosurgery*, vol. 60, no. 1, supplement 1, pp. S43–S50, 2007.

[34] P. D. Aker, A. R. Gross, C. H. Goldsmith, and P. Peloso, "Conservative management of mechanical neck pain: systematic overview and meta-analysis," *British Medical Journal*, vol. 313, no. 7068, pp. 1291–1296, 1996.

[35] G. A. Malanga, G. E. Ruoff, A. J. Weil, C. A. Altman, F. Xie, and D. G. Borenstein, "Cyclobenzaprine ER for muscle spasm associated with low back and neck pain: two randomized, double-blind, placebo-controlled studies of identical design," *Current Medical Research and Opinion*, vol. 25, no. 5, pp. 1179–1196, 2009.

[36] R. Browning, J. L. Jackson, and P. G. O'Malley, "Cyclobenzaprine and back pain: a meta-analysis," *Archives of Internal Medicine*, vol. 161, no. 13, pp. 1613–1620, 2001.

[37] J. Hampton Atkinson, M. A. Slater, R. A. Williams et al., "A placebo-controlled randomized clinical trial of nortriptyline for chronic low back pain," *Pain*, vol. 76, no. 3, pp. 287–296, 1998.

[38] S. M. Salerno, R. Browning, and J. L. Jackson, "The effect of antidepressant treatment on chronic back pain: a meta-analysis," *Archives of Internal Medicine*, vol. 162, no. 1, pp. 19–24, 2002.

[39] G. J. McCleane, "Does gabapentin have an analgesic effect on background, movement and referred pain? A randomised, double-blind, placebo controlled study," *Pain Clinic*, vol. 13, no. 2, pp. 103–107, 2001.

[40] K. Yildirim, M. Sisecioglu, S. Karatay et al., "The effectiveness of gabapentin in patients with chronic radiculopathy," *Pain Clinic*, vol. 15, no. 3, pp. 213–218, 2003.

[41] S. Khoromi, A. Patsalides, S. Parada, V. Salehi, J. M. Meegan, and M. B. Max, "Topiramate in chronic lumbar radicular pain," *Journal of Pain*, vol. 6, no. 12, pp. 829–836, 2005.

[42] L. Manchikanti, K. A. Cash, V. Pampati, B. W. Wargo, and Y. Malla, "Cervical epidural injections in chronic-discogenic neck pain without disc herniation or radiculitis: preliminary results of a randomized, double-blind, controlled trial," *Pain Physician*, vol. 13, no. 4, pp. E265–E278, 2010.

[43] R. Benyamin, V. Singh, A. T. Parr, A. Conn, S. Diwan, and S. Abdi, "Systematic review of the effectiveness of cervical epidurals in the management of chronic neck pain," *Pain Physician*, vol. 12, no. 1, pp. 137–157, 2009.

[44] G. Malhotra, A. Abbasi, and M. Rhee, "Complications of transforaminal cervical epidural steroid injections," *Spine*, vol. 34, no. 7, pp. 731–739, 2009.

[45] L. Anderberg, M. Annertz, L. Persson, L. Brandt, and H. Säveland, "Transforaminal steroid injections for the treatment of cervical radiculopathy: a prospective and randomised study," *European Spine Journal*, vol. 16, no. 3, pp. 321–328, 2007.

[46] A. R. Gross, C. Goldsmith, J. L. Hoving et al., "Conservative management of mechanical neck disorders: a systematic review," *Journal of Rheumatology*, vol. 34, no. 5, pp. 1083–1102, 2007.

[47] L. C. G. Persson, C. A. Carlsson, and J. Y. Carlsson, "Long-lasting cervical radicular pain managed with surgery, physiotherapy, or a cervical collar: a prospective, randomized study," *Spine*, vol. 22, no. 7, pp. 751–758, 1997.

[48] L. C. G. Persson, U. Moritz, L. Brandt, and C. A. Carlsson, "Cervical radiculopathy: pain, muscle weakness and sensory loss in patients with cervical radiculopathy treated with surgery, physiotherapy or cervical collar: a prospective, controlled study," *European Spine Journal*, vol. 6, no. 4, pp. 256–266, 1997.

[49] P. G. Matz, "Does nonoperative management play a role in the treatment of cervical spondylotic myelopathy?" *Spine Journal*, vol. 6, no. 6, supplement, pp. S175–S181, 2006.

[50] J. C. Lee, D. T. Lin, and C. Z. Hong, "The effectiveness of simultaneous thermotherapy with ultrasound and electrotherapy with combined AC and DC current on the immediate pain relief of myofascial trigger points," *Journal of Musculoskeletal Pain*, vol. 5, no. 1, pp. 81–90, 1997.

[51] J. P. Petrie and B. L. Hazleman, "A controlled study of acupuncture in neck pain," *British Journal of Rheumatology*, vol. 25, no. 3, pp. 271–275, 1986.

[52] D. Irnich, N. Behrens, H. Molzen et al., "Randomised trial of acupuncture compared with conventional massage and "sham" laser acupuncture for treatment of chronic neck pain," *British Medical Journal*, vol. 322, no. 7302, pp. 1574–1577, 2001.

[53] P. White, G. Lewith, P. Prescott, and J. Conway, "Acupuncture versus placebo for the treatment of chronic mechanical neck pain. A randomized, controlled trial," *Annals of Internal Medicine*, vol. 141, no. 12, pp. 920–928, 2004.

[54] R. M. Coan, G. Wong, and P. L. Coan, "The acupuncture treatment of neck pain: a randomized controlled study," *American Journal of Chinese Medicine*, vol. 9, no. 4, pp. 326–332, 1981.

Hindawi Publishing Corporation
Advances in Orthopedics
Volume 2012, Article ID 908324, 4 pages
doi:10.1155/2012/908324

Review Article

Imaging Modalities for Cervical Spondylotic Stenosis and Myelopathy

C. Green,[1] J. Butler,[1] S. Eustace,[1] A. Poynton,[1,2] and J. M. O'Byrne[1]

[1] *Department of Trauma & Orthopaedic Surgery, Royal College of Surgeons in Ireland, Cappagh National Orthopaedic Hospital, Finglas, Dublin 11, Ireland*
[2] *Mater Misericordiae University Hospital, Eccles Street, Dublin 7, Ireland*

Correspondence should be addressed to C. Green, connorjgreen@gmail.com

Received 29 March 2011; Accepted 19 May 2011

Academic Editor: F. Cumhur Öner

Cervical spondylosis is a spectrum of pathology presenting as neck pain, radiculopathy, and myelopathy or all in combination. Diagnostic imaging is essential to diagnosis and preoperative planning. We discuss the modalities of imaging in common practice. We examine the use of imaging to differentiate among central, subarticular, and lateral stenosis and in the assessment of myelopathy.

1. Introduction

Imaging modalities for cervical spondylosis aim to assist the clinician in differentiating discogenic neck pain, radiculopathy, and myelopathy. Radiological assessment helps to localise the site and level of the disease for preoperative planning when surgical intervention is required. The current modalities in common use are pain film roentgenology, magnetic resonance imaging, and computed tomography.

Despite advances in diagnostic imaging plain film remains an inexpensive initial radiological evaluation of the spine in cervical spondylosis. Anteroposterior, lateral, and oblique radiographs can be acquired easily at the time of consultation. These images can show changes in the facet and uncovertebral, osteophytes, and disc space [1]. This is an indication of the underlying pathology but not diagnostic as these findings are common in the adult population [1]. Weight-bearing plain films can also assess alignment and sagittal canal diameter. Measurement of the anteroposterior diameter is typically determined on a lateral plain film as the distance from the posterior surface of the vertebral body to the closest point on the spinolaminar line at the pedicle level. However, this is a two-dimensional assessment of a three-dimensional structure and such measurements have shown to be inaccurate. Three-dimensional imaging modalities are now used for more accurate assessment. Lateral flexion-extention views are also useful initial investigations [2]. These will help to assess cervical range of motion and identify fused segments and instability. Instability is suggested where translation of >3.5 mm and sagittal plane angulation of >11 degrees are present [3].

Compared with other radiological studies available to evaluate the spine magnetic resonance imaging (MRI) provides the greatest range of information [4]. It provides an accurate morphological assessment of both osseous and soft tissue structures including intervertebral discs, spinal ligaments, and the neural elements. Dynamic weight bearing MRI has recently been championed as the preferred technique for pathology-specific diagnosis [5, 6]. Computed tomography in isolation lacks the soft tissue detail achieved with MRI scanning. However, CT is still a useful modality when there is a contraindication to MRI and where metal artefact is obstructing the anatomy. CT myelography is an invasive procedure and is associated with a number of risks. It is only used for patients who have contraindications, equivocal findings, or failed MR imaging because of metal artefact.

Imaging for spinal stenosis should aim to determine the site of compression. Spinal stenosis can be divided into central, subarticular recess (lateral recess), and lateral

[7]. Central stenosis results in concentric narrowing of the spinal canal and can result in cervical myelopathy. Radicular symptoms can be attributed to either subarticular recess stenosis in lateral aspect of the central spinal canal or lateral stenosis at the foramina. Radiological evaluation of the spinal cervical spine can as such be broadly slit into central and lateral.

2. Central Radiological Assessment: Central Stenosis and Myelopathy

Modalities employed for a central assessment of the cervical spine should determine the extent and site of canal stenosis and any associated myelopathy.

3. Assessment of Sagittal Diameter of the Spinal Canal

The size of the cervical spinal canal is clinically important [4, 8]. The spinal canal is narrowed with central stenosis, and this can lead to cervical myelopathy. The role of the narrow cervical spine in the expression of clinical syndromes was evaluated by Edwards and LaRocca [9]. They predicted that patients with a canal size of <10 mm had myelopathy, those with a canal size of 13 to 17 mm were less prone to myelopathy but were more prone to symptomatic cervical spondylosis, and those with a canal size of greater than 17 mm were asymptomatic [9]. MRI studies which take into account soft tissue structures, weight-bearing, and dynamic imaging have suggested that a congenital sagittal diameter of <13 mm is a significant risk factor for development of stenosis [4]. However, a number of authors have reported an incidence of asymptomatic stenosis of between 16 and 19% [10, 11]. With MRI scanning becoming more routinely available the best management of this group of individuals will be challenging.

There are numerous ways to evaluate the diameter of the spinal canal. Although traditionally determined on a lateral plain film such measurements have shown to be inaccurate. Inaccuracy has also been attributed to variation in the distance from the X-ray source and rotation of the subject [4, 8]. In order to improve accuracy of this measurement on plain film a number of authors have described the use of a ratio between the sagittal diameter of the vertebral body and the diameter of the canal [12, 13]. Pavlov's ratio was considered normal when >1 and stenotic when <0.8. However, some authors have reported a poor correlation between the space available for the cord and the Pavlov ratio [14, 15].

The most accurate measurement of spinal canal diameter is obtained using MRI. Unlike other modalities MRI takes into account both osseous and soft tissue structures when calculating the canal diameter. This is important as central stenosis is often due to a combination of degenerative hypertrophy of the facet joints, osteophytic spurring, ligamentum flavum thickening, ossification of the posterior longitudinal ligament, posterior disc protrusion, and translation of one anatomical segment on the next [7]. The examination should be performed using thin sections and high resolution. Spinal MRI should include imaging sets obtained in the axial and sagittal planes using T1-weighted, proton-density, and T2-weighted techniques. In addition pulse sequences that provide high signal from cerebrospinal fluid (myelographic effect) help delineate epidural pathological processes such as disc fragments and osteophytes [16]. The bony and osteophytic components of the spinal stenosis pattern are seen best using a T2-weighted gradient-echo technique.

4. Myelopathy

As well as the anatomy of spinal cord compression MRI can show the pathological spinal cord changes in cervical spondylotic myelopathy. Signal change not only indicates the presence of myelopathic change but has also been used as a predictor of outcome [17]. Takahashi et al. were the first group to correlate a high signal on T2-weighted MR images with a poor clinical result after both operative and nonoperative management [18]. However, controversy exists in the interpretation of signal changes in the spinal cord. This may explain why although some studies have shown similar results to Takahashi et al. other studies have not [19, 20].

Myelopathy is seen as increased signal within the cord on T2-weighted and a decreased signal on T1-weighted MRI. However, these signal changes are not reciprocal and are likely to represent different underlying pathology [21]. Attempts have been made to correlate MRI and histological findings. Oedema and gliosis have been described as a high-intensity signal change on T2-weighted MRI, and myelomalacia and necrosis as a low-intensity signal change on T1-weighted MRI [22]. This is an important distinction as it suggests that those changes seen with increased intensity on T2 images are reversible whereas those seen a low signal on T1 are irreversible. However, other authors suggest that all increased signals in the spinal cord represent diffuse neuronal cell loss, replacement by glial cells in the stroma, and axonal and spongy degeneration in the white matter indicating advanced spinal cord damage [23]. Radiological classifications systems to quantify changes in signal intensity have been developed in an attempt to identify the radiological divide between reversible and irreversible changes [24]. The simplest of these describes three grades absent, obscure, and bright [25]. But a more detailed classification system that accommodates both T1- and T2-weighted MRI is more predictive of surgical outcome than those that include T2-weighted changes alone [17]. In addition, postoperative MRI has been used to identify late onset of low T1 SI changes in patients with poor neurological recovery [17].

It seems intuitive that multisegmental increased signal change on T2-weighted images would indicate a more severe and extensive pathology and be associated with poor clinical course. However, despite studies showing that multisegemntal disease is associated with a poor functional recovery [26] and more extensive pathology [19] others have shown a mild cervical myelopathy in patients with extensive high signal change [17, 27].

5. Lateral Radiological Assessment: Radiculopathy

Radicular symptoms can be attributed to either subarticular recess stenosis in lateral aspect of the central spinal canal or lateral stenosis at the foramina. Detailed history and examination findings are essential to interpreting the results of these scans. The distribution of radiculopathy should be localised to a nerve root. Imaging should be used to ascertain if compression of that nerve root is occurring. Where impingement is demonstrated and surgery is being considered the exact location of obstruction needs to be identified. Preoperative planning should distinguish between subarticular recess stenosis at the same level as the exiting nerve root and lateral stenosis at the foramina below.

As discussed MRI is the diagnostic standard for evaluation of the cervical spine. However, exaggeration of foraminal stenosis is associated with gradient-echo axial MR imaging scans obtained through the cervical region [28]. Foraminal stenosis has been reported in as high as twenty percent of asymptomatic subjects older than forty years of age [10]. As a result some surgeons carry out a CT myelogram preoperatively. Compressive osteophytes and foraminal stenosis are best identified with use of CT scans [2]. CT myelography has been reported superior to MRI in distinguishing osseous from soft tissue compression of neural structures at the foramina [29, 30]. However, due to the well-documented rick factures associated with cervical myelopathy this examination should be reserved for specific circumstances where MRI will not suffice.

6. Future Techniques

Intraoperative ultrasound has been described to be useful during central corpectomy for compressive cervical myelopathy. It is inexpensive and simple imaging modality. It is helpful in identifying the vertebral artery and the trajectory of approach [31]. However, ossification of the posterior longitudinal ligament limits the use of this technique [31]. Development of advanced MRI techniques such as diffusion tensor imaging has shown promise in intramedullary microarchitectural analysis with improved imaging quality and increased lesion identification when compared to conventional MRI [32]. Metabolic neuroimaging has been described for image acquisition from the spinal cord. Findings on high-resolution 18F-fluorodeoxyglucose positron emission tomography (FDG-PET) have been compared with clinical scores and findings on magnetic resonance imaging in patients undergoing surgery for myelopathy [33]. FDG-PET findings correlated with preoperative scores, postoperative scores, and the rate of postoperative improvement, but they had no correlation with high-intensity intramedullary signal changes on T2-weighted images. The major limitation of this technology is the poor resolution of PET scans. Future technological advancements in PET scanning may facilitate evaluation of early spinal cord damage and provide indications for surgical intervention.

References

[1] D. R. Gore, S. B. Sepic, and G. M. Gardner, "Roentgenographic findings of the cervical spine in asymptomatic people," *Spine*, vol. 11, no. 6, pp. 521–524, 1986.

[2] R. D. Rao, B. L. Currier, T. J. Albert et al., "Degenerative cervical spondylosis: clinical syndromes, pathogenesis, and management," *Journal of Bone and Joint Surgery. American*, vol. 89, no. 6, pp. 1360–1378, 2007.

[3] A. A. White III and M. M. Panjabi, "Update on the evaluation of instability of the lower cervical spine," *Instructional Course Lectures*, vol. 36, pp. 513–520, 1987.

[4] Y. Morishita, M. Naito, H. Hymanson, M. Miyazaki, G. Wu, and J. C. Wang, "The relationship between the cervical spinal canal diameter and the pathological changes in the cervical spine," *European Spine Journal*, vol. 18, no. 6, pp. 877–883, 2009.

[5] T. Harada, Y. Tsuji, Y. Mikami et al., "The clinical usefulness of preoperative dynamic MRI to select decompression levels for cervical spondylotic myelopathy," *Magnetic Resonance Imaging*, vol. 28, no. 6, pp. 820–825, 2010.

[6] A. Ferreiro Perez, M. Garcia Isidro, E. Ayerbe, J. Castedo, and J. R. Jinkins, "Evaluation of intervertebral disc herniation and hypermobile intersegmental instability in symptomatic adult patients undergoing recumbent and upright MRI of the cervical or lumbosacral spines," *European Journal of Radiology*, vol. 62, no. 3, pp. 444–448, 2007.

[7] C. R. Gundry and H. M. Fritts, "Magnetic resonance imaging of the musculoskeletal system: part 8. The spine, section 2," *Clinical Orthopaedics and Related Research*, no. 343, pp. 260–271, 1997.

[8] M. J. Lee, E. H. Cassinelli, and K. D. Riew, "Prevalence of cervical spine stenosis: anatomic study in cadavers," *Journal of Bone and Joint Surgery. American*, vol. 89, no. 2, pp. 376–380, 2007.

[9] W. C. Edwards and H. LaRocca, "The developmental segmental sagittal diameter of the cervical spinal canal in patients with cervical spondylosis," *Spine*, vol. 8, no. 1, pp. 20–27, 1983.

[10] S. D. Boden, P. R. McCowin, D. O. Davis, T. S. Dina, A. S. Mark, and S. Wiesel, "Abnormal magnetic-resonance scans of the cervical spine in asymptomatic subjects. A prospective investigation," *Journal of Bone and Joint Surgery. American*, vol. 72, no. 8, pp. 1178–1184, 1990.

[11] L. M. Teresi, R. B. Lufkin, M. A. Reicher et al., "Asymptomatic degenerative disk disease and spondylosis of the cervical spine: MR imaging," *Radiology*, vol. 164, no. 1, pp. 83–88, 1987.

[12] H. Pavlov, J. S. Torg, B. Robie, and C. Jahre, "Cervical spinal stenosis: determination with vertebral body ratio method," *Radiology*, vol. 164, no. 3, pp. 771–775, 1987.

[13] J. S. Torg, H. Pavlov, and S. E. Genuario, "Neurapraxia of the cervical spinal cord with transient quadriplegia," *Journal of Bone and Joint Surgery. American*, vol. 68, no. 9, pp. 1354–1370, 1986.

[14] H. R. Blackley, L. D. Plank, and P. A. Robertson, "Determining the sagittal dimensions of the canal of the cervical spine," *Journal of Bone and Joint Surgery. British*, vol. 81, no. 1, pp. 110–112, 1999.

[15] S. S. Prasad, M. O'Malley, M. Caplan, I. M. Shackleford, and R. K. Pydisetty, "MRI measurements of the cervical spine and their correlation to Pavlov's ratio," *Spine*, vol. 28, no. 12, pp. 1263–1268, 2003.

[16] E. R. Melhem, R. Itoh, and P. J. M. Folkers, "Cervical spine: three-dimensional fast spin-echo MR imaging—improved

recovery of longitudinal magnetization with driven equilibrium pulse," *Radiology*, vol. 218, no. 1, pp. 283–288, 2001.

[17] A. Avadhani, S. Rajasekaran, and A. P. Shetty, "Comparison of prognostic value of different MRI classifications of signal intensity change in cervical spondylotic myelopathy," *Spine Journal*, vol. 10, no. 6, pp. 475–485, 2010.

[18] M. Takahashi, Y. Sakamoto, M. Miyawaki, and H. Bussaka, "Increased MR signal intensity secondary to chronic cervical cord compression," *Neuroradiology*, vol. 29, no. 6, pp. 550–556, 1987.

[19] E. Wada, K. Yonenobu, S. Suzuki, A. Kanazawa, and T. Ochi, "Can intramedullary signal change on magnetic resonance imaging predict surgical outcome in cervical spondylotic myelopathy?" *Spine*, vol. 24, no. 5, pp. 455–462, 1999.

[20] K. Yone, T. Sakou, M. Yanase, and K. Ijiri, "Preoperative and postoperative magnetic resonance image evaluations of the spinal cord in cervical myelopathy," *Spine*, vol. 17, no. 10, pp. S388–S392, 1992.

[21] J. Bednarik, Z. Kadanka, L. Dusek et al., "Presymptomatic spondylotic cervical cord compression," *Spine*, vol. 29, no. 20, pp. 2260–2269, 2004.

[22] I. Ohshio, A. Hatayama, K. Kaneda, M. Takahara, and K. Nagashima, "Correlation between histopathologic features and magnetic resonance images of spinal cord lesions," *Spine*, vol. 18, no. 9, pp. 1140–1149, 1993.

[23] K. Uchida, H. Nakajima, R. Sato et al., "Multivariate analysis of the neurological outcome of surgery for cervical compressive myelopathy," *Journal of Orthopaedic Science*, vol. 10, no. 6, pp. 564–573, 2005.

[24] T. F. Mehalic, R. T. Pezzuti, B. I. Applebaum, and G. W. Sypert, "Magnetic resonance imaging and cervical spondylotic myelopathy," *Neurosurgery*, vol. 26, no. 2, pp. 217–227, 1990.

[25] M. Nakamura and Y. Fujimura, "Magnetic resonance imaging of the spinal cord in cervical ossification of the posterior longitudinal ligament," *Spine*, vol. 23, no. 1, pp. 38–40, 1998.

[26] J. J. Fernández de Rota, S. Meschian, A. Fernández de Rota, V. Urbano, and M. Baron, "Cervical spondylotic myelopathy due to chronic compression: the role of signal intensity changes in magnetic resonance images," *Journal of Neurosurgery. Spine*, vol. 6, no. 1, pp. 17–22, 2007.

[27] M. Matsumoto, Y. Toyama, M. Ishikawa, K. Chiba, N. Suzuki, and Y. Fujimura, "Increased signal intensity of the spinal cord on magnetic resonance images in cervical compressive myelopathy: does it predict the outcome of conservative treatment?" *Spine*, vol. 25, no. 6, pp. 677–682, 2000.

[28] D. M. Yousem and S. K. Gujar, "Are C1-2 punctures for routine cervical myelography below the standard of care?" *American Journal of Neuroradiology*, vol. 30, no. 7, pp. 1360–1363, 2009.

[29] T. J. Masaryk, M. T. Modic, M. A. Geisinger et al., "Cervical myelopathy: a comparison of magnetic resonance and myelography," *Journal of Computer Assisted Tomography*, vol. 10, no. 2, pp. 184–194, 1986.

[30] R. W. Jahnke and B. L. Hart, "Cervical stenosis, spondylosis, and herniated disc disease," *Radiologic Clinics of North America*, vol. 29, no. 4, pp. 777–791, 1991.

[31] V. Moses, R. T. Daniel, and A. G. Chacko, "The value of intraoperative ultrasound in oblique corpectomy for cervical spondylotic myelopathy and ossified posterior longitudinal ligament," *British Journal of Neurosurgery*, vol. 24, no. 5, pp. 518–525, 2010.

[32] T. Song, W. J. Chen, B. Yang et al., "Diffusion tensor imaging in the cervical spinal cord," *European Spine Journal*, pp. 1–7, 2010.

[33] K. Uchida, S. Kobayashi, T. Yayama et al., "Metabolic neuroimaging of the cervical spinal cord in patients with compressive myelopathy: a high-resolution positron emission tomography study," *Journal of Neurosurgery*, vol. 101, no. 1, pp. 72–79, 2004.