BioMed Research International

Prognostic Assessment and Management of Liver Cirrhosis

Lead Guest Editor: Xingshun Qi
Guest Editors: Ankur Arora, Shanhong Tang, Andrea Mancuso, and Fernando Romeiro

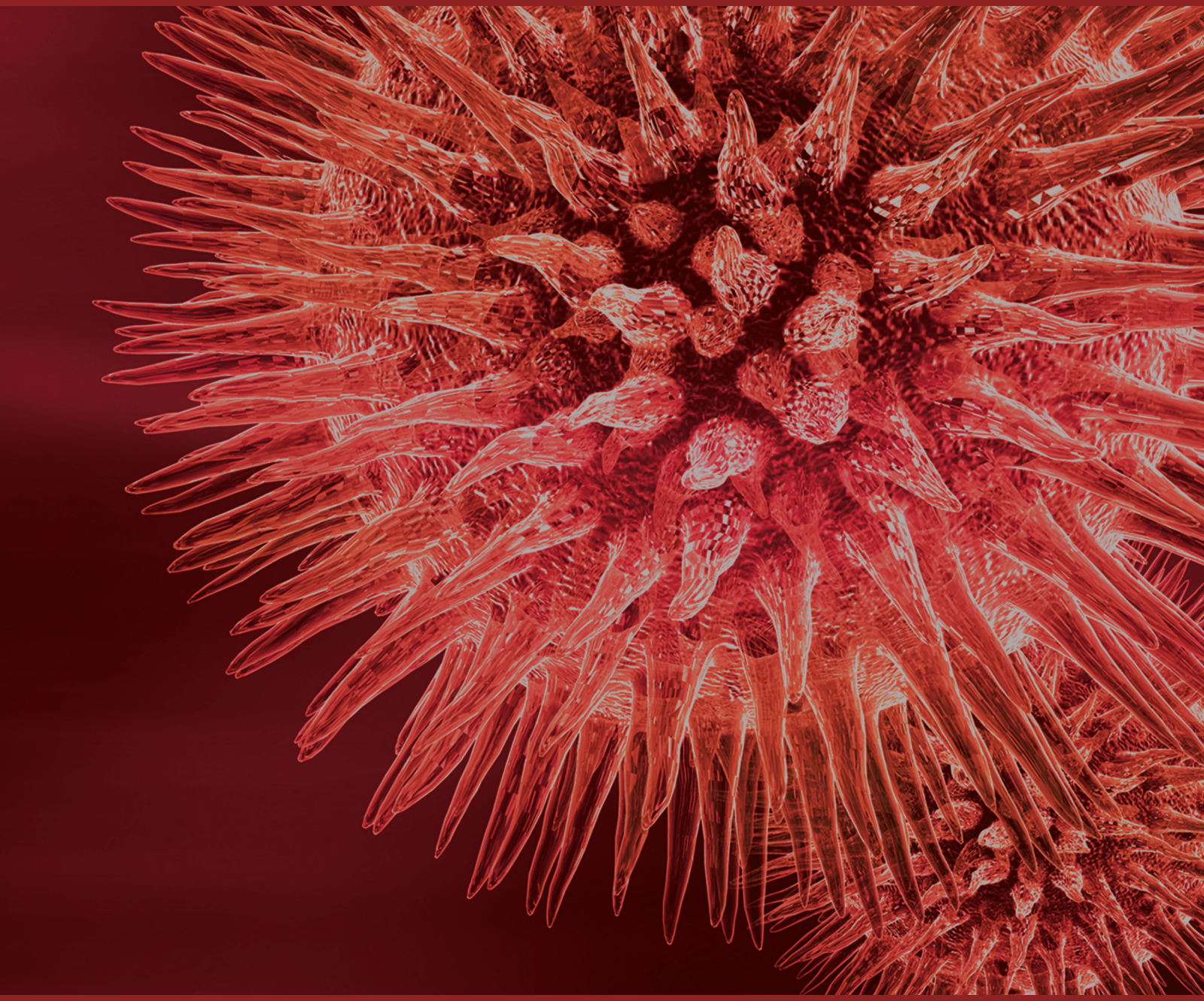

Prognostic Assessment and Management of Liver Cirrhosis

BioMed Research International

Prognostic Assessment and Management of Liver Cirrhosis

Lead Guest Editor: Xingshun Qi
Guest Editors: Andrea Mancuso and Fernando Romeiro

Contents

Hindawi
BioMed Research International
Volume 2017, Article ID 5326898, 3 pages
https://doi.org/10.1155/2017/5326898

Editorial

Prognostic Assessment and Management of Liver Cirrhosis

Xingshun Qi,[1] Ankur Arora,[2] Shanhong Tang,[3] Andrea Mancuso,[4,5] and Fernando Gomes Romeiro[6]

[1] *Department of Gastroenterology, General Hospital of Shenyang Military Area, Shenyang, China*
[2] *Worthing Hospital, Western Sussex NHS Foundation Trust, West Sussex, UK*
[3] *Department of Gastroenterology, General Hospital of Chengdu Military Area, Chengdu, China*
[4] *Medicina Interna 1, ARNAS Civico-Di Cristina-Benfratelli, Piazzale Liotti 4, Palermo, Italy*
[5] *Epatologia e Gastroenterologia, Ospedale Niguarda Ca' Granda, Piazza Ospedale Maggiore 3, 20162 Milano, Italy*
[6] *Faculdade de Medicina de Botucatu, UNESP, Campus de Botucatu, s/n, Botucatu, SP, Brazil*

Correspondence should be addressed to Xingshun Qi; xingshunqi@126.com

Received 5 July 2017; Accepted 6 July 2017; Published 1 August 2017

Liver cirrhosis is the 13th leading cause of death worldwide, with increasing mortality rates in the last decades. Many strategies have been developed to reduce the mortality caused by cirrhosis complications, such as ascites, gastroesophageal variceal bleeding, hepatic encephalopathy, and hepatocellular carcinoma. This special issue aimed to provide a platform to explore the prognostic assessment and management of liver cirrhosis. Finally, 12 articles were published, including 4 review articles and 8 research articles. In this editorial, 5 guest editors briefly introduced them.

The deployment of esophageal stent is a novel treatment option for controlling refractory variceal bleeding. In a systematic review with meta-analysis of 5 studies, X.-D. Shao et al. found that nearly all esophageal stents could be successfully deployed with a high rate of complete response, a low incidence of rebleeding, and no stent-related complications. Notably, few patients died of variceal bleeding after the deployment of esophageal stents. Based on the evidence from this study, esophageal stent may be considered for the management of refractory variceal bleeding.

J. M. Choi et al. reported a review on coronary computed tomography angiography in combination with coronary artery calcium scoring for the preoperative cardiac evaluation of liver transplant recipients, discussing the perioperative cardiovascular complications of liver transplantation as a leading cause of postoperative morbidity and mortality following liver transplantation. In fact, ischemic coronary artery disease and cardiomyopathy, the most common cardiovascular diseases, could be negative predictors of postoperative outcomes after liver transplantation. Therefore, comprehensive cardiovascular evaluations are required to assess perioperative risks and prevent concomitant cardiovascular complications after liver transplantation. Coronary artery calcium score (CACS) and coronary computed tomography angiography (CCTA) are the main types of cardiac computed tomography. CCTA in combination with the CACS is a validated noninvasive alternative to coronary angiography for diagnosing and grading the severity of coronary artery disease. A CACS > 400 is associated with significant coronary artery disease and a known important predictor of posttransplant cardiovascular complications in liver transplant recipients. In the review, the usefulness, advantages, and disadvantages of CCTA combined with CACS as a noninvasive diagnostic tool for preoperative cardiac evaluation are discussed.

L. Lei et al. reviewed the recent knowledge regarding diagnostic criteria, treatment, and prognosis of acute kidney injury. Notably, dynamic changes of serum creatinine are still the main diagnostic criteria for acute kidney injury. Other new markers, including CysC (Cystatin c), KIM-1 (kidney injury molecule 1), and NGAL (neutrophil gelatinase associated lipocalin), also have diagnostic value of acute kidney injury.

The risk of fractures in cirrhotic patients is twofold higher than in other people, contributing to the increased mortality observed in these patients. Different from other cirrhosis complications, cirrhosis-related osteoporosis cannot

be ameliorated by liver transplantation. In fact, it usually worsens after the use of immunosuppressant drugs. These characteristics have gained space as important concerns among health professionals who treat cirrhotic patients. L. A. A. Santos and F. G. Romeiro presented an extensive review about cirrhosis-related osteoporosis, including definitions related to bone conditions, epidemiological data, pathophysiology, diagnosis, and treatment options. Since cirrhosis-related osteoporosis is a multifactorial disease, the authors used figures to group the most relevant causes according to the bone cells involved, making this part of the text more understandable for the nonspecialist reader. They also consulted more than 130 references to make a deep review on cirrhosis-related osteoporosis, depicting important studies about it. One of the main messages in this article is that cirrhosis-related osteoporosis must be considered in all patients with liver cirrhosis in order to avoid fractures and further complications seen in nontreated cases. The article points out that some treatment options have achieved good results, especially when they are combined. Calcium and vitamin D supplementation is discussed in a practical point of view, as well as the other treatment options. Therefore, the article brings relevant information to improve the care of cirrhotic patients regarding their bone health.

The impact of antiviral therapy on hepatitis C virus infection related liver cirrhosis is unclear. In a retrospective analysis of 25 patients with hepatitis C virus infection related liver cirrhosis, G. Zhang et al. found that the rate of sustained virological response was 72% after the treatment of pegylated interferon plus ribavirin and that sustained virological response was significantly associated with a decrease in the liver fibrosis index and an increase in the albumin levels and platelet counts. However, the authors also emphasized the importance of monitoring the occurrence of hepatocellular carcinoma during a long-term follow-up, considering that the incidence of hepatocellular carcinoma was 16%. Taken together, pegylated interferon plus ribavirin may be helpful for the improvement of prognosis of hepatitis C virus infection related liver cirrhosis.

Shunt stenosis and hepatic encephalopathy are two major complications after transjugular intrahepatic portosystemic shunt. F. He et al. analyzed the impact of pathological features on the development of shunt stenosis and hepatic encephalopathy in 361 patients treated with transjugular intrahepatic portosystemic shunt. The authors provided the novel findings that the risk of shunt stenosis and hepatic encephalopathy were associated with the severity of inflammation and fibrosis in the liver tissue, respectively. Additionally, they found a positive correlation between shunt stenosis and development of hepatic encephalopathy.

It has been well recognized that carvedilol significantly decreases the portal pressure and prevent from variceal bleeding in liver cirrhosis. More recently, several studies also suggest the potential antifibrotic effects of carvedilol in rats intoxicated with CCl4, those with ethanol-induced liver injury, and human umbilical vascular endothelial cell model. X. Tian et al. conducted an experimental study to further explore the antifibrotic effects of carvedilol in a bile duct ligation rat model and its potential mechanisms. The authors found that carvedilol could attenuate the progression of liver fibrosis by reducing the accumulation of collagen and inhibiting the activation of hepatic stellate cells. In addition, its benefit can be gradually strengthened with an increased dose of carvedilol.

Hepatic venous portal gradient is the only established exam for diagnosing portal hypertension. However, it is invasive, expensive, and not widely available. Hence, many studies have been looking for noninvasive markers of portal hypertension using lab tests and indices such as platelet count, prothrombin time, and aspartate aminotransferase platelet ratio, but until now these markers were not deemed as reliably predictors of hepatic venous portal gradient. Thus, other surrogate markers have been searched among imaging exams, such as ultrasonography, computed tomography, and magnetic resonance imaging. When restricted to images, these exams still have limited utility for predicting the presence of portal hypertension. For this reason, new techniques have been developed to predict this finding more accurately, such as magnetic resonance elastography. A. M. Gharib et al. analyzed the usage of magnetic resonance elastography as a surrogate marker of hepatic venous portal gradient measurement in patients with liver disease who were enrolled in a clinical trial to receive simtuzumab, an anti-LOXL2 antibody. The authors found interesting correlations between magnetic resonance elastography, hepatic venous portal gradient, and other variables such as aspartate aminotransferase, gamma glutamyl transferase, soluble LOXL2, liver LOXL2 gene expression, platelets count, and liver biopsy findings. Of note, on stepwise multivariate regression analysis, magnetic resonance elastography was the only variable independently associated with hepatic venous portal gradient, showing that in selected patients this measure can be very useful to estimate the portal pressure.

Nonselective beta blockers (NSBB) constitute one of the mainstays of primary as well as secondary prophylaxis of variceal bleeding in liver cirrhosis. Hepatic venous portal gradient assessment, although an invasive procedure, is currently the only validated method available to monitor the effect of pharmacological therapy in portal hypertension. N. McDonald et al. in their initial small feasibility study have endeavoured to use quantitative MRI markers for the assessment of hemodynamic changes following NSBB usage in portal hypertension. Phase-contrast MR angiography, a noninvasive MR based flow-related technique, was employed to acquire hemodynamic data in selected intra-abdominal vessels at baseline and after 4 weeks of NSBB therapy. Whilst a significant reduction in cardiac output (as measured by superior aortic flow) was documented no significant changes were identified in the visceral blood flow or the T1 relaxation time (in liver and spleen). As the authors rightly concluded larger studies would be required for further consolidating their findings and in determining the true value of noninvasive MR techniques in monitoring hemodynamic changes in portal hypertension.

Hepatocellular carcinoma remains one of the dreaded complications of liver cirrhosis and over the years has evolved as the second most lethal cancer globally. Ultrasound surveillance is an integral part of both the AASLD and EASL

guidelines and aims at detecting hepatocellular carcinoma at an early and potentially treatable stage in patient with liver cirrhosis. Early detection and suitable treatment are crucial for improving the disease prognosis, patient survival rates, and their quality of life. But unfortunately early detection of hepatocellular carcinoma may not always be easy because of various reasons including the multifarious appearances the background cirrhotic parenchyma can manifest on ultrasound. M. Soresi et al., following an anecdotal observation of a correlation between coarse nodular pattern of liver parenchyma on ultrasound and evolution into hepatocellular carcinoma, conceived the idea of a longitudinal study investigating the potential risk of hepatocellular carcinoma development in patients with different ultrasound echo patterns. In their prospective study of 359 cirrhotic patients undergoing ultrasound screening the liver echo pattern was assessed and categorized into homogeneous, bright liver, coarse, coarse small nodular pattern, and coarse large nodular pattern. Liver function tests, alpha-fetoprotein assay, and portal hypertension evaluation were other components of the screening program. M. Soresi et al. found alpha-fetoprotein, coarse large nodular pattern, portal hypertension, and age to be independent predictors of hepatocellular carcinoma development. Remarkably, coarse large nodular pattern was found to be a major risk factor for hepatocellular carcinoma wherein 40.7% developed hepatocellular carcinoma. These results are indeed stimulating and could help us diagnose hepatocellular carcinoma early in this subset of patients perhaps by revising the surveillance ultrasound timings. On the contrary, homogeneous and bright liver echo patterns and absence of portal hypertension were not related to development of hepatocellular carcinoma.

Previous studies suggested the potential role of miR-200s (i.e., miR-200a, miR-200b, miR-200c, miR-429, and miR-141) in the development of tissue fibrosis. T. Ma et al. conducted an experimental study to explore the mechanisms of miR-200c in the induction of liver fibrosis. They found that miR-200c activated hepatic stellate cells and then induced liver fibrosis progression via regulating FOG2/PI3K pathway.

M. Liu et al. investigated the role of ERp57 in the development of hepatitis B virus related hepatocellular carcinoma in hepatitis B virus-hepatocellular carcinoma tissues and cell lines, which showed that high expression of ERp57 might lead to poor prognosis in patient with hepatitis B virus related hepatocellular carcinoma. They indicate that ERp57 might be a potential biomarker of these patients. The mechanism and related signal transduction pathways of ERp57 in pathogenesis of hepatitis B virus-hepatocellular carcinoma should be further studied.

Xingshun Qi
Ankur Arora
Shanhong Tang
Andrea Mancuso
Fernando Gomes Romeiro

Hindawi
BioMed Research International
Volume 2017, Article ID 9281450, 8 pages
https://doi.org/10.1155/2017/9281450

Clinical Study

Assessment of Haemodynamic Response to Nonselective Beta-Blockers in Portal Hypertension by Phase-Contrast Magnetic Resonance Angiography

Natasha McDonald,[1] David M. L. Lilburn,[2] Neil J. Lachlan,[3] Gillian Macnaught,[2] Dilip Patel,[4] Arjun N. A. Jayaswal,[5] Peter C. Hayes,[6] Scott I. Semple,[2] and Jonathan A. Fallowfield[1]

[1] *MRC Centre for Inflammation Research, Queen's Medical Research Institute, University of Edinburgh, 47 Little France Crescent, Edinburgh EH16 4TJ, UK*
[2] *BHF Centre for Cardiovascular Science, Queen's Medical Research Institute, University of Edinburgh, 47 Little France Crescent, Edinburgh EH16 4TJ, UK*
[3] *Glasgow Royal Infirmary, 84 Castle Street, Glasgow G4 0SF, UK*
[4] *Department of Radiology, Royal Infirmary of Edinburgh, 51 Little France Crescent, Edinburgh EH16 4SA, UK*
[5] *University of Oxford Centre for Clinical Magnetic Resonance Research (OCMR), Level 0, John Radcliffe Hospital, Oxford OX3 9DU, UK*
[6] *Liver Unit, Royal Infirmary of Edinburgh, 51 Little France Crescent, Edinburgh EH16 4SA, UK*

Correspondence should be addressed to Jonathan A. Fallowfield; jonathan.fallowfield@ed.ac.uk

Received 9 February 2017; Revised 8 April 2017; Accepted 4 May 2017; Published 15 June 2017

Academic Editor: Ankur Arora

A significant unmet need exists for accurate, reproducible, noninvasive diagnostic tools to assess and monitor portal hypertension (PHT). We report the first use of quantitative MRI markers for the haemodynamic assessment of nonselective beta-blockers (NSBB) in PHT. In a randomized parallel feasibility study in 22 adult patients with PHT and a clinical indication for NSBB, we acquired haemodynamic data at baseline and after 4 weeks of NSBB (propranolol or carvedilol) using phase-contrast MR angiography (PC-MRA) in selected intra-abdominal vessels. T1 mapping of liver and spleen was undertaken to assess changes in tissue composition. Target NSBB dose was achieved in 82%. There was a substantial reduction from baseline in mean average flow in the superior abdominal aorta after 4 weeks of NSBB therapy (4.49 ± 0.98 versus 3.82 ± 0.86 L/min, $P = 0.03$) but there were no statistically significant differences in flow in any other vessels, even in patients with >25% decrease in heart rate (47% of patients). Mean percentage change in liver and spleen T1 following NSBB was small and highly variable. In conclusion, PC-MRA was able to detect reduction in cardiac output by NSBB but did not detect significant changes in visceral blood flow or T1. This trial was registered with the ISRCTN registry (ISRCTN98001632).

1. Introduction

Structural changes within the cirrhotic liver, combined with portal and systemic haemodynamic changes, lead to portal hypertension (PHT) which underlies the majority of clinical manifestations and complications of cirrhosis such as varices, ascites, hepatorenal syndrome, and encephalopathy. Currently, hepatic venous pressure gradient (HVPG) measurement is the only validated method of assessing PHT and evaluating the effect of pharmacological interventions. The prognostic value of PHT measurement at different stages in the natural history of cirrhosis is well established, with cut-off values for the development of complications (HVPG > 10 mmHg) and variceal rupture (HVPG > 12 mmHg) [1, 2]. However, HVPG measurement is invasive and expensive and is neither accessible nor used widely outside of specialist centres. A recommendation from the Baveno V Consensus

Workshop on Methodology of Diagnosis and Therapy in PHT was to identify noninvasive tools for measuring PHT, which could have clinical utility for monitoring changes in PHT over time or in response to treatment [3].

A number of approaches have been investigated for the noninvasive assessment of PHT encompassing routine laboratory tests (e.g., platelets to spleen ratio [4]), serum markers of inflammation and fibrosis (e.g., sCD163 and Enhanced Liver Fibrosis test [5]), quantitative assays of liver function (e.g., dual cholate clearance [6], indocyanine green retention [7]), and imaging techniques (e.g., transient elastography [8]) which have all shown varying levels of diagnostic accuracy. Recently, magnetic resonance imaging (MRI) based techniques have shown promise for investigating differential visceral blood flow in the hyperdynamic circulation of patients with cirrhosis [9] and in quantifying PHT. For example, MRI derived hepatic blood flow parameters and azygous flow have been shown to correlate with portal pressure [10] and variceal size [11], respectively. Furthermore, a recent study suggested a predictive model of HVPG based on the combination of MRI acquired splenic artery velocity and liver T1 relaxation time [12]. These MRI measurements can be performed on 1.5-tesla or 3-tesla scanners, potentially without contrast agents, no breath-hold scans, and short scan times, all features which increase the potential for the widespread adoption of the technique across healthcare systems.

Nonselective beta-blockers (NSBB) reduce HVPG and are, therefore, an established treatment in both primary and secondary prophylaxis of variceal bleeding in cirrhosis, either in combination with endoscopic band ligation or as an alternative [13]. It has been repeatedly shown that less than 50% of patients achieve a successful haemodynamic response to propranolol, which is in turn associated with an increased risk of variceal bleeding [14, 15]. Perhaps unsurprisingly, HVPG-guided drug therapy in PHT was recently shown to achieve greater reduction in portal pressure leading to better patient outcomes, including survival [16]. In addition to its well-documented effect on portal pressure, data from animal models also suggests that carvedilol may have an antifibrotic and anti-inflammatory effect in liver parenchyma [17, 18], potentially modifying extracellular matrix composition and influencing liver T1 relaxation time.

We hypothesised that quantitative MRI derived haemodynamic and structural markers, acquired noninvasively in a single scan session, could be used to inform which patients respond to NSSB therapy. Here, we report the findings of an initial small feasibility study.

2. Patients and Methods

2.1. Study Design and Patient Population. This was a single-centre, open-label, parallel study conducted at the Royal Infirmary of Edinburgh from January 2015 to March 2016. The study was conducted in accordance with the ethical principles of the Declaration of Helsinki 2013 and Good Clinical Practice guidelines. It was approved by NHS Lothian Research and Development and the South East Scotland Research Ethics Committee 02 (REC Reference: 14/SS/1050). All patients gave written informed consent.

22 patients requiring prophylaxis of variceal haemorrhage for cirrhotic PHT were randomized 1 : 1, by sealed opaque envelope, to either carvedilol or propranolol treatment. Study inclusion criteria were age 18–80 and presence of liver cirrhosis and PHT where commencement of NSBB was clinically indicated. Study exclusion criteria were contraindication to NSBB therapy (such as moderate to severe asthma) or MRI scan; contraindication to administration of gadolinium-based MRI contrast (including eGFR < 30 mL/min); concomitant use of drugs used to treat PHT; previous TIPSS insertion; portal vein thrombosis; hepatocellular carcinoma; pregnancy or breastfeeding; and inability to obtain informed consent.

2.2. Assessments. Upon enrolment, information on liver disease aetiology, past medical history, medication and alcohol history, and results of the most recent upper gastrointestinal endoscopy were recorded. Patients underwent a physical examination and routine laboratory investigations (full blood count, coagulation screen, and liver and renal function tests), followed by the baseline MRI scan. Liver disease severity was also assessed at baseline according to the Model for End Stage Liver Disease (MELD) score and Child-Pugh score. Starting doses of once-daily NSBB were 6.25 mg for carvedilol and 80 mg for modified release propranolol. Patients' compliance with medication and adverse events monitoring were assessed at an initial follow-up visit after 1 week of NSBB therapy. Provided that NSBB were tolerated clinically and haemodynamically (resting heart rate (HR) ≥ 50 beats per minute (b.p.m), systolic blood pressure (SBP) ≥ 95 mmHg), the dose was escalated to the target once-daily dose of 12.5 mg of carvedilol or 160 mg of propranolol. Further treatment compliance and adverse events monitoring were assessed by weekly telephone consultations. After 4 weeks, whilst on the NSBB, the second MRI was performed. An interval of 4 weeks was chosen as haemodynamic responses to NSBB after chronic use exceed the acute response rate [19]. Consistent with previous landmark NSBB trial in PHT, treatment was targeted at a resting HR reduction of more than 25% from baseline [20]; this was defined as a clinical haemodynamic response to NSBB (HR responders).

2.3. MRI. Patients were fasted for at least 4 hours prior to MRI scans to avoid postprandial changes in splanchnic blood flow. All patients had an estimated glomerular filtration rate of more than 60 mL/min and serum creatinine levels within the normal range. The radiology team (radiographers, radiologists, and MRI physicists) were blinded to the treatment allocation.

MR imaging was obtained at the Edinburgh Imaging Facility at Queen's Medical Research Institute using a 3-tesla Verio MRI system (Siemens Healthcare, GmbH, Erlangen, Germany) with a combination of spine matrix and body matrix coil elements. Firstly, we used electrocardiogram-gated gadolinium (Gd; Gadavist 0.1 mmol/kg) contrast-enhanced MRA sequences to visualise the vessels and rapidly identify the appropriate cross-section view of the vessel of interest. Phase-contrast MR was then planned on the appropriate view in order to determine flow rates within

Table 1: Baseline characteristics of the study population.

Patient characteristic	Treatment group			*P* value (propranolol versus carvedilol)
	Propranolol MR	Carvedilol	All patients	
Number	11	11	22	1.00
Age, years (mean ± SD)	56 ± 7	56 ± 10	56 ± 9	0.99
Male sex, *n* (%)	10 (91)	8 (73)	18 (82)	0.28
Aetiology of liver disease				
Alcoholic liver disease, *n* (%)	5 (45)	3 (27)	8 (36)	0.39
Nonalcoholic fatty liver disease, *n* (%)	3 (27)	4 (36)	7 (32)	0.66
Viral hepatitis, *n* (%)	0 (0)	2 (18)	2 (9.1)	0.15
Other, *n* (%)	3 (27)	2 (18)	5 (23)	0.62
Child-Pugh Score, *n* (%)				
Child-Pugh A	7 (64)	6 (55)	13 (59)	0.67
Child-Pugh B	2 (18)	3 (27)	5 (23)	0.62
Child-Pugh C	2 (18)	2 (18)	4 (18)	1.00
Baseline heart rate, bpm	78 (69–81)	82 (72–94)	79 (69–89)	0.14
Systolic BP, mm Hg	128 (116–146)	136 (115–150)	136 (115–150)	0.99
Splenomegaly, *n* (%)	8 (73)	8 (73)	16 (73)	1.00
Thrombocytopaenia, *n* (%)	9 (82)	10 (91)	19 (86)	0.55
Final beta blocker dose (mg)	160 in 7 patients 80 in 4 patients	12.5 in all	—	
Target beta blocker dose achieved, *n* (%)	7 (64)	11 (100)	18 (82)	**0.03**
Completed study, *n* (%)	9 (82)	10 (91)	19 (86)	0.55
Heart rate responders, *n* (%)	5* (56)	4 (40)	9 (47)	0.50

*Heart rate response in propranolol group was observed in 5 patients; 3 on 80 mg of propranolol MR and 2 on 160 mg of propranolol MR.

that vessel, as previously described [9]. Assessment of flow rates was performed in the following vessels: proper hepatic artery, portal vein, superior mesenteric artery, superior aorta (acquired 2 cm above the coeliac trunk), inferior aorta (acquired 2 cm above the iliac bifurcation), renal arteries, and azygous vein, as previously described [9]. 2-D PC blood flow was analysed by two independent observers experienced in PC-MRA, using Siemens Argus Flow software, as previously described [9].

In addition, we assessed liver and spleen T1 relaxation time mapping using an established protocol [21].

2.4. MRI T1 Analysis. Analysis of the pre-Gd T1 maps of liver and spleen was performed, with the aim of identifying a change in the T1 value between the pre- and posttreatment scans. The images were analysed by a single operator using Liver*MultiScan*™ software (Perspectum Diagnostics, Oxford, UK). T1 values representing the mode of a segmented liver/spleen slice histogram were used for analysis. In addition, 3 regions of interest (ROI) were positioned manually within the liver/spleen T1 maps and the mean values of 3 ROIs were used for further analysis.

2.5. Statistical Analysis. A sample size of 20 patients per group was calculated as sufficient to create a 90% confidence interval on the mean change from baseline that would exclude the zero if a 25% change was observed for that parameter, assuming the observed baseline mean and standard deviation for the study was similar to the historically observed standard deviation [9]. Following problems with patient recruitment and extended study staffing, the target sample size was reduced to 10 patients per group (i.e., total of 20 completed patients), supported by blinded interim analysis on 16 completed patient datasets which indicated that the overall analysis of the reduced patient dataset would still generate meaningful and valuable results.

Statistical analysis was performed using GraphPad Prism version 6.0 (GraphPad Software, USA). Variables were summarised as mean ± standard deviation (SD) if normally distributed and as median with interquartile range (IQR) if not. A comparison of numerical variables between the groups was performed using paired Student's *t*-test when the samples were normally distributed and the Mann–Whitney *U*-test when not. Chi-square test was used to compare categorical data. Association between two continuous variables was assessed using the Pearson and Spearman correlation coefficient, as appropriate. The variability of the liver and splenic T1 data and the interobserver variability were assessed using Bland-Altman plots. A *P* value of less than 0.05 (two-tailed) was considered statistically significant throughout.

3. Results

3.1. Demographic and Clinical Characteristics of Study Participants. 22 patients were recruited during the study period (Table 1). Most were male (82%) with a mean ± SD age of 56 ± 9 years. Commonest aetiologies of liver disease were alcohol

Table 2: Baseline and 4-week post-NSBB blood flow. Data shown as mean ± SD and analysed by paired t-test ($n = 19$).

	Baseline blood flow (L/min)	4-week blood flow (L/min)	P value
Superior aorta	4.49 ± 0.98	3.83 ± 0.86	**0.029**
Inferior aorta	1.45 ± 0.63	1.30 ± 0.53	0.41
Superior mesenteric artery	0.58 ± 0.20	0.56 ± 0.21	0.76
Proper hepatic artery	0.35 ± 0.23	0.33 ± 0.27	0.85
Total renal arterial	0.82 ± 0.34	0.64 ± 0.32	0.079
Portal vein	1.05 ± 0.61	0.83 ± 0.31	0.17
Azygos vein	0.30 ± 0.23	0.25 ± 0.16	0.49

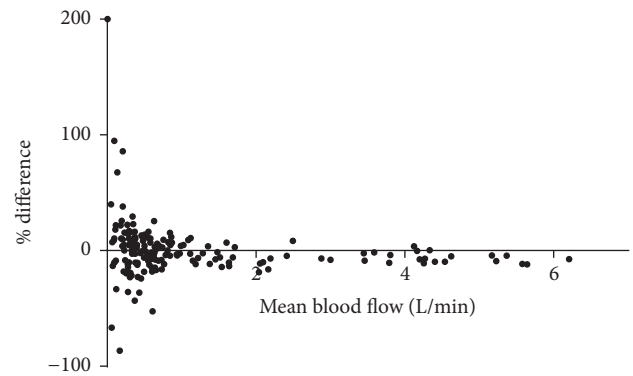

Figure 1: Bland-Altman plot of percentage differences in average blood flow measurements between the two observers against the mean blood flow. The bias between the 2 sets of measurements was small (0.2% or 0.05 L/min; limits of agreement −0.23 to 0.33).

(36%) and nonalcoholic fatty liver disease (32%). The majority of patients (59%) were Child-Pugh class A, and median (IQR) MELD score was 10 (8–15). There were no differences in baseline characteristics between carvedilol and propranolol groups. 19 out of 22 participants had both baseline and repeat MRI scans (1 patient died from complications of cirrhosis during the study; 2 patients were unable to tolerate NSBB, both on propranolol). Target NSBB dose was achieved in 82% overall, but more frequently with carvedilol (100% carvedilol versus 64% propranolol; $P = 0.03$). A greater than 25% reduction in resting HR was achieved in 47% of participants who completed the study (56% in propranolol group and 40% in carvedilol group).

3.2. Quantification of the Regional and Visceral Blood Flow. There was excellent interobserver agreement for average blood flow assessment (Pearson correlation coefficient 1.0, $P < 0.0001$, and Bland-Altman analysis, Figure 1).

There was a substantial reduction from baseline in mean average blood flow in the superior abdominal aorta after 4 weeks of NSBB therapy (4.49 ± 0.98 versus 3.83 ± 0.86 L/min, $P = 0.029$; $n = 19$; Table 2). In all other vessels, there was a downward trend in mean average flow after 4 weeks of NSBB therapy, although the reduction in flow was not statistically significant. In the HR responders, there was a significant reduction in mean average blood flow in the superior and inferior aorta ($n = 9$; Figure 2). There were no appreciable differences in blood flow changes between carvedilol and propranolol treated patients (Figure 3).

3.3. Liver and Spleen T1 Mapping. There was a strong agreement between the 2 methods (histogram and ROI) to estimate liver and spleen T1 values (Spearman's Rho = 0.98 for liver and 0.95 for spleen, $P < 0.001$ for both, $n = 15$). Representative screen shots of the axial T1 relaxation maps are shown in Figure 4. Overall, there was no consistent trend of change in liver or spleen T1 after 4 weeks of NSBB (Figure 5). There was no clear correlation between changes in liver T1 against spleen T1 ($n = 15$) (Figure 5(c)). The range of changes in T1 were similar in absolute values between the liver (1.2–193 ms) and spleen (18.5–99.2 ms). The mean ± SD percentage change in liver and spleen T1 following NSBB was small and highly variable (7.67 ± 6.8 for liver and 3.88 ± 2.6 for spleen).

4. Discussion

This is the first study to use PC-MRA as a noninvasive readout of response in an interventional study of the pharmacological treatment for PHT. Previous research has shown that this technique is reproducible and reliable [9, 11, 22, 23]. Importantly, all patients were able to tolerate the baseline and repeat scans, including patients with ascites. There were no reported adverse reactions to gadolinium contrast in this group of patients with advanced liver disease. We were able to obtain good quality flow measurements in all patients and all vessels as well as interpretable T1 relaxation maps of liver and spleen in 79% of patients who had both baseline and 4-week scans.

We confirmed previous reports that NSBB achieve the target HR response in around 50% of patients (47% overall in our study). The issue of compliance with medication was addressed by weekly monitoring (in person and via telephone) for the duration of the trial and supported by the fact that all 19 patients that completed the study achieved a significant reduction between baseline and 4-week HR (paired t-test $P < 0.0001$).

In this study, PC-MRA was able to detect a significant reduction in cardiac output by NSBB (as measured by superior aortic flow). This is a predictable effect of NSBB and, reassuringly, provides validation of the use of the PC-MRA methodology in this population. However, PC-MRA did not detect statistically significant changes in blood flow in other vessels, such as the expected reduction in portal inflow and splanchnic vasoconstriction. This may simply be a reflection of the small sample size for this study. Additionally,

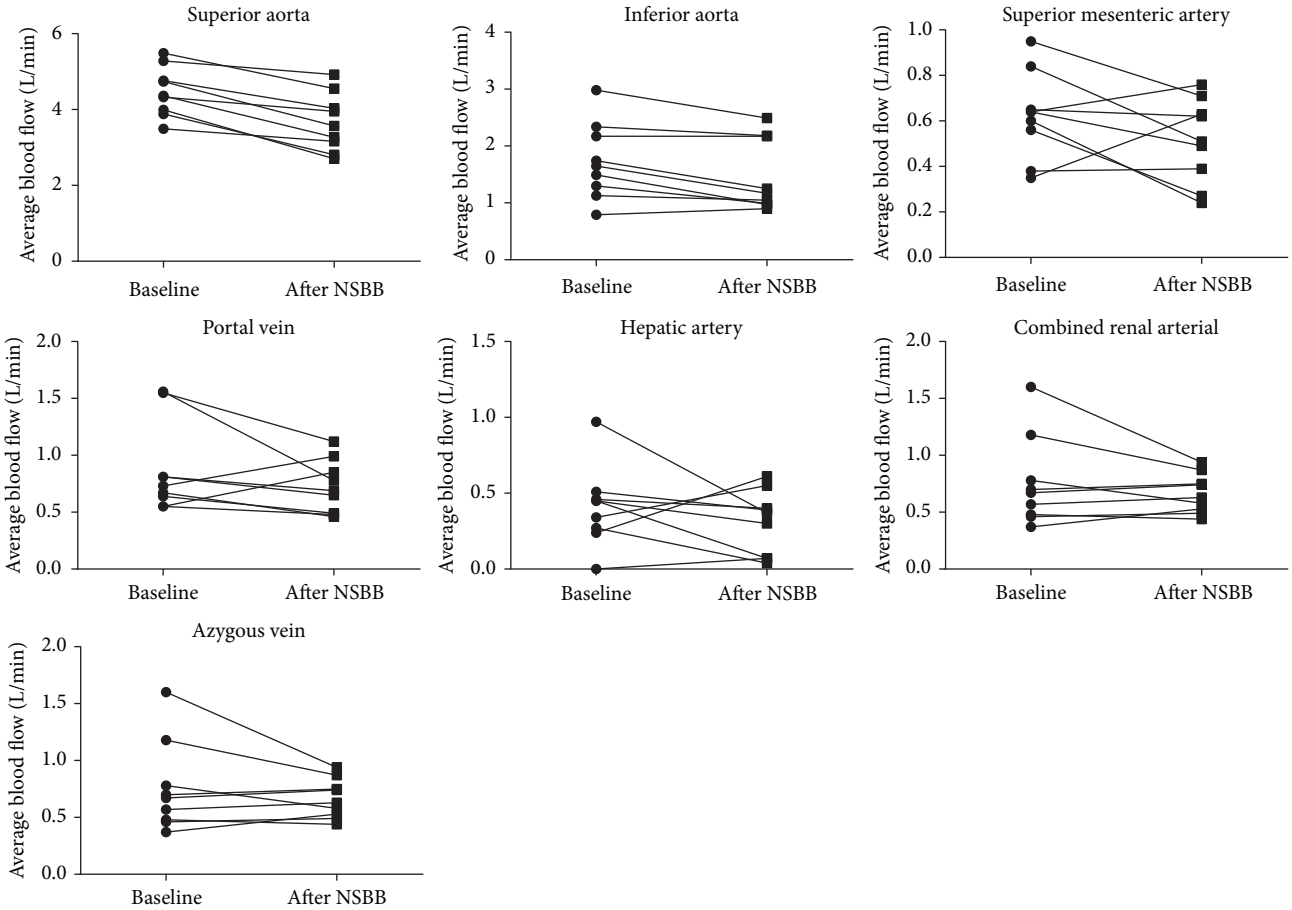

Figure 2: Individual PC-MRA derived blood flow measurements in heart rate responders at baseline and after 4 weeks of NSBB therapy ($n = 9$). There was a significant reduction in the blood flow in superior and inferior aorta after 4 weeks of NSBB therapy ($P < 0.001$ and 0.010, resp.). The changes in flow in all other vessels were not statistically significant. Data analysed by paired t-test.

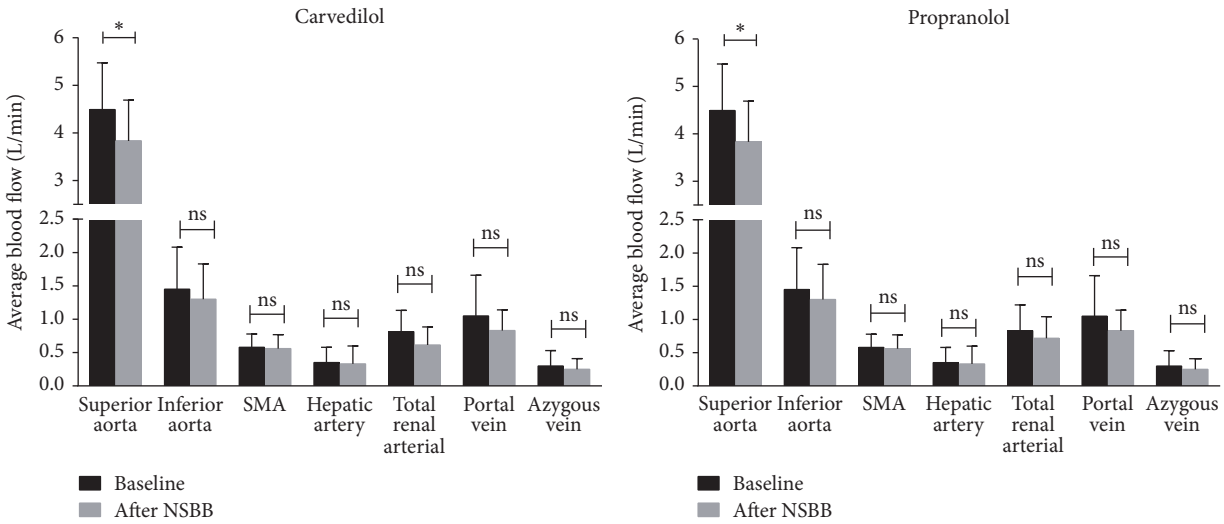

Figure 3: Baseline and 4-week post-NSBB PC-MRA derived blood flow measurements for individual vessels. Data represented as mean ± SD and analysed by paired t-test; $^{*}P < 0.05$, ns: not significant. SMA: superior mesenteric artery.

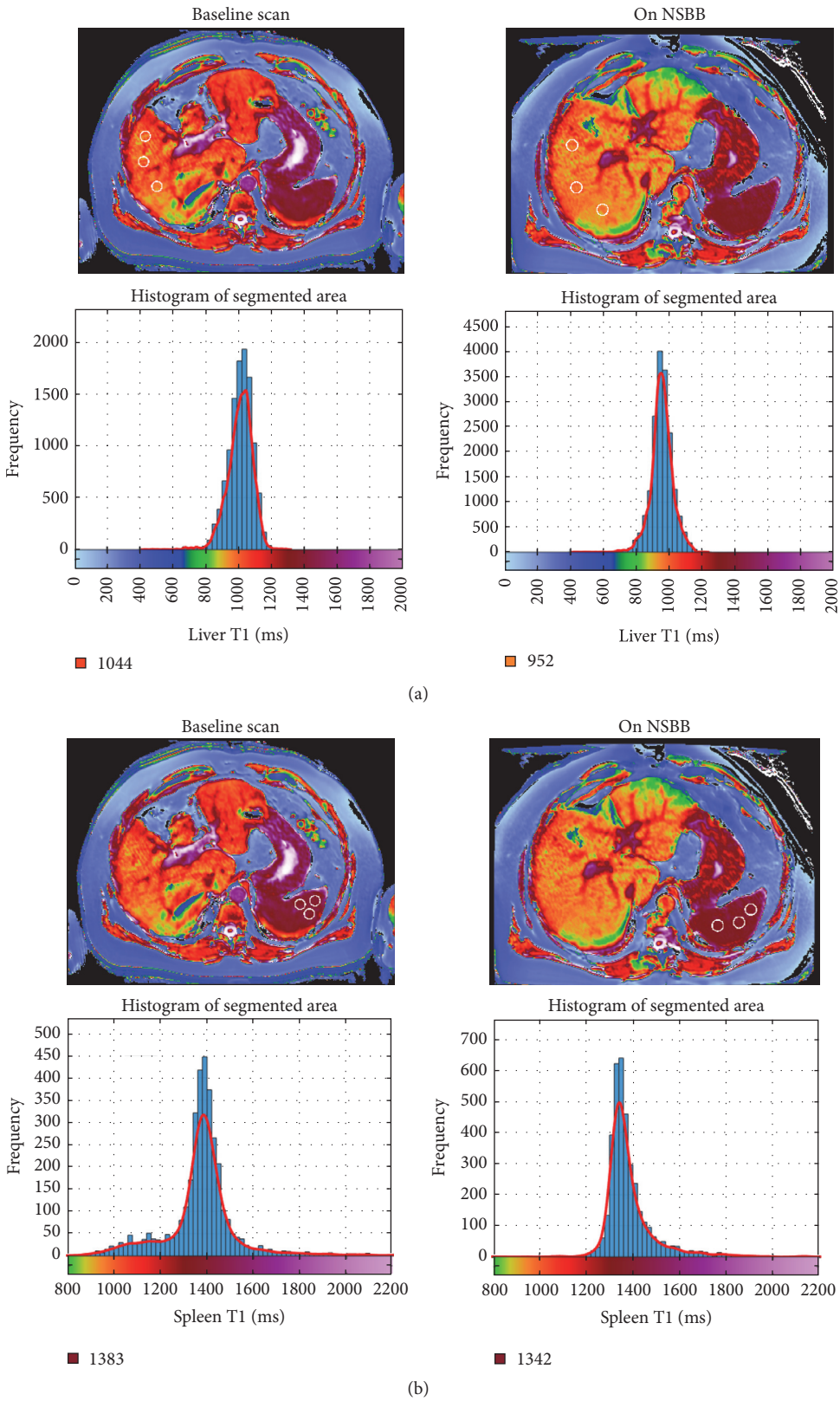

Figure 4: Axial T1 relaxation maps of liver (a) and spleen (b) before and after NSBB therapy. Top row shows representative image of liver (a) and spleen (b) T1 relaxation map from a single patient; position of the 3 ROIs is indicated by white circles. Bottom row shows corresponding segmented liver (a) and spleen (b) histograms and T1 colour scales from the same patient. Numbers below each histogram represent the mode T1.

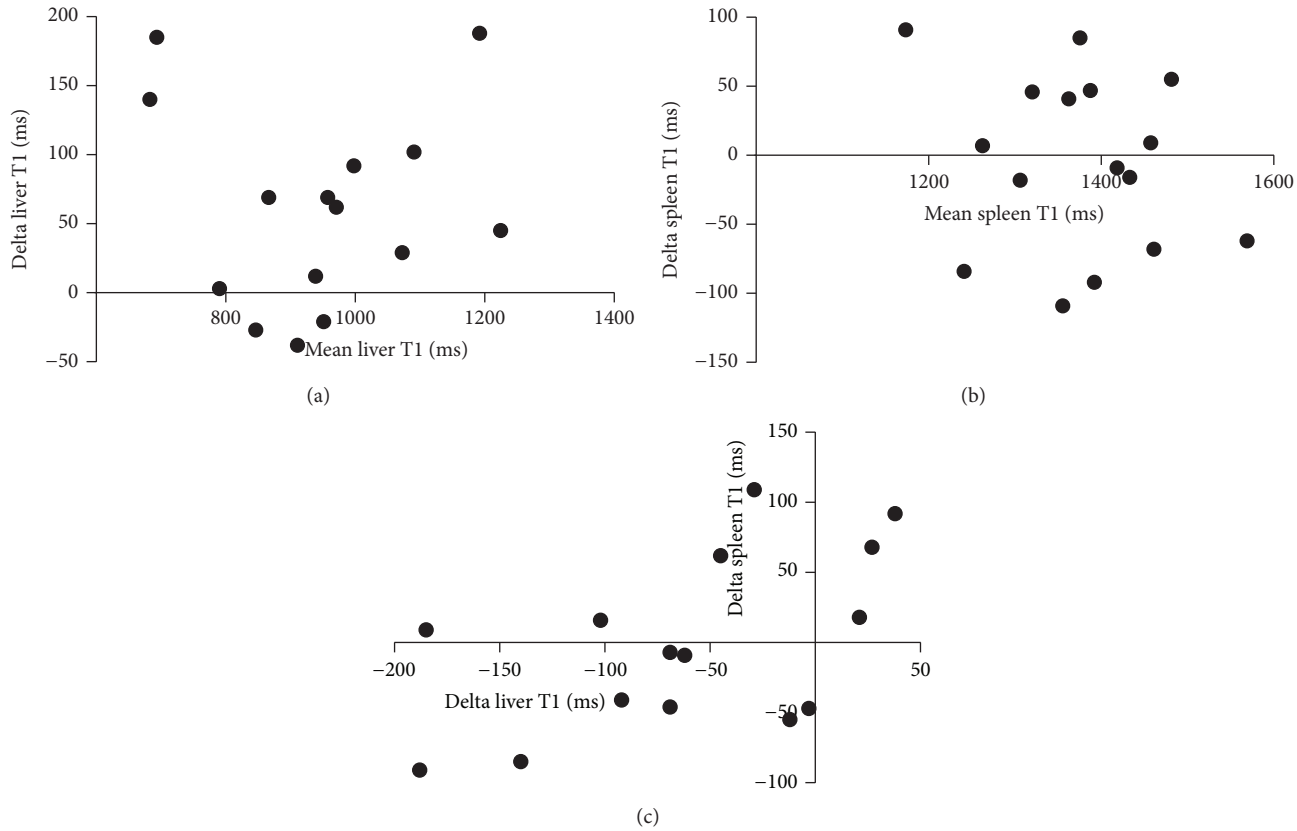

Figure 5: Absolute change in liver (a) and spleen (b) T1 (delta T1) after 4 weeks of NSBB therapy. Correlation of changes in delta T1 between liver and spleen (c). There was no consistent increase or decrease in liver or splenic T1 values as a result of NSBB treatment. In addition, there was no clear correlation found between changes in liver T1 and splenic T1. Bland-Altman analysis.

the HR responders showed a significant reduction in the average flow in the inferior aorta and a nonsignificant trend towards decrease in flow in all other vessels, again suggesting that a larger study may have shown larger and significant haemodynamic effects. Furthermore, it is also possible that the known variable clinical efficacy of NSBB contributed to the interpretation of results, especially since reduction in HR has previously not been found to correlate strongly with the HVPG response [24]. To establish, definitively, whether PC-MRA has sufficient sensitivity to monitor the response to NSBB, a larger study with concurrent HVPG measurements and/or clinical outcomes will be required.

The lack of a significant and consistent change in liver T1 values may be due to the relatively short interval between the 2 scans, thus not allowing sufficient time for remodelling of hepatic extracellular matrix that may occur as a result of proposed antifibrotic and/or anti-inflammatory effect of carvedilol. The absence of concurrent $T2^*$ mapping, which allows an iron correction to be applied to T1 values [21], may also be relevant, although significant intrasubject variation in tissue iron concentration during the 4-week follow-up period seems unlikely. In this study, T1 relaxation mapping was unable to detect reduction in liver and spleen perfusion, expected as a result of haemodynamic effects of NSBB. This could be due to either the lack of significant effect of NSBB on visceral blood flow or the dominant contribution of the liver/spleen fibrosis to the T1 readout and consequent lack of sensitivity of this technique to the changes in blood volume.

5. Conclusions

In this initial feasibility study, PC-MRA was able to detect a robust reduction in cardiac output by NSBB (as measured by superior aortic flow) but did not detect significant changes in visceral blood flow or T1 relaxation time in liver and spleen. A larger study, evaluating NSBB or TIPSS by PC-MRA and contemporaneous HVPG measurement, is now required to determine the true value of noninvasive MRI in this setting.

Conflicts of Interest

Jonathan A. Fallowfield has received consultancy fees from Novartis and Merck and research grant funding from GlaxoSmithKline and Intercept Pharmaceuticals. The other authors have no conflicts of interest to report that are relevant to this publication. Arjun N. A. Jayaswal's Ph.D. Studentship is cosupervised by Perspectum Diagnostics and University of Oxford.

Acknowledgments

This study was funded by the grant from the Chief Scientist Office (Grant no. SCD/20). Jonathan A. Fallowfield

is supported by a NHS Research Scotland Senior Clinical Fellowship. Scott I. Semple is supported by NHS Lothian Research and Development. The authors thank the staff of the Edinburgh Imaging QMRI Facility for their assistance with MR imaging.

References

[1] R. J. Groszmann, G. Garcia-Tsao, J. Bosch et al., "Beta–blockers to prevent gastroesophageal varices in patients with cirrhosis," *New England Journal of Medicine*, vol. 353, no. 21, pp. 2254–2261, 2005.

[2] C. Ripoll, R. Groszmann, G. Garcia-Tsao et al., "Hepatic venous pressure gradient predicts clinical decompensation in patients with compensated cirrhosis," *Gastroenterology*, vol. 133, no. 2, pp. 481–488, 2007.

[3] R. de Franchis and Baveno V. F., "Revising consensus in portal hypertension: report of the Baveno V consensus workshop on methodology of diagnosis and therapy in portal hypertension," *Journal of Hepatology*, vol. 53, no. 4, pp. 762–768, 2010.

[4] E. G. Giannini, A. Zaman, A. Kreil et al., "Platelet count/spleen diameter ratio for the noninvasive diagnosis of esophageal varices: results of a multicenter, prospective, validation study," *American Journal of Gastroenterology*, vol. 101, no. 11, pp. 2511–2519, 2006.

[5] T. D. Sandahl, R. McGrail, H. J. Moller et al., "The macrophage activation marker sCD163 combined with markers of the Enhanced Liver Fibrosis (ELF) score predicts clinically significant portal hypertension in patients with cirrhosis," *Alimentary Pharmacology and Therapeutics*, vol. 43, no. 11, pp. 1222–1231, 2016.

[6] S. Helmke, J. Colmenero, and G. T. Everson, "Noninvasive assessment of liver function," *Current Opinion in Gastroenterology*, vol. 31, no. 3, pp. 199–208, 2015.

[7] M.-L. L. Pind, F. Bendtsen, T. Kallemose, and S. Moller, "Indocyanine green retention test (ICG-r15) as a noninvasive predictor of portal hypertension in patients with different severity of cirrhosis," *European Journal of Gastroenterology and Hepatology*, vol. 28, no. 8, pp. 948–954, 2016.

[8] M. You, K. W. Kim, J. Pyo et al., "A Meta–analysis for the diagnostic performance of transient elastography for clinically significant portal hypertension," *Ultrasound in Medicine & Biology*, vol. 43, no. 1, pp. 59–68, 2017.

[9] N. C. McAvoy, S. Semple, J. M. J. Richards et al., "Differential visceral blood flow in the hyperdynamic circulation of patients with liver cirrhosis," *Alimentary Pharmacology and Therapeutics*, vol. 43, no. 9, pp. 947–954, 2016.

[10] L. Annet, R. Materne, E. Danse, J. Jamart, Y. Horsmans, and B. E. Van Beers, "Hepatic flow parameters measured with MR imaging and Doppler US: correlations with degree of cirrhosis and portal hypertension," *Radiology*, vol. 229, no. 2, pp. 409–414, 2003.

[11] H. Gouya, O. Vignaux, P. Sogni et al., "Chronic liver disease: systemic and splanchnic venous flow mapping with optimized cine phase–contrast MR imaging validated in a phantom model and prospectively evaluated in patients," *Radiology*, vol. 261, no. 1, pp. 144–155, 2011.

[12] N. Palaniyappan, E. Cox, C. Bradley et al., "Non–invasive assessment of portal hypertension using quantitative magnetic resonance imaging," *Journal of Hepatology*, vol. 65, no. 6, pp. 1131–1139, 2016.

[13] G. Garcia-Tsao and J. Bosch, "Management of varices and variceal hemorrhage in cirrhosis," *The New England Journal of Medicine*, vol. 362, no. 9, pp. 823–832, 2010.

[14] P. Sharma, A. Kumar, B. C. Sharma, and S. K. Sarin, "Early identification of haemodynamic response to pharmacotherapy is essential for primary prophylaxis of variceal bleeding in patients with 'high-risk' varices," *Alimentary Pharmacology and Therapeutics*, vol. 30, no. 1, pp. 48–60, 2009.

[15] F. Feu, J. C. Garcia-Pagan, J. Bosch et al., "Relation between portal pressure response to pharmacotherapy and risk of recurrent variceal haemorrhage in patients with cirrhosis," *Lancet*, vol. 346, no. 8982, pp. 1056–1059, 1995.

[16] C. Villanueva, I. Graupera, C. Aracil et al., "A randomized trial to assess whether portal pressure guided therapy to prevent variceal rebleeding improves survival in cirrhosis," *Hepatology*, vol. 65, no. 5, pp. 1693–1707, 2017.

[17] R. F. De Araujo, V. B. Garcia, R. F. De Carvalho Leitao et al., "Carvedilol improves inflammatory response, oxidative stress and fibrosis in the alcohol–induced liver injury in rats by regulating kuppfer cells and hepatic stellate cells," *PLoS ONE*, vol. 11, no. 2, Article ID e0148868, 2016.

[18] N. Hamdy and E. El-Demerdash, "New therapeutic aspect for carvedilol: antifibrotic effects of carvedilol in chronic carbon tetrachloride–induced liver damage," *Toxicology and Applied Pharmacology*, vol. 261, no. 3, pp. 292–299, 2012.

[19] D. Tripathi, G. Therapondos, H. F. Lui, A. J. Stanley, and P. C. Hayes, "Haemodynamic effects of acute and chronic administration of low–dose carvedilol, a vasodilating β-blocker, in patients with cirrhosis and portal hypertension," *Alimentary Pharmacology and Therapeutics*, vol. 16, no. 3, pp. 373–380, 2002.

[20] D. Lebrec, T. Poynard, P. Hillon, and J. P. Benhamou, "Propranolol for prevention of recurrent gastrointestinal bleeding in patients with cirrhosis. a controlled study," *New England Journal of Medicine*, vol. 305, no. 23, pp. 1371–1374, 1981.

[21] R. Banerjee, M. Pavlides, E. M. Tunnicliffe et al., "Multiparametric magnetic resonance for the non–invasive diagnosis of liver disease," *Journal of Hepatology*, vol. 60, no. 1, pp. 69–77, 2014.

[22] M. D. Chouhan, R. P. Mookerjee, A. Bainbridge et al., "Caval subtraction 2d phase–contrast mri to measure total liver and hepatic arterial blood flow: proof–of–principle, correlation with portal hypertension severity and validation in patients with chronic liver disease," *Investigative Radiology*, vol. 52, no. 3, pp. 170–176, 2017.

[23] T. Yzet, R. Bouzerar, J.-D. Allart et al., "Hepatic vascular flow measurements by phase contrast MRI and doppler echography: a comparative and reproducibility study," *Journal of Magnetic Resonance Imaging*, vol. 31, no. 3, pp. 579–588, 2010.

[24] G. Garcia-Tsao, N. D. Grace, R. J. Groszmann et al., "Short–term effects of propranolol on portal venous pressure," *Hepatology*, vol. 6, no. 1, pp. 101–106, 1986.

Hindawi
BioMed Research International
Volume 2017, Article ID 2670658, 8 pages
https://doi.org/10.1155/2017/2670658

Research Article

miR-200c Accelerates Hepatic Stellate Cell-Induced Liver Fibrosis via Targeting the FOG2/PI3K Pathway

Tengfei Ma,[1,2,3] Xiuqin Cai,[1,2,3] Zifeng Wang,[2,3] Li Huang,[4] Chang Wang,[2,3] Songshan Jiang,[5] Yunpeng Hua,[1] and Quentin Liu[2,3]

[1] *Department of Liver Surgery, The First Affiliated Hospital, Sun Yat-sen University, Guangzhou 510080, China*
[2] *Sun Yat-sen University Cancer Center, State Key Laboratory of Oncology in South China, Collaborative Innovation Center of Cancer Medicine, Guangzhou, China*
[3] *Institute of Cancer Stem Cell, Dalian Medical University, Dalian, China*
[4] *Department of Biliary and Pancreatic Surgery, The First Affiliated Hospital, Sun Yat-sen University, Guangzhou 510080, China*
[5] *School of Life Sciences, Sun Yat-sen University, Guangzhou 510080, China*

Correspondence should be addressed to Yunpeng Hua; hyp0427@163.com and Quentin Liu; liuq9@mail.sysu.edu.cn

Received 5 February 2017; Accepted 21 March 2017; Published 13 June 2017

Academic Editor: Goutam Ghosh Choudhury

Background. Although expression of miR-200s is aberrant in liver fibrosis, its role in liver fibrogenesis still remains unknown. Here, we investigated the role of miR-200c in the activation of human hepatic stellate cells (HSCs) and induction of liver fibrosis. *Methods*. We engineered human HSCs (LX2 cell line) to stably express miR-200c (LX2-200c) or empty vector control (LX2-nc). *Results*. miR-200c expression upregulated α-smooth muscle actin (SMA) and vimentin, enhanced HSCs growth and migration, increased expression of collagen type I (a main component of ECM) gene and secretion of epidermal growth factor (EGF), and upregulated the phosphorylation of Akt, a downstream effector of the PI3K pathway. As a target of miR-200s and inhibitor of PI3K pathway, FOG2 protein expression was significantly suppressed in LX2-200c cells. Moreover, LY294002, a highly selective inhibitor of PI3K, blocked phosphorylation of Akt and the effects of miR-200c. *Conclusions*. These data suggest that miR-200c activates HSCs in liver fibrosis possibly by downregulating FOG2 protein expression and upregulating PI3K/Akt signaling. Autocrine activation of EGF signaling may also be a mechanism of miR-200c-mediated HSCs activation. So miR-200c can be a potential marker for HSCs activation and liver fibrosis progression, as well as a potential target to attenuate liver fibrosis.

1. Introduction

Liver fibrosis is a common outcome of chronic hepatic injuries including viral hepatitis, alcoholic or nonalcoholic steatohepatitis, autoimmune and chronic inflammatory conditions, and metabolic disorders. It usually progresses toward cirrhosis and eventually induces liver failure and hepatocellular carcinoma (HCC), which is recognized as a source of increasing morbidity and mortality worldwide. The prevalence of cirrhosis has been estimated at 0.3% in the United States and Western Europe and 1-2% globally. It is the 14th leading cause of mortality globally, 12th leading cause of mortality in the United States, and the 4th leading cause in Central Europe and Mexico [1–3]. However, there are few effective therapies for liver fibrosis because its mechanisms are still complicated and poorly understood.

It is well-known that liver fibrosis is an excessive wound healing response to most forms of chronic liver disease and is characteristic of the excessive deposit of extracellular matrix (ECM) proteins. Hepatic stellate cells (HSCs) are recognized as the main matrix-producing cells in the liver. Following a fibrogenic stimulus, the HSCs change from quiescent vitamin A-storing cells to activated myofibroblast-like cells with ECM increasing dramatically, especially type I collagen. Besides secreting ECM, activated HSCs also produce a number of profibrotic cytokines and growth factors to both maintain and deteriorate the fibrotic process in paracrine and autocrine ways [4–9]. So HSCs may be a good target for prevention and treatment of liver fibrosis.

Table 1: Primer sequences and/or ordering information used for qPCR analyses.

Gene	Sense	Antisense
Collagen type I	5′-GTGCGATGACGTGATCTGTGA-3′	5′-TTGGTCGGTGGGTGACTCTG-3′
GAPDH	5′-GGAGCGAGATCCCTCCAAAAT-3′	5′-GGCTGTTGTCATACTTCTCATGG-3′
Hsa-miR-200c	EXIQON, product number: 204482	
U6	EXIQON, product number: 203907	

MicroRNAs (miRNAs) are endogenous small noncoding RNA sequences of 20–23 nucleotides that control gene expression by degrading target mRNAs or suppressing their translation. Over one-third of human genes appear to be the targets of conserved miRNAs, which are thought to be involved in various biological processes (normal growth and development) and pathological processes (cancer and other diseases). However, evidence is accumulating that miRNAs participate in the progression of liver fibrosis and regulation of HSCs proliferation/apoptosis [10–12]. The miR-200s (miR-200a, miR-200b, miR-200c, miR-429, and miR-141) have recently been implicated in tissue fibrosis [13, 14]. For example, expression of miR-200s was elevated in a mouse unilateral ureteral obstruction (UUO) model and the expression of miR-200a and -200b was increased in a mouse liver fibrosis model and human clinical samples. Feng et al. [15] also found upregulation of miR-200a, 200b, and 200c in fatty liver tissues. Moreover, upregulation of miR-200b stimulated proliferation and migration of HSCs via the PI3K/Akt signaling pathway [16], while upregulation of miR-200a inhibited TGF-β1-induced HSC activation and proliferation [17]. However, few reports have addressed the role of miR-200c in HSC activation and liver fibrosis. Our results in the present study revealed that miR-200c plays a critical role in HSC activation and liver fibrosis progression via targeting FOG2 and activating PI3K/Akt signaling.

2. Material and Methods

2.1. Reagents and Materials. The human hepatic stellate cell line (LX-2) and the human embryonic kidney cell line cells (HEK 293T) were obtained from American Type Culture Collection (ATCC). Dulbecco's modified Eagle's medium (DMEM) was purchased from Invitrogen Life Technologies, Inc. (Carlsbad, CA, USA). Fetal bovine serum (FBS) and Opti-MEM were obtained from GIBCO (Los Angeles, CA, USA). Anti-Akt, anti-phospho-Akt, anti-GAPDH antibodies, and LY 294002 (PI3K inhibitor) were obtained from Cell Signaling Technology Inc. (Danvers, MA, USA). Anti-FOG2 and anti-α-smooth muscle actin (SMA) antibodies were purchased from Abcam (New Territories, Hong Kong). Anti-vimentin antibody was obtained from Millipore (Schwalbach am Taunus, Germany). Lipofectamine 2000 and Trizol were obtained from Invitrogen. Cell Counting Kit-8 (CCK-8) was from Dojindo (Kumamoto, Japan). miExpress™ Precursor miRNA Expression (pEZX-MR03) clone was ordered from GeneCopoeia (Rockville, MD, USA). Universal-RT-microRNA-PCR kits were from EXIQON (Vedbaek, Denmark). SYBR Green qPCR superMix was from Transgen Biotech (Beijing, China).

2.2. Cell Culture and Construction of the HSCs Stably Overexpressing miR-200c. The LX-2 cells and 293T cells were cultured in DMEM supplemented with 10% FBS, 100 U/mL penicillin, and 100 μg/mL streptomycin at 37°C in a humidified atmosphere of 5% CO_2. Briefly, we first generated miR-200c-eGFP lentiviral particles or control scramble lentiviral particles. The 293T cells were cotransfected with 5 μg of either hsa-miR-200c-eGFP carrying plasmid (Catalog No.: HmiR0180-MR03, GeneCopoeia) or 5 μg of pEZX-MR03 (Catalog No.: CmiR0001-MR03, GeneCopoeia) and second generation packaging plasmid (7.5 μg of psPAX2) and envelop plasmid (2.5 μg of pMD2G). The virus-containing supernatant was collected 48 and 72 h after transfection and passed through a 0.5 μm sterile filter. Then, 2×10^4 LX2 cells were infected in a 35 mm dish by 1 ml of miR-200c-expressing or scramble lentiviruses containing 1 μl of polybrene (8 mg/ml). Three days after transduction, the cells were trypsinized and replated in 60-mm dishes. Puromycin (2 μg/ml) was added 3 days after transfection to select and purify the miR-200c-expressing or scramble clones.

2.3. Real Time qPCR. RNA was extracted using Trizol (Invitrogen) according to the manufacturer's instructions. cDNA was synthesized from 2 μg of total RNA using a high-capacity cDNA Reverse Transcription Kit (Invitrogen) for mRNA and Universal cDNA synthesis kit II (EXIQON) for miRNA, respectively. Oligo dT primers were used for reverse transcription of mRNA, whereas stem-loop RT primers were employed for reverse transcription of miRNA. Real time quantitative PCR (qPCR) for miRNA expression analysis was performed on a LightCycler 480 Instrument II (Roche Life Sciences, Penzberg, Germany) using the Universal-RT-microRNA-PCR Kit (EXIQON). qPCR for mRNA expression analysis was performed on an Bio-Rad CFX96 Real Time PCR System (Bio-Rad, Pleasanton, CA, USA) using the SYBR Green method (Invitrogen). GAPDH served as the control for mRNA analyses, and U6 snRNA served as the control for miRNA analyses. Primer sequences and/or ordering information used for qPCR analyses are displayed in Table 1. The relative expression levels of miRNAs and mRNAs were calculated by the 2-ddCt method.

2.4. Western Blot Analysis. Protein extraction and immunoblot analysis were performed as described previously [18]. Briefly, cells were washed three times with ice-cold PBS and lysed in radioimmunoprecipitation assay (RIPA) lysis buffer (0.01 mol/L sodium phosphate, pH7.2, 150 mmol/L NaCl, 2 mmol/L EDTA, 1% NP-40, 1% sodium deoxycholate, 0.1% SDS, 2 mmol/L AEBSF, 130 mmol/L bestatin, 14 mmol/L E-64, 0.3 mmol/L aprotinin, and 1 mmol/L leupeptin). Total cell

lysates were resolved on denaturing and reducing 10–12% SDS-PAGE, and the proteins were transferred from the gel onto Immobilon-P membranes. The membrane was blocked with 5% bovine serum albumin (BSA) in PBS, incubated with different antibodies, incubated with horseradish peroxidase-(HRP-) conjugated secondary antibody, and treated with clarity enhanced chemiluminescence (ECL) substrate (Millipore) to visualize the protein bands.

2.5. Proliferative Analysis. LX2-200c and LX2-nc cells were seeded at 1×10^3 cells/well in 96-well plates, respectively, with or without treatment of LY294002, cultured for 0, 1, 2, 3, 4, and 5 days, incubated with 10 μL of CCK-8 plus 100 μL of DMEM/well for 2 h, and then placed in a microplate reader (BioTek Synergy2, Winooski, VT, USA) to measure the absorbance at 450 nm.

2.6. Wound Healing Assay. LX2-200c and LX2-nc cells were seeded at 5×10^4 cells/well in 6-well plates, respectively, with or without treatment of LY294002. When cells were grown to 80% confluence, a wound track was scraped using a sterile 200-μl pipette tip to create a denuded zone of constant width in the middle of each well. Then, each well was washed with PBS twice to remove the detached cells. Cell migration to the wounded region was observed under a microscope. Images were captured at 0, 12, and 24 h to monitor the wound healing process. Migration ratio (%) was calculated by dividing the width of the denuded zone at 12 h or 24 h by its width at 0 h.

2.7. ELISA. The conditioned medium was collected. Briefly, LX2-200c and LX2-nc cells were seeded at 5×10^4 cells/well in 6-well plates, respectively, grown to 80% confluence, and washed with sterile PBS three times. The growth medium was replaced with an equal volume of serum-free DMEM and, after 24 h, the supernatant was centrifuged to remove cells and particulates, collected, and stored at −80°C.

Human EGF protein levels were quantified by ELISA using the colorimetric sandwich ELISA kit (Proteintech, Chicago, ILUSA) according to the instruction manual. Briefly, samples and standards were diluted with PT 1-ec diluent in wells precoated with a monoclonal anti-human EGF antibody and treated with 1% BSA in PBS for 1 h to block nonspecific binding. The plates were incubated for 2 h at room temperature to allow capture of the EGF-tagged protein by the bound antibody, extensively washed with buffer, incubated with a biotinylated polyclonal antibody to EGF for 1 h at 37°C in a humidified environment, washed with buffer, incubated with Streptavidin-HRP for 40 min, washed, incubated with TMB (tetramethylbenzidine) substrate for 10 min, and incubated with stop solution to terminate the color reaction. Absorbance was measured at 450 nm.

2.8. Statistical Analysis. Each experiment was performed in at least triplicate. Results are expressed as the mean ± standard deviation. Data were analyzed using GraphPad Prism (GraphPad Software Inc., La Jolla, CA). Statistical analysis was performed using the Student t-test. $P < 0.05$ was considered statistically significant.

3. Results

3.1. miR-200c Promotes the Activity, Proliferation, and Migration of HSCs. First, we constructed two cell lines from the human HSC line (LX2): one stably overexpressed miR-200c (LX2-200c) and its control that expressed empty vector (LX2-nc) ($P = 0.013$, Figures 1(a) and 1(b)). We found that LX2-200c had markedly higher levels of α-SMA and vimentin (classical activation markers of HSCs [19]; Figure 1(c)) and significantly higher cell growth rate (all $P < 0.05$; Figure 1(d), and Table 1). The wound healing assay showed that more LX2-200c cells than LX-2-nc cells migrated into the wound track after 12 h and 24 h. The wound track area after 12 h and 24 h was markedly smaller for LX2-200c than for LX2-nc (50.7% ± 3.1% and 23.7% ± 2.5%, respectively, versus 76.0% ± 3.0% and 50.3% ± 2.5%, respectively; all $P < 0.001$; Figures 1(e) and 1(f)).

3.2. miR-200c Activates the PI3K/Akt Pathway via Suppressing Expression of FOG2. Because activation of the PI3K/Akt pathway is required for HSC proliferation and migration [20], we further probed whether the proliferative and migratory effects of miR-200c are dependent on the activation of PI3K/Akt. Our results showed that the level of phosphorylation at Akt residue S473 was significantly higher in LX2-200c cells than LX2-nc cells (Figure 2(a)). We also observed that 25 μM LY-294002 (a PI3K inhibitor) significantly inhibited the expression of phospho-Akt in LX2-200c cells in a time-dependent manner (Figure 2(b)) and blocked the proliferation and migration of LX2-200c cells (Figures 2(c) and 2(d)). Moreover, the wound area for LX2-200c cells after 12 h and 24 h was significantly larger with LY-294002 treatment than without treatment (79% ± 3.0% and 57.7% ± 3.5%, respectively, versus 57.7% ± 3.2% and 19.3% ± 3.1%, respectively; all $P < 0.001$; Figures 2(d) and 2(e)).

To further probe the mechanism of miR-200c-mediated PI3K signaling, we measured the expression of FOG2 (a reported inhibitor of PI3K [16, 21–23]) and PI3K after miR-200c transfection and found that LX2-200c cells had significantly decreased levels of FOG2 while no significant change was observed in PI3K expression (Figure 2(f)), which is consistent with our previous finding of increased Akt phosphorylation.

3.3. miR-200c Overexpression Upregulates the Expression of Collagen Type I and Epidermal Growth Factor (EGF) via the FOG2/PI3K/Akt Pathway. Collagen type I is the main component of the ECM and dramatically increases in liver fibrosis [20]. We found that miR-200c overexpression significantly upregulated the gene expression of collagen type I in HSCs (Figure 3(a)). To assess whether PI3K/Akt signaling is involved in miR-200c-mediated collagen type I gene expression, we treated LX2-200c cells with 25 μM LY294002 in the presence of 10% serum for 30 min and detected a marked drop in their collagen type I mRNA levels (Figure 3(b)).

Epidermal growth factor (EGF) plays a role in liver fibrosis through promoting the autocrine/paracrine proliferation and activation of HSCs [24–26]. Assessment of EGF protein level in the conditioned medium of HSCs revealed

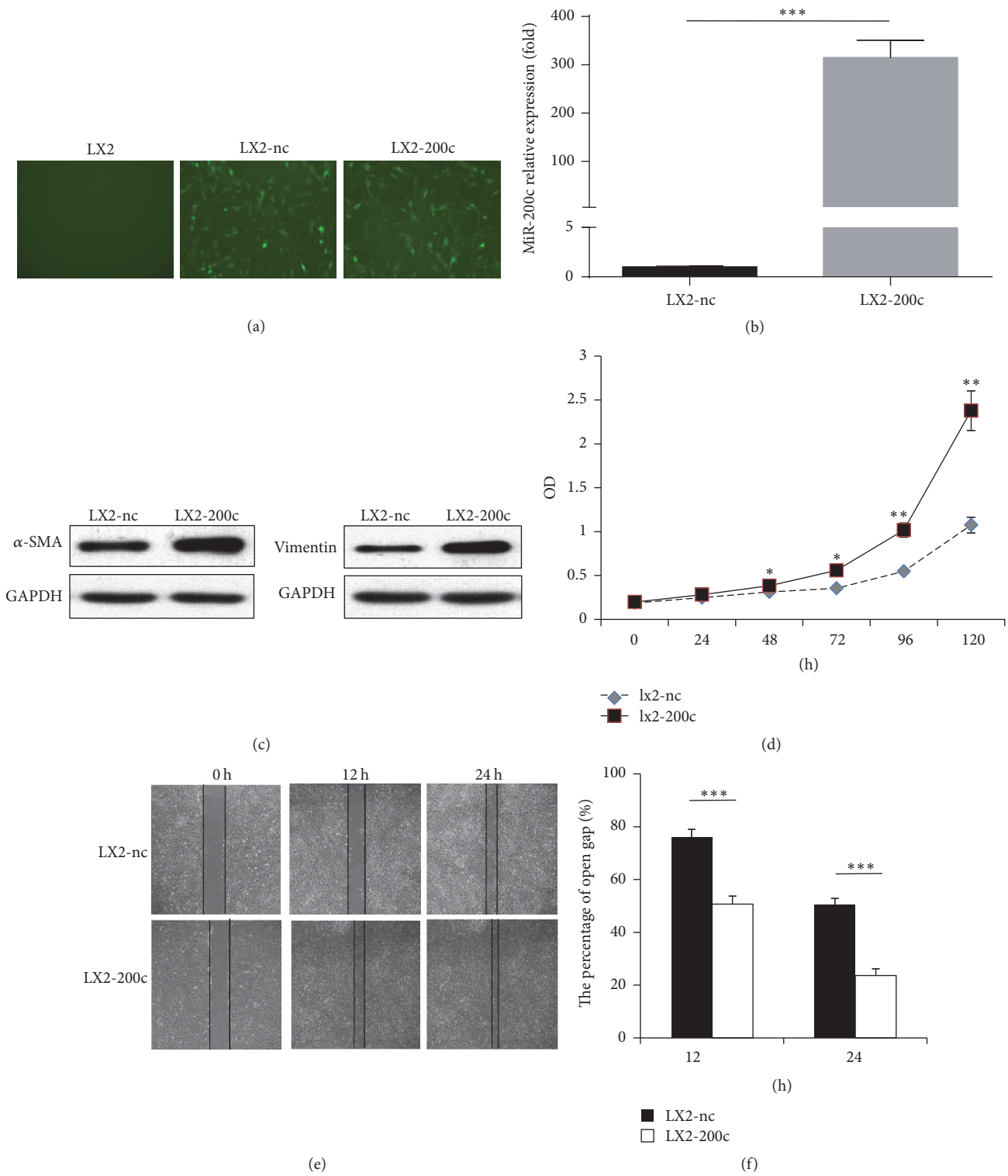

Figure 1: miR-200c promotes the activity, proliferation, and migration of HSCs. (a, b) Construction of two cell lines (LX2-200c and LX2-nc) from the human HSC line (LX2). LX2-200c stably overexpressed miR-200c and LX2-nc expressed empty vector as the control. Green fluorescent protein (GFP) expression was observed in LX2-200c and LX2-nc by fluorescence microscopy, rather than in LX2 (original magnification ×400). The level of miR-200c expression in LX2-200c was approximately 314 times of that in LX2-nc cells. (c) LX2-200c had markedly higher levels of α-SMA and vimentin. (d) miR-200c promoted the proliferation of LX2. (e, f) The migration of LX2 was increased by miR-200c. $*$ means $p < 0.05$, $**$ means $p < 0.01$, and $***$ means $p < 0.001$.

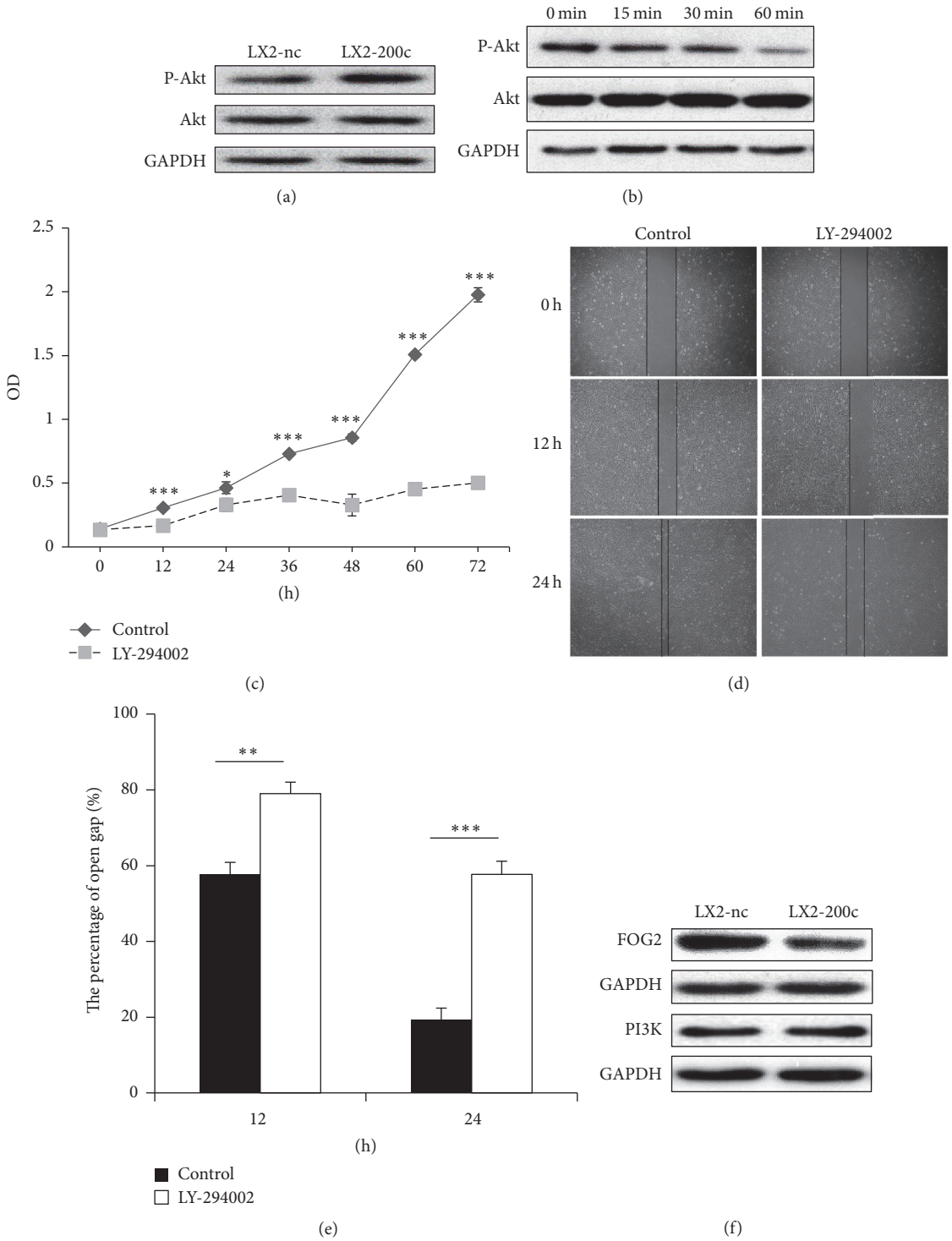

Figure 2: miR-200c activates the PI3K/Akt pathway via suppressing expression of FOG2. (a) The level of phosphorylation at Akt residue S473 was significantly higher in LX2-200c cells than LX2-nc cells. (b) 25 μM LY-294002 (a PI3K inhibitor) significantly inhibited the expression of phospho-Akt in LX2-200c cells in a time-dependent manner. (c–e) 25 μM LY-294002 significantly inhibited the proliferation and migration of LX2-200c cells. (f) There was the significantly lower levels of FOG2 expression in LX2-200c cells, while no significant change was observed in PI3K expression. $*$ means $p < 0.05$, $**$ means $p < 0.01$, and $***$ means $p < 0.001$.

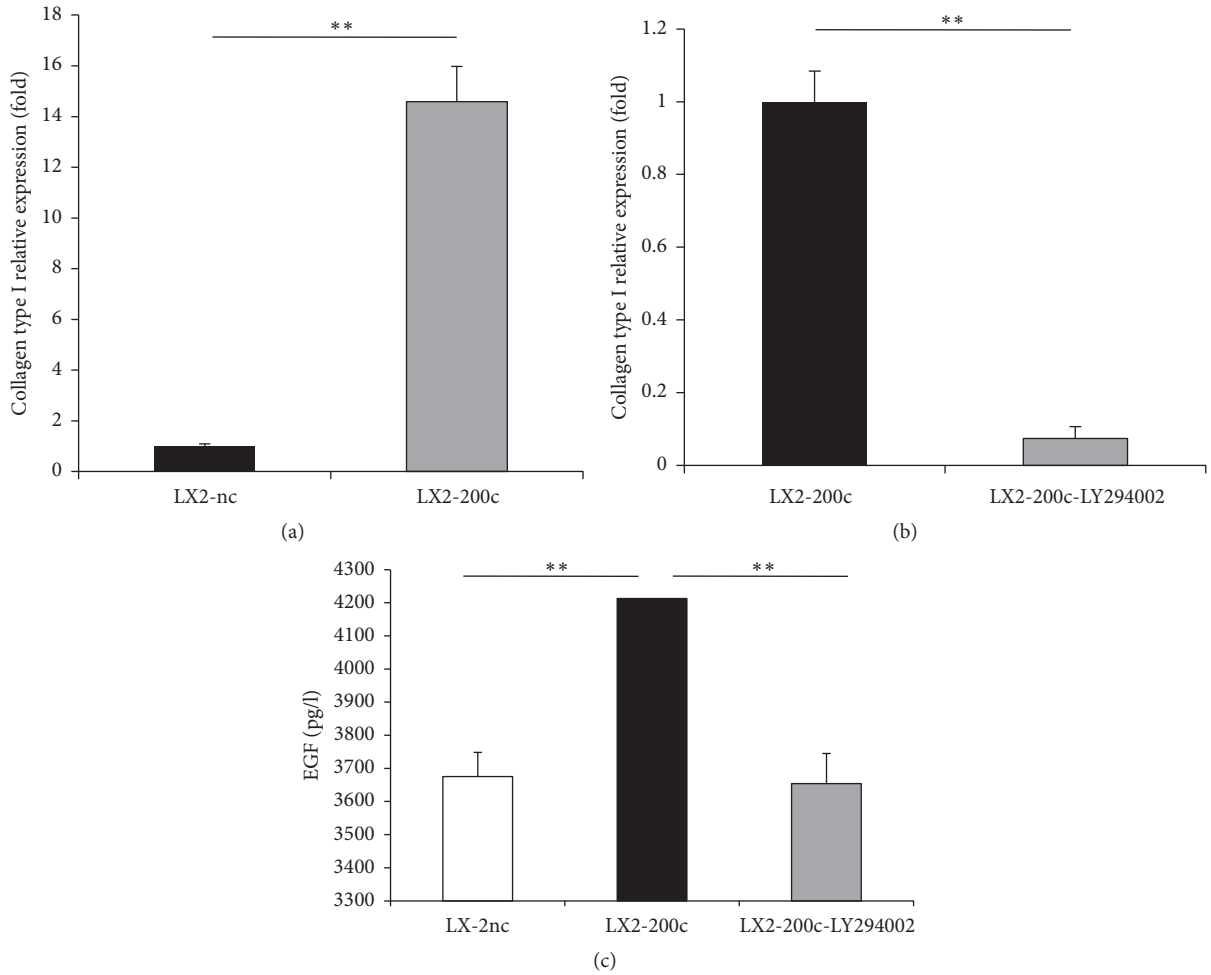

Figure 3: miR-200c overexpression upregulates the expression of collagen type I and epidermal growth factor (EGF) via the FOG2/PI3K/Akt pathway. (a, c) miR-200c overexpression significantly upregulated the gene expression of collagen type I and EGF secretion in HSCs. (b, c) 25 μM LY-294002 (a PI3K inhibitor) significantly inhibited the gene expression of collagen type I and EGF secretion in LX2-200c cells. $**$ means $p < 0.01$.

a significantly increased level of EGF secretion by HSCs after miR-200c transfection (Figure 3(c)), which could be inhibited by treatment with 25 μM LY294002 for 30 min (Figure 3(c)). These findings proved that PI3K/Akt signaling is involved in miR-200c-enhanced secretion of EGF.

4. Conclusion

Hepatic stellate cells (HSCs) are thought to play a crucial role in liver fibrosis, as their activation following liver injury is responsible for increased synthesis and deposition of ECM proteins in the liver. In addition, the proliferation and migration of HSCs after activation effectively amplify the fibrotic response. Furthermore, profibrotic cytokines and growth factors secreted by activated HSCs (like transforming growth factor-β [TGF-β], platelet-derived growth factor [PDGF], matrix metalloproteinases [MMPs], epidermal growth factor [EGF], leptin, and so on [4–9]) perpetuate the fibrotic process through paracrine and autocrine effects.

Although several studies have reported the involvement of miR-200s in the development of tissue fibrosis, including liver fibrosis, no study has implicated miR-200c. Additionally, miR-200a and miR-200b were found to have opposite effects on liver fibrosis development [13–17]. Herein, we showed that proliferation and migration of a human HSC (LX-2) cell line were enhanced by engineering it to stably overexpress miR-200c (LX2-200c). The expressions of α-SMA and vimentin (biomarkers of activated HSCs) and collagen type I (a major component of ECM) were found to be upregulated significantly in LX2-200c.

The phosphatidylinositol 3-kinase (PI3K)-Akt pathway plays a key role in cellular hypertrophy. The PI3K enzyme, a well-known upstream mediator of Akt kinase activation, is composed of a catalytic subunit, p110, and a regulatory subunit, p85α. The catalytic subunit of PI3K can recruit Akt kinase to the membrane and activate it by phosphorylation. Activated Akt further phosphorylates several downstream proteins that play central roles in hypertrophy, cell growth, cell survival, and protein synthesis [20]. However, a novel protein FOG2 binds to p85α, thereby inhibiting PI3K activation. Intriguingly, miR-200 was reported to decrease FOG2

expression by targeting the 3′ UTR of the FOG2 mRNA, thereby altering PI3K activity and regulating the insulin signaling pathway and metabolism [16, 21]. Park et al. [22] indicated that FOG2 is downregulated by mimics of miR-200b and miR-200c in mouse mesangial cells (MMC). Mei et al. [23] also found that miR-200c inhibited the expression of PTEN and FOG2 to promote the expansion and immune suppressive activity of myeloid-derived suppressor cells (MDSCs). In the present studies, we showed that transfection of miR-200c significantly reduced FOG2 protein levels in LX-2 cells, which subsequently led to PI3K/Akt signaling activation. To determine whether the effect of miR-200c is mediated through the FOG2/PI3K pathway, we used LY294002, a specific PI3 kinase inhibitor, to block PI3K activation in the LX-2 cells transfected with miR-200c. The results showed that LY294002 treatment significantly inhibited miR-200c-enhanced LX-2 cell proliferation and migration and ECM deposition, which suggested that PI3K/Akt activation was essential to the profibrotic effect of miR-200c.

EGF plays a role in liver fibrosis, liver cirrhosis, and even hepatocellular carcinoma (HCC). EGF expression in the liver increases during cirrhosis, and the level of EGF mRNA expression is associated with poor survival of cirrhotic patients. Bachem et al. [24] indicated that EGF signaling triggered HSC proliferation in a receptor-dependent autocrine/paracrine manner. Zhang et al. [25] pointed out that EGF expression was significantly increased in activated HSCs, and EGF promotes HSC proliferation via activation of the EGF receptor (EGFR). Fuch et al. [26] reported that the small-molecule EGFR inhibitor erlotinib inhibited the activation of HSCs, prevented the progression of cirrhosis, and caused fibrosis to regress in some animal models. Our results showed that miR-200c overexpression also promoted the secretion of EGF in HSCs and that miR-200c-mediated EGF secretion could be inhibited by LY294002 treatment. However, our preliminary experiment showed that miR-200c overexpression had no effect on other growth factors, including transforming growth factor-β1 (TGF-β1), platelet-derived growth factor (PDGF), fibroblast growth factor (FGF), hepatocyte growth factor (HGF), and vascular endothelial growth factor (VEGF). So we speculated that miR-200c promoted HSC proliferation, migration, and ECM production in part via autocrine activation of EGF signaling, rather than signaling by other growth factors. In addition, PI3K/Akt signaling also played a key role in miR-200c-mediated EGF secretion by HSCs.

In summary, our results show directly that miR-200c is an important promoter of HSCs activity, proliferation, and migration and has a very important role in liver fibrosis. We found that the effects of miR-200c on HSCs and liver fibrosis are mediated via downregulation of FOG2 protein synthesis, activation of PI3K/Akt signaling, upregulation of activation of autocrine EGF signaling, and upregulation of collagen type I production in HSCs (Figure 4). In view of its putative pathogenic role in HSCs, miR-200c may be a potential marker for HSC activation and liver fibrosis progression, and even a potential target for the treatment of liver fibrosis.

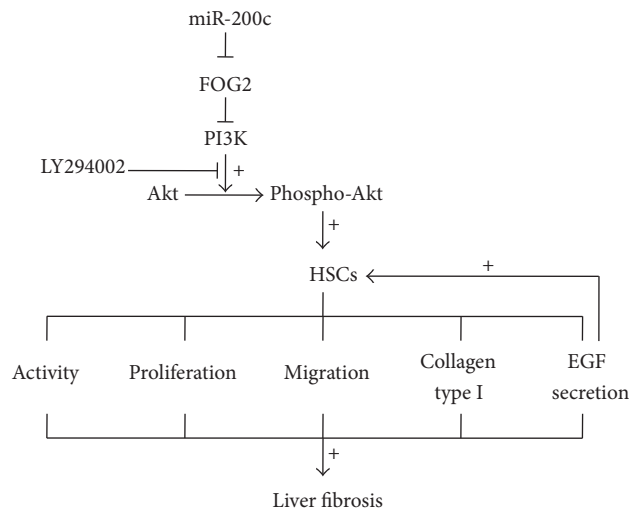

Figure 4: Schematic model of miR-200c accelerating hepatic stellate cell-induced liver fibrosis via targeting the FOG2/PI3K pathway. miR-200c activates HSCs and finally accelerates the progression of liver fibrosis via downregulation of FOG2 protein synthesis, activation of PI3K/Akt signaling. Autocrine activation of EGF signaling may also be a mechanism of miR-200c-mediated HSCs activation.

Abbreviations

HSCs: Hepatic stellate cells
SMA: α-Smooth muscle actin
EGF: Epidermal growth factor
HCC: Hepatocellular cancer
ECM: Extracellular matrix
miRNAs: MicroRNAs
UUO: Unilateral ureteral obstruction
DMEM: Dulbecco's modified Eagle's medium
FBS: Fetal bovine serum
qPCR: Real time quantitative PCR
RIPA: Radioimmunoprecipitation assay
BSA: Bovine serum albumin
ECL: Clarity enhanced chemiluminescence
TGF-β: The transforming growth factor β
PDGF: Platelet-derived growth factor
MMPs: Matrix metalloproteinases
PI3K: Phosphatidylinositol 3-kinase
MMC: Mouse mesangial cells
MDSCs: Myeloid-derived suppressor cells
EGFR: EGF receptor
FGF: Fibroblast growth factor
HGF: Hepatocyte growth factor
VEGF: Vascular endothelial growth factor.

Data Access

The datasets during and/or analysed during the current study are available from the corresponding author on reasonable request.

Conflicts of Interest

The authors declare that they have no conflicts of interest.

Authors' Contributions

Tengfei Ma and Xiuqin Cai contributed equally to this work. The project was conceived and directed by Yunpeng Hua and Quentin Liu. Data were collected, analyzed, and interpreted by Tengfei Ma, Xiuqin Cai, Zifeng Wang, Songshan Jiang, Chang Wang, and Yunpeng Hua. Statistical analysis was performed by Li Huang. The manuscript was written by Yunpeng Hua. All authors read and approved the final manuscript.

Acknowledgments

This study was supported by grants from the National Natural Science Foundation of China (no. 81201918), the Science and Technology Project of Guangdong Province (nos. 2012B031800099, 2014A020212626), the Doctorial Fellowship of Higher Education of China (no. 200805581172), and the Scientific Research Foundation for Returned Overseas Chinese Scholars and the State Education Ministry (no. 311, in 2015).

References

[1] V. Hernandez-Gea and S. L. Friedman, "Pathogenesis of liver fibrosis," *Annual Review of Pathology*, vol. 6, pp. 425–456, 2011.

[2] E. A. Tsochatzis, J. Bosch, and A. K. Burroughs, "Liver cirrhosis," *The Lancet*, vol. 383, no. 9930, pp. 1749–1761, 2014.

[3] O. Ramos-Lopez, E. Martinez-Lopez, S. Roman, N. A. Fierro, and A. Panduro, "Genetic, metabolic and environmental factors involved in the development of liver cirrhosis in Mexico," *World Journal of Gastroenterology*, vol. 21, no. 41, pp. 11552–11566, 2015.

[4] Z. Liu, J. Yi, R. Ye et al., "miR-144 regulates transforming growth factor-β1 iduced hepatic stellate cell activation in human fibrotic liver," *International Journal of Clinical and Experimental Pathology*, vol. 8, pp. 3994–4000, 2015.

[5] N. Ikeda, S. Murata, T. Maruyama et al., "Platelet-derived adenosine 5'-triphosphate suppresses activation of human hepatic stellate cell: In vitro study," *Hepatology Research*, vol. 42, no. 1, pp. 91–102, 2012.

[6] R. Bansal, J. van Baarlen, G. Storm, and J. Prakash, "The interplay of the Notch signaling in hepatic stellate cells and macrophages determines the fate of liver fibrogenesis," *Scientific Reports*, vol. 5, Article ID 18272, 2015.

[7] M. Mikula, V. Proell, A. N. M. Fischer, and W. Mikulits, "Activated hepatic stellate cells induce tumor progression of neoplastic hepatocytes in a TGF-β dependent fashion," *Journal of Cellular Physiology*, vol. 209, no. 2, pp. 560–567, 2006.

[8] K. Taura, S. de Minicis, E. Seki et al., "Hepatic stellate cells secrete angiopoietin 1 that induces angiogenesis in liver fibrosis," *Gastroenterology*, vol. 135, no. 5, pp. 1729–1738, 2008.

[9] B.-B. Wang, J.-Y. Cheng, H.-H. Gao, Y. Zhang, Z.-N. Chen, and H. Bian, "Hepatic stellate cells in inflammation-fibrosis-carcinoma axis," *Anatomical Record*, vol. 293, no. 9, pp. 1492–1496, 2010.

[10] J. Lambrecht, I. Mannaerts, and L. A. van Grunsven, "The role of miRNAs in stress-responsive hepatic stellate cells during liver fibrosis," *Frontiers in Physiology*, vol. 6, article 209, 2015.

[11] J. Du, X. Niu, Y. Wang et al., "MiR-146a-5p suppresses activation and proliferation of hepatic stellate cells in nonalcoholic fibrosing steatohepatitis through directly targeting Wnt1 and Wnt5a," *Scientific Reports*, vol. 5, Article ID 16163, 2015.

[12] M. Coll, A. E. Taghdouini, L. Perea et al., "Integrative miRNA and gene expression profiling analysis of human quiescent hepatic stellate cells," *Scientific Reports*, vol. 5, Article ID 11549, 2015.

[13] S. Yang, S. Banerjee, A. de Freitas et al., "Participation of miR-200 in pulmonary fibrosis," *The American Journal of Pathology*, vol. 180, no. 2, pp. 484–493, 2012.

[14] Y. Murakami, H. Toyoda, M. Tanaka et al., "The progression of liver fibrosis is related with overexpression of the miR-199 and 200 families," *PLoS ONE*, vol. 6, no. 1, Article ID e16081, 2011.

[15] Y. Y. Feng, X. Q. Xu, C. B. Ji, C. M. Shi, X. R. Guo, and J. F. Fu, "Aberrant hepatic MicroRNA expression in nonalcoholic fatty liver disease," *Cellular Physiology and Biochemistry*, vol. 34, no. 6, pp. 1983–1997, 2014.

[16] Y. Xiao, J. Wang, Y. Chen et al., "Up-regulation of miR-200b in biliary atresia patients accelerates proliferation and migration of hepatic stallate cells by activating PI3K/Akt signaling," *Cellular Signalling*, vol. 26, no. 5, pp. 925–932, 2014.

[17] X. Sun, Y. He, T.-T. Ma, C. Huang, L. Zhang, and J. Li, "Participation of miR-200a in TGF-β1-mediated hepatic stellate cell activation," *Molecular and Cellular Biochemistry*, vol. 388, no. 1-2, pp. 11–23, 2014.

[18] Y. Hua, S. White-Gilbertson, J. Kellner et al., "Molecular chaperone gp96 is a novel therapeutic target of multiple myeloma," *Clinical Cancer Research*, vol. 19, no. 22, pp. 6242–6251, 2013.

[19] J. Kim, S. Wang, J. Hyun et al., "Hepatic stellate cells express thymosin beta 4 in chronically damaged liver," *PLoS ONE*, vol. 10, no. 3, Article ID e0122758, 2015.

[20] S. Reif, A. Lang, J. N. Lindquist et al., "The role of focal adhesion kinase-phosphatidylinositol 3-kinase-Akt signaling in hepatic stellate cell proliferation and type I collagen expression," *Journal of Biological Chemistry*, vol. 278, no. 10, pp. 8083–8090, 2003.

[21] S. Hyun, J. H. Lee, H. Jin et al., "Conserved MicroRNA miR-8/miR-200 and its target USH/FOG2 control growth by regulating PI3K," *Cell*, vol. 139, no. 6, pp. 1096–1108, 2009.

[22] J. T. Park, M. Kato, H. Yuan et al., "FOG2 protein down-regulation by transforming growth factor-β1-induced MicroRNA-200b/c leads to akt kinase activation and glomerular mesangial hypertrophy related to diabetic nephropathy," *The Journal of Biological Chemistry*, vol. 288, no. 31, pp. 22469–22480, 2013.

[23] S. Mei, J. Xin, Y. Liu et al., "MicroRNA-200c promotes suppressive potential of myeloid-derived suppressor cells by modulating PTEN and FOG2 expression," *PLoS ONE*, vol. 10, no. 8, Article ID e0135867, 2015.

[24] M. G. Bachem, U. Riess, and A. M. Gressner, "Liver fat storing cell proliferation is stimulated by epidermal growth factor/transforming growth factor alpha and inhibited by transforming growth factor beta," *Biochemical and Biophysical Research Communications*, vol. 162, no. 2, pp. 708–714, 1989.

[25] D. Zhang, J. Zhang, X. Jiang et al., "Heparin-binding epidermal growth factor-like growth factor: a hepatic stellate cell proliferation inducer via ErbB receptors," *Journal of Gastroenterology and Hepatology*, vol. 29, no. 3, pp. 623–632, 2014.

[26] B. C. Fuchs, Y. Hoshida, T. Fujii et al., "Epidermal growth factor receptor inhibition attenuates liver fibrosis and development of hepatocellular carcinoma," *Hepatology*, vol. 59, no. 4, pp. 1577–1590, 2014.

Hindawi
BioMed Research International
Volume 2017, Article ID 4932759, 8 pages
https://doi.org/10.1155/2017/4932759

Research Article

Surveillance Program for Diagnosis of HCC in Liver Cirrhosis: Role of Ultrasound Echo Patterns

Maurizio Soresi,[1] Antonino Terranova,[1] Anna Licata,[1] Antonietta Serruto,[1] Giuseppe Montalto,[1] Giuseppe Brancatelli,[2] and Lydia Giannitrapani[1]

[1] *Biomedical Department of Internal Medicine and Specialties (Di.Bi.M.I.S.), University of Palermo, Palermo, Italy*
[2] *Section of Radiology, Di.Bi.Me.F., University of Palermo, Palermo, Italy*

Correspondence should be addressed to Lydia Giannitrapani; lydiagiannitp@gmail.com

Received 23 January 2017; Revised 6 April 2017; Accepted 11 April 2017; Published 30 May 2017

Academic Editor: Ankur Arora

International guidelines suggest ultrasound surveillance for hepatocellular carcinoma (HCC) early diagnosis in liver cirrhosis (LC) patients, but 40% of nodules <2 cm escape detection. We investigated the existence of an ultrasound pattern indicating a higher risk of developing HCC in patients under surveillance. 359 patients with LC (Child-Pugh A-B8) underwent ultrasound screening (median follow-up 54 months, range 12–90 months), liver function tests, alpha-fetoprotein assay, and portal hypertension evaluation. Echo patterns were homogeneous, bright liver, coarse, coarse small nodular pattern, and coarse large nodular pattern. During follow-up 13.9% developed HCC. At multivariate analysis using Cox's model alpha-fetoprotein, coarse large nodular pattern, portal hypertension, and age were independent predictors of HCC development. Kaplan-Meier estimates of HCC cumulative risk in relation to the baseline echo patterns showed risk of 75% in coarse large nodular pattern patients, 23% coarse small nodular pattern, 21% coarse pattern, 0% homogeneous, and bright liver echo patterns (log-rank test = 23.6, $P < 0.001$). Coarse large nodular pattern indicates a major risk factor for HCC as 40.7% of patients with this pattern developed HCC. Homogeneous and bright liver echo patterns and the absence of portal hypertension were not related to HCC. This observation could raise the question of possibly modifying the follow-up timing in this subset of patients.

1. Introduction

International guidelines of the screening programs for the early detection of hepatocellular carcinoma (HCC) in cirrhosis patients suggest an ultrasound every six months as the first level of investigation [1–5]. Their main goal is to diagnose the so-called very early HCC, that is, a neoplastic nodule measuring <2 cm [2]. This diagnosis is not always easy, both due to the relatively low sensitivity of the tool, which in very early HCC does not exceed 60% [6, 7], and due to the pattern of presentation at onset, which is sometimes multinodular or infiltrative [8, 9]. Therefore, other indicators to select patients who may have a higher risk of progression in HCC are necessary [10]. Retrospective studies indicate that the *coarse nodular* pattern is a risk factor for the development of HCC [11–15]. Coarse echo pattern is the most common one found in liver cirrhosis (LC) [11]; it is defined coarse nodular by the detection within the liver of small multiple hypoechoic nodular images (<1 cm) at US. A coarse large nodular pattern (CLNP) presents nodules >5 mm, while in a coarse small nodular pattern (CSNP) nodules are <5 mm [11–15]. Histological studies on cirrhotic liver have shown the risk of evolution of these macronodules in HCC [16]. Although the international guidelines recognize the coarse nodular pattern as a risk factor for HCC, they do not recommend a closer follow-up when it is present [2].

In our clinical practice we have anecdotally observed a correlation between coarse nodular pattern and evolution into hepatocellular carcinoma. Consequently, to put this observation in perspective, we carried out a longitudinal study on a cohort of patients with LC prospectively followed from January 2007 to June 2014 in a surveillance program for the early detection of HCC. Our aim was to test the hypothesis that an echo pattern may be associated with a greater

or lower risk of evolution to HCC and, in this case, if it is advisable to monitor these patients at shorter or longer follow-up intervals.

2. Materials and Methods

2.1. Patient Enrolment. We prospectively enrolled consecutive patients with LC of different etiologies, who routinely underwent the surveillance program in accordance with the international guidelines [2, 3]. Exclusion criteria were the following: (a) patients with a history of malignancy; (b) patients with hepatic nodules with suspected malignancy at the first ultrasound; (c) patients of age > 80 years; (d) patients with Child-Pugh class > B 9; and (e) when ultrasound was difficult to perform due to obese habitus or interference from gas in the bowel.

From January 2008 to June 2015, a total of 425 patients were enrolled, but 66 (15.5%) were excluded for reasons above mentioned. 359 patients were thus included in the study (178 M, 181 F), with a mean age of 64.9 ± 9.4 years. The median follow-up was 54 months (12–90 months). Sixty-one of the 359 patients were lost during follow-up due to death or dropout. However, all 61 had a minimum follow-up period of at least 12 months and were therefore also included in the analysis.

The study was carried out under informed consent according to protocols approved by the Biomedical Department of Internal Medicine and Specialties (DIBIMIS) Institutional Review Board (IRB)

A questionnaire designed to assess clinical history, onset of liver disease and its etiology, comorbidities, and medication was administered to all the patients included. All patients also underwent a physical examination, complete blood count, and kidney and liver function tests and were then classified according to the Child-Pugh score [17]. If the etiology of liver disease was unknown, HBsAg, anti-HDV, anti-HCV, and iron serum marker (ferritin, serum iron, and transferrin saturation) assays were performed. Non-organ-specific autoantibodies (ANA, AMA, ASMA, and LKM1) were assayed in patients negative for viral and iron marker screening. Alpha 1 fetoprotein (AFP) assay was performed in all patients every six months.

2.2. Abdominal Ultrasound. Ultrasound (US) examinations were performed in the morning after an overnight fast of at least 10 hours, using a 5000 Philips HDI machine with a 2–5 MHz convex probe.

Based on the US pattern, patients were divided into five groups:

(1) Homogeneous (H): echoes being homogeneously distributed and echogenicity was slightly or not increased.

(2) Bright liver (BL): according to the classical definition [18].

(3) Coarse pattern (C): characterized by "pinhead" echoes which are coarse and not homogeneously distributed, without posterior beam attenuation and without formation of nodules [18, 19] (Figure 1).

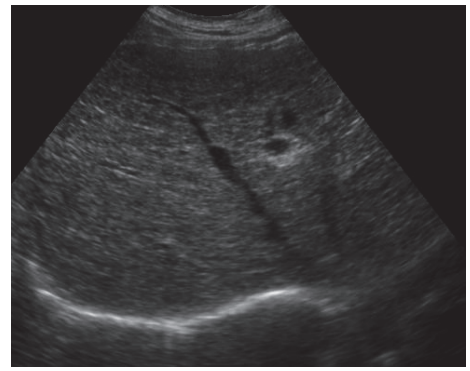

Figure 1: Coarse echo pattern (see text).

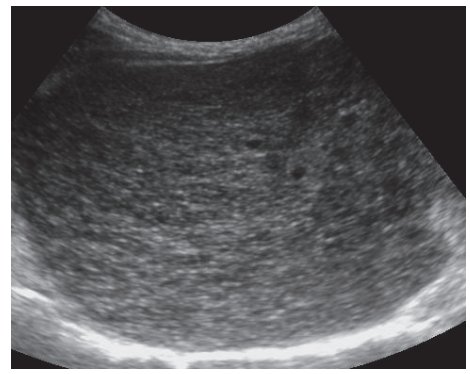

Figure 2: Hypoechoic nodules < 5 mm in diameter on the background of the coarse echo pattern.

(4) Coarse small nodular pattern (CSNP): echo pattern showing scattered hypoechoic nodules up to 3–5 mm in diameter on the background of the coarse echo pattern described above [14] (Figure 2).

(5) Coarse large nodular pattern (CLNP): showing scattered hypoechoic nodules > 5 mm in diameter on the background of the coarse echo pattern mentioned above [14] (Figure 3).

Portal vein diameter (PVD), longitudinal diameter of spleen (LDS), and reduction in the respiratory variations of splenic and mesenteric vein diameters were measured in accordance with the literature data and EFSUMB guidelines [20–22]. Normal values were those recommended (reduction of the respiratory variations of splenic and mesenteric vein diameters) by the same guidelines [22].

The platelet to spleen ratio was calculated as described previously by Giannini and colleagues as the ratio between platelet number/mm^3 and the bipolar diameter of the spleen in millimeters (cut-off 909) [23].

US was performed by two operators (MS, AT) with comparable ability; they had the same professional background, having been trained in this specific field, and both had over a decade of experience.

To reduce interobserver variability of both operators, a set of standard images with H, BL, C, and CSNP was used

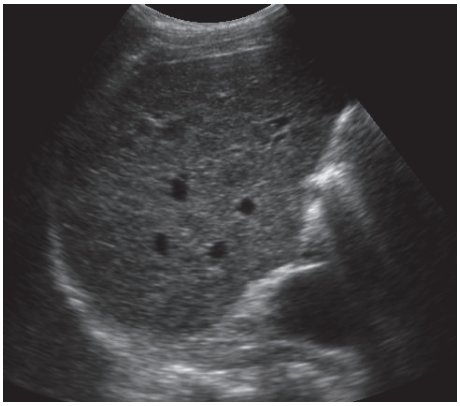

Figure 3: Hypoechoic nodules > 5 mm in diameter on the background of the coarse echo pattern.

to assess echo patterns as in Caturelli's work and Kitamura's work figures for the CLNP [11, 14].

Before the study, the ultrasound operators agreed on general roles to follow in the procedure of examination, and they participated in a short training program according to previous ultrasound studies performed in other training [21, 24].

After training, skilled operators identified the possible sources of interobserver variability and issued a strict protocol.

The echo pattern was known to the operators during every serial US examination.

2.3. Diagnosis and Follow-Up. LC was diagnosed by histology in 20% of cases; in the remaining cases diagnosis was made on the basis of clinical (presence of spider nevi, palmar erythema, and ascites), endoscopic (esophageal varices or congestive gastropathy), ultrasound (irregular liver surface, hypertrophy of the left segments, ascites, and signs of portal hypertension) parameters [24], and laboratory abnormalities (INR elongation, hypoalbuminemia, increased gamma globulin, and thrombocytopenia). Patients with LC were staged according to the Child-Pugh clinical classification [17].

HCC was diagnosed in accordance with the AASLD guidelines [2, 3] and staged according to the Barcelona Clinic Liver Cancer (BCLC) staging [25].

Patients underwent a medical examination, liver function tests, and AFP assay, as well as ultrasound every six months, with a variability ranging ±1 month in 20% of total examinations.

Nodules showing growth over time or onset of new lesions >1 cm, in accordance with the guidelines, were considered as potential HCC and radiological examinations or biopsy were performed, as set out in the specific guidelines [2, 3].

Portal Hypertension Diagnosis. Patients were considered to have portal hypertension if they had

(1) endoscopic signs of portal hypertension, that is, presence of esophageal varices, gastric varices portal hypertensive gastropathy, and gastric antral vascular ectasia,

(2) ascites and/or collateral circulation,

(3) at least 2 of these signs: portal diameter > 1.2 cm, respiratory variations < 40%, and platelet to spleen ratio < 909.

According to the absence/presence of portal hypertension, patients were labeled as 0/1, respectively.

2.4. Statistical Analysis. Data were expressed as mean ± SD if the distribution was normal, otherwise as median and range (min–max). Differences between the means of the various groups were calculated by ANOVA. Fisher's exact test, χ^2, and Mantel Haenszel χ^2 (χ^2_{MH}), were used when appropriate. Weighted kappa (k) statistics were used to evaluate interobserver agreement for echo pattern definition (scored 0/1). The kappa (k) value was scored according to Landis and Koch [26]. The strength of concordance was classified as follows: $k = 0$, none; $k < 0.21$, slight; $k = 0.21$–0.4, fair; $k = 0.41$–0.60, moderate; $k = 0.61$–0.8, substantial; $k \geq 0.81$, perfect [26]. To assess which variables measured at baseline were predictive of degeneration to HCC, the univariate Cox proportional hazards model (Hr) was fitted to each variable. All variables with a $P < 0.05$ underwent multivariate analysis to assess their value as independent predictors [27].

The Kaplan-Meier method was used to estimate the risks of HCC degeneration associated with liver echo pattern at enrolment. The log-rank test was used to estimate the probability of cumulative risk of HCC associated with the liver echo pattern [28].

The time of observation used in calculating the risk of HCC began at enrolment and ended when liver cancer was diagnosed, or when the patient died or at the last check-up, whichever came first. The Statistical Software SPSS version 22.0 was used for the statistical analysis. $P < 0.05$ was considered significant.

3. Results

3.1. Overview of the Cohort. The demographic, clinical, and stage of liver disease data are shown in Table 1. About one-third of patients had Diabetes Mellitus. 316/359 (88%) patients were in Child-Pugh class A and 197 (55%) had endoscopic signs of portal hypertension.

HCV infection was the most frequent etiology, being present in 260 patients (72.3%), followed by HBV in 24 cases (6.7%, of which 1.1% had anti HDV). 35 cases were of cryptogenic etiology (9.7%), which included 7 patients with a history of metabolic syndrome, 17 cases (4.7%) were in the alcohol group, and 15 cases (4.1%) had autoimmune liver diseases (including 2 patients with autoimmune hepatitis, 2 with primary sclerosing cholangitis, and 11 with primary biliary cirrhosis). The mixed/other forms were 9 (2.5%, including 2 with hemochromatosis).

In total, 90 patients (25%) with HCV-associated LC had completed at least one course of antiviral treatment (Peginterferon alone or Peginterferon plus ribavirin), while

Table 1: Clinical and laboratory features of the study patients.

	$N = 359$
Age (years)	64.9 ± 9.4
Sex (M/F)	181/178
AST (IU/L)	53 (8–477)
ALT (IU/L)	56 (12–443)
ALB (g/dL)	3.9 ± 0.6
Platelets n/mm^3	130.000 (26.000–400.000)
Longitudinal diameter of spleen (mm)	132 ± 26
AFP (ng/mL)	5.2 (0.2–258)
Diabetes Mellitus	119 (33%)
Antiviral treatment	118 (33%)
Child-Pugh Score:	
A5-6	316 (88%)
B7-8	43 (12%)
Endoscopic portal hypertension	197 (55%)
Portal hypertension	237 (66%)

AST, aspartate transaminase; ALT, alanine transaminase; ALB, albumin; AFP, alpha-fetoprotein
Portal hypertension (endoscopic + noninvasive).

Table 2: Correlation coefficient (k) of the two sonographers for single echo pattern classified according to Landis' score.

	k concordance	95% CI	Landis' score
H	1	—	Perfect agreement
BL	0.85	0.80–0.90	Perfect agreement
C	0.88	0.81–0.95	Perfect agreement
CSNP	0.79	0.75–0.83	Substantial agreement
CLNP	0.78	0.73–0.93	Substantial agreement

H, homogeneous; BL, bright liver; C, coarse pattern; CSNP, coarse small nodular pattern; CLNP, coarse large nodular pattern.

all patients with HBV-associated LC were on treatment with nucleoside/nucleotide analogs.

3.2. Distribution of Echo Patterns. Overall, for the various echo patterns, k was 0.85 (95% CI 0.75–0.9), that is, perfect agreement according to Landis' score. Table 2 shows the k concordance for each single echo pattern, which oscillated between substantial and perfect agreement. No discordance was observed for the H pattern.

Table 3 shows the echo patterns at enrolment and the follow-up period of each pattern. There were no significant statistical differences among them ($F = 0.9$; P = ns).

In 90 subjects (25%) the echo structure changed during the follow-up period. Figure 4 shows these changes and their distribution at baseline and at the end of the follow-up period. At the end of follow-up the nodular echo patterns (both CSNP and CLNP) had increased in a statistically significant way ($\chi^2_{\mathrm{MH}} = 114,7$; $P = 0.0001$). In fifty patients (13.9%; CI 95% 10.5–17.9) LC evolved into HCC during follow-up.

Table 3: Echo patterns at enrolment and duration of follow-up.

	$n =$	% (IC 95%)	Follow-up in month*
H	8	2.3 (1.14–4.3)	48.0 ± 20.6
BL	44	12.2 (IC 95% 9.2–16.0)	48.5 ± 22.1
C	248	69.1 (IC 95% 64.1–73.6)	49.71 ± 23.4
CSNP	32	8.9%; (IC 95% 6.4–12.3)	44.9 ± 22.9
CLNP	27	7.5 (IC 95% 5.2–10.7)	44.5 ± 20.7

*($F = 0.9$; P = ns).
H, homogeneous; BL, bright liver; C, coarse pattern; CSNP, coarse small nodular pattern; CLNP, coarse large nodular pattern.

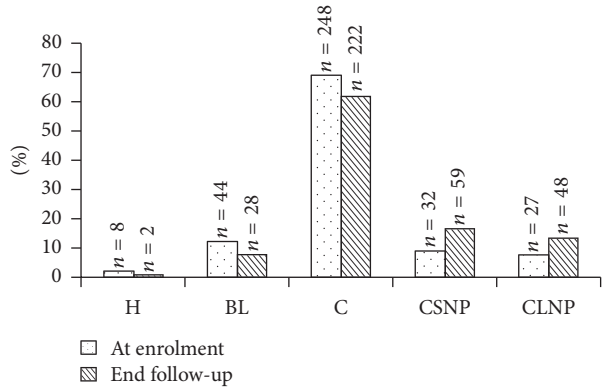

Figure 4: Changes in echo pattern at enrolment and end of follow-up (H, homogeneous; BL, bright liver; C, coarse pattern; CSNP, coarse small nodular pattern; CLNP, coarse large nodular pattern) ($\chi^2_{\mathrm{MH}} = 114,7$; $P = 0.0001$).

3.3. Prognostic Indicators of HCC Evolution According to the Different Echo Patterns and PH. Using the Cox model (Table 4), at univariate analysis many factors were associated at baseline with the evolution in HCC, while at multivariate analysis only AFP: Hr = 1.1 (CI 95%: 1.05–1.2) ($P < 0.02$), CLNP: Hr = 3.4 (CI 95% = 1.6–6.6) ($P = 0.02$), age: Hr = 1.05 (CI 95% 1.02–1.1) ($P = 0.03$), and PH: Hr 2.1 (CI 95%: 1.1–4.1) $P = 0.03$ were found to be independent predictors of HCC. Even when we eliminated AFP from the multivariate model, CLNP, age, and PH were still associated factors of HCC degeneration (data not shown).

The median follow-up time of patients with PH was 49 (12–90) months; in those without PH it was 48 (12–90) months (P = ns).

Figure 5 shows the cumulative risk curves for the development of HCC in relation to the baseline echo pattern. Using the Kaplan-Meier method, the US pattern at the end of follow-up showed a cumulative risk % (±SE) for HCC of 75% (±10%) for patients with CLNP, 23% (±10%) with CSNP, 21% (±3%) with C pattern, and 0% with the H and BL patterns. The log-rank test of the five curves showed a statistically significant difference (log-rank test = 23.6, $P < 0.001$).

Table 5 shows the echo pattern distribution at enrolment in relation to the BCLC Stage. There was no statistically significant association between BCLC Stage and echo patterns at enrolment.

Table 4: Risk factors for progression to hepatocellular carcinoma according to Cox's model at univariate and multivariate analysis.

	HR univariate	95% CI	$P <$	HR multivariate	95% CI	$P <$
Age	1.05	1.02–1.08	0.02	1.05	1.02–1.1	0.03
Sex	1.14	0.6–1.9	ns	—	—	
HCV	2.06	0.9–4.5	ns	—	—	
HBV	1.36	0.5–3.8	ns	—	—	
Alcohol	0.43	0.1–3.1	ns	—	—	
Cryptogenetic	0.4	0.1–2.7	ns	—	—	
Autoimmune liver diseases	0.047	0.02–37.1	ns	—	—	
Metabolic	0.8	0.22–111.7	ns	—	—	
H	—	—	—	—	—	
BL	—	—	—	—	—	
C	1.02	0.55–1.90	ns	—	—	
CSNP	1.02	0.36–2.84	ns	—	—	
CLNP	3.84	1.9–7.51	0.02	3.4	1.6–6.6	0.01
AFP ng/ml	1.1	1.06–1.2	0.0001	1.1	1.05–1.2	0.02
AST IU/L	1.04	1.01–1.07	0.03	—	—	—
ALT IU/L	1.1	1.03–1.2	0.0001	—	—	—
ALB g/dl	0.51	0.31–0.81	0.005	—	—	—
Antiviral treatment	0.9	0.7–2	ns	—	—	—
Child-Pugh score (A5-B8)	0.9	0.65–1.21	ns	—	—	—
Diabetes Mellitus	1.12	0.8–2.15	ns	—	—	
Endoscopic portal hypertension	1.78	0.75–4.25	ns	—	—	—
Portal hypertension	2.3	1.18–4.5	0.02	2.1	1.1–4.1	0.03

HR, Hazard Ratio; CI, Confidence Interval; H, homogeneous; BL, bright liver; C, coarse pattern; CSNP, coarse small nodular pattern; CLNP, coarse large nodular pattern; AFP, alpha-fetoprotein; AST, aspartate transaminase; ALT, alanine transaminase; ALB, albumin; portal hypertension (endoscopic + noninvasive).

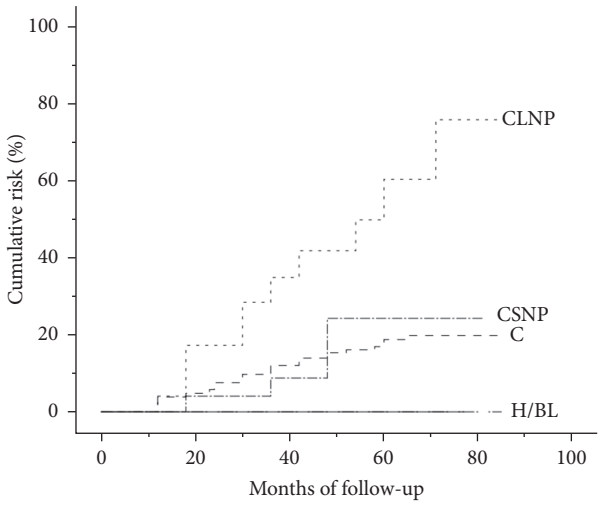

Figure 5: Cumulative risk for echo patterns: H/BL (homogeneous/bright liver), C (coarse), CSNP (coarse small nodular pattern), and CLNP (coarse large nodular pattern). A log-rank test showed significant differences (log-rank test = 23.6, $P < 0.001$).

During follow-up, patients who developed more frequently HCC were those with CLNP pattern at enrolment 11/27 (40%; CI 95% 24.4–59.4), in a statistically different manner versus C 35/248 (14%; CI 95% 10.3–14.1) ($P < 0.002$) and versus CSNP 4/32 (12.5%; CI 95% 5.1–28.2) ($P < 0.0001$).

3.4. Reliability of Ultrasound. Ultrasound missed 12 nodules, detected by CT or MR, 8/11 were smaller than 2 cm, and 3 were <3 cm. In 1 case the nodule was not detected by ultrasound and suspected because there was an abrupt increase of AFP from 30 to 210 ng/mL without increase in serum levels of AST/ALT; CT confirmed the presence of HCC 2.3 cm. The positive predictive value of ultrasound was 79% (CI 95%; 67–88); the negative predictive value was 96% (CI 95% 93–98%).

4. Discussion

Hepatocellular carcinoma is one of the most frequent cancers in the world, with a high mortality rate. Since the main associated risk factor is LC [29], cirrhotic patients undergo six-monthly surveillance programs with ultrasound, aimed at establishing an early diagnosis, which is associated with a greater effectiveness of treatment [1–5].

Unfortunately, tumors > 2 cm are often found, even in patients under surveillance. Early diagnosis is not easy, due to the limited sensitivity of US, not exceeding 60% in very early HCC [6, 7], and to the pattern of tumor spread, which can sometimes be multinodular or infiltrating [8, 9]. The positive and negative predictive values are consistent with data reported in the literature when, as in our study, the gold standard consists of radiological investigations such as CT and MR. The reliability of ultrasound is lower when the gold standard is the histological study of explanted livers [30].

Table 5: Distribution of HCC and BCLC staging in relation to the echo patterns at enrolment.

Echo pattern at enrolment	H	BL	C	CSNP	CLNP	
	$n = 8$	$n = 44$	$n = 248$	$n = 32$	$n = 27$	
HCC $n = 50$	$n = 0$	$n = 0$	$n = 35$	$n = 4$	$n = 11$	
BCLC Stage						
0	0	0	15	1	6	
A	0	0	17	3	5	
B	0	0	2	0	0	
C	0	0	1	0	0	
D	0	0	0	0	0	$\chi^2 = 3.5$; P = NS

H, homogeneous; BL, bright liver; C, coarse pattern; CSNP, coarse small nodular pattern; CLNP, coarse large nodular pattern; HCC, hepatocellular carcinoma; BCLC, Barcelona Clinic Liver Cancer.

Moreover, not all patients with liver cirrhosis have an equal risk of developing HCC; therefore an increasing number of studies are being targeted to select "at risk" subpopulations to better focus the surveillance programs and reduce costs [10]. Reducing the follow-up interval to three months has not been very useful because this increased the number of false positives (regenerative nodules) and increased costs, without improving the diagnosis rates of very early HCC [31]. In the literature, the coarse nodular pattern has been proposed as an independent risk factor for the onset of hepatocellular carcinoma [11–15]. However, all the studies conducted so far have the limitation of being retrospective and performed with older generation ultrasound equipment.

In our study, the k value, using Landis's score, ranged between 0.79 and 1, which suggests that ultrasound has a good degree of reproducibility in defining the different echo patterns of liver cirrhosis, when it is performed by expert operators with specific training using up-to-date equipment as already demonstrated in previous US studies [21, 24] and according to what is recommended by current guidelines [1].

We conducted a longitudinal prospective study, the first to our knowledge, in which we followed a cohort of 359 patients with LC for a mean follow-up period of 54 months (12–90 months). In fifty of these subjects to date LC has evolved into hepatocellular carcinoma. This percentage (13.9%) is in agreement with findings in the current literature [31, 32]. The echo pattern most frequently associated with the neoplastic evolution was the CLNP 11/27 (40%). Using the Cox regression model at multivariate analysis the variables considered as risk factors for the onset of HCC were AFP, the CLNP, and age. Our data, therefore, although limited by the small number of CLNP patients confirm that this pattern has an increased risk for neoplastic degeneration. Moreover, histological studies have found in these subjects an increase in the hepatocellular proliferation index, evaluated with bromouridine [13], with techniques of immunoreactivity for the DNA polymerase-α [14] and with the nucleolar organizer regions [15].

It is well known that hepatocarcinogenesis in cirrhosis follows a "multiple steps" model, with the transition from a regenerative nodule, then a dysplastic nodule, and finally HCC [33]. A macronodular liver is probably at a greater risk because this mechanism is activated and can potentially be achieved in a number of different areas. Furthermore, the cirrhotic liver tends to become nodular over time, as confirmed in our study by the statistically significant trend increase (Table 2) in the nodular pattern during the surveillance period, and the pattern that increases most is the macronodular one. We used the Kaplan-Meier curves to estimate the cumulative risk of developing HCC. As shown in Figure 2, the coarse large nodular pattern appears to be significantly more at risk than the other echo patterns. In detail, at the end of follow-up, the risk of developing hepatocellular carcinoma was 75% for the CLNP, 23% for CSNP, and 21% for C.

Portal hypertension has been reported to be associated with a higher risk of HCC in patients with compensated cirrhosis [34]. It is well known, however, that endoscopic signs are specific but poorly sensitive for identifying which patients already have portal hypertension. Recent data suggest that noninvasive parameters can reliably indicate the presence or absence of clinically significant portal hypertension in patients with compensated cirrhosis [35]. In our study we used other noninvasive parameters of portal hypertension included in the guidelines, such as portal vein diameter and respiratory changes, and those already known in the literature, such as the spleen/platelet ratio [20–23]. With these we found that PH was an independent risk factor of neoplastic degeneration. We are aware that these data need to be confirmed, as a major limitation of our study is the lack of HVPG measurements. However, our results are supported by the study of Ripoll, who found that HVPG values > 10 mm Hg, together with low albumin levels and viral etiology, are indicative of neoplastic degeneration in LC patients. Although it is difficult to explain the reasons for such an association, some metabolic pathways of the cirrhotic patient may possibly stimulate portal hypertension and hepatocarcinogenesis, as suggested by the recent finding of heat shock protein increase in portal hypertension [36].

In this study the AFP was also confirmed as an independent risk factor for the development of hepatocellular carcinoma. However, the meta-analysis by Singal et al. has clarified its true role. This marker is a risk factor for HCC, but its evaluation is not very useful because it only slightly enhances US sensitivity in diagnosing early cancer from 64% to 70%, while increasing the cost [7].

When we compared the relationship between the echo patterns at enrolment and the BCLC staging of HCC, we found no statistical association. This result is important as it provides two suggestions: the first is that although the macronodular pattern does indicate a risk of neoplastic transformation, the six-monthly follow-up proposed by the guidelines allows a timely diagnosis of the disease; the second is that the biological aggressiveness of the tumor has probably no relationship with the US pattern and the presence of multiple nodules, as in the CLNP or CSNP, is therefore not predictive for a multifocal evolution.

Finally, similarly to the study by Caturelli et al. [11] none of the HCC cases developed on BL.

5. Conclusions

In summary, in this study we found that the CLNP and PH age and AFP are the most significant risk factors for malignant degeneration. While the CLNP group include a small number of patients, the absence of a relationship between the US findings at enrolment and tumor prognosis assessed by the BCLC classification suggests that to obtain an early diagnosis of HCC in the presence of a CLNP it is not necessary to shorten the six-month follow-up interval. In fact the level of risk determines whether to provide surveillance or not while the surveillance interval depends on the rate of tumor growth and the minimum size of tumor at diagnosis consistent with a high cure rate. There is no evidence, so far, data suggesting that higher risk equals more rapid growth. This is important because these patients, due to the lack of liver homogeneity observed at ultrasound, often arouse alarm requiring frequent and repeated imaging examinations, thus increasing the cost of the surveillance programs. However, its association with PH opens the door to new prospects, and further studies are required with histological or molecular marker analyses to allow the selection of higher risk categories. In this case the question could be raised as to whether it would be appropriate to change the follow-up timing in a given subpopulation of patients.

Finally, we are aware that the limited number of patients included in our study has not the power to modify the current timing of US in LC patients; however, they point to implement other studies with a greater number of patients in order to evaluate the opportunity to modify the current timing of US and, at the same time, reduce costs.

Conflicts of Interest

The authors declare no conflicts of interest.

References

[1] J. Bruix, M. Sherman, J. M. Llovet et al., "Clinical management of hepatocellular carcinoma, conclusions of the barcelona-2000 EASL conference," *Journal of Hepatology*, vol. 35, no. 3, pp. 421–430, 2001.

[2] J. Bruix, M. Sherman, Practice Guidelines Committee, and American Association for the Study of Liver Diseases, "Management of hepatocellular carcinoma," *Hepatology*, vol. 42, no. 5, pp. 1208–1236, 2005.

[3] J. Bruix and M. Sherman, "American Association for the Study of Liver Diseases. Management of hepatocellular carcinoma: an update," *Hepatology*, vol. 53, pp. 1020–1022, 2011.

[4] European association for the Study of the Liver and European Organisation for Research and Treatment of Cancer, "EASL-EORTC clinical practice guidelines: management of hepatocellular carcinoma," *Journal of Hepatology*, vol. 56, pp. 908–943, 2012.

[5] Italian Association for the Study of the Liver (AISF), AISF Expert Panel, AISF Coordinating Committee, L. Bolondi, U. Cillo, M. Colombo et al., "Position paper of the Italian Association for the Study of the Liver (AISF): the multidisciplinary clinical approach to hepatocellular carcinoma," *Digestive and Liver Diseases*, vol. 45, pp. 712–723, 2013.

[6] L. Bolondi, "Screening for hepatocellular carcinoma in cirrhosis," *Journal of Hepatology*, vol. 39, no. 6, pp. 1076–1084, 2003.

[7] A. Singal, M. L. Volk, A. Waljee, R. Salgia, P. Higgins, and M. A. Rogers, "Meta-analysis: surveillance with ultrasound for early-stage hepatocellular carcinoma in patients with cirrhosis," *Alimentary Pharmacology and Therapeutics*, pp. 37–47, 2009.

[8] T. Stroffolini, P. Andreone, A. Andriulli et al., "Characteristics of hepatocellular carcinoma in Italy," *Journal of Hepatology*, vol. 29, no. 6, pp. 944–952, 1998.

[9] M. Soresi, E. La Spada, L. Giannitrapani, E. Campagna, V. Di Gesaro, and Granà W., "Hepatocellular carcinoma: comparison of two different periods at the same center," *European Journal of Internal Medicine*, vol. 21, pp. 127–130, 2010.

[10] M. Sherman and A. Klein, "AASLD single-topic research conference on hepatocellular carcinoma: conference proceedings," *Hepatology*, vol. 40, no. 6, pp. 1465–1473, 2004.

[11] E. Caturelli, L. Castellano, S. Fusilli et al., "Coarse nodular US pattern in hepatic cirrhosis: risk for hepatocellular carcinoma," *Radiology*, vol. 226, no. 3, pp. 691–697, 2003.

[12] N. Mikami, M. Ebara, M. Yoshikawa, and M. Ohto, "Relationship between ultrasound-findings of low-echoic nodule of hepatic parenchyma in liver cirrhosis and development of hepatocellular carcinoma," *Japanese Journal of Gastroenterology*, vol. 87, no. 4, pp. 1010–1019, 1990.

[13] K. Tarao, H. Hoshino, A. Shimizu et al., "Patients with ultrasonic coarse-nodular cirrhosis who are anti-hepatitis C virus-positive are at high risk for hepatocellular carcinoma," *Cancer*, vol. 75, no. 6, pp. 1255–1262, 1995.

[14] S. Kitamura, H. Iishi, M. Tatsuta et al., "Liver with hypoechoic nodular pattern as a risk factor for hepatocellular carcinoma," *Gastroenterology*, vol. 108, no. 6, pp. 1778–1784, 1995.

[15] F. Azzaroli, A. Colecchia, F. Lodato et al., "A statistical model predicting high hepatocyte proliferation index and the risk of developing hepatocellular carcinoma in patients with hepatitis C virus-related cirrhosis," *Aliment Pharmacol Ther*, vol. 24, pp. 129–136, 2006.

[16] P. Hytiroglou, N. D. Theise, M. Schwartz, E. Mor, C. Miller, and S. N. Thung, "Macroregenerative nodules in a series of adult cirrhotic liver explants: issues of classification and nomenclature," *Hepatology*, vol. 21, no. 3, pp. 703–708, 1995.

[17] R. N. H. Pugh, I. M. Murray Lyon, and J. L. Dawson, "Transection of the oesophagus for bleeding oesophageal varices," *The British Journal of Surgery*, vol. 60, no. 8, pp. 646–649, 1973.

[18] A. E. A. Joseph, S. H. Saverymuttu, S. Al-Sam, M. G. Cook, and J. D. Maxwell, "Comparison of liver histology with ultrasonography in assessing diffuse parenchymal liver disease," *Clinical Radiology*, vol. 43, no. 1, pp. 26–31, 1991.

[19] M. Soresi, L. Giannitrapani, A. M. Florena et al., "Reliability of the bright liver echo pattern in diagnosing steatosis in patients with cryptogenic and HCV-related hypertransaminasaemia," *Clinical Radiology*, vol. 64, no. 12, pp. 1181–1187, 2009.

[20] L. Bolondi, L. Gandolfi, V. Arienti et al., "Ultrasonography in the diagnosis of portal hypertension: diminished response of portal vessels to respiration," *Radiology*, vol. 142, no. 1, pp. 167–172, 1982.

[21] C. Sabbá, C. Merkel, M. Zoli et al., "Interobserver and interequipment variability of echo-doppler examination of the portal vein: effect of a cooperative training program," *Hepatology*, vol. 21, no. 2, pp. 428–433, 1995.

[22] A. Berzigotti and F. Piscaglia, "Ultrasound in portal hypertension–part 1," *Ultraschall in der Medizin*, pp. 548–568, 2011.

[23] E. Giannini, F. Botta, P. Borro et al., "Platelet count/spleen diameter ratio: proposal and validation of a non-invasive parameter to predict the presence of oesophageal varices in patients with liver cirrhosis," *Gut*, vol. 52, no. 8, pp. 1200–1205, 2003.

[24] M. Soresi, D. Noto, A. B. Cefalù et al., "Nonalcoholic fatty liver and metabolic syndrome in Italy: results from a multicentric study of the Italian Arteriosclerosis society," *Acta Diabetologica*, vol. 50, no. 2, pp. 241–249, 2013.

[25] A. Forner, M. E. Reig, C. R. de Lope, and J. Bruix, "Current strategy for staging and treatment: the BCLC update and future prospects," *Seminars in Liver Disease*, vol. 30, no. 1, pp. 61–74, 2010.

[26] J. R. Landis and G. G. Koch, "The measurement of observer agreement for categorical data," *Biometrics*, vol. 33, no. 1, pp. 159–174, 1977.

[27] D. R. Cox, "Regression models and life-tables," *Journal of the Royal Statistical Society*, vol. 34, pp. 187–220, 1972.

[28] E. L. Kaplan and P. Meier, "Nonparametric estimation from incomplete observations," *Journal of the American Statistical Association*, vol. 53, pp. 457–481, 1958.

[29] G. Fattovich, T. Stroffolini, I. Zagni, and F. Donato, "Hepatocellular carcinoma in cirrhosis: incidence and risk factors," *Gastroenterology*, vol. 127, pp. S35-S50, 2004.

[30] R. F. Hanna, V. Z. Miloushev, A. Tang et al., "Comparative 13-year meta-analysis of the sensitivity and positive predictive value of ultrasound, CT, and MRI for detecting hepatocellular carcinoma," *Abdominal Radiology*, vol. 41, no. 1, pp. 71–90, 2016.

[31] J.-C. Trinchet, C. Chaffaut, V. Bourcier et al., "Ultrasonographic surveillance of hepatocellular carcinoma in cirrhosis: A randomized trial comparing 3- and 6-month periodicities," *Hepatology*, vol. 54, no. 6, pp. 1987–1997, 2011.

[32] H. B. El-Serag, "Epidemiology of viral hepatitis and hepatocellular carcinoma," *Gastroenterology*, vol. 142, pp. 1264–1273, 2012.

[33] J.-Y. Choi, J.-M. Lee, and C. B. Sirlin, "CT and MR imaging diagnosis and staging of hepatocellular carcinoma: part I. Development, growth, and spread: key pathologic and imaging aspects," *Radiology*, vol. 272, no. 3, pp. 635–654, 2014.

[34] C. Ripoll, R. J. Groszmann, G. Garcia-Tsao et al., "Hepatic venous pressure gradient predicts development of hepatocellular carcinoma independently of severity of cirrhosis," *Journal of Hepatology*, vol. 50, no. 5, pp. 923–928, 2009.

[35] A. Berzigotti, S. Seijo, U. Arena et al., "Elastography, spleen size, and platelet count identify portal hypertension in patients with compensated cirrhosis," *Gastroenterology*, vol. 144, pp. 102–111, 2013.

[36] M. Buck, G. Garcia-Tsao, R. J. Groszmann et al., "Novel inflammatory biomarkers of portal pressure in compensated cirrhosis patients," *Hepatology*, vol. 59, no. 3, pp. 1052–1059, 2014.

Hindawi
BioMed Research International
Volume 2017, Article ID 8523649, 7 pages
https://doi.org/10.1155/2017/8523649

Review Article

Advances in the Diagnosis and Treatment of Acute Kidney Injury in Cirrhosis Patients

Lei Lei,[1,2] Liangping Li,[2] and Hu Zhang[1]

[1] *Department of Gastroenterology and Hepatology, West China Hospital, Sichuan University, Chengdu, China*
[2] *Department of Gastroenterology and Hepatology, Sichuan Provincial People's Hospital, Chengdu, China*

Correspondence should be addressed to Hu Zhang; zhanghu@scu.edu.cn

Received 3 November 2016; Accepted 22 January 2017; Published 10 May 2017

Academic Editor: Shanhong Tang

Liver cirrhosis is a common progressive and chronic clinical liver disease. Due to the strong compensation ability of the liver, no obvious symptoms develop in the early stage. However, multiple systems are involved in decompensation of the liver. Acute kidney injury (AKI) is one of the most serious complications, characterized by a sharp drop in the glomerular filtration rate (GFR); a rapid increase in Scr and BUN, as well as sodium and water storage; and a disturbance of acid-base balance. The mortality rate is high, and the prognosis is very poor. Thus, it is important to make a definite diagnosis and initiate treatment in the early stage to decrease mortality and improve the prognosis. Although diagnosing liver cirrhosis with serum creatinine has many shortcomings, a dynamic change in this marker is still the main diagnostic criterion for AKI. Identifying new markers of kidney injury with clinical value has also become an increasing focus of research. In this text, we review recent changes regarding categorization of AKI diagnostic criteria as well as new markers of AKI and treatments for cirrhosis-related AKI.

1. Background

Cirrhosis is a common clinical liver disease that is progressive and chronic. Due to the strong compensation ability of the liver, no apparent symptoms develop in the early stage. In contrast, multiple systems are affected in the decompensation stage. Acute kidney injury (AKI) is one of the most serious complications, especially in end-stage liver disease. AKI is characterized by a sharp drop in the glomerular filtration rate (GFR), a rapid increase in Scr and BUN, and increased sodium and water storage.

The etiology of cirrhosis-related AKI is as follows: (1) hypovolemia: an absolute shortage of blood volume, observed in conditions such as hemorrhage, diarrhea, excessive diuresis, and large-volume paracentesis; in contrast, a relative shortage of blood volume results from severe and unique cirrhosis-related abnormities of hemodynamics and nondiuretic, antihypertensive drugs; (2) inflammation: sepsis, including spontaneous bacterial peritonitis (SBP); (3) severe systemic response syndrome, which has separate causes; and (4) use of nephrotoxic drugs such as nonsteroidal anti-inflammatory drugs (NSAIDS), aminoglycosides, and radiographic contrast agents [1].

AKI develops in approximately 19% of hospitalized patients with cirrhosis [2]. It is a key predictive parameter for prognosis [3], suggesting a very poor result for patients with cirrhosis. It is estimated that AKI can increase the likelihood of death at day 30 by almost 10-fold in patients with cirrhosis [4]. Therefore, it is important to make a definitive diagnosis in the early stage and to prescribe appropriate medications to avoid mortality and improve prognosis. It is also necessary to improve our knowledge and understanding of AKI and cirrhosis-related AKI.

2. Diagnostic Criteria for AKI

AKI diagnosis is controversial due to a lack of unified diagnostic criteria [5], although some criteria, such as the RIFLE criteria, AKIN criteria, and KDIGO criteria, have been published. The Acute Dialysis Quality Initiative (ADQI) group first proposed the RIFLE diagnostic criteria in 2004. On the basis of the RIFLE criteria, the Acute Kidney Injury Network

Table 1: Current diagnostic criteria for acute kidney injury (AKI).

Criteria	Diagnostic criteria	Staging
RIFLE criteria	Increase in Scr to ≥1.5 times baseline within 7 days; GFR decrease >25%; or urine volume <0.5 ml/kg/h for 6 h	*Risk*. Scr increase of 1.5–1.9 times baseline; GFR decrease of 25–50%; or urine output < 0.5 ml/kg/h for 6 h *Injury*. Scr increase of 2.0–2.9 times baseline; GFR decrease of 50–75%; or urine output < 0.5 ml/kg/h for 12 h *Failure*. Scr increase ≥3.0 times baseline; GFR decrease of 50–75%; Scr increase ≥4.0 mg/dl (353.6 μmol/L) with an acute increase of at least 0.5 mg/dl (44 μmol/L); urine output < 0.3 ml/kg/h for ≥24 h; or anuria for ≥12 h
AKIN criteria	Increase in Scr by ≥0.3 mg/dl (26.5 μmol/L) within 48 h; increase in Scr ≥ 1.5 times baseline within 48 h; or urine volume < 0.5 ml/kg/h for 6 h	*Stage 1*. Scr increase of 1.5–1.9 times baseline; Scr increase ≥0.3 mg/dl (26.5 μmol/L); or urine output <0.5 ml/kg/h for 6 h *Stage 2*. Scr increase of 2.0–2.9 times baseline or urine output <0.5 ml/kg/h for 12 h *Stage 3*. Scr increase of 3.0 times baseline; Scr increase ≥4.0 mg/dl (353.6 μmol/L) with an acute increase of at least 0.5 mg/dl (44 μmol/L); urine output < 0.3 ml/kg/h for ≥24 h; or anuria for ≥12 h
KDIGO criteria	Increase in Scr by 0.3 mg/dl (26.5 μmol/L) within 48 h; increase in Scr to ≥1.5 times baseline that is known or presumed to have occurred within the previous 7 days; or urine volume < 0.5 ml/kg/h for 6 h	*Stage 1*. Scr increase of 1.5–1.9 times baseline; Scr increase ≥0.3 mg/dl (26.5 μmol/L); or urine output <0.5 ml/kg/h for 6–12 h *Stage 2*. Scr increase of 2.0–2.9 times baseline or urine output < 0.5 ml/kg/h for ≥12 h *Stage 3*. Scr increase of 3.0 times baseline; Scr increase to ≥4.0 mg/dl (353.6 μmol/L); initiation of renal replacement therapy; urine output < 0.3 ml/kg/h for ≥24 h; or anuria for ≥12 h

(AKIN) criteria were established in 2007. Partly based on the AKIN and RIFLE criteria, Kidney Disease: Improving Global Outcomes (KDIGO) published the KDIGO standard for the evaluation and management of AKI in 2012.

RIFLE criteria include parameters present during the whole course of the condition, ranging from kidney injury to end-stage renal failure. The criteria divide AKI into three levels, namely, risk, injury, and failure, according to changes in Scr, GFR, and urine volume. The prognosis of AKI is classified into two levels, namely, loss of renal function and end-stage renal disease (ESRD), based on the time of complete loss of renal function [5]. The RIFLE criteria have good maneuverability, high sensitivity, and high specificity in clinical research and can predict the prognosis of cirrhosis patients with AKI to a certain extent [6]. However, the criteria have some weaknesses; for example, Scr plays the same role as change in urine volume in assessing renal function, and GFR measurement is instable. Given these limitations, AKIN modified the RIFLE criteria and created its own criteria in 2007 to disseminate knowledge of AKI (Table 1).

The AKIN criteria also classify AKI into three stages, namely, dangerous, injury, and failure, but the parameter of GFR is excluded. In addition, the time window defining AKI development is limited to no longer than 48 h, and the threshold of Scr is set to no less than 26.5 μmol/L, with or without a 50% increase from baseline within seven days. The change in the absolute value of Scr is emphasized here to indicate that a slight change in Scr could suggest a severely poor prognosis and that the baseline Scr level is a predictive parameter for renal function reversibility [7] (Table 1).

The KDIGO criteria were formulated on the basis of both the AKIN and RIFLE criteria. Some of the parameters drawn from the AKIN criteria include an increase in Scr ≥ 0.3 mg/dl (26.5 μmol/L) or ≥50% baseline within 48 h and a urine volume < 0.5 mL/kg/h for more than 6 h. The parameters derived from the RIFLE criteria include an increase in Scr ≥ 50% baseline within 7 d or a decrease in GFR > 25% and a urine volume < 0.5 ml/kg/h for more than 6 h. The KDIGO criteria have the strengths of both the RIFLE and AKIN criteria by selectively including various parameters, but their reliability and sensitivity should be further tested in clinical studies [8] (Table 1).

3. Diagnosis of Cirrhosis-Related AKI

AKI has been widely recognized, but AKI in patients with cirrhosis is still a great challenge in clinical practice. The general diagnostic criteria for cirrhosis-related AKI are an increase in Scr ≥ 50% of baseline and >1.5 mg/dl (133 μmol/l). To ensure early diagnosis and good management of AKI, the International Club of Ascites (ICA) created a new definition for cirrhosis-related AKI in 2015 [9] (Table 2).

Table 2: International Club of Ascites (ICA-AKI) 2015 definition for the diagnosis and management of AKI in patients with cirrhosis.

Subject	Definition
Baseline Scr	A Scr value obtained in the previous 3 months, when available, can be used as the baseline Scr. In patients with more than one value within the previous 3 months, the value closest to the admission time to the hospital should be used. In patients without a previous Scr value, the Scr upon admission should be used as the baseline value
Definition of AKI	Increase in Scr ≥ 0.3 mg/dl (≥26.5 μmol/L) within 48 h or a percentage increase in Scr ≥ 50% from baseline that is known or presumed to have occurred within the previous 7 days
Staging of AKI	*Stage 1*. Increase in Scr ≥ 0.3 mg/dl (26.5 μmol/L) or an increase in Scr ≥ 1.5-fold to 2-fold from baseline *Stage 2*. Increase in Scr > 2-fold to 3-fold from baseline *Stage 3*. Increase in Scr > 3-fold from baseline or Scr ≥ 4.0 mg/dl (353.6 μmol/L) with an acute increase ≥0.3 mg/dl (26.5 μmol/L) or initiation of renal replacement therapy
Progression of AKI	*Progression*. Progression of AKI to a higher stage or need for RRT *Regression*. Regression of AKI to a lower stage
Response to treatment	*No Response*. No regression of AKI *Partial Response*. Regression of AKI stage with a reduction of Scr to ≥0.3 mg/dl (26.5 μmol/L) above the baseline value *Full Response*. Return of Scr to a value within 0.3 mg/dl (26.5 μmol/L) of the baseline value

Due to the inaccuracy of urine volume records for cirrhosis patients, a dynamic change in Scr is a key parameter to ensuring an accurate diagnosis [9]. The main differences between the new criteria and the general criteria for cirrhosis patients are as follows [9]. (1) An absolute value of Scr is highlighted. (2) The criterion for the cut-off value of Scr ≥1.5 mg/dl (133 μmol/L) has been removed. (3) The staging system for AKI ensures a good assessment of both the progression stage and the regression stage because it allows a slightly longer time of one week to monitor a change in Scr. In the new ICA criteria for AKI, the urine output criterion has been removed because it is not appropriate for patients with cirrhosis (i.e., many patients with cirrhosis are oliguric but can maintain normal kidney function).

4. Categories of Cirrhosis-Related AKI

AKI can be divided into prerenal azotemia (PRA), acute tubular necrosis (ATN), and hepatorenal syndrome (HRS). Prerenal azotemia (PRA) results from various factors caused by the effective reduction of circulating blood volume. The reduction leads to a decrease in renal perfusion pressure. Consequently, the GFR cannot be maintained at a normal level, but renal tissue integrity is not damaged. If risk factors are removed at an early stage, renal function can be reversed to normal in most patients. Acute tubular necrosis (ATN) results from renal tubular epithelial cell injury/necrosis caused by renal ischemia and/or toxic damage, which leads to a dramatic decline in GFR, severe electrolyte imbalance, water sodium retention, and metabolic acidosis.

The HRS diagnostic criteria devised by the ICA in 1996 [10] are as follows: (1) Scr > 132.6 μmol/L; (2) HRS caused by hypovolemia, ATN, use of nephrotoxic drugs, inflammation, or chronic kidney disease; and (3) HRS divided into type I and type II HRS according to the pace of deterioration. Type I HRS is a special form of AKI and is one of the most serious syndromes of cirrhosis decompensation and acute liver failure [11, 12]. HRS does not respond to fluid expansion. HRS thus has a poor prognosis, even if terlipressin, human albumin, and dialysis are used [12]. Type II HRS is characterized by a slow and progressive decline of renal function and mainly occurs in patients with refractory ascites. The treatment strategy for AKI varies between different types; thus, it is important to make the correct diagnosis. Differential diagnosis is difficult because the clinical characteristics of the two types are similar, and they can convert into one another or coexist.

The HRS criteria were revised in 2007 [13] as follows: (1) cirrhosis with ascites; (2) Scr > 132.6 μmol/L; (3) no decrease in Scr (≤132.6 μmol/L) 2 days after withdrawal of diuretics and expansion with albumin; (4) recommended albumin dosage of 1 g/(kg∗d) and maximum dosage of 100 g/d; (5) no shock history; (6) no recent use of nephrotoxic drugs; and (7) no albuminuria (>500 mg/d), no microscopic hematuria (urine RBC > 500/HP), and no renal parenchymal disease detected by ultrasonic examination. Further modification of the diagnostic criteria for HRS-related AKI was performed by the ICA in 2015. The use of Scr > 132.6 μmol/L was removed, and AKI was defined as an absolute increase in Scr ≥ 0.3 mg/dL (26.5 μmol/L) or ≥50% from baseline within 7 days.

5. Assessment of Renal Function

5.1. Traditional Markers Used to Assess Renal Function. Scr is the most practical and agreed upon biomarker for the

assessment of renal function in cirrhosis patients [14], and it is the primary marker with which all types of renal failure can be predicted. However, there are some limitations to using Scr; namely, it may be normal or slightly increased because of high compensation and renal tubular secretion of creatinine in the presence of apparent kidney injury. These factors can lead to a delay in obtaining the correct diagnosis and initiating early management. Malnutrition exists in 67% of patients with cirrhosis, and production of creatinine from creatine decreases in muscles secondary to muscle wasting; therefore, Scr may be normal even if GFR is very low. The ability of this marker to assess renal function is much poorer. It can be influenced by some nonkidney factors, such as age, gender, race, prerenal factors, metabolism, and nutrition. The lab value of Scr may be lower than its actual value in patients with hyperbilirubinemia [15]. Furthermore, Scr cannot reveal the cause of AKI, so it is not a sufficiently sensitive marker to assess cirrhosis with AKI at an early stage and is therefore not ideal.

GFR is currently the best indicator of renal function. Clinically, MDRD and the Cockcroft Gault formula are used to assess GFR in the general population. Nevertheless, both overestimate GFR in cirrhosis patients [14]. Furthermore, although MDRD has more advantages regarding its use in the assessment of GFR in cirrhosis patients, its accuracy is much lower than that in noncirrhosis patients. The Cockcroft Gault formula is greatly influenced by weight, so it is not used for cirrhosis patients with edema and ascites [16].

Urine volume is a key marker for assessing kidney injury [14]. However, it is controversial to consider urine volume in patients with decompensated liver cirrhosis. Urine volume is affected by many factors, and its specificity is not high. For example, urine volume is normal in patients with nonoliguric AKI, despite the fact that their kidneys are severely damaged. Thus, urine volume has not been suggested for inclusion in the new ICA criteria for AKI diagnosis.

5.2. Emerging Markers to Assess Renal Function. Scr is still one of the main diagnostic criteria for AKI, although it has some disadvantages [9]. In particular, a dynamic change in Scr is a key criterion for cirrhosis-related AKI patients. The treatment strategy significantly differs among cases of AKI with different causes, so identification of the causal factors for AKI, while challenging, is very important. New biomarkers of kidney injury can distinguish structural AKI from functional AKI, which is very helpful for making a quick and accurate diagnosis. Several new markers have become topics of research, with studies mainly focused on CysC (Cystatin c), KIM-1 (kidney injury molecule 1), and NGAL (neutrophil gelatinase associated lipocalin). Reports from Europe and the United States have revealed that the combined application of NEGL or urine biomarkers [9], such as NGAL, KIM-1, and proteinuria, is potentially helpful for the differential diagnosis of cirrhosis-related AKI, but this should be further explored.

CysC is eliminated only through the kidney, and minor kidney damage could lead to a change in CysC [17]. Serum CysC concentration is mainly determined by GFR. If the GFR decreases by 20%, CysC will increase, so CysC is a reflection of early changes in ideal endogenous markers of GFR. A growing number of reports have demonstrated that CysC can be used as a marker for AKI assessment and prognosis [17]. Furthermore, CysC is not typically affected by age, gender, race, or weight; more specifically, it cannot be disturbed by hyperbilirubinemia. The sensitivity and specificity are 66% and 86%, respectively, when CysC > 1.23 mg/L. It is also a good predictive indicator of short-term mortality.

KIM-1 is a unique and sensitive biomarker for early kidney injury [18]. KIM-1 is a type I transmembrane glycoprotein that contains immunoglobulin and a mucin domain. KIM-1 is expressed at a very low level in normal kidney tissues. It can exhibit high expression in dedifferentiated and proliferative renal tubule epithelium after kidney injury, but it is not detectable in totally atrophic tubular epithelia. KIM-1 is related to early injury and restoration of renal tubular epithelia. It is a new, noninvasive, and sensitive marker for early diagnosis of AKI, which is more specific and less susceptible to other factors, such as urinary tract infection (only at the urine test level). However, the detection of KIM-1 has not been standardized, and its independent value as a predictor of severe AKI is unclear [18].

NGAL is a new member of the lipocalin family. It has been reported that cisplatin, which can lead to renal tubular necrosis after intraperitoneal injection at a high dosage, can quickly induce the expression of kidney NGAL and its secretion from renal tubular cells [19]. NGAL, which is expressed in injured renal tubules and can induce epithelial regeneration, enters the blood within 2 h after injury and is excreted through urine. A study of 132 cirrhosis patients by Barreto et al. revealed that [20] the urine NGAL level in AKI patients was significantly higher than that in patients without AKI, and the NGAL level in consecutive AKI patients was significantly higher than that in temporary AKI patients. Thus, NGAL could be used to distinguish HRS from renal failure caused by other factors. Verna et al. reported [21] that the sensitivity and specificity of nonprerenal AKI diagnosis were 88% and 85%, respectively, when the urine NGAL density was 110 ng/mL. NGAL could predict the irreversibility of kidney function injury individually, so it might also predict mortality (which is independent of other risk factors) [22]. However, NGAL can be affected by systemic inflammation, and it is difficult to detect urine NGAL in oliguric and anuric patients.

6. Prevention and Treatment of Cirrhosis-Related AKI

6.1. General Treatment. Based on the ICA-AKI diagnostic criteria proposed for AKI in 2015 [9], we recommend that patients with cirrhosis and ascites who are in initial ICA-AKI stage 1 be managed as soon as possible with the following measures: (1) drug chart review, including review of all medications, reduction or withdrawal of diuretic therapy, and withdrawal of all potentially nephrotoxic drugs, vasodilators, or NSAIDs; (2) plasma volume expansion in patients with clinically suspected hypovolemia; and (3) prompt recognition and early treatment of bacterial infections when diagnosed or strongly suspected.

6.2. Drug Treatment. When AKI is characterized by an initial ICA-AKI stage 2 or 3 or by progression of the initial stage despite general therapeutic measures, patients who meet all the other diagnostic criteria for HRS should be placed on vasoconstrictors and albumin [9], irrespective of the final value of Scr. Vasoconstrictors can ameliorate vasodilatation in HRS patients, improve effective arterial blood volume (EABV), and ameliorate renal vasoconstriction and renal blood flow. Frequently used vasoconstrictors include terlipressin, midodrine, and noradrenaline. Continuous infusion is not required for terlipressin, and it has a low incidence of adverse effects; these advantages make it the first choice among vasoconstrictor analogues. Albumin can be combined with a vasodilator and can expand blood volume. As recommended by the European Association for the Study of the Liver (ESAL) [23] in 2010, terlipressin in combination with albumin should be considered the first-line therapeutic agent for type 1 HRS. The aim of this therapy is to improve renal function sufficiently to decrease Scr to <133 μmol/l. Terlipressin plus albumin is effective in 60–70% of patients with type 2 HRS. If serum creatinine does not decrease by at least 25% after 3 days, the dosage of terlipressin should be increased in a stepwise manner up to a maximum of 2 mg/4 h. For patients with a partial response (serum creatinine does not decrease to <133 μmol/L) or for those with no reduction of serum creatinine, treatment should be discontinued within 14 days. Albumin at 1 g/kg per day up to a maximum of 100 g/day over 2 days is recommended for HRS patients, with a subsequent change to 20–40 g/d. Terlipressin (0.5–2.0 mg, iv, once every 4–6 days) is given in combination with albumin. If the Scr level does not decrease, the dosage should be increased every few days up to the maximum dosage of 12 mg/d without adverse effects. The longest course should be 14 days.

It is reported [24] that the higher the initial Scr, the lower the response to terlipressin. Terlipressin in combination with albumin should be considered early when the Scr of a cirrhosis patient is higher than baseline and meets the AKI diagnostic criteria. There is no need to wait until the Scr level is higher than the ULN (>1.5 mg/dl). All AKI patients regardless of progression stage should be placed on vasoconstrictors if there is no obvious evidence of ATN or other renal diseases [3].

Transjugular intrahepatic portosystemic shunt (TIPS) has been reported to improve renal function in patients with decompensated cirrhosis and can also decrease their Scr [13, 25]. TIPS can improve refractory ascites, variceal bleeding, refractory hepatic pleural effusion, hepatorenal syndrome, refractory ascites, and variceal hemorrhage, which are the appropriate indications. Zhang and Zhao [26] reported that Scr was improved 7 days after TIPS and decreased to a normal level after 90 days if the Scr baseline was no more than 2 mg/dl, but the posttherapy MELD score was not significantly different from the score before therapy. If the Scr at baseline was more than 2 mg/dl, the Scr and MELD score were significantly improved after TIPS. Nie et al. reported [27] that TIPS can improve Scr and has a good effect on hemostasis with a low incidence of complications in addition to favorable clinical effects and a high safety rating. However, in clinical practice, attention should be paid to the following contraindications: Child-Pugh > 11 points, severe liver failure serum bilirubin > 5 mg/dl, severe cardiopulmonary dysfunction, severe coagulopathy, uncontrolled intrahepatic or systemic infection, biliary obstruction, portal vein cavernous transformation, and polycystic liver [16].

Renal replacement therapy (RRT) is important for AKI patients with decompensated cirrhosis. It can improve short-term survival and provide a basis for liver transplantation. Zhang et al. [28] reported on 284 severe AKI patients who were enrolled and received consecutive RRT. Renal function was recovered in 89 cases (31.33%). The incidence of chronic kidney disease in patients whose renal function was recovered was lower than that in patients whose renal function was not recovered. Moreover, the APACHE II score and organ failure number were relatively lower in patients whose renal function was recovered. These data suggest that complications, APACHE II score, and organ failure number are the key factors in RRT for AKI patients. In practice, the status of illness should be addressed in real time and RRT should be prescribed for patients as soon as possible, which can accelerate renal function recovery and improve survival.

Liver transplantation is one of the most important treatment strategies to improve the prognosis of ATN, which has the effect of improving survival and quality of life [24, 29]. Scr level before transplantation is an important predictive factor for mortality or renal dysfunction after surgery [30]. Therefore, renal function should be improved before surgery to improve outcomes and prevent renal failure [30, 31]. The incidence of renal failure after liver transplantation has decreased to 20% over time [32]. Liver transplantation for decompensated cirrhosis patients with AKI has been given increasing attention.

7. Conclusion

Cirrhosis-related AKI is caused by many factors and has high morbidity and mortality rates, so identifying the key causal factors is critical. The diagnostic criteria fo cirrhosis-related AKI proposed by the ICA are the preferred choice for diagnosing AKI in cirrhosis. The assessment of renal function should be completed with traditional and emerging markers. A dynamic change in Scr is one of the most important diagnostic criteria, although it has some limitations. The exploration of new diagnostic markers has become a popular focus of research. Some treatments are currently available, such as removal of incentives, drug therapy, TIPS, and RPT. Liver transplantation is a good choice for refractory patients. It is imperative to make an early diagnosis and provide appropriate treatment for these patients to achieve a better outcome. A multicenter, prospective study with a large cohort of cirrhosis-related AKI patients that uses uniform criteria is warranted to elucidate the key causes of AKI and to develop better individual prevention and treatment strategies.

Disclosure

Lei Lei and Hu Zhang are co-first authors.

Conflicts of Interest

There are no conflicts of interest.

References

[1] L. Yu, M. Wang, and C. He, "Progress in diagnosis and treatment of acute renal injury in cirrhosis," *Infectious Disease Information*, vol. 27, no. 02, pp. 69–73, 2014.

[2] G. Garcia-Tsao, C. R. Parikh, and A. Viola, "Acute kidney injury in cirrhosis," *Hepatology*, vol. 48, no. 6, pp. 2064–2077, 2008.

[3] J. M. Belcher, G. Garcia-Tsao, A. J. Sanyal et al., "Association of AKI With mortality and complications in hospitalized patients with cirrhosis," *Hepatology*, vol. 57, no. 2, pp. 753–762, 2013.

[4] F. Wong, J. G. O'Leary, K. R. Reddy et al., "New consensus definition of acute kidney injury accurately predicts 30-day mortality in patients with cirrhosis and infection," *Gastroenterology*, vol. 145, no. 6, pp. 1280–1288.e1, 2013.

[5] R. Bellomo, C. Ronco, J. A. Kellum, R. L. Mehta, and P. Palevsky, "Acute renal failure—definition, outcome measures, animal models, fluid therapy and information technology needs: the Second International Consensus Conference of the Acute Dialysis Quality Initiative (ADQI) Group," *Critical Care*, vol. 8, no. 4, pp. R204–R212, 2004.

[6] P. M. Palevsky, K. D. Liu, P. D. Brophy et al., "KDOQI US commentary on the 2012 KDIGO clinical practice guideline for acute kidney injury," *American Journal of Kidney Diseases*, vol. 61, no. 5, pp. 649–672, 2013.

[7] R. L. Mehta, J. A. Kellum, S. V. Shah et al., "Acute Kidney Injury Network: report of an initiative to improve outcomes in acute kidney injury," *Critical Care*, vol. 11, no. 2, p. R31, 2007.

[8] J. A. Kellum, N. Lameire, P. Aspelin et al., "Kidney disease: improving global outcomes (KDIGO) acute kidney injury work group. KDIGO clinical practice guideline for acute kidney injury," *Kidney International Supplements*, vol. 2, supplement 1, pp. 1–138, 2012.

[9] P. Angeli, P. Ginès, F. Wong et al., "Diagnosis and management of acute kidney injury in patients with cirrhosis: revised consensus recommendations of the International Club of Ascites," *Journal of Hepatology*, vol. 62, no. 4, pp. 968–974, 2015.

[10] V. Arroyo, P. Ginès, A. L. Gerbes et al., "Definition and diagnostic criteria of refractory ascites and hepatorenal syndrome in cirrhosis," *Hepatology*, vol. 23, no. 1, pp. 164–176, 1996.

[11] M. Hartleb and K. Gutkowski, "Kidneys in chronic liver diseases," *World Journal of Gastroenterology*, vol. 18, no. 24, pp. 3035–3049, 2012.

[12] C. Francoz and F. Durand, "A new look at renal dysfunction in the cirrhotic patient," *Critical Care*, vol. 16, no. 2, article 118, 2012.

[13] F. Salerno, A. Gerbes, P. Ginès, F. Wong, and V. Arroyo, "Diagnosis, prevention and treatment of hepatorenal syndrome in cirrhosis," *Gut*, vol. 56, no. 9, pp. 1310–1318, 2007.

[14] J. Cai and T. Han, "Diagnosis and treatment of acute renal injury in patients with liver cirrhosis," *Chinese Journal of Clinical Hepatology*, vol. 30, no. 12, pp. 1352–1356, 2014.

[15] M. L. Knapp and O. Hadid, "Investigations into negative interference by jaundiced plasma in kinetic Jaffe methods for plasma creatinine determination," *Annals of Clinical Biochemistry*, vol. 24, no. 1, pp. 85–97, 1987.

[16] M. K. Nadim, J. A. Kellum, A. Davenport et al., "Hepatorenal syndrome: the 8th international consensus conference of the Acute Dialysis Quality Initiative (ADQI) Group," *Critical Care*, vol. 16, no. 1, article R23, 2012.

[17] S. Jia, S. Liu, L. Zhou et al., "The significance of serum cystatin C in the early diagnosis of chronic renal failure in the elderly," *China Diagnostics*, vol. 17, no. 10, pp. 1834–1836, 2013.

[18] N. Obermüller, H. Geiger, C. Weipert, and A. Urbschat, "Current developments in early diagnosis of acute kidney injury," *International Urology and Nephrology*, vol. 46, no. 1, pp. 1–7, 2014.

[19] J. Mishra, K. Mori, Q. Ma, C. Kelly, J. Barasch, and P. Devarajan, "Neutrophil gelatinase-associated lipocalin: a novel early urinary biomarker for cisplatin nephrotoxicity," *American Journal of Nephrology*, vol. 24, no. 3, pp. 307–315, 2004.

[20] R. Barreto, C. Elia, E. Solà et al., "Urinary neutrophil gelatinase-associated lipocalin predicts kidney outcome and death in patients with cirrhosis and bacterial infections," *Journal of Hepatology*, vol. 61, no. 1, pp. 35–42, 2014.

[21] E. C. Verna, R. S. Brown, E. Farrand et al., "Urinary neutrophil gelatinase-associated lipocalin predicts mortality and identifies acute kidney injury in cirrhosis," *Digestive Diseases and Sciences*, vol. 57, no. 9, pp. 2362–2370, 2012.

[22] F. Åberg, M. Lempinen, M. Hollmén, A. Nordin, H. Mäkisalo, and H. Isoniemi, "Neutrophil gelatinase-associated lipocalin associated with irreversibility of pre-liver transplant kidney dysfunction," *Clinical Transplantation*, vol. 28, no. 8, pp. 869–876, 2014.

[23] European Association for the Study of the Liver, "EASL clinical practice guidelines on the management of ascites, spontaneous bacterial peritonitis, and hepatorenal syndrome in cirrhosis," *Journal of Hepatology*, vol. 53, no. 3, pp. 397–417, 2010.

[24] S. B. Hiremath and L. D. Srinivas, "Survival benefits of terlipressin and non-responder state in hepatorenal syndrome: a meta-analysis," *Indian Journal of Pharmacology*, vol. 45, no. 1, pp. 54–60, 2013.

[25] J. Muciño-Bermejo, R. Carrillo-Esper, M. Uribe, and N. Méndez-Sánchez, "Acute kidney injury in critically ill cirrhotic patients: a review," *Annals of Hepatology*, vol. 11, no. 3, pp. 301–310, 2012.

[26] Z. Zhang and Y. Zhao, "Decompensated cirrhosis in patients with acute kidney injury-related risk factors," *China's Modern Drug Application*, vol. 9, no. 9, pp. 39–40, 2015.

[27] X. Nie, Y. He, and G. Li, "Hepatorenal syndrome and hepatic encephalopathy," *Chinese Journal of Laboratory Diagnosis*, vol. 16, no. 3, pp. 475–478, 2012.

[28] L. Zhang, C. Xing, L. Xie et al., "Factors of renal function recovery in patients with severe acute renal injury treated by continuous renal replacement therapy," *Advances in Modern Biomedicine*, vol. 14, no. 8, pp. 1490–1493, 2014.

[29] M. S. Campbell, D. S. Kotlyar, C. M. Brensinger et al., "Renal function after orthotopic liver transplantation is predicted by duration of pretransplantation creatinine elevation," *Liver Transplantation*, vol. 11, no. 9, pp. 1048–1055, 2005.

[30] R. Ruiz, H. Kunitake, A. H. Wilkinson et al., "Long-term analysis of combined liver and kidney transplantation at a single center," *Archives of Surgery*, vol. 141, no. 8, pp. 735–741, 2006.

[31] P. Angeli, A. Sanyal, S. Moller et al., "Current limits and future challenges in the management of renal dysfunction in patients

with cirrhosis: report from the International Club of Ascites," *Liver International*, vol. 33, no. 1, pp. 16–23, 2013.

[32] X. Wu and F. Su, "Decompensated cirrhosis in patients with acute kidney injury-related risk factors," *Journal of Practical Hepatology*, vol. 17, no. 4, pp. 360–363, 2014.

Hindawi
BioMed Research International
Volume 2017, Article ID 2067479, 8 pages
https://doi.org/10.1155/2017/2067479

Research Article

Magnetic Resonance Elastography Shear Wave Velocity Correlates with Liver Fibrosis and Hepatic Venous Pressure Gradient in Adults with Advanced Liver Disease

Ahmed M. Gharib,[1] Ma Ai Thanda Han,[2] Eric G. Meissner,[3,4,5] David E. Kleiner,[6] Xiongce Zhao,[7] Mary McLaughlin,[3] Lindsay Matthews,[3] Bisharah Rizvi,[2] Khaled Z. Abd-Elmoniem,[1] Ralph Sinkus,[8] Elliot Levy,[9] Christopher Koh,[2] Robert P. Myers,[10] G. Mani Subramanian,[10] Shyam Kottilil,[3] Theo Heller,[2] Joseph A. Kovacs,[4] and Caryn G. Morse[4]

[1] *National Institute of Diabetes and Digestive and Kidney Diseases, Biomedical and Metabolic Imaging Branch, Bethesda, MD, USA*
[2] *National Institute of Diabetes and Digestive and Kidney Diseases, Liver Diseases Branch, Bethesda, MD, USA*
[3] *Laboratory of Immunoregulation, National Institute of Allergy and Infectious Diseases, Bethesda, MD, USA*
[4] *Critical Care Medicine Department, NIH Clinical Center, AIDS Section, Bethesda, MD, USA*
[5] *Division of Infectious Diseases, Department of Microbiology and Immunology, Medical University of South Carolina, Charleston, SC, USA*
[6] *Laboratory of Pathology, National Cancer Institute, Bethesda, MD, USA*
[7] *National Institute of Diabetes and Digestive and Kidney Diseases, Office of the Director, Bethesda, MD, USA*
[8] *Biomedical Engineering, Imaging Sciences and Biomedical Engineering Division, Kings College, London, UK*
[9] *Interventional Radiology, NIH Clinical Center, Bethesda, MD, USA*
[10] *Gilead Sciences, Inc., Foster City, CA, USA*

Correspondence should be addressed to Caryn G. Morse; cmorse@cc.nih.gov

Received 10 January 2017; Accepted 20 March 2017; Published 5 April 2017

Academic Editor: Fernando Romeiro

Background. Portal hypertension, an elevation in the hepatic venous pressure gradient (HVPG), can be used to monitor disease progression and response to therapy in cirrhosis. Since obtaining HVPG measurements is invasive, reliable noninvasive methods of assessing portal hypertension are needed. *Methods.* Noninvasive markers of fibrosis, including magnetic resonance elastography (MRE) shear wave velocity, were correlated with histologic fibrosis and HVPG measurements in hepatitis C (HCV) and/or HIV-infected patients with advanced liver disease enrolled in a clinical trial of treatment with simtuzumab, an anti-LOXL2 antibody. *Results.* This exploratory analysis includes 23 subjects: 9 with HCV monoinfection, 9 with HIV and HCV, and 5 with HIV and nonalcoholic steatohepatitis. Median Ishak fibrosis score was 4 (range 1–6); 11 subjects (48%) had cirrhosis. Median HVPG was 6 mmHg (range 3–16). Liver stiffness measured by MRE correlated with HVPG ($r = 0.64$, $p = 0.01$), histologic fibrosis score ($r = 0.71$, $p = 0.004$), noninvasive fibrosis indices, including APRI ($r = 0.81$, $p < 0.001$), and soluble LOXL2 ($r = 0.82$, $p = 0.001$). On stepwise multivariate regression analysis, MRE was the only variable independently associated with HVPG ($R^2 = 0.377$, $p = 0.02$). *Conclusions.* MRE of the liver correlated independently with HVPG. MRE is a valid noninvasive measure of liver disease severity and may prove to be a useful tool for noninvasive portal hypertension assessment. *Trial Registration Number*. This trial is registered with NCT01707472.

1. Background

Chronic liver injury with progressive hepatic fibrosis can result in cirrhosis, a leading cause of morbidity and mortality worldwide [1]. Portal hypertension, defined as increased pressure within the portal venous system, contributes to the serious complications of end stage liver disease, including

gastroesophageal varices and ascites. The established standard for diagnosing portal hypertension is transjugular measurement of the hepatic venous portal gradient (HVPG), the difference between wedged and free hepatic venous pressures. HVPG measurements are utilized in managing liver disease for prognostication, monitoring of progression, and measuring response to therapy [2–5]. However, HVPG measurements are invasive, costly, and often available only at referral centers [6].

Identifying reliable noninvasive markers of portal hypertension would improve clinical ability to determine disease status and monitor fibrosis progression with reduced risk compared with HVPG measurements. A number of laboratory tests and laboratory indices have been evaluated as noninvasive markers of portal hypertension, including platelet count, prothrombin time, and aspartate aminotransferase platelet ratio (APRI); however these markers cannot reliably predict the presence of varices or serve as surrogates for HVPG [7].

Conventional imaging modalities have been used to support a diagnosis of cirrhosis and portal hypertension but have limited utility for confirming the presence of fibrosis or for the longitudinal assessment of portal hypertension [8–10]. Ultrasound-based vibration-controlled transient elastography (VCTE; Fibroscan) can predict advanced fibrosis and cirrhosis and correlates with HVPG [11]. Liver stiffness measured by VCTE predicts clinical decompensation and complications of portal hypertension [12]. However, VCTE is limited by operator dependence, small sampling window, and unreliability in patients with abdominal obesity or ascites [13].

Magnetic resonance elastography (MRE) is now available as an alternative method for determining liver stiffness. MRE can accurately detect both early and advanced fibrosis [14] and predict the presence of esophageal varices [15]. MRE can be successfully performed in most patients, including those with ascites, anatomical variants, and liver transplant recipients [16]. The accuracy of MRE appears to be superior to VCTE [17, 18], though the number of clinical studies that compare the two methods is small. The use of MRE of the liver in assessment of portal hypertension has been explored in animal models [19]; however studies in humans are limited to the detection of clinical manifestations of portal hypertension, such as the development of esophageal varices [20].

In this prospective, exploratory study, we assessed the accuracy of noninvasive fibrosis biomarkers and MRE shear wave velocity for the diagnosis of fibrosis and portal hypertension in a cohort of hepatitis C (HCV) and/or human immunodeficiency virus- (HIV-) infected liver disease patients. Participants were evaluated as part of a clinical trial evaluating the safety and efficacy of simtuzumab (Gilead Sciences, Inc., Foster City, CA), a humanized monoclonal antibody that inhibits lysyl oxidase-like 2 (LOXL2), an enzyme that contributes to liver fibrosis by catalyzing collagen cross-linkage.

2. Methods

2.1. Patient Population. Adults 18 years of age or older, with HIV, HCV, or HIV/HCV, were enrolled from October 2012 to December 2014. HCV infection was confirmed by measurement of HCV RNA >2,000 IU/mL. For HIV-infected subjects, an HIV viral load <400 copies/mL on stable combination antiretroviral therapy for ≥3 months was required. Patients with known cirrhosis could participate if they were Child-Pugh class A [21].

The NIAID Institutional Review Board approved the study. All participants provided written informed consent (NCT01707472). The primary study results are reported elsewhere [22].

2.2. Transjugular Liver Biopsy with Portal Pressure Measurements. HVPG measurements were obtained during transjugular liver biopsy. The left, middle, and right hepatic veins were cannulated and the free hepatic vein pressure (FHVP) and the wedged hepatic venous pressure (WHVP) were assessed. The WHVP was measured within each hepatic vein branch with gentle inflation of a balloon occlusion catheter. HVPG was calculated by subtracting the FHVP from the WHVP. Peak HVPG is reported and used for analysis.

2.3. Histology. Formalin-fixed paraffin-embedded liver biopsy sections were stained with hematoxylin and eosin, Masson's trichrome, or reticulin and interpreted by a single liver pathologist (DEK). Inflammatory activity and fibrosis were scored using the modified histology activity index (Ishak) scoring system [23]. Steatosis was graded on a scale of 0 to 3 based on the percentage of cells with fat according to the NASH-Clinical Research Network scoring system [24]. Stellate cell activation was quantified by immunohistochemical staining for activated smooth muscle actin [25] (Inova Health Systems, Falls Church, VA).

2.4. Magnetic Resonance Elastography. The imaging protocol for magnetic resonance elastography (MRE) has been described previously [26]. Briefly, MR examination was performed on a 3.0T system (Achieva, Philips Medical Systems, Best, Netherlands) using 32-element surface coil. A mechanical transducer set at vibration frequency of 56 Hz was placed against the supine subjects' side at the lowest right rib in the right-left direction. An operator blinded to participant clinical status performed image processing to provide shear wave speed in m/sec.

2.5. Laboratory Markers of Fibrosis. Platelet counts, liver-associated enzymes including alkaline phosphatase, aspartate aminotransferase (AST), alanine aminotransferase (ALT), and gamma-glutamyl transferase (GGT), and noninvasive estimators of liver fibrosis validated in similar liver disease populations, including the APRI [27], FIB-4 [28], Forns [29], and Fibroindex [30], were determined at the time of liver biopsy.

2.6. Soluble LOXL2. Soluble LOXL2 (sLOXL2) concentrations were measured in serum using a proprietary immunoassay (Singulex, Alameda, CA).

2.7. Hepatic LOXL2 Gene Expression. In a subset of participants ($n = 12$), total RNA isolated from liver was reverse

transcribed using random primers with the High Capacity cDNA Reverse Transcriptase Kit (ThermoFischer Scientific, Waltham, MA), as previously described [22, 31]. Gene expression was determined as cycle of threshold (Ct) based on 40 PCR cycles, using expression of *GAPDH* and *GUSB* as endogenous controls to determine delta Ct values. *GAPDH* Ct values were distributed between 23 and 27. Data from 2 samples was excluded from analysis due to inadequate signal strength, defined as a *GAPDH* Ct value >27. Thus, confirmatory qRT-PCR data are presented from 10 of 12 subjects. Expression reactions using predesigned Taqman assays assembled into custom-designed 96-well plates (ThermoFischer Scientific) were run on an Applied Biosystems 7500 Real-Time PCR System, as previously described [31].

2.8. Statistical Analysis. Pairwise correlations between biomarkers of interest were evaluated with Spearman's correlation coefficient. For this exploratory analysis, a p value of ≤0.05, without adjustment for multiple comparisons, was considered statistically significant. Simple linear regression was employed to screen for biomarkers associated with HVPG. Biomarkers with a p value ≤0.15 from the simple linear regressions were identified as potential candidates. Backward stepwise multiple regression analysis was performed on HVPG using the candidate biomarkers. Stepwise variable elimination was based on a threshold p value of ≤0.15. Analyses were performed using JMP v.11 (SAS, Cary, NC, USA).

2.9. Data Availability. Datasets analyzed for the current study are available from the corresponding author on request.

3. Results

3.1. Baseline Demographic and Clinical Characteristics. Twenty-three patients completed the screening evaluation. Demographic and clinical characteristics of the cohort are shown in Table 1. The median age was 57 years (range 45–76 years) and 78% of participants were males. HCV was present in 18 (78%), 9 of whom had HIV coinfection. Sixteen (89%) of the HCV-infected participants were genotype 1. Five (22%) participants had HIV infection and nonalcoholic steatohepatitis (NASH) [24].

Liver biopsy size ranged from 6 to 24 mm, median 12 mm. Six (26%) of samples were <10 mm and therefore considered suboptimal for staging and grading [32].

Median Ishak fibrosis score was 4 (range 1–6) and 11 participants (48%) had cirrhosis, all Child-Pugh class A. Median HVPG was 8 mmHg (range 3–16 mmHg) and HVPG was ≥10 mmHg in 8 (35%) participants.

3.2. Correlates of HVPG. HVPG (n = 23) correlated positively with AST (r = 0.48, p = 0.01) and GGT (r = 0.62, p = 0.001) and negatively correlated with platelets (r = −0.72, p = 0.002). No significant correlation was seen between HVPG and ALT (Table 2).

While HVPG correlated with liver biopsy fibrosis score (r = 0.52, p = 0.04), HVPG demonstrated a better correlation with Forns' Index (r = 0.76, p < 0.001), Fibroindex (r = 0.75, p = 0.001), and APRI (r = 0.59, p = 0.02). (Table 2).

Stepwise regression analysis, including AST, GGT, platelets, liver biopsy fibrosis score, and MRE, identified MRE as the only biomarker independently associated with HVPG (R^2 = 0.377, p = 0.015).

3.3. Correlates of MRE. MRE was completed in 15 participants (3 HCV, 7 HIV/HCV, and 5 HIV/NASH). Median shear wave velocity was 2.13 m/sec (range 1.25–3.03 m/sec). MRE correlated significantly with HVPG (r = 0.64, p = 0.009; Figure 1), as well as with Ishak fibrosis score (r = 0.71, p = 0.003), total histologic activity index (HAI) inflammation (r = 0.64, p = 0.01), periportal inflammation (r = 0.72,

Table 1: Baseline demographic and clinical characteristics of study subjects (n = 23).

Parameter	
Age, years	54 (45–76)
Male, n (%)	18 (78%)
Liver disease etiology, n (%)	
HCV	9 (39%)
HCV/HIV	9 (39%)
HIV/NASH	5 (22%)
Body mass index, kg/m^2	30 (21–46)
>30 kg/m^2 (obesity), n (%)	12 (52%)
Laboratory studies	
Platelets, K/uL	159 (45–284)
Alkaline phosphatase, U/L	107 (51–210)
Aspartate aminotransferase (AST), U/L	56 (22–151)
Alanine aminotransferase (ALT), U/L	77 (30–161)
Total bilirubin, mg/dL	0.8 (0.3–2.3)
Direct bilirubin, mg/dL	0.3 (0.1–1.4)
Gamma-glutamyl transferase (GGT), U/L	150 (19–531)
Albumin, g/dL	4.1 (3.0–5.5)
Prothrombin time (PT), seconds	14.3 (12.3–16.4)
International normalized ratio (INR)	1.1 (0.9–1.3)
Hepatitis C characteristics (n = 18)	
HCV viral load, log 10, IU/mL	6.9 (4.7–7.8)
Hepatitis C genotype, n (%)	
1a	13 (72)
1b	3 (17)
2	1 (6)
4	1 (6)
MRE shear wave velocity, m/sec (n = 15)	2.13 (1.25–3.03)
HVPG, mmHg	6 (3–16)
Liver biopsy length, mm	12 (6–24)
<10 mm, n (%)	6 (26)
Liver biopsy scoring	
Fibrosis, Ishak (range 0–6)	4 (1–6)
Inflammation, total HAI (range 0–18)	8 (1–14)
Steatosis (range 0–4)	1 (0–2)

Median, range presented unless otherwise noted.

Table 2: Correlation coefficients (Spearman ρ) for selected variables*.

	MRE shear wave velocity	HVPG	Ishak fibrosis score	sLOXL2
MRE shear wave velocity (n = 15)		*0.64*	0.71	0.82
HVPG (n = 23)	*0.64*		0.53	*0.58*
Liver biopsy (n = 23)				
Ishak fibrosis score	0.71	0.53		0.31
Total HAI inflammation score	*0.64*	*0.49*	0.36	0.30
% alpha smooth muscle actin (αSMA)	0.74	*0.50*	*0.51*	0.08
Selected laboratory studies (n = 23)				
Platelets	−0.70	−0.72	*−0.47*	*−0.57*
Aspartate aminotransferase (AST)	0.74	*0.50*	0.55	0.70
Alanine aminotransferase (ALT)	0.28	0.13	*0.42*	0.24
Gamma-glutamyl transferase (GGT)	0.43	0.63	0.56	0.28
Non-invasive fibrosis indices (n = 23)				
APRI	**0.81**	0.57	0.57	**0.72**
FIB-4	0.67	**0.66**	*0.44*	0.71
Forns' index	0.71	**0.76**	0.44	*0.60*
Fibroindex	0.75	**0.75**	0.40	**0.80**
Serum soluble LOXL2 (n = 23)	0.82	*0.58*	0.31	
Liver LOXL2 (n = 10)	*0.86*[a]	*0.69*	0.18	0.31

MRE: magnetic resonance elastography; HVPG: hepatic venous pressure gradient; HAI: histologic activity index; APRI: AST/platelet ratio index; LOXL2: lysyl oxidase-like 2.
[a]MRE and liver LOXL2 results available for 8 participants.
* p values are indicated as follows: *Italics*, 0.01–0.05; Underlined, 0.001–<0.01; **Bold**, <0.001.

p = 0.002), lobular inflammation (r = 0.8, p = 0.002), and αSMA (r = 0.70, p = 0.008) (Table 2).

Furthermore, MRE had a significant positive correlation with AST (r = 0.74, p = 0.002) and significant negative correlation with platelets (r = −0.70, p = 0.004). In addition, MRE had significant correlations with noninvasive fibrosis biomarkers, including APRI (r = 0.81, p < 0.001), FIB-4 (r = 0.67, p = 0.006), Fibroindex (r = 0.76, p = 0.001), and Forns' Index (r = 0.72, p = 0.002). No correlation with ALT (r = 0.28, p = 0.31) or GGT (r = 0.43, p = 0.1) was observed.

3.4. Correlates of LOXL2. Soluble LOXL2 (n = 23) levels correlated significantly with AST (r = 0.70, p = 0.001) and negatively with platelets (r = −0.57, p = 0.01) (Table 2). sLOXL2 also had significant positive correlation with the noninvasive fibrosis biomarkers, APRI (r = 0.72, p = 0.001), FIB-4 (r = 0.71, p = 0.001), Fibroindex (r = 0.80, p =< 0.0001), and Forns' Index (r = 0.6, p = 0.009).

Soluble LOXL2 correlated with HVPG (r = 0.58, p = 0.02) but did not correlate with fibrosis or inflammation by biopsy.

Liver LOXL2 gene expression, analyzed by PCR in 10 participants, also correlated with HVPG (r = 0.69, p = 0.03) and HAI total (r = 0.82, p = 0.006), but not with fibrosis (r = 0.18, p = 0.61).

Serum soluble (n = 13; r = 0.82, p < 0.001) and liver LOXL2 (n = 8; r = 0.82, p = 0.03) both had strong correlations with MRE (Figure 1).

4. Discussion

We have demonstrated that hepatic MRE measurement of shear wave velocity may be a valuable biomarker in assessing the degree of portal hypertension as measured by HVPG. Stepwise regression analysis of HVPG on multiple biomarkers of interest showed that MRE had an independent association with HVPG, suggesting potential utility of MRE in detection and monitoring of portal hypertension. Additionally, our study demonstrates correlations between MRE-measured hepatic shear wave velocity with other noninvasive fibrosis biomarkers, including APRI, FIB-4, Fibroindex, and Forns' Index, and with sLOXL2 levels, although none of these markers showed an independent association with HVPG in a multivariate analysis.

In porcine and canine models of progressive portal hypertension, liver and spleen stiffness assessed by MRE correlated with portal pressure [19, 33]. In a small human study, MRE was sensitive to pressure when change in volumetric strain was found after transjugular intrahepatic portosystemic shunt (TIPS) placement [34]. This study demonstrated that percentage change in volumetric strain measurements before and after TIPS procedure correlated well with pre-TIPS HVPG. These findings suggest that MRE measures dynamic, pressure-dependent liver stiffness in addition to the static components of fibrosis. However, to the best of our knowledge, our study is the first to identify a strong correlation between MRE-measured shear wave velocity, HVPG, and serum soluble LOXL2. This was possible at higher magnetic field strength (3 T) not used in the previously mentioned studies. A higher magnetic field is known to be more sensitive to phase changes that are the backbone of the MRE readout sequences. Additionally, utilizing 32-channel coils and mechanical vibrations (instead of acoustic vibrations) might have added to the robustness and sensitivity of our methods.

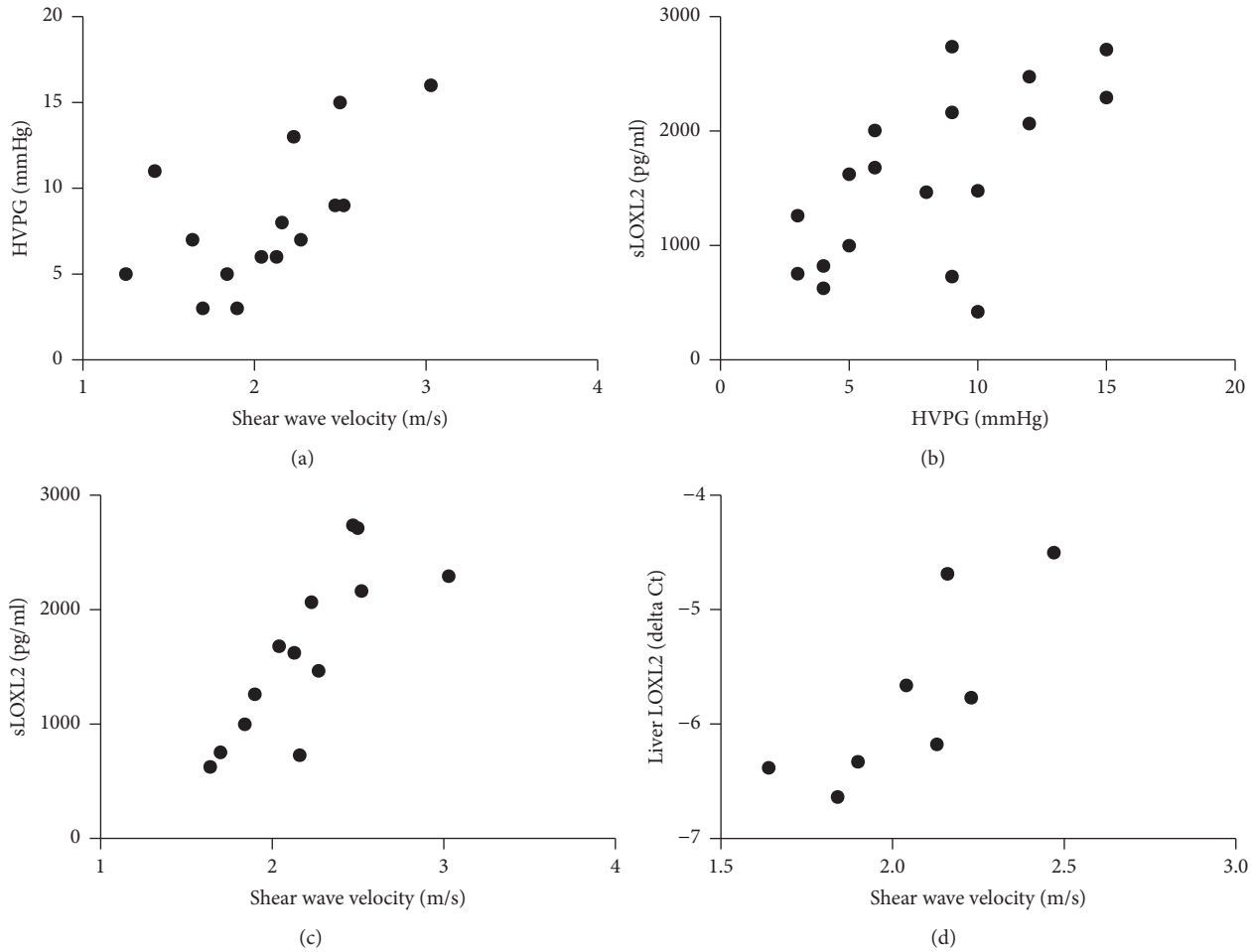

Figure 1: Significant correlations were seen between MRE-measured shear wave velocity, a measure of liver stiffness, and HVPG (a), sLOXL2 (c), and liver LOXL2 (d). sLOXL2 also correlated well with HVPG (b).

MRE shear wave velocity also correlated with hepatic fibrosis, confirming the findings of earlier MRE studies in HCV and nonalcoholic fatty liver disease [35–37]. Interestingly, MRE had a strong correlation with histologic inflammatory scores and αSMA in addition to histologic fibrosis, suggesting that MRE-measured shear wave velocity may detect hepatic inflammation. Studies have shown hepatic inflammation can increase liver stiffness irrespective of fibrosis [38], although the mechanism is not fully understood. However, the increase in cellular volume seen with inflammation may affect the procession of the shear wave as it propagates through the hepatic tissue. The dynamic component of liver stiffness is affected by change in perfusion that can be influenced by hepatic inflammation. Moreover, changes in the mechanical state of cells capable of contraction, such as vascular smooth muscle cells and activated hepatic stellate cells in the perisinusoidal spaces, can influence liver stiffness [39].

A correlation was also seen between αSMA, a contractile protein expressed by activated hepatic stellate cells with the myofibroblast phenotype, and HVPG. αSMA is increased in the liver of patients with chronic liver diseases and correlates with the extent of hepatic fibrosis [40]. In chronic viral hepatitis, αSMA also correlates with necroinflammatory grade, suggesting that hepatocyte necroinflammation drives hepatic stellate cell activation and subsequent fibrogenesis [41]. Our observations agree with accumulating evidence suggesting that stellate cells also regulate liver microcirculation and portal pressure. In animal models of fibrosis, αSMA causes cellular contractility through calcium dependent and independent contractile forces, leading to increased portal resistance [42]. As fibrosis advances, myofibroblasts are recruited and impede portal circulation through vasoactive mediators and interactions with the extracellular matrix [43, 44]. Inhibition of αSMA with nitric oxide in rat and human hepatic stellate cells reduces portal pressure by 20% [45].

We also observed a correlation between sLOXL2 levels, hepatic LOXL2 expression, and portal pressure. In addition to cross-linking collagen, LOXL2 increases matrix tension, triggering fibroblasts to covert to contractile myofibroblasts through activation of hepatic TGFβ1 [46, 47]. LOXL2 also stimulates expression of myofibroblasts grown on collagen matrices through integrin mediated focal adhesion kinase activation [48]. As myofibroblasts regulate portal resistance,

LOXL2 may also contribute to development of portal hypertension. Interestingly, sLOXL2 had the most significant correlation with MRE compared to other parameters. Longitudinal studies of hepatic fibrosis, including ongoing trials of simtuzumab in NASH and advanced liver fibrosis, will contribute to the understanding of the function of LOXL2 in fibrosis progression and portal hypertension.

Limitations of our study include the cross-sectional design, small size with limited numbers of patients with cirrhosis and portal hypertension, and lack of a validation cohort. Further cross-sectional and longitudinal study in a larger population of patients with clinically significant portal hypertension is needed to confirm our findings. Multiple comparisons were made and, though statistically significant, many correlations were weak. Additionally, the liver biopsy samples obtained by transjugular biopsy were small, with 6 (26%) suboptimal for grading, likely resulting in understaging and undergrading of fibrosis [32] and potentially attenuating relationships between biopsy parameters and noninvasive markers. MRE requires specialized hardware, usually only available at academic medical centers, and is limited to patients eligible and tolerant of MR imaging. Compared to transient elastography and other ultrasound-based shear wave elastography methods, MRE would be expected to cost more.

In conclusion, MRE shear wave velocity correlates with noninvasive biomarkers and was independently associated with HVPG. Given this, MRE may prove to be a useful noninvasive measure of disease severity and portal hypertension. In addition, our study demonstrated the novel correlation of soluble LOXL2 and hepatic LOXL2 expression with portal hypertension.

Abbreviations

αSMA: Alpha smooth muscle actin
ALT: Alanine aminotransferase
AST: Aspartate aminotransferase
APRI: Aspartate aminotransferase to platelet ratio index
FHVP: Free hepatic vein pressure
GGT: Gamma-glutamyl transferase
HAI: Histologic activity index
HCV: Hepatitis C virus
HIV: Human immunodeficiency virus
HVPG: Hepatic venous pressure gradient
LOXL2: Lysyl oxidase-like 2
MRE: Magnetic resonance elastography
NASH: Nonalcoholic steatohepatitis
qRT: Quantitative real time
RNA: Ribonucleic acid
TGFβ1: Transforming growth factor beta-1
TIPS: Transjugular intrahepatic portosystemic shunt
WHVP: Wedged hepatic venous pressure
VCTE: Vibration-controlled transient elastography.

Disclosure

This paper was presented in part at The Liver Meeting (AASLD), Boston, MA, November 7–11, 2014, and Digestive Disease Week (DDW), Washington, DC, May 16–19, 2015.

Conflicts of Interest

Dr. Meissner receives grant support from Gilead Sciences, Inc. Drs. Myers and Subramanian are employed by and own stock in Gilead Sciences Inc. All other coauthors report no conflicts of interest.

Authors' Contributions

Ahmed M. Gharib and Ma Ai Thanda Han equally contributed to this work. Ahmed M. Gharib, Eric G. Meissner, David E. Kleiner, Robert P. Myers, G. Mani Subramanian, Shyam Kottilil, Theo Heller, Joseph A. Kovacs, and Caryn G. Morse were responsible for study concept and design; Ahmed M. Gharib, Eric G. Meissner, Mary McLaughlin, Lindsay Matthews, Khaled Z. Abd-Elmoniem, Elliot Levy, Christopher Koh, Theo Heller, Joseph A. Kovacs, and Caryn G. Morse were responsible for acquisition of data; Ahmed M. Gharib, Ma Ai Thanda Han, Eric G. Meissner, David E. Kleiner, Xiongce Zhao, Bisharah Rizvi, Elliot Levy, Christopher Koh, Robert P. Myers, G. Mani Subramanian, Theo Heller, Joseph A. Kovacs, and Caryn G. Morse were responsible for analysis and interpretation of data; Ahmed M. Gharib, Ma Ai Thanda Han, Eric G. Meissner, Joseph A. Kovacs, and Caryn G. Morse were responsible for drafting of the manuscript; David E. Kleiner, Ralph Sinkus, Christopher Koh, G. Mani Subramanian, Theo Heller, Joseph A. Kovacs, and Caryn G. Morse were responsible for critical revision of the manuscript for content; Xiongce Zhao was responsible for statistical analysis; Eric G. Meissner, Shyam Kottilil, and Caryn G. Morse were responsible for obtained funding; Mary McLaughlin, Lindsay Matthews, and Khaled Z. Abd-Elmoniem were responsible for technical or material support; Joseph A. Kovacs and Caryn G. Morse were responsible for study supervision.

Acknowledgments

The authors thank Dr. Zachary Goodman, who performed alpha smooth muscle actin staining for the study, the volunteers who participated in this research, and NIH care providers and support staff. This work was supported by the United States National Institutes of Health (NIH) Intramural Research Program, NIH Clinical Center, NIAID, and NIDDK and, in part, by an NIH Bench to Bedside Award funded by the Office of AIDS Research and funded in part with federal funds from the National Cancer Institute, under contract HHSN261200800001E.

References

[1] R. Lozano, M. Naghavi, K. Foreman et al., "Global and regional mortality from 235 causes of death for 20 age groups in 1990 and 2010: a systematic analysis for the Global Burden of Disease Study 2010," *The Lancet*, vol. 380, no. 9859, pp. 2095–2128, 2012.

[2] C. Ripoll, R. Bañares, D. Rincón et al., "Influence of hepatic venous pressure gradient on the prediction of survival of patients with cirrhosis in the MELD era," *Hepatology*, vol. 42, no. 4, pp. 793–801, 2005.

[3] J. Turnes, J. C. Garcia-Pagan, J. G. Abraldes, M. Hernandez-Guerra, A. Dell'Era, and J. Bosch, "Pharmacological reduction of portal pressure and long-term risk of first variceal bleeding in patients with cirrhosis," *The American Journal of Gastroenterology*, vol. 101, no. 3, pp. 506–512, 2006.

[4] A. Zipprich, G. Garcia-Tsao, S. Rogowski, W. E. Fleig, T. Seufferlein, and M. M. Dollinger, "Prognostic indicators of survival in patients with compensated and decompensated cirrhosis," *Liver International*, vol. 32, no. 9, pp. 1407–1414, 2012.

[5] R. J. Groszmann, G. Garcia-Tsao, J. Bosch et al., "Beta-blockers to prevent gastroesophageal varices in patients with cirrhosis," *New England Journal of Medicine*, vol. 353, no. 21, pp. 2254–2261, 2005.

[6] J. Bosch, J. G. Abraldes, A. Berzigotti, and J. C. García-Pagan, "The clinical use of HVPG measurements in chronic liver disease," *Nature Reviews Gastroenterology and Hepatology*, vol. 6, no. 10, pp. 573–582, 2009.

[7] H. Deng, X. Qi, and X. Guo, "Diagnostic accuracy of APRI, AAR, FIB-4, FI, king, lok, forns, and fibroindex scores in predicting the presence of esophageal varices in liver cirrhosis: a systematic review and meta-analysis," *Medicine*, vol. 94, no. 42, Article ID e1795, 2015.

[8] Y. J. Choi, S. K. Baik, D. H. Park et al., "Comparison of Doppler ultrasonography and the hepatic venous pressure gradient in assessing portal hypertension in liver cirrhosis," *Journal of Gastroenterology and Hepatology*, vol. 18, no. 4, pp. 424–429, 2003.

[9] Y. J. Kim, S. S. Raman, N. C. Yu, K. J. To'o, R. Jutabha, and D. S. K. Lu, "Esophageal varices in cirrhotic patients: evaluation with liver CT," *American Journal of Roentgenology*, vol. 188, no. 1, pp. 139–144, 2007.

[10] L. Annet, R. Materne, E. Danse, J. Jamart, Y. Horsmans, and B. E. Van Beers, "Hepatic flow parameters measured with MR imaging and doppler US: correlations with degree of cirrhosis and portal hypertension," *Radiology*, vol. 229, no. 2, pp. 409–414, 2003.

[11] C. Bureau, S. Metivier, J. M. Peron et al., "Transient elastography accurately predicts presence of significant portal hypertension in patients with chronic liver disease," *Alimentary Pharmacology and Therapeutics*, vol. 27, no. 12, pp. 1261–1268, 2008.

[12] M. A. Robic, B. Procopet, S. Métivier et al., "Liver stiffness accurately predicts portal hypertension related complications in patients with chronic liver disease: a prospective study," *Journal of Hepatology*, vol. 55, no. 5, pp. 1017–1024, 2011.

[13] L. Castéra, J. Foucher, P.-H. Bernard et al., "Pitfalls of liver stiffness measurement: a 5-year prospective study of 13,369 examinations," *Hepatology*, vol. 51, no. 3, pp. 828–835, 2010.

[14] M. Yin, K. J. Glaser, J. A. Talwalkar, J. Chen, A. Manduca, and R. L. Ehman, "Hepatic MR elastography: clinical performance in a series of 1377 consecutive examinations1," *Radiology*, vol. 278, no. 1, pp. 114–124, 2016.

[15] S. U. Shin, J.-M. Lee, M. H. Yu et al., "Prediction of esophageal varices in patients with cirrhosis: usefulness of three-dimensional MR elastography with echo-planar imaging technique," *Radiology*, vol. 272, no. 1, pp. 143–153, 2014.

[16] S. Singh, S. K. Venkatesh, A. Keaveny et al., "Diagnostic accuracy of magnetic resonance elastography in liver transplant recipients: a pooled analysis," *Annals of Hepatology*, vol. 15, no. 3, pp. 363–376, 2016.

[17] L. Huwart, C. Sempoux, E. Vicaut et al., "Magnetic resonance elastography for the noninvasive staging of liver fibrosis," *Gastroenterology*, vol. 135, no. 1, pp. 32–40, 2008.

[18] S. Ichikawa, U. Motosugi, H. Morisaka et al., "Comparison of the diagnostic accuracies of magnetic resonance elastography and transient elastography for hepatic fibrosis," *Magnetic Resonance Imaging*, vol. 33, no. 1, pp. 26–30, 2015.

[19] M. Yin, A. Kolipaka, D. A. Woodrum et al., "Hepatic and splenic stiffness augmentation assessed with MR elastography in an in vivo porcine portal hypertension model," *Journal of Magnetic Resonance Imaging*, vol. 38, no. 4, pp. 809–815, 2013.

[20] M. Ronot, S. Lambert, L. Elkrief et al., "Assessment of portal hypertension and high-risk oesophageal varices with liver and spleen three-dimensional multifrequency MR elastography in liver cirrhosis," *European Radiology*, vol. 24, no. 6, pp. 1394–1402, 2014.

[21] E. Cholongitas, G. V. Papatheodoridis, M. Vangeli, N. Terreni, D. Patch, and A. K. Burroughs, "Systematic review: the model for end-stage liver disease—should it replace Child-Pugh's classification for assessing prognosis in cirrhosis?" *Alimentary Pharmacology & Therapeutics*, vol. 22, no. 11-12, pp. 1079–1089, 2005.

[22] E. G. Meissner, M. McLaughlin, L. Matthews et al., "Simtuzumab treatment of advanced liver fibrosis in HIV and HCV-infected adults: results of a 6-month open-label safety trial," *Liver International*, vol. 36, no. 12, pp. 1783–1792, 2016.

[23] K. Ishak, A. Baptista, L. Bianchi et al., "Histological grading and staging of chronic hepatitis," *Journal of Hepatology*, vol. 22, no. 6, pp. 696–699, 1995.

[24] D. E. Kleiner, E. M. Brunt, M. Van Natta et al., "Design and validation of a histological scoring system for nonalcoholic fatty liver disease," *Hepatology*, vol. 41, no. 6, pp. 1313–1321, 2005.

[25] Y.-O. Kweon, Z. D. Goodman, J. L. Dienstag et al., "Decreasing fibrogenesis: an immunohistochemical study of paired liver biopsies following lamivudine therapy for chronic hepatitis B," *Journal of Hepatology*, vol. 35, no. 6, pp. 749–755, 2001.

[26] D. A. Herzka, M. S. Kotys, R. Sinkus, R. I. Pettigrew, and A. M. Gharib, "Magnetic resonance elastography in the liver at 3 Tesla using a second harmonic approach," *Magnetic Resonance in Medicine*, vol. 62, no. 2, pp. 284–291, 2009.

[27] C.-T. Wai, J. K. Greenson, R. J. Fontana et al., "A simple noninvasive index can predict both significant fibrosis and cirrhosis in patients with chronic hepatitis C," *Hepatology*, vol. 38, no. 2, pp. 518–526, 2003.

[28] R. K. Sterling, E. Lissen, N. Clumeck et al., "Development of a simple noninvasive index to predict significant fibrosis in patients with HIV/HCV coinfection," *Hepatology*, vol. 43, no. 6, pp. 1317–1325, 2006.

[29] X. Forns, S. Ampurdanès, J. M. Llovet et al., "Identification of chronic hepatitis C patients without hepatic fibrosis by a simple predictive model," *Hepatology*, vol. 36, no. 4, part 1, pp. 986–992, 2002.

[30] M. Koda, Y. Matunaga, M. Kawakami, Y. Kishimoto, T. Suou, and Y. Murawaki, "Fibroindex, a practical index for predicting significant fibrosis in patients with chronic hepatitis C," *Hepatology*, vol. 45, no. 2, pp. 297–306, 2007.

[31] E. G. Meissner, D. Wu, A. Osinusi et al., "Endogenous intrahepatic IFNs and association with IFN-free HCV treatment outcome," *The Journal of Clinical Investigation*, vol. 124, no. 8, pp. 3352–3363, 2014.

[32] D. C. Rockey, S. H. Caldwell, Z. D. Goodman, R. C. Nelson, A. D. Smith, and American Association for the Study of Liver Diseases, "Liver biopsy," *Hepatology*, vol. 49, no. 3, pp. 1017–1044, 2009.

[33] G. I. Nedredal, M. Yin, T. McKenzie et al., "Portal hypertension correlates with splenic stiffness as measured with MR elastography," *Journal of Magnetic Resonance Imaging*, vol. 34, no. 1, pp. 79–87, 2011.

[34] S. Hirsch, J. Guo, R. Reiter et al., "Towards compression-sensitive magnetic resonance elastography of the liver: sensitivity of harmonic volumetric strain to portal hypertension," *Journal of Magnetic Resonance Imaging*, vol. 39, no. 2, pp. 298–306, 2014.

[35] R. Loomba, T. Wolfson, B. Ang et al., "Magnetic resonance elastography predicts advanced fibrosis in patients with nonalcoholic fatty liver disease: a prospective study," *Hepatology*, vol. 60, no. 6, pp. 1920–1928, 2014.

[36] L. Huwart, C. Sempoux, N. Salameh et al., "Liver fibrosis: Noninvasive assessment with MR elastography versus aspartate aminotransferase-to-platelet ratio index," *Radiology*, vol. 245, no. 2, pp. 458–466, 2007.

[37] R. Loomba, J. Cui, T. Wolfson et al., "Novel 3D magnetic resonance elastography for the noninvasive diagnosis of advanced fibrosis in NAFLD: a prospective study," *The American Journal of Gastroenterology*, vol. 111, no. 7, pp. 986–994, 2016.

[38] U. Arena, F. Vizzutti, G. Corti et al., "Acute viral hepatitis increases liver stiffness values measured by transient elastography," *Hepatology*, vol. 47, no. 2, pp. 380–384, 2008.

[39] J. J. Tomasek, G. Gabbiani, B. Hinz, C. Chaponnier, and R. A. Brown, "Myofibroblasts and mechano-regulation of connective tissue remodelling," *Nature Reviews Molecular Cell Biology*, vol. 3, no. 5, pp. 349–363, 2002.

[40] G. Carpino, S. Morini, S. Ginanni Corradini et al., "Alpha-SMA expression in hepatic stellate cells and quantitative analysis of hepatic fibrosis in cirrhosis and in recurrent chronic hepatitis after liver transplantation," *Digestive and Liver Disease*, vol. 37, no. 5, pp. 349–356, 2005.

[41] C.-M. Chu, W.-C. Shyu, and Y.-F. Liaw, "Comparative studies on expression of α-smooth muscle actin in hepatic stellate cells in chronic hepatitis B and C," *Digestive Diseases and Sciences*, vol. 53, no. 5, pp. 1364–1369, 2008.

[42] W. Laleman, L. Van Landeghem, T. Severi et al., "Both Ca^{2+}-dependent and -independent pathways are involved in rat hepatic stellate cell contraction and intrahepatic hyperresponsiveness to methoxamine," *American Journal of Physiology—Gastrointestinal and Liver Physiology*, vol. 292, no. 2, pp. G556–G564, 2007.

[43] A. C. Melton, A. Datta, and H. F. Yee Jr., "$[Ca^{2+}]$i-independent contractile force generation by rat hepatic stellate cells in response to endothelin-1," *American Journal of Physiology—Gastrointestinal and Liver Physiology*, vol. 290, no. 1, pp. G7–G13, 2006.

[44] E. Novo, S. Cannito, E. Morello et al., "Hepatic myofibroblasts and fibrogenic progression of chronic liver diseases," *Histology and Histopathology*, vol. 30, no. 9, pp. 1011–1032, 2015.

[45] H. T. T. Duong, Z. X. Dong, L. Su et al., "The use of nanoparticles to deliver nitric oxide to hepatic stellate cells for treating liver fibrosis and portal hypertension," *Small*, vol. 11, no. 19, pp. 2291–2304, 2015.

[46] V. Barry-Hamilton, R. Spangler, D. Marshall et al., "Allosteric inhibition of lysyl oxidase-like-2 impedes the development of a pathologic microenvironment," *Nature Medicine*, vol. 16, no. 9, pp. 1009–1017, 2010.

[47] P.-J. Wipff, D. B. Rifkin, J.-J. Meister, and B. Hinz, "Myofibroblast contraction activates latent TGF-β1 from the extracellular matrix," *Journal of Cell Biology*, vol. 179, no. 6, pp. 1311–1323, 2007.

[48] H. E. Barker, D. Bird, G. Lang, and J. T. Erler, "Tumor-secreted LOXL2 activates fibroblasts through FAK signaling," *Molecular Cancer Research*, vol. 11, no. 11, pp. 1425–1436, 2013.

Hindawi
BioMed Research International
Volume 2017, Article ID 4612769, 10 pages
https://doi.org/10.1155/2017/4612769

Research Article

Carvedilol Attenuates the Progression of Hepatic Fibrosis Induced by Bile Duct Ligation

Xiaopeng Tian,[1,2] Chunhong Zhao,[1,3] Jinbo Guo,[1] Shurui Xie,[1,2] Fengrong Yin,[1] Xiaoxia Huo,[1] and Xiaolan Zhang[1]

[1]*Department of Gastroenterology, The Second Hospital of Hebei Medical University, Hebei Key Laboratory of Gastroenterology, Hebei Institute of Gastroenterology, Shijiazhuang, China*
[2]*Department of Gastroenterology, Xingtai People's Hospital, Xingtai, Hebei 054000, China*
[3]*Department of Fever Related Disease, The PLA General Hospital, Beijing 100853, China*

Correspondence should be addressed to Xiaolan Zhang; xiaolanzh@126.com

Received 4 November 2016; Revised 7 January 2017; Accepted 30 January 2017; Published 15 March 2017

Academic Editor: Xingshun Qi

Background. The sympathetic nervous system (SNS) is responsible for hepatic stellate cells (HSCs) activation and the accumulation of collagen that occurs in hepatic fibrogenesis. Carvedilol has been widely used for the complication of hepatic cirrhosis in the clinic. Furthermore, it has powerful antioxidant properties. We assessed the potential antifibrotic effects of carvedilol and the underlying mechanisms that may further enhance its clinical benefits. *Methods.* Using a bile duct ligation rat model of hepatic fibrosis, we studied the effects of carvedilol on the fibrosis, collagen deposition, and oxidative stress based on histology, immunohistochemistry, western blot, and RT-PCR analyses. *Results.* Carvedilol attenuated liver fibrosis, as evidenced by reduced hydroxyproline content and the accumulation of collagen, downregulated TIMP-1 and TIMP-2, and upregulated MMP-13. MMP-2 was an exception, which was decreased after carvedilol treatment for 2 weeks and upregulated after carvedilol treatment for 4 weeks. Carvedilol reduced the activation of HSCs, decreased the induction of collagen, transforming growth factor-β1, and MDA content, and strengthened the SOD activity. The antifibrotic effects were augmented as dosages increased. *Conclusions.* The study indicates that carvedilol attenuated hepatic fibrosis in a dose-dependent manner. It can decrease collagen accumulation and HSCs activation by the amelioration of oxidative stress.

1. Introduction

Hepatic fibrosis, a reversible wound-healing response to a variety of stimuli, is characterized by the accumulation of extracellular matrix (ECM) mainly secreted by activated hepatic stellate cells (HSCs) [1]. In normal liver, ECM is a highly dynamic substratum with a precisely regulated balance between synthesis and degradation. When ECM production exceeds degradation, hepatic fibrosis develops as a result of the progressive thickening of fibrotic septae and chemical cross-linking of collagen [2]. Transforming growth factor-β_1 (TGF-β_1) is the most potent fibrogenic cytokine in the liver, which is stored as an inactivated protein bound to a latency-associated protein. Once activated, TGF-β_1 binds to Smad proteins, which enhances the transcription of target genes, including procollagen I and procollagen III, and then leads to fibrosis development [3].

Oxidative stress also plays a major role in hepatic fibrogenesis, which is an important stimulus to HSCs activation [4]. Reactive oxygen species (ROS) generated by oxidative stress can induce hepatocyte necrosis/apoptosis and HSCs activation [5]. In addition, ROS leads to a decrease in antioxidant defense such as superoxide dismutase (SOD). Besides being used as a nonselective β-adrenergic blocker, carvedilol has been studied as an antioxidant [6, 7]. It has been demonstrated that inhibition of ROS-induced Smad3 activation by carvedilol could improve myocardial fibrosis [8]. Moreover, carvedilol has been studied in the field of hepatic fibrosis. For cirrhotic rats, one-week carvedilol administration could decrease their portal pressure and

endothelial-related vasodilatory activity [9]. Recently, a study by Hamdy and El-Demerdash has proved that carvedilol has potential antifibrotic effects on carbon tetrachloride (CCl_4) induced liver fibrosis, which can be explained by amelioration of oxidative stress [10]. In conclusion, carvedilol as a nonselective β-adrenoreceptor antagonist and antioxidant might be beneficial for hepatic fibrosis treatment.

In the present study, hepatic fibrosis model was established by bile duct ligation (BDL) in Sprague-Dawley (SD) rats. Carvedilol was administered in three dosages 48 hours after BDL for 2 weeks and 4 weeks, respectively. In addition to assessing the effects of carvedilol on liver fibrosis, we also investigated its potential mechanisms.

2. Materials and Methods

2.1. Animal Experiments and Drug Treatment. Fifty adult male Wistar rats weighing 250–300 g were obtained from the Experimental Animal Center of Hebei Medical University (permission number 705188). The research was conducted in accordance with the internationally accepted principles for laboratory animal use and care as found in the US guidelines (NIH publication #85-23, revised in 1985). The experiment was performed in compliance with the national ethical guidelines for the care and use of laboratory animals (certificate number 911102).

The rats were randomly divided into five groups (10 rats per group): sham surgery control group, bile duct ligation (BDL) model group, low-dose carvedilol treatment group ($0.1\,mg{\cdot}kg^{-1}{\cdot}d^{-1}$, CAR-L), medium-dose carvedilol treatment group ($1\,mg{\cdot}kg^{-1}{\cdot}d^{-1}$, CAR-M), and high-dose carvedilol treatment group ($10\,mg{\cdot}kg^{-1}{\cdot}d^{-1}$, CAR-H). Rat hepatic fibrosis model was established by applying BDL. Forty-eight hours after the operation, carvedilol was administered twice a day. Each group was also randomly divided into two groups, and their liver tissue specimens were separately taken 2 weeks and 4 weeks after BDL.

2.2. Liver Function Detection and Histological Examination. Blood was obtained from the left ventricular apex of rats and centrifuged at $3000g$ at $4^{\circ}C$ for 10 min to collect the serum. The levels of alanine aminotransferase (ALT), aspartate aminotransferase (AST), total bilirubin (TBil), and albumin (Alb) were detected using a fully automatic biochemical analyzer. Liver specimens were fixed for 12–24 h in 4% phosphate-buffered paraformaldehyde (Huarui Scientific & Technological Co.) and then embedded in paraffin for light microscopy examination. Tissue sections (4 μm thick) were stained with hematoxylin and eosin (H&E) for morphological evaluation and Masson trichrome (MT) for assessing the degree of fibrosis.

2.3. Immunohistochemical Staining. The 3 μm thick liver tissues embedded in paraffin were deparaffinized and serially dehydrated in ethanol. Then, they were treated with 5% hydrogen peroxide for 10 min to inactivate the endogenous peroxidase. After 20 min of blocking with PBS containing 10% normal goat serum, the sections were incubated with primary antibodies. The primary antibodies included type I, III, and IV collagen (rabbit polyclonal antibody; Beijing Biosynthesis Biotechnology) used as a marker for collagen expression; smooth muscle actin polyclonal antibody (rabbit polyclonal antibody; Santa Cruz Biotechnology) used as a marker of activated HSC; TGF-β_1 (rabbit polyclonal antibody; Beijing Biosynthesis Biotechnology) used as marker of cytokine. After treatment with HRP-conjugated goat anti-mouse IgG and 50 μL of streptavidin-peroxidase solutions for 30 min at RT, the sections were stained with DAB and counterstained with hematoxylin. The positive areas showed the color of brown yellow. Immunohistochemical analysis was performed with Image-Pro Plus.

2.4. Hydroxyproline Determination. Collagen was detected by estimating the hydroxyproline content, an amino acid characteristic of collagen. Hepatic hydroxyproline was measured using a hydroxyproline detection kit (Jiancheng Institute of Biotechnology, Nanjing, China) according to the manufacturer's instructions.

2.5. Western Blot Analysis. Liver samples were homogenized with lysis buffer (Cell Signal Technology Inc., Danvers, MA) and centrifuged at 20,000 ×g for 60 minutes at $4^{\circ}C$. The resultant supernatants were used as the total liver protein and subjected to western blotting. The protein concentrations were determined by Bradford's method. Proteins were resolved by sodium dodecyl sulphate polyacrylamide gel electrophoresis and transferred to a polyvinyl difluoride membrane. Each blot was treated with the anti-b-actin antibody (β-actin 1 : 5,000; mouse monoclonal antibody; Sigma-Aldrich, St. Louis, MO), anti-matrix metalloproteinase-13 (MMP-13, 1 : 400), antitissue inhibitors of metalloproteinase-1 (TIMP-1, 1 : 400), anti-MMP-2 (1 : 300), and anti-TIMP-2 (1 : 400). All the above were from Santa Cruz Biotechnology. Then, secondary antibody (Santa Cruz Biotechnology) was added, and the reaction bands of western blot were quantified by Quantity One software (Bio-Rad Laboratories, Inc., Berkeley, CA) and modified by the β-actin. The values (% of control) are given as means ± SD of 5 animals.

2.6. Determination of Oxidative Damage and Antioxidant Enzyme Activity. Frozen liver tissues from each rat were defrosted and poached in ice-cold phosphate buffer. 100 mg liver tissue was weighed for homogenizing and centrifuged at 3,000 rpm for 10 min and the supernatant was imbibed for determination. Oxidative stress was determined by detecting the concentration of malonyldialdehyde (MDA) by thiobarbituric acid reactive substances. The experiment was conducted according to the manufacturer's instructions (Jiancheng Institute of Biotechnology, Nanjing, China). The conjugation was accompanied by an increase in absorbance at 532 nm. The cytosolic SOD activity was assayed using the SOD detection kit (Jiancheng Institute of Biotechnology, Nanjing, China). The autooxidation rate of epinephrine, which was progressively inhibited by the increasing amounts of SOD in the homogenate, was monitored spectrophotometrically at 550 nm. The amount of enzyme that inhibited 50% of epinephrine autooxidation was defined as 1 U of SOD activity.

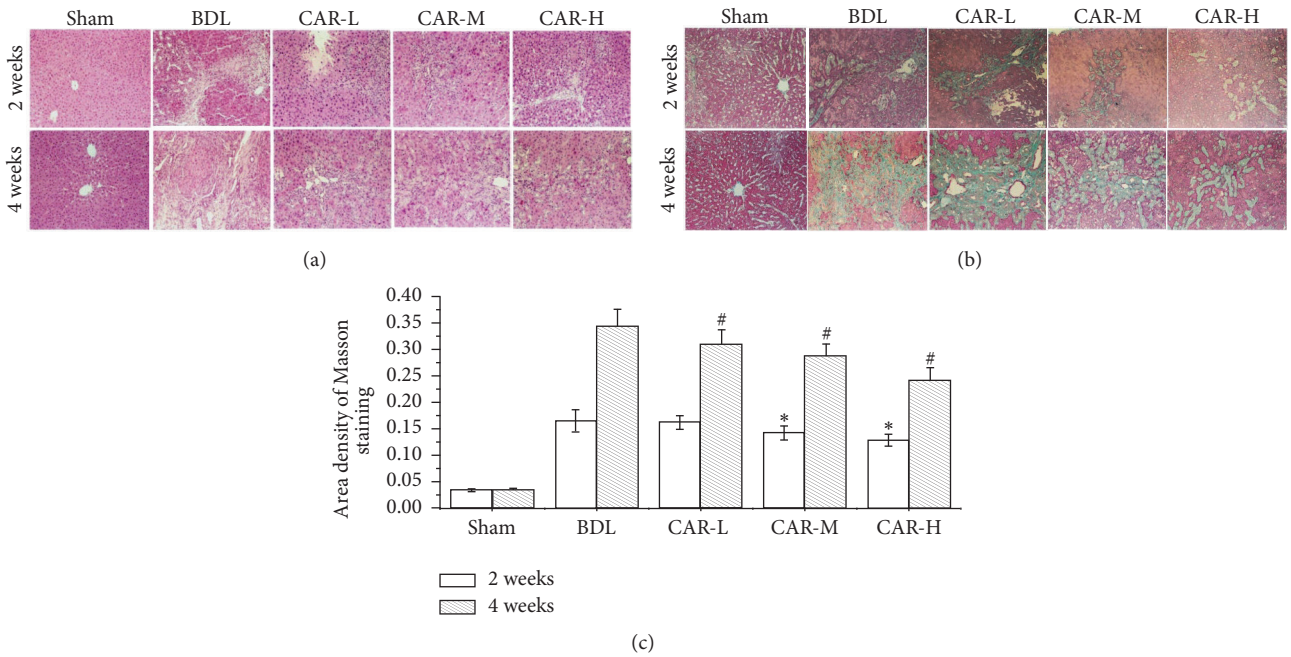

Figure 1: Representative photomicrographs of liver sections stained with H&E and MT, respectively. (a) H&E staining showed the pathologic changes in sham, BDL, CAR-L, CAR-M, and CAR-H groups two weeks and four weeks after bile duct ligation, respectively (magnification ×200). (b) MT staining showed the scar formation in the above five groups, respectively (magnification ×200). (c) The area density of Masson staining was significantly lower after carvedilol treatment. $^{*}P < 0.05$ *versus* BDL group for 2 weeks; $^{\#}P < 0.01$ *versus* BDL group for 4 weeks. CAR-H *versus* CAR-L, $P < 0.05$.

Table 1: Levels of ALT, AST, Alb, and TBil in BDL model after carvedilol treatment for two weeks.

Group	ALT (U/L)	AST (U/L)	ALB (g/L)	TBil (μmol/L)
Sham	45.8 ± 4.18	128.9 ± 15.12	36.1 ± 2.77	1.4 ± 0.37
BDL	92.6 ± 11.22*	418.1 ± 40.71*	27.5 ± 3.98*	84.7 ± 11.39*
CAR-L	90.6 ± 9.26*	406.4 ± 34.53*	27.3 ± 2.36*	85.6 ± .9.21*
CAR-M	86.5 ± 13.86*	391.2 ± 45.51*	28.1 ± 3.25*	82.5 ± 12.24*
CAR-H	81.7 ± 10.65*#	370.3 ± 38.19*#	28.4 ± 3.27*	78.7 ± 13.12*

BDL: bile duct ligation; sham: sham-operated; CAR: carvedilol; ALT: alanine transaminase; AST: aspartate transaminase; Alb: albumin; TBil: total bilirubin. $^{*}P < 0.05$ *versus* sham; $^{\#}P < 0.05$ *versus* BDL.

2.7. Statistical Analysis. Data were analyzed statistically by one-factor analysis of variance (ANOVA). Differences between experimental groups were analyzed using Student-Newman-Keuls (SNK) multiple-range test. The significant level was set at $P < 0.05$. Results are expressed as means ± SD.

3. Results

3.1. Carvedilol Attenuated Liver Injury and Fibrosis. We found that the liver functions in hepatic fibrosis model groups were obviously damaged according to the expression of ALT, AST, TBil, and Alb. And the levels of ALT and AST in CAR-H groups were significantly lower than in model groups (Tables 1 and 2). H&E and MT staining were used to evaluate the therapeutic effects of different dosages of carvedilol on hepatic fibrosis. Two weeks after BDL, the liver tissues in BDL group exhibited distortion architecture, showing hepatocellular degeneration with formation of fibrous tissue infiltrated with inflammatory cells (Figure 1(a)). Four weeks after BDL, the increased hyperplasia of fibrous tissue led to fibrous septa formation (Figure 1(a)). Liver specimens obtained from carvedilol-treated group displayed a significant decrease in fibrous tissue and the hepatocytes largely retained their normal appearance, especially in the CAR-H group (Figures 1(a) and 1(b)). As determined by Masson's trichrome staining, BDL markedly induced liver fibrosis. These alterations were significantly attenuated by carvedilol administration, and the efficacy was more obvious as the dosages increased (Figure 1(c)).

3.2. Carvedilol Prevented the Abnormal Collagen Deposition. Type I, III, and IV collagen expressions were detected by immunohistochemistry staining. It was demonstrated that

Table 2: Levels of ALT, AST, Alb, and TBil in BDL model after carvedilol treatment for four weeks.

Group	ALT (U/L)	AST (U/L)	ALB (g/L)	TBil (μmol/L)
Sham	48.7 ± 6.24	136.9 ± 16.35	35.2 ± 3.12	1.39 ± 0.45
BDL	121.7 ± 15.33*	603.9 ± 60.92*	25.3 ± 5.06*	141.2 ± 17.06*
CAR-L	118.35 ± 14.93*	586.32 ± 47.56*	25.5 ± 4.12*	135.6 ± 18.8*
CAR-M	112.46 ± 16.89*	552.1 ± 40.55*#	26.09 ± 3.78*	133.2 ± 16.32*
CAR-H	105.2 ± 13.34*#	519.6 ± 58.4*#	27.1 ± 3.49*	127.7 ± 13.06*

BDL: bile duct ligation; sham: sham-operated; CAR: carvedilol; ALT: alanine transaminase; AST: aspartate transaminase; Alb: albumin; TBil: total bilirubin.
*$P < 0.05$ *versus* sham; #$P < 0.05$ *versus* BDL.

the expressions of type I, III, and IV collagens in carvedilol-treated groups were markedly reduced compared to BDL group, while no marked differences were found among the three carvedilol-treated groups (Figures 2(a), 2(b), and 2(c)).

Hydroxyproline is unique to collagen and thus serves as a specific biochemical marker of collagen production. Two weeks after BDL, the hydroxyproline content in BDL group was markedly higher than that in the sham group. However, it was significantly decreased in CAR-M and CAR-H groups ($0.315 \pm 0.034\ \mu g \cdot mg^{-1}$, $0.279 \pm 0.031\ \mu g \cdot mg^{-1}$ *versus* $0.363 \pm 0.027\ \mu g \cdot mg^{-1}$; $P < 0.01$, $P < 0.01$, resp.) (Figure 2(d)). Four weeks after BDL, the hydroxyproline content in the CAR-L, CAR-M, and CAR-H groups was significantly lower than that in BDL group ($0.719 \pm 0.024\ \mu g \cdot mg^{-1}$, $0.654 \pm 0.048\ \mu g \cdot mg^{-1}$, and $0.605 \pm 0.034\ \mu g \cdot mg^{-1}$ *versus* $0.778 \pm 0.052\ \mu g \cdot mg^{-1}$; $P < 0.05$, $P < 0.01$, and $P < 0.01$, resp.) (Figure 2(d)). And a significant difference was found between the CAR-H and CAR-L groups ($P < 0.05$).

3.3. Carvedilol Inhibited HSC Activation and Induced Activated HSC Apoptosis. We investigated the changes of HSCs in the present BDL rats to examine the effect of BDL-induced overactive sympathetic tone on the activation of HSCs, the key cell for the progressive accumulation of collagen in fibrosis disease. Immunohistochemistry staining for a-SMA, the marker of the activated HSCs, was mildly increased in the BDL group compared to that in sham group and was reduced by carvedilol treatment. After the 2-week carvedilol administration, the α-SMA expression in CAR-M and CAR-H groups was markedly reduced compared to that in BDL group (19.95 ± 2.02%, 18.77 ± 2.15% *versus* 23.77 ± 2.43%; $P < 0.01$, $P < 0.01$, resp.) (Figures 3(a) and 3(c)). After the 4-week carvedilol administration, the positive expression of α-SMA in CAR-L, CAR-M, and CAR-H groups was significantly decreased compared to that in BDL group (33.86 ± 2.23%, 30.77 ± 2.17%, and 28.72 ± 1.74% *versus* 36.88% ± 2.83%; $P < 0.05$, $P < 0.01$, and $P < 0.01$, resp.) (Figures 3(a) and 3(c)). And a significant difference was found among the carvedilol-treated groups (CAR-M *versus* CAR-L, $P < 0.05$; CAR-H *versus* CAR-M, $P < 0.05$).

HSCs apoptosis was determined by TUNEL and α-SMA immunohistochemical double staining. Among the 2-week groups, the apoptosis index of HSC was markedly higher in the CAR-M and CAR-H groups than in BDL group (6.45 ± 1.12%, 7.89 ± 1.06% *versus* 4.95 ± 0.95%; $P < 0.05$, $P < 0.01$, resp.) (Figures 3(b) and 3(d)). Similarly, in the 4-week groups, the apoptosis index was markedly higher in the CAR-M and CAR-H group than in BDL group (4.63 ± 1.06%, 6.17 ± 1.27% *versus* 2.35 ± 0.94; $P < 0.05$, $P < 0.01$, resp.) (Figures 3(b) and 3(d)). And a statistical difference was found between the CAR-H group and CAR-M groups ($P < 0.05$). The results suggested that carvedilol may inhibit the activation of HSCs and promote apoptosis via the antisympathetic predominance pathway.

3.4. The Effects of Carvedilol on MMPs and TIMPs. The degradation of the matrix components markers MMP-2, TIMP-2, MMP-13, and TIMP-1 was used for the same rats in order to evaluate the accumulation and the degradation of matrix components based on the western blot and real-time Q-PCR (Figure 4). Two weeks after BDL, western blot results showed that MMP-2 protein expression was markedly higher in BDL group than in sham group (1.99 ± 0.13 *versus* 1.24±0.09; $P < 0.01$), but it was significantly reduced in CAR-H group (1.33 ± 0.04). After carvedilol treatment for 4 weeks, the MMP-2 protein expression in CAR-M and CAR-H group was significantly higher than that in BDL group (1.99 ± 0.16, 2.15 ± 0.24 *versus* 1.49 ± 0.22; $P < 0.01$, $P < 0.01$, resp.).

After carvedilol treatment for 2 weeks, the MMP-13 protein expression in CAR-L, CAR-M, and CAR-H groups was significantly higher than that in BDL group (1.27 ± 0.11, 1.30 ± 0.13, and 1.43 ± 0.1 *versus* 1.1 ± 0.11; $P < 0.05$, $P < 0.05$, and $P < 0.01$, resp.). Similar results were shown in 4-week carvedilol groups. And a significant difference was found between the CAR-L and CAR-H groups ($P < 0.05$). The MMP-2 and MMP-13 mRNA expressions showed the same tendency as the protein expression above (data was not shown).

TIMP-1 and TIMP-2, mainly produced by HSC, combine with active MMPs to inhibit their activity. Two weeks and 4 weeks after BDL, the protein expression of TIMP-1 and TIMP-2 in BDL group was increased compared with that in sham group. After BDL and carvedilol treatment for 2 weeks and 4 weeks, TIMP-1 protein expression in CAR-M and CAR-H groups was markedly reduced. In the 2-week groups, the protein expression of TIMP-2 in the CAR-H group was dramatically lower than that in the BDL group (0.78 ± 0.06 *versus* 1.41 ± 0.09; $P < 0.01$). In the 4-week groups, TIMP-2 in CAR-L, CAR-M, and CAR-H groups was significantly reduced compared with that in the BDL group (1.12 ± 0.13, 1.06 ± 0.15, and 0.92 ± 0.07 *versus* 1.42 ± 0.07; $P < 0.01$, $P < 0.01$, and $P < 0.01$, resp.)

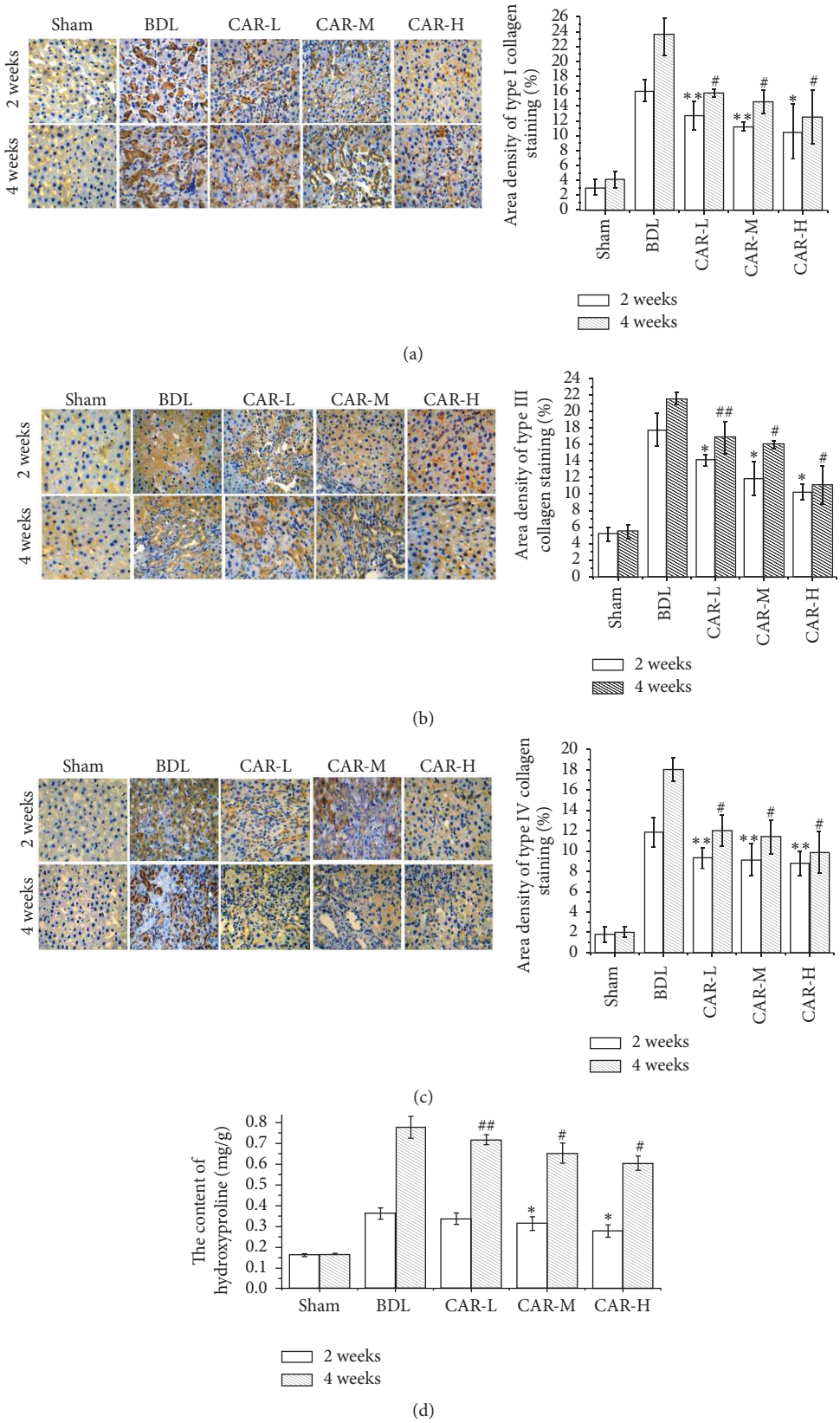

Figure 2: ECM-related collagen I, collagen III, and collagen IV expression and hydroxyproline content in the five groups. (a) Expression of collagen I by immunohistochemical staining (magnification ×200). (b) Expression of collagen III by immunohistochemical staining (magnification ×200). (b) Expression of collagen IV by immunohistochemical staining (magnification ×200). (a–c) Expressions of collagen I, collagen III, and collagen IV were the highest in the BDL group, which were decreased in association with the carvedilol dosage. $^{**}P < 0.05$, $^{*}P < 0.01$ *versus* BDL group for 2 weeks; $^{\#\#}P < 0.05$, $^{\#}P < 0.01$ *versus* BDL group for 4 weeks. (d) Liver hydroxyproline content expressed as μg/mg of wet tissue. The content of hydroxyproline was markedly decreased after carvedilol treatment, especially in the CAR-M and CAR-H groups. $^{*}P < 0.01$ *versus* BDL group for 2 weeks; $^{\#\#}P < 0.05$, $^{\#}P < 0.01$ *versus* BDL group for 4 weeks. CAR-H *versus* CAR-L, $P < 0.05$.

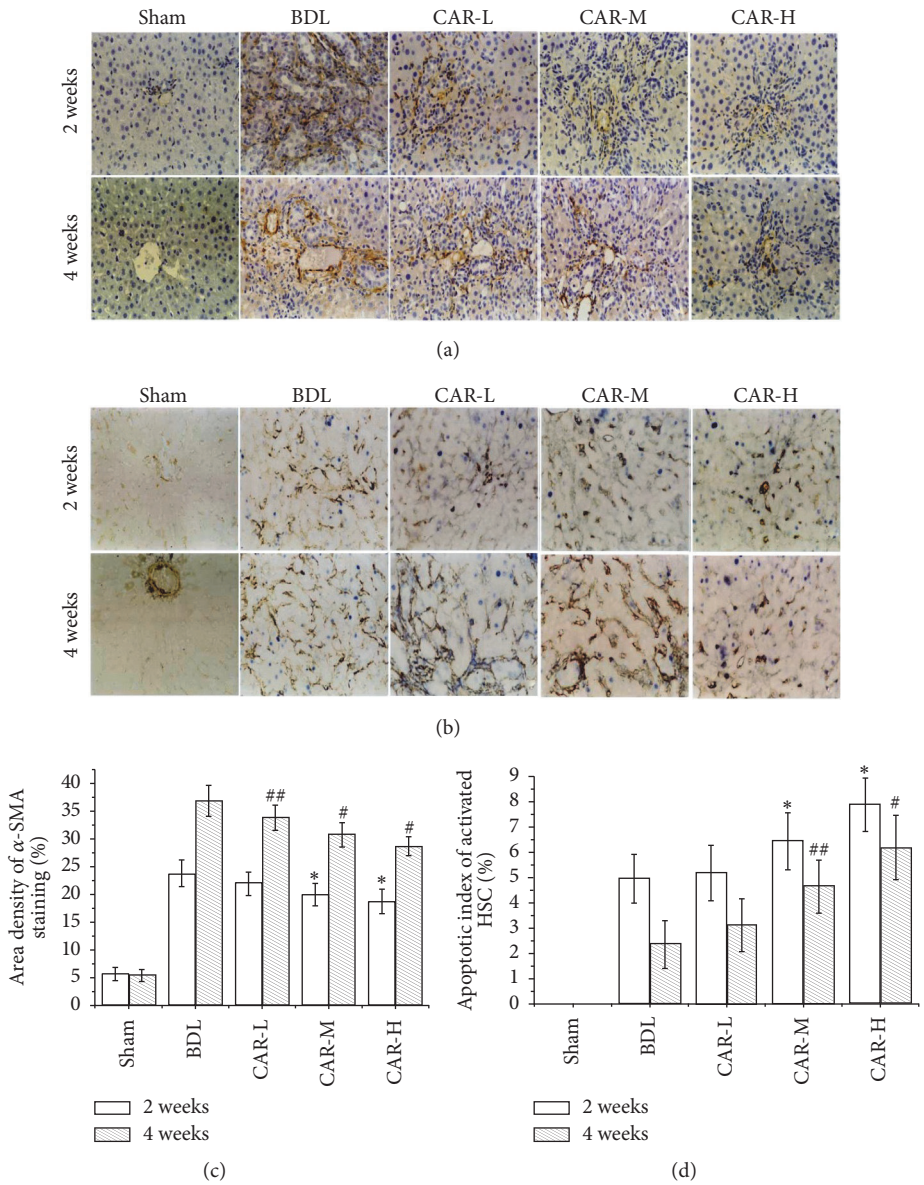

Figure 3: α-SMA expression and the apoptotic index of activated HSC. (a, c) Expression of α-SMA by immunohistochemical staining (magnification ×200). Treatment with carvedilol was effective in inhibiting HSC activation. Moreover, it was related to the doses of the drug. $^{*}P < 0.01$ *versus* BDL group for 2 weeks; $^{\#\#}P < 0.05$, $^{\#}P < 0.01$ *versus* BDL group for 4 weeks. CAR-M *versus* CAR-L, $P < 0.05$; CAR-H *versus* CAR-M, $P < 0.05$. CAR-M *versus* CAR-L, $P < 0.05$; CAR-H *versus* CAR-M, $P < 0.05$. (b, d) Apoptosis of activated HSC by TUNEL and α-SMA immunohistochemical double staining. The apoptosis of activated HSC was markedly increased after carvedilol treatment, especially in the CAR-M and CAR-H groups. $^{*}P < 0.05$, $^{*}P < 0.01$ *versus* BDL group for 2 weeks; $^{\#\#}P < 0.05$, $^{\#}P < 0.01$ *versus* BDL group for 4 weeks. CAR-H *versus* CAR-M, $P < 0.05$.

(Figures 4(a) and 4(e)). And there was a significant difference between the CAR-L and CAR-H groups ($P < 0.01$). The results determined by RT-PCR were the same as the results above (the data was not shown). All these results suggest that carvedilol may modify the shift in the balance of the accumulation and degradation of matrix components in the BDL rats.

3.5. Carvedilol Inhibited TGF-β_1 Expression. We detected the expression of TGF-β_1 by immunohistochemistry staining. In the 2-week groups, the expression of TGF-β_1 in CAR-M and CAR-H groups was markedly reduced compared with that in the BDL group (7.14 ± 1.60%, 6.44 ± 3.64% *versus* 10.10 ± 1.14%; $P < 0.01$, $P < 0.01$, resp.). But no statistical difference was found between the CAR-M and CAR-H groups. Four weeks after BDL, TGF-β_1 expression in CAR-L, CAR-M, and CAR-H groups was significantly decreased compared with that in the BDL group (7.35 ± 0.68%, 7.04 ± 0.33%, and 6.53 ± 0.81% *versus* 14.00 ± 1.81%; $P < 0.01$, $P < 0.01$, and $P < 0.01$, resp.) (Figures 5(a) and 5(b)).

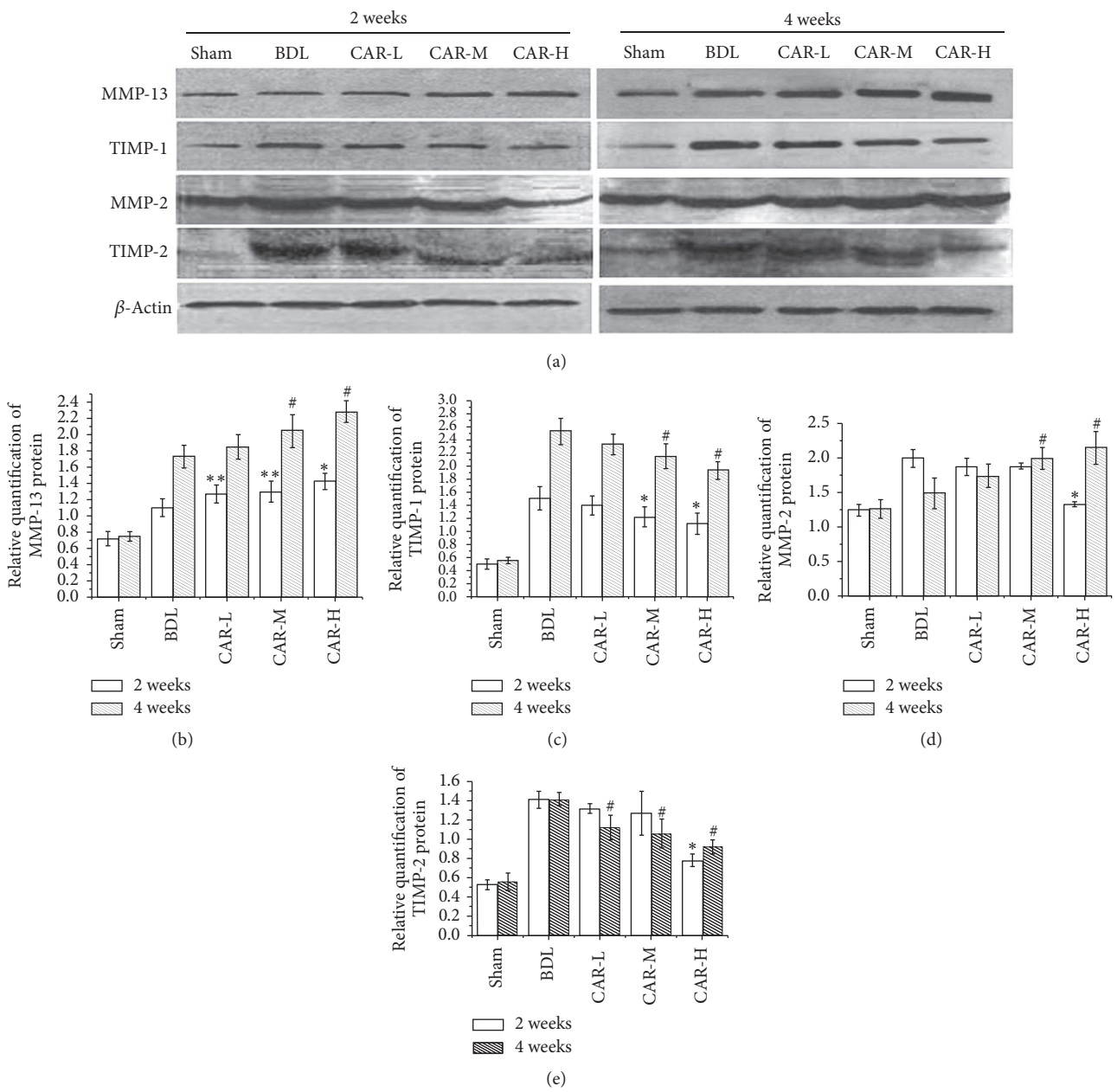

Figure 4: Expression of MMP-13, TIMP-1, MMP-2, and TIMP-2 by western blot analysis. (a) Band of each test index detected by western blot. (b) The expression of MMP-13 was markedly increased after carvedilol therapy. $^{**}P < 0.05$, $^{*}P < 0.01$ *versus* BDL group for 2 weeks; $^{\#}P < 0.01$ *versus* BDL group for 4 weeks. (c) TIMP-1 expression was significantly decreased after carvedilol treatment, especially in the CAR-M and CAR-H groups. $^{*}P < 0.01$ *versus* BDL group for 2 weeks; $^{\#}P < 0.01$ *versus* BDL group for 4 weeks. (d) MMP-2 expression was significantly decreased after carvedilol treatment for 2 weeks in the CAR-H group, while no obvious changes were found among the BDL, CAR-L, and CAR-M groups. $^{*}P < 0.01$ *versus* BDL group. The expression of MMP-2 was increased after carvedilol treatment for 4 weeks, especially in the CAR-M and CAR-H groups. $^{\#}P < 0.01$ *versus* BDL group. (e) TIMP-2 expression was significantly decreased after carvedilol treatment for 2 weeks in the CAR-H group, while no obvious changes were found among the BDL, CAR-L, and CAR-M groups. $^{*}P < 0.01$ *versus* BDL group. The expression of TIMP-2 was also decreased after carvedilol treatment for 4 weeks. $^{\#}P < 0.01$ *versus* BDL group.

3.6. Carvedilol Inhibited Lipid Peroxidation and Enhanced SOD Activities. As expected, two weeks after BDL, thiobarbituric acid method (TBA) showed that MDA contents in the CAR-L, CAR-M, and CAR-H groups were significantly lower than those in the BDL group (0.73 ± 0.09, 0.67 ± 0.62, and 0.63±0.09 *versus* 0.94±0.19; $P < 0.01$, $P < 0.01$, and $P < 0.01$, resp.), while no statistical difference was found among the carvedilol-treated groups. Four weeks after BDL, there was no significant difference between the carvedilol-treated groups and the BDL group (Figure 6(a)).

We also determined the SOD activities by xanthine oxidase method. Two weeks after BDL, it was shown that SOD

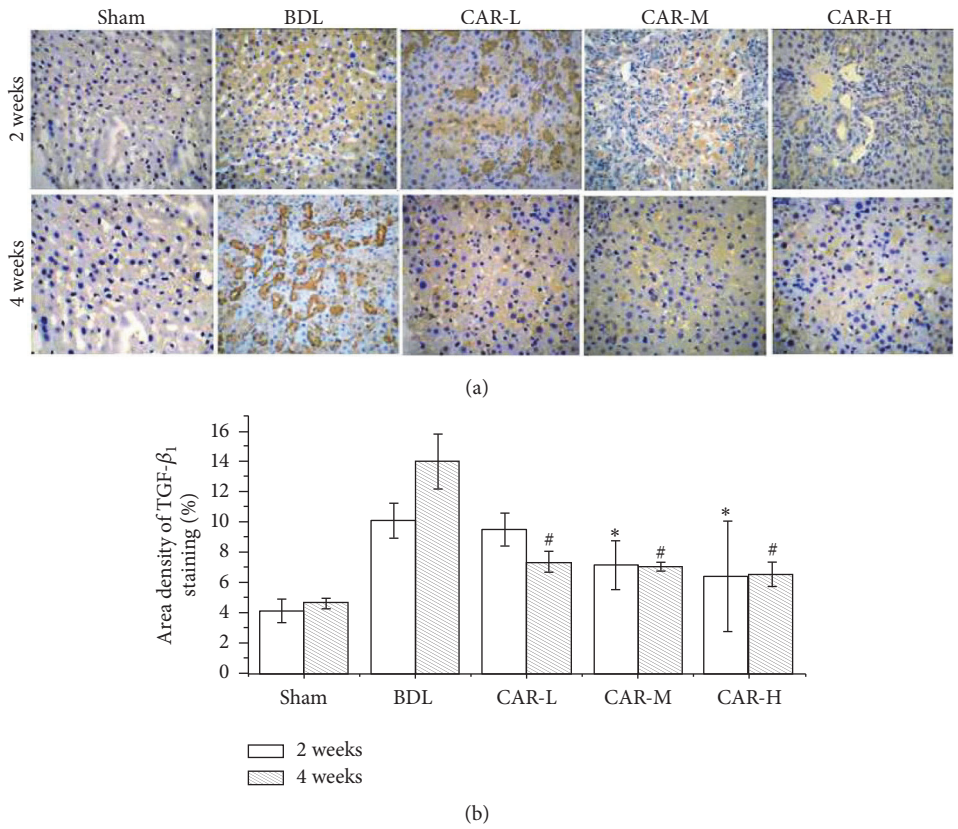

Figure 5: Expression of TGF-β_1 by immunohistochemical staining (magnification ×200). The expression of TGF-β_1 was significantly decreased after carvedilol therapy. $^{*}P < 0.01$ *versus* BDL group for 2 weeks; $^{\#}P < 0.01$ *versus* BDL group for 4 weeks.

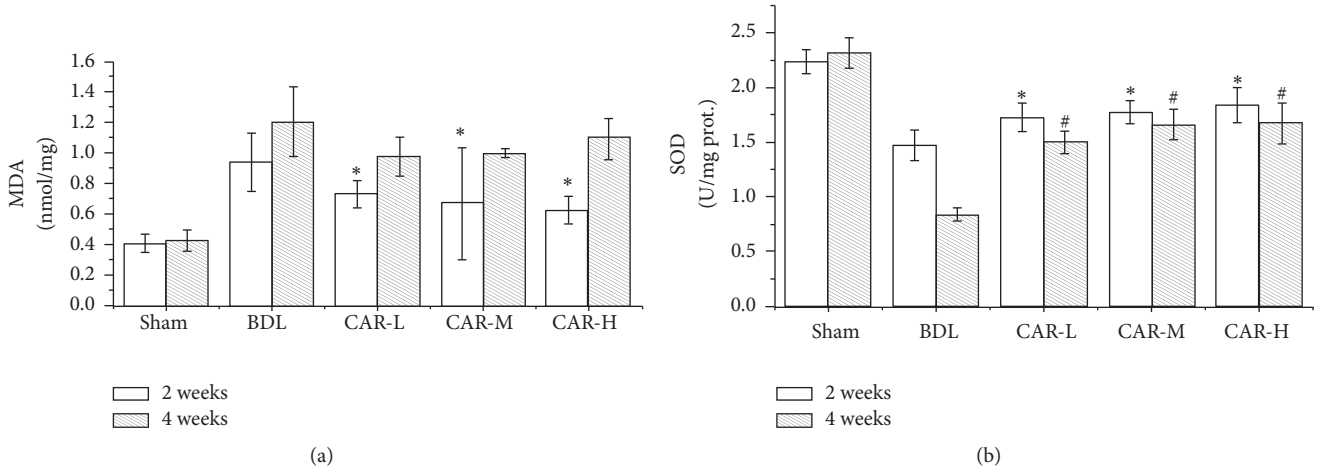

Figure 6: Effect of carvedilol on oxidative stress markers. (a) The MDA level was markedly decreased after carvedilol treatment for 2 weeks. $^{*}P < 0.01$ *versus* BDL group. However, no statistical differences were found compared with the BDL group after applying carvedilol in different doses for 4 weeks. (b) SOD activities were markedly higher after carvedilol treatment. $^{*}P < 0.01$ *versus* BDL group for 2 weeks; $^{\#}P < 0.01$ *versus* BDL group for 4 weeks.

activities in the CAR-L, CAR-M, and CAR-H groups were higher than those in the BDL group (1.73 ± 0.13, 1.78 ± 0.11, and 1.84 ± 0.16 *versus* 1.48 ± 0.14; $P < 0.01$, $P < 0.01$, and $P < 0.01$, resp.), while no marked differences were found among the three carvedilol-treated groups. Similarly, four weeks after BDL, SOD activities in the CAR-L, CAR-M, and CAR-H groups were higher than those in the BDL group (1.50 ± 0.10, 1.66 ± 0.14, and 1.67 ± 0.19 *versus* 0.84 ± 0.06; $P < 0.01$, $P < 0.01$, and $P < 0.01$, resp.) (Figure 6(b)).

4. Discussion

Carvedilol is a nonselective beta-blocker with potent antioxidant and free radical scavenging properties, which is used in the treatment of portal hypertension commonly associated with chronic liver diseases. Considering these powerful antioxidant properties of carvedilol, we predicted that carvedilol may exert an antifibrotic effect on chronic liver injury. This means carvedilol has additional clinical benefits. So, in the present study, we investigated the efficacy of carvedilol on BDL-induced hepatic fibrosis and the potential mechanisms involved. Three dosages of carvedilol treatment for 2 weeks and 4 weeks were used, which was beneficial for observing the curative effect on different stages of fibrosis.

In the study, H&E and Masson staining confirmed the established hepatic fibrosis model. The liver inflammatory and fibrous formations were markedly alleviated by carvedilol treatment. Hepatic fibrosis is characterized by abnormal accumulation of ECM, which is changed not only in quality but also in quantity. In normal liver, the low-density basement membrane-like matrix in the space of Disse is mainly composed of collagens IV and VI. However, the fibrillar collagens including collagens I and III and fibronectin are markedly increased in hepatic fibrosis [1]. This indicated that carvedilol diminished the expression of type I, III, and IV collagens in a dose-dependent manner. Determination of hydroxyproline content in liver tissues is regarded as a good method for quantifying fibrosis and evaluating the efficacy of new antifibrotic agents. In the study, the results implied that carvedilol administration significantly decreased the content of hydroxyproline. TGF-β is the mostly potent fibrogenic cytokine, which has three major isoforms (TGF-β_1, TGF-β_2, and TGF-β_3). TGF-β_1 is the principal isoform implicated in liver fibrosis. The activated TGF-β_1 combines with Smad proteins via its cognate receptors, which enhances the transcription of target genes, including collagens I and III [11, 12]. The results confirmed that carvedilol administration strongly reduced TGF-β_1 expression. Therefore, we inferred that the inhibition of TGF-β_1 by carvedilol was one of the pathways for decreasing collagen expression.

HSCs are typically found in the space of Disse in a quiescent state [13]. HSCs may be activated to myofibroblasts expressing α-SMA by several stimuli such as cytokines and inflammatory mediators. Activated HSCs migrate to and proliferate in sites of liver injury, synthesize ECM components, and upregulate the expression levels of α-SMA and collagen matrices [14]. Hence, α-SMA is a marker of HSC activation and proliferation. The results of α-SMA expression showed that carvedilol administration inhibited HSC activation. Furthermore, α-SMA and TUNEL double staining demonstrated that carvedilol increased the apoptosis of activated HSC. Regulating the biologic behavior of HSC may be one of the reasons for carvedilol to prevent the progression of hepatic fibrosis.

Hepatic fibrosis occurs because of the synthesis and excessive deposition of ECM in the space of Disse along with insufficient ECM degradation. The equilibrium between MMPs and TIMPs mainly determines the homeostasis of ECM. MMPs are the main enzymes responsible for ECM degradation and TIMPs are their specific inhibitors [15]. In the early stage of hepatic fibrogenesis, MMP-2 would degrade the normal ECM around HSCs, which accelerates the HSCs activation [16]. In the late stage, MMPs including MMP-2 are beneficial to the treatment of hepatic fibrosis through degrading ECM. Activated HSCs upregulate the expressions of TIMP-1 and TIMP-2 [17]. TIMP-1 not only restrains the ability of MMPs, but also inhibits the apoptosis of activated HSCs [18]. In the study, carvedilol was shown to upregulate MMP-13 expression. Meanwhile, it downregulated the expressions of TIMP-1 and TIMP-2 in a dose-dependent manner. However, MMP-2 expression was different from MMP-13. After the two-week carvedilol treatment, MMP-2 expression was decreased compared with that in the BDL group, but it markedly increased after the 4-week carvedilol treatment. Hence, we speculated that carvedilol could prevent the activation of HSCs through restraining MMP-2 expression in the early stage of fibrogenesis. In the late stage, carvedilol upregulated the expressions of MMP-2 and MMP-13, which was beneficial for ECM degradation.

Bile duct ligation is an established method for investigating cholestasis and hepatic fibrosis, which leads to changes in the equilibrium between antioxidant and prooxidant activities [19]. The deposition of hydrophobic bile acids damages the mitochondrial electron transport chain and enhances the production of ROS. ROS plays an important role in amplifying the inflammatory response, stimulating the production of profibrogenic mediators, and initiating hepatic fibrogenesis. Therefore, inhibiting oxidative stress can hinder the progression of hepatic fibrosis. We investigated the influence of carvedilol on oxidative stress condition through determining MDA level and SOD activity. MDA is the main product of lipid peroxidation and its concentration is presented as the total level of lipid peroxidation products [20]. After carvedilol treatment for 2 weeks, the MDA level was markedly decreased compared with that in the BDL group, while no statistical difference was found among the three carvedilol-treated groups. Unexpectedly, after carvedilol treatment for 4 weeks, the MDA level was not decreased. This demonstrated that low dosage of carvedilol could decrease the level of MDA in the early stage of liver fibrosis. However, the antioxidant efficacy was decreased with the passage of time. As a free radical scavenging enzyme, SOD protects the biological systems from oxidative stress. The current study showed a distinct decrease of SOD activity in BDL-induced liver fibrosis. On the other hand, it was significantly increased after carvedilol treatment. Thus, we concluded that carvedilol reduced the oxidative stress through decreasing the MDA level and upregulating the SOD activity. The efficacy was more obvious in the early stage of fibrogenesis.

In summary, carvedilol plays a preventive role in a dose-dependent fashion in the progression of hepatic fibrosis induced by BDL, which is associated with decreased TGF-β_1 expression, increased HSCs apoptosis, and increased ratio of MMPs/TIMPs, as well as its antioxidant property. Consequently, carvedilol treatment as early as possible in the maximum dosage that patients are able to bear may be beneficial for preventing hepatic fibrosis progression.

Disclosure

Xiaopeng Tian, Chunhong Zhao, and Jinbo Guo are the first authors. They contributed equally to the manuscript. The funders were not involved in data analysis or interpretation.

Competing Interests

The authors declare that there are no competing interests regarding the publication of this paper.

Authors' Contributions

Xiaopeng Tian, Chunhong Zhao, and Jinbo Guo contributed equally to this manuscript. Xiaopeng Tian, Chunhong Zhao, and Jinbo Guo performed rats experiments, analyzed the data, and discussed the results, while Jinbo Guo drafted the manuscript. Xiaolan Zhang participated in experiment design and coordination, helped to draft the manuscript, and gave the final approval of the version to be published.

Acknowledgments

This work was supported by Research Grant of the Second Hospital of Hebei Medical University. The authors would like to thank all the members of the Hebei Key Laboratory of Gastroenterology (Shijiazhuang, China) for their contributions to this work.

References

[1] Y. A. Lee, M. C. Wallace, and S. L. Friedman, "Pathobiology of liver fibrosis: a translational success story," *Gut*, vol. 64, no. 5, pp. 830–841, 2015.

[2] E. Arriazu, M. R. de Galarreta, F. J. Cubero et al., "Extracellular matrix and liver disease," *Antioxidants and Redox Signaling*, vol. 21, no. 7, pp. 1078–1097, 2014.

[3] S. L. Friedman, "Mechanisms of hepatic fibrogenesis," *Gastroenterology*, vol. 134, no. 6, pp. 1655–1669, 2008.

[4] I. Bingül, C. Başaran-Küçükgergin, A. F. Aydin et al., "Betaine treatment decreased oxidative stress, inflammation, and stellate cell activation in rats with alcoholic liver fibrosis," *Environmental Toxicology and Pharmacology*, vol. 45, pp. 170–178, 2016.

[5] K. Richter and T. Kietzmann, "Reactive oxygen species and fibrosis: further evidence of a significant liaison," *Cell and Tissue Research*, vol. 365, no. 3, pp. 591–605, 2016.

[6] K. Shimada, E. Hirano, T. Kimura, M. Fujita, and C. Kishimoto, "Carvedilol reduces the severity of atherosclerosis in apolipoprotein E-deficient mice via reducing superoxide production," *Experimental Biology and Medicine*, vol. 237, no. 9, pp. 1039–1044, 2012.

[7] P. Budni, R. C. Pedrosa, E. M. Dalmarco, J. B. Dalmarco, T. S. Frode, and D. W. Filho, "Carvedilol enhances the antioxidant effect of vitamins E and C in chronic Chagas heart disease," *Arquivos Brasileiros de Cardiologia*, vol. 101, no. 4, pp. 304–310, 2013.

[8] J.-N. Zhu, R. Chen, Y.-H. Fu et al., "Smad3 inactivation and MiR-29b upregulation mediate the effect of carvedilol on attenuating the acute myocardium infarction-induced myocardial fibrosis in rat," *PLoS ONE*, vol. 8, no. 9, Article ID e75557, 2013.

[9] H.-C. Lin, Y.-T. Y.-T. Huang, H.-C. Wei et al., "Hemodynamic effects of one week of carvedilol administration on cirrhotic rats," *Journal of Gastroenterology*, vol. 41, no. 4, pp. 361–368, 2006.

[10] N. Hamdy and E. El-Demerdash, "New therapeutic aspect for carvedilol: antifibrotic effects of carvedilol in chronic carbon tetrachloride-induced liver damage," *Toxicology and Applied Pharmacology*, vol. 261, no. 3, pp. 292–299, 2012.

[11] F. Xu, C. Liu, D. Zhou, and L. Zhang, "TGF-β/SMAD pathway and its regulation in hepatic fibrosis," *Journal of Histochemistry and Cytochemistry*, vol. 64, no. 3, pp. 157–167, 2016.

[12] U. E. Lee and S. L. Friedman, "Mechanisms of hepatic fibrogenesis," *Best Practice and Research: Clinical Gastroenterology*, vol. 25, no. 2, pp. 195–206, 2011.

[13] M. Sarem, R. Znaidak, M. Macías, and R. Rey, "Hepatic stellate cells: it's role in normal and pathological conditions," *Gastroenterologia y Hepatologia*, vol. 29, no. 2, pp. 93–101, 2006.

[14] M. J. P. Arthur, "Fibrogenesis II. Metalloproteinases and their inhibitors in liver fibrosis," *American Journal of Physiology—Gastrointestinal and Liver Physiology*, vol. 279, no. 2, pp. G245–G249, 2000.

[15] R. Visse and H. Nagase, "Matrix metalloproteinases and tissue inhibitors of metalloproteinases: structure, function, and biochemistry," *Circulation Research*, vol. 92, no. 8, pp. 827–839, 2003.

[16] J. Kurzepa, A. Mądro, G. Czechowska et al., "Role of MMP-2 and MMP-9 and their natural inhibitors in liver fibrosis, chronic pancreatitis and non-specific inflammatory bowel diseases," *Hepatobiliary and Pancreatic Diseases International*, vol. 13, no. 6, pp. 570–579, 2014.

[17] J. P. Iredale, R. C. Benyon, M. J. P. Arthur et al., "Tissue inhibitor of metalloproteinase-1 messenger RNA expression is enhanced relative to interstitial collagenase messenger RNA in experimental liver injury and fibrosis," *Hepatology*, vol. 24, no. 1, pp. 176–184, 1996.

[18] F. R. Murphy, R. Issa, X. Zhou et al., "Inhibition of apoptosis of activated hepatic stellate cells by tissue inhibitor of metalloproteinase-1 is mediated via effects on matrix metalloproteinase inhibition. Implications for reversibility of liver fibrosis," *Journal of Biological Chemistry*, vol. 277, no. 13, pp. 11069–11076, 2002.

[19] M. J. Vázquez-Gil, M. J. Mesonero, O. Flores et al., "Sequential changes in redox status and nitric oxide synthases expression in the liver after bile duct ligation," *Life Sciences*, vol. 75, no. 6, pp. 717–732, 2004.

[20] A. C. Donepudi, L. M. Aleksunes, M. V. Driscoll, N. P. Seeram, and A. L. Slitt, "The traditional ayurvedic medicine, Eugenia jambolana (Jamun fruit), decreases liver inflammation, injury and fibrosis during cholestasis," *Liver International*, vol. 32, no. 4, pp. 560–573, 2012.

Hindawi
BioMed Research International
Volume 2017, Article ID 1252647, 8 pages
https://doi.org/10.1155/2017/1252647

Research Article

Increased ERp57 Expression in HBV-Related Hepatocellular Carcinoma: Possible Correlation and Prognosis

Miao Liu,[1,2] Lingyao Du,[1,2] Zhiliang He,[1,2] Libo Yan,[1,2] Ying Shi,[1,2] Jin Shang,[1,2] and Hong Tang[1,2]

[1] *Center of Infectious Diseases, West China Hospital, Sichuan University, Chengdu 610041, China*
[2] *Division of Infectious Diseases, State Key Laboratory of Biotherapy and Cancer Center, West China Hospital, Sichuan University and Collaborative Innovation Center for Biotherapy, Chengdu 610041, China*

Correspondence should be addressed to Hong Tang; htang6198@hotmail.com

Received 20 December 2016; Accepted 13 February 2017; Published 8 March 2017

Academic Editor: Shanhong Tang

Aim. ERp57 is involved in virus induced endoplasmic reticulum stress (ERS) and plays an important role in tumorigenesis. This study aimed to find whether HBV infection altered ERp57 expression and whether ERp57 regulation was involved in hepatitis B virus-related hepatocellular carcinoma (HBV-HCC) genesis. *Materials and Methods.* HBV-HCC tissues, chronic hepatitis B (CHB) liver tissues, and normal liver tissues were acquired. ERp57 expressions in these tissues were detected through immunohistochemistry (IHC). And ERp57 expression in liver cell line L02, HBV replicative liver cell line L02-pHBV4.1, and HCC cell lines were detected through western blot for verification. Then medical data on patients providing HCC tissues were collected and analyzed along with ERp57 expression. *Results.* Higher ERp57 expression was found in HCC and CHB tissues ($p < 0.001$). And HCC cell lines and L02-pHBV4.1 presented higher ERp57 expression as well. In patients, ERp57 expression showed significant differences between death and survival groups ($p = 0.037$). And cumulative survival in patients with higher ERp57 (score $\geqslant 8.75$) is significantly lower ($p = 0.009$). *Conclusion.* Our study found increased expression of ERp57 in HBV-HCC. Such altered expression could be related to HBV infection and high ERp57 expression may lead to poor prognosis of HBV-HCC patients.

1. Background

Hepatitis B virus (HBV) infection is one of the leading causes of hepatocellular carcinoma [1]. Although its mechanisms has been studied for decades, there is still a lot of information that remains unknown. Recent studies have confirmed that some host factors interacting with HBV were involved in viral tumorigenesis, resulting in alternation of host cell biological characteristics [2–4]. The endoplasmic reticulum (ER), where viral DNA replicates and viral proteins are synthesized, could be easily influenced by virus. When virus infects cells, plenty of unfolding or misfolding proteins aggregates in ER to generate a stress. Series of procedures, called endoplasmic reticulum stress (ERS) response, would be triggered to ease it afterwards. And overresponse of ERS would trigger overtranscription of target genes downstream including oncogenes. Endoplasmic reticulum proteins (ERps) play critical roles in ERS and many proteins such as ERp29, ERp72, and calreticulin identified to be ERS concerning [5–8].

In 1999, Oliver found that ERp57 could interact with calreticulin, influencing the folding of newly synthesized proteins [9]. As an important protein disulfide isomerase (PDI), ERp57/GRP58 has been named after abbreviation of endoplasmic reticulum resident protein 57 or 58 kDa glucose-regulated protein. It catalyzes formation, decomposition, and isomerization of disulfide bond, working as a multifunctional protein in kinds of biological procedures [10]. In tumorigenesis, ERp57 presents contradictory roles among different tumors. Low expression of ERp57 in gastric cancer patients would lead to poor prognosis [11]. However, high expression in ovarian cancer patients would result in drug resistance and lead to poor prognosis as well [12]. In liver diseases, ERp57 is suggested to be involved in several hepatic disorders.

Table 1: Detailed criteria of Axiotis Score*.

Percentage score		Intensity score	
0	0~10% positive cells	0	No color
1	11~25% positive cells	1	Yellow
2	26~50% positive cells	2	Brown
3	51~75% positive cells	3	Tan
4	76~100% positive cells		

*The sum of the two scores equaled the sum score. And five different sum scores from random view under 400x magnification were acquired for a mean sum score. The assessments were implemented by two pathologists unaware of the tissue section arrangement. If there were differences in their opinions, extra mean would be calculated with the two mean sums for final score.

However, there is no specific study focusing on its roles in HBV-related hepatocarcinogenesis.

So we conducted this study, trying to clarify whether HBV infection altered ERp57 expression and whether ERp57 regulation was involved in hepatitis B virus-related hepatocellular carcinoma (HBV-HCC) genesis.

2. Methods

2.1. Study Subjects. Tissue sections of HBV-HCC were obtained from pathologic specimen bank of West China Hospital, Sichuan University. Each set of tissues contained a cancer tissue section, an adjacent one and a distal one. Patients providing these samples were part of pathologically diagnosed HBV-HCC patients in West China Hospital in 2012. Their medical data were collected via electronic medical system. Their prognosis was acquired via telephone follow-up.

The chronic hepatitis B (CHB) liver sections were acquired from CHB patients consulting in West China Hospital when liver biopsy was needed to make therapeutic decision. Normal liver sections were acquired from the specimen bank in Department of Forensic Pathology, West China School of Basic and Forensic Medicine, Sichuan University.

HCC cell lines including Huh7, HepG2, and HepG2.2.15, HBV replicative normal liver cell line L02-pHBV4.1, and normal liver cell line L02 were stored in Division of Infectious Diseases, State Key Laboratory of Biotherapy and Cancer Center.

2.2. Study Method

2.2.1. Detection of ERp57 Expression in Tissue Samples. Immunohistochemistry (IHC) was used to detect ERp57 expression in tissues. The primary antibody was a rabbit polyclonal IgG to ERp57 (sc-28823, Santa Cruz, USA). And the secondary antibody was part of EnVision™ G2 Systems (Dako, Glostrup, Denmark). With 3,3- diaminobenzidine as reagent to horseradish peroxidase (HRP) linked to the secondary antibody, ERp57 were stained. Nucleus was counterstained with hematoxylin then. After mounting, tissue sections were scored according to Axiotis standard. The percentage of positive cells and its staining intensity were evaluated. The detailed scoring criteria were in Table 1.

Table 2: Sequences of primers used in RT-PCR.

Primer name	Sequence
ERp57 forward primer	5′-CTCCTCGCCTCCGCCTCAGA-3′
ERP57 reverse primer	5′-AGCCCACCACCGAGGCATCT-3′
GAPDH forward primer	5′-ACCCACTCCTCCACCTTTGA-3′
GAPDH reverse primer	5′-CTGTTGCTGTAGCCAAATTCGT-3′

2.2.2. Detection of ERp57 Transcription and Expression in Cells. Total RNA was extracted from cells with Trizol (ThermoFisher, USA) and reversely transcribed into cDNA. RT-PCR was applied to detect ERp57 transcription with Fast Start Universal SYBR Green Master in light Cycler 96 (Roche). Detailed information of primers used in RT-PCR was shown in Table 2.

Cells were lysed for total proteins. After quantitation, total proteins were separated with electrophoresis in SDS-polyacrylamide gel and transferred to PVDF membrane. With same multifunctional primary antibody as before and HRP-linked goat against rabbit secondary antibody (ZSGB-BIO, Beijing, China), ERp57 were marked and visualized via chemiluminescent substrate (ThermoFisher, USA) and ChemiDoc™ MP imaging system (Bio-Rad, USA). Then band intensity of ERp57 expression was semiquantified in the imaging system.

2.3. Statistical Analysis. All data were processed and analyzed in SPSS 18.00. Enumeration data were described with percentage and analyzed with chi-square test. Measurement data were analyzed for normality first. If the data was normal, it would be described with mean and standard deviation (SD), analyzed with t-test. Otherwise it would be described with median and interquartile range (IQR), analyzed with u test. Relationship between associated factors, ERp57 expression, and prognosis were analyzed with correlation or regression. The prognosis was analyzed with cumulative survival with Mantel-Cox test.

2.4. Ethics Approval and Consent to Participate. The biological samples were acquired for medical or forensic purpose other than our study originally. Samples of HCC tissues were acquired according to surgical resection of tumors. And samples from CHB patients were originally used for assessment of antiviral indications. Normal tissues were originally prepared for medicolegal expertise. Informed consent was signed by patients or their relatives when these actions happened and additional editions were acquired at the same time for samples' further usage of investigational purpose. When follow-up phone calls were made to patients or their relatives, oral permissions on their tissue sections and medical data to be applied in this study were acquired as well. All the procedures were approved and supervised by Ethics Committee of West China Hospital, Sichuan University.

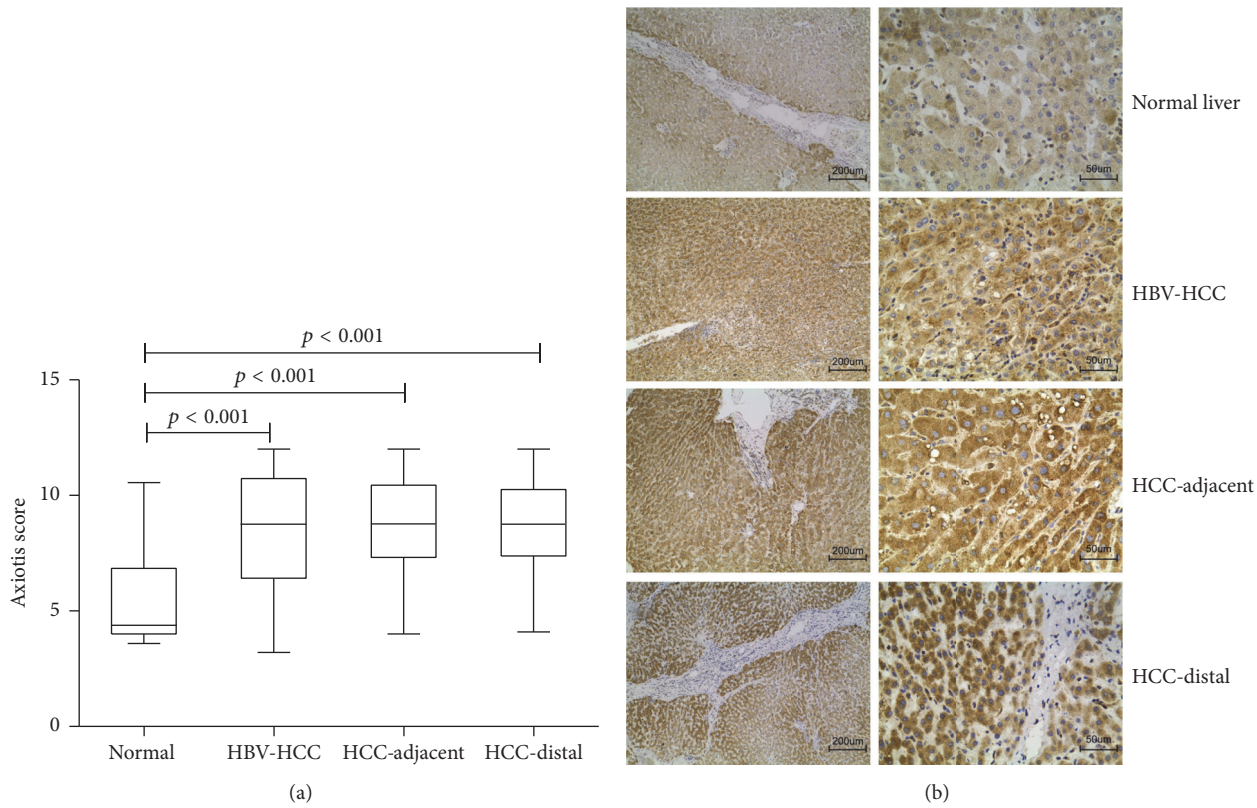

Figure 1: ERp57 expression in HCC liver tissues. (a) Statistical diagram of ERp57 expression score in normal livers and HCC tissues. (b) Representative images of IHC stained ERp57 in normal livers and HCC tissues.

3. Results

3.1. ERp57 Expression in Different Kinds of Liver Tissues. A total of 66 sets of HBV-HCC tissues, 57 CHB tissues, and 16 normal liver tissues were acquired in this study. And positive ERp57 expression was found in all kinds of tissues through IHC. Though no significant difference was found between the median Axiotis score of cancer tissues, adjacent tissues and distal tissues (10.725 ± 2.325 versus 10.45 ± 1.45 versus 10.25 ± 1.36), respectively, their ERp57 expression was significantly higher compared to normal liver tissues (4.375 ± 2.84) (Figure 1). Thus ERp57 expression was altered not only in HBV-HCC tissues but also in HBV-HCC related adjacent and distal tissues. It suggested that the alternation of ERp57 expression could be related to cellular malignant transformation.

However, the distal tissues showed little manifestation of tumor cells but a status of HBV infection, so HBV infection might be another impact factor to ERp57 expression. To clarify this, CHB liver tissues were compared with normal ones. Its median Axiotis score of ERp57 expression was significantly increased compared to normal liver tissues (4.375 ± 2.84 versus 5.8 ± 4.025, $p < 0.001$) (Figure 2). Such result suggested that HBV infection could be another promoting factor of high ERp57 expression.

3.2. ERp57 Expression in Different Kinds of Liver Cell Lines. Experimental results in cell lines confirmed the correlation between cellular malignant transformation, HBV infection, and ERp57 expression. ERp57 expression in HCC cell lines including Huh7, HepG2, and HepG2.2.15 was significantly increased compared to normal liver cell L02, proving that cellular malignant transformation promoted ERp57 expression. As preconceived, the ERp57 expression in Huh7 and HepG2 was only increased moderately. But it was increased strongly in HepG2.2.15 cells which mimicked a status of HBV-HCC (Figure 3).

L02-pHBV4.1 was established by stably transfecting HBV replicative plasmid pHBV4.1 into L02. It mimicked the status of HBV infected liver without inflammatory cell infiltration and it is applicable to investigate the influence from HBV to host cytokines. In this cell, ERp57 transcription and expression were significantly increased compared to L02, suggesting that HBV did promote ERp57 expression and such influence could be relevant to ERp57 transcription (Figure 4).

3.3. Correlation between ERp57 Expression in HBV-HCC Tissues and Prognosis. In the 66 HBV-HCC patients providing tissues, male patients took the minority ($N = 8$). The mean age was 50.23 ± 11.60 years old. Alpha fetal protein (AFP) in these patients was distributed widely (0.92-495383.00 ng/ml). Most patients only showed moderately elevated ALT (47 ± 38.5 IU/L). Most patients ($N = 52$) were diagnosed as HBeAg negative CHB. Viral loads of the whole crowed located at a relatively low level (500 ± 6167.5 IU/mL). According to radiological examinations, surgery records, and pathological reports, Ishake score of the 66 distal tissues showed a median



Figure 2: ERp57 expression variation in CHB liver tissues. (a) Statistical diagram of ERp57 expression score in normal livers and CHB liver tissues. (b) Representative images of IHC stained ERp57 in normal livers and CHB liver tissues.

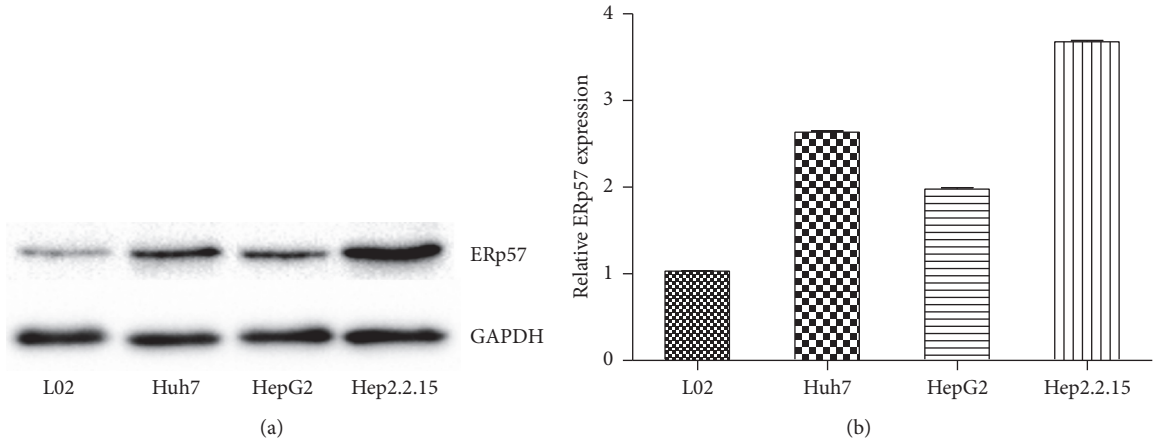

Figure 3: ERp57 expression in normal liver cell line and HCC cell lines. (a) ERp57 expression detected by western blot in different cell lines with GAPDH as internal reference. (b) Statistical diagram of Quantity One captured western blot detected ERp57 expression data. The ERp57/GAPDH ratios of other cell lines were transformed into relative ratio according to the ERp57/GAPDH ratio of L02 cells as "1."

value of 5 ± 2, implying most patients had background of cirrhosis. And 46 patients suffered tumors with size ⩾ 5 cm. Moreover, high differentiated tumor was found in 6 patients, while moderate differentiation was found in 50 patients and poor differentiation was found in 10 patients. Capsule invasion, margin involvement, tumor thrombus, and metastasis were found in 39, 3, 21, and 7 patients, respectively. Till the date of follow-up call made (December, 2015), 28 patients survived and 19 patients died of HCC related complications. The other 19 patients were lost to follow-up (Table 3).

Patients' biological characteristics and factors related to the disease status were analyzed for their correlation to ERp57 expression in cancer tissues. Through univariate analysis, occurrence of tumor thrombus and prognosis were identified as two significant factors related to ERp57 expression in cancer tissues in this crowd ($p = 0.021$ and 0.037) (Table 3). As patients with tumor thrombus would encounter poor prognosis more frequently, the significant relationship between ERp57 expression and tumor thrombus also reminded that ERp57 was an essential factor related to prognosis.

So we excluded patients lost to follow-up, dividing the rest of them into two groups according to their prognosis (death or survival). The occurrence of tumor thrombus was obviously more frequent in patients with poor prognosis ($p = 0.003$) and ERp57 expression did show significant differences between the death and survival groups (10.6 + 4.15 versus 8.025 + 3.4, $p = 0.037$) (Table 4). Then we calculated an ROC curve to identified a cut-off value (Axiotis score = 8.75) and divided whole crowd into two groups according to the criterion. In the follow-up period of 36 months, the cumulative survival in group with score ⩾ 8.75 is significantly lower compared to group with score < 8.75 ($p = 0.009$) (Figure 5). All these results suggested that HBV-HCC patients with higher expression of ERp57 in cancer tissues would encounter shorter life expectancy.

4. Discussion

The solid tumor cells live in an acid environment with low oxygen because tumor itself usually develops faster

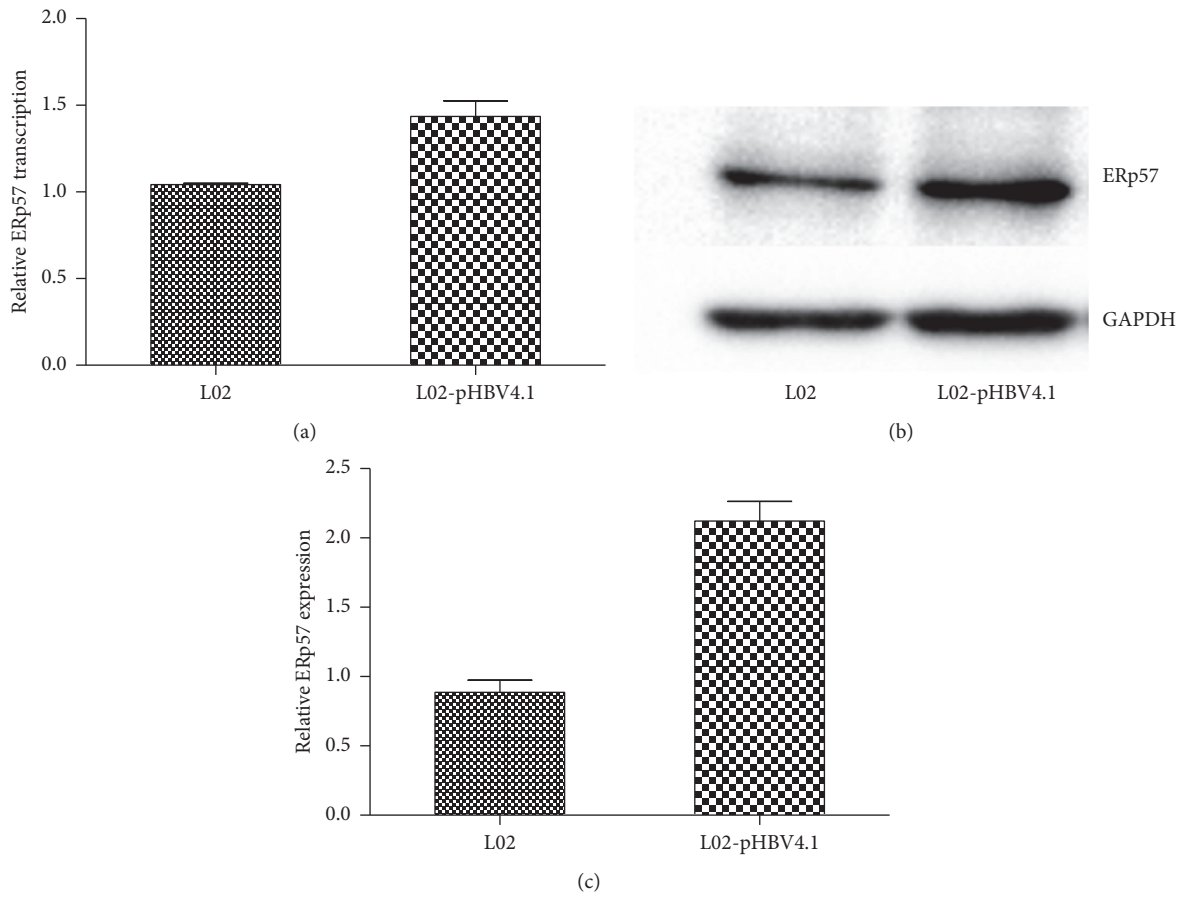

Figure 4: Transcription and expression level of ERp57 in normal liver cell line L02 and HBV replicative liver cell line L02-pHBV4.1. (a) RT-PCR detected relative ERp57 mRNA level in L02 and L02-pHBV4.1 with GAPDH as internal reference. (b) ERp57 expression detected by western blot in L02 and L02-pHBV4.1 with GAPDH as internal reference. (c) Statistical diagram of Quantity One captured western blot detected ERp57 expression data. The ERp57/GAPDH ratios of HBV infected cell line, L02-pHBV4.1, was transformed into relative ratio according to the ERp57/GAPDH ratio of L02 cells as "1."

Table 3: Univariate analysis of factors related to ERp57 expression in HCC tissue sections.

Factors	Frequency/media (mean) ± IQR(SD)	Mann–Whitney test (Z)/Pearson test (r)/Kruskal-Wallis test (X^2)	P value
Gender (male/female)	8/58	−0.079	0.937
Age (year)	50.23 ± 11.60	−0.169	0.176
AFP (ng/ml)	198.3 ± 1690.84	0.213	0.091
ALT (IU/L)	47 ± 38.5	−0.105	0.408
HBeAg (positive/negative)	14/52	−1.044	0.297
HBVDNA (IU/mL)	500 ± 6167.5	0.089	0.480
Ishak Score	5 ± 2	−0.210	0.090
Tumor Size (<5 cm/⩾5 cm)	20/46	−1.487	0.137
Differentiated degree (poor/moderate/high)	10/50/6	−1.347	0.178
Capsule invasion (positive/negative)	39/27	−1.742	0.081
Margin involvement (positive/negative)	3/63	−0.893	0.372
Tumor thrombus (positive/negative)	21/45	−2.3	0.021
Metastasis (positive/negative)	7/59	−1.063	0.288
Prognosis (death/survival/lost to follow-up)	19/28/19	−2.083	0.037

Table 4: Univariate analysis of factors related to prognosis in patients within follow-up ($N = 47$).

Factors	Death ($N = 19$)	Survival ($N = 28$)	Mann–Whitney test (Z)/Pearson test (r)/Kruskal-Wallis test (X^2)	P value
Gender (male/female)	17/2	25/3	−0.000	1.000
Age (year)	46 ± 25	50.5 ± 13.75	−0.651	0.515
AFP (ng/ml)	528.8 ± 3064.72	93.62 ± 1153.70	−0.902	0.367
ALT (IU/L)	37 ± 23.5	46 ± 28	−1.206	0.228
HBeAg (positive/negative)	2/17	8/20	2.201	0.168
HBVDNA (IU/mL)	500 ± 0	500 ± 10775	−1.192	0.233
Ishak Score	4 ± 2	5 ± 2	−0.906	0.365
Tumor Size (<5 cm/⩾5 cm)	5/14	11/17	0.848	0.357
Differentiated degree (poor/moderate/high)	3/16/0	3/20/5	3.863	0.145
Capsule invasion (positive/negative)	9/10	15/13	0.174	0.676
Margin involvement (positive/negative)	2/17	1/27	0.916	0.338
Tumor thrombus (positive/negative)	10/9	3/25	9.940	0.003
Metastasis (positive/negative)	3/16	1/27	2.170	0.289
Axiotis score of ERp57 expression in tissue sections	10.6 ± 4.15	8.025 ± 3.4	−2.083	0.037

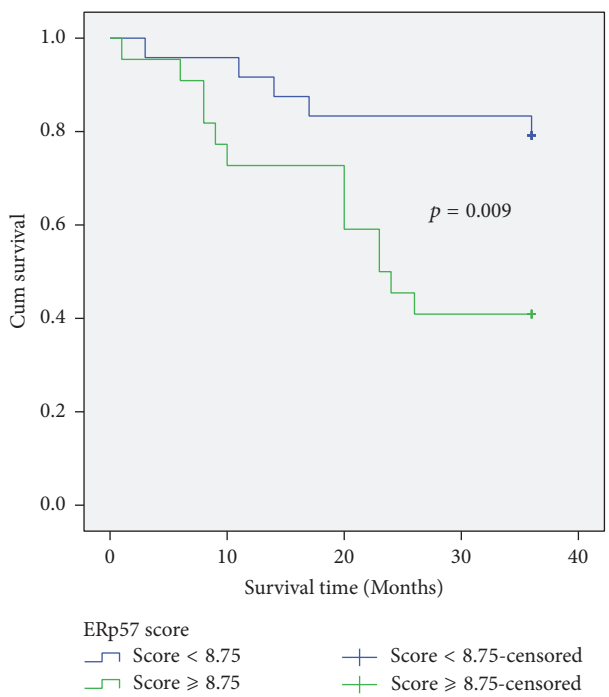

Figure 5: Cumulative Survival in two groups divided by ERp57 expression. Two groups were divided by cut-off value (Axiotis score = 8.75). Blue curve represented the group with ERp57 score < 8.75, while the green curve represented the group with ERp57 score ⩾ 8.75. According to Mantel-Cox test, cumulative survival of these two groups showed significant difference ($p = 0.009$).

than its vascularization [5]. In such an environment, ERS is essential to tumor cells. It activates series of signaling transduction pathway to assist the cell adaptive survival. For example, ERp57 in cells works coordinately with calreticulin to influence folding of newly synthesized proteins. Upregulated ERp57 would induce unfolded protein response (UPR), one type of ERS, to prevent export of unfolded proteins. Through such way, tumor cells could maintain their cellular homeostasis for survival [6, 7]. And when ERp57 joins in transcriptional complex assembly along with STAT3, it could be involved in nuclear signaling pathway to promote cell proliferation. However, ERp57 also participates in formation of major histocompatibility complex class I (MHC I) to influence the immunogenicity of tumor cells. So upregulated ERp57 would accelerate maturation of dendritic cells, enhancing host surveillance and reducing production of negative regulators to antitumor immunity [13].

The controversial function in the mechanism endows ERp57 complicated roles in different kinds of tumors [11, 12, 14]. However, the exact role it played in HBV-HCC remained to be learned. In our study, we found that no matter in HBV-HCC cancer tissues, adjacent tissues, or distal tissues, higher expression of ERp57 was found compared to normal liver tissue. Interestingly, ERp57 expression among the three kinds of HBV-HCC related tissues showed no differences. Such result implied that ERp57 was increased in cell transition to malignancy. And its expression might have been upregulated already before the cells were fully transformed. The fact that cell lines derived from HCC presented higher ERp57

expression than normal liver cells also verified the correlation between malignant transition and ERp57 expression.

The background of HBV infection no matter in HBV-HCC tissues, especially the distal ones, or in HepG2.2.15 cells suggested a possible correlation between HBV infection and ERp57 expression. HBV has been confirmed as a tumorigenesis virus for decades [15]. As the endoplasmic reticulum is an important site of virus replication and progeny virus assembly, plenty of viral proteins aggregate in the ER when virus infected ER, triggering ERS to upregulated ER proteins expression [16]. Previous study has found HCV could upregulate ER proteins such as GRp78 and GRp94 in the liver [17]. As another hepatotropic virus, HBV was confirmed to be involved in the regulation of ER proteins in our study. ERp57 expression was increased both in liver tissues and in cell lines if there was HBV infection.

It was interesting that when we analyzed the relationship between serum HBV viral load and the ERp57 expression in HCC patients, no significant result was found ($p = 0.480$). Such phenomenon seemed not to make sense as HBV was considered to be one of the ERp57 inducers. However, the extremely low level of viremia in HCC patients would be an explanation. Viruses need proper intracellular environment to accomplish their life cycles. As a result, the alternation in HCC cells as well as the host immunity of HCC patients would inhibit the viral replication [18]. In our study, the median viral load is 2 log 10 IU/mL. Statistically, extremely low serum HBV DNA would decrease the difference of serum viral load among patients and lead to an insufficient analysis. Moreover, the cells had been malignantly transformed already. As we found that HCC cell lines presented higher expression of ERp57 (Figure 3), the impact from HBV to ERp57 expression would be covered by the malignant transformation to some degree. In recent studies, scientists proved again that the serum HBV DNA and intracellular cccDNA and total DNA were significantly higher in CHB patients than in HCC patients, and they also found an inconsistency between serum viral DNA and intracellular viral DNA in HCC patients [19]. So significant relationship might be found if intracellular HBV DNA could be detected other than serum HBV DNA.

ERp57 expression was reported to be associated with prognosis of patients. In gastric cancer where ERp57 presented as a tumor inhibitor, low expression of ERp57 results in poor prognosis [11]. However, the situation was quite different in our study. When possible factors related to ERp57 expression were analyzed, the existence of tumor thrombus and prognosis were the only two significant ones. Portal vein tumor thrombus in HCC is a proved poor prognostic factor [20]. Patients with portal vein tumor thrombus were reported to encounter a median survival time about 4 months [21, 22]. So the result suggested a correlation between high ERp57 expression and poor prognosis. Moreover, when patients were grouped according to their prognosis, ERp57 was increased significantly in the death group. And the cumulative survival analysis revealed that patients with higher ERp57 expression would have shorter survival time. These results proved that ERp57 was involved in the prognosis of HBV-HCC patients and its influence on the occurrence of tumor thrombus could be one way. Other studies supported our findings. A newly reported research demonstrated that *Antrodia cinnamomea* (EEAC), a Chinese herb, decreased ERp57 to suppress HCC migration. Downregulation of ERp57 by siRNA effectively inhibit transwell immigration of HCC cells. It suggested that ERp57 could affect cell proliferation and migration [23].

ERp57 locates in cytoplasm, nucleus, and endoplasmic reticulum. Its dynamic subcellular localization is considered as a key factor to explain its complex action in tumorigenesis. Oncogene activation is vastly related to ERp57 immigration into nucleus as part of transcription complex. As part of STAT-3 transcription complex, ERp57 translocated into nucleus to modulate intracellular gene expression mediated by TORC1 and TORC2, interfering Ref-A1 related DNA repair [24, 25]. And ERp57 also combines with nuclear factor κB (NF-κB), altering its subcellular location [13]. So the correlation between dynamic subcellular localization of ERp57 and its multiple biological function is worth further investigation.

5. Conclusion

Our study found increased expression of ERp57 in HBV-HCC. Such altered expression could be related to HBV infection and high ERp57 expression may lead to poor prognosis of HBV-HCC patients. It provides information on the role ERp57 played in HBV-HCC genesis, guiding us a direction to further investigations in its mechanism.

Competing Interests

There are no competing interests in the article and no permission needs to be acquired for its publication.

Authors' Contributions

Miao Liu and Lingyao Du contributed equally to the manuscript.

Acknowledgments

This work was supported by "973" National Basic Research Program of China (2013CB911302) and Science and Technology Projects of Sichuan Province (2015SZ0049). Basic experiment of this study was supported by Fund 2013CB911302 and clinical follow-up of HCC patients was supported by Fund 2015SZ0049.

References

[1] Y. Huang and A. S. F. Lok, "Viral factors and outcomes of chronic HBV infection," *American Journal of Gastroenterology*, vol. 106, no. 1, pp. 93–95, 2011.

[2] X. Tian, J. Li, Z.-M. Ma, C. Zhao, D.-F. Wan, and Y.-M. Wen, "Role of hepatitis B surface antigen in the development of hepatocellular carcinoma: regulation of lymphoid enhancer-binding factor 1," *Journal of Experimental and Clinical Cancer Research*, vol. 28, no. 1, article 58, 2009.

[3] E. Hildt, B. Munz, G. Saher, K. Reifenberg, and P. H. Hofschneider, "The PreS2 activator MHBs^t of hepatitis B virus activates c-raf-1/Erk2 signaling in transgenic mice," *EMBO Journal*, vol. 21, no. 4, pp. 525–535, 2002.

[4] Y.-W. Li, F.-C. Yang, H.-Q. Lu, and J.-S. Zhang, "Hepatocellular carcinoma and hepatitis B surface protein," *World Journal of Gastroenterology*, vol. 22, no. 6, pp. 1943–1952, 2016.

[5] C. Giampietri, S. Petrungaro, S. Conti, A. Facchiano, A. Filippini, and E. Ziparo, "Cancer microenvironment and endoplasmic reticulum stress response," *Mediators of Inflammation*, vol. 2015, Article ID 417281, 11 pages, 2015.

[6] S. Taouji and É. Chevet, "Modulating endoplasmic reticulum stress in the treatment of cancer," *Medecine/Sciences*, vol. 31, no. 6-7, pp. 667–673, 2015.

[7] E. Chevet, C. Hetz, and A. Samali, "Endoplasmic reticulum stress-activated cell reprogramming in oncogenesis," *Cancer Discovery*, vol. 5, no. 6, pp. 586–597, 2015.

[8] M. Zanetti, J. J. Rodvold, and N. R. Mahadevan, "The evolving paradigm of cell-nonautonomous UPR-based regulation of immunity by cancer cells," *Oncogene*, vol. 35, no. 3, pp. 269–278, 2016.

[9] J. D. Oliver, H. L. Roderick, D. H. Llewellyn, and S. High, "ERp57 functions as a subunit of specific complexes formed with the ER lectins calreticulin and calnexin," *Molecular Biology of the Cell*, vol. 10, no. 8, pp. 2573–2582, 1999.

[10] S. S. Shishkin, L. S. Eremina, L. I. Kovalev, and M. A. Kovaleva, "AGR2, ERp57/GRP58, and some other human protein disulfide isomerases," *Biochemistry (Moscow)*, vol. 78, no. 13, pp. 1415–1430, 2013.

[11] C. M. Leys, S. Nomura, B. J. LaFleur et al., "Expression and prognostic significance of prothymosin-α and ERp57 in human gastric cancer," *Surgery*, vol. 141, no. 1, pp. 41–50, 2007.

[12] L. Cicchillitti, A. Della Corte, M. Di Michele, M. B. Donati, D. Rotilio, and G. Scambia, "Characterisation of a multimeric protein complex associated with ERp57 within the nucleus in paclitaxel-sensitive and -resistant epithelial ovarian cancer cells: the involvement of specific conformational states of β-actin," *International Journal of Oncology*, vol. 37, no. 2, pp. 445–454, 2010.

[13] B. J. Grindel, B. Rohe, S. E. Safford, J. J. Bennett, and M. C. Farach-Carson, "Tumor necrosis factor-α treatment of HepG2 cells mobilizes a cytoplasmic pool of ERp57/1,25D 3-MARRS to the nucleus," *Journal of Cellular Biochemistry*, vol. 112, no. 9, pp. 2606–2615, 2011.

[14] B. Seliger, R. Stoehr, D. Handke et al., "Association of HLA class i antigen abnormalities with disease progression and early recurrence in prostate cancer," *Cancer Immunology, Immunotherapy*, vol. 59, no. 4, pp. 529–540, 2010.

[15] C. De Martel, J. Ferlay, S. Franceschi et al., "Global burden of cancers attributable to infections in 2008: a review and synthetic analysis," *The Lancet Oncology*, vol. 13, no. 6, pp. 607–615, 2012.

[16] T. S. Fung, J. Torres, and D. X. Liu, "The emerging roles of viroporins in ER stress response and autophagy induction during virus infection," *Viruses*, vol. 7, no. 6, pp. 2834–2857, 2015.

[17] S. A. Lozano-Sepulveda, O. L. Bryan-Marrugo, C. Cordova-Fletes, M. C. Gutierrez-Ruiz, and A. M. Rivas-Estilla, "Oxidative stress modulation in hepatitis C virus infected cells," *World Journal of Hepatology*, vol. 7, no. 29, pp. 2880–2889, 2015.

[18] P. Safaie, M. Poongkunran, P. P. Kuang et al., "Intrahepatic distribution of hepatitis B virus antigens in patients with and without hepatocellular carcinoma," *World Journal of Gastroenterology*, vol. 22, no. 12, pp. 3404–3411, 2016.

[19] M. Wang, N. Qiu, S. Lu et al., "Serum hepatitis B surface antigen is correlated with intrahepatic total HBV DNA and cccDNA in treatment-naïve patients with chronic hepatitis B but not in patients with HBV related hepatocellular carcinoma," *Journal of Medical Virology*, vol. 85, no. 2, pp. 219–227, 2013.

[20] J. M. Lee, B. K. Jang, Y. J. Lee et al., "Survival outcomes of hepatic resection compared with transarterial chemoembolization or sorafenib for hepatocellular carcinoma with portal vein tumor thrombosis," *Clinical and Molecular Hepatology*, vol. 22, no. 1, pp. 160–167, 2016.

[21] E. Villa, A. Moles, I. Ferretti et al., "Natural history of inoperable hepatocellular carcinoma: estrogen receptors' status in the tumor is the strongest prognostic factor for survival," *Hepatology*, vol. 32, no. 2, pp. 233–238, 2000.

[22] J. M. Llovet, A. Burroughs, and J. Bruix, "Hepatocellular carcinoma," *Lancet*, vol. 362, no. 9399, pp. 1907–1917, 2003.

[23] Y.-Y. Chen, F.-C. Liu, T.-S. Wu, and M.-J. Sheu, "Antrodia cinnamomea Inhibits migration in human hepatocellular carcinoma cells: the role of ERp57 and PGK-1," *American Journal of Chinese Medicine*, vol. 43, no. 8, pp. 1671–1696, 2015.

[24] S. Chichiarelli, E. Gaucci, A. Ferraro et al., "Role of ERp57 in the signaling and transcriptional activity of STAT3 in a melanoma cell line," *Archives of Biochemistry and Biophysics*, vol. 494, no. 2, pp. 178–183, 2010.

[25] M. H. Choe, J. W. Min, H. B. Jeon et al., "ERp57 modulates STAT3 activity in radioresistant laryngeal cancer cells and serves as a prognostic marker for laryngeal cancer," *Oncotarget*, vol. 6, no. 5, pp. 2654–2666, 2015.

Hindawi
BioMed Research International
Volume 2017, Article ID 8061091, 8 pages
https://doi.org/10.1155/2017/8061091

Research Article

Favorable Outcomes of Chinese HCV-Related Cirrhotic Patients with Sustained Virological Response after Pegylated Interferon Plus Ribavirin Treatment

Geng-lin Zhang,[1,2] You-ming Chen,[1] Ting Zhang,[3] Qing-xian Cai,[1] Xiao-hong Zhang,[1] Zhi-xing Zhao,[1] Chao-shuang Lin,[1] and Zhi-liang Gao[1,4]

[1] *Department of Infectious Diseases, The Third Affiliated Hospital, Sun Yat-Sen University, Guangzhou, China*
[2] *Guangdong Key Laboratory of Liver Disease Research, The Third Affiliated Hospital, Sun Yat-Sen University, Guangzhou, China*
[3] *Department of Ultrasound, The Third Affiliated Hospital, Sun Yat-Sen University, Guangzhou, China*
[4] *Key Laboratory of Tropical Disease Control, Sun Yat-Sen University, Ministry of Education, Guangzhou, China*

Correspondence should be addressed to Chao-shuang Lin; linchaoshuang@126.com and Zhi-liang Gao; zhilianggao@21cn.com

Received 20 October 2016; Revised 8 December 2016; Accepted 4 January 2017; Published 23 January 2017

Academic Editor: Xingshun Qi

Few studies have conducted follow-up investigations of the clinical course in HCV-related cirrhotic patients who achieved a sustained virological response (SVR) with pegylated interferon plus ribavirin treatment (PegIFN + RBV). We investigated the clinical course and laboratory data in a prospective cohort study enrolling HCV-related cirrhotic patients who received PegIFN + RBV between August 2008 and July 2013 in China. Complete blood counts, liver function tests, and HCV-RNA were serially examined. Liver-related complications were recorded. To detect hepatocellular carcinoma (HCC), alpha-fetoprotein assays, and ultrasound scans were repeated at 6-month intervals. Twenty-five patients were enrolled, including 8 patients with decompensation events before treatment. Eighteen patients achieved SVR with a mean follow-up period of 25.78 months. During the follow-up period, only one patient exhibited HCV-RNA positivity and no decompensation events were detected, but 4 patients developed HCC after SVR. APRI decreased more in patients with SVR than in patients with non-SVR (median, −1.33 versus 0.86, $P < 0.001$). The albumin levels and platelet counts significantly increased during the follow-up period after SVR (44.27±4.09 versus 42.63±4.37, $P = 0.037$ and 173.89 ± 87.36 versus 160.11 ± 77.97, $P = 0.047$). These data indicated that HCV-related cirrhotic patients with SVR after PegIFN + RBV may have a favorable clinical course and improvements in laboratory data. Moreover, HCC should be monitored.

1. Introduction

Approximately 25–50 million Chinese were infected with hepatitis C virus (HCV) [1]. Without treatment, 16% of patients with HCV progress to liver cirrhosis within 20 years after infection, and 41% develop liver cirrhosis within 30 years [2]. As the patients infected with HCV age, the risk of developing life-threatening complications (decompensated cirrhosis or hepatocellular carcinoma) is expected to increase [3]. The annual risk of developing decompensated liver diseases has been shown to be 4% in cirrhotic patients. The annual mortality is 13% for patients with decompensated liver disease, and the ten-year survival rate is only 25% [4]. Thus, these cirrhotic patients infected with HCV make a significant burden on public health.

Before the introduction of direct-acting antiviral agents (DAAs), the combination of pegylated interferon and ribavirin (subsequently referred to as PegIFN + RBV) was the approved treatment for chronic hepatitis C (CHC) [5]. The incidence of developing hepatic events (decompensation, hepatocellular carcinoma (HCC) and death) reduced in patients with sustained virological response (SVR) [6–8]. A report showed that interferon therapy could be associated with a reduction of HCC development even in patients without SVR [8]. Moreover, successful antiviral therapy in selected patients waiting for liver transplantation could delay

the disease progression and can prevent the transplanted liver HCV reinfection, subsequently leading to a decrease of posttransplant morbidity and mortality [9–12]. Therefore, eradication of HCV in this population should be urgently considered.

To date, data focused on this topic in Chinese patients are scarce. Thus, to determine the impact of SVR on the clinical outcomes of cirrhotic patients, we conducted this retrospective analysis of data from a prospective cohort study enrolling Chinese patients with HCV-related cirrhosis, treated with PegIFN + RBV and followed up according to standardized criteria. We serially assessed changes in the laboratory data from patients achieving SVR.

2. Patients and Methods

2.1. Study Design. Chinese patients with HCV-related liver cirrhosis who were previously untreated were enrolled into our study to receive PegIFN + RBV treatment at our department between August 2008 and July 2013. Criteria for admission to our study included a positive serum test of anti-HCV and HCV-RNA, cirrhosis proved by liver biopsy, or evidence of an irregular and nodular liver by ultrasonography or magnetic resonance imaging (MRI) together with impaired liver synthetic function. Cirrhotic patients with a history of decompensation events (including ascites, sepsis, variceal bleeding, and hepatic encephalopathy) were included if the Child-Turcotte-Pugh (CTP) score < 9 at enrollment. Patients who met with any of the following criteria were excluded: (1) coexisting with other liver disorders, (2) a positive test of anti-HIV, (3) active drug users or ongoing alcohol consumption, (4) patients with an uncontrolled psychiatric disease, (5) pregnancy, (6) history of organ transplantation, (7) CTP score ≥ 9, and (8) laboratory values for creatinine ≥ 1.5 mg/dL, absolute neutrophil counts < 1000/mL, platelet counts < 50,000/mL, or hemoglobin < 10.0 g/dL.

Patients received a combination of PegIFN-a-2a (Pegasys, Roche, Basel, Switzerland) plus daily RBV for a duration of 48 weeks. Patients were initially treated with PegIFNa-2a (180 μg/week) plus RBV (900 mg/day), and then the dose was decreased or adjusted as a function of hematologic tolerance. Growth factor use (erythropoietin, granulocyte colony-stimulating factor, and/or recombinant human interleukin-11) was used to maintain adherence to therapy. Treatment was discontinued if HCV-RNA loads at week 12 dropped less than 2 log compared with baseline values, or if HCV-RNA loads still can be detected at week 24, or viral breakthrough existed. All patients were required to undergo the follow-up program after termination of treatment. The study was approved by the Ethics Committee of our hospital. All patients provided written informed consent. The study conformed to the ethical guidelines of the 1975 Declaration of Helsinki.

2.2. Assessment of Response to Therapy. A SVR was defined as HCV-RNA negativity determining by the Roche Amplicor™ HCV test (the lower limit of detection was 15 IU/mL) for more than 6 months after therapy, and any other outcome was considered as nonsustained virological responses (non-SVR). Negativity of serum HCV-RNA was assessed at treatment week 4 (rapid virological response, RVR), at treatment week 12 (early virological response, EVR), at treatment week 24 (delayed virological response, DVR), and at the end of treatment (EOT). After EOT, patients who tested positive for HCV-RNA during the follow-up were defined as relapsers.

2.3. Laboratory and Imaging Assessment. Evaluation of the patients involved a medical history, a physical examination, and laboratory tests (including the complete blood counts, biochemical tests). Anti-HCV was assessed using the ARCHITECT system (Abbott Diagnostics, Abbott Park, IL, USA). HCV-RNA loads were measured using the Roche Amplicor HCV test (the lower limit of detection was 15 IU/mL.) according to the manufacturer's instructions. HCV-RNA was detected at baseline (BL), week 4, week 12, week 24, week 36, EOT, and 24 weeks after treatment and the follow-up period. INNO-LiPA HCV II kit assay was used to determine the HCV genotype. Liver biopsy specimens were evaluated by two liver pathology specialists who were blinded to the etiology.

2.4. Follow-Up. The length of the follow-up period was calculated from the starting date of certification of SVR to the last follow-up visit. Complete blood counts, liver function tests, HCV-RNA, and physical examinations were performed every 6 months during follow-up and at the last visit. Liver-related events (ascites, upper gastrointestinal bleeding, and hepatic encephalopathy) were recorded. Ascites was diagnosed by physical examination and/or ultrasound detection. Portosystemic encephalopathy was defined by clinical manifestations. Endoscopy was used to confirm the source of gastroesophageal bleeding if needed. To detect HCC, alpha-fetoprotein (AFP) assays and ultrasound scans were repeated every 6 months. If HCC development was suspected, MRI was performed. HCC was diagnosed according to the guidelines of the European Association for the Study of the Liver [13].

2.5. Statistical Analysis. Continuous variables are expressed as mean and standard deviation or median and range, and categorical variables are reported as the absolute and relative frequencies. The Wilcoxon signed-rank test and analysis of variance (ANOVA) were used to analyze the data. Comparisons between groups were conducted by the Mann–Whitney U test or Student's t test for continuous variables and Fisher's exact probability test for categorical data. Ratios were examined by Pearson's chi-square test. A P value less than 0.05 was considered statistically significant. All statistical analyses were performed using the SPSS 13 software package (SPSS Inc., IL, USA).

3. Results

3.1. Patient Characteristics. Of a total of 28 consecutive HCV-related cirrhotic patients who met the diagnostic criteria,

Table 1: Baseline characteristics of 25 patients with HCV-related cirrhosis stratified based on different responses.

Group	All patients (n = 25)	SVR (n = 18)	Non-SVR (n = 7)	P (SVR versus Non-SVR)
Age (years)	48.76 ± 9.53	46.89 ± 9.14	53.57 ± 9.43	0.117
Sex (male, n)	15	11	4	0.856
BMI	23.05 ± 2.96	23.12 ± 3.26	22.86 ± 2.21	0.852
Compensated (n)	17	12	5	0.819
CTP score (5/6/7)	19/4/2	14/3/1	5/1/1	0.769
HGB (g/L)	133.08 ± 17.11	134.11 ± 16.49	130.43 ± 19.71	0.639
Neutr ($\times 10^9$/L)	2.30 ± 0.93	2.42 ± 1.05	1.98 ± 0.43	0.154
PLT ($\times 10^9$/L)	86 (55–346)	136.5 (55–346)	77.28 ± 14.53	0.085
ALT (U/L)	55 (19–174)	60 (19–174)	50 (35–68)	0.449
AST (U/L)	72 (24–217)	70.5 (24–217)	73 (37–157)	0.966
Albumin (g/L)	39.66 ± 5.40	40.12 ± 5.02	38.50 ± 6.56	0.513
Tbil (μmol/L)	18.55 ± 8.67	18.35 ± 9.40	19.09 ± 7.05	0.853
APRI	1.98 (0.24–7.86)	1.90 (0.24–7.86)	2.24 (1.05–5.45)	0.270
HCV-RNA (IU/mL)	6.22 ± 1.00	6.05 ± 1.14	6.65 ± 0.23	0.183
HCV-RNA > 800,000 (IU/mL)	19	12	7	0.137
Genotype (1/2/3/6, n)	15/3/3/4	9/3/2/4	6/0/1/0	0.323

SVR: sustained virological response; BMI: body mass index; CTP: Child-Turcotte-Pugh score; Neutr: neutrophil; ALT: alanine aminotransferase; AST: aspartate aminotransferase; Tbil: bilirubin; APRI: aspartate aminotransferase to platelet ratio index. Data are shown as the mean ± SD or median (range).

3 were excluded from the final analysis (1 withdrew for intolerance after the first injection, and 2 were lost to follow-up). Finally, 25 patients completed the therapy and were assigned to the study group. Four patients were diagnosed with cirrhosis by liver biopsy, whereas the other 21 patients were diagnosed clinically before enrollment. The mean age was 48.76 ± 9.53 (range: 33–65) years; there were 15 (15/25, 60%) males. The majority of patients (15/25, 60%) were infected with HCV genotype 1. Among them, 8 (32%) patients had a history of decompensation events (6 patients with ascites, 2 patients with variceal bleeding). At baseline, 2 patients had Child B class cirrhosis, and 23 patients had Child A class cirrhosis. Eighteen patients achieved SVR after a course of therapy, resulting in a SVR rate of 72% (18/25). Patients with different treatment outcomes (18 patients with SVR, 7 patients with non-SVR) were similar in terms of the demographic, biochemical and virological data at baseline (Table 1). Nine patients in the SVR group received spleen interventions before therapy (6 with splenectomy and 3 with splenic embolization); however, no participants in the non-SVR group received such therapy, resulting in a difference in platelet counts. The baseline characteristics of the patients based on the response to treatment are shown in Table 1.

3.2. Response to Therapy. Fatigue, a prolonged flu-like syndrome, and abnormalities of hematocytes were the common subjective adverse events. Symptomatic treatment and growth factor use were encouraged to maintain adherence to therapy. 25 patients tolerated the treatment well and completed it. Eighteen patients achieved SVR (18/25, 72%). In the subgroup of patients with decompensation events, 6 achieved SVR (6/8, 75%). The rate of SVR according to the HCV genotype was 60% (9/15) for genotype 1 patients and 90% (9/10) for non-genotype 1 patients. Nonresponse (NR) was observed in 4 (16%) patients. At treatment week 4, 13 patients (52%) had undetectable HCV-RNA. At treatment week 12, 20 patients (80%) had undetectable HCV-RNA. At treatment week 24, 21 patients (84%) had undetectable HCV-RNA. During the remaining treatment, 3 (12%) patients developed virologic breakthrough and HCV-RNA became positive at treatment weeks 36, weeks 36, and weeks 48, respectively. Eighteen patients (72%) achieved an EOT response and remained HCV-RNA negative through week 24 after termination of therapy. Therefore, SVR was observed in 18 (72%) patients.

3.3. Long-Term Outcomes. The eradication of HCV infection was indicated with a significantly lower rate of cirrhosis-related complications, HCC, and deaths. The follow-up period initiated from the time patients achieved SVR. The average duration of follow-up period was 25.78 ± 13.20 months. HCV-RNA was examined every 6 months using the Roche Amplicor HCV test during the follow-up period. Only one patient (5%) developed HCV-RNA positivity at 6 months after the date of SVR confirmation. The long-term clinical outcomes were assessed at every visit. No decompensation events were detected in the patients with SVR. Moreover, no patients died. However, 4 patients (2 males and 2 females) with SVR developed HCC during the follow-up period. Three of these patients had a genotype 1 HCV infection, and the other patient had a genotype 3 infection. Two of these patients had episodes of decompensation events before enrollment. Their baseline AFP levels were 9.95 ± 1.54 ng/mL, which is in the normal range (AFP reference range < 20 ng/mL). Moreover, the AFP levels at the time of the HCC diagnosis were also normal (6.63 ± 1.98 ng/mL). The confirmation time of HCC diagnosis was different; two patients were diagnosed at the date of confirmation of SVR, one was diagnosed within the first year, and the other was diagnosed in the

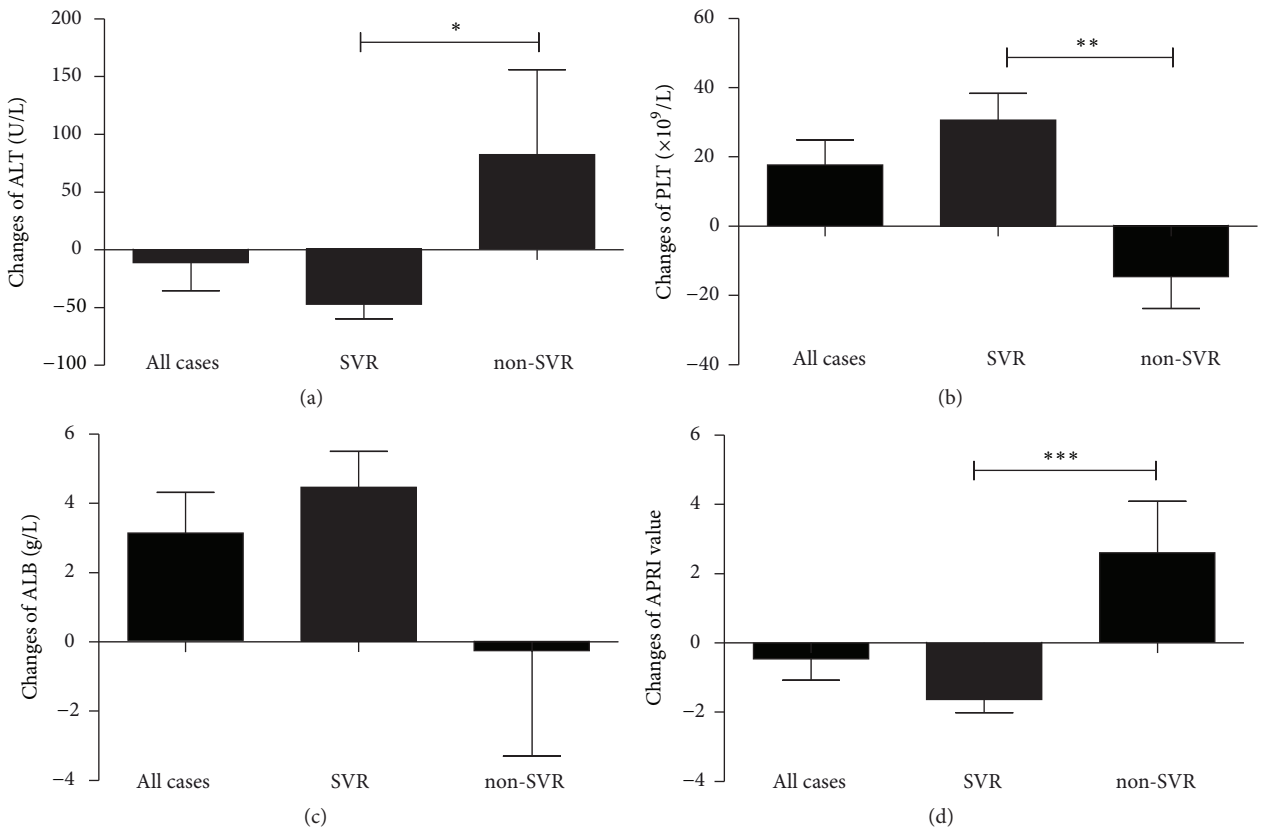

Figure 1: Changes in ALT values, absolute platelet counts, albumin values, and APRI levels in each group based on different treatment outcomes. The ALT levels (a) and APRI values (d) significantly reduced in the SVR patients compared with the non-SVR patients. Platelet counts (b) and albumin levels (c) increased in the patients with SVR and decreased in the non-SVR patients. P values represent comparisons between values at the initiation of treatment and at the last visit using the Wilcoxon signed-rank test or Student's t-test. ALT: alanine aminotransferase; PLT: platelet counts; ALB: albumin; APRI: aspartate aminotransferase to platelet ratio index; SVR: sustained virological response. $^{*}P < 0.05$; $^{**}P < 0.01$; $^{***}P < 0.001$.

third year after confirmation of SVR. All patients had a single lesion with a mean diameter less than 3 cm that was first detected by ultrasound and then confirmed by MRI. Two cases underwent surgical resection, and others received radiofrequency ablation.

3.3.1. ALT Values, Absolute Platelet Counts, Albumin Values, and AST-to-Platelet Ratio Index (APRI) Levels at the Initiation of Therapy and at the End of Follow-Up. Changes in ALT values between the end of follow-up and the initiation of therapy significantly decreased in the SVR group than patients with non-SVR ($P = 0.025$) (Figure 1(a)). The decreased value in each group was −19 U/L (−141, 512) in all patients, −26.5 U/L (−141, 7) in patients with SVR, and 0 U/L (−34, 512) in patients with non-SVR. The platelet counts increased in patients with SVR and decreased in non-SVR patients ($P = 0.003$) (Figure 1(b)). The extent of change in each group was 18 ± 36.48 in all patients, 30.67 ± 32.60 in patients with SVR, and −14.57 ± 24.36 in patients with non-SVR. A significant difference was observed in the values between SVR and non-SVR patients ($P = 0.003$), indicating that the platelet counts elevated only in patients who gained the eradication of HCV. The albumin levels elevated in SVR patients and decreased in non-SVR patients ($P = 0.215$) (Figure 1(c)). The extent of change in albumin values in each group was 3.2 g/L (−17.5, 14.2) in all patients, 3.35 g/L (−1.1, 14.2) in patients with SVR, and 1.8 g/L (−17.5, 6.5) in patients with non-SVR. The AST-to-platelet ratio index (APRI) was used to evaluate liver fibrosis. High APRI values can represent the progression of liver fibrosis. APRI was calculated according to the published formula [14, 15]. In our study, the APRI values declined significantly in SVR patients compared with non-SVR patients ($P < 0.001$) (Figure 1(d)). The extent of change in APRI levels in each group was −1.09 (−6.90, 10.4) in all patients, −1.33 (−6.90, 0.04) in patients with SVR, and 0.86 (−1.09, 10.4) in patients with non-SVR. The APRI value increased in almost all patients with non-SVR (6/7, 86%); however, the APRI value only increased in one patient with SVR (5% versus 86%, $P < 0.001$), suggesting that cirrhosis may be resolved in patients with HCV eradication.

3.3.2. Serial Changes in ALT Values, Absolute Platelet Counts, Albumin Values, and APRI Levels in Patients with SVR. We analyzed the serial changes in ALT values, absolute platelet counts, albumin values, and APRI levels in the 18 patients who achieved SVR. The ALT values decreased progressively

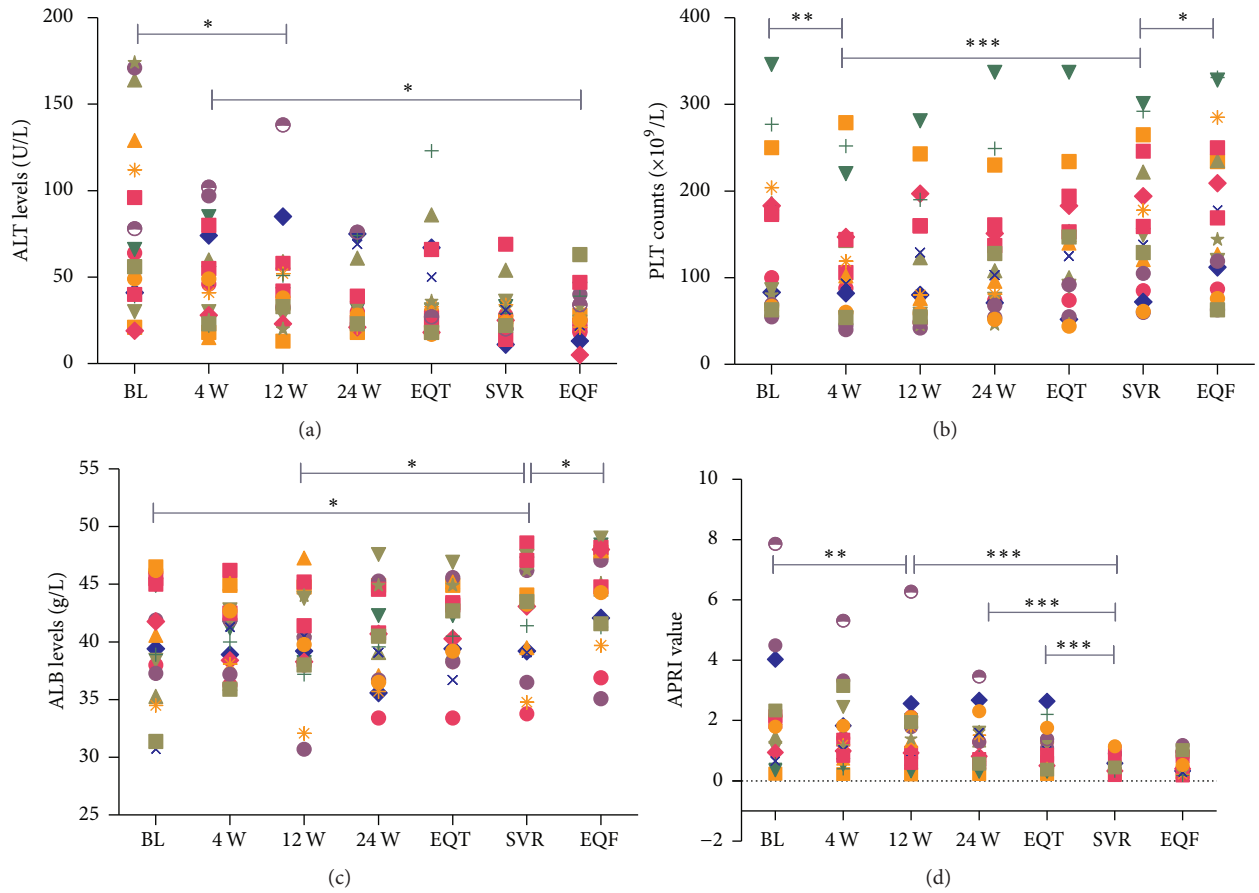

Figure 2: Serial changes in ALT values, absolute platelet counts, albumin values, and APRI levels in patients with SVR. ALT levels decreased progressively after the initiation of treatment until the end of the follow-up period (a). Platelet counts markedly decreased at treatment week 4 and then gradually increased (b). Albumin levels markedly increased during the follow-up period after the certification of SVR (c). APRI values decreased progressively during the therapy and tended to decline continuously throughout the follow-up (d). ALT: alanine aminotransferase; PLT: platelet; ALB: albumin; APRI: aspartate aminotransferase to platelet ratio index; BL: baseline; 4 W: treatment week 4; 12 W: treatment week 12; 24 W: treatment week 24; EOT: end of treatment response; SVR: sustained virological response; EOF: end of follow-up. $^{*}P < 0.05$; $^{**}P < 0.01$; $^{***}P < 0.001$.

after the initiation of treatment until the end of the follow-up period. The ALT values declined rapidly 12 weeks after the beginning of treatment and gradually until confirmation of SVR by 36.5 U/L (13, 138) ($P = 0.033$) and 27.5 U/L (11, 69) ($P = 0.001$), respectively. Then, the ALT levels nearly returned to normal and continued to decrease gradually until the end of the follow-up period (29.56 ± 13.5 U/L) (Figure 2(a)). The mean platelet count was 136.5×10^9/L (55, 346) at baseline. The platelet counts markedly decreased 4 weeks after the initiation of treatment by 31 ± 39.72 ($\times 10^9$/L) ($P = 0.002$) and gradually increased thereafter with a SVR of 160.11 ± 77.97 ($P < 0.001$). Moreover, the platelet counts continued to increase gradually until the end of follow-up compared with the value at SVR (173.89 ± 87.36, $P < 0.047$) (Figure 2(b)). The albumin levels did not change significantly during the first 12 weeks after the initiation of treatment ($P = 0.922$), but they increased gradually thereafter with a significant difference at SVR compared with week 12 (42.63 ± 4.37 versus 40 ± 4.26 g/L, $P = 0.014$). More interestingly, albumin levels markedly increased during the follow-up period after certification of SVR (44.27 ± 4.09 versus 42.63 ± 4.37 g/L, $P = 0.037$). The mean albumin level was 40.12 ± 5.02 at baseline, 44.00 ± 4.26 at week 12, 42.63 ± 4.37 at SVR, and 44.27 ± 4.09 at the last follow-up, respectively (Figure 2(c)). The APRI value decreased progressively after initiation of treatment until the end of follow-up. The APRI value was 1.91 (0.24–7.86) at baseline and 1.35 (0.22–6.27) at week 12 with a significant difference compared with baseline ($P = 0.006$) and then gradually decreased to a lowest value at SVR 0.58 (0.19–1.15) compared to the baseline value ($P < 0.001$). The APRI levels tended to decline continuously throughout the follow-up period to a value of 0.37 (0.18–1.19), but the difference was not significant ($P = 0.196$) (Figure 2(d)).

4. Discussion

Directly acting antiviral agents (DAAs) may be the first choice for HCV-related cirrhotic patients in many western countries. Studies have shown that DAAs can overcome the drawbacks of interferon based therapy in HCV-related cirrhotic patients.

Data on compensated cirrhotic patients showed SVR rates more than 90%, and a little lower SVR rate in decompensated patients with an optimal safety profile [16]. Moreover, a recent study reported that the rate of liver transplant wait-listing for patients with decompensated cirrhosis decreased by over 30% using DAAs therapy [17]. However, in China, clinical trials focusing on DAA are incomplete, and these agents are not approved for clinical use. Because of the incidence of liver decompensation, which is approximately 2–6% per year [18], cirrhotic patients should be treated in an urgent manner. Therefore, the combination of PegIFN + RBV remains the standard of care for cirrhotic patients. Patients with advanced liver disease typically have a poor response to PegIFN + RBV. Pooled metaestimates for SVR rates in cirrhotic patients revealed 17% with PegIFN + RBV [19]. Our results showed a SVR rate of 72%, slightly high for cirrhotic patients as 32% patients in our study had a history of decompensation events. This disparity may be interpreted by the different host genetic factors which could affect the treatment response. The single nucleotide polymorphisms near the interleukin (IL) 28B gene have been recently indicated to be linked with treatment outcomes and may be a good indicator of SVR. A cross-sectional observational study conducted in China showed that the majority of patients (84.1%) carried IL-28B genotype CC (rs12979860) [20]. The better efficacy of antiviral therapy in our study may be attributed to the favorable genotype of IL-28B polymorphisms.

HCV genotype definitely plays an important role in the response to PegIFN + RBV. The SVR rate was approximately 40% in North America and 50% in Western Europe patients infected with HCV genotype 1. Higher SVR rates were obtained in patients infected with other genotypes (up to approximately 80%) [21]. But, these data were achieved from patients with chronic hepatitis C. Consistent with previous reports [22, 23], HCV genotype 1 patients in our study developed lower SVR rates compared with other genotypes (60% versus 90%). Previous studies have reported that the SVR rate can be predicted by measuring of HCV-RNA at treatment week 12. Our results were similar to those of previous studies. In our study, 90% of patients (18/20) who achieved EVR finally had SVR after treatment, suggesting a strong positive predictive value for SVR. Several reports evaluating long-term follow-up studies of chronic hepatitis C patients achieving SVR have indicated that the incidence of relapse of HCV-RNA is relatively low, although relapse is not rare [24, 25]. During the mean follow-up period of 25.78 months, the reappearance of HCV-RNA was detected in only one patient, suggesting the persistent presence of undetectable HCV-RNA, which might result in decreased hepatic inflammation.

The mortality of cirrhotic patients is determined majorly by decompensation complications or HCC. Therefore, eradication of HCV by successful antiviral therapy may halt disease progression and HCC development, finally lowering disease-related mortality. A recent Japanese study demonstrated that SVR with successful antiviral therapy decreased the risk ratio for the overall mortality and disease-related mortality of HCV patients [26]. In addition, achieving SVR decreased the risk of HCC, liver decomposition, and all-cause mortality in patients with cirrhosis [27, 28]. Achieving SVR before liver transplantation in patients with advanced cirrhosis has been shown to reduce the risk for posttransplant HCV virus recurrence, which is known to limit graft and overall survival [29]. However, there are little data concerning the long-term outcomes in patients with HCV-related liver cirrhosis who achieved SVR, especially in Chinese patients. In our study, we demonstrated a favorable clinical course in southern Chinese patients who achieved SVR. In the follow-up period, no decompensation events were recorded. Furthermore, no deaths occurred. Therefore, because of its potential benefits, PegIFN + RBV should be an alternative choice and be encouraged in selected cirrhotic patients.

The risk of HCC was considered to decrease among patients who achieved SVR after PegIFN + RBV therapy [27, 30]. However, several recent reports revealed that viral eradication induced by DAAs maybe did not reduce the risk of HCC development in cirrhotic patients; furthermore patients who were previously treated for HCC still had a high risk of recurrence [31, 32]. In our study, 4 patients (22%) who achieved SVR developed HCC within the first 3 years during the follow-up. A previous study reported that the AFP levels after interferon treatment were correlated with the occurrence of HCC among patients with SVR [33]. AFP levels greater than 6 ng/mL have been shown to be associated with an increasing risk of HCC. Similarly, this study showed that the AFP levels were more than 6 ng/mL at baseline, even at the time of SVR confirmation. Although the AFP level was normal, 4 patients were suspected of HCC development by ultrasound, and confirmed by MRI. Because our study was a retrospective study enrolling small cohort of patients, causal relationships could not be established. Prospective studies are needed to define the relationship between HCC and SVR and to determine the best surveillance options for cirrhotic patients.

There is little information available concerning changes in the laboratory parameters of patients with HCV-related cirrhosis who gained SVR. In our study, ALT levels and APRI levels reduced in SVR patients in the follow-up period. Absolute platelet counts and albumin values declined in patients with non-SVR and increased in patients who achieved SVR. These data indicated that the progression of liver fibrosis differs between SVR patients and non-SVR patients. Several studies showed that histological improvement was achieved in chronic hepatitis C patients who achieved SVR after antiviral therapy [34, 35]. In a subgroup from the HALT-C trial, patients with advanced fibrosis or cirrhosis treated with low-dose PegIFN showed both a histological improvement and a reduction in portal pressure [36]. The APRI was considered to be a surrogate marker of fibrosis. The change in APRI in our study appeared to support this hypothesis. Our results were based on laboratory data but not on liver biopsy, providing indirect data regarding the improvement of hepatic fibrosis.

Furthermore, serial changes in ALT values, absolute platelet counts, albumin values, and APRI levels in patients with SVR showed that the ALT levels decreased for only 12 weeks after the initiation of treatment and returned to nearly normal during the study period. The absolute platelet

counts continued to elevate significantly. Thus, serial changes in the absolute platelet counts may be used to estimate the long-term improvement of liver fibrosis after SVR. Consistent with the absolute platelet counts, the albumin values elevated significantly during the follow-up period. Previous long-term follow-up studies revealed no differences in ALT values, albumin values, or absolute platelet counts at the last visit point compared with 24 weeks after the termination of IFN treatment [37, 38]. However, our results demonstrated gradual increases in platelet counts after treatment. Previous reports have revealed that ALT levels normalized in the majority of CHC patients after SVR [38], although only a few studies have reported this finding in cirrhotic patients.

To our knowledge, rare studies have conducted a follow-up of longitudinal changes in APRI levels in HCV-infected cirrhotic patients who achieved SVR in a long-term study. Liver biopsy is the most reliable approach to evaluate the fibrotic stage, although this procedure has some limitations, such as sampling variability, procedural discomfort, and added cost. A previous study showed that APRI could be used to distinguish between F0-F1 and F2–F4 fibrosis [14]. Moreover, APRI was recently recommended by the WHO to assess the stage of fibrosis for making decisions regarding antiviral therapy [15]. The APRI levels were reduced significantly at treatment week 12 and then gradually decreased throughout the entire study period, suggesting a histological improvement in patients with SVR. As we know, rare reports have demonstrated an improvement of liver fibrosis using liver biopsy in cirrhotic patients with SVR during the long-term follow-up period, which may be due to the increasing risk of bleeding. We demonstrated this improvement by monitoring the changes of platelet counts and APRI, the consequential index of fibrosis.

Our study has some limitations. Firstly, histological confirmation by liver biopsy was only available in a few patients before treatment; the diagnosis of cirrhosis and its progression were determined by clinical evidence in most patients. Secondly, this was a descriptive study and the follow-up period (median of 25.6 months) was not long enough. In addition, among 18 patients with SVR, 4 patients developed HCC during the follow-up period, resulting in a relatively high incidence of HCC development. Therefore, large sample cohort studies are needed for further confirmation.

We reported a favorable clinical outcome in patients who gained SVR after treatment with PegIFN + RBV. HCV-RNA remained negative in most patients, and the laboratory parameters including APRI improved during the follow-up period. Thus, anti-HCV treatment should be urgently considered when the diagnosis of cirrhosis was established. Ultimately, HCC development could be detected in several SVR patients. Therefore, HCV clearance does not mean cure, and HCC should be closely monitored.

Abbreviations

APRI: Aspartate aminotransferase to platelet ratio index
PegIFN: Pegylated interferon
RBV: Ribavirin
SVR: Sustained virological response.

Competing Interests

The authors declare that they have no competing interests.

Authors' Contributions

Zhang Geng-lin and Chen You-ming contributed equally to this work.

Acknowledgments

This study was supported by grants from National Natural Science Foundation of China (no. 81672701), Science and Technology Program of Guangzhou, China (no. 1561000155), Fundamental Research Funds for the Central Universities (15ykjc05e), and Sun Yat-Sen University Clinical Research 5010 Program (no. 2010011).

References

[1] Y. D. Chen, M. Y. Liu, W. L. Yu et al., "Hepatitis C virus infections and genotypes in China," *Hepatobiliary & Pancreatic Diseases International: HBPD INT*, vol. 1, no. 2, pp. 194–201, 2002.

[2] H.-H. Thein, Q. Yi, G. J. Dore, and M. D. Krahn, "Estimation of stage-specific fibrosis progression rates in chronic hepatitis C virus infection: a meta-analysis and meta-regression," *Hepatology*, vol. 48, no. 2, pp. 418–431, 2008.

[3] H. Razavi, I. Waked, C. Sarrazin et al., "The present and future disease burden of hepatitis C virus (HCV) infection with today's treatment paradigm," *Journal of Viral Hepatitis*, vol. 21, supplement 1, pp. 34–59, 2014.

[4] D. B. Strader, T. Wright, D. L. Thomas, and L. B. Seeff, "Diagnosis, management, and treatment of hepatitis C," *Hepatology*, vol. 39, no. 4, pp. 1147–1171, 2004.

[5] L. C. Casey and W. M. Lee, "Hepatitis C virus therapy update 2013," *Current Opinion in Gastroenterology*, vol. 29, no. 3, pp. 243–249, 2013.

[6] Y. Shiratori, Y. Ito, O. Yokosuka et al., "Antiviral therapy for cirrhotic hepatitis C: association with reduced hepatocellular carcinoma development and improved survival," *Annals of Internal Medicine*, vol. 142, no. 2, pp. 105–114, 2005.

[7] S. Bruno, T. Stroffolini, M. Colombo et al., "Sustained virological response to interferon-α is associated with improved outcome in HCV-related cirrhosis: a retrospective study," *Hepatology*, vol. 45, no. 3, pp. 579–587, 2007.

[8] Y. Miyake, Y. Iwasaki, and K. Yamamoto, "Meta-analysis: reduced incidence of hepatocellular carcinoma in patients not responding to interferon therapy of chronic hepatitis C," *International Journal of Cancer*, vol. 127, no. 4, pp. 989–996, 2010.

[9] A. Iacobellis, M. Siciliano, F. Perri et al., "Peginterferon alfa-2b and ribavirin in patients with hepatitis C virus and decompensated cirrhosis: a controlled study," *Journal of Hepatology*, vol. 46, no. 2, pp. 206–212, 2007.

[10] G. T. Everson, N. A. Terrault, A. S. Lok et al., "A randomized controlled trial of pretransplant antiviral therapy to prevent recurrence of hepatitis C after liver transplantation," *Hepatology*, vol. 57, no. 5, pp. 1752–1762, 2013.

[11] J. S. Crippin, T. McCashland, N. Terrault, P. Sheiner, and M. R. Charlton, "A pilot study of the tolerability and efficacy of

antiviral therapy in hepatitis C virus-infected patients awaiting liver transplantation," *Liver Transplantation*, vol. 8, no. 4, pp. 350–355, 2002.

[12] X. Forns, M. García-Retortillo, T. Serrano et al., "Antiviral therapy of patients with decompensated cirrhosis to prevent recurrence of hepatitis C after liver transplantation," *Journal of Hepatology*, vol. 39, no. 3, pp. 389–396, 2003.

[13] J. Bruix, M. Sherman, J. M. Llovet et al., "Clinical management of hepatocellular carcinoma. Conclusions of the barcelona-2000 EASL conference," *Journal of Hepatology*, vol. 35, no. 3, pp. 421–430, 2001.

[14] C.-T. Wai, J. K. Greenson, R. J. Fontana et al., "A simple noninvasive index can predict both significant fibrosis and cirrhosis in patients with chronic hepatitis C," *Hepatology*, vol. 38, no. 2, pp. 518–526, 2003.

[15] WHO, Guidelines for the prevention, care and treatment of persons with chronic hepatitis B infection, March 2015. http://www.who.int/hepatitis/publications/hepatitis-b-guidelines-policy/en/.

[16] P. Ferenci, K. Kozbial, M. Mandorfer, and H. Hofer, "HCV targeting of patients with cirrhosis," *Journal of Hepatology*, vol. 63, no. 4, pp. 1015–1022, 2015.

[17] J. A. Flemming, W. R. Kim, C. L. Brosgart, and N. A. Terrault, "Reduction in liver transplant wait-listing in the era of direct-acting antiviral therapy," *Hepatology*, 2016.

[18] G. D'Amico, G. Garcia-Tsao, and L. Pagliaro, "Natural history and prognostic indicators of survival in cirrhosis: a systematic review of 118 studies," *Journal of Hepatology*, vol. 44, no. 1, pp. 217–231, 2006.

[19] J. M. Vierling, S. Zeuzem, F. Poordad et al., "Safety and efficacy of boceprevir/peginterferon/ribavirin for HCV G1 compensated cirrhotics: meta-analysis of 5 trials," *Journal of Hepatology*, vol. 61, no. 2, pp. 200–209, 2014.

[20] H. Rao, L. Wei, J. C. Lopez-Talavera et al., "Distribution and clinical correlates of viral and host genotypes in Chinese patients with chronic hepatitis C virus infection," *Journal of Gastroenterology and Hepatology*, vol. 29, no. 3, pp. 545–553, 2014.

[21] D. B. Smith, J. Bukh, C. Kuiken et al., "Expanded classification of hepatitis C virus into 7 genotypes and 67 subtypes: updated criteria and genotype assignment web resource," *Hepatology*, vol. 59, no. 1, pp. 318–327, 2014.

[22] A. Iacobellis, F. Perri, M. R. Valvano, N. Caruso, G. A. Niro, and A. Andriulli, "Long-term outcome after antiviral therapy of patients with hepatitis C virus infection and decompensated cirrhosis," *Clinical Gastroenterology and Hepatology*, vol. 9, no. 3, pp. 249–253, 2011.

[23] H. R. Cheong, H. Y. Woo, J. Heo et al., "Clinical efficacy and safety of the combination therapy of peginterferon alpha and ribavirin in cirrhotic patients with HCV infection," *The Korean Journal of Hepatology*, vol. 16, no. 1, pp. 38–48, 2010.

[24] E. G. Giannini, M. Basso, V. Savarino, and A. Picciotto, "Sustained virological response to pegylated interferon and ribavirin is maintained during long-term follow-up of chronic hepatitis C patients," *Alimentary Pharmacology and Therapeutics*, vol. 31, no. 4, pp. 502–508, 2010.

[25] S. Maylin, M. Martinot-Peignoux, M.-P. Ripault et al., "Sustained virological response is associated with clearance of hepatitis C virus RNA and a decrease in hepatitis C virus antibody," *Liver International*, vol. 29, no. 4, pp. 511–517, 2009.

[26] D. Maruoka, F. Imazeki, M. Arai, T. Kanda, K. Fujiwara, and O. Yokosuka, "Long-term cohort study of chronic hepatitis C according to interferon efficacy," *Journal of Gastroenterology and Hepatology*, vol. 27, no. 2, pp. 291–299, 2012.

[27] S. Aleman, N. Rahbin, O. Weiland et al., "A risk for hepatocellular carcinoma persists long-term after sustained virologic response in patients with hepatitis C-associated liver cirrhosis," *Clinical Infectious Diseases*, vol. 57, no. 2, pp. 230–236, 2013.

[28] A. J. van der Meer, B. J. Veldt, J. J. Feld et al., "Association between sustained virological response and all-cause mortality among patients with chronic hepatitis C and advanced hepatic fibrosis," *Journal of the American Medical Association*, vol. 308, no. 24, pp. 2584–2593, 2012.

[29] F. Tekin, F. Gunsar, Z. Karasu, U. Akarca, and G. Ersoz, "Safety, tolerability, and efficacy of pegylated-interferon alfa-2a plus ribavirin in HCV-related decompensated cirrhotics," *Alimentary Pharmacology and Therapeutics*, vol. 27, no. 11, pp. 1081–1085, 2008.

[30] A. K. Singal, A. Singh, S. Jaganmohan et al., "Antiviral therapy reduces risk of hepatocellular carcinoma in patients with hepatitis C virus-related cirrhosis," *Clinical Gastroenterology and Hepatology*, vol. 8, no. 2, pp. 192–199, 2010.

[31] F. Conti, F. Buonfiglioli, A. Scuteri et al., "Early occurrence and recurrence of hepatocellular carcinoma in HCV-related cirrhosis treated with direct-acting antivirals," *Journal of Hepatology*, vol. 65, no. 4, pp. 727–733, 2016.

[32] K. Kozbial, S. Moser, R. Schwarzer et al., "Unexpected high incidence of hepatocellular carcinoma in cirrhotic patients with sustained virologic response following interferon-free direct-acting antiviral treatment," *Journal of Hepatology*, vol. 65, no. 4, pp. 856–858, 2016.

[33] Y. Asahina, K. Tsuchiya, T. Nishimura et al., "α-Fetoprotein levels after interferon therapy and risk of hepatocarcinogenesis in chronic hepatitis C," *Hepatology*, vol. 58, no. 4, pp. 1253–1262, 2013.

[34] F. Toccaceli, V. Laghi, L. Capurso et al., "Long-term liver histology improvement in patients with chronic hepatitis C and sustained response to interferon," *Journal of Viral Hepatitis*, vol. 10, no. 2, pp. 126–133, 2003.

[35] Y. Shiratori, F. Imazeki, M. Moriyama et al., "Histologic improvement of fibrosis in patients with hepatitis C who have sustained response to interferon therapy," *Annals of Internal Medicine*, vol. 132, no. 7, pp. 517–524, 2000.

[36] M. L. Shiffman, A. M. Di Bisceglie, K. L. Lindsay et al., "Peginterferon Alfa-2a and ribavirin in patients with chronic hepatitis C who have failed prior treatment," *Gastroenterology*, vol. 126, no. 4, pp. 1015–1023, 2004.

[37] S. L. George, B. R. Bacon, E. M. Brunt, K. L. Mihindukulasuriya, J. Hoffman, and A. M. Di Bisceglie, "Clinical, virologic, histologic, and biochemical outcomes after successful HCV therapy: a 5-year follow-up of 150 patients," *Hepatology*, vol. 49, no. 3, pp. 729–738, 2009.

[38] D. Maruoka, F. Imazeki, M. Arai, T. Kanda, K. Fujiwara, and O. Yokosuka, "Longitudinal changes of the laboratory data of chronic hepatitis C patients with sustained virological response on long-term follow-up," *Journal of Viral Hepatitis*, vol. 19, no. 2, pp. e97–e104, 2012.

Hindawi
BioMed Research International
Volume 2017, Article ID 4081525, 9 pages
https://doi.org/10.1155/2017/4081525

Review Article

Coronary Computed Tomography Angiography in Combination with Coronary Artery Calcium Scoring for the Preoperative Cardiac Evaluation of Liver Transplant Recipients

Jae Moon Choi,[1] Yu-Gyeong Kong,[1] Joon-Won Kang,[2] and Young-Kug Kim[1]

[1]*Department of Anesthesiology and Pain Medicine, Asan Medical Center, University of Ulsan College of Medicine, Seoul, Republic of Korea*
[2]*Department of Radiology, Asan Medical Center, University of Ulsan College of Medicine, Seoul, Republic of Korea*

Correspondence should be addressed to Joon-Won Kang; jwonkang@amc.seoul.kr and Young-Kug Kim; kyk@amc.seoul.kr

Received 13 October 2016; Revised 7 December 2016; Accepted 18 December 2016; Published 10 January 2017

Academic Editor: Andrea Mancuso

Liver transplantation is the best treatment option for early-stage hepatocellular carcinoma, liver cirrhosis, fulminant liver failure, and end-stage liver diseases. Even though advances in surgical techniques and perioperative care have improved postoperative outcomes, perioperative cardiovascular complications are a leading cause of postoperative morbidity and mortality following liver transplantation. Ischemic coronary artery disease (CAD) and cardiomyopathy are the most common cardiovascular diseases and could be negative predictors of postoperative outcomes in liver transplant recipients. Therefore, comprehensive cardiovascular evaluations are required to assess perioperative risks and prevent concomitant cardiovascular complications that would preclude good outcomes in liver transplant recipients. The two major types of cardiac computed tomography are the coronary artery calcium score (CACS) and coronary computed tomography angiography (CCTA). CCTA in combination with the CACS is a validated noninvasive alternative to coronary angiography for diagnosing and grading the severity of CAD. A CACS > 400 is associated with significant CAD and a known important predictor of posttransplant cardiovascular complications in liver transplant recipients. In this review article, we discuss the usefulness, advantages, and disadvantages of CCTA combined with CACS as a noninvasive diagnostic tool for preoperative cardiac evaluation and for maximizing the perioperative outcomes of liver transplant recipients.

1. Introduction

Since the first successful liver transplantation was reported in 1963 [1], this procedure has been performed to treat hepatocellular carcinoma at early stages, liver cirrhosis, fulminant liver failure, and end-stage liver diseases. Advances in surgical techniques, organ preservation, and perioperative care including immunosuppression have further improved the perioperative outcomes of liver transplantation [2]. As the average age of patients undergoing liver transplantation continues to increase, perioperative cardiovascular complications are a leading cause of morbidity and mortality after liver transplantation [3]. Previous cardiac disease, adverse intraoperative cardiovascular events, and an integrated model for end-stage liver disease score are known as independent predictors of cardiovascular complications for the 6-month period after liver transplantation [4].

The American College of Cardiology/American Heart Association guidelines recommend cardiovascular evaluation for individuals undergoing noncardiac surgery [5]. As with any patient being considered for a surgical procedure, individuals with end-stage liver disease should have an evaluation for cardiac function and coronary heart disease. Since the incidence of perioperative cardiovascular complications varies from 25% to 70% in liver transplant recipients [3, 6, 7], these patients need to be very thoroughly evaluated for cardiac function. Ischemic coronary artery disease (CAD) and cardiomyopathy are the most common cardiovascular

diseases and could be negative predictors of postoperative outcomes in liver transplant recipients [8]. The prevalence of CAD ranges between 2.5% and 12% in patients undergoing orthotopic liver transplantation [9–12]. The history of CAD is also reported to be an important risk factor for postoperative acute coronary syndrome in liver transplant recipients [13]. Taken together, the evidence to date indicates that meticulous cardiovascular evaluations are required to assess perioperative risks and to prevent concomitant cardiovascular complications that would preclude good outcomes in patients undergoing liver transplantation.

A scientific statement from the American Heart Association and the American College of Cardiology Foundation gives a class I recommendation to screen all potential liver transplant candidates for cardiovascular disease initially with a history and physical examination [14]. Noninvasive stress echocardiography is needed as an initial screening test in liver transplant candidates, to assess the cardiac risk [15]. Pretransplant cardiac revascularization is recommended in liver transplant candidates with significant coronary artery stenosis [15]. Newer and more sophisticated imaging modalities, such as cardiac computed tomography and cardiac magnetic resonance imaging, have allowed for more precise diagnostic cardiovascular testing [5]. The two major types of cardiac computed tomography are the coronary artery calcium score (CACS) and coronary computed tomography angiography (CCTA). CCTA with contrast allows for imaging of the heart chambers, coronary arteries, and pulmonary vessels in three dimensions. CCTA was introduced as a noninvasive diagnostic method for evaluating CAD and improving postoperative outcomes by detecting obstructive coronary plaques that result in luminal diameter narrowing in one or more coronary arteries and can be used in combination with CACS. In CACS, pictures are taken of the heart to investigate the calcium deposits in the coronary arteries. Coronary artery calcium deposits are only present in atherosclerotic arteries [16] and represent a very specific sign of CAD. Increases in the calcium deposits in coronary arteries increase the risk of a heart attack or other cardiovascular complications [17].

CCTA has a negative predictive value of 97–99% for predicting the absence of obstructive CAD [18, 19]. In addition, a CACS > 400 on CCTA is known to be predictive of cardiovascular complications within 1 month of a liver transplantation [20]. We here review the usefulness, advantages, and disadvantages of CCTA combined with CACS as a noninvasive diagnostic tool for evaluating preoperative CAD and for reducing postoperative cardiac complications in liver transplant recipients.

2. Preoperative Cardiac Evaluation Tests

Preoperative testing for cardiovascular evaluation is highly recommended in liver transplant candidates with a history of cardiovascular disease, alcoholism, or diabetes mellitus, especially in patients > 60 years of age [21]. However, cardiovascular evaluations are challenging in liver transplant candidates. The majority of these patients cannot undergo cardiopulmonary exercise testing due to deconditioning, malnutrition-associated muscle weakness, ascites, anemia, and cirrhotic cardiomyopathy [22]. Preoperative cardiac assessments in patients undergoing liver transplantation include electrocardiography, cardiopulmonary exercise testing, basal and dobutamine stress echocardiography, myocardial perfusion imaging by single-photon emission computed tomography (SPECT), coronary angiography, and cardiac computed tomography [23].

2.1. Electrocardiography. Preoperative resting electrocardiography is a noninvasive test used to obtain diagnostic and prognostic information on liver transplant recipients [5]. Standard 12-lead electrocardiography is useful for continuously recording pulse generation, heart rhythm, conduction disturbances, and ischemic changes. One of the most important electrocardiographic parameters in patients with liver cirrhosis is the prolongation of the QT interval [27]. A corrected QT interval > 450 ms indicates an increased risk of ventricular arrhythmia and sudden cardiac death [28]. However, it is helpful to perform pharmacological stress testing, such as dobutamine stress echocardiography and stress SPECT, to assess functional capacity in liver transplant recipients [5].

2.2. Cardiopulmonary Exercise Testing. Preoperative cardiopulmonary exercise testing is a safe, noninvasive method to determine the cardiopulmonary reserve in liver transplant recipients. The preoperative cardiopulmonary reserve assessed by submaximal cardiopulmonary exercise testing represents a sensitive and specific predictor of early survival after liver transplantation [29]. In patients undergoing liver transplantation, impaired anaerobic threshold is related to postoperative hospitalization, survival, and mortality [30]. Because most liver transplant recipients are too debilitated to complete cardiopulmonary exercise testing, many centers conduct pharmacological stress test using dipyridamole, dobutamine, or adenosine [14].

2.3. Dobutamine Stress Echocardiography. Dobutamine stress echocardiography has been introduced as an initial screening test for coronary heart disease. The American Association for the Study of Liver Disease recommends dobutamine stress echocardiography as an effective screening tool for evaluating CAD in patients undergoing liver transplantation [31]. Currently, the American College of Cardiology and the American Heart Association recommend that noninvasive stress testing may be considered for liver transplant candidates who have ≥ 3 risk factors for CAD [5]. A previous meta-analysis has suggested that dobutamine stress echocardiography detects CAD with a high degree of sensitivity and specificity in the general population [32]. Although dobutamine stress echocardiography is commonly used to evaluate risk stratification, it does not accurately reflect the severity of obstructive CAD in liver transplant candidates [33, 34]. In a subset analysis of orthotopic liver transplant candidates, dobutamine stress echocardiography compared with coronary angiography has a 75% sensitivity and 57% specificity in detecting CAD [12]. Dobutamine stress echocardiography has a 9% sensitivity, 33% positive predictive value,

and 89% negative predictive value for predicting early cardiac events after liver transplantation [13].

The use of β-blocking agents for the prevention of esophageal variceal bleeding in end-stage liver disease has been found to be a common cause of failure to achieve the target heart rate in dobutamine stress echocardiography. The previously reported results of dobutamine stress echocardiography were inconclusive in 19–21% of patients on β-blocking agents [35, 36]. In addition, when β-blocking agents are stopped to enable dobutamine stress echocardiography, there is an increased risk of variceal bleeding [37].

2.4. SPECT. SPECT is the most widely known nuclear test for evaluating myocardial perfusion using diffusible radiotracers. The sensitivity of SPECT is approximately 90%, and the specificity is 75–80% in pharmacological stress studies that use thallium [38]. In liver transplant candidates, however, SPECT imaging is known to be an inaccurate screening test. The sensitivity of SPECT is 37% and its positive predictive value is 22% in comparison with coronary angiography in liver transplant candidates [39]. Adenosine-SPECT has a sensitivity of 62% and a positive predictive value of 30% for diagnosing severe CAD in patients with end-stage liver disease [40]. In patients undergoing orthotopic liver transplantation, SPECT has a sensitivity of 57%, a positive predictive value of 28%, and a negative predictive value of 91% for predicting early cardiac events [13]. A primary deficiency of SPECT is associated with the vasodilating agents used (adenosine and dipyridamole). Chronically decreased arterial vascular resistance in patients with advanced liver failure may limit the typical vasodilating response of the coronary arteries to adenosine or regadenoson [39, 40].

2.5. Coronary Angiography. The current standard for the diagnosis of symptomatic obstructive CAD is coronary angiography [41]. Coronary angiography is known as a superior diagnostic tool for evaluating coronary heart disease. The main advantage of coronary angiography is that it can be diagnosed and treated simultaneously with immediate percutaneous coronary intervention. With the lack of high-level evidence for the superiority of noninvasive tests, many centers rely on invasive coronary angiography [42]. Significant CAD is defined as a more than 50% decrease in the lumen diameter resulting in a hemodynamically significant reduction in coronary blood flow [43]. The increased use of coronary angiography and percutaneous coronary intervention before orthotopic liver transplant is also associated with significant reductions in postoperative coronary events and all-cause mortality [44]. In contrast, coronary interventions do not reduce mortality rates in orthotopic liver transplant patients with severe CAD [45]. The authors of that study proposed that patients who undergo coronary intervention prior to liver transplantation are at high risk of death from a cardiac event.

Coronary angiography in patients with relatively advanced liver disease is more likely to increase the risk of vascular complications, such as bleeding, due to coagulation abnormalities secondary to thrombocytopenia and prolonged prothrombin time [46]. According to recent studies, transradial cardiac catheterization appears to be a safe method in liver transplant candidates despite significantly lower platelet count and higher international normalized ratio [47, 48]. No adverse events were recorded after coronary angiography in 84 orthotopic liver transplant candidates [49]. However, it remains unclear when to proceed with invasive coronary angiography. A standardized protocol for assessing CAD in liver transplant recipients is therefore needed.

3. CCTA

Noninvasive coronary imaging has been a topic of great research interest for a number of years [50]. CCTA is validated as a potential alternative to coronary angiography for diagnosing and grading the severity of CAD in a large number of patients [19, 51]. The main obstacles to interrupting the noninvasive visualization of coronary arteries include cardiac motion, small vessel size, and the need for elevated intravascular contrast resolution [52]. The advent of multidetector computed tomography has enabled the acquisition of excellent anatomic details of the coronary arteries in a beating heart. Multidetector computed tomography has the potential to considerably reduce the radiation dose and the amount of contrast agent required while maintaining high diagnostic accuracy [53, 54]. Multidetector computed tomography also has the capability to simultaneously and continuously obtain multiple images. Approximately 300 transaxial images with a thickness of 0.5–1 mm are obtained during a single breath-hold. Through the use of electrocardiographic data, multidetector computed tomography images can be reconstructed at the optimal cardiac phases that have no or minimal coronary artery motion.

The findings obtained from coronary angiography are limited to information regarding the coronary artery lumen and cannot identify the accumulation of atherosclerotic plaques in the coronary vessel wall. However, CCTA can delineate the coronary anatomy in three dimensions and noninvasively visualize coronary vessels in any desired spatial orientation using the acquisition of volumetric data sets. Manipulation of the images through prospectively electrocardiogram-triggered high-pitch spiral acquisition offers distinct advantages in comparison with coronary angiography [55].

An atherosclerotic lesion is defined by intimal and smooth muscle cell proliferation, lipid accumulation, and connective tissue deposition [56]. Atherosclerosis eventually causes the obstruction of blood flow and leads to clinical symptoms. CCTA acquires detailed images of calcified and noncalcified plaques [57]. CCTA has the potential to detect the length, morphology, and composition of atherosclerotic plaques in stenotic regions [58–61]. More research is needed to compare atherosclerotic plaque characteristics such as site, length, composition, and morphology between liver transplant candidates and other populations.

Clinically significant but not critical coronary artery stenosis on CCTA is defined as the narrowing of the coronary artery diameter by 50% to 70% [62, 63]. There is debate about

whether CCTA should be considered for patients with end-stage liver disease [21]. Routine preoperative CCTA has a low yield in patients evaluated for liver transplant. In a previous study of 1045 cirrhotic patients with no history of chest pain or CAD, CCTA revealed a similar frequency of obstructive CAD in the cirrhotic (7.9%) and healthy (7.2%) cohorts [64]. Twenty-four of the patients in that study with obstructive CAD with CCTA were referred for cardiac catheterization, and only 6 ultimately underwent revascularization [64]. In several previous meta-analyses, however, multidetector computed tomography has demonstrated a 98-99% sensitivity and 89–91% specificity for the detection of coronary plaques [65–67]. CCTA has also shown a good negative predictive value (83–99%) for excluding significant CAD [68]. A normal scanning result in CCTA can effectively exclude obstructive CAD and abolish the need for further investigation [21]. CCTA combined with regadenoson-induced stress computed tomography perfusion is a stress test with a high diagnostic performance in assessing intermediate coronary artery stenosis in asymptomatic patients [69]. However, there have been no previous reports that compared CCTA and invasive coronary angiography for detecting CAD in liver transplant recipients. Further studies are thus needed to determine the diagnostic accuracy of CCTA in comparison with coronary angiography for the detection of coronary artery stenosis and in making interventional decisions in liver transplant candidates.

4. CACS

CACS—as estimated by noncontrast, electrocardiography-gated computed tomography—is an established noninvasive tool for the identification and quantification of calcified plaques in a coronary artery [70]. Calcium phosphate and hydroxyapatite are responsible for the calcification of the coronary artery. Coronary artery calcium deposits can be measured rapidly and noninvasively using computed tomography. The presence of calcium in a coronary artery is defined by the presence of any pixel within the region of interest with a computed tomography density > 130 Hounsfield units due to noise [70, 71]. A density factor derived from the peak brightness of each calcium focus and its area on a computed tomography scan have been used to determine the calcium score for each scan using the method developed by Agatston et al. [70]. The calcium scores for each lesion were then summed to define the total CACS for each patient. The quantification of coronary artery calcium on computed tomography is correlated with the severity of luminal narrowing, stenosis severity, and total plaque burden in the artery due to atherosclerotic disease [72].

CACS values are generally classified as absent (0), minimal (1–10), mild (11–100), moderate (101–400), or extensive (>400) (Figure 1) [73]. A CACS < 10 indicates the absence of any significant coronary obstructive lesion. CACS is an independent predictor of coronary heart disease risk and mortality and reflects the prevalence and extent of atherosclerosis. In several meta-analyses undertaken to date, a higher CACS has been associated with a greater degree of coronary artery stenosis and a higher risk of coronary heart disease [74–76]. In the general population, a doubling of the CACS increases the probability of coronary events by 25% during a median follow-up period of 3.8 years [77]. In a previous large prospective study that followed up 44,052 patients over a 5-year period, the mortality rate associated with a CACS ranging from 1 to 10 was 1.06%, which was higher than in cases with a CACS of 0 (0.52%) and lower than in patients with CACS > 10 (3.96%) [78]. A CACS > 400 is significantly associated with the presence of coronary artery stenosis on coronary angiography in asymptomatic patients and liver transplant candidates [25, 73].

CCTA combined with CACS is well tolerated in comparison with the stress test and is a useful noninvasive technique for assessing CAD in patients with end-stage liver disease. The prognostic value of CCTA is comparable to that of dobutamine stress echocardiography and it has a negative predictive value of 95% for major adverse cardiac events in the 1-year posttransplant follow-up period in orthotopic liver transplant recipients [10]. Kong et al. reported a mean CACS on CCTA of 42 ± 195 in 443 liver transplant candidates and that 11 (2.5%) patients were categorized into the extensive groups [20]. Based on that study, a CACS > 400 is an important predictor of early cardiovascular complications such as a nonfatal myocardial infarction, serious arrhythmia, and cardiac death after liver transplantation [20]. Increasing age, male sex, and diabetes mellitus have also been associated with a CACS > 400 in liver transplant recipients [79]. CCTA is recommended for preoperative cardiovascular assessment in liver transplant candidates who had a diagnosis of diabetes mellitus or ≥ 2 traditional risk factors for CAD (age > 45 years for male or > 55 years for female, hypercholesterolemia, hypertension, tobacco use, and family history of early CAD) [80]. Therefore, we suggest CCTA combined with CACS for preoperative cardiac evaluation in liver transplant recipients with the above-mentioned CAD risk. Coronary angiography is likely to be performed in patients with coronary artery stenosis ≥ 50% on CCTA or CACS > 400.

However, there is still limited information on the predictive ability of the CACS with respect to perioperative outcomes in patients undergoing liver transplantation (Table 1). More studies are needed to clarify this. Furthermore, it is important to understand that CACS should be used to indicate coronary angiography with possible interventional procedures to reduce the risk for perioperative acute cardiac events.

5. Advantages and Disadvantages of CCTA Combined with CACS

Noninvasive CCTA reduces the need for invasive coronary angiography and can be safely used in the perioperative cardiovascular risk assessment of liver transplant candidates during the posttransplant follow-up period [24]. CACS is significantly associated with cardiovascular risk factors, such as age and the involved number of coronary vessels, and is a more sensitive detector of cardiovascular risk factors than the Framingham risk score in liver transplant recipients [81]. Detecting an increase in coronary artery calcium has the

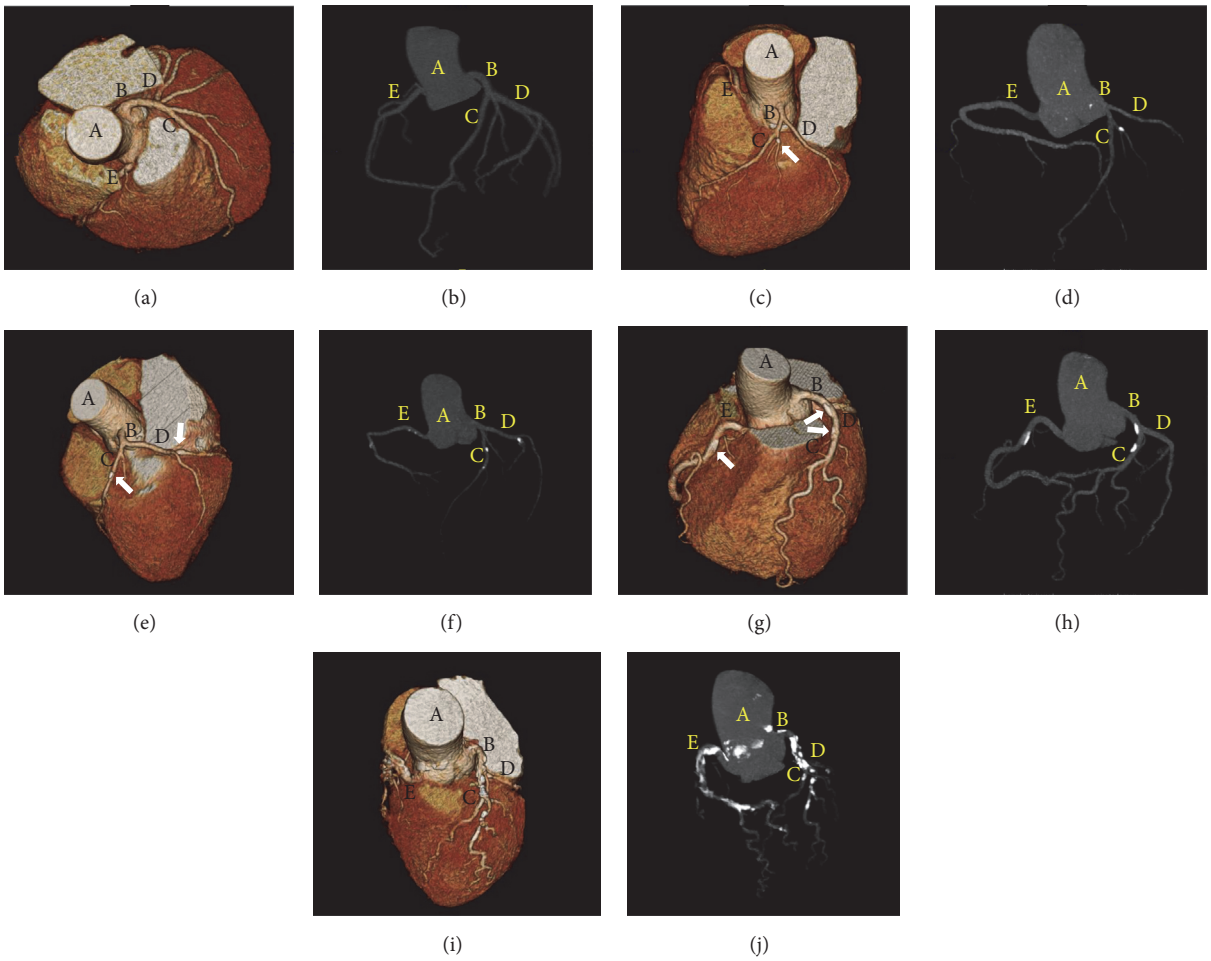

Figure 1: Three-dimensional volume-rendered images (a, c, e, g, and i) and angiographic images (b, d, f, h, and j) of the coronary artery obtained using computed tomographic angiography in patients undergoing liver transplantation. ((a) and (b)) CACS = 0 (absent); ((c) and (d)) CACS = 9 (minimal); ((e) and (f)) CACS = 95 (mild); ((g) and (h)) CACS = 279 (moderate); ((i) and (j)) CACS = 5210 (extensive). Arrows indicate coronary calcified plaques. A, aorta; B, left main coronary artery; C, left anterior descending artery; D, left circumflex artery; E, right coronary artery. CACS, coronary artery calcium score.

Table 1: Clinical applications of CCTA in combination with the CACS in LT candidates.

Study	Patients (n)	Positive criteria; positive patients, n (%)	Clinical outcomes
Jodocy et al. [24]	54	CACS > 300 or > 50% stenosis on CCTA; 24 (44%)	CCTA and CACS are useful tools for perioperative cardiovascular risk assessments.
Cassagneau et al. [10]	52	> 50% stenosis on CCTA; 6 (12%)	The prognostic value of CCTA is comparable to dobutamine stress echocardiography.
Chae et al. [11]	247	Mild to moderate involvement on CCTA; 27 (11%)	CCTA should be included in routine pretransplant cardiac workups.
Kemmer et al. [25]	85	CACS > 100; 30 (35%)	CACS is a valid alternative tool for risk stratification of LT candidates.
Kong et al. [20]	443	CACS > 400; 11 (3%)	CACS > 400 is a predictor of cardiovascular complications following LT.
Poulin et al. [26]	100	≥ 70% stenosis on CCTA and/or CAG; 20 (20%)	Using CCTA in the evaluation of LT candidates is challenging but is feasible and safe.

CACS, coronary artery calcium score; CAD, coronary artery disease; CAG, coronary angiography; CCTA, coronary computed tomography angiography; LT, liver transplantation.

potential to identify a risk for increased CAD across all age groups [82]. CACS is also a useful tool for risk stratification in both younger and elderly patients. In addition, the coronary artery calcium area has been shown to be reflective of the atherosclerotic plaque burden within the coronary system [71]. Serial evaluations of the CACS by computed tomography provide information regarding the progression, stabilization, and regression of coronary artery atherosclerosis. Coronary angiography has high interobserver and intraobserver variability during interpretation [41]. However, the interobserver and intraobserver variability in CACS on computed tomography has been shown to be excellent [83, 84].

The necessary radiation dose for CCTA has been found previously to be in the range of 8–21 mSv, which is higher than that associated with conventional coronary angiography (2–5 mSv) [85]. However, improvements in computed tomography technology and software quality have allowed significant decreases in radiation doses for CCTA image acquisition below 1 mSv [55, 86]. A given CACS must be compared with the score of an average person matched for sex, age, and risk factor profiles for coronary heart disease [87]. The same CACS may have different implications in different people depending on their sex, age, and risk factor profiles. Related factors, including heart rate and irregular heart rhythm, can interfere with the diagnostic quality of the images [88]. Ascites, dyspnea, orthopnea, and altered mental status caused by hepatic encephalopathy can affect breath-holding ability in liver transplant recipients. In addition, the coronary artery lumen on CCTA can be obscured in a region of severe coronary calcification or in the presence of a coronary stent. CCTA also presents difficulties when assessing distal coronary artery segments and some side branches with a diameter < 1.5 mm [89].

6. Conclusion

Notwithstanding diverse clinical experiences and various advances in knowledge, no gold standard has yet been developed for cardiac evaluation in liver transplant candidates. Due to an equal or high incidence of CAD associated with significant morbidity in these patients, the development of a screening protocol with a reliable predictive value is still required. Given that the clinical applications that can be used in liver transplant candidates remain limited, CCTA combined with CACS seems to be a reliable screening option for preoperative noninvasive evaluation of CAD in liver transplant recipients with diabetes mellitus or ≥ 2 traditional risk factors for CAD. Coronary angiography can be performed in liver transplant recipients with coronary artery stenosis ≥ 50% on CCTA or CACS > 400. In addition, CCTA combined with CACS provides useful information for predicting posttransplant cardiovascular complications in patients undergoing liver transplantation.

Competing Interests

The authors declare no competing interests regarding the publication of this paper.

References

[1] T. E. Starzl, T. L. Marchioro, K. N. Vonkaulla, G. Hermann, R. S. Brittain, and W. R. Waddell, "Homotransplantation of the liver in humans," *Surgery, gynecology & obstetrics*, vol. 117, pp. 659–676, 1963.

[2] J. Fung, K. Abu-Elmagd, A. Jain et al., "A randomized trial of primary liver transplantation under immunosuppression with FK 506 vs cyclosporine," *Transplantation Proceedings*, vol. 23, no. 6, pp. 2977–2983, 1991.

[3] G. Therapondos, A. D. Flapan, J. N. Plevris, and P. C. Hayes, "Cardiac morbidity and mortality related to orthotopic liver transplantation," *Liver Transplantation*, vol. 10, no. 12, pp. 1441–1453, 2004.

[4] T. R. Fouad, W. M. Abdel-Razek, K. W. Burak, V. G. Bain, and S. S. Lee, "Prediction of cardiac complications after liver transplantation," *Transplantation*, vol. 87, no. 5, pp. 763–770, 2009.

[5] L. A. Fleisher, K. E. Fleischmann, A. D. Auerbach et al., "2014 ACC/AHA guideline on perioperative cardiovascular evaluation and management of patients undergoing noncardiac surgery: executive summary a report of the american college of cardiology/American Heart Association task force on practice guidelines," *Circulation*, vol. 130, no. 24, pp. 2215–2245, 2014.

[6] G. W. Dec, N. Kondo, M. L. Farrell, J. Dienstag, A. B. Cosimi, and M. J. Semigran, "Cardiovascular complications following liver transplantation," *Clinical Transplantation*, vol. 9, no. 6, pp. 463–471, 1995.

[7] S. D. Johnston, J. K. Morris, R. Cramb, B. K. Gunson, and J. Neuberger, "Cardiovascular morbidity and mortality after orthotopic liver transplantation," *Transplantation*, vol. 73, no. 6, pp. 901–906, 2002.

[8] M. S. Mandell, J. Lindenfeld, M.-Y. Tsou, and M. Zimmerman, "Cardiac evaluation of liver transplant candidates," *World Journal of Gastroenterology*, vol. 14, no. 22, pp. 3445–3451, 2008.

[9] D. Filì, G. Vizzini, D. Biondo et al., "Clinical burden of screening asymptomatic patients for coronary artery disease prior to liver transplantation," *American Journal of Transplantation*, vol. 9, no. 5, pp. 1151–1157, 2009.

[10] P. Cassagneau, A. Jacquier, R. Giorgi et al., "Prognostic value of preoperative coronary computed tomography angiography in patients treated by orthotopic liver transplantation," *European Journal of Gastroenterology and Hepatology*, vol. 24, no. 5, pp. 558–562, 2012.

[11] W.-Y. Chae, S. Hwang, Y.-I. Yoon et al., "Clinical value of preoperative coronary risk assessment by computed tomographic arteriography prior to adult living donor liver transplantation," *Transplantation Proceedings*, vol. 44, no. 2, pp. 415–417, 2012.

[12] C. L. Donovan, P. A. Marcovitz, J. D. Punch et al., "Two-dimensional and dobutamine stress echocardiography in the preoperative assessment of patients with end-stage liver disease prior to orthotopic liver transplantation," *Transplantation*, vol. 61, no. 8, pp. 1180–1188, 1996.

[13] R. Nicolau-Raducu, M. Gitman, D. Ganier et al., "Adverse cardiac events after orthotopic liver transplantation: a cross-sectional study in 389 consecutive patients," *Liver Transplantation*, vol. 21, no. 1, pp. 13–21, 2015.

[14] K. L. Lentine, S. P. Costa, M. R. Weir et al., "Cardiac disease evaluation and management among kidney and liver transplantation candidates: a scientific statement from the American Heart Association and the American College of Cardiology

Foundation," *Journal of the American College of Cardiology*, vol. 60, no. 5, pp. 434–480, 2012.

[15] P. Martin, A. DiMartini, S. Feng, R. Brown, and M. Fallon, "Evaluation for liver transplantation in adults: 2013 practice guideline by the American Association for the Study of Liver Diseases and the American Society of Transplantation," *Hepatology*, vol. 59, no. 3, pp. 1144–1165, 2014.

[16] L. E. Bolick and D. H. Blankenhorn, "A quantitative study of coronary arterial calcification," *The American journal of pathology*, vol. 39, pp. 511–519, 1961.

[17] Z.-H. Hou, B. Lu, Y. Gao et al., "Prognostic value of coronary CT angiography and calcium score for major adverse cardiac events in outpatients," *JACC: Cardiovascular Imaging*, vol. 5, no. 10, pp. 990–999, 2012.

[18] E. Maffei, A. Palumbo, C. Martini et al., "Diagnostic accuracy of 64-slice computed tomography coronary angiography in a large population of patients without revascularisation: registry data and review of multicentre trials," *Radiologia Medica*, vol. 115, no. 3, pp. 368–384, 2010.

[19] W. B. Meijboom, M. F. L. Meijs, J. D. Schuijf et al., "Diagnostic accuracy of 64-slice computed tomography coronary angiography. a prospective, multicenter, multivendor study," *Journal of the American College of Cardiology*, vol. 52, no. 25, pp. 2135–2144, 2008.

[20] Y.-G. Kong, J.-W. Kang, Y.-K. Kim et al., "Preoperative coronary calcium score is predictive of early postoperative cardiovascular complications in liver transplant recipients," *British Journal of Anaesthesia*, vol. 114, no. 3, pp. 437–443, 2015.

[21] M. F. Di Carli and R. Blankstein, "Low yield of routine preoperative coronary computed tomography angiography in patients evaluated for liver transplantation," *Circulation*, vol. 130, no. 16, pp. 1337–1339, 2014.

[22] M. Lemyze, S. Dharancy, and B. Wallaert, "Response to exercise in patients with liver cirrhosis: implications for liver transplantation," *Digestive and Liver Disease*, vol. 45, no. 5, pp. 362–366, 2013.

[23] European Association for the Study of the Liver, "EASL clinical practice guidelines: liver transplantation," *Journal of Hepatology*, vol. 64, no. 2, pp. 433–485, 2016.

[24] D. Jodocy, S. Abbrederis, I. W. Graziadei et al., "Coronary computer tomographic angiography for preoperative risk stratification in patients undergoing liver transplantation," *European Journal of Radiology*, vol. 81, no. 9, pp. 2260–2264, 2012.

[25] N. Kemmer, J. Case, S. Chandna, and G. W. Neff, "The role of coronary calcium score in the risk assessment of liver transplant candidates," *Transplantation Proceedings*, vol. 46, no. 1, pp. 230–233, 2014.

[26] M.-F. Poulin, E. Y. Chan, and R. Doukky, "Coronary computed tomographic angiography in the evaluation of liver transplant candidates," *Angiology*, vol. 66, no. 9, pp. 803–810, 2015.

[27] A. Páll, Á. Czifra, Z. Vitális, M. Papp, G. Paragh, and Z. Szabó, "Pathophysiological and clinical approach to cirrhotic cardiomyopathy," *Journal of Gastrointestinal and Liver Diseases*, vol. 23, no. 3, pp. 301–310, 2014.

[28] S. M. J. M. Straus, J. A. Kors, M. L. De Bruin et al., "Prolonged QTc interval and risk of sudden cardiac death in a population of older adults," *Journal of the American College of Cardiology*, vol. 47, no. 2, pp. 362–367, 2006.

[29] J. M. Prentis, D. M. D. Manas, M. I. Trenell, M. Hudson, D. J. Jones, and C. P. Snowden, "Submaximal cardiopulmonary exercise testing predicts 90-day survival after liver transplantation," *Liver Transplantation*, vol. 18, no. 2, pp. 152–159, 2012.

[30] W. Bernal, R. Martin-Mateos, M. Lipcsey et al., "Aerobic capacity during cardiopulmonary exercise testing and survival with and without liver transplantation for patients with chronic liver disease," *Liver Transplantation*, vol. 20, no. 1, pp. 54–62, 2014.

[31] K. F. Murray and R. L. Carithers Jr., "AASLD practice guidelines: evaluation of the patient for liver transplantation," *Hepatology*, vol. 41, no. 6, pp. 1407–1432, 2005.

[32] M. L. Geleijnse, B. J. Krenning, B. M. van Dalen et al., "Factors affecting sensitivity and specificity of diagnostic testing: dobutamine stress echocardiography," *Journal of the American Society of Echocardiography*, vol. 22, no. 11, pp. 1199–1208, 2009.

[33] P. Nguyen, J. Plotkin, T. M. Fishbein et al., "Dobutamine stress echocardiography in patients undergoing orthotopic liver transplantation: a pooled analysis of accuracy, perioperative and long term cardiovascular prognosis," *International Journal of Cardiovascular Imaging*, vol. 29, no. 8, pp. 1741–1748, 2013.

[34] D. Snipelisky, M. Levy, and B. Shapiro, "Utility of dobutamine stress echocardiography as part of the pre-liver transplant evaluation: an evaluation of its efficacy," *Clinical Cardiology*, vol. 37, no. 8, pp. 468–472, 2014.

[35] M. E. Harinstein, J. D. Flaherty, A. H. Ansari et al., "Predictive value of dobutamine stress echocardiography for coronary artery disease detection in liver transplant candidates," *American Journal of Transplantation*, vol. 8, no. 7, pp. 1523–1528, 2008.

[36] L. G. Umphrey, R. T. Hurst, M. F. Eleid et al., "Preoperative dobutamine stress echocardiographic findings and subsequent short-term adverse cardiac events after orthotopic liver transplantation," *Liver Transplantation*, vol. 14, no. 6, pp. 886–892, 2008.

[37] J. Ehtisham, M. Altieri, E. Salamé, E. Saloux, I. Ollivier, and M. Hamon, "Coronary artery disease in orthotopic liver transplantation: pretransplant assessment and management," *Liver Transplantation*, vol. 16, no. 5, pp. 550–557, 2010.

[38] S. R. Underwood, C. Anagnostopoulos, M. Cerqueira et al., "Myocardial perfusion scintigraphy: the evidence," *European Journal of Nuclear Medicine and Molecular Imaging*, vol. 31, no. 2, pp. 261–291, 2004.

[39] C. J. Davidson, M. Gheorghiade, J. D. Flaherty et al., "Predictive value of stress myocardial perfusion imaging in liver transplant candidates," *American Journal of Cardiology*, vol. 89, no. 3, pp. 359–360, 2002.

[40] S. Bhutani, J. Tobis, R. Gevorgyan et al., "Accuracy of stress myocardial perfusion imaging to diagnose coronary artery disease in end stage liver disease patients," *The American Journal of Cardiology*, vol. 111, no. 7, pp. 1057–1061, 2013.

[41] P. J. Scanlon, D. P. Faxon, A. M. Audet et al., "ACC/AHA guidelines for coronary angiography: executive summary and recommendations. A report of the American College of Cardiology/American Heart Association Task Force on Practice Guidelines (Committee on Coronary Angiography) developed in collaboration with the Society for Cardiac Angiography and Interventions," *Circulation*, vol. 99, no. 17, pp. 2345–2357, 1999.

[42] S. Baker, C. Chambers, P. Mcquillan et al., "Myocardial perfusion imaging is an effective screening test for coronary artery disease in liver transplant candidates," *Clinical Transplantation*, vol. 29, no. 4, pp. 319–326, 2015.

[43] E. J. Topol and S. E. Nissen, "Our preoccupation with coronary luminology. The dissociation between clinical and angiographic findings in ischemic heart disease," *Circulation*, vol. 92, no. 8, pp. 2333–2342, 1995.

[44] H. Maddur, P. D. Bourdillon, S. Liangpunsakul et al., "Role of cardiac catheterization and percutaneous coronary intervention in the preoperative assessment and management of patients before orthotopic liver transplantation," *Liver Transplantation*, vol. 20, no. 6, pp. 664–672, 2014.

[45] D. F. Snipelisky, C. McRee, K. Seeger, M. Levy, and B. P. Shapiro, "Coronary interventions before liver transplantation: might not avert postoperative cardiovascular events," *Texas Heart Institute Journal*, vol. 42, no. 5, pp. 438–442, 2015.

[46] B. G. Keeffe, H. Valantine, and E. B. Keeffe, "Detection and treatment of coronary artery disease in liver transplant candidates," *Liver Transplantation*, vol. 7, no. 9, pp. 755–761, 2001.

[47] C. P. Huded, J. E. Blair, R. N. Sweis, and J. D. Flaherty, "Transradial cardiac catheterization in liver transplant candidates," *American Journal of Cardiology*, vol. 113, no. 10, pp. 1634–1638, 2014.

[48] E. Jacobs, V. Singh, A. Damluji et al., "Safety of transradial cardiac catheterization in patients with end-stage liver disease," *Catheterization and Cardiovascular Interventions*, vol. 83, no. 3, pp. 360–366, 2014.

[49] B. C. Lee, F. Li, A. J. Hanje, K. Mumtaz, K. D. Boudoulas, and S. M. Lilly, "Effectively screening for coronary artery disease in patients undergoing orthotopic liver transplant evaluation," *Journal of Transplantation*, vol. 2016, Article ID 7187206, 5 pages, 2016.

[50] L. Xu, Z. Sun, and Z. Fan, "Noninvasive physiologic assessment of coronary stenoses using cardiac CT," *BioMed Research International*, vol. 2015, Article ID 435737, 12 pages, 2015.

[51] J. Abdulla, S. Z. Abildstrom, O. Gotzsche, E. Christensen, L. Kober, and C. Torp-Pedersen, "64-Multislice detector computed tomography coronary angiography as potential alternative to conventional coronary angiography: a systematic review and meta-analysis," *European Heart Journal*, vol. 28, no. 24, pp. 3042–3050, 2007.

[52] E. Maffei, C. Martini, S. Seitun et al., "Computed tomography coronary angiography in the selection of outlier patients: a feasibility report," *Radiologia Medica*, vol. 117, no. 2, pp. 214–229, 2012.

[53] M. Dewey, E. Zimmermann, F. Deissenrieder et al., "Noninvasive coronary angiography by 320-row computed tomography with lower radiation exposure and maintained diagnostic accuracy: comparison of results with cardiac catheterization in a head-to-head pilot investigation," *Circulation*, vol. 120, no. 10, pp. 867–875, 2009.

[54] J. P. Earls, E. L. Berman, B. A. Urban et al., "Prospectively gated transverse coronary CT angiography versus retrospectively gated helical technique: improved image quality and reduced radiation dose," *Radiology*, vol. 246, no. 3, pp. 742–753, 2008.

[55] S. Achenbach, M. Marwan, D. Ropers et al., "Coronary computed tomography angiography with a consistent dose below 1 mSv using prospectively electrocardiogram-triggered high-pitch spiral acquisition," *European Heart Journal*, vol. 31, no. 3, pp. 340–346, 2010.

[56] R. Ross, "The pathogenesis of atherosclerosis: a perspective for the 1990s," *Nature*, vol. 362, no. 6423, pp. 801–809, 1993.

[57] A. W. Leber, A. Becker, A. Knez et al., "Accuracy of 64-slice computed tomography to classify and quantify plaque volumes in the proximal coronary system: a comparative study using intravascular ultrasound," *Journal of the American College of Cardiology*, vol. 47, no. 3, pp. 672–677, 2006.

[58] M. G. Dalager, M. Bøttcher, J. Thygesen, G. Andersen, and H. E. Bøtker, "Different plaque composition and progression in patients with stable and unstable coronary syndromes evaluated by cardiac CT," *BioMed Research International*, vol. 2015, Article ID 401357, 9 pages, 2015.

[59] H. S. Hecht and G. Roubin, "Usefulness of computed tomographic angiography guided percutaneous coronary intervention," *American Journal of Cardiology*, vol. 99, no. 6, pp. 871–875, 2007.

[60] S. Schroeder, A. Kuettner, M. Leitritz et al., "Reliability of differentiating human coronary plaque morphology using contrast-enhanced multislice spiral computed tomography: a comparison with histology," *Journal of Computer Assisted Tomography*, vol. 28, no. 4, pp. 449–454, 2004.

[61] R. Virmani, A. P. Burke, A. Farb, and F. D. Kolodgie, "Pathology of the vulnerable plaque," *Journal of the American College of Cardiology*, vol. 47, no. 8, supplement, pp. C13–C18, 2006.

[62] G. T. Gyenes and W. A. Ghali, "Should all patients with asymptomatic but significant (> 50%) left main coronary artery stenosis undergo surgical revascularization?" *Circulation*, vol. 118, no. 4, pp. 422–425, 2008.

[63] S. Achenbach, "Quantification of coronary artery stenoses by computed tomography," *JACC: Cardiovascular Imaging*, vol. 1, no. 4, pp. 472–474, 2008.

[64] J. An, J. H. Shim, S.-O. Kim et al., "Prevalence and prediction of coronary artery disease in patients with liver cirrhosis: a registry-based matched case-control study," *Circulation*, vol. 130, no. 16, pp. 1353–1362, 2014.

[65] A. B. Meijer, Y. L. O, J. Geleijns, and L. J. M. Kroft, "Meta-analysis of 40- and 64-MDCT angiography for assessing coronary artery stenosis," *American Journal of Roentgenology*, vol. 191, no. 6, pp. 1667–1675, 2008.

[66] G. Mowatt, J. A. Cook, G. S. Hillis et al., "64-Slice computed tomography angiography in the diagnosis and assessment of coronary artery disease: systematic review and meta-analysis," *Heart*, vol. 94, no. 11, pp. 1386–1393, 2008.

[67] G. M. Schuetz, N. M. Zacharopoulou, P. Schlattmann, and M. Dewey, "Meta-analysis: noninvasive coronary angiography using computed tomography versus magnetic resonance imaging," *Annals of Internal Medicine*, vol. 152, no. 3, pp. 167–177, 2010.

[68] R. Blankstein and M. F. Di Carli, "Integration of coronary anatomy and myocardial perfusion imaging," *Nature Reviews Cardiology*, vol. 7, no. 4, pp. 226–236, 2010.

[69] J. Baxa, M. Hromádka, J. Šedivý et al., "Regadenoson-stress dynamic myocardial perfusion improves diagnostic performance of CT angiography in assessment of intermediate coronary artery stenosis in asymptomatic patients," *BioMed Research International*, vol. 2015, Article ID 105629, 7 pages, 2015.

[70] A. S. Agatston, W. R. Janowitz, F. J. Hildner, N. R. Zusmer, M. Viamonte Jr., and R. Detrano, "Quantification of coronary artery calcium using ultrafast computed tomography," *Journal of the American College of Cardiology*, vol. 15, no. 4, pp. 827–832, 1990.

[71] J. A. Rumberger, D. B. Simons, L. A. Fitzpatrick, P. F. Sheedy, and R. S. Schwartz, "Coronary artery calcium area by electron-beam computed tomography and coronary atherosclerotic plaque area: a histopathologic correlative study," *Circulation*, vol. 92, no. 8, pp. 2157–2162, 1995.

[72] J. F. Breen, P. F. Sheedy II, R. S. Schwartz et al., "Coronary artery calcification detected with ultrafast CT as an indication of coronary artery disease," *Radiology*, vol. 185, no. 2, pp. 435–439, 1992.

[73] J. A. Rumberger, B. H. Brundage, D. J. Rader, and G. Kondos, "Electron beam computed tomographic coronary calcium scanning: a review and guidelines for use in asymptomatic persons," *Mayo Clinic Proceedings*, vol. 74, no. 3, pp. 243–252, 1999.

[74] P. G. O'Malley, A. J. Taylor, J. L. Jackson, T. M. Doherty, and R. C. Detrano, "Prognostic value of coronary electron-beam computed tomography for coronary heart disease events in asymptomatic populations," *American Journal of Cardiology*, vol. 85, no. 8, pp. 945–948, 2000.

[75] M. J. Pletcher, J. A. Tice, M. Pignone, and W. S. Browner, "Using the coronary artery calcium score to predict coronary heart disease events: a systematic review and meta-analysis," *Archives of Internal Medicine*, vol. 164, no. 12, pp. 1285–1292, 2004.

[76] L. J. Shaw, P. Raggi, E. Schisterman, D. S. Berman, and T. Q. Callister, "Prognostic value of cardiac risk factors and coronary artery calcium screening for all-cause mortality," *Radiology*, vol. 228, no. 3, pp. 826–833, 2003.

[77] R. Detrano, A. D. Guerci, J. J. Carr et al., "Coronary calcium as a predictor of coronary events in four racial or ethnic groups," *New England Journal of Medicine*, vol. 358, no. 13, pp. 1336–1345, 2008.

[78] M. Blaha, M. J. Budoff, L. J. Shaw et al., "Absence of coronary artery calcification and all-cause mortality," *JACC: Cardiovascular Imaging*, vol. 2, no. 6, pp. 692–700, 2009.

[79] Y.-G. Kong, T.-Y. Ha, J.-W. Kang, S. Hwang, S.-G. Lee, and Y.-K. Kim, "Incidence and predictors of increased coronary calcium scores in liver transplant recipients," *Transplantation Proceedings*, vol. 47, no. 6, pp. 1933–1938, 2015.

[80] Z. Raval, M. E. Harinstein, A. I. Skaro et al., "Cardiovascular risk assessment of the liver transplant candidate," *Journal of the American College of Cardiology*, vol. 58, no. 3, pp. 223–231, 2011.

[81] N. C. McAvoy, N. Kochar, G. McKillop, D. E. Newby, and P. C. Hayes, "Prevalence of coronary artery calcification in patients undergoing assessment for orthotopic liver transplantation," *Liver Transplantation*, vol. 14, no. 12, pp. 1725–1731, 2008.

[82] R. Tota-Maharaj, M. J. Blaha, R. Blankstein et al., "Association of coronary artery calcium and coronary heart disease events in young and elderly participants in the multi-ethnic study of atherosclerosis: a secondary analysis of a prospective, population-based cohort," *Mayo Clinic Proceedings*, vol. 89, no. 10, pp. 1350–1359, 2014.

[83] L. S. Broderick, J. Shemesh, R. L. Wilensky et al., "Measurement of coronary artery calcium with dual-slice helical CT compared with coronary angiography: evaluation of CT scoring methods, interobserver variations, and reproducibility," *American Journal of Roentgenology*, vol. 167, no. 2, pp. 439–444, 1996.

[84] R. B. Kaufmann, P. F. Sheedy II, J. F. Breen et al., "Detection of heart calcification with electron beam CT: interobserver and intraobserver reliability for scoring quantification," *Radiology*, vol. 190, no. 2, pp. 347–352, 1994.

[85] J. Hausleiter, T. Meyer, M. Hadamitzky et al., "Radiation dose estimates from cardiac multislice computed tomography in daily practice: impact of different scanning protocols on effective dose estimates," *Circulation*, vol. 113, no. 10, pp. 1305–1310, 2006.

[86] J. Stehli, T. A. Fuchs, S. Bull et al., "Accuracy of coronary CT angiography using a submillisievert fraction of radiation exposure: comparison with invasive coronary angiography," *Journal of the American College of Cardiology*, vol. 64, no. 8, pp. 772–780, 2014.

[87] M. J. Pletcher, J. A. Tice, M. Pignone, C. McCulloch, T. Q. Callister, and W. S. Browner, "What does my patient's coronary artery calcium score mean? Combining information from the coronary artery calcium score with information from conventional risk factors to estimate coronary heart disease risk," *BMC Medicine*, vol. 2, article 31, 2004.

[88] M. H. K. Hoffmann, H. Shi, R. Manzke et al., "Noninvasive coronary angiography with 16-detector row CT: effect of heart rate," *Radiology*, vol. 234, no. 1, pp. 86–97, 2005.

[89] D. A. Bluemke, S. Achenbach, M. Budoff et al., "Noninvasive coronary artery imaging: magnetic resonance angiography and multidetector computed tomography angiography: a scientific statement from the American Heart Association committee on cardiovascular imaging and intervention of the council on cardiovascular radiology and intervention, and the councils on clinical cardiology and cardiovascular disease in the young," *Circulation*, vol. 118, no. 5, pp. 586–606, 2008.

Hindawi Publishing Corporation
BioMed Research International
Volume 2016, Article ID 3681731, 8 pages
http://dx.doi.org/10.1155/2016/3681731

Clinical Study

Pathological Predictors of Shunt Stenosis and Hepatic Encephalopathy after Transjugular Intrahepatic Portosystemic Shunt

Fuliang He,[1] Shan Dai,[1] Zhibo Xiao,[2] Lei Wang,[1] Zhendong Yue,[1] Hongwei Zhao,[1] Mengfei Zhao,[1] Qiushi Lin,[3] Xiaoqun Dong,[1,3] and Fuquan Liu[1]

[1]*Department of Interventional Therapy, Beijing Shijitan Hospital, Capital Medical University, The 9th Affiliated Hospital of Peking University, Beijing 100038, China*
[2]*Department of Plastic Surgery, The Second Affiliated Hospital of Harbin Medical University, Harbin 150081, China*
[3]*Department of Internal Medicine, Section of Hematology-Oncology, Section of Gastroenterology, Stephenson Cancer Center, College of Medicine, University of Oklahoma Health Sciences Center, Oklahoma City, OK 73104, USA*

Correspondence should be addressed to Fuquan Liu; liufq_sjt@163.com

Received 14 July 2016; Revised 22 August 2016; Accepted 31 August 2016

Academic Editor: Xingshun Qi

Background. Transjugular intrahepatic portosystemic shunt (TIPS) is an artificial channel from the portal vein to the hepatic vein or vena cava for controlling portal vein hypertension. The major drawbacks of TIPS are shunt stenosis and hepatic encephalopathy (HE); previous studies showed that post-TIPS shunt stenosis and HE might be correlated with the pathological features of the liver tissues. Therefore, we analyzed the pathological predictors for clinical outcome, to determine the risk factors for shunt stenosis and HE after TIPS. *Methods.* We recruited 361 patients who suffered from portal hypertension symptoms and were treated with TIPS from January 2009 to December 2012. *Results.* Multivariate logistic regression analysis showed that the risk of shunt stenosis was increased with more severe inflammation in the liver tissue (OR, 2.864; 95% CI: 1.466–5.592; $P = 0.002$), HE comorbidity (OR, 6.266; 95% CI, 3.141–12.501; $P < 0.001$), or higher MELD score (95% CI, 1.298–1.731; $P < 0.001$). Higher risk of HE was associated with shunt stenosis comorbidity (OR, 6.266; 95% CI, 3.141–12.501; $P < 0.001$), higher stage of the liver fibrosis (OR, 2.431; 95% CI, 1.355–4.359; $P = 0.003$), and higher MELD score (95% CI, 1.711–2.406; $P < 0.001$). *Conclusion.* The pathological features can predict individual susceptibility to shunt stenosis and HE.

1. Introduction

Portal hypertension is defined as an increase in the blood pressure of portal venous system [1]. Portal vein pressure ranges between 1 and 4 mmHg higher than the hepatic vein (HV) pressure and not more than 6 mmHg higher than right atrial pressure [2]. Portal hypertension is defined as portal pressures that exceed these limits. Transjugular intrahepatic portosystemic shunt (TIPS) is an artificial channel from the portal vein to the hepatic vein. TIPS has been demonstrated as an effective procedure to control serious complications including gastrointestinal bleeding and refractory ascites in patients with portal hypertension caused by liver cirrhosis, Budd-Chiari syndrome (BCS), and other liver diseases. The technical success rate of TIPS has reached 95–100% whereas an operation-related mortality rate was only 1%. It can manage >90% gastrointestinal bleeding and 50–92% refractory ascites [3]. It is thus well accepted that TIPS plays an important role in treatment of patients with portal hypertension syndrome.

The major drawbacks of TIPS are shunt stenosis and hepatic encephalopathy (HE), which dramatically reduce the prognosis of TIPS and influence the patients' quality of life [4]. Our previous study showed that post-TIPS HE which occurred within 3 months was associated with high MELD score [5]. Several recent studies have revealed that the incidence of shunt stenosis and HE might be correlated with the pathological features of the liver tissues [6, 7]. Therefore, it

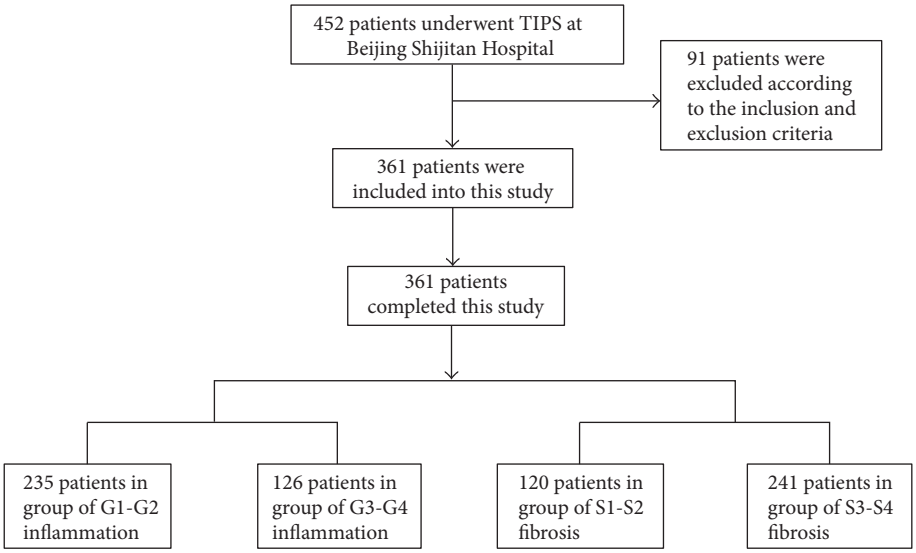

Figure 1: Enrollment flowchart of patients included in this study.

is of great interest to elucidate whether pathological disorders of cirrhosis liver tissue confer the risk for post-TIPS shunt stenosis and HE. Thus, we performed biopsy of the liver tissues from the original shunt to each patient during TIPS in our single center. We analyzed the clinical and pathological data of the patients enrolled to determine the risk factors for HE and shunt stenosis after TIPS.

2. Materials and Methods

2.1. Clinical Data of the Patients. This study was approved by Institutional Review Board (IRB) committee at Beijing Shijitan Hospital. All procedures were carried out according to the guidelines approved by the ethics committee at Beijing Shijitan Hospital (approval number: 2008001). Informed consents of the procedures and data collection were acquired from all the patients and their families.

Inclusion and exclusion criteria were carefully designed to exclude the confounding factors. The inclusion criteria were (1) portal hypertension caused by hepatitis B-related cirrhosis; (2) indications for TIPS treatment: secondary prevention for variceal bleeding and/or refractory ascites; (3) signed informed consent; and (4) aged between 18 and 75 years. The patients with one or more of the following characteristics were excluded: (1) patients with portal hypertension combined with primary or metastatic liver tumors, (2) combined with HE before the treatment, (3) combined with active variceal bleeding (the time frame of the acute bleeding episode should be 3 days), and (4) combined with hemorrhage of gastrointestinal ulcer; (5) patients with history of TIPS placement or shunt surgery; (6) patients with severe cardiopulmonary diseases; and (7) patients with uncontrolled systemic infection.

Between January 2009 and December 2012, 452 patients underwent TIPS at the Department of Interventional Therapy, Beijing Shijitan Hospital, Capital Medical University (Beijing, China). Among these patients, 361 patients were enrolled into this study according to the inclusion and exclusion criteria (Figure 1). After hospitalization, a magnetic resonance imaging of the portal vein (MRPV) (Figures 2(a) and 3(a)) was performed on each patient. Laboratory tests, including alanine aminotransferase (ALT), aspartate aminotransferase (AST), and blood ammonia, were recorded for each patient before TIPS. All the patients underwent the TIPS procedure and biopsy. Complete clinical and pathological data were collected retrospectively for those patients.

2.2. Procedures of TIPS. The TIPS procedure under general anesthesia was conducted in the Interventional Radiology Center. The Rösch Uchida Transjugular Liver Access Set (Cook, Bloomington, IN, United States) was used. The right internal jugular vein puncture was performed and a 10-F sheath was placed in the vein. After a 5-F multipurpose catheter was used to engage the right hepatic vein, a 10-F curved cannula was delivered into the hepatic vein. A puncture needle in a sheath was advanced into the portal vein through the liver parenchyma and the guide wire was placed into the portal vein through the sheath. A 5-F pigtail catheter was used for angiography and pressure measurement of the portal vein, and an 8 mm or 10 mm diameter angioplasty balloon according to the portal vein was introduced along the guide wire to dilate the shunt. Liver tissues were obtained with biopsy forceps before balloon dilation: biopsy forceps (Minimally Invasive Medical Technology Co., Ltd., Nanjing, China) were inserted through the 10-F curved cannula to the liver parenchyma to obtain the liver tissues (Figures 2(b) and 3(b)). After the biopsy, a covered stent (Bard, Fluency) with a diameter of 8 mm or 10 mm according to the portal vein diameter was implanted to the predilated channel. An additional stent was utilized to extend the shunt if one stent was not enough. The varicose coronary gastric vein was embolized to prevent future gastrointestinal bleeding. The portal vein angiography (Figures 2(c) and 3(c)) and portal pressure measurement were performed after the procedure.

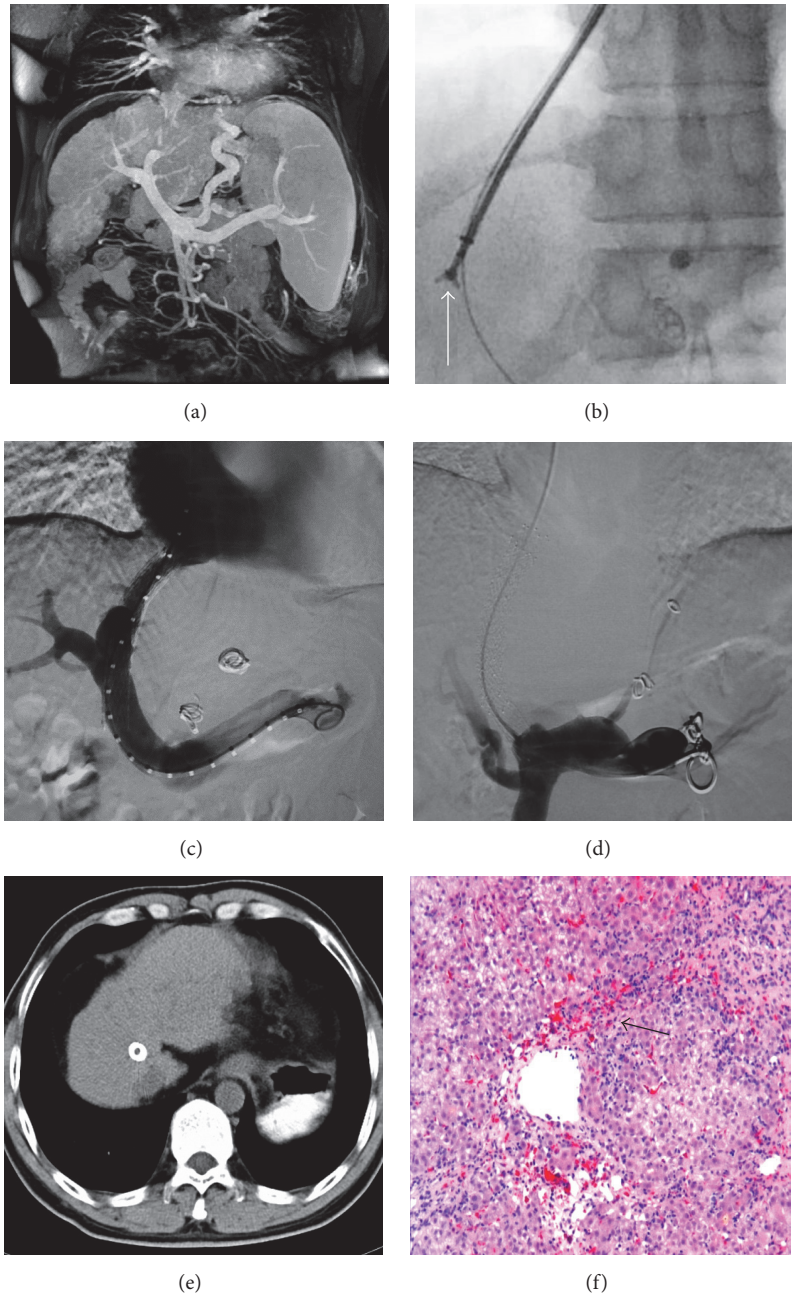

Figure 2: A representative case of shunt restenosis. This was from a 42 y/o male patient, who was diagnosed with hepatitis B-related liver cirrhosis and had suffered from gastrointestinal bleeding 2 weeks before hospitalization. (a) Coronal image of MRPV showed severe cirrhosis and portal hypertension leading to gastric coronary vein varices and splenomegaly. (b) Biopsy with the forceps before balloon dilation of the shunt under X-ray (the arrow pointed at the tip of the forceps). (c) Angiography showed that TIPS was performed successfully after the biopsy, with no procedure-related complications. (d) Angiography after 16 months of TIPS showed that the shunt was totally occluded. (e) The transverse image of CT after 16 months of TIPS highlighted the positon of the stent and revealed that the cirrhosis was still severe. (f) Pathological diagnosis demonstrated the widespread intralobular bridging necrosis with multiple hepatic lobules involved (arrow), which meant stage III inflammation (H&E staining, ×100).

The portosystemic pressure gradient (PSG) was measured before and after the shunt creation.

2.3. Pathological Information and Patient Grouping. Pathological diagnosis was performed for all the liver tissues that were collected during TIPS, to identify the severity of inflammation (Figure 2(f)) and the presence of fibrosis (Figure 3(d)), which were caused by dilation of the liver parenchyma. The patients were divided into 2 groups according to pathological characteristics: (1) group G0–G2 versus group G3-G4 based on inflammation or (2) group S0–S2 versus group S3-S4 based on fibrosis.

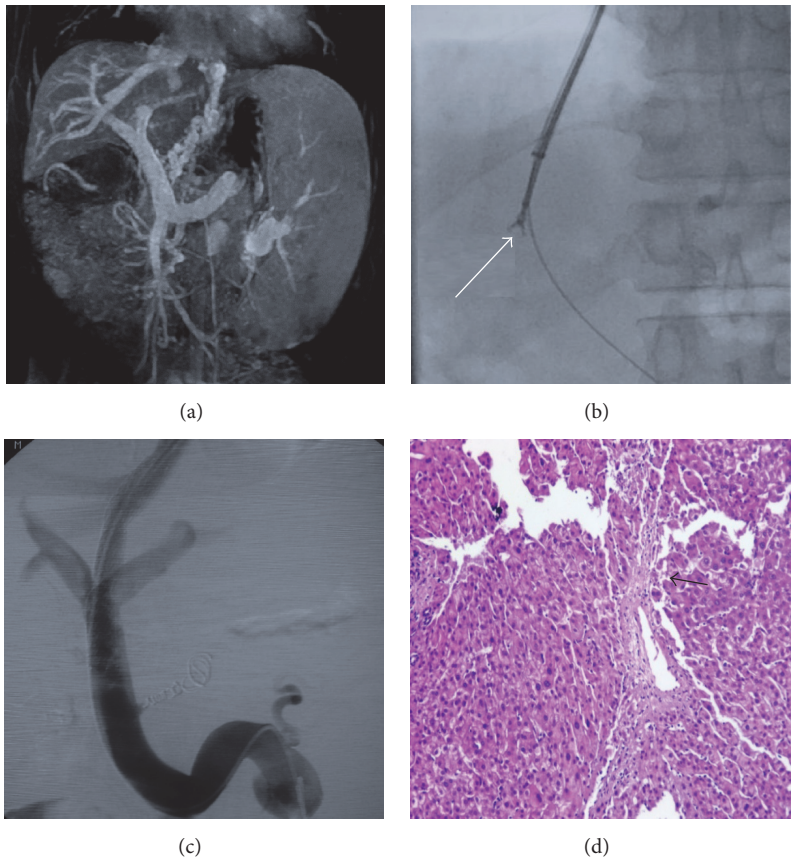

Figure 3: A representative case of HE after TIPS. This was from a 56 y/o male patient diagnosed with hepatitis B-related cirrhosis, who had suffered from gastrointestinal bleeding 4 weeks before hospitalization. The patient developed HE at 1 month after TIPS. (a) Coronal image of MRPV showed liver cirrhosis, severe gastric coronary vein varices, and splenomegaly induced by portal hypertension. (b) Biopsy with the forceps before balloon dilation of the shunt under X-ray (the arrow pointed at the tip of the forceps). (c) Angiography showed that TIPS was performed successfully after the biopsy, with no procedure-related complications. (d) Pathological characteristics of the liver tissues obtained during TIPS highlighted the fibrous septum with disturbance of hepatic lobule (arrow), which meant grade III fibrosis (H&E staining, ×100).

2.4. Postoperative Treatment and Observation. All the patients were asked to stay in bed for 8 h after the operation; pressure dressing and sand bag pressing were used for the piercing site area, and the vital signs of the patients were real-time monitored. Intravenous injection of branched chain amino acid (250–500 mL, 1 time/day) and oral administration of lactulose (15–30 mL, 2-3 times/day) were used routinely to prevent HE. Liver protection strategy was taken (bicyclol tablets, 25 mg, p.o., 3 times/day).

Demographic and clinical characteristics of the patients 1 week before and after TIPS were collected. Complications including abdominal cavity hemorrhage, subcapsular hematoma, hepatic failure, infection, bile peritonitis, or pneumothorax were closely observed during the perioperative period.

2.5. Follow-Up. The patients were routinely followed up for 24 months. Dietary guidance against HE was given to each patient. Clinical and demographic parameters were compared between these groups. The patients underwent ultrasound examination at 1, 3, 6, 12, and 24 months after TIPS placement. Incidence rates of shunt stenosis and HE after TIPS were calculated.

2.6. Statistical Analyses. SPSS 17.0 software was used for statistical analyses. Quantitative data was described as mean ± standard division (SD). Qualitative data was described as frequencies and percentages. Student's t-test and chi-square test were used for the comparisons of the quantitative and qualitative data. Multivariate logistic regression analysis was used to assess the risk factors related to the endpoints. The odds ratio (OR) values with 95% confidence intervals (CI) were calculated. A P value of <0.05 was considered statistically significant.

3. Results

3.1. Patient Data. A total of 361 patients were enrolled in the study (Table 1). The mean age was 49.90 ± 11.34 years old. The hepatic function status was evaluated by Child-Pugh classification, dividing the patients into 3 groups: 207, 93, and 61 in classes A, B, and C, respectively. The mean MELD score was 10.60 ± 3.11. The ALT, AST, and blood ammonia before TIPS were 45.87 ± 17.88 U/L, 41.02 ± 14.77 U/L, and 82.70 ± 18.48 μmol/L, respectively. The indications for TIPS included gastroesophageal variceal bleeding in 301 patients, refractory ascites in 43 patients, and gastroesophageal variceal bleeding

Table 1: Demographics and clinical and pathological characteristics of patients undergoing TIPS.

Variable	Overall	Stenosis (n = 40)	Nonstenosis (n = 321)	P value	HE (n = 86)	Non-HE (n = 275)	P value
Age (mean ± SD, years)	49.90 ± 11.34	50.45 ± 10.33	49.83 ± 11.7	0.747	50.37 ± 10.18	49.76 ± 11.69	0.661
MELD score	10.60 ± 3.11	13.05 ± 2.06	10.25 ± 3.05	<0.001	13.52 ± 2.22	9.68 ± 2.77	<0.001
Bilirubin (μmol/L)	33.65 ± 66.83	40.38 ± 58.11	33.25 ± 30.23	<0.001	39.26 ± 50.14	40.15 ± 28.96	<0.001
Creatinine (mg/dL)	0.82 ± 0.45	0.83 ± 0.41	0.81 ± 0.36	0.264	0.89 ± 0.31	0.80 ± 0.44	0.546
INR	1.40 ± 0.32	1.46 ± 0.35	1.39 ± 0.28	0.864	1.45 ± 0.34	1.40 ± 0.29	0.901
Blood ammonia	82.70 ± 18.48	82.95 ± 19.22	82.67 ± 18.41	0.929	86.77 ± 2.05	81.43 ± 17.44	0.035
ALT (U/L)	45.87 ± 17.88	45.38 ± 16.66	45.93 ± 18.05	0.852	49.52 ± 19.98	44.73 ± 17.05	0.047
AST (U/L)	41.02 ± 14.77	43.05 ± 15.71	40.77 ± 14.65	0.358	42.74 ± 14.45	40.49 ± 14.85	0.217
PVP pre-TIPS	40.07 ± 3.25	43.18 ± 3.57	39.81 ± 3.12	<0.001	44.30 ± 2.34	38.75 ± 2.19	<0.001
PVP post-TIPS	11.03 ± 1.87	11.45 ± 2.23	10.98 ± 1.82	0.130	11.85 ± 1.80	10.77 ± 1.82	<0.001
PVP reduction	29.04 ± 3.42	30.73 ± 3.88	28.83 ± 3.30	0.001	32.45 ± 2.81	27.98 ± 2.85	<0.001
Gender							
Male (n/%)	237 (65.7)	24 (60.0)	213 (66.4)	0.425	54 (62.8)	183 (66.5)	0.552
Female (n/%)	124 (34.3)	16 (40.0)	108 (33.6)		32 (37.2)	92 (33.5)	
Inflammation grading							
G1-G2	235 (65.1)	17 (42.5)	218 (67.9)	0.001	41 (47.4)	194 (70.5)	<0.001
G3-G4	126 (34.9)	23 (57.5)	103 (32.1)		45 (52.3)	81 (29.5)	
Fibrosis staging							
S1-S2	120 (33.2)	8 (20.0)	112 (34.9)	0.074	17 (19.8)	103 (37.5)	0.002
S3-S4	241 (66.8)	32 (80.0)	209 (65.1)		69 (80.2)	172 (62.5)	
HE occurrence						Shunt restenosis occurrence	
Y	86 (23.8)	24 (60.0)	62 (19.3)	<0.001	24 (27.9)	16 (5.8)	<0.001
N	275 (76.2)	16 (40.0)	259 (80.7)		62 (72.1)	259 (94.2)	
Indication of TIPS							
Gastric variceal bleeding	301 (83.4)	35 (87.5)	266 (82.9)	0.865	74 (86.0)	227 (82.5)	0.785
Refractory ascites	43 (11.9)	4 (10.0)	39 (12.1)		8 (9.3)	25 (12.7)	
Both symptoms	17 (4.7)	1 (2.5)	16 (5.0)		4 (4.7)	13 (4.8)	
Child-Pugh classification							
A	207 (57.3)	18 (45.0)	189 (58.9)	0.164	50 (58.7)	157 (57.1)	0.875
B	93 (25.8)	15 (37.5)	78 (24.3)		23 (26.7)	70 (25.5)	
C	61 (16.9)	7 (17.5)	54 (16.8)		13 (15.1)	48 (17.5)	
Number of stents							
1	270 (74.8)	30 (75.0)	240 (74.8)	0.974	61 (70.9)	209 (76.0)	0.345
2	91 (25.2)	10 (25.0)	81 (25.2)		25 (29.1)	66 (24.0)	
Diameter of stent (mm)							
8	298 (82.5)	32 (80.0)	266 (82.9)	0.660	74 (86.0)	224 (81.5)	0.327
10	63 (17.5)	8 (20.0)	55 (17.1)		12 (14.0)	51 (18.5)	

TIPS: transjugular intrahepatic portosystemic shunt; MELD: model for end-stage liver disease; INR: international normalized ratio; ALT: alanine aminotransferase; AST: aspartate aminotransferase; PVP: portal vein pressure; G: grading; S: staging; HE: hepatic encephalopathy.

Table 2: Multivariate analysis of the risk factors of stent restenosis.

Index	OR (95% CI)	*P* value
Inflammation grading	2.864 (1.466–5.592)	0.002
MELD score	1.499 (1.298–1.731)	<0.001
HE occurrence	6.266 (3.141–12.501)	<0.001

MELD: model for end-stage liver disease; HE: hepatic encephalopathy.

Table 3: Multivariate analysis of the risk factors of HE.

Index	OR (95% CI)	*P* value
Fibrosis staging	2.431 (1.355–4.359)	0.003
MELD score	2.029 (1.711–2.406)	<0.001
Shunt restenosis occurrence	6.266 (3.141–12.501)	<0.001

HE: hepatic encephalopathy; MELD model for end-stage liver disease; PVP: portal vein pressure.

combined with refractory ascites in 17 patients. The mean PSG before and after TIPS shunt creation was 32.86 ± 2.23 mmHg and 10.03 ± 1.87 mmHg, respectively. The 8 mm stent was used in 298 patients, whereas the 10 mm stent was used in 63 patients. The number of stents utilized was 1 in 270 patients and 2 in 91 patients, respectively.

3.2. Pathological Examination Results. As for inflammation grading, 235 (65.1%) of the 361 patients were in grades G1-G2 and 126 (34.9%) patients in G3-G4. As for staging of the liver fibrosis, 120 (33.2%) patients were in S1-S2 and 241 (66.8%) patients in S3-S4. The biopsy during TIPS was successful in all cases (100%), and no procedure-related complications including abdominal cavity hemorrhage, subcapsular hematoma, infection, damage of vein, bile peritonitis, or pneumothorax were observed.

3.3. Factors Associated with Shunt Stenosis and HE. Shunt stenosis developed in 40 (11.1%) cases within two years. In univariate analysis, the severity of the liver inflammation, MELD score, PSG before TIPS shunting, and PSG reduction were associated with shunt stenosis. The multivariate logistic regression analysis showed that the risk of shunt stenosis was much higher in patients with more severe inflammation in liver tissue (odds ratio [OR], 2.864; 95% CI: 1.466–5.592; $P = 0.002$) or HE occurrence (OR, 6.266; 95% CI, 3.141–12.501; $P < 0.001$). The risk of shunt stenosis increased about 50% for each 1-point increase in the MELD score (95% CI, 1.298–1.731; $P < 0.001$) (Table 2).

In the present study, HE occurred in 86 (23.8%) patients. In univariate analysis, HE after TIPS was associated with staging of the liver fibrosis, inflammation severity, occurrence of shunt stenosis, MELD score, blood ammonia level, ALT level before TIPS, PSG before TIPS, PSG after TIPS, and PSG reduction. In multivariate logistic regression analysis, the risk of HE was much higher in those with high stage of the liver fibrosis (OR, 2.431; 95% CI, 1.355–4.359; $P = 0.003$) or shunt stenosis occurrence (OR, 6.266; 95% CI, 3.141–12.501; $P < 0.001$). The risk of HE increased about 100% for each 1-point increase in the MELD score (95% CI, 1.711–2.406; $P < 0.001$) (Table 3). The correlation of HE and shunt stenosis was 98.0% ($P < 0.001$).

4. Discussion

TIPS is an effective and widely used method of treating complications of portal hypertension induced by cirrhosis; however, two serious complications have limited the wide application of this technology. First is the stenosis of the shunt after TIPS. The application of covered stents has greatly decreased the incidence of stenosis of the shunt; however, this complication still occurs, and the exact mechanisms involved in the development of stenosis are unclear. The other drawback of TIPS is HE. The incidence of postoperative HE is about 25%–45% [8, 9], which severely affects the prognosis and quality of life of the patients.

The present study focuses on examining the risk factors associated with shunt stenosis of TIPS using covered stents. Previous studies suggest that stent thrombosis, bile leakage, and pseudo-intima hyperplasia may be the major causes of stenosis of shunt using bare stent [10–12]. Covered stents have been routinely applied in TIPS procedures and have greatly increased the 1-year patency rate to 90–95% [13]. In our study, increased odds of shunt stenosis were associated with more severe inflammation in liver tissue and a high MELD score. The previous studies revealed that increased levels of TNF-α as well as IL-2, IL-6, and IL-10 in serum of patients play important roles in the progress of inflammation of severe hepatitis B-related liver cirrhosis [14, 15]. Meanwhile, recent studies demonstrated that inflammation induced by TNF-α and ILs was a key node in stenosis of carotid artery stenting (CAS), which could be the target of treating the stenosis [16, 17]. In our study, stenosis of TIPS was also associated with inflammation. Probably, increased secretion of inflammatory cytokines in cirrhosis of high grade inflammation plays a major role in the process of TIPS shunt stenosis. Anti-inflammation therapy might increase the patency rate of TIPS and would serve as a research direction in the future.

The incidence (23.8%) of post-TIPS HE observed in the present study was similar to previous studies. Merola et al. showed that higher MELD scores, hyponatremia, and higher total bilirubin level were associated with the development of overt HE post-TIPS [18]. Other studies demonstrated that the risk of post-TIPS HE was higher in the patients with increased age, preexisting HE, and higher Child-Pugh score [19, 20]. Although there have been some hypotheses of HE, the underlying molecular mechanisms remain unclear. It has been indicated that blood ammonia in the portal vein bypasses the liver metabolism and then enters the systemic circulation through the shunt after TIPS, and increased blood supply would lead to the dysfunction of the central nervous system and thus HE [21]. In our study, high grade of liver fibrosis and high portal pressure before TIPS were the risk factors of HE. The pathological investigation might explain the results: on the one hand, severe fibrosis of the Disse space and sinusoid capillarization was observed in S3-S4 inflammation group. These changes would restrict the blood flow in portal vein but increase the blood flow in the small collateral vessels. The alteration could reduce the metabolism

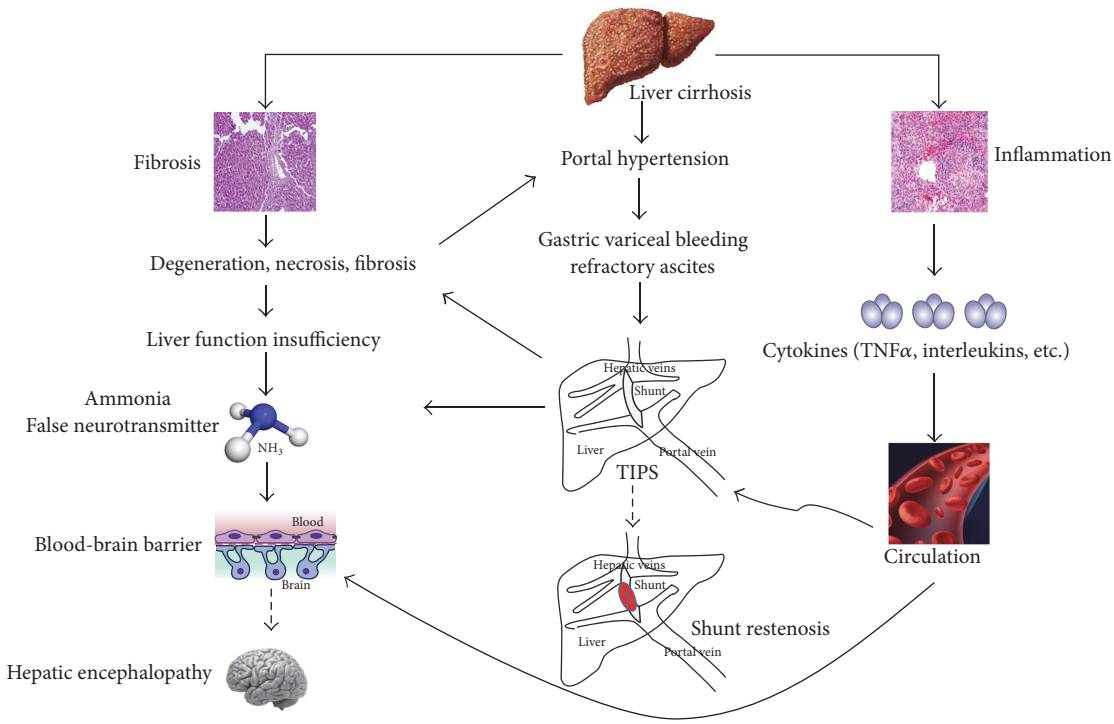

Figure 4: Hypothesis of shunt restenosis and HE after TIPS. Pathological features of the liver tissues predicted the incidence of shunt restenosis and HE. Elevated levels of cytokines in the circulation induced by inflammation play a critical role in restenosis of the stent, which may serve as the target for treatment. Increased blood ammonia and false neurotransmitter result in liver dysfunction induced by fibrosis, which is aggregated by TIPS. In addition, the release of cytokines induced by inflammation can influence the permeability of the blood-brain barrier (BBB), making it easier for the blood ammonia and false neurotransmitter to cross the BBB, leading to the neurodysfunction, and finally promoting the development of HE.

of blood ammonia in the liver cells and, therefore, increase the level of blood ammonia [22]. On the other hand, the metabolism and detoxification abilities of the liver could be further decreased by more severe inflammation and fibrosis, when the blood flow from the portal vein into the liver was reduced after TIPS. These features could induce the ischemic necrosis of the hepatocytes and liver dysfunction, reduce the metabolism of blood ammonia, and finally increase the incidence of HE occurrence (Figure 4).

This is the study on the correlation between pathological changes of the liver and the clinical features after TIPS, as well as on the risk factors of shunt stenosis after TIPS using covered stents. We found that pathological examination, as the golden standard of a disease, can reveal more information underlying the mechanism of stenosis and HE after TIPS and thus help improve the postoperative survival rate of the patients who undergo TIPS.

There are some limitations in the study. The results did reflect the pathological status before the creation of a shunt; however, the pathological data at the occurrence of shunt stenosis or HE was not acquired. Although the inflammation status of the liver affects the patency of the TIPS shunt, further detection of the inflammatory cytokines should be carried out. All the patients included in this study were suffering from portal hypertension caused by hepatitis B-related cirrhosis, while no patients with hepatitis C or alcoholic cirrhosis were involved.

5. Conclusion

The pathological features of the liver tissue obtained during TIPS can help predict the complications including shunt stenosis and HE. Appropriate strategy targeting these critical factors could be taken to improve the postoperative survival rate of the patients who undergo TIPS.

Competing Interests

The authors declare no competing interests.

Authors' Contributions

Fuliang He and Shan Dai are co-first authors and contributed equally in this study.

Acknowledgments

This study was supported by Capital Foundation of Medical Development, no. Z131100006813036 (PI: Fuquan Liu).

References

[1] F.-L. He, L. Wang, Z.-D. Yue, H.-W. Zhao, and F.-Q. Liu, "Parallel transjugular intrahepatic portosystemic shunt for controlling

portal hypertension complications in cirrhotic patients," *World Journal of Gastroenterology*, vol. 20, no. 33, pp. 11835–11839, 2014.

[2] Z. Ling, X. Liu, Y. Cheng et al., "Decreased diversity of the oral microbiota of patients with hepatitis B virus-induced chronic liver disease: a pilot project," *Scientific Reports*, vol. 5, Article ID 17098, 2015.

[3] M. Rössle, "Root cause analysis: can it improve outcome after transjugular intrahepatic portosystemic shunt creation?" *Journal of Vascular and Interventional Radiology*, vol. 26, no. 10, pp. 1453–1454, 2015.

[4] B. C. Perry and S. W. Kwan, "Portosystemic shunts: stable utilization and improved outcomes, two decades after the transjugular intrahepatic portosystemic shunt," *Journal of the American College of Radiology*, vol. 12, no. 12, pp. 1427–1433, 2015.

[5] J. Yao, L. Zuo, G. An et al., "Risk factors for hepatic encephalopathy after transjugular intrahepatic portosystemic shunt in patients with hepatocellular carcinoma and portal hypertension," *Journal of Gastrointestinal and Liver Diseases*, vol. 24, no. 3, pp. 301–307, 2015.

[6] V. Ahluwalia, J. B. Wade, F. G. Moeller et al., "The etiology of cirrhosis is a strong determinant of brain reserve: a multimodal magnetic resonance imaging study," *Liver Transplantation*, vol. 21, no. 9, pp. 1123–1132, 2015.

[7] S. Siramolpiwat, "Transjugular intrahepatic portosystemic shunts and portal hypertension-related complications," *World Journal of Gastroenterology*, vol. 20, no. 45, pp. 16996–17010, 2014.

[8] J. G. Abraldes and P. Tandon, "Therapies: drugs, scopes and transjugular intrahepatic portosystemic shunt—when and how?" *Digestive Diseases*, vol. 33, no. 4, pp. 524–533, 2015.

[9] J. S. Bajaj, "Diagnosing minimal hepatic encephalopathy: from the ivory tower to the real world," *Gastroenterology*, vol. 149, no. 6, pp. 1330–1333, 2015.

[10] P. V. Suhocki, M. P. Lungren, B. Kapoor, and C. Y. Kim, "Transjugular intrahepatic portosystemic shunt complications: prevention and management," *Seminars in Interventional Radiology*, vol. 32, no. 2, pp. 123–132, 2015.

[11] S. S. Sabri, N. Abi-Jaoudeh, W. Swee et al., "Short-term rebleeding rates for isolated gastric varices managed by transjugular intrahepatic portosystemic shunt versus balloon-occluded retrograde transvenous obliteration," *Journal of Vascular and Interventional Radiology*, vol. 25, no. 3, pp. 355–361, 2014.

[12] B. I. Engstrom, J. J. Horvath, P. V. Suhocki et al., "Covered transjugular intrahepatic portosystemic shunts: accuracy of ultrasound in detecting shunt malfunction," *American Journal of Roentgenology*, vol. 200, no. 4, pp. 904–908, 2013.

[13] J. M. Perarnau, A. Le Gouge, C. Nicolas et al., "Covered vs. uncovered stents for transjugular intrahepatic portosystemic shunt: a randomized controlled trial," *Journal of Hepatology*, vol. 60, no. 5, pp. 962–968, 2014.

[14] H. Ataseven, I. H. Bahcecioglu, N. Kuzu et al., "The levels of ghrelin, leptin, TNF-α, and IL-6 in liver cirrhosis and hepatocellular carcinoma due to HBV and HDV infection," *Mediators of Inflammation*, vol. 2006, Article ID 78380, 6 pages, 2006.

[15] J.-T. Kao, C.-J. Yu, C.-L. Feng, S.-M. Tsai, Y.-L. Chen, and Y.-Y. Wu, "IL-6 significantly correlates with p-STAT3 expression and presents high variceal bleeding with mortality in cirrhotic patients: a cross-sectional study," *Journal of Microbiology, Immunology and Infection*, 2015.

[16] Z.-Y. Xia, H. Yang, H.-Q. Qu, W.-D. Cheng, and L.-X. Wang, "Impact of carotid artery stenting on plasma interleukin-6, tumor necrosis factor-α and C-reactive protein," *International Angiology*, vol. 31, no. 1, pp. 28–32, 2012.

[17] G. Niccoli, "Inflammation: a key mechanism of adverse reactions to coronary stent and a target for future therapies," *Current Vascular Pharmacology*, vol. 11, no. 4, pp. 377–378, 2013.

[18] J. Merola, N. Chaudhary, M. Qian et al., "Hyponatremia: a risk factor for early overt encephalopathy after transjugular intrahepatic portosystemic shunt creation," *Journal of Clinical Medicine*, vol. 3, no. 2, pp. 359–372, 2014.

[19] P. Peter, Z. Andrej, S. P. Katarina, G. Manca, and S. Pavel, "Hepatic encephalopathy after transjugular intrahepatic portosystemic shunt in patients with recurrent variceal hemorrhage," *Gastroenterology Research and Practice*, vol. 2013, Article ID 398172, 5 pages, 2013.

[20] M. Bai, X. Qi, Z. Yang et al., "Predictors of hepatic encephalopathy after transjugular intrahepatic portosystemic shunt in cirrhotic patients: a systematic review," *Journal of Gastroenterology and Hepatology*, vol. 26, no. 6, pp. 943–951, 2011.

[21] O. Riggio, S. Angeloni, F. M. Salvatori et al., "Incidence, natural history, and risk factors of hepatic encephalopathy after transjugular intrahepatic portosystemic shunt with polytetrafluoroethylene-covered stent grafts," *The American Journal of Gastroenterology*, vol. 103, no. 11, pp. 2738–2746, 2008.

[22] Z. J. Haskal and J. Radhakrishnan, "Transjugular intrahepatic portosystemic shunts in hemodialysis-dependent patients and patients with advanced renal insufficiency: safety, caution, and encephalopathy," *Journal of Vascular and Interventional Radiology*, vol. 19, no. 4, pp. 516–520, 2008.

Hindawi Publishing Corporation
BioMed Research International
Volume 2016, Article ID 1423462, 12 pages
http://dx.doi.org/10.1155/2016/1423462

Review Article

Diagnosis and Management of Cirrhosis-Related Osteoporosis

Lívia Alves Amaral Santos and Fernando Gomes Romeiro

Department of Internal Medicine, Botucatu Medical School, Universidade Estadual Paulista (UNESP), Av. Prof. Mário Rubens Guimarães Montenegro, s/n, Distrito de Rubião Jr., 18 608 917 Botucatu, SP, Brazil

Correspondence should be addressed to Fernando Gomes Romeiro; fgromeiro@gmail.com

Received 9 July 2016; Accepted 3 October 2016

Academic Editor: Fumio Imazeki

Management of cirrhosis complications has greatly improved, increasing survival and quality of life of the patients. Despite that, some of these complications are still overlooked and scarcely treated, particularly those that are not related to the liver. This is the case of osteoporosis, the only cirrhosis complication that is not solved after liver transplantation, because bone loss often increases after immunosuppressant therapy. In this review, the definitions of bone conditions in cirrhotic patients are analyzed, focusing on the more common ones and on those that have the largest impact on this population. Risk factors, physiopathology, diagnosis, screening strategies, and treatment of osteoporosis in cirrhotic patients are discussed, presenting the more striking data on this issue. Therapies used for particular conditions, such as primary biliary cirrhosis and liver transplantation, are also presented.

1. Introduction

In recent decades, advances in the management of cirrhosis complications and in liver transplantation have been increasing survival rates and improving the quality of life of cirrhotic patients. However, the longer survival of these patients has increased the risk of some extrahepatic manifestations such as osteoporosis. Regardless of the liver disease etiology, the presence of cirrhosis implies a risk of fractures two-fold higher than in noncirrhotic people [1]. Osteoporosis, the main bone disturbance among patients with liver insufficiency, is a systemic and progressive disease that affects bone mass and strength, thereby increasing the risk of fractures and compromising life quality due to pain and deformities [2]. Furthermore, this is the only cirrhosis complication that persists for years after liver transplantation [3–6].

Despite that, osteoporosis is often overlooked and few cirrhosis patients are submitted to exams to diagnose it. Even those who were diagnosed are sometimes precluded from starting a treatment due to the few options that can be offered. Consequently, many patients with liver cirrhosis also suffer from osteoporosis, which can have a big impact on them. In particular, patients receiving glucocorticoids and/or those submitted to liver transplantation suffer an additional decrease in their bone mass due to the use of immunosuppressant drugs. Therefore, some authors have advocated that bone densitometry must be part of the evaluation performed before orthotopic liver transplantation (OLT) [2, 7]. Furthermore, recent data have suggested that bone status must be assessed in all cirrhotic patients [8, 9].

The first studies of osteoporosis in liver diseases evaluated patients with alcoholic cirrhosis or chronic cholestatic diseases, such as primary biliary cholangitis (PBC) [10–15]. Then, other studies assessed patients before and after OLT [16, 17]. Most of them have shown that osteoporosis is common among all cirrhotic patients regardless of the liver disease etiology or the degree of liver impairment [7, 9, 18, 19]. Thus, the aim of this review was to evaluate the physiopathology, the impact, the diagnosis, and the management of osteoporosis in patients with liver cirrhosis, in order to show the more recent data and establish some comparisons between cirrhotic patients under different conditions.

2. Definition and Prevalence

As the population has been reaching older ages, the prevalence of primary and idiopathic osteoporosis has been increasing worldwide, with a global prevalence estimated at around 200 million [20]. According to the WHO definition, osteoporosis is diagnosed when bone density is less than

2.5 standard deviations below the peak value obtained from normal adults and adjusted for gender. It requires that the bone assessed be free from other systemic problems, including osteomalacia, or local abnormalities, such as osteophytes, extraskeletal calcifications, or deformities due to previous fractures [21].

A limitation of this definition is that the threshold was established from studies of postmenopausal Caucasian women, so there is not a single value that could be applied to all patients, such as those with liver diseases [1]. This may account for why many authors addressing bone impairment in patients with liver diseases have described it by employing the term "hepatic osteodystrophy." However, this denomination also includes osteomalacia, which is caused by impaired bone mineralization and is not common among cirrhotic patients [2].

The many risk factors associated with bone loss include alcohol abuse, smoking, liver cirrhosis, neoplastic illness, malnutrition, prolonged glucocorticoid treatment (prednisone 5 mg/day for >3 months), kidney disease, vitamin D deficiency, and some hormonal disturbances such as diabetes, Cushing syndrome, hypogonadism, hyperparathyroidism, hyperthyroidism, and hypercalciuria [22, 23]. Prevalence in cirrhotic patients varies from 12 to 70% according to the diagnostic approach and the liver disease etiology [2, 8, 19, 23, 24]. The initial disease that caused the liver fibrosis is important in some particular conditions, such as cholestatic diseases, in which osteoporosis prevalence seems to be higher, varying from 20 to 44% even without an established diagnosis of cirrhosis and in proportion to the degree of liver insufficiency [1, 23, 25].

Patients with osteoporosis are susceptible to fractures of different bones such as vertebrae, femoral neck, and distal radio. The fractures occur when bones deform more than their peak strain or if they are not able to deform and exceed their peak stress [26]. Vertebral compressing fractures afflict 7% to 35% of cirrhotic patients, whereas the prevalence of peripheral fractures is around 10% [2, 27]. Again, the fracture rates are also higher in cholestatic diseases, varying from 13 to 22% according to the degree of liver insufficiency [1, 2, 4, 6, 25, 28, 29].

Although osteoporosis is asymptomatic in most cases, at five years after OLT it is related to symptoms associated with low quality of life scores because the patients report a decrease in bodily pain and physical function domains [5]. Low bone mineral density (BMD) before liver transplantation and the presence of a prior fracture are relevant predictors of bone loss after OLT. Once the patient is submitted to this procedure and starts taking immunosuppressive therapy, the loss of BMD is faster from the third to the sixth month after the surgery, and the incidence of fractures is between 6 and 65% [6]. Early bone loss after the surgery may affect the patients for years, making them susceptible to fractures even when BMD is being restored [4].

Remarkably, bone loss in liver cirrhosis is more severe among trabecular bones, such as vertebrae, with a lesser impact on the cortical ones. This pattern of increased vertebral damage is similar to some findings observed in the elderly, leading to compression fractures, disability, and spinal deformities [27, 32, 33]. Unexpectedly, most of these fractures are overlooked in noncirrhotic individuals [34]. A reasonable cause may be the fact that vertebral fractures can be less symptomatic than hip fractures, which occurs in individuals who are still able to walk [35]. On the other hand, hip fractures have a larger impact on mortality. Probably, this increase in mortality is due to the impact on patients' ability to walk and take care of themselves.

Prevention has been facilitated by BMD measurement, because it is the best predictor of fractures caused by osteoporosis. For each BMD reduction of one standard deviation, the risk of fractures is 2 to 3 times higher [21, 36]. Even so, BMD should be evaluated with additional information because there is not a single value to predict fractures in all cirrhotic patients [1].

3. Physiopathology

Although the mechanisms of cirrhosis-related osteoporosis are not fully understood, it is well known that the association between liver and bone diseases occurs due to an imbalance of bone turnover, which depends on osteoblastic and osteoclastic activity [22]. Most studies point to a more significant impairment in bone formation, suggesting that osteoporosis in cirrhotic patients is a multifactorial disease in which different mechanisms act together to reduce bone mass until achieving skeletal fragility [2]. Histological specimens from bones of cirrhotic patients with bone loss are similar to those obtained from elderly or postmenopausal women [37].

Part of the current knowledge is based on toxic effects and hormonal imbalances caused by liver insufficiency. In addition, chronic inflammation seems to play a role that is attributed to the small intestinal bacterial overgrowth caused by portal hypertension, leading to an increased flow of bacterial components into the portal vein [38]. The relevance of this process in hepatic decompensation was already evaluated by our group, showing that cirrhotic patients with hepatic encephalopathy remained hospitalized for more time when they presented higher levels of C reactive protein, a marker of systemic inflammation [39]. The inflammation process combined with immobilization is already recognized as a risk factor for bone loss. Thus, chronic inflammation in cirrhotic patients seems to be an additional cause that would account for the differences in regulators of bone remodeling and osteoclastogenesis observed in comparisons between liver disease patients with and without bone loss.

Prior studies found that serum tumor necrosis factor receptors and interleukin 6 (IL-6) levels were inversely correlated with BMD and that IL-6 can lead to bone loss by inducing the receptor activator of nuclear factor kβ (RANKL) [40, 41]. RANKL is a member of the tumor necrosis factor family. It is a RANK ligand that is crucial for osteoclastic activation and differentiation. In a relevant study of noncirrhotic individuals from Italy, the authors showed that low serum RANKL was an independent predictor of nontraumatic fractures [42]. On the other hand, osteoclastogenesis is counteracted by osteoprotegerin (OPG), which is a RANKL receptor, making the balance between RANKL and OPG a

chief point for regulating bone homeostasis. Results from patients with liver diseases showed an imbalance between RANKL and OPG, leading to bone loss [43–45].

Moschen et al. measured the soluble RANKL (sRANKL) in liver disease patients and found that it was higher than in controls, except in the cirrhotic subgroup. They also found higher OPG in these patients, in whom the highest levels were found in those with cirrhosis. Then, they showed that the OPG/sRANKL ratio was proportional to the degree of liver insufficiency and that it was higher in the subgroup of cirrhotic patients with osteoporosis and osteopenia. Of note, the sRANKL values were higher in patients with normal BMD in the lumbar spine. Furthermore, the authors found that RANKL+ cells were more prominent in liver biopsy specimens from liver disease patients. They hypothesized that the high sRANKL levels reflected increased bone turnover in liver disease patients and that the high OPG/sRANKL ratio might be an attempt to maintain bone homeostasis in these patients [45].

As the physiopathology of cirrhosis-related osteoporosis is not fully understood, other factors are briefly presented in this review in order to support a further discussion about possible treatment options.

3.1. Genetic Factors. Until now, there is not a single known genetic marker of osteoporosis predisposition. Some genetic polymorphisms are linked to the development of chronic cholestatic diseases, such as PBC. In this specific disease, insulin-like growth factor 1 (IGF-1) polymorphisms seem to have a higher influence on bone loss than the collagen type Iα1 Sp1 polymorphism, which was previously evaluated in primary osteoporosis [46, 47]. Despite the reasonable knowledge on the possible role of these polymorphisms in PBC, more studies are still needed in this area [2, 48].

3.2. Hormonal Disturbances. Hypogonadism is a common finding in chronic liver disease. More than 90% of men with liver cirrhosis present low testosterone levels, which have an independent impact on mortality [49, 50]. There are many reasons for low levels of sexual hormones in these patients, including hypothalamic-pituitary-gonadal axis dysfunction [49]. Some symptoms found in hypogonadism are similar to those seen in advanced liver disease, hampering the ability to recognize which of them are the main cause of such patient complaints [50].

Hypogonadism is a cause of increased bone turnover, particularly in patients with hemochromatosis [27, 30–32, 51, 52]. Despite the iron overload effects, patients with hemochromatosis seem to be more prone to developing osteoporosis when they also have hypogonadism [30–32]. Some authors have hypothesized that low levels of sexual hormones (estrogen or testosterone) increase the osteoclasts life spam and decrease it in osteoblasts, leading to higher bone resorption than new bone synthesis [26, 30–32, 53]. Likewise, there are other hormones involved in liver diseases that can affect bone remodeling, such as osteocalcin.

Osteocalcin, a hormone secreted by osteoblasts, is involved in many steps of bone synthesis, such as calcium homeostasis, bone matrix mineralization, and osteoblastic proliferation [35]. Low osteocalcin levels have been found in patients with chronic liver diseases and are associated with bone loss [1, 30–32, 54, 55].

Another factor that can impair osteoblastic cells activity is a reduction in insulin-like growth factor 1 (IGF-1) levels. Since IGF-1 is produced in the liver, its deficiency is common in chronic liver diseases, impairing osteoblastic activity, collagen synthesis on bone matrix, and even bone mineralization [27, 54, 56, 57]. IGF-1 levels are lower in cirrhotic patients with osteoporosis when compared to those without osteoporosis, and they are also associated with the degree of hepatic insufficiency [57]. Of note, the IGF-1 replacement in animals with cholestatic disease is able to mitigate and partially reverse osteoporosis [1].

3.3. Toxic Effects. Alcohol is a well-known risk factor for osteoporosis in normal and cirrhotic populations [55]. Bone biopsies from patients addicted to alcohol who presented low levels of osteocalcin revealed decreased bone synthesis, but these levels were normalized after stopping alcohol consumption [30–32, 58, 59]. Moreover, these low osteocalcin levels can be added to malnutrition, hypogonadism, and other findings attributed to alcohol abuse.

Similar to some of these effects, *in vitro* studies showed a noxious effect on osteoblastic cells exposed to iron overload, another cause of decreased bone synthesis that accounts for osteoporosis in patients with hemochromatosis [27, 30–32, 60]. Thus, whereas hypogonadism has a dual effect on osteoclastic and osteoblastic cells, the toxic effects of alcohol and iron are more noticeable in relation to the bone synthesis. However, the role of bilirubin and biliary acids on bone loss seems to be even more complex.

Reduction of osteoblastic activity has been reported when unconjugated bilirubin levels are high [1, 55]. Nonclinical studies showed that bilirubin levels have an irreversible and dose-dependent impact on osteoblastic activity [22, 61, 62]. Another study showed that lithocholic acid can impair the effects of vitamin D on osteoblasts [63]. Some clinical studies found a progressive reduction in BMD, which was proportional to the degree of jaundice in patients with PBC or primary sclerosing cholangitis (PSC) [22, 64, 65]. However, another study did not find this correlation [66].

Glucocorticoids are often used after OLT and for patients with some liver diseases but are associated with bone loss [67, 68]. Of note, glucocorticoid-induced osteoporosis is a great concern in relation to the use of these drugs [69–71]. The bone side effects can be even worse when these drugs are associated with calcineurin inhibitors, impairing osteoblastic differentiation and increasing osteoclastic activity [8, 70, 72].

4. Other Factors

Vitamin D (25-hydroxyvitamin D) is a liposoluble substance that exerts important effects on bone metabolism. Low levels can be found in about one-third of liver disease patients, but severe deficiency is more common in those stricken by cirrhosis and/or cholestatic diseases, because jaundice can

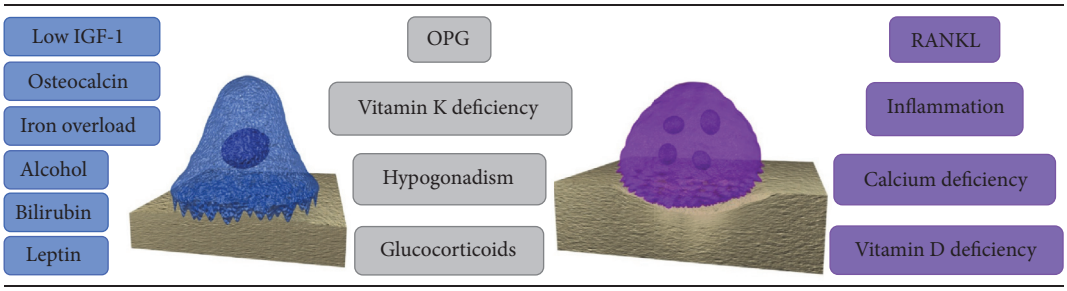

Figure 1: Factors that can be involved in cirrhosis-related osteoporosis by modulating the activity of osteoblastic and osteoclastic cells. The factors most related to osteoblastic activity are illustrated in the left column. The factors related to both osteoblastic and osteoclastic activity are displayed in the middle column. The factors most related to osteoclastic activity are shown in the right column. OPG = osteoprotegerin; RANKL = receptor activator of nuclear factor kβ; IGF-1 = insulin-like growth factor 1. Although most factors are related to osteoblastic activity, malnutrition and alcohol abuse have a broad effect on bone loss because they can be involved in other risk factors displayed above, such as leptin levels and vitamin deficiencies.

make them more prone to malnutrition, malabsorption, and suppressed skin synthesis [22, 73, 74]. Vitamin D deficits can cause bone loss due to increased bone turnover, thus increasing the risk of fractures [8, 75–77]. Calcium and vitamin D deficiency can lead to secondary hypoparathyroidism, which may increase bone turnover in cholestatic patients [2, 78]. Despite that, no clear association has been established between bone loss and calcium or bone loss and vitamin D levels [4, 22].

Vitamin K has an antiapoptotic effect on osteoblasts, and decreased levels can impair the synthesis of important proteins of bone matrix (osteocalcin and osteonectin) in patients with PBC [37, 79, 80]. It is also involved in the inhibition of osteoclastic differentiation [81–83].

Many studies have accessed the anorexigen effect of the adipokine leptin, which is also well known for its role in energy expenditure. It is mostly secreted by adipocytes and is involved in bone homeostasis, thus enhancing bone matrix synthesis, decreasing RANKL production, and increasing osteoblastic proliferation. Despite the decrease observed in cholestatic patients, not all hepatic diseases lead to suppressed leptin levels, and clear data on its role in osteoporosis are still lacking [1, 84].

Finally, smoking, lack of physical activity, malnutrition, and low body mass index are common findings among cirrhotic patients. As all of them are associated with osteoporosis both in cirrhotic and noncirrhotic patients, their avoidance is suggested in order to preserve bone health [85–88]. Even though most factors involved in cirrhosis-related osteoporosis are more closely linked to bone formation, malnutrition and alcohol abuse have a widespread effect because they can be involved in other risk factors mentioned above, such as leptin levels and vitamin deficiencies.

Figure 1 presents some of these interactions observed in cirrhotic-related osteoporosis, focusing on its effects on osteoblastic and osteoclastic cells.

5. Diagnosis and Screening

Screening for osteoporosis is an important part of cirrhosis management, but it is not always performed [89]. Moreover, densitometry indications have been applied just for patients considered for OLT and for those with cholestatic diseases or those under glucocorticoid therapy.

It has been accepted that bone mass is the best measurement for evaluating skeletal strength [90]. Thus, the guidelines indicated that all cirrhotic patients should be screened by an initial dual-energy X-ray absorptiometry (DXA) exam, emphasizing that a normal result should never be sufficient to discard the risk of osteoporosis and that any additional risk factor must lead to a higher level of awareness [90]. The exam allows measurement of BMD and should be repeated after 2 to 3 years to assess significant bone loss, particularly in the presence of the aforementioned risk factors [48, 90]. For cholestatic patients with more than one risk factor and for those who recently started glucocorticoid therapy, DXA should be repeated in one year [48]. In addition, BMD should be measured again before OLT [91].

Regarding DXA accuracy, some limitations must be taken into account. The presence of ascites causes underestimation of the real BMD value. This problem is even worse in the lumbar spine and in patients with a large volume of ascites, leading to vertebral BMD values of 4.2 to 7% higher after paracentesis and changing the diagnosis of 12% of patients [91, 92]. Therefore, it is recommended to measure BMD just after paracentesis to not overestimate bone alterations [91, 92].

A lateral vertebral X-ray can be important as a complimentary exam to search for dorsal and lumbar spine fractures [2]. In cases with local deformities, the corresponding BMD values can be altered and are not reliable. Subtle deformities from previous fractures can cause significant changes in BMD, leading to misinterpretation of the values obtained. To avoid this inaccuracy, clinicians must ask about previous traumas and look for them during the physical exam. Whether the risk of local deformities exists, a two-dimensional X-ray exam can be used to check the vertebrae and the femoral neck before ordering a more expensive exam. Any surface alteration on the cortical layer or signals of lumbar vertebrae collapse are reasons to change the area used for BMD measurements.

Some lab tests can be also useful for evaluating bone metabolism, including serum calcium, vitamin D, phosphorus, osteocalcin, procollagen I carboxyterminal peptide, and parathyroid hormone (PTH), as well as urinary amino telopeptides of collagen I and urinary calcium [2, 93].

In a recent trial, body mass index, leukocyte count, serum bilirubin, and transient elastography values were independently associated with low BMD [19]. In another study developed by our group, we found that high PTH levels and low handgrip strength could be used as accurate predictors of low BMD in the lumbar spine of cirrhotic patients, showing values of these variables that can be used as cutoff points to indicate which patients should be submitted to DXA [9].

Since there are noninvasive measures that can be used as surrogate markers of osteoporosis, bone biopsies are rarely used in cirrhotic patients. In cases of bone loss, bone biopsies from cirrhotic patients have findings that are quite similar to those seen in elderly people [37]. The exception is alcoholic liver cirrhosis, in which impaired osteoblastic activity leads to increased resorption surfaces, lowering the trabecular bone volume [13, 94].

6. Treatment

Most recommendations for osteoporosis treatment in cirrhotic patients were based on results obtained from trials assessing postmenopausal women and smaller studies including patients with dissimilar liver diseases [54]. As a rule, the modifiable risk factors should be taken into account in order to minimize the bone loss, starting from lifestyle changes such as tobacco and alcohol cessation and increasing physical activity as much as possible to improve spinal biomechanics [27]. Furthermore, a balanced diet must be prescribed because nutritional deficits are common among cirrhotic patients.

It is well known that patients with osteoporosis and/or fractures associated with skeletal fragility must be treated, and part of the treatment has been also recommended for patients with osteopenia when they present additional risk factors for bone loss, such as those with cholestatic diseases [2].

For the majority of patients, osteopenia (T scores between 1 and 2.5 standard deviation from normal values) is not considered a disease. Even so, it leads to awareness that bone loss is already present. For instance, Guañabens et al. reported that patients with PBC whose T scores are below 1.5 standard deviation from normal values had a significant risk for vertebral fractures, showing that patients without osteoporosis also suffer fractures and should be considered for receiving prophylactic therapy [25].

6.1. Calcium and Vitamin D Supplementation. Although the ideal amount of calcium ingestion has been debated for decades, calcium supplementation is still part of osteoporosis treatment. The total calcium intake should achieve a daily ingestion of 1.0 to 1.5 grams according to age and other factors. Preferably, calcium from diet should be chosen, because it would facilitate the patients' compliance. Moreover, data on cardiovascular risk in patients taking calcium supplements are still unclear [95, 96]. Nevertheless, as this risk was not evaluated in specific populations, it should not preclude the use of these supplements [97]. The supplement most widely consumed by patients is calcium carbonate, which must be ingested along with foods to increase absorption. Calcium citrate is more suitable for patients with achlorhydria or other conditions that could impair gastrointestinal absorption. Another important recommendation is that calcium tablets should never be ingested together with fluoroquinolones, tetracycline, bisphosphonates, phenythoin, or levothyroxine, because the supplements impair the absorption of these drugs.

Oral 25-hydroxyvitamin D supplementation can be prescribed at a dose of 260 μg every 2 weeks. Since calcitriol (1,25-dihydroxycholecalciferol) is the final active metabolite of vitamin D, it seems to be a better treatment to these patients. Calcitriol is usually prescribed as a daily oral dose of 800 U but can also be taken at a weekly dose of 5000 U [2]. In a clinical trial in which calcitriol (0.5 mg twice per day) was given to 38 cirrhotic patients for 12 months, the authors showed that the supplementation was the only factor significantly related to BMD increasing [98]. Although calcium and vitamin D are widely used for osteoporotic patients, evidence confirming that these supplements could reverse or avoid osteoporosis is unclear [27].

In a systematic review of calcium and vitamin supplementation to prevent or treat osteoporosis in the general population, Bolland et al. found small benefits in fracture avoidance from calcium and vitamin D supplements. The authors reported that calcium supplements have some effect on reducing vertebral fractures; however, the number needed to treat (NNT) in order to prevent one vertebral fracture was 489 patients taking the supplements for 6.2 years [99]. The results on isolated vitamin D supplementation were even weaker, suggesting no benefit of adding vitamin D to calcium supplements. A small effect on hip-fracture risk was produced by both supplements [99].

In addition, data from elderly noncirrhotic patients showed that adherence to these supplements decreases through time. Less than half of them are still taking it after one year if educational interventions are not provided [100]. Data from cirrhotic patients are not so common, but some studies of patients with PBC showed that calcium and vitamin D were not able to change their BMD when compared to hormonal replacement therapy [101, 102]. Even so, it is always worthwhile to test for vitamin D deficiency in cholestatic patients, particularly those taking cholestyramine, which impairs its absorption [27].

6.2. Hormonal Replacement. Hormonal replacement can be a valuable approach for patients with hypogonadism, increasing BMD values in both genders and decreasing the risk of fractures in women [102–105]. In contrast, one of the studies of PBC patients suggested that those receiving estrogens could present a high risk of cholestasis [106]. Moreover, the risk of developing hepatocellular carcinoma in patients receiving testosterone is another concern, although there are no clinical data to confirm this hypothesis [21, 107].

Isoniemi et al. treated 33 postmenopausal women for two years after OLT. Given some reasonable concern about the procoagulant effect of oral hormonal replacement therapy, the authors chose a transdermal estradiol treatment, which was given in the first six months after OLT. After one year of treatment, the authors documented respective lumbar and femoral BMD increases of 5.3% and 3.3%. Of note, the increases were not as great after the second year (1.2% at both sites). Furthermore, they still documented a marked improve in the patients' lipid profile [108]. Other studies also reported similar BMD results from transdermal hormonal replacement in patients with PBC, showing that this type of treatment is safe and can bring other benefits to patients [101, 102, 109, 110].

6.3. Calcitonin. Calcitonin is able to inhibit osteoclastic activity, but the use of this hormone for cirrhotic patients is still controversial. In the former study, women stricken by PBC and other liver diseases had bone density measured at two moments before the treatment, showing a significant decrease in PBC cases in a six-month period. Then, 13 patients who had reduced bone density received a four-month treatment composed of calcitonin (40 U) thrice a week together with daily calcium and vitamin D supplements, which curbed their bone loss in comparison to the nontreated patients [111]. The results were confirmed by a further study at the same university, when the improvement was observed only in patients who had suffered a more pronounced bone loss and received the treatment. In this trial, calcitonin was administered on a schedule similar to the previous one, but for 3 years [112]. In contrast, another study reported that calcitonin given for 6 months was ineffective at increasing BMD in PBC patients [113].

In a study performed after OLT, 17 patients received a daily 40 IU dosage of intramuscular calcitonin for 15 days every 3 months combined with daily calcium supplement (1 g). After one year, the improvement in vertebral BMD was comparable to that observed in 23 patients receiving 400 mg of sodium etidronate given 15 days every 3 months [93]. Taken together, these results suggest that the beneficial effect of calcitonin in patients with liver diseases is more pronounced in those who present a faster bone loss.

6.4. Sodium Fluoride and Raloxifene. Sodium fluoride is well known for increasing lumbar spine bone mass in osteoporotic patients [114]. In a small randomized controlled trial, it was given to 7 PBC patients at a daily dosage of 50 mg with calcium and vitamin D supplements, while the placebo group ($n = 8$) received only the supplements. The results indicated that sodium fluoride halted the bone loss compared to the placebo [115]. The same group completed another trial comparing sodium fluoride with etidronate in two groups of 13 women with PBC. After two years of treatment, the authors found a subtle increase in vertebral BMD only in the fluoride group. Despite the occurrence of two vertebral fractures in this group, etidronate was considered a safe treatment [116]. More studies are needed to confirm efficacy and safety of sodium fluoride for cirrhotic patients.

Raloxifene is a second-generation selective estrogen-receptor modulator that shows estrogenic actions on bones. It has been used to treat osteoporosis in patients without liver diseases, but not yet in cirrhotic patients. A prior study was performed in nine postmenopausal women with PBC, suggesting a possible benefit in lumbar spine BMD [117]. The lack of studies in patients with liver cirrhosis hampers recommending it for this population.

6.5. Bisphosphonates. Anticatabolic drugs seem to be a good option for treating osteoporosis in cirrhotic patients, because they are stricken by several metabolic alterations. Bisphosphonates appear to be helpful in the treatment of cirrhosis-related osteoporosis, because these drugs attach to the bone surface and prevent resorption (the so-called "antiresorptive" effect) [118]. Bisphosphonates are able to increase bone mass in postmenopausal women, but concerns about the potential risk of ulceration on esophageal varices have reduced the number of studies in cirrhotic patients, hampering the extrapolation of any data to them. After some trials showing interesting results, this risk has been considered lower than formerly estimated [21].

One of the first trials that showed a significant effect of bisphosphonates on bone mass was conducted in 1998. Ninety patients received pamidronate 60 mg every 3 months before OLT and for 9 months after the procedure. Before treatment, seven subjects had vertebral fractures (most of them had PBC and lower BMD values compared to other patients). Jaundiced patients also received calcium and vitamin D. Since this routine treatment was adopted, symptomatic fractures were no longer registered, leading the authors to recommend it [119].

As commented above on sodium fluoride, results obtained from etidronate showed that it was only able to prevent bone loss, which did not change in two years of treatment. This finding prompted the authors to consider that etidronate was not capable of increasing bone mass in PBC patients [116, 120]. Thus, they performed a 2-year randomized trial using alendronate 10 mg daily for 13 PBC patients, achieving good BMD results and no significant side effects [120]. Similar findings were also observed in a trial using 70 mg weekly throughout one year [121]. Another trial comparing monthly ibandronate versus weekly alendronate (150 mg and 70 mg, resp.) for PBC patients found comparable effects on BMD but a higher compliance with the monthly treatment [122]. Yet, it is important to point out that these trials included only patients with PBC.

Other studies assessed the efficacy and safety profile of parenteral drugs, such as pamidronate. Data obtained from trials using this drug in cirrhotic patients are also limited to few studies. Ninkovic et al. assessed 99 patients randomized to receive pamidronate 60 mg intravenously in a single-dose versus no treatment before OLT. The authors did not find any difference in fracture rates or BMD between the former and latter groups [123]. Twelve of these patients were also included in another study assessing iliac-crest biopsies before and three months after OLT, showing a lesser degree of bone resorption in patients who received pamidronate ($n = 7$) [124].

Dodidou et al. evaluated 21 OLT patients who had taken infusions of pamidronate (30 mg) every three months after the surgery, combined with vitamin D and calcium supplements. The authors also assessed 13 cardiac transplant patients taking the same regimen and compared data from transplanted subjects with a historical reference group. They found a significant increase in lumbar spine and femoral neck BMD in those who received pamidronate, which persisted during the second year of treatment [125]. In another trial, this same treatment was administered to 43 patients after OLT, comparing BMD with 38 controls. Twenty-four patients (54% with osteoporosis) and all the controls (23% with osteoporosis) presented a significant increase in lumbar spine but not in femoral neck BMD [126].

Millonig et al. investigated the role of alendronate 70 mg weekly combined with calcium and vitamin D supplements for preventing bone loss in 98 patients who had osteoporosis or osteopenia and started receiving this drug after OLT. The authors assessed BMD before OLT and every year after until 48 months to document bone changes in this interval. A significant improvement was observed between 4 and 12 months after OLT in lumbar spine BMD of osteoporotic patients, with subtle changes in the subsequent years. In femoral neck, osteoporotic patients increased their BMD between 4 and 12 months and until 3 years after OLT. Only two patients discontinued the drug because they reported abdominal discomfort, and the drug was changed to pamidronate 30 mg monthly [127].

Crawford et al. evaluated the effect of zoledronic acid 4 mg on BMD of 32 patients submitted to OLT (18% of whom had osteoporosis). The drug infusion was given within seven days after OLT and repeated at one, three, six, and nine months after the procedure. Calcium and vitamin D were also administered. The authors compared the results with those of 30 patients receiving placebo (10% with osteoporosis) and reported that lumbar spine, femoral neck, and total hip BMD measurements favored zoledronic acid at the first 3 and 6 months after OLT. Fifteen patients did not complete the study, four of them because of fractures (2 nonvertebral fractures in the treatment group and 2 vertebral fractures in the placebo group). Despite the benefits in BMD, the drug induced hyperparathyroidism and postinfusion hypocalcemia [128].

Atamaz et al. conducted a trial with 44 subjects receiving alendronate 70 mg weekly and 40 patients in a control group. Initially, 98 patients were recruited after OLT, but three of them died, one discontinued the treatment because noncompliance, and two subjects in the alendronate group had gastrointestinal distress. The drug was given for one month and led to a significant improvement in mean BMD at lumbar spine, femoral neck, and total femur (5.1 ± 3.9%, 4.3 ± 3.8%, and 3.6 ± 3.8%, resp.). Musculoskeletal pain and upper gastrointestinal adverse events were present in 38.6% and 29.5% of subjects, respectively. There were two nonvertebral fractures in the control group and none in the alendronate group. Seven patients in the control group and three in the alendronate group had new vertebral fractures. It was noteworthy that most of the vertebral fractures were detected only in X-ray exams [129].

Bodingbauer et al. recruited 96 patients after OLT to receive 4 mg of zoledronic acid monthly plus calcium and vitamin D or only calcium and vitamin D. The treatments were administered for one year after OLT. Thirty-five patients in the study group and 34 in the control group were monitored for 2 years. Pyrexia and musculoskeletal pain were more common in the study group. The authors reported a significant ($p = 0.05$) reduction of vertebral fractures in the study group (four subjects) compared to the control group (11 subjects). Six months after OLT there were no significant differences on lumbar spine BMD between the groups, but a small difference in femoral neck BMD [130]. Part of the study sample was reevaluated to reassess data from transiliac biopsies, showing that zoledronic acid reduced bone turnover in 21 patients [131].

Monegal et al. performed a randomized controlled trial comparing pamidronate versus placebo in 10 Spanish centers. They analyzed 32 patients in the experimental group and 34 in the placebo group. Pamidronate 90 mg was given within 7 to 12 days after OLT and again three months after the surgery. All patients received calcium and vitamin D supplements. Seven subjects in the experimental group and three in the placebo group had fractures within the first year after OLT, most of which were in vertebrae. The number of adverse events did not differ between the groups. The authors reported a significant improvement in lumbar BMD achieved by pamidronate use (2.9% in the treatment group and 1% in the control group). However, both groups displayed a subtle decrease in femoral neck BMD. Additionally, trochanteric BMD was reduced only in the placebo group [132].

These prior trials evaluated specific populations, such as PBC patients or those submitted to OLT, but none of them had included only patients with cirrhosis during the treatment. Given the toxic effect of cholestasis and immunosuppressant drugs on bone health, it is somewhat difficult to extrapolate the data from these studies to all cirrhotic patients. Therefore, it has provoked several discussions about the possibility of performing similar studies of cirrhotic individuals.

Then, Yurci et al. studied a different sample composed of patients with cirrhosis (31 subjects) and viral hepatitis (50 subjects) who had reduced T scores in at least one region. The authors divided their sample into six groups according to the drugs administered (salmon calcitonin 200 IU daily, calcium, vitamin D, and different dosages of alendronate). Most cirrhotic patients had compensated liver disease (18 subjects out of 31). Six patients with decompensated cirrhosis died during the study, but none of them was receiving bisphosphonates. Seven cirrhotic patients had the treatment discontinued. The authors concluded that alendronate prevented trabecular and cortical bone loss in their sample, with no significant side effects [118]. Unfortunately, the groups had few subjects with cirrhosis.

In a recent trial performed by Bansal et al., 215 cirrhotic patients were recruited to participate, of whom 47 had osteoporosis and received a monthly ibandronate dosage of 150 mg combined with calcium and vitamin D supplements for six months. The major cause of cirrhosis was alcoholic liver disease, and most patients had decompensated cirrhosis,

esophageal varices, and ascites. This last finding was present in 175 subjects, bringing concern about the precision of BMD measures, as previously mentioned in this review and by other studies. Four patients with osteoporosis had fractures, 16 died, and 12 lost follow-up, so that only 19 completed the study. These 19 patients had a significant improvement in mean BMD (from 0.81 ± 0.07 to 0.88 ± 0.07) and T scores (from −3.28 ± 0.72 to 2.45 ± 0.45) [19].

7. Conclusions

As cirrhotic patients have been submitted to many treatments to achieve better survival, cirrhosis-related osteoporosis has become more common, especially among patients who present any other risk factor for bone loss, such as cholestatic diseases, alcohol abuse, hypogonadism, or the other factors previously mentioned in this review. Furthermore, osteoporosis is the only cirrhosis complication that worsens after liver transplantation. Thus, health professionals must become aware of this condition in order to diagnose it as soon as possible. Many screening strategies can be helpful for showing which patients should be submitted to specific exams, thereby reducing the budget of a whole population screening.

Once osteoporosis is diagnosed in cirrhotic patients or in those who were already submitted to OLT, it is important to control the risk factors that can increase bone loss, such as alcohol consumption, smoking, sedentary lifestyle, and glucocorticoid use. Dietary calcium intake must be checked, and calcium obtained from foods is generally preferable to tablets, which can impair the absorption of some drugs. Vitamin D levels should be measured while supplements seem to be valuable in specific conditions, such as cholestatic diseases. Since calcium and vitamin D supplementation seem insufficient to curb bone loss in this population, additional therapy must be prescribed.

Most trials that assess osteoporosis treatment in cirrhotic subjects had a limited sample and a short follow-up. Studies on hormonal replacement therapy for patients with hypogonadism achieved interesting results in women, but concerns about hepatocellular carcinoma prevented similar trials in men. Even among women with PBC or after OLT, the results were more striking in the first year of estrogen therapy. Despite the exciting data on efficacy and safety reported, more studies are still required to evaluate the beneficial effects of hormonal replacement on the bone health of cirrhotic patients. The same can be said about calcitonin, sodium fluoride, and raloxifene.

Notwithstanding the same problem regarding small samples, clinical trials with bisphosphonates combined with calcium and vitamin D supplements have achieved encouraging results. However, concerns about the risk of mucosal damage on esophageal varices have reduced the number of studies with cirrhotic patients, and most trials included only subjects who were submitted to OLT under different immunosuppressant regimens, hampering the ability to reach conclusions that could be applied to patients who still have liver cirrhosis. For now, the available results suggest that some bisphosphonates are safe and can really improve the bone health of patients with cirrhosis. It is important to know that some side effects can prevent the use of these drugs for all patients and that most data were obtained from surrogate markers and not from fracture incidence. Therefore, more studies are also needed to clarify the best options for this population [133].

Competing Interests

The authors declare that they have no competing interests.

Acknowledgments

The authors are grateful to EAP (Escritório de Apoio à Pesquisa-Botucatu Medical School/UNESP) and UPECLIN (Unidade de Pesquisa Clínica-UNESP) for their support. They also wish to thank the financial support received from Coordenação de Aperfeiçoamento de Pessoal de Nível Superior (Capes), Pró-Reitoria de Pesquisa (PROPe/UNESP), and São Paulo Research Foundation (FAPESP) Grants nos. 2014/22572-9 and 2016/07117-9.

References

[1] B. A. Luxon, "Bone disorders in chronic liver diseases," *Current Gastroenterology Reports*, vol. 13, no. 1, pp. 40–48, 2011.

[2] N. Guañabens and A. Parés, "Management of osteoporosis in liver disease," *Clinics and Research in Hepatology and Gastroenterology*, vol. 35, no. 6-7, pp. 438–445, 2011.

[3] S. Giannini, M. Nobile, M. Ciuffreda et al., "Long-term persistence of low bone density in orthotopic liver transplantation," *Osteoporosis International*, vol. 11, no. 5, pp. 417–424, 2000.

[4] J. E. Hay, "Osteoporosis in liver diseases and after liver transplantation," *Journal of Hepatology*, vol. 38, no. 6, pp. 856–865, 2003.

[5] H. Bownik and S. Saab, "Health-related quality of life after liver transplantation for adult recipients," *Liver Transplantation*, vol. 15, no. 2, pp. S42–S49, 2009.

[6] D. Kaemmerer, B. Schmidt, G. Lehmann, G. Wolf, U. Settmacher, and M. Hommann, "Treatment of bone loss in patients with chronic liver disease awaiting liver transplantation," *Transplantation Research*, vol. 1, no. 1, article 7, 2012.

[7] A. Alcalde Vargas, J. M. Pascasio Acevedo, I. Gutiérrez Domingo et al., "Prevalence and characteristics of bone disease in cirrhotic patients under evaluation for liver transplantation," *Transplantation Proceedings*, vol. 44, no. 6, pp. 1496–1498, 2012.

[8] A. Gatta, A. Verardo, M. Di Pascoli, S. Giannini, and M. Bolognesi, "Hepatic osteodystrophy," *Clinical Cases in Mineral and Bone Metabolism*, vol. 11, no. 3, pp. 185–191, 2014.

[9] L. A. A. Santos, T. B. Lima, L. Augusti et al., "Handgrip strength as a predictor of bone mineral density in outpatients with cirrhosis," *Journal of Gastroenterology and Hepatology*, vol. 31, no. 1, pp. 229–234, 2016.

[10] R. G. Long, E. Meinhard, R. K. Skinner, Z. Varghese, M. R. Wills, and S. Sherlock, "Clinical, biochemical, and histological studies of osteomalacia, osteoporosis, and parathyroid function in chronic liver disease," *Gut*, vol. 19, no. 2, pp. 85–90, 1978.

[11] P. R. Mills, R. Vallance, G. Birnie et al., "A prospective survey of radiological bone and joint changes in primary biliary cirrhosis," *Clinical Radiology*, vol. 32, no. 3, pp. 297–302, 1981.

[12] J. A. Cuthbert, C. Y. C. Pak, and J. E. Zerwekh, "Bone disease in primary biliary cirrhosis: increased bone resorption and turnover in the absence of osteoporosis or osteomalacia," *Hepatology*, vol. 4, no. 1, pp. 1–8, 1984.

[13] J. A. Jorge-Hernandez, C. E. Gonzalez-Reimers, A. Torres-Ramirez et al., "Bone changes in alcoholic liver cirrhosis. A histomorphometrical analysis of 52 cases," *Digestive Diseases and Sciences*, vol. 33, no. 9, pp. 1089–1095, 1988.

[14] T. H. Diamond, "Metabolic bone disease in primary biliary cirrhosis," *Journal of Gastroenterology and Hepatology*, vol. 5, no. 1, pp. 66–81, 1990.

[15] N. Guanabens, A. Pares, L. Marinoso et al., "Factors influencing the development of metabolic bone disease in primary biliary cirrhosis," *American Journal of Gastroenterology*, vol. 85, no. 10, pp. 1356–1362, 1990.

[16] E. Meys, E. Fontanges, N. Fourcade, A. Thomasson, M. Pouyet, and P. D. Delmas, "Bone loss after orthotopic liver transplantation," *The American Journal of Medicine*, vol. 97, no. 5, pp. 445–450, 1994.

[17] A. Monegal, M. Navasa, N. Guañabens et al., "Osteoporosis and bone mineral metabolism disorders in cirrhotic patients referred for orthotopic liver transplantation," *Calcified Tissue International*, vol. 60, no. 2, pp. 148–154, 1997.

[18] J. George, H. K. Ganesh, S. Acharya et al., "Bone mineral density and disorders of mineral metabolism in chronic liver disease," *World Journal of Gastroenterology*, vol. 15, no. 28, pp. 3516–3522, 2009.

[19] R. K. Bansal, M. Kumar, P. R. Sachdeva, and A. Kumar, "Prospective study of profile of hepatic osteodystrophy in patients with non-choleastatic liver cirrhosis and impact of bisphosphonate supplementation," *United European Gastroenterology Journal*, vol. 4, no. 1, pp. 77–83, 2016.

[20] J.-Y. Reginster and N. Burlet, "Osteoporosis: a still increasing prevalence," *Bone*, vol. 38, no. 2, supplement 1, pp. S4–S9, 2006.

[21] J. D. Collier, M. Ninkovic, and J. E. Compston, "Guidelines on the management of osteoporosis associated with chronic liver disease," *Gut*, vol. 50, supplement 1, pp. i1–i9, 2002.

[22] G. López-Larramona, A. J. Lucendo, S. González-Castillo, and J. M. Tenias, "Hepatic osteodystrophy: an important matter for consideration in chronic liver disease," *World Journal of Hepatology*, vol. 3, no. 12, pp. 300–307, 2011.

[23] R. Lupoli, A. Di Minno, G. Spadarella et al., "The risk of osteoporosis in patients with liver cirrhosis: a meta-analysis of literature studies," *Clinical Endocrinology*, vol. 84, no. 1, pp. 30–38, 2016.

[24] Z. Savic, D. Damjanov, N. Curic et al., "Vitamin D status, bone metabolism and bone mass in patients with alcoholic liver cirrhosis," *Bratislava Medical Journal*, vol. 115, no. 9, pp. 573–578, 2014.

[25] N. Guañabens, D. Cerdá, A. Monegal et al., "Low bone mass and severity of cholestasis affect fracture risk in patients with primary biliary cirrhosis," *Gastroenterology*, vol. 138, no. 7, pp. 2348–2356, 2010.

[26] E. Seeman, "The structural and biomechanical basis of the gain and loss of bone strength in women and men," *Endocrinology and Metabolism Clinics of North America*, vol. 32, no. 1, pp. 25–38, 2003.

[27] N. Guanabens and A. Pares, "Liver and bone," *Archives of Biochemistry and Biophysics*, vol. 503, no. 1, pp. 84–94, 2010.

[28] M. Solaymani-Dodaran, T. R. Card, G. P. Aithal, and J. West, "Fracture risk in people with primary biliary cirrhosis: a population-based cohort study," *Gastroenterology*, vol. 131, no. 6, pp. 1752–1757, 2006.

[29] M. A. Chinnaratha, S. Chaudhary, M. Doogue, R. J. Mccormick, R. J. Woodman, and A. J. Wigg, "Prevalence of hepatic osteodystrophy and vitamin D deficiency in cirrhosis," *Internal Medicine Journal*, vol. 45, no. 12, pp. 1230–1235, 2015.

[30] T. Diamond, D. Stiel, M. Lunzer, M. Wilkinson, and S. Posen, "Ethanol reduces bone formation and may cause osteoporosis," *The American Journal of Medicine*, vol. 86, no. 3, pp. 282–288, 1989.

[31] T. Diamond, D. Stiel, and S. Posen, "Osteoporosis in hemochromatosis: iron excess, gonadal deficiency, or others factors?" *Annals of Internal Medicine*, vol. 110, no. 6, pp. 430–436, 1989.

[32] T. H. Diamond, D. Stiel, M. Lunzer, D. McDowall, R. P. Eckstein, and S. Posen, "Hepatic osteodystrophy. Static and dynamic bone histomorphometry and serum bone Gla-protein in 80 patients with chronic liver disease," *Gastroenterology*, vol. 96, no. 1, pp. 213–221, 1989.

[33] M. Newman, C. Minns Lowe, and K. Barker, "Spinal orthoses for vertebral osteoporosis and osteoporotic vertebral fracture: a systematic review," *Archives of Physical Medicine and Rehabilitation*, vol. 97, no. 6, pp. 1013–1025, 2016.

[34] D. L. Kendler, D. C. Bauer, K. S. Davison et al., "Vertebral fractures: clinical importance and management," *American Journal of Medicine*, vol. 129, no. 2, pp. e221–e221, 2016.

[35] O. R. Pavel, M. Popescu, L. Novac et al., "Postmenopausal osteoporosis—clinical, biological and histopathological aspects," *Romanian Journal of Morphology and Embryology*, vol. 57, no. 1, pp. 121–130, 2016.

[36] D. Marshall, O. Johnell, and H. Wedel, "Meta-analysis of how well measures of bone mineral density predict occurrence of osteoporotic fractures," *British Medical Journal*, vol. 312, no. 7041, pp. 1254–1259, 1996.

[37] R. W. Gasser, "Cholestasis and metabolic bone disease—a clinical review," *Wiener Medizinische Wochenschrift*, vol. 158, no. 19-20, pp. 553–557, 2008.

[38] J. P. Nolan, "The role of intestinal endotoxin in liver injury: a long and evolving history," *Hepatology*, vol. 52, no. 5, pp. 1829–1835, 2010.

[39] F. G. Romeiro, F. da Silva Yamashiro, M. F. Américo et al., "Erythromycin versus neomycin in the treatment of hepatic encephalopathy in cirrhosis: a randomized double-blind study," *BMC Gastroenterology*, vol. 13, article 13, 2013.

[40] J. Dai, D. Lin, J. Zhang et al., "Chronic alcohol ingestion induces osteoclastogenesis and bone loss through IL-6 in mice," *The Journal of Clinical Investigation*, vol. 106, no. 7, pp. 887–895, 2000.

[41] J. L. Gonzalez-Calvin, F. Gallego-Rojo, R. Fernandez-Perez, F. Casado-Caballero, E. Ruiz-Escolano, and E. G. Olivares, "Osteoporosis, mineral metabolism, and serum soluble tumor necrosis factor receptor p55 in viral cirrhosis," *Journal of Clinical Endocrinology and Metabolism*, vol. 89, no. 9, pp. 4325–4330, 2004.

[42] G. Schett, S. Kiechl, K. Redlich et al., "Soluble RANKL and risk of nontraumatic fracture," *The Journal of the American Medical Association*, vol. 291, no. 9, pp. 1108–1113, 2004.

[43] D. Hegedus, V. Ferencz, P. L. Lakatos et al., "Decreased bone density, elevated serum osteoprotegerin, and β-cross-laps in Wilson disease," *Journal of Bone and Mineral Research*, vol. 17, no. 11, pp. 1961–1967, 2002.

[44] F. Szalay, D. Hegedus, P. Laszlo Lakatos et al., "High serum osteoprotegerin and low RANKL in primary biliary cirrhosis," *Journal of Hepatology*, vol. 38, no. 4, pp. 395–400, 2003.

[45] A. R. Moschen, A. Kaser, S. Stadlmann et al., "The RANKL/OPG system and bone mineral density in patients with chronic liver disease," *Journal of Hepatology*, vol. 43, no. 6, pp. 973–983, 2005.

[46] P. Peris, L. Alvarez, J. Oriola et al., "Collagen type Iα1 gene polymorphism in idiopathic osteoporosis in men," *Rheumatology*, vol. 39, no. 11, pp. 1222–1225, 2000.

[47] P. L. Lakatos, E. Bajnok, I. Tornai et al., "Insulin-like growth factor I gene microsatellite repeat, collagen type Iα1 gene Sp1 polymorphism, and bone disease in primary biliary cirrhosis," *European Journal of Gastroenterology and Hepatology*, vol. 16, no. 8, pp. 753–759, 2004.

[48] A. Parés and N. Guañabens, "Treatment of bone disorders in liver disease," *Journal of Hepatology*, vol. 45, no. 3, pp. 445–453, 2006.

[49] M. Grossmann, R. Hoermann, L. Gani et al., "Low testosterone levels as an independent predictor of mortality in men with chronic liver disease," *Clinical Endocrinology*, vol. 77, no. 2, pp. 323–328, 2012.

[50] M. Sinclair, M. Grossmann, P. J. Gow, and P. W. Angus, "Testosterone in men with advanced liver disease: abnormalities and implications," *Journal of Gastroenterology and Hepatology*, vol. 30, no. 2, pp. 244–251, 2015.

[51] T. M. Kelly, C. Q. Edwards, A. W. Meikle, and J. P. Kushner, "Hypogonadism in hemochromatosis: reversal with iron depletion," *Annals of Internal Medicine*, vol. 101, no. 5, pp. 629–632, 1984.

[52] P. Guggenbuhl, Y. Deugnier, J. F. Boisdet et al., "Bone mineral density in men with genetic hemochromatosis and HFE gene mutation," *Osteoporosis International*, vol. 16, no. 12, pp. 1809–1814, 2005.

[53] H. Bell, N. Raknerud, J. A. Falch, and E. Haug, "Inappropriately low levels of gonadotrophins in amenorrhoeic women with alcoholic and non-alcoholic cirrhosis," *European Journal of Endocrinology*, vol. 132, no. 4, pp. 444–449, 1995.

[54] G. López-Larramona, A. J. Lucendo, and L. González-Delgado, "Alcoholic liver disease and changes in bone mineral density," *Revista Espanola de Enfermedades Digestivas*, vol. 105, no. 10, pp. 609–621, 2013.

[55] G. López-Larramona, A. J. Lucendo, and J. M. Tenías, "Association between nutritional screening via the Controlling Nutritional Status index and bone mineral density in chronic liver disease of various etiologies," *Hepatology Research*, vol. 45, no. 6, pp. 618–628, 2015.

[56] B. Y. Reed, J. E. Zerwekh, K. Sakhaee, N. A. Breslau, F. Gottschalk, and C. Y. Pak, "Serum IGF 1 is low and correlated with osteoblastic surface in idiopathic osteoporosis," *Journal of Bone and Mineral Research*, vol. 10, no. 8, pp. 1218–1224, 1995.

[57] F. J. Gallego-Rojo, J. L. Gonzalez-Calvin, M. Muñoz-Torres, J. L. Mundi, R. Fernandez-Perez, and D. Rodrigo-Moreno, "Bone mineral density, serum insulin-like growth factor I, and bone turnover markers in viral cirrhosis," *Hepatology*, vol. 28, no. 3, pp. 695–699, 1998.

[58] P. Peris, A. Pares, N. Guanabens et al., "Reduced spinal and femoral bone mass and deranged bone mineral metabolism in chronic alcoholics," *Alcohol and Alcoholism*, vol. 27, no. 6, pp. 619–625, 1992.

[59] P. Peris, A. Parés, N. Guañabens et al., "Bone mass improves in alcoholics after 2 years of abstinence," *Journal of Bone and Mineral Research*, vol. 9, no. 10, pp. 1607–1612, 1994.

[60] K. Yamasaki and H. Hagiwara, "Excess iron inhibits osteoblast metabolism," *Toxicology Letters*, vol. 191, no. 2-3, pp. 211–215, 2009.

[61] C. H. Janes, E. R. Dickson, R. Okazaki, S. Bonde, A. F. McDonagh, and B. L. Riggs, "Role of hyperbilirubinemia in the impairment of osteoblast proliferation associated with cholestatic jaundice," *Journal of Clinical Investigation*, vol. 95, no. 6, pp. 2581–2586, 1995.

[62] M. Weinreb, R. D. Pollak, and Z. Ackerman, "Experimental cholestatic liver disease through bile-duct ligation in rats results in skeletal fragility and impaired osteoblastogenesis," *Journal of Hepatology*, vol. 40, no. 3, pp. 385–390, 2004.

[63] S. Ruiz-Gaspà, N. Guañabens, A. Enjuanes et al., "Lithocholic acid downregulates vitamin D effects in human osteoblasts," *European Journal of Clinical Investigation*, vol. 40, no. 1, pp. 25–34, 2010.

[64] K. V. N. Menon, P. Angulo, S. Weston, E. R. Dickson, and K. D. Lindor, "Bone disease in primary biliary cirrhosis: independent indicators and rate of progression," *Journal of Hepatology*, vol. 35, no. 3, pp. 316–323, 2001.

[65] M. M. J. Guichelaar, M. Malinchoc, J. Sibonga, B. L. Clarke, and J. E. Hay, "Bone metabolism in advanced cholestatic liver disease: analysis by bone histomorphometry," *Hepatology*, vol. 36, no. 4, part 1, pp. 895–903, 2002.

[66] D. L. H. Smith, N. J. Shire, N. B. Watts, T. Schmitter, G. Szabo, and S. D. Zucker, "Hyperbilirubinemia is not a major contributing factor to altered bone mineral density in patients with chronic liver disease," *Journal of Clinical Densitometry*, vol. 9, no. 1, pp. 105–113, 2006.

[67] M. Prince, E. Christensen, and C. Gluud, "Glucocorticosteroids for primary biliary cirrhosis," *Cochrane Database of Systematic Reviews*, no. 2, Article ID CD003778, 2005.

[68] F. N. R. Van Berkum, R. Beukers, J. C. Birkenhäger, P. P. M. Kooij, S. W. Schalm, and H. A. P. Pols, "Bone mass in women with primary biliary cirrhosis: the relation with histological stage and use of glucocorticoids," *Gastroenterology*, vol. 99, no. 4, pp. 1134–1139, 1990.

[69] K. G. Saag, "Glucocorticoid-induced osteoporosis," *Endocrinology and Metabolism Clinics of North America*, vol. 32, no. 1, pp. 135–157, 2003.

[70] D. Jia, C. A. O'Brien, S. A. Stewart, S. C. Manolagas, and R. S. Weinstein, "Glucocorticoids act directly on osteoclasts to increase their life span and reduce bone density," *Endocrinology*, vol. 147, no. 12, pp. 5592–5599, 2006.

[71] X. Whittier and K. G. Saag, "Glucocorticoid-induced Osteoporosis," *Rheumatic Disease Clinics of North America*, vol. 42, no. 1, pp. 177–189, 2016.

[72] R. S. Weinstein, R. L. Jilka, A. Michael Parfitt, and S. C. Manolagas, "Inhibition of osteoblastogenesis and promotion of apoptosis of osteoblasts end osteocytes by glucocorticoids potential mechanisms of their deleterious effects on bone," *The Journal of Clinical Investigation*, vol. 102, no. 2, pp. 274–282, 1998.

[73] J. Arteh, S. Narra, and S. Nair, "Prevalence of vitamin D deficiency in chronic liver disease," *Digestive Diseases and Sciences*, vol. 55, no. 9, pp. 2624–2628, 2010.

[74] E. Cholongitas, E. Theocharidou, J. Goulis, E. Tsochatzis, E. Akriviadis, and K. Burroughs, "Review article: the extra-skeletal effects of vitamin D in chronic hepatitis C infection," *Alimentary Pharmacology and Therapeutics*, vol. 35, no. 6, pp. 634–646, 2012.

[75] P. Lips, "Vitamin D deficiency and secondary hyperparathyroidism in the elderly: consequences for bone loss and fractures and therapeutic implications," *Endocrine Reviews*, vol. 22, no. 4, pp. 477–501, 2001.

[76] A. Mounach, Z. Ouzzif, G. Wariaghli et al., "Primary biliary cirrhosis and osteoporosis: a case-control study," *Journal of Bone and Mineral Metabolism*, vol. 26, no. 4, pp. 379–384, 2008.

[77] P. Malik, R. W. Gasser, G. Kemmler et al., "Low bone mineral density and impaired bone metabolism in young alcoholic patients without liver cirrhosis: a cross-sectional study," *Alcoholism: Clinical and Experimental Research*, vol. 33, no. 2, pp. 375–381, 2009.

[78] G. W. McCaughan and R. B. Feller, "Osteoporosis in chronic liver disease: pathogenesis, risk factors, and management," *Digestive Diseases*, vol. 12, no. 4, pp. 223–231, 1994.

[79] K. V. Kowdley, M. J. Emond, J. A. Sadowski, and M. M. Kaplan, "Plasma vitamin K1 level is decreased in primary biliary cirrhosis," *American Journal of Gastroenterology*, vol. 92, no. 11, pp. 2059–2061, 1997.

[80] S. Nishiguchi, S. Shimoi, H. Kurooka et al., "Randomized pilot trial of vitamin k2 for bone loss in patients with primary biliary cirrhosis," *Journal of Hepatology*, vol. 35, no. 4, pp. 543–545, 2001.

[81] Y. Koshihara, K. Hoshi, R. Okawara, H. Ishibashi, and S. Yamamoto, "Vitamin K stimulates osteoblastogenesis and inhibits osteoclastogenesis in human bone marrow cell culture," *Journal of Endocrinology*, vol. 176, no. 3, pp. 339–348, 2003.

[82] Y. Hiruma, K.-I. Nakahama, H. Fujita, and I. Morita, "Vitamin K2 and geranylgeraniol, its side chain component, inhibited osteoclast formation in a different manner," *Biochemical and Biophysical Research Communications*, vol. 314, no. 1, pp. 24–30, 2004.

[83] S. Cockayne, J. Adamson, S. Lanham-New et al., "Vitamin K and the prevention of fractures: systematic review and meta-analysis of randomized controlled trials," *Archives of Internal Medicine*, vol. 166, no. 12, pp. 1256–1261, 2006.

[84] I. A. Nakchbandi and S. W. van der Merwe, "Current understanding of osteoporosis associated with liver disease," *Nature Reviews Gastroenterology & Hepatology*, vol. 6, no. 11, pp. 660–670, 2009.

[85] J. L. Gonzalez-calvin, A. Garcia-sanchez, V. Bellot, M. Munoz-torres, E. Raya-alvarez, and D. Salvatierra-rios, "Mineral metabolism, osteoblastic function and bone mass in chronic alcoholism," *Alcohol and Alcoholism*, vol. 28, no. 5, pp. 571–579, 1993.

[86] F. Santolaria, E. González-Reimers, J. L. Pérez-Manzano et al., "Osteopenia assessed by body composition analysis is related to malnutrition in alcoholic patients," *Alcohol*, vol. 22, no. 3, pp. 147–157, 2000.

[87] E. González-Reimers, J. Alvisa-Negrín, F. Santolaria-Fernández et al., "Prognosis of osteopenia in chronic alcoholics," *Alcohol*, vol. 45, no. 3, pp. 227–238, 2011.

[88] K. M. Kim, H. S. Choi, M. Choi, and H. Y. Chung, "Calcium and Vitamin D supplementations: 2015 position statement of the korean society for bone and mineral research," *Journal of Bone Metabolism*, vol. 22, no. 4, pp. 143–149, 2015.

[89] I. Loria, C. Albanese, M. Giusto et al., "Bone disorders in patients with chronic liver disease awaiting liver transplantation," *Transplantation Proceedings*, vol. 42, no. 4, pp. 1191–1193, 2010.

[90] W. Leslie, "AGA technical review on osteoporosis in hepatic disorders," *Gastroenterology*, vol. 125, no. 3, pp. 941–966, 2003.

[91] N. Guañabens, A. Monegal, A. Muxi et al., "Patients with cirrhosis and ascites have false values of bone density: implications for the diagnosis of osteoporosis," *Osteoporosis International*, vol. 23, no. 4, pp. 1481–1487, 2012.

[92] E. D. Labio, D. B. Del Rosario, S. I. Strasser, G. W. McCaughan, and B. A. Crawford, "Effect of ascites on bone density measurement in cirrhosis," *Journal of Clinical Densitometry*, vol. 10, no. 4, pp. 391–394, 2007.

[93] M. A. Valero, C. Loinaz, L. Larrodera, M. Leon, E. Moreno, and F. Hawkins, "Calcitonin and bisphosphonates treatment in bone loss after liver transplantation," *Calcified Tissue International*, vol. 57, no. 1, pp. 15–19, 1995.

[94] D. Chappard, B. Plantard, M. Petitjean, C. Alexandre, and G. Riffat, "Alcoholic cirrhosis and osteoporosis in men: a light and scanning electron microscopy study," *Journal of Studies on Alcohol*, vol. 52, no. 3, pp. 269–274, 1991.

[95] J. Kim, H. Lee, K. S. Kang, K. Chun, and G. S. Hwang, "Protective effect of Korean Red Ginseng against glucocorticoid-induced osteoporosis in vitro and in vivo," *Journal of Ginseng Research*, vol. 39, no. 1, pp. 46–53, 2015.

[96] T. Waldman, R. Sarbaziha, C. N. B. Merz, and C. Shufelt, "Calcium supplements and cardiovascular disease: a review," *American Journal of Lifestyle Medicine*, vol. 9, no. 4, pp. 298–307, 2015.

[97] C. S. Shin and K. M. Kim, "The risks and benefits of calcium supplementation," *Endocrinology and Metabolism*, vol. 30, no. 1, pp. 27–34, 2015.

[98] S. Shiomi, K. Masaki, D. Habu et al., "Calcitriol for bone disease in patients with cirrhosis of the liver," *Journal of Gastroenterology and Hepatology*, vol. 14, no. 6, pp. 547–552, 1999.

[99] M. J. Bolland, W. Leung, V. Tai et al., "Calcium intake and risk of fracture: systematic review," *British Medical Journal*, vol. 351, Article ID h4580, 2015.

[100] C. Mateo Pascual, R. Julián Viñals, M. V. Castell Alcalá, R. Queipo, and A. Otero Piume, "Evaluation of adherence to treatment with calcium and Vitamin D in the elderly in a basic health area," *Revista de Calidad Asistencial*, vol. 31, no. 1, pp. 10–17, 2016.

[101] J. S. Crippin, R. A. Jorgensen, E. R. Dickson, and K. D. Lindor, "Hepatic osteodystrophy in primary biliary cirrhosis: effects of medical treatment," *The American Journal of Gastroenterology*, vol. 89, no. 1, pp. 47–50, 1994.

[102] S. P. Pereira, J. O'Donohue, C. Moniz et al., "Transdermal hormone replacement therapy improves vertebral bone density in primary biliary cirrhosis: results of a 1-year controlled trial," *Alimentary Pharmacology and Therapeutics*, vol. 19, no. 5, pp. 563–570, 2004.

[103] T. Diamond, D. Stiel, and S. Posen, "Effects of testosterone and venesection on spinal and peripheral bone mineral in six hypogonadal men with hemochromatosis," *Journal of Bone and Mineral Research*, vol. 6, no. 1, pp. 39–43, 1991.

[104] "Effects of hormone therapy on bone mineral density: results from the postmenopausal estrogen/progestin interventions (PEPI) trial. The Writing Group for the PEPI," *JAMA*, vol. 276, no. 17, pp. 1389–1396, 1996.

[105] J. E. Rossouw, G. L. Anderson, R. L. Prentice et al., "Risks and benefits of estrogen plus progestin in healthy postmenopausal women: principal results from the Women's Health Initiative randomized controlled trial," *The Journal of the American Medical Association*, vol. 288, no. 3, pp. 321–333, 2002.

[106] R. H. Boone, A. M. Cheung, L. M. Girlan, and E. J. Heathcote, "Osteoporosis in primary biliary cirrhosis: a randomized trial

of the efficacy and feasibility of estrogen/progestin," *Digestive Diseases and Sciences*, vol. 51, no. 6, pp. 1103–1112, 2006.

[107] European Association for the Study of the Liver, "EASL Clinical Practice Guidelines: management of cholestatic liver diseases," *Journal of Hepatology*, vol. 51, no. 2, pp. 237–267, 2009.

[108] H. Isoniemi, J. Appelberg, C.-G. Nilsson, P. Mäkelä, J. Risteli, and K. Höckerstedt, "Transdermal estrogen therapy improves lipid profile and osteoporosis in postmenopausal liver transplant patients," *Transplantation Proceedings*, vol. 33, no. 1-2, pp. 1472–1473, 2001.

[109] R. Olsson, L.-Å. Mattsson, K. Obrant, and D. Mellström, "Estrogen-progestogen therapy for low bone mineral density in primary biliary cirrhosis," *Liver*, vol. 19, no. 3, pp. 188–192, 1999.

[110] S. Ormarsdóttir, H. Mallmin, T. Naessén et al., "An open, randomized, controlled study of transdermal hormone replacement therapy on the rate of bone loss in primary biliary cirrhosis," *Journal of Internal Medicine*, vol. 256, no. 1, pp. 63–69, 2004.

[111] A. Floreani, M. Chiaramonte, S. Giannini et al., "Longitudinal study on osteodystrophy in primary biliary cirrhosis (PBC) and a pilot study on calcitonin treatment," *Journal of Hepatology*, vol. 12, no. 2, pp. 217–223, 1991.

[112] A. Floreani, F. Zappala, W. Fries et al., "A 3-year pilot study with 1,25-dihydroxyvitamin D, calcium, and calcitonin for severe osteodystrophy in primary biliary cirrhosis," *Journal of Clinical Gastroenterology*, vol. 24, no. 4, pp. 239–244, 1997.

[113] M. Camisasca, A. Crosignani, P. M. Battezzati et al., "Parenteral calcitonin for metabolic bone disease associated with primary biliary cirrhosis," *Hepatology*, vol. 20, no. 3, pp. 633–637, 1994.

[114] M. Kleerekoper and D. B. Mendlovic, "Sodium fluoride therapy of postmenopausal osteoporosis," *Endocrine Reviews*, vol. 14, no. 3, pp. 312–323, 1993.

[115] N. Guañabens, A. Parés, L. del Rio et al., "Sodium fluoride prevents bone loss in primary biliary cirrhosis," *Journal of Hepatology*, vol. 15, no. 3, pp. 345–349, 1992.

[116] N. Guanabens, A. Pares, A. Monegal et al., "Etidronate versus fluoride for treatment of osteopenia in primary biliary cirrhosis: preliminary results after 2 years," *Gastroenterology*, vol. 113, no. 1, pp. 219–224, 1997.

[117] C. Levy, D. M. Harnois, P. Angulo, R. Jorgensen, and K. D. Lindor, "Raloxifene improves bone mass in osteopenic women with primary biliary cirrhosis: results of a pilot study," *Liver International*, vol. 25, no. 1, pp. 117–121, 2005.

[118] A. Yurci, A. O. Kalkan, O. Ozbakir et al., "Efficacy of different therapeutic regimens on hepatic osteodystrophy in chronic viral liver disease," *European Journal of Gastroenterology and Hepatology*, vol. 23, no. 12, pp. 1206–1212, 2011.

[119] H. L. Reeves, R. M. Francis, D. M. Manas, M. Hudson, and C. P. Day, "Intravenous bisphosphonate prevents symptomatic osteoporotic vertebral collapse in patients after liver transplantation," *Liver Transplantation and Surgery*, vol. 4, no. 5, pp. 404–409, 1998.

[120] N. Guañabens, A. Parés, I. Ros et al., "Alendronate is more effective than etidronate for increasing bone mass in osteopenic patients with primary biliary cirrhosis," *The American Journal of Gastroenterology*, vol. 98, no. 10, pp. 2268–2274, 2003.

[121] C. O. Zein, R. A. Jorgensen, B. Clarke et al., "Alendronate improves bone mineral density in primary biliary cirrhosis: a randomized placebo-controlled trial," *Hepatology*, vol. 42, no. 4, pp. 762–771, 2005.

[122] N. Guañabens, A. Monegal, D. Cerdá et al., "Randomized trial comparing monthly ibandronate and weekly alendronate for osteoporosis in patients with primary biliary cirrhosis," *Hepatology*, vol. 58, no. 6, pp. 2070–2078, 2013.

[123] M. Ninkovic, S. Love, B. D. M. Tom, P. W. P. Bearcroft, G. J. M. Alexander, and J. E. Compston, "Lack of effect of intravenous pamidronate on fracture incidence and bone mineral density after orthotopic liver transplantation," *Journal of Hepatology*, vol. 37, no. 1, pp. 93–100, 2002.

[124] S. Vedi, M. Ninkovic, N. J. Garrahan, G. J. M. Alexander, and J. E. Compston, "Effects of a single infusion of pamidronate prior to liver transplantation: a bone histomorphometric study," *Transplant International*, vol. 15, no. 6, pp. 290–295, 2002.

[125] P. Dodidou, T. Bruckner, S. Hosch et al., "Better late than never? Experience with intravenous pamidronate treatment in patients with low bone mass or fractures following cardiac or liver transplantation," *Osteoporosis International*, vol. 14, no. 1, pp. 82–89, 2003.

[126] P. Pennisi, A. Trombetti, E. Giostra, G. Mentha, R. Rizzoli, and C. E. Fiore, "Pamidronate and osteoporosis prevention in liver transplant recipients," *Rheumatology International*, vol. 27, no. 3, pp. 251–256, 2007.

[127] G. Millonig, I. W. Graziadei, D. Eichler et al., "Alendronate in combination with calcium and vitamin D prevents bone loss after orthotopic liver transplantation: a prospective single-center study," *Liver Transplantation*, vol. 11, no. 8, pp. 960–966, 2005.

[128] B. A. Crawford, E. D. Labio, S. I. Strasser, and G. W. McCaughan, "Vitamin D replacement for cirrhosis-related bone disease," *Nature Clinical Practice Gastroenterology and Hepatology*, vol. 3, no. 12, pp. 689–699, 2006.

[129] F. Atamaz, S. Hepguler, M. Akyildiz, Z. Karasu, and M. Kilic, "Effects of alendronate on bone mineral density and bone metabolic markers in patients with liver transplantation," *Osteoporosis International*, vol. 17, no. 6, pp. 942–949, 2006.

[130] M. Bodingbauer, T. Wekerle, B. Pakrah et al., "Prophylactic bisphosphonate treatment prevents bone fractures after liver transplantation," *American Journal of Transplantation*, vol. 7, no. 7, pp. 1763–1769, 2007.

[131] B. M. Misof, M. Bodingbauer, P. Roschger et al., "Short-term effects of high-dose zoledronic acid treatment on bone mineralization density distribution after orthotopic liver transplantation," *Calcified Tissue International*, vol. 83, no. 3, pp. 167–175, 2008.

[132] A. Monegal, N. Guañabens, M. J. Suárez et al., "Pamidronate in the prevention of bone loss after liver transplantation: a randomized controlled trial," *Transplant International*, vol. 22, no. 2, pp. 198–206, 2009.

[133] M. Ablikim, M. N. Achasov, X. C. Ai et al., "Observation of $e^+e^- \rightarrow \pi^0\pi^0 h_c$ and a neutral charmoniumlike structure $Z_c(4020)^0$," *Physical Review Letters*, vol. 113, no. 21, Article ID 212002, 2014.

Hindawi Publishing Corporation
BioMed Research International
Volume 2016, Article ID 4054513, 10 pages
http://dx.doi.org/10.1155/2016/4054513

Review Article

Esophageal Stent for Refractory Variceal Bleeding: A Systemic Review and Meta-Analysis

Xiao-Dong Shao, Xing-Shun Qi, and Xiao-Zhong Guo

Department of Gastroenterology, General Hospital of Shenyang Military Area Command, Shenyang 110016, China

Correspondence should be addressed to Xiao-Dong Shao; sxdsys608@189.cn

Received 18 February 2016; Revised 15 June 2016; Accepted 20 June 2016

Academic Editor: Michel Kahaleh

Background. Preliminary studies suggest that covered self-expandable metal stents may be helpful in controlling esophageal variceal bleeding. *Aims*. To evaluate the effectiveness and safety of esophageal stent in refractory variceal bleeding in a systematic review and meta-analysis. *Methods*. A comprehensive literature search was conducted on PubMed, EMBASE, and Cochrane Library covering the period from January 1970 to December 2015. Data were selected and abstracted from eligible studies and were pooled using a random-effects model. Heterogeneity was assessed using I^2 test. *Results*. Five studies involving 80 patients were included in the analysis. The age of patients ranged from 18 to 91 years. The mean duration of follow-up was 46.8 d (range, 30–60 d). The success rate of stent deployment was 96.7% (95% CI: 91.6%–99.5%) and complete response to esophageal stenting was in 93.9% (95% CI: 82.2%–99.6%). The incidence of rebleeding was 13.2% (95% CI: 1.8%–32.8%) and the overall mortality was 34.5% (95% CI: 24.8%–44.8%). Most of patients (87.4%) died from hepatic or multiple organ failure, and only 12.6% of patients died from uncontrolled bleeding. There was no stent-related complication reported and the incidence of stent migration was 21.6% (95% CI: 4.7%–46.1%). *Conclusion*. Esophageal stent may be considered in patients with variceal bleeding refractory to conventional therapy.

1. Introduction

Esophageal varices are portosystemic collateral venous channels related to portal hypertension and present in nearly 50% of patients diagnosed with cirrhosis [1]. They initially develop as small varices that gradually dilate at a rate of 5% per year. Acute variceal bleeding is a severe complication of portal hypertension causing 70% of all upper gastrointestinal bleeding episodes in patients with portal hypertension [2]. With the use of current prophylactic therapies of variceal bleeding, including nonselective beta-blockers and band ligation, the rate of first variceal bleeding is about 8% per year [3]. Risk factors of variceal bleeding mainly include the severity of liver disease, the size of varix, and the presence of red wale marks [4]. Hemodynamic studies suggest a close association of hepatic venous pressure gradient with the risk of variceal bleeding [5]. Prognostic factors for death include the severity of variceal bleeding, the degree of hepatic dysfunction, and the development of complications including acute renal failure and bacterial infections [6]. Mortality of patients with variceal bleeding has decreased significantly over the last two decades with the implementation of intensive care management, including the use of antibiotic prophylaxis and endoscopic variceal band ligation [7, 8]. However, the treatment of refractory bleeding and prevention of early rebleeding are still a challenge for physicians [9].

The aim of treatment of acute variceal bleeding is to correct hypovolemia, prevent complications, and achieve hemostasis. After resuscitation, airway protection, and prevention of complication, the initial approach for variceal bleeding is a combination of vasoactive drugs, antibiotics, and endoscopic therapy [10]. About 80%–90% of acute variceal bleeding episodes are successfully controlled by endoscopic therapy [11]. In 10%–20% of patients acute variceal bleeding is not controlled with this primary endoscopic and pharmacological therapy, which is known as refractory variceal bleeding [12]. More aggressive therapies may be used to deal with refractory variceal bleeding. Early TIPS should be considered in patients at high risk of treatment failure after initial endoscopic and pharmacological therapy [13].

Although rescue TIPS is very effective in controlling the bleeding, the mortality is high (25–60%) due to the poor condition of patients [14]. Balloon tamponade aims at achieving hemostasis by direct compression of the bleeding varices. However, after deflating the balloon, the recurrence rate of bleeding is about 50% [15]. Complications can occur in more than 25% of the patients treated with balloon tamponade with fatal ones in 5% of the cases. So it is recommended that balloon tamponade should only be used by skilled and experienced personnel in intensive care facilities [16]. Additionally, the use of the tube is highly unpleasant for patients. Surgical procedures are employed less frequently with the development of endoscopic therapy and TIPS. Although surgical procedures can effectively control variceal bleeding, the mortality remains high (45–75%) and hepatic encephalopathy is a major complication after shunt procedures [17]. The above-mentioned limitations prompt physicians to seek other modalities to deal with refractory esophageal variceal bleeding.

Self-expandable metal stents (SEMSs) are mainly used in various benign and malignant esophageal diseases, such as stricture, tracheoesophageal fistula, perforation, and achalasia [18]. Anecdotal experience suggests that the covered SEMSs may be useful in controlling esophageal variceal bleeding [19–25]. Since refractory variceal bleeding is an uncommon complication of cirrhosis, most of studies on the effectiveness of esophageal stent have been limited to a small number of patients [26–32]. A recent randomized controlled trial included only 13 patients undergoing esophageal stenting for refractory variceal bleeding [33]. The purpose of this study was to evaluate the effectiveness and safety of esophageal stent in patients with refractory variceal bleeding by pooling all available evidence in a systematic review with meta-analysis.

2. Materials and Methods

2.1. Literature Search. A comprehensive literature search was conducted using PubMed, EMBASE, and Cochrane Library for the period from January 1970 to December 2015. The search terms included, in different combinations, "esophageal stent", "self-expandable metal stents", "variceal bleeding", "variceal hemorrhage", and "endoscopic hemostasis". The search was limited to studies in humans published in English. References of eligible articles and review articles were manually searched.

2.2. Selection of Articles. The selection criteria were studies in (1) patients with cirrhosis irrespective of etiology; (2) patients with refractory variceal bleeding; and (3) series that included at least 10 patients. Case reports or series with fewer than 10 patients were excluded. After excluding duplicate articles, article titles and abstracts were screened by a reviewer (SXD). Each eligible article was reviewed in full text.

2.3. Data Extraction. Data were abstracted by the same reviewer and entered into an Excel spreadsheet (Microsoft Corp., Redmond, Washington). The following information was abstracted from each study: author, country, publication year, publication type, study design, participants, and outcome of interest (success rate of stent deployment, response to esophageal stent, rebleeding rate, overall mortality, cause of death, stent-related complications, and incidence of stent migration).

2.4. Definitions

Refractory Variceal Bleeding. Patients with active variceal bleeding were unresponsive to pharmacologic and endoscopic therapy and required transfusion.

Response to Esophageal Stent. Clinically, response was considered as complete hemostasis if the patients' symptoms of bleeding resolved. No response was defined as persistent or worsening symptoms of bleeding. Endoscopically, response was defined as no active bleeding or oozing from a varix on endoscopy. No response was defined as active bleeding or oozing found on endoscopy. Eligible studies used endoscopic and/or clinical criteria to assess the response to esophageal stent.

Esophageal Stent-Related Complications. Esophageal stent-related complications include esophageal tear or perforation, pulmonary dysfunction, aspiration pneumonia, asphyxia, and esophageal ulcer leading to bleeding which need further specific treatment.

Stent Migration. Esophageal stent migration was defined as stent migrating proximally or distally from the place where stents were deployed initially. Radiological examinations were necessary.

Overall Mortality. Overall mortality was defined as any death events throughout the follow-up period. The follow-up period varied across the studies, with the longest duration being 60 d.

2.5. Statistical Analysis. Data from eligible studies were pooled using a random-effects model with StatsDirect statistical software Version 2.7.8. Outcomes are expressed as proportions (percentages) with 95% CIs. The pooled analyses are presented as forest plots. Statistical heterogeneity between studies was assessed using the Cochran Q test and I^2 statistic. I^2 value of greater than 50% or a P value of less than 0.05 for the Q statistic was taken to indicate significant heterogeneity.

3. Results

3.1. Literature Search Results. Five studies involving a total of 80 patients were included in the analyses. Eight studies were excluded because each had a small number of study subjects. Figure 1 summarizes the results of the literature search. Table 1 summarizes the characteristics of the 5 eligible studies.

3.2. Characteristics of Study Participants. Seventy-one patients were male. The age ranged from 18 to 91 years. The mean duration of follow-up was 46.8 d (range, 30–60 d).

Table 1: Study characteristics.

Author	Country	Publication year	Publication type	Study design	Number of cases	Gender (M/F)	Age (years)	Child class A (%)	Child classes B + C (%)	HCC (%)	Previous bleeding episode (%)	Previous BT (%)
Zehetner et al. [20]	Austria	2008	Full text	Retrospective	34	33/1	Mean: 56 (32–91)	0 (0%)	34 (100%)	NA	24 (70.59%)	6
Wright et al. [24]	UK	2010	Full text	Retrospective	10	9/1	Mean: 49 (18–70)	NA	NA	2 (20%)	NA	5
Mishin et al. [32]	Moldova	2013	Abstract	Retrospective	12	8/4	Mean: 46.92 (24–62)	NA	NA	NA	NA	NA
Müller et al. [26]	Germany	2015	Full text	Retrospective	11	8/3	Mean: 64 (43–72)	1 (9.09%)	10 (90.91%)	3 (27.27%)	5 (45.45%)	NA
Escorsell et al. [33]	Spain	2016	Full text	RCT	13	13/0	Median: 69 (40–81)	3 (23.08%)	10 (76.92%)	2 (15.38%)	6 (46.15%)	0

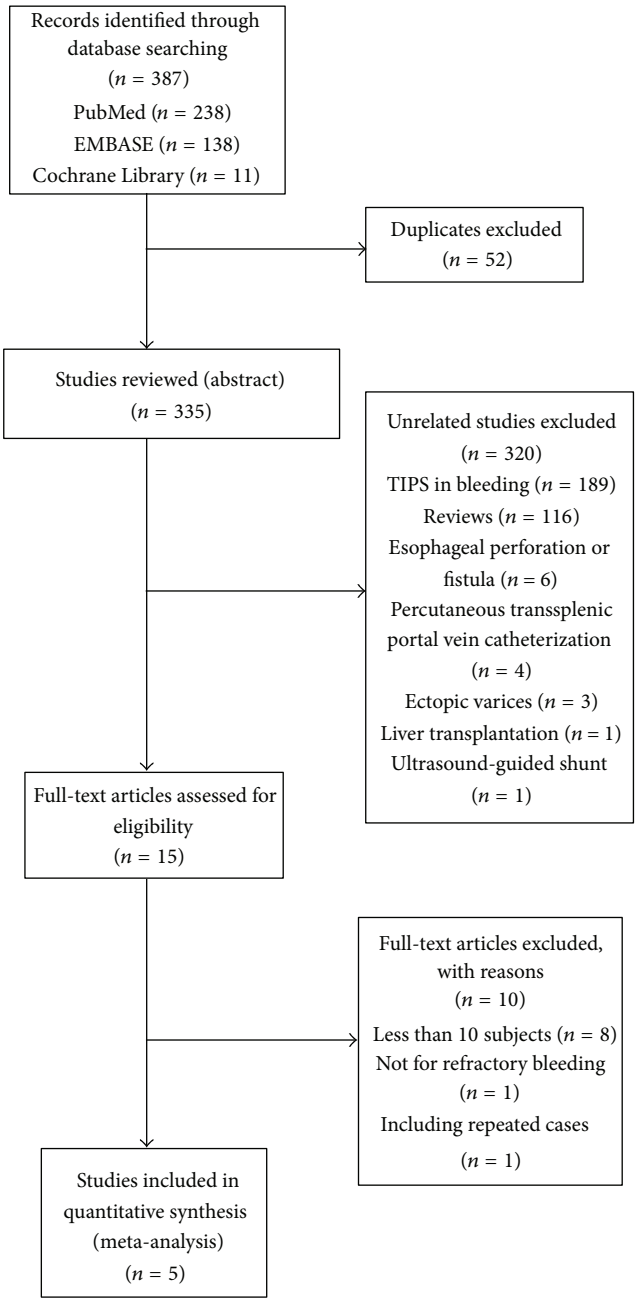

Figure 1: Study selection flow chart. Of a total of 387 studies, only 5 studies met selection criteria. TIPS indicates transjugular intrahepatic portosystemic shunt.

Table 2 shows the results of the various outcomes of the individual studies.

3.3. Stent Deployment. The success rate of stent deployment was 96.7% (95% CI: 91.6%–99.5%) (Figure 2). Heterogeneity was not significant among the studies ($I^2 = 6.8\%$; $P = 0.37$).

3.4. Response to Esophageal Stent. Complete response to esophageal stenting was in 93.9% (95% CI: 82.2%–99.6%) (Figure 3(a)). Heterogeneity was significant among the studies ($I^2 = 62.5\%$; $P = 0.03$). The incidence of rebleeding was 13.2% (95% CI: 1.8%–32.8%) (Figure 3(b)). Heterogeneity was significant among the studies ($I^2 = 78.1\%$; $P = 0.00$).

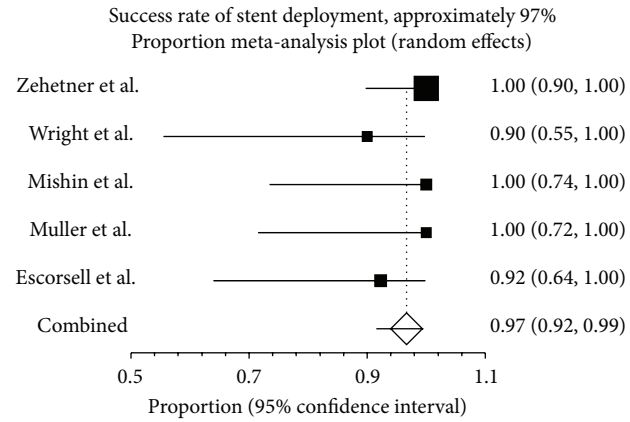

Figure 2: Deployment of esophageal stent in patients with refractory variceal bleeding. The esophageal stents were successfully deployed in 96.7% (95% CI: 91.6%–99.5%) of the 80 patients in the 5 studies. There was no heterogeneity among the studies ($P = 0.37$).

3.5. Mortality. The overall mortality was 34.5% (95% CI: 24.8%–44.8%) (Figure 4(a)). Heterogeneity was not significant among the studies ($I^2 = 0$; $P = 0.60$). 87.4% (95% CI: 71.2%–97.5%) of patients died from hepatic or multiple organ failure (Figure 4(b)). Only 12.6% (95% CI: 2.5%–28.8%) of patients died from uncontrolled bleeding (Figure 4(c)).

3.6. Complications. There was no stent-related complication reported.

3.7. Stent Migration. The incidence of stent migration was 21.6% (95% CI: 4.7%–46.1%) (Figure 5). Heterogeneity was significant among the studies ($I^2 = 81.6\%$; $P = 0.00$).

4. Discussion

This study shows the following: (1) esophageal stent was successfully deployed in 96.7% of patients with refractory variceal bleeding; (2) after successful deployment, the hemostasis rate was 93.9%; (3) the rate of rebleeding after esophageal stent is 13.2%; (4) no stent-related complications were reported in the 5 studies; (5) the overall mortality of patients was 34.5%; (6) a majority of patients with refractory variceal bleeding died of hepatic or multiple organ failure and only a minority of patients died from uncontrolled bleeding.

Variceal bleeding is a lethal complication of liver cirrhosis. When acute variceal bleeding fails to respond to pharmacological or endoscopic treatment, balloon tamponade is often undertaken [34, 35]. Although balloon tamponade is effective in controlling bleeding, it can be associated with complications such as perforation, asphyxia, and aspiration pneumonia [36–40]. And when balloon is extracted, the

Table 2: Outcomes of esophageal stent.

Author	Success of deployment	Time of stenting (d)	Stent migration	Stent-related complications	Bleeding controlled	TIPS after stent	Follow-up (d)	Rebleeding	30 d mortality	42 d mortality	60 d mortality	Death from uncontrolled bleeding	Death from hepatic or multiple organ failure
Zehetner et al. [20]	34 (100%)	1–14	7	0	34 (100%)	8	60	0 (0%)	9 (26.47%)	NA	10 (29.41%)	0	10 (100%)
Wright et al. [24]	9 (90%)	6–14	0	0	6 (66.67%)	1	60	1 (11.11%)	NA	5 (50%)	NA	2 (40%)	3 (60%)
Mishin et al. [32]	12 (100%)	NA	5	0	12 (100%)	NA	30	1 (8.33%)	3 (25%)	NA	NA	0	3 (100%)
Müller et al. [26]	11 (100%)	5–24	7	0	11 (100%)	2	42	1 (9.09%)	NA	3 (27.27%)	NA	0	3 (100%)
Escorsell et al. [33]	12 (92.31%)	0–12	0	0	11 (91.67%)	4	42	6 (50%)	NA	6 (50%)	NA	1 (16.67%)	5 (83.33%)

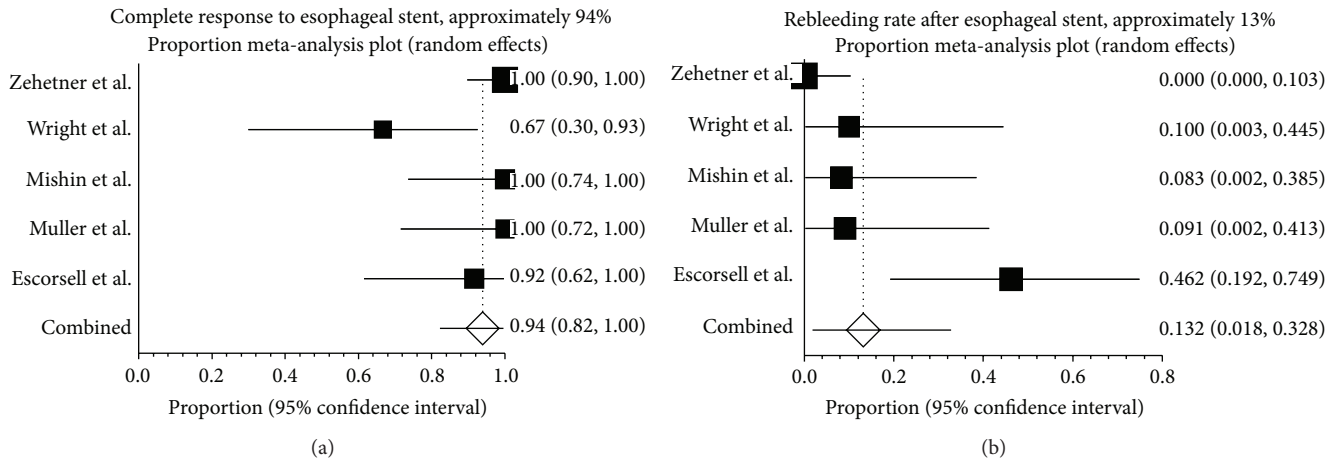

Figure 3: Response to esophageal stent in refractory variceal bleeding. (a) Forest plot shows that 93.9% (95% CI: 82.2%–99.6%) of the 80 patients in the 5 studies had a complete response (resolution of acute variceal bleeding without further need for other treatments) after deployment of esophageal stent. There was evidence of heterogeneity among the studies ($P = 0.03$). (b) Just over one-tenth (13.2%) of the patients treated with esophageal stents rebled after this procedure. There was evidence of heterogeneity among studies ($P = 0.00$).

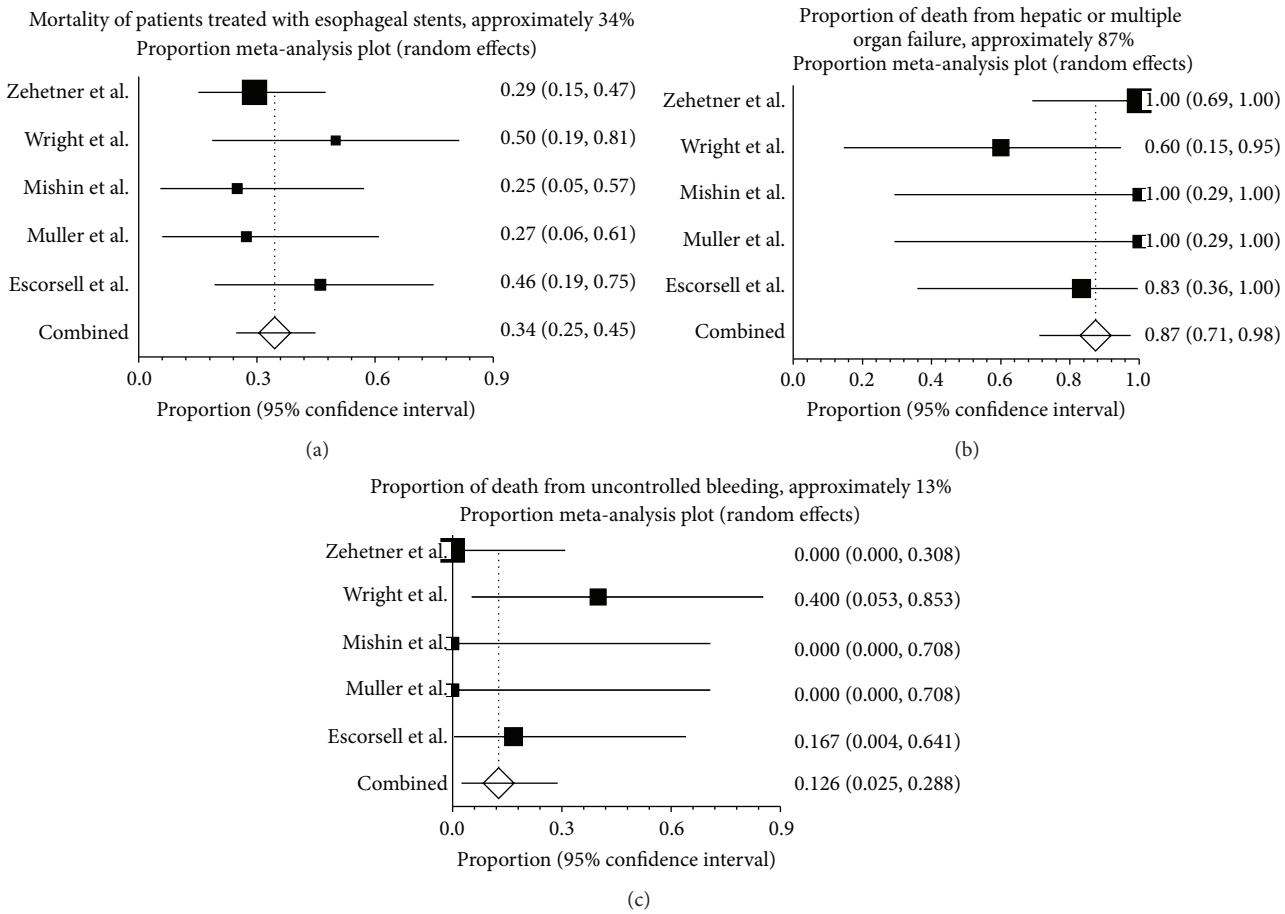

Figure 4: Mortality and causes of death of patients treated with esophageal stents. (a) Forest plot shows that about one-third [34.5% (95% CI: 24.8%–44.8%)] of the 80 patients in the 5 studies died within 30 or 60 d of undergoing esophageal stents. There was no evidence of heterogeneity among studies ($P = 0.60$). (b) About nine-tenth [87.4% (95% CI: 71.2%–97.5%)] of deaths were due to hepatic or multiple organ failure in patients treated with esophageal stents. There was no evidence of heterogeneity among studies ($P = 0.25$). (c) Just over one-tenth [12.6% (95% CI: 2.5%–28.8%)] of deaths were contributed to uncontrolled bleeding. There was no evidence of heterogeneity among studies ($P = 0.30$).

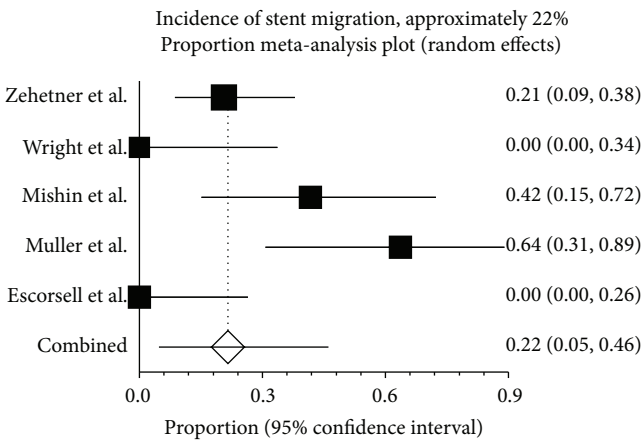

Figure 5: Stent migration after stent deployment. Stent migration was noted in about one-fifth [21.6% (95% CI: 4.7%–46.1%)] of the 80 patients in the 5 studies. There was, however, evidence of heterogeneity among the studies ($P = 0.00$).

rebleeding rate can be as high as 50% [6]. TIPS is an alternative for refractory variceal bleeding and can achieve complete response in most cases [12]. Hepatic encephalopathy is the most common complication of TIPS [41]. Acute and acute-on-chronic liver failure are regarded as contraindications of TIPS [42, 43]. If these patients had undergone TIPS at the time of bleeding, the risk of early death after TIPS would have been very high, approaching 60% [44].

Esophageal stent is a nonsurgical approach that maintains the patency of esophagus in malignant or benign esophageal obstructions [45]. Esophageal stent is also used in dealing with esophageal perforation and fistula with a satisfactory outcome [18]. However, few studies explored its use in patients with refractory variceal bleeding. Consequently, the evidence on the effectiveness of esophageal stent in refractory variceal bleeding has been limited to a small number of study participants. Pooled results from 5 studies found a wide range of response and rebleeding rates, perhaps due to the lack of statistical power. In this study, we combined the data from these small studies, which allowed us to provide the best evidence on the effectiveness of esophageal stent in refractory variceal bleeding.

The stents used in the 5 studies are self-expandable covered esophageal metal stent (SX-ELLA-Danis, Czech Republic) that are specifically produced for controlling variceal bleeding [19]. The success rate of deploying stent in patients with acute variceal bleeding is 96.7%. This proportion is well within the range for success rate of esophageal stenting in patients with malignant and benign esophageal strictures. Serious conditions, such as esophageal perforation [24] and acute bleeding, may not hinder the deployment of esophageal stents. Of course, the specific design of stents used in these studies may contribute to such a high success rate of procedures. However, in the earliest report of this procedure, five standard esophageal stents were also successfully inserted into expected positions with radiological guide [19]. Some reports indicated that the deployment of esophageal stent in patients with acute variceal bleeding is not a difficult procedure and specific designs of stents are more adequate in emergency room or intensive care unit without radiological facility [24]. In rare cases, the stents were inserted blindly without either X-ray or endoscopy [24]. However, Müller et al. pointed out that adequate training and exercise are necessary for successful deployment of esophageal stent in patients with acute variceal bleeding and blind stent implantation should not be advocated with concern of adverse events [26].

Refractory variceal bleeding is controlled after stent deployment in 93.9% of patients. Balloon tamponade is widely used in variceal bleeding which is adopted in 17.4% of patients with rebleeding [46]. Reportedly, 80%–90% of patients with refractory variceal bleeding treated with balloon tamponade achieved hemostasis [15]. This pooled analysis shows that in general the efficacy of esophageal stent on controlling bleeding seems not to be inferior to balloon tamponade. In the only RCT comparing esophageal stent and balloon tamponade, the primary composite endpoint (absence of digestive bleeding with absence of serious adverse events and survival at day 15) was achieved in 66% of the cases in the esophageal stent group but only in 20% in the balloon tamponade group [33]. According to this RCT, esophageal stent appears to be superior to balloon tamponade in treating refractory bleeding. In addition, esophageal stent allows patients to take food and drugs orally and undergo necessary diagnostic procedures including endoscopy. Esophageal stent is more comfortable than balloon tamponade for patients. The endotracheal intubation is not necessary for esophageal stenting, but balloon tamponade usually requires airway protection with intubation [38]. Balloon tamponade could be maintained for a maximum of 24–48 h to avoid esophageal or gastric pressure necrosis, but esophageal stents could remain in place for a longer period (range: 0–24 d). Thus, in hospitals where TIPS is not available, the longer retention time of stent is critical for safe transfer of patients to other medical centers. However, gastric varices will not be compressed by esophageal stent, so balloon tamponade still has a role in the management of gastric variceal bleeding.

With the use of banding ligation, vasoactive drugs, and antibiotics, the mortality of patients with variceal bleeding has been improved in recent years [47–50]. But initial failure to control bleeding or early rebleeding is usually associated with higher mortality [51]. The mortality rate increases to 80% if the initial treatment fails to stop acute bleeding [19]. In our study, the hemostasis rate was 94%, but the overall mortality is still 34%. These figures are higher than a general 6-week mortality rate of 15–20% using standard techniques [8]. This high mortality is attributed to the fact that all studies were conducted in high-risk patients with severe underlying liver diseases. The patients who are not responsive to standard therapy usually have advanced diseases and worse liver function. Child-Pugh class is the main predictor of outcome in patients with variceal bleeding [52]. Three of the 5 studies clearly recorded the Child-Pugh score, in which the proportion of patients with Child classes B and C is 77%–100%. Indeed, most of death cases (87%) were from hepatic or multiple organ failure. The mortality rate of 34% in our study is lower than the results of previous studies conducted in

patients with refractory variceal bleeding treated with other modalities [53].

The safety of esophageal stent in patients with variceal bleeding should be carefully assessed. The design of SX-ELLA-Danis stent with a protective pressure valve decreases the risk of perforation due to overinflated gastric balloon in esophagus [19]. In fact, two patients with concurrent variceal bleeding and esophagus perforation were successfully treated with this specifically designed stent [24]. Esophageal stenting followed by TIPS may be a reasonable choice for patients with variceal bleeding and perforation induced by balloon tamponade. There is no stent-related complication reported in the 5 studies, but an acute deterioration of pulmonary function was reported in a case report [23]. So the safety of this procedure should be further investigated in a larger number of patients. Stent migration occurred in about one-fifth of patients but the dislocation, proximal or distal, is not associated with any major damage such as rebleeding, perforation, or obstruction. With close monitoring the stent migration was easily detected and repositioned with endoscopy.

Collectively, esophageal stent may be considered as an alternative to refractory variceal bleeding in future. However, our conclusions should be cautiously interpreted due to the following limitations. First, there is significant heterogeneity among studies in terms of length of follow-up and important endpoints such as complete response, incidence of rebleeding, and stent migration. Second, the quality of the studies is mediocre. Only one study was a small RCT. Third, the characteristics of the patients included in the studies are reported incompletely. Two studies did not report the Child-Pugh classification. Two studies did not report the presence of HCC. Two studies did not report the presence of previous bleeds. Fourth, the overall mortality in these studies is disappointingly high. Fifth, the stent has to be removed after a period of 1-2 weeks. Thus, additional strategies to lower portal pressure are warranted. The best combination of different modalities with esophageal stent needs further studies. In all of the 5 studies included in this analysis, esophageal stents serve as a temporary or bridging treatment followed by other therapies.

Competing Interests

The authors declare that there is no conflict of interests regarding the publication of this paper.

References

[1] G. Garcia-Tsao and J. Bosch, "Management of varices and variceal hemorrhage in cirrhosis," *The New England Journal of Medicine*, vol. 362, no. 9, pp. 778–832, 2010.

[2] G. D'Amico and R. de Franchis, "Upper digestive bleeding in cirrhosis. Post-therapeutic outcome and prognostic indicators," *Hepatology*, vol. 38, no. 3, pp. 599–612, 2003.

[3] B. Fortune and G. Garcia-Tsao, "Current management strategies for acute esophageal variceal hemorrhage," *Current Hepatitis Reports*, vol. 13, no. 1, pp. 35–42, 2014.

[4] R. De Franchis and M. Primignani, "Natural history of portal hypertension in patients with cirrhosis," *Clinics in Liver Disease*, vol. 5, no. 3, pp. 645–663, 2001.

[5] C. Merkel, M. Bolognesi, S. Bellon et al., "Prognostic usefulness of hepatic vein catheterization in patients with cirrhosis and esophageal varices," *Gastroenterology*, vol. 102, no. 3, pp. 973–979, 1992.

[6] J. Bosch, A. Berzigotti, J. C. Garcia-Pagan, and J. G. Abraldes, "The management of portal hypertension: rational basis, available treatments and future options," *Journal of Hepatology*, vol. 48, no. 1, pp. S68–S92, 2008.

[7] N. Carbonell, A. Pauwels, L. Serfaty, O. Fourdan, V. G. Lévy, and R. Poupon, "Improved survival after variceal bleeding in patients with cirrhosis over the past two decades," *Hepatology*, vol. 40, no. 3, pp. 652–659, 2004.

[8] K. Stokkeland, L. Brandt, A. Ekbom, and R. Hultcrantz, "Improved prognosis for patients hospitalized with esophageal varices in Sweden 1969–2002," *Hepatology*, vol. 43, no. 3, pp. 500–505, 2006.

[9] G.-H. Lo, K.-H. Lai, J.-S. Cheng, M.-H. Chen, and H.-T. Chiang, "A prospective, randomized trial of butyl cyanoacrylate injection versus band ligation in the management of bleeding gastric varices," *Hepatology*, vol. 33, no. 5, pp. 1060–1064, 2001.

[10] R. Baares, A. Albillos, D. Rincón et al., "Endoscopic treatment versus endoscopic plus pharmacologic treatment for acute variceal bleeding: a meta-analysis," *Hepatology*, vol. 35, no. 3, pp. 609–615, 2002.

[11] G.-H. Lo, K.-H. Lai, W.-W. Ng et al., "Injection sclerotherapy preceded by esophageal tamponade versus immediate sclerotherapy in arresting active variceal bleeding: a prospective randomized trial," *Gastrointestinal Endoscopy*, vol. 38, no. 4, pp. 421–424, 1992.

[12] G. Garcia-Tsao, A. J. Sanyal, N. D. Grace et al., "Prevention and management of gastroesophageal varices and variceal hemorrhage in cirrhosis," *Hepatology (Baltimore, Md.)*, vol. 46, no. 3, pp. 922–938, 2007.

[13] J. C. García-Pagán, K. Caca, C. Bureau et al., "Early use of TIPS in patients with cirrhosis and variceal bleeding," *The New England Journal of Medicine*, vol. 362, no. 25, pp. 2370–2379, 2010.

[14] À. Escorsell and J. Bosch, "Self-expandable metal stents in the treatment of acute esophageal variceal bleeding," *Gastroenterology Research and Practice*, vol. 2011, Article ID 910986, 6 pages, 2011.

[15] A. Avgerinos and A. Armonis, "Balloon tamponade technique and efficacy in variceal haemorrhage," *Scandinavian Journal of Gastroenterology*, vol. 29, no. 207, pp. 11–16, 1994.

[16] M. D'Amico, A. Berzigotti, and J. C. Garcia-Pagan, "Refractory acute variceal bleeding: what to do next?" *Clinics in Liver Disease*, vol. 14, no. 2, pp. 297–305, 2010.

[17] G. D'Amico, L. Pagliaro, and J. Bosch, "The treatment of portal hypertension: a meta-analytic review," *Hepatology*, vol. 22, no. 1, pp. 332–354, 1995.

[18] P. Sharma and R. Kozarek, "Role of esophageal stents in benign and malignant diseases," *The American Journal of Gastroenterology*, vol. 105, no. 2, pp. 258–273, 2010.

[19] R. Hubmann, G. Bodlaj, M. Czompo et al., "The use of self-expanding metal stents to treat acute esophageal variceal bleeding," *Endoscopy*, vol. 38, no. 9, pp. 896–901, 2006.

[20] J. Zehetner, A. Shamiyeh, W. Wayand, and R. Hubmann, "Results of a new method to stop acute bleeding from

esophageal varices: implantation of a self-expanding stent," *Surgical Endoscopy and Other Interventional Techniques*, vol. 22, no. 10, pp. 2149–2152, 2008.

[21] A. Dechene, A. El Fouly, E. J. De Dechêne, T. Zoepf, and G. Gerken, "S1510: the bleeding stopped—what now? Self-expanding metal stents (SEMS) in refractory variceal bleeding and as part of combination therapy," *Gastrointestinal Endoscopy*, vol. 71, no. 5, p. AB181, 2010.

[22] W.-R. Matull, T. J. S. Cross, D. Yu, M. C. Winslet, and J. O'Beirne, "A removable covered self-expanding metal stent for the management of Sengstaken-Blakemore tube-induced esophageal tear and variceal hemorrhage," *Gastrointestinal Endoscopy*, vol. 68, no. 4, pp. 767–768, 2008.

[23] A. Dechene, M. Adamzik, G. Gerken, and A. Canbay, "Acute bronchial obstruction following esophageal stent implantation for variceal bleeding," *Endoscopy*, vol. 41, supplement 2, pp. E146–E147, 2009.

[24] G. Wright, H. Lewis, B. Hogan, A. Burroughs, D. Patch, and J. O'Beirne, "A self-expanding metal stent for complicated variceal hemorrhage: experience at a single center," *Gastrointestinal Endoscopy*, vol. 71, no. 1, pp. 71–78, 2010.

[25] I. Mishin, G. Ghidirim, A. Dolghii, G. Bunic, and G. Zastavnitsky, "Implantation of self-expanding metal stent in the treatment of severe bleeding from esophageal ulcer after endoscopic band ligation," *Diseases of the Esophagus*, vol. 23, no. 7, pp. E35–E38, 2010.

[26] M. Müller, T. Seufferlein, L. Perkhofer, M. Wagner, and A. Kleger, "Self-expandable metal stents for persisting esophageal variceal bleeding after band ligation or injection-therapy: a retrospective study," *PLoS ONE*, vol. 10, no. 6, Article ID e0126525, 2015.

[27] M. S. Zakaria, I. M. Hamza, M. A. Mohey, and R. G. Hubamnn, "The first Egyptian experience using new self-expandable metal stents in acute esophageal variceal bleeding: Pilot study," *Saudi Journal of Gastroenterology*, vol. 19, no. 4, pp. 177–181, 2013.

[28] F. C. Fierz, W. Kistler, V. Stenz, and C. Gubler, "Treatment of esophageal variceal hemorrhage with self-expanding metal stents as a rescue maneuver in a swiss multicentric cohort," *Case Reports in Gastroenterology*, vol. 7, no. 1, pp. 97–105, 2013.

[29] I. L. Holster, E. J. Kuipers, H. R. Van Buuren, M. C. W. Spaander, and E. T. T. L. Tjwa, "Self-expandable metal stents as definitive treatment for esophageal variceal bleeding," *Endoscopy*, vol. 45, no. 6, pp. 485–488, 2013.

[30] A. Dechêne, A. H. El Fouly, L. P. Bechmann et al., "Acute management of refractory variceal bleeding in liver cirrhosis by self-expanding metal stents," *Digestion*, vol. 85, no. 3, pp. 185–191, 2012.

[31] B. S. Ravindra, N. Ganjoo, E. B. Maanthagonda, and K. Shinde, "Esophageal variceal stent for uncontrolled post endoscopic variceal ligation ulcer bleed," *Indian Journal of Gastroenterology*, vol. 32, supplement 1, no. 1, p. A12, 2013.

[32] I. Mishin, G. Zastavnitsky, G. Ghidirim, and G. Bunic, "Self-expanding metal stents: a new hemostasis method for bleeding esophageal varices," *Hepatology International*, vol. 7, supplement 1, article S540, 2013.

[33] À. Escorsell, O. Pavel, A. Cárdenas et al., "Esophageal balloon tamponade versus esophageal stent in controlling acute refractory variceal bleeding: a multicenter randomized, controlled trial," *Hepatology*, vol. 63, no. 6, pp. 1957–1967, 2016.

[34] B. Feneyrou, J. Hanana, J. P. Daures, and J. B. Prioton, "Initial control of bleeding from esophageal varices with the Sengstaken-Blakemore tube. Experience in 82 patients," *The American Journal of Surgery*, vol. 155, no. 3, pp. 509–511, 1988.

[35] R. De Franchis, "Revising consensus in portal hypertension: report of the Baveno v consensus workshop on methodology of diagnosis and therapy in portal hypertension," *Journal of Hepatology*, vol. 53, no. 4, pp. 762–768, 2010.

[36] C.-F. Chong, "Esophageal rupture due to Sengstaken-Blakemore tube misplacement," *World Journal of Gastroenterology*, vol. 11, no. 41, pp. 6563–6565, 2005.

[37] A. Avgerinos, C. Klonis, G. Rekoumis, P. Gouma, N. Papadimitriou, and S. Raptis, "A prospective randomized trial comparing somatostatin, balloon tamponade and the combination of both methods in the management of acute variceal haemorrhage," *Journal of Hepatology*, vol. 13, no. 1, pp. 78–83, 1991.

[38] J. Panés, J. Terés, J. Bosch, and J. Rodés, "Efficacy of balloon tamponade in treatment of bleeding gastric and esophageal varices. Results in 151 consecutive episodes," *Digestive Diseases and Sciences*, vol. 33, no. 4, pp. 454–459, 1988.

[39] R. de Franchis, G. M. Eisen, L. Laine et al., "Esophageal capsule endoscopy for screening and surveillance of esophageal varices in patients with portal hypertension," *Hepatology*, vol. 47, no. 5, pp. 1595–1603, 2008.

[40] T. C. Collyer, S. E. T. Dawson, and D. Earl, "Acute upper airway obstruction due to displacement of a Sengstaken-Blakemore tube," *European Journal of Anaesthesiology*, vol. 25, no. 4, pp. 341–342, 2008.

[41] M. Rössle, "TIPS: 25 years later," *Journal of Hepatology*, vol. 59, no. 5, pp. 1081–1093, 2013.

[42] Z. Hassoun, M. Deschênes, M. Lafortune et al., "Relationship between pre-TIPS liver perfusion by the portal vein and the incidence of post-TIPS chronic hepatic encephalopathy," *The American Journal of Gastroenterology*, vol. 96, no. 4, pp. 1205–1209, 2001.

[43] T. D. Boyer and Z. J. Haskal, "The role of transjugular intrahepatic portosystemic shunt in the management of portal hypertension," *Hepatology*, vol. 41, no. 2, pp. 386–400, 2005.

[44] J. E. Lopera, "Role of emergency transjugular intrahepatic portosystemic shunts," *Seminars in Interventional Radiology*, vol. 22, no. 4, pp. 253–265, 2005.

[45] A. J. Dormann, S. Meisner, N. Verin, and A. Wenk Lang, "Self-expanding metal stents for gastroduodenal malignancies: systematic review of their clinical effectiveness," *Endoscopy*, vol. 36, no. 6, pp. 543–550, 2004.

[46] D. Cook and L. Laine, "Indications, technique, and complications of balloon tamponade for variceal gastrointestinal bleeding," *Journal of Intensive Care Medicine*, vol. 7, no. 4, pp. 212–218, 1992.

[47] A. E. S. Gimson, J. K. Ramage, M. Z. Panos et al., "Randomised trial of variceal banding ligation versus injection sclerotherapy for bleeding oesophageal varices," *The Lancet*, vol. 342, no. 8868, pp. 391–394, 1993.

[48] G. Ioannou, J. Doust, and D. C. Rockey, "Terlipressin for acute esophageal variceal hemorrhage," *Cochrane Database of Systematic Reviews*, no. 1, Article ID CD002147, 2001.

[49] M.-C. Hou, H.-C. Lin, T.-T. Liu et al., "Antibiotic prophylaxis after endoscopic therapy prevents rebleeding in acute variceal hemorrhage: a randomized trial," *Hepatology*, vol. 39, no. 3, pp. 746–753, 2004.

[50] A. K. Burroughs, C. K. Triantos, J. O'Beirne, and D. Patch, "Predictors of early rebleeding and mortality after acute variceal hemorrhage in patients with cirrhosis," *Nature Clinical Practice Gastroenterology and Hepatology*, vol. 6, no. 2, pp. 72–73, 2009.

[51] Z. Ben-Ari, F. Cardin, A. P. McCormick, G. Wannamethee, and A. K. Burroughs, "A predictive model for failure to control bleeding during acute variceal haemorrhage," *Journal of Hepatology*, vol. 31, no. 3, pp. 443–450, 1999.

[52] L. Amitrano, M. A. Guardascione, F. Manguso et al., "The effectiveness of current acute variceal bleed treatments in unselected cirrhotic patients: refining short-term prognosis and risk factors," *The American Journal of Gastroenterology*, vol. 107, no. 12, pp. 1872–1878, 2012.

[53] J. C. Garcia-Pagán and J. Bosch, "Endoscopic band ligation in the treatment of portal hypertension," *Nature Clinical Practice Gastroenterology and Hepatology*, vol. 2, no. 11, pp. 526–535, 2005.