BioMed Research International

Genitourethral Reconstruction

Guest Editors: Ralf Herwig, Salvatore Sansalone, and Peter Rehder

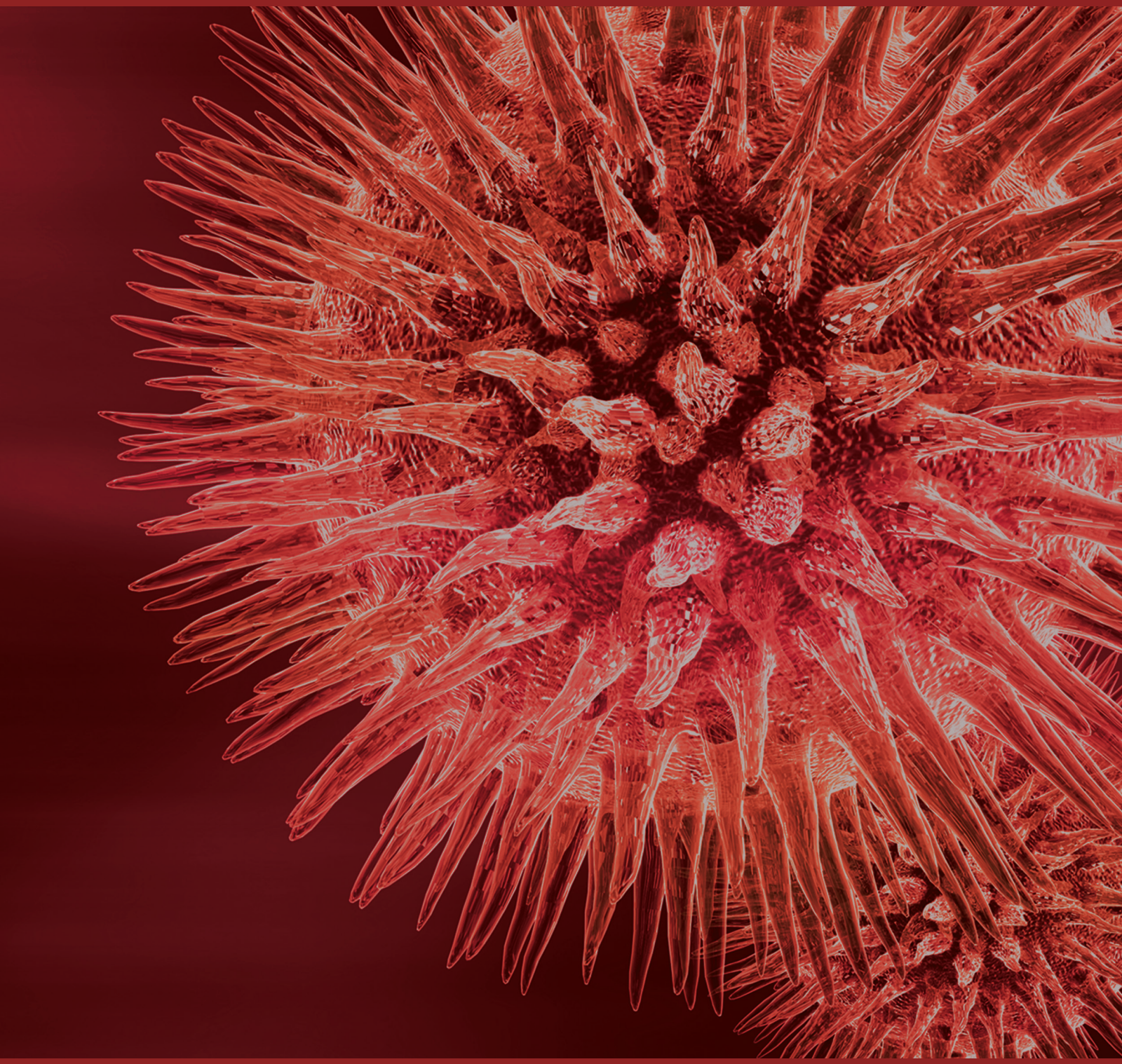

Genitourethral Reconstruction

BioMed Research International

Genitourethral Reconstruction

Guest Editors: Ralf Herwig, Salvatore Sansalone, and Peter Rehder

Copyright © 2015 Hindawi Publishing Corporation. All rights reserved.

This is a special issue published in "BioMed Research International." All articles are open access articles distributed under the Creative Commons Attribution License, which permits unrestricted use, distribution, and reproduction in any medium, provided the original work is properly cited.

Contents

Hindawi Publishing Corporation
BioMed Research International
Volume 2015, Article ID 535438, 2 pages
http://dx.doi.org/10.1155/2015/535438

Editorial

Genitourethral Reconstruction

Ralf Herwig,[1] Salvatore Sansalone,[2] and Peter Rehder[3]

[1]*Department of Reconstructive Urology, Andrology and Men's Health, Vienna Urology Foundation, 1010 Vienna, Austria*
[2]*Department of Urology, University of Rome "Tor Vergata", Via Orazio Raimondo 18, 00173 Rome, Italy*
[3]*Department of Urology, Medical University of Innsbruck, 6020 Innsbruck, Austria*

Correspondence should be addressed to Ralf Herwig; dr.ralf.herwig@gmail.com

Received 28 December 2014; Accepted 28 December 2014

Copyright © 2015 Ralf Herwig et al. This is an open access article distributed under the Creative Commons Attribution License, which permits unrestricted use, distribution, and reproduction in any medium, provided the original work is properly cited.

To write an editorial is always a good opportunity to say thanks to my coeditors Salvatore Sansalone and Peter Rehder for all the work they have done and to the authors of the many high-class manuscripts.

Reconstructive urology and andrology are still a very new research direction in the field of urology. For this reason we should specially take care to produce innovative research results. These results should not only reflect the so-called mainstream research but should focus on serving the patients.

Here we are particularly keen not to repeat past mistakes from other disciplines.

Reconstructive urology is a highly specialized field of urology that restores both structure and function to the genitourinary tract. Prostate procedures, full or partial hysterectomies, trauma (auto accidents, gunshot wounds, industrial accidents, straddle injuries, etc.), disease, obstructions, blockages (e.g., urethral strictures), and, occasionally, childbirth can require reconstructive surgery. The urinary bladder, ureters (the tubes that lead from the kidneys to the urinary bladder) and genitalia are other examples of reconstructive urology.

The goal in penile reconstruction is to either create or restore both functional and aesthetic phallus. This includes the ability not only to void while standing, from the tip of the phallus, but also to achieve sexual function, with a sensate penis of sufficient bulk to allow for penetration. Generally, the extent of the defect dictates the means of reconstruction we chose for our patients. A surgical defect may range from one involving a single tissue or structure (i.e., skin or urethra) to a total penectomy defect, requiring microsurgical reconstruction. The buried penis presents another interesting problem that demands a somewhat different surgical approach and procedure.

The classical reconstructive surgery in this field is reconstruction after resection of urethral strictures. Here we discuss two different techniques with perineal access in this issue.

Perineal ureterostomy is an option to manage complex and/or recurrent urethral strictures and is necessary after urethrectomy and/or penectomy. Both techniques are associated with about 20% recurrence rate and the patient should be informed about this risk.

Urinary diversion after cystectomy is an important field of reconstruction, which is very often associated with urinary retention and urinary incontinence. In the study of M. Życzkowski et al., the authors present a surgical modification during cystectomy with orthotopic ileal neobladder. The authors could demonstrate that sacrocolpopexy with polypropylene tape as valuable surgical modification during cystectomy with orthotopic ileal bladder is a valuable surgical method which provides patients with a better quality of life.

Another field in this context is transgender surgery. This is a highly complex and specified kind of surgery. For decades, several techniques have been proposed, but, as suggested by C. G. Sutcliffe et al. in a systematic review, no operative standards of care are available in this particular surgical field. Although many procedures are more or less harmonised, several complications are known to occur. Neovaginal prolapse is a relatively rare complication after male-to-female sexual reassignment surgery and tends to be very distressing for both patients and surgeons. In the article of S. Bucci et al. report about the authors incidence in total and partial neovaginal

prolapse, how they prevent it, and what their optimal way is to correct it.

Among the hospitalized patients, the admission rate of genitourinary trauma patients is assumed to be 2–10% and one-third of them were found to have an injury on external genitalia. Despite the fact that a classification of trauma is important to establish a strategy of treatment, to date there have been less efforts to make a classification for trauma of external genitalia. To date, there are no specific guidelines for the treatment of severe penile surgery because the injury mechanism is a complex and multifaceted subject. J. H. Kim et al. describe in their review the various penile injuries, which have relatively higher incidence. Physicians should keep in mind that the goal of treatment of penile injury is to achieve normal-like appearance, reduce functional damage such as erectile dysfunction and sensory loss, and minimize the postoperative sequel.

In this light, penile implant surgery often seems the only solution to prevent erectile function in trauma patients.

Nevertheless, nowadays, after 20 years of PDE5 inhibitors, the number of penile implant applications is rising. Although penile implantation remains a final solution for patients with refractory impotence, undesirable postoperative effects, including penile size reduction and cold sensation of the glans penis, remain problematic. Herein G.-L. Hsu et al. found that venous ligations at a retrocoronal level constitute a viable option for reducing the incidence of glanular size reduction. This encouraging preliminary study shows that a combination of venous stripping of the retrocoronal plexus and ligation of the deep dorsal vein and cavernous veins at the penile hilum appears to enhance glanular dimension in implant patients and may treat cold glans syndrome.

Peyronie's disease (PD) is a condition, which is getting more and more common. Nowadays it is assumed that about 10% of all males are suffering from this disease. It is characterized through formation of fibrous plaques which result in penile deformity, pain, and erectile dysfunction. C. Loreto et al. found out that apoptotic cell death occurs in stabilized PD plaques and is partly induced by the intrinsic mitochondrial pathway. The present findings possibly have clinical implications and may help to devise improved treatment strategies and may suggest perhaps new medical treatment options.

Andrology is the medical specialty that deals with male health, particularly relating to the problems of the male reproductive system and urological problems that are unique to men.

It is also known as "the science of men." It is the counterpart to gynaecology, which deals with medical issues which are specific to the female reproductive system. Andrology has only been studied as a distinct specialty since the late 1960s; the first specialist journal on the subject was the German periodical Andrologie (now called Andrologia), published from 1969 onwards.

All over the world, erectile dysfunction (ED) is considered one of the most diffuse sexual disorders. The prevalence rate of ED increases with age and with concomitant morbidities. Based on these considerations, phosphodiesterase-5 inhibitors (PDE5-i) have become the most popular treatment and are currently the first-line monotherapy for ED. But this category of drugs is not depicted from side effects that could impair pharmacological adherence. In this general context, studies on natural compounds have been conducted with the intention to limit side effects and to maintain efficacy. S. Sansalone et al. demonstrate that patients affected by mild-moderate ED may significantly benefit from oral therapy with this special mixture of natural ingredients by improving sexual and ejaculation function and sexual quality of life. In particular, those patients with moderate arterial dysfunction may significantly benefit from this medication.

A further burden in reduced sperm quality is uni- or bilateral varicocele. Varicoceles are recognized as the most common surgically correctable cause of male infertility, but the exact mechanism of varicocele-induced impairment of spermatogenesis remains a matter of debate. The exact association between reduced male fertility and varicocele is unknown, but a meta-analysis showed that semen improvement is usually observed after surgical correction. The group around Fabrizio Iacono present their experience on patients affected by bilateral varicocele and other scrotal comorbidities treated with surgery with a single scrotal access.

All of these outstanding works are hopefully adapted to expand our knowledge in the field of reconstructive urology and andrology. My coauthors and I are happy about this very successful issue. I wish you all continued enthusiasm and success in your work in this amazing area of medicine.

Ralf Herwig
Salvatore Sansalone
Peter Rehder

Hindawi Publishing Corporation
BioMed Research International
Volume 2015, Article ID 365715, 6 pages
http://dx.doi.org/10.1155/2015/365715

Clinical Study

Perineal Urethrostomy: Surgical and Functional Evaluation of Two Techniques

Nicolaas Lumen, Matthias Beysens, Charles Van Praet, Karel Decaestecker, Anne-Francoise Spinoit, Piet Hoebeke, and Willem Oosterlinck

Department of Urology, Ghent University Hospital, De Pintelaan 185, 9000 Ghent, Belgium

Correspondence should be addressed to Nicolaas Lumen; nicolaas.lumen@uzgent.be

Received 19 February 2014; Accepted 28 September 2014

Academic Editor: Ralf Herwig

Copyright © 2015 Nicolaas Lumen et al. This is an open access article distributed under the Creative Commons Attribution License, which permits unrestricted use, distribution, and reproduction in any medium, provided the original work is properly cited.

Introduction. PU is an option to manage complex and/or recurrent urethral strictures and is necessary after urethrectomy and/or penectomy. PU is generally assumed to be the last option before abandoning the urethral outlet. *Methods*. Between 2001 and 2013, 51 patients underwent PU. Mean age (± standard deviation) was 60 ± 15 years. Only 13 patients (25.5%) did not undergo previous urethral interventions. PU was performed according to the Johanson ($n = 35$) or Blandy ($n = 16$) technique and these 2 groups were compared for surgical failure, maximum urinary flow (Q_{max}), urinary symptoms, and quality of life (according to the International Prostate Symptom Score). *Results*. Both groups were similar for patient's and stricture characteristics. Only follow-up duration was significantly longer after Johanson PU (47.9 months versus 11.1 months; $P = 0.003$). For the entire cohort, 11 patients (21.6%) were considered a failure (9 or 25.7% for Johanson group and 2 or 12.5% for Blandy group; $P = 0.248$). There was a significant improvement of Q_{max} in both groups. Quality of life after PU was comparable in both groups. *Conclusions*. PU is associated with a 21.6% recurrence rate and the patient should be informed about this risk.

1. Introduction

Urethroplasty is the best option to restore urethral patency in case of urethral stricture disease [1, 2]. Nevertheless, urethroplasty is associated with a failure rate of 10–50%, depending on stricture etiology, stricture length, previous interventions, and the type of technique used [3–6]. Stricture recurrence after (several attempts of) urethroplasty might trigger the decision to stop further attempts in restoring patency of the entire urethra. The surgeon might take this decision because he has no further reconstructive options left or the patient might take this decision because he does not want further reconstruction with the risk of recurrent stricture [7]. At that point, perineal urethrostomy (PU) is a valuable option. A successful PU allows the patient to resume normal voiding and is generally assumed to be the last option before abandoning the urethral outlet. This procedure is reported to be a satisfactory solution, especially in the elderly [7]. PU is also needed after urethrectomy and/or penectomy [8, 9]. Different types of PU have been described [7, 10–12]. These techniques are mainly derived from the first stage of the two-stage urethroplasty described by Johanson [13] and Blandy et al. [14], both renowned pioneers in the field of urethral surgery.

The aim of this paper is to evaluate the surgical and functional outcome after Johanson or Blandy PU. To our knowledge, this is the largest series published on Johanson PU and the first to compare Johanson with Blandy PU.

2. Material and Methods

2.1. Patient Population. Fifty-one patients underwent PU at the Ghent University Hospital between January, 2001, and June, 2013 (Table 1). Data were retrospectively analysed. Mean (± standard deviation) and median (interquartile range) follow-up of the entire cohort was, respectively, 36 (± 41.6) and 16 (8–48) months. The Johanson and Blandy technique was used in 35 and 16 patients, respectively. Median follow-up was significantly longer in the Johanson group compared to the Blandy group (36 versus 9 months; $P < 0.001$). Early postoperative complications were scored according to the Clavien-Dindo classification [15]. Patients were further

Table 1: Patient and stricture characteristics. Values are presented as mean ± standard deviation or number (%). For follow-up, the median value with interquartile range is provided because of unequal variances.

	Total (n = 51)	Johanson (n = 35)	Blandy (n = 16)	P value
Follow-up (months)				
Mean (± standard deviation)	36.3 ± 41.6	47.9 ± 45.5	11.1 ± 10.4	**0.002**[*]
Median (interquartile range)	16 (8–48)	36 (11–75)	9 (6–13)	**<0.001**[*]
Age (years)	60.1 ± 15.1	60.5 ± 14.7	59.2 ± 16.4	0.769[°]
Stricture length (cm)	8.6 ± 5.0	9.3 ± 5.0	7.1 ± 4.8	0.141[°]
Preop Q_{max} (mL/s)	3.1 ± 4.8	2.6 ± 3.1	3.9 ± 6.6	0.483[°]
Etiology				
Idiopathic	8 (15.7%)	6 (17.1%)	2 (12.5%)	
Iatrogenic	21 (41.2%)	17 (48.6%)	4 (25.0%)	
Traumatic	5 (9.8%)	2 (5.7%)	3 (18.8%)	0.271[§]
Inflammatory	7 (13.7%)	5 (14.3%)	2 (12.5%)	
Urethrectomy	10 (19.6%)	5 (14.3%)	5 (31.2%)	
Previous interventions				
None	13 (25.5%)	8 (22.96%)	5 (31.2%)	
DVIU/dilation	7 (13.7%)	7 (20.0%)	0 (0.0%)	0.074[§]
Urethroplasty	31 (60.8%)	20 (57.1%)	11 (68.8%)	
Location				
Bulbar	12 (23.5%)	10 (28.6%)	2 (12.5%)	
Penile	12 (23.5%)	7 (20.0%)	5 (31.2%)	
Membranous	5 (9.8%)	1 (2.9%)	4 (25.0%)	0.053[§]
Panurethral	22 (43.1%)	17 (48.6%)	5 (31.2%)	
Suprapubic catheter				
No	35 (68.6%)	24 (68.6%)	11 (68.8%)	
Yes	16 (31.4%)	11 (31.4%)	5 (31.2%)	0.99[#]

([*] Mann-Whitney test; [°] independent samples t-test; [§] Fisher's exact test; [#] Chi-square test.)

followed up on a regular basis with history taking, clinical examination, and uroflowmetry. In case of suspicion of stenosis, urethrography and ureteroscopy were performed. Need for any additional urethral instrumentation (including dilation) was defined as failure. In November 2013, all surviving patients (n = 44) were sent the IPSS (International Prostate Symptom Score). The IPSS is used to score obstructive and irritative voiding symptoms with a score varying from 0 (no symptoms) to 35 (very severe symptoms). It also contains a question on quality of life (QoL) varying from 0 (very satisfied) to 6 (very dissatisfied). We redistributed QoL score into 3 groups: satisfactory QoL (score 0 → 2), acceptable QoL (score = 3), and dissatisfied with QoL (score 4 → 6). The study was approved by the local ethics committee (EC UZG 2007/434 and EC UZG 2008/234).

2.2. Surgical Technique. Patients were placed in the lithotomy position. For Blandy PU, an inverted-U perineal incision was made. For the Johanson procedure, an inverted-U or midline perineal incision was performed. The bulbar urethra was exposed and opened ventrally. The urethrotomy was extended proximally until healthy urethra was encountered. For patients with stricture, at the membranous urethra, the urethrotomy was extended into the membranous urethra up to the apex of the prostate. In this series, a complete transection of the urethra with mobilization of the proximal urethral stump towards the perineum was never performed. For Johanson PU, scrotal skin was invaginated towards the opened urethra (Figure 1) and an incision was made at the scrotal skin according to the length of the opened urethra. The scrotal skin edges were sutured to the urethral mucosa with interrupted sutures Vicryl 3.0. For an extensive description and illustrations of this technique, we refer to a previous publication [12]. For Blandy PU, the apex of the inverted-U perineal flap was sutured to the most proximal part of the opened urethra. The edges of the perineal flap were further sutured distally to the urethral mucosal edges with Vicryl 3.0. From the moment tension occurred between the sutures, a midline incision was made at the posterior scrotal skin, and two scrotal skin flaps were mobilized to finalize the PU (Figure 2).

2.3. Statistical Analysis. Groups were analyzed with independent samples t-test (equal variances) or Mann-Whitney test (unequal variances) for continuous variables and with Chi-square or Fischer's exact test for categorical variables. One-year failure free survival (FFS) was evaluated using Kaplan-Meier survival analysis and log-rank statistics. Logistic regression analysis was performed to identify factors predicting failure and QoL. For failure, analyzed factors were patient's age, stricture etiology, stricture length, stricture location, previous interventions, type of operation, and presence

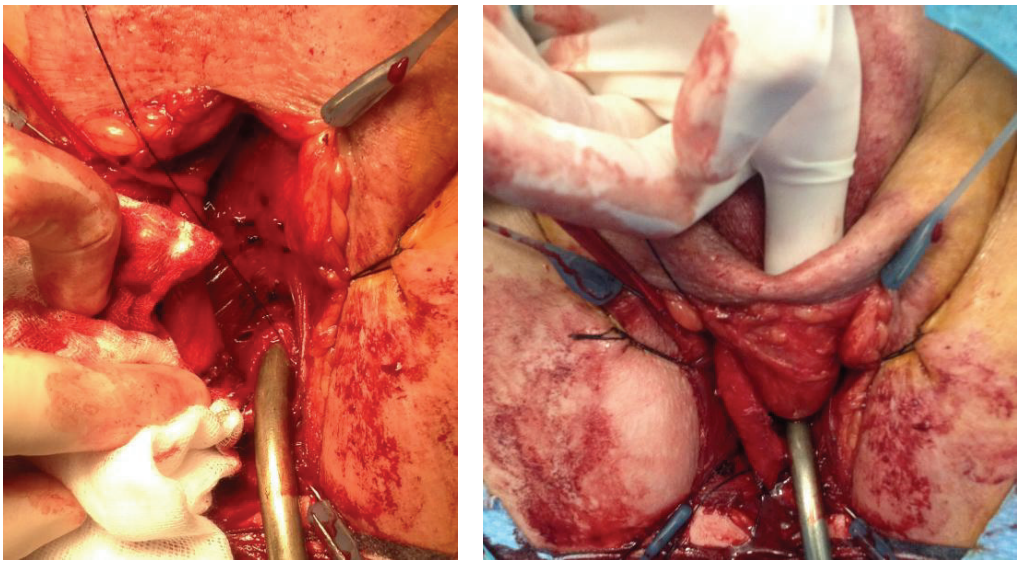

(a) (b)

Figure 1: Technique of Johanson PU. After opening of the proximal urethra (a). Mobilisation of the scrotal skin to the proximal urethra (b).

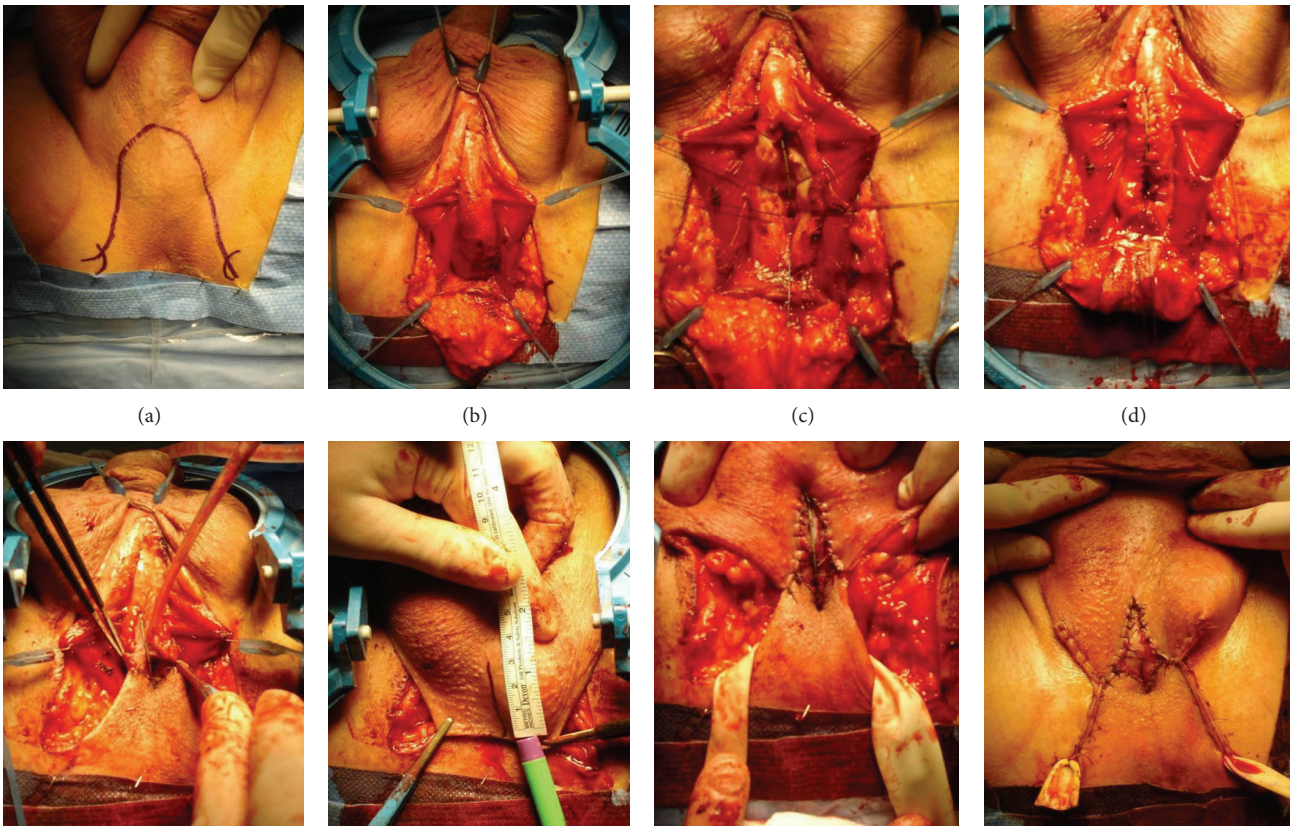

(a) (b) (c) (d)

(e) (f) (g) (h)

Figure 2: Technique of Blandy PU. Inverted-U perineal incision (a). Exposure of the bulbar urethra (b). Opening of the bulbar urethra (c). Hemostatic sutures on the corpus spongiosum and suturing of the tip of the inverted-U flap towards the proximal urethral opening (d). Suturing of the inverted-U flap to the urethral edges (e). Creation of scrotal flaps (f) and advancement to the urethral mucosa (g). Closure of the wound and final result (h).

of a suprapubic catheter. For QoL, analyzed factors were patient's age, stricture etiology, and failure of PU. A P value <0.05 is considered as statistically significant.

3. Results and Discussion

Only 13 (25.5%) patients did not undergo previous urethral interventions. Seven (13.7%) patients underwent at least one urethrotomy and/or dilation. Thirty-one patients (60.8%) underwent at least one previous urethroplasty (with or without urethrotomy/dilation). Ten (19.6%) patients underwent PU after urethrectomy: 3 patients because of urethral malignancy and 7 patients concomitant with penectomy for penile malignancy ($n = 5$) or penile gangrene ($n = 2$).

For the entire cohort, 11 (21.6%) patients suffered a failure. In the Johanson group, 9 (25.7%) patients experienced failure versus 2 (12.5%) patients in the Blandy group ($P = 0.248$) (Table 2). One-year FFS was 86.5% for the entire cohort and 87.3 and 84.8% for the Johanson and Blandy groups, respectively (log-rank $P = 0.904$). The mean time to recurrence was 29.7 months for the Johanson group and 5 months for the Blandy group ($P = 0.415$). In the Johanson group, 3 and 2 failures were treated with VY-plasty and intermittent urethrotomies/dilations, respectively. The remaining 4 failures were treated with a Blandy PU, mesh graft augmented PU, buccal mucosa graft augmented PU, and a 7-flap perineal urethrostomy. The failures in the Blandy group were treated with a mesh graft augmented PU. Eight (15.7%) patients suffered a postoperative complication, with 4 complications reported in each group (Johanson 11.5% versus Blandy 25%; $P = 0.237$). One patient developed urosepsis and was treated with intravenous antibiotics (grade 2). Six patients suffered wound dehiscence treated conservatively with secondary healing in 4 patients (grade 1) and by surgical closure in 2 patients (grade 3b). One patient had a severe postoperative bleeding and needed surgical exploration (grade 3b). The two failures in the Blandy group suffered a postoperative wound dehiscence with secondary healing and this was identified as the cause of failure. For the other failures, no apparent cause could be identified. Compared to the preoperative situation, there was a significant improvement of maximum urinary flow (Q_{max}) (3.1 versus 13.0 mL/s; $P < 0.001$). This improvement remained significant for both groups: from 2.6 to 10.9 mL/s in the Johanson group and from 3.9 to 16 mL/s in the Blandy group.

Of 44 surviving patients, 32 (62.7%) patients sent back the questionnaires (19 and 13 patients after Johanson and Blandy PU, resp.). One patient treated with Johanson PU only answered the QoL questionnaire. Mean postoperative IPSS was 8.7 for the entire cohort. IPSS after Johanson and Blandy PU was, respectively, 10.2 and 6.6 ($P = 0.078$). For the entire cohort, 14 (43.7%), 12 (37.5%), and 6 (18.8%) patients reported, respectively, a satisfactory, acceptable, and dissatisfactory QoL after PU. Four dissatisfied patients had Johanson PU (21.1%) and two had Blandy PU (15.4%). Differences in QoL were not statistically significant between both groups ($P = 0.635$).

Logistic regression analysis could not identify any significant factors that predicted failure of PU (Table 3). Failure of PU tends to predict dissatisfaction with QoL (odds ratio 5.5; 95% CI 0.8–37.6; $P = 0.08$).

Table 2: Surgical and functional outcomes. Values are presented as mean ± standard deviation or number (%).

	Total	Johanson	Blandy	P value
Operation time (min)	102.1 ± 37.3	97.2 ± 33.7	112.6 ± 43.4	0.172°
Failure				
No	40 (78.4%)	26 (74.3%)	14 (87.5%)	0.248§
Yes	11 (21.6%)	9 (25.7%)	2 (12.5%)	
Time to recurrence (months)	31.6 ± 39	29.7 ± 39.2	5.0 ± 2.8	0.415°
Complications				
No	43 (84.3%)	31 (88.6%)	12 (75.0%)	
Grade 1	4 (7.8%)	1 (2.9%)	3 (18.8%)	0.237§
Grade 2	1 (2.0%)	1 (2.9%)	0 (0%)	
Grade 3	3 (5.9%)	2 (5.7%)	1 (6.2%)	
	$n = 26$	$n = 15$	$n = 11$	
Postop Q_{max} (mL/s)	13.0 ± 7.5	10.9 ± 6.3	16.0 ± 8.2	0.087°
	$n = 31$	$n = 18$	$n = 13$	
IPSS (0 → 35)	8.7 ± 5.6	10.2 ± 5.1	6.6 ± 5.8	0.078°
Postvoid dribbling				
Absent	23 (74.2%)	14 (77.8%)	9 (69.2%)	
Present	8 (25.8%)	4 (22.2%)	4 (30.8%)	0.448§
	$n = 32$	$n = 19$	$n = 13$	
QoL				
Satisfied (0 → 2)	14 (43.7%)	7 (36.8%)	7 (53.8%)	
Acceptable (3)	12 (37.5%)	8 (42.1%)	4 (30.8%)	0.635§
Dissatisfied (4 → 6)	6 (18.8%)	4 (21.1%)	2 (15.4%)	

(°Independent samples t-test; §Fisher's exact test.)

Table 3: Univariate logistic regression analysis.

Predictive factor for failure	OR (95%-CI)	P value
Type of operation	0.179 (0.019–1.658)	0.13
Follow-up	1.007 (0.991–1.023)	0.405
Age	0.984 (0.937–1.034)	0.525
Stricture length	1.099 (0.945–1.279)	0.221
Etiology	0.957 (0.530–1.729)	0.885
Previous interventions	0.653 (0.247–1.729)	0.391
Location	0.839 (0.549–2.091)	0.839
Suprapubic catheter	0.243 (0.026–2.272)	0.215

PU is an option to manage complex and/or recurrent urethral strictures [7, 12, 16] and is needed after urethrectomy/penectomy [8, 9]. Nevertheless, success with PU is far from guaranteed as shown by the 21.6% failure rate in this series. This failure rate corresponds well to the 0–30% failure rate reported by other series [7, 10, 11, 16, 17].

Comparison between series is difficult because of differences in follow-up and study population. Peterson et al. reported 100% success [16]. In this series, only 18% of cases underwent prior urethroplasty and stricture etiology was lichen sclerosus which mainly affects the penile urethra. Therefore, PU could be performed at a healthy, unaffected bulbar urethra. These factors probably explain the favorable results in their series. This is in contrast to our series and the series of Barbagli et al. [7], Kulkarni et al. [17], and Myers et al. [11], where, respectively, 60.8%, 52.6%, 96.3%, and 48% of patients underwent one or more urethroplasties. Previous urethroplasty is a well-known risk factor for failure in urethral reconstruction [3, 5, 6]. Indeed, after previous urethroplasty, the urethra is already scarred and of poorer quality and if this segment needs to be used for PU, it can lead to further scarring and narrowing of PU. This is certainly the case in our series where only 23.5% of patients had no involvement of the bulbar urethra, which is incorporated in the PU. This might explain the higher failure rate in our series and the series of Barbagli et al. [7], Kulkarni et al. [17], and Myers et al. [11] In this context, it is important to inform the patient that recurrence after PU is possible, despite the fact that it is offered as the final solution for his complex/recurrent stricture.

Until 2009, Johanson PU was our preferred technique. From 2010, we started with Blandy PU as preferred modality. This has several reasons. (1) In 2009, two major series were published on Blandy PU and currently Blandy PU is the standard technique for PU. So, we started to follow the mainstream in PU, which explains the significant shorter follow-up time with Blandy PU. (2) The Johanson technique has several inconveniences for the patient: the invagination of the scrotal skin is unaesthetic and the patient urinates on the scrotum (Figure 1). (3) We find the Blandy technique easier to perform compared to the Johanson technique. This might be contradictory as the operation time with Blandy technique is longer compared to the Johanson technique. This longer operation time may reflect the learning curve we had to go through with the Blandy technique. Furthermore, during Blandy PU technique, we sutured the edges of the opened corpus spongiosum for hemostasis (Figure 2(d)), which was not performed during Johanson PU. This was the reason for one case of the severe postoperative bleeding in the Johanson group. Because of the significant difference in follow-up for the Johanson and Blandy groups, it is not possible to draw conclusions about possible differences or equalities between both techniques based on these data. However, Blandy PU is now generally considered as the standard technique for PU, and our data suggest that Johanson PU remains an option, especially when Blandy PU is not possible. This is, for instance, the case if the bulbar urethra is approached by a midline perineal incision for urethroplasty and when the peroperative findings make a one-stage reconstruction impossible. In this case, a two-stage procedure or formal PU must be performed. A Blandy PU is no longer possible, since no inverted-U flap is available, but the Johanson technique is still an option. An alternative for this case is a 7-flap perineal urethrostomy [10]. Another case is when the inverted-U flap of the Blandy technique cannot be brought towards the proximal urethra without any tension (e.g., obese patients or stricture extending in the proximal bulbar urethra or membranous urethra). As the scrotal skin is very elastic, it can usually be mobilized even up to the level of the membranous urethra, and, for this case, the Johanson technique can be performed. In our series, both failures in the Blandy group were due to tension at the anastomosis between the urethra and the inverted-U flap with wound dehiscence and subsequent stenosis of the neomeatus. These failures might have been prevented if another technique such as the Johanson technique would have been used. Another option would be to transect the urethra and mobilize the proximal urethral stump towards the perineal incision. This was never performed in this series. Particularly for membranous or deep bulbar strictures, this maneuver will not lead to a substantial gain of length in order to reduce tension with perineal skin flaps. Furthermore, transection of the urethra will eliminate the retrograde blood supply of the proximal urethra. As the majority of patients in our series already underwent previous urethroplasty, we opted to preserve the urethral blood supply as much as possible to avoid ischemic damage to the urethra at which the PU is performed. Myers et al. [11] also postulated that preservation of the urethral blood supply is an important key to success in PU.

In this series, 18.8% of patients were dissatisfied after PU with no significant differences between the two groups. This is higher compared to the 1.2% and 0% dissatisfaction rate in the series of Barbagli et al. [7] and Peterson et al. [16], respectively. Failure of PU tends to predict dissatisfaction. This might explain our higher dissatisfaction rate compared to the series of Peterson et al. [16] where no patients suffered a recurrence. This, however, cannot explain the higher dissatisfaction rate compared to the series of Barbagli et al. [7] with a similar failure rate. For 3 out of 6 dissatisfied patients, there was a specific reason in this series. In one patient, PU was the end point of an iatrogenic stricture after transurethral resection of the prostate. He considered this a serious complication of what he expected to be a simple procedure for benign prostatic hyperplasia [18]. This patient was more dissatisfied with the whole urologic history rather than with PU itself. Two other dissatisfied patients underwent PU after penectomy. In these patients, PU was not a choice but a necessity that was suddenly needed. This is in contrast to patients who have a long history of urethral stricture disease in which PU is often a relief. Most of these patients in our series indeed underwent several urethral manipulations (urethroplasty, urethrotomy, and dilations) or had a suprapubic catheter. For these patients it is a relief to be able to void again, even if this is in a seated position. It is much more likely that these patients will be more satisfied with PU compared to patients after urethrectomy/penectomy who are "condemned" to PU.

This study has several important limitations. It concerns a single-center and retrospective study. The follow-up duration differs significantly between both groups and is on average less than 1 year in the Blandy group. A comparison between both groups is therefore subject to important bias and hard conclusions cannot be made based on these data. With longer follow-up, it is probable that more failures will be detected in the Blandy group, further affecting surgical and functional outcome. Evaluation of the functional outcome

with questionnaires is hampered by 37% of patients who did not return the questionnaire. It is impossible to estimate whether or not more dissatisfied patients have not responded to the invitation to fill in the questionnaire. IPSS is used to score obstructive and irritative symptoms after PU. Although IPSS is frequently used to describe voiding symptoms before and after urethral reconstruction, it is not validated for this pathology and Nuss et al. [19] reported that 21% of patients with urethral stricture disease reported symptoms that were not scored by IPSS. Validated questionnaires for urethral reconstruction are recently developed [20] and should be used in the future for further evaluation. Another limitation is that there are no functional scores available before PU nor is there a control group that remained on suprapubic diversion or repetitive urethral manipulations.

4. Conclusion

About 1 out of 5 patients suffered a recurrence after PU and the patient should be informed about this risk. Although the majority of patients had a satisfactory/acceptable QoL after PU, the dissatisfaction rate in this series is higher than previously reported.

Conflict of Interests

The authors declare no potential conflict of interests with respect to the authorship and/or publication of this paper.

References

[1] R. Santucci and L. Eisenberg, "Urethrotomy has a much lower success rate than previously reported," *The Journal of Urology*, vol. 183, no. 5, pp. 1859–1862, 2010.

[2] K. F. Rourke and G. H. Jordan, "Primary urethral reconstruction: the cost minimized approach to the bulbous urethral stricture," *Journal of Urology*, vol. 173, no. 4, pp. 1206–1210, 2005.

[3] N. Lumen, P. Hoebeke, and W. Oosterlinck, "Urethroplasty for urethral strictures: quality assessment of an in-home algorithm: original article: clinical investigation," *International Journal of Urology*, vol. 17, no. 2, pp. 167–174, 2010.

[4] N. Lumen, P. Hoebeke, E. Deschepper, E. van Laecke, K. de Caestecker, and W. Oosterlinck, "Urethroplasty for failed hypospadias repair: a matched cohort analysis," *Journal of Pediatric Urology*, vol. 7, no. 2, pp. 170–173, 2011.

[5] D. N. Wood, D. E. Andrich, T. J. Greenwell, and A. R. Mundy, "Standing the test of time: the long-term results of urethroplasty," *World Journal of Urology*, vol. 24, no. 3, pp. 250–254, 2006.

[6] B. N. Breyer, J. W. McAninch, J. M. Whitson et al., "Multivariate analysis of risk factors for long-term urethroplasty outcome," *The Journal of Urology*, vol. 183, no. 2, pp. 613–617, 2010.

[7] G. Barbagli, M. De Angelis, G. Romano, and M. Lazzeri, "Clinical outcome and quality of life assessment in patients treated with perineal urethrostomy for anterior urethral stricture disease," *Journal of Urology*, vol. 182, no. 2, pp. 548–557, 2009.

[8] G. Gakis, J. A. Witjes, E. Compérat et al., "EAU guidelines on primary urethral carcinoma," *European Urology*, vol. 64, no. 5, pp. 823–830, 2013.

[9] G. Pizzocaro, F. Algaba, S. Horenblas et al., "EAU penile cancer guidelines 2009," *European Urology*, vol. 57, no. 6, pp. 1002–1012, 2010.

[10] D. French, S. J. Hudak, and A. F. Morey, "The "7-flap" perineal urethrostomy," *Urology*, vol. 77, no. 6, pp. 1487–1489, 2011.

[11] J. B. Myers, S. P. Porten, and J. W. McAninch, "The outcomes of perineal urethrostomy with preservation of the dorsal urethral plate and urethral blood supply," *Urology*, vol. 77, no. 5, pp. 1223–1227, 2011.

[12] W. Oosterlinck, N. Lumen, and G. Van Cauwenberghe, "Surgical treatment of urethral stenoses: technical aspects," *Annales d'Urologie*, vol. 41, no. 4, pp. 173–207, 2007.

[13] B. Johanson, "The reconstruction in stenosis of the male urethra," *Zeitschrift fur Urologie*, vol. 46, pp. 361–375, 1953.

[14] J. P. Blandy, M. Singh, and G. C. Tresidder, "Urethroplasty by scrotal flap for long urethral strictures," *British Journal of Urology*, vol. 40, no. 3, pp. 261–267, 1968.

[15] D. Dindo, N. Demartines, and P.-A. Clavien, "Classification of surgical complications: a new proposal with evaluation in a cohort of 6336 patients and results of a survey," *Annals of Surgery*, vol. 240, no. 2, pp. 205–213, 2004.

[16] A. C. Peterson, E. Palminteri, M. Lazzeri, G. Guanzoni, G. Barbagli, and G. D. Webster, "Heroic measures may not always be justified in extensive urethral stricture due to lichen sclerosus (balanitis xerotica obliterans)," *Urology*, vol. 64, no. 3, pp. 565–568, 2004.

[17] S. Kulkarni, G. Barbagli, D. Kirpekar, F. Mirri, and M. Lazzeri, "Lichen sclerosus of the male genitalia and urethra: surgical options and results in a multicenter international experience with 215 patients," *European Urology*, vol. 55, no. 4, pp. 945–956, 2009.

[18] D. J. Summerton, N. D. Kitrey, N. Lumen, E. Serafetinidis, and N. Djakovic, "EAU Guidelines on iatrogenic trauma," *European Urology*, vol. 62, no. 4, pp. 628–639, 2012.

[19] G. R. Nuss, M. A. Granieri, L. C. Zhao, D. J. Thum, and C. M. Gonzalez, "Presenting symptoms of anterior urethral stricture disease: a disease specific, patient reported questionnaire to measure outcomes," *Journal of Urology*, vol. 187, no. 2, pp. 559–562, 2012.

[20] M. J. Jackson, I. Chaudhury, A. Mangera et al., "A prospective patient-centred evaluation of urethroplasty for anterior urethral stricture using a validated patient-reported outcome measure," *European Urology*, vol. 64, no. 5, pp. 777–782, 2013.

Hindawi Publishing Corporation
BioMed Research International
Volume 2015, Article ID 306191, 4 pages
http://dx.doi.org/10.1155/2015/306191

Clinical Study

Sacrocolpopexy with Polypropylene Tape as Valuable Surgical Modification during Cystectomy with Orthotopic Ileal Bladder: Functional Results

Marcin Życzkowski, Bartosz Muskała, Zbigniew Kaletka, Piotr Bryniarski, Krzysztof Nowakowski, Rafał Bogacki, and Andrzej Paradysz

Department and Clinic of Urology, Medical University of Silesia, 41-800 Katowice, Poland

Correspondence should be addressed to Marcin Życzkowski; mzyczkowski@poczta.onet.pl

Received 24 April 2014; Revised 6 November 2014; Accepted 6 November 2014

Academic Editor: Ralf Herwig

Copyright © 2015 Marcin Życzkowski et al. This is an open access article distributed under the Creative Commons Attribution License, which permits unrestricted use, distribution, and reproduction in any medium, provided the original work is properly cited.

Introduction. Urinary diversion is very often associated with urinary retention and urinary incontinence. In this study, a surgical modification during cystectomy with orthotopic ileal neobladder is presented. *Material and Methods*. Female patients enrolled in the study (n-24) were subjected to sacrocolpopexy during the operation. Apart from oncological control, the follow-up consisted of 1-hour inlay test and questionnaires (UDI-6 and IIQ-7) in the 3rd, 6th, and 12th month after the operation. In the 12th month after the surgery, the urodynamic pressure-flow test was performed. Outcomes were compared with the control group (n-18) in which sacrocolpopexy was not implemented. *Results*. The study group was characterised by reduced urinary retention and improved continence. *Conclusion*. Sacrocolpopexy during cystectomy with orthotopic ileal bladder is a valuable surgical method which provides patients with a better quality of life.

1. Introduction

Bladder cancer is the 9th most frequently occurring cancer among all malignancies. It is found 3-4 times more often in men than in women [1]. About 30% of newly diagnosed bladder cancers are muscle-invasive where the method of choice for treatment is a radical cystectomy [2]. There are many methods of urinary diversion after cystectomy but creating a neobladder is the one which best corresponds to natural anatomical conditions. Unfortunately, in a significant percentage of patients, urinary retention occurs which requires catheterization of the intestinal reservoir. On the other hand, achieving the urinary continence grade being satisfactory for doctors and above all for women who underwent this kind of operation is not always possible. That is why, in order to avoid these complications, there are still attempts to modify already well-tried operation methods or just to introduce new ones. The surgery for pelvic organ prolapse focuses on the restoration of the vaginal anatomy and normal bladder and bowel function [3]. It is proven that this method is superior to other surgical techniques in terms of restoration of the normal vaginal axis and maintenance of vaginal capacity in cases of pelvic organ prolapse [4]. The reinforcement of the pelvic floor seems to be also useful after cystectomy with neobladder creation.

2. Objectives

The aim of this open-label study is the effectiveness assessment of modification of the operation technique during radical cystectomy in the form of sacrocolpopexy with a polypropylene tape.

3. Material and Methods

42 female patients aged 54–66 (average 59,7) with muscle-invasive bladder cancer and qualified for surgical treatment were enrolled in the research. 24 of them were in the study group. The control group consisted of 18 patients (Table 1). A simple randomization was used to divide assigned patients to

Table 1: Preoperative patient's characteristics.

	Study group	Control group	P
Age (years)	59,5	57,7	0,3
T, n (%)			
2a	7 (29)	5 (27)	0,4
2b	3 (12,5)	3 (16,5)	
3a	10 (42)	7 (40)	
3b	4 (16,5)	3 (16,5)	
Grade, n (%)			
LG	4 (16)	3 (16)	0,3
HG	20 (84)	15 (84)	
BMI (kg/cm^2)	21,3	22,1	0,3

T: tumour staging, LG: low grade, HG: high grade, and BMI: Body Mass Index.

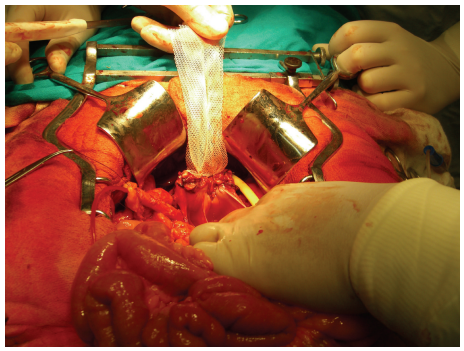

Figure 1: Polypropylene mesh sutured to the vaginal stump.

the two above mentioned groups. All females underwent radical cystectomy. The urinary bladder, uterus with appendages, and anterior vaginal wall were excised. In any case the urinary diversion with Studer ileal bladder was performed. 45 cm long segment of ileum which was 25 cm proximal to the ileocecal valve was used. Ureters were implanted in the proximal part of pouch by a standard end-to-side method using "double J" ureteral stents. Before the anastomosis of enteral pouch with urethra was performed, each patient from the study group underwent sacrocolpopexy with a 8 × 3 cm tape made from a polypropylene mesh Dallop PP TDM KTM designed for the surgical treatment of hernias. A vaginal stump was sutured to promontorium with the mesh making C-shape suture line (Figure 1). The anastomosis of enteral pouch with urethra was performed with 6–10 single sutures.

The females were taken under accurate observation which lasted from 12 to 48 months. The oncological control was routine: chest, abdomen, and pelvis imaging (computed tomography) every 3 to 6 months for 2 years based on the risk of recurrence. Particular attention was paid to functional outcomes of urinary drainage with an ileal neobladder, especially to evaluate urinary retention grade and urinary incontinence. A follow-up planned for the first 12 months after the operation proceeded as follows: a one-hour inlay test, UDI-6 (Urinary Distress Inventory) and IIQ-7 (Incontinence Impact Questionnaire) questionnaires were performed in the 3rd, 6th, and 12th month after the operation. The inlay test was performed as follows: patients were asked to empty their bladders and to drink 500 mL of water in 15 minutes. After a 30-minute rest they performed similar activities: climbing stairs, walking, and coughing. The test was defined as positive if the urine loss was greater than 2 grams (pad weighed before and after the test). Urodynamic study in the form of pressure-flow study by means of Medtronic Duet G2 device was performed in the 12th month.

All data was checked for normality with Kolmogorov-Smirnov test. For analysis of continuous variables without normal distribution nonparametric Mann-Whitney U test was used. For analysis of categorical variables chi-square was used. Statistical examination was conducted with the aid of Statistica Statsoft v 9.0. P values <5% were considered statistically significant.

4. Results

Serious postoperative complications were not observed among patients from the examined group. In 4 patients there was prolonged urinary leakage and in 4 female patients postoperative ileus lasting over 5 days occurred. None of the females needed reoperation due to complications. With regard to lymph node metastases, the adjuvant chemotherapy was applied in 6 female patients. The average result of the UDI-6 questionnaire in the 3rd, 6th, and 12th month was, respectively, 2,0, 1,5, and 0,83. The average result of IIQ-7 questionnaire in the 3rd, 6th, and 12th month was, respectively, 1,5, 0,9, and 0,57. A one-hour inlay test in the 3rd, 6th, and 12th month of observation was negative in, respectively, 75% (n-18), 87,5% (n-21), and 91,6% (n-22) of patients. Urodynamic study was performed in the 12th month of observation in 20 female patients. The average cystometric capacity of a neobladder was 471 mL (350–576). All created neobladders were characterized by low intravesical pressure (mean 17,4 cm H_2O). Slight urinary leakage while coughing was observed in 10% (n-2) of females with abdominal leak point pressure (ALPP) > 90 cm H_2O). Only one of the operated female patients needed clean intermittent catheterization (CIC) due to the large amount of urinary retention after the micturition (400 mL). In the rest of 23 patients, the capacity of urinary retention after the micturition was about 65 mL (Tables 2, 3, and 4).

The results in the control group were as follows: the average result of the UDI-6 questionnaire in the 3rd, 6th, and 12th month was 2,9, 2,5, and 1,4, respectively. The average result of IIQ-7 questionnaire in the 3rd, 6th, and 12th month was, respectively, 2,5, 2,0, and 1,9. The inlay test in the 3rd, 6th, and 12th month was negative in 44% (n-8), 61% (n-11), and 67% (n-12) of female patients. In the urodynamic study performed in the 12th month of observation, the average cystometric capacity of a neobladder was 450 mL. Mean intravesical pressure by maximal cystometric capacity was 18 cm H_2O. Positive coughing test occurred in 60% (n-12) of female patients with ALPP > 90 cm H_2O. 10 patients (41,6%) needed CIC. The average urinary retention after the micturition was 184 mL.

Table 2: Postoperative 1-hour inlay test results.

	Study group	Control group	P
1-hour inlay test at 1st month, n (%)			
Negative	18 (75)	8 (44,4)	0,03
Positive	6 (25)	10 (55,6)	
1-hour inlay test at 6thmonth, n (%)			
Negative	21 (87,5)	11 (61)	0,02
Positive	3 (12,5)	7 (39)	
1-hour inlay test at 12th month, n (%)			
Negative	22 (91,7)	12 (67)	0,003
Positive	2 (8,3)	6 (33)	

Table 3: Quality of life parameters after surgery (UDI-6 and IIQ-7 questionnaires results).

	Study group	Control group	P
UDI-6 score (avg.) at months			
3	2,0 ± 0,29	2,9 ± 0,25	
6	1,5 ± 0,1	2,5 ± 0,2	0,02
12	0,8 ± 0,05	1,4 ± 0,1	
IIQ-7 score (avg.) at months			
3	1,5 ± 0,2	2,5 ± 0,21	
6	0,9 ± 0,11	2,0 ± 0,12	0,002
12	0,57 ± 0,1	1,8 ± 0,15	

UDI-6: Urogenital Distress Inventory and IIQ-7: Incontinence Impact Questionnaire.

Table 4: Urodynamic parameters after surgery (pressure-flow study).

	Study group	Control group	P
Average cystometric capacity (mL)	471 ± 20,3	452 ± 23,1	0,3
Average pressure at max capacity (cmH_2O)	17,4 ± 3,6	18 ± 3,1	0,3
ALPP >90 cm H_2O positive, n (%)	2 (8,3)	12 (66,7)	0,03
Average PVR (mL)	65 ± 10,3	184 ± 15,1	0,04

ALPP: abdominal leak point pressure and PVR: postvoid residual volume.

Statistical significance was observed in the following values:

(i) a 1-hour inlay test questionnaire in the 3rd (P-0,03), 6th (P-0,02), and 12th month (0,003),

(ii) UDI-6 in the 3rd, 6th, and 12th month (P-0,002),

(iii) IIQ-7 in the 3rd, 6th, and 12th month (P-0,002),

(iv) incidence of positive ALPP > 90 cm H_2O in pressure-flow study (P-0,003),

(v) postvoid residual volume (P-0,04).

5. Discussion

The bladder cancer is the second most frequently occurring urinary system neoplasm. The cancer deriving from urothelium is the most common histological subtype constituting 90% of cases. The gold standard of treatment of the muscle-invasive bladder cancer is a radical cystectomy.

The proper selection of the method of urinary diversion in patients after cystectomy is one of the biggest challenges for urologists to deal with. Besides oncological radicality, the essence of the operation is to provide the patients with as good quality of life as possible. There are many kinds of neobladders using various segments of the digestive tract: from the small intestine to the sigmoid. None of them has significant advantage over the others with regard to providing patients the best quality of life [5].

The essence of a good functional result of a neobladder is effective bladder emptying and retained continence. According to some authors, sparing of sympathetic innervation during the cystectomy may be crucial to preserve urinary continence [6, 7]. Other authors claim that preserving the continence is still possible even if the autonomic innervation was not spared. In this case, the key to a good functional result is a delicate dissection of rhabdosphincter surroundings and preserving the pudendal innervation [8].

The Studer neobladder is an enteral pouch with good functional results [9]. It is said that patients with urinary diversion carried out by this method are characterized by total urinary continence in daytime in about 90% of cases [10]. Nocturnal incontinence takes place more often as it is about 60% [11]. A gradual improvement of continence proceeds from 6 to 12 months after creating a neobladder. Evaluation and potential therapy of urinary incontinence should be performed after the period in which the neobladder reaches its effective capacity.

The crucial problem concerning the effectiveness of a neobladder is urinary retention which constitutes the reason for recurrent urinary tract infections and urinary calculi formation. It is estimated that the necessity of clean intermittent catheterization (CIC) in patients with a neobladder made from the small intestine occurs in 20–70% of cases [12, 13] In most cases, the reason for ineffective emptying of neobladder in women is its anatomical factors in the form of neobladder folding and its displacement towards the back of pelvis. The reduction of the percentage of patients with urinary retention can be achieved by various modifications in the course of operation.

It is reported that the shorter segment of the small intestine (<40 cm), used in order to create a neobladder, results in the lower percentage of patients who need CIC [14]. The same effect may be observed in the patients who underwent sacrocolpopexy with or without a polypropylene tape. The short-term success rates of this method are reaching 90% in case of pelvic organ prolapse [4]. The abdominal

sacral colpopexy comprises interposition of a synthetic mesh between the vagina and sacrum. This technique allows for more support of the vagina and distribution of tension over a larger surface area [15]. The attachment of vaginal stump to promontorium preserves the adequate axis of the neobladder.

The omental flap is also an effective surgical manoeuvre which ensures neobladder firmness. Comparing results in study and control group, this research proves that sacrocolpopexy during cystectomy significantly improves functional outcomes of urinary diversion in the form of less frequent and severe urinary retention and better diurnal continence.

6. Conclusions

Conclusions are drawn as follows.

(i) Fixation of vagina stump to promontorium is a simple method leading to stabilisation and reinforcement of the new-formed bladder neck.

(ii) Sacrocolpopexy in patients after cystectomy with orthotopic ileal bladder is a valuable operative modification which clearly ameliorates functioning of the neobladder: reduces the postvoid residual volume and decreases necessity of CIC.

(iii) It is possible that this mechanism, besides gentle preparing of urethral sphincter surroundings, significantly leads to continence improvement.

(iv) Presented method requires further observation and investigation based on greater number of cases.

Conflict of Interests

The authors declare that there is no conflict of interests regarding the publication of this paper.

References

[1] M. Ploeg, K. K. H. Aben, and L. A. Kiemeney, "The present and future burden of urinary bladder cancer in the world," *World Journal of Urology*, vol. 27, no. 3, pp. 289–293, 2009.

[2] R. E. Hautmann, H. Abol-Enein, K. Hafez et al., "Urinary diversion," *Urology*, vol. 69, no. 1, supplement, pp. 17–49, 2007.

[3] A.-L. W. M. Coolen, A. M. J. van Oudheusden, H. W. F. van Eijndhoven et al., "A comparison of complications between open abdominal sacrocolpopexy and laparoscopic sacrocolpopexy for the treatment of vault prolapse," *Obstetrics and Gynecology International*, vol. 2013, Article ID 528636, 7 pages, 2013.

[4] A. Uzoma and K. A. Farag, "Vaginal vault prolapse," *Obstetrics and Gynecology International*, vol. 2009, Article ID 275621, 9 pages, 2009.

[5] E. W. Gerharz, Å. Månsson, S. Hunt, E. C. Skinner, and W. Månsson, "Quality of life after cystectomy and urinary diversion: an evidence based analysis," *The Journal of Urology*, vol. 174, no. 5, pp. 1729–1736, 2005.

[6] N. Bhatta Dhar, T. M. Kessler, R. D. Mills, F. Burkhard, and U. E. Studer, "Nerve-sparing radical cystectomy and orthotopic bladder replacement in female patients," *European Urology*, vol. 52, no. 4, pp. 1006–1014, 2007.

[7] W. H. Turner, H. Danuser, K. Moehrle, and U. E. Studer, "The effect of nerve sparing cystectomy technique on postoperative continence after orthotopic bladder substitution," *Journal of Urology*, vol. 158, no. 6, pp. 2118–2122, 1997.

[8] B. Ali-El-Dein, M. Gomha, and M. A. Ghoneim, "Critical evaluation of the problem of chronic urinary retention after orthotopic bladder substitution in women," *The Journal of Urology*, vol. 168, no. 2, pp. 587–592, 2002.

[9] B. P. Schrier, M. P. Laguna, F. van der Pal, S. Isorna, and J. A. Witjes, "Comparison of orthotopic sigmoid and ileal neobladders: continence and urodynamic parameters," *European Urology*, vol. 47, no. 5, pp. 679–685, 2005.

[10] U. E. Studer, H. Danuser, W. Hochreiter, J. P. Springer, W. H. Turner, and E. J. Zingg, "Summary of 10 years' experience with an ileal low-pressure bladder substitute combined with an afferent tubular isoperistaltic segment," *World Journal of Urology*, vol. 14, no. 1, pp. 29–39, 1996.

[11] C. F. Granberg, S. A. Boorjian, P. L. Crispen et al., "Functional and oncological outcomes after orthotopic neobladder reconstruction in women," *BJU International*, vol. 102, no. 11, pp. 1551–1555, 2008.

[12] R. E. Hautmann, "The ileal neobladder to the female urethra," *Urologic Clinics of North America*, vol. 24, no. 4, pp. 827–835, 1997.

[13] R. E. Hautmann, T. Paiss, and R. de Petriconi, "The ileal neobladder in women: 9 years of experience with 18 patients," *Journal of Urology*, vol. 155, no. 1, pp. 76–81, 1996.

[14] L. J. Nesrallah, F. G. Almeida, M. F. Dall'Oglio, A. J. Nesrallah, and M. Srougi, "Experience with the orthotopic ileal neobladder in women: a mid-term follow-up," *BJU International*, vol. 95, no. 7, pp. 1045–1047, 2005.

[15] N. Y. Siddiqui and A. L. Edenfield, "Clinical challenges in the management of vaginal prolapse," *International Journal of Women's Health*, vol. 6, no. 1, pp. 83–94, 2014.

Hindawi Publishing Corporation
BioMed Research International
Volume 2014, Article ID 375285, 6 pages
http://dx.doi.org/10.1155/2014/375285

Review Article

Traumatic Penile Injury: From Circumcision Injury to Penile Amputation

Jae Heon Kim,[1] Jae Young Park,[2] and Yun Seob Song[1]

[1] *Department of Urology, Soonchunyang University Hospital, College of Medicine, Soonchunhyang University, Seoul, Republic of Korea*
[2] *Department of Urology, Korea University Ansan Hospital, Korea University College of Medicine, Ansan, Republic of Korea*

Correspondence should be addressed to Jae Young Park; jaeyoungpark@korea.ac.kr and Yun Seob Song; yssong@schmc.ac.kr

Received 24 April 2014; Revised 16 August 2014; Accepted 16 August 2014; Published 28 August 2014

Academic Editor: Ralf Herwig

Copyright © 2014 Jae Heon Kim et al. This is an open access article distributed under the Creative Commons Attribution License, which permits unrestricted use, distribution, and reproduction in any medium, provided the original work is properly cited.

The treatment of external genitalia trauma is diverse according to the nature of trauma and injured anatomic site. The classification of trauma is important to establish a strategy of treatment; however, to date there has been less effort to make a classification for trauma of external genitalia. The classification of external trauma in male could be established by the nature of injury mechanism or anatomic site: accidental versus self-mutilation injury and penis versus penis plus scrotum or perineum. Accidental injury covers large portion of external genitalia trauma because of high prevalence and severity of this disease. The aim of this study is to summarize the mechanism and treatment of the traumatic injury of penis. This study is the first review describing the issue.

1. Introduction

Among the hospitalized patients, the admission rate of genitourinary trauma patients has been assumed to be 2–10% and one-third or two-thirds of them were found to have the injury on external genitalia [1]. Male is prone to have external genitalia more frequently than female because the male is more exposed to violence or extreme exercise [1].

External genitalia injury can be categorized as accidental in origin including during circumcision and as other traumatic origins including animal bite, gunshots, or self-mutilation [2]. Most injuries of the male genitalia include penetrating injury with foreign bodies owing to psychiatric illness and abnormal sexual behaviors [3].

In this study, we reviewed the traumatic injury of external genitalia in male by describing diverse traumatic nature of the injury. This issue has never been reviewed before.

2. Etiologies and Classifications

To date, there is no standard classification for external genitalia injury. Main reasons for this include the diverse natures of injury mechanism and various anatomical landmarks. Rashid et al. reported the classification of male genitalia injury by anatomical location [4]. Type I injury includes distal portion of the penis with proximal part of the penis being preserved. Type II injury includes severe injury on shaft of penis with penile crus being preserved. Type III injury includes the injury when urethral catheterization is necessary with external urethral part being preserved. Type IV injury includes the injury when suprapubic cystostomy is needed [4]. However, this classification could not reflect the nature of injury mechanism such as penetrating or strangulation injury. The other classification for male external genitalia could be suggested as adult or pediatric injury, iatrogenic. In this report, authors suggest the classification by pediatric and adult injury and also including self-mutilation injury. For detailed etiologies, there are circumcision injury, animal bite injury, strangulation injury, penetration injury, zipper injury, and penile fracture and self-mutilation injury.

2.1. Pediatric Injury. Pediatric injury of penis includes circumcision injury, animal bite injury, and zipper injury. Reports of penile injury in the pediatric population are sporadic and often related with sexual abuse. Most reports about the pediatric penile injury were based on a small number of cases [5–11].

The types and severity of nonsexual pediatric penile injury vary from a small injury to total emasculation. Owing to their rarity and disparity there is no universal therapeutic strategy in their management.

The etiologies for pediatric penile injury are different from that of adult penile injury [6–11]. El-Bahnasawy and El-Sherbiny reported the pediatric penile injury in large population group of 64 patients [5]. The most common cause was circumcision (63%), followed by hair-tie strangulation. The most common sequel after replantation was the loss of the coronal sulcus, in which buccal graft has been used with the successful outcome [12].

2.1.1. Circumcision Injury. Circumcision is one of the most common operations in urology, which is usually a safe and simple procedure with low morbidity. However, serious complications can occur because unprofessional practice performs it [13]. The penile injury from circumcision is diverse: from infections to disfigurement or partial to total amputation of the penis.

Gee et al. reported the postoperative complication rate as 0.2–0.6%, which ranges from bleeding, lymphedema, fistula formation, and iatrogenic hypospadias to the partial or complete amputation of the glans penis [14, 15]. El-Bahnasawy and El-Sherbiny [5] reported the largest series of pediatric penile injury. Sixty-four boys with penile injury were hospitalized over 20 years and among them 43 boys (67%) had penile injury caused by circumcision.

Although circumcision is regarded as a minor surgical procedure, it is not free of complications. Urologists have to pay more attention to reducing the complication by circumcision. Penile injury by circumcision also can have lifetime functional, psychological, and cosmetic sequel.

2.1.2. Animal Bite Injury. The sequel of penile injury by animal bite is related with initial severity of the wound. Pediatrics has more tendencies to be exposed to animal bite injury, of which the most common cause is a dog bite [16]. Although most of the injuries are not severe condition, total or nearly total amputation of penis is being reported [17]. Nowadays, infective complications occur less because most wounds are initially treated properly with antibiotics [18]. Initial treatment strategy includes sufficient clean irrigation, excision of infective wound, and administration of broad spectrum antibiotics [19]. In some cases, vaccination against tetanus and rabies is needed [1, 18, 19].

2.1.3. Zipper Injury. Penile zipper injury occurs most commonly in boys with phimosis; in particular it occurs when the redundant foreskin gets entrapped during hastened dressing or undressing. Entrapment of the foreskin within the zipper itself is the most problematic condition [20]. Most of the cases are detected in an earlier stage of trauma but in rare cases, delayed presentation and comorbidities may worsen the treatment outcome.

Penile zipper injury is a challenging management disease, especially when the injured penis is complicated by medical comorbidities. Delayed disease includes the edema and infection of entrapped skin, which complicates the treatment [9].

Various methods of zipper removal have been described including both surgical and nonsurgical methods. Documented methods are manual disengagement of the zipper with lubrication [21], cutting the median bar with bone cutter or hacksaw [20, 22], dismantling the fastener [23–25], or removal of the entrapped skin [26, 27].

2.2. Adult Injury. Most of adult penile injuries are penile fracture and other causes include strangulation injury and penetrating injury.

2.2.1. Penile Fracture. Penile fracture is a rupture of the tunica albuginea, which is the outer membrane of the penile corpora cavernosum, occurring during penile erection. The etiology of this injury can be divided into two parts: sexual and nonsexual causes. The primary mechanism of this injury is an abrupt, blunt trauma by forceful bending of the erect penis over the pubic bone or perineum [28]. For sexual causes, vigorous intercourse and masturbation were reported [28–30] and, for nonsexual causes, falling off from bed, placing an erect penis in the underwear, and spontaneous fracture during urination were reported [28–31]. Most penile fractures are underreported because of culture issues.

Penile fracture could be diagnosed based on clinical presentation and physical examination. It rarely needs radiologic evaluation except in cases with gross hematuria that requires retrograde urethrography [32, 33]. Physical examination reveals swelling of the penile shaft with eggplant deformity, discoloration, and deviation of the penile shaft. In cases when the hematoma is contained within Buck's fascia, the rolling sign which is a palpable clot felt direct over the tear in the tunica albuginea could be manifested [30]. Surgical exploration warranted when penile fracture is suspected because either clinically or radiologically penile fracture could not be excluded [34]. If the depth of injury extended into Buck's fascia, bloody discharge can extravagate into the subcutaneous plane of the scrotum, perineum, or pubic areas, resulting in significant swelling with discoloration. Concomitant urethral injuries have been reported to be 3% to 38 [35]. Total urethral rupture also could happen and its rate is up to 2.32%, which needs end to end urethral anastomosis [29].

The location of the fractured site is usually transverse and unilateral in nature [36]. There could be many complications such as erectile dysfunction and urethral stricture, which depends on the time interval since initial injury [36]. Many reports support the immediate surgical repair offers, which yield better long-term results than conservative treatment [33–36]. The current standard treatment for penile fracture is immediate surgical repair, because of low rate of subsequent morbidity. Immediate surgical repair results in an excellent outcome in sexual behavior among 90% of patients [37].

During surgical repair of penile rupture, urethral catheterization could facilitate anatomical orientation, which makes easier discrimination from a large hematoma [37].

2.2.2. Strangulation Injury. Penile strangulation is not common and only a few reports have been published up to now. Most common cause for penile strangulation is foreign body object which compress circumferentially by metallic or nonmetallic material. Nonmetallic and thin objects are easy to remove. The causing objects for penile strangulation documented are usually heavy metal rings, hammer-head, and plastic bottle neck, sprockets, or plumbing cuff [38]. Metal objects are relatively difficult to remove and to cut the metal objects is the most common method documented [38, 39]. However, in real practice, most medical facilities are not equipped with appropriate cutting machine. Furthermore, cutting the metallic object is a time-consuming process [38]. Cutting tools described are an iron saw, orthopedic equipment, and a high-speed diamond-tipped dental drill [40, 41].

Other methods to solve the penile strangulation include aspiration method and delving method [42]. Another useful method is using a string with a glandular puncture, which is easier and quicker than the previous methods [40, 41]. However, in cases of combining with the foreskin edema, decompression with puncture both on foreskin and glandular lesion should be performed [40, 41].

2.2.3. Penetrating Injury. Among the penetrated injured sites by foreign body, urethra is the most common involved site besides areas of the penis including penile skin, glans, and corpus cavernosum [43].

The main reason for penetrating injury into penis is self-insertion of foreign body on purpose of sexual eroticism [44]. Most cases of penetrating injury in penis can be diagnosed through physical examination and retrograde urethrography; computed tomography or ultrasound test is seldom necessary [45]. Various foreign bodies, such as a screw, a wire, and a safety pin, have reported in the urethra [46]. The most appropriate method for removing the penetrated international body depends on the size and depth of penetration of the material.

3. Psychiatric Impact

Total penile amputation is an uncommon penile injury [47, 48]. However, about 87% of the patients reported had psychiatric problems. Self-amputation of the penis is known as Klingsor syndrome [47, 49]. The extent of self-mutilation varies in its severity from supericial injury to total amputation or total emasculation [50, 51]. Klingsor syndrome is a disease of self-mutilation by a psychiatric patient, often suffering from religious delusions [50–52].

These psychiatric patients have paranoid schizophrenia along with command hallucinations [51, 53]. This disease is a urological emergency, which requires urgent surgical corrections because the associated hemorrhage can be torrential and life threatening.

Genital self-mutilation injury has a common connotation with eating behavior disorders such as anorexia and bulimia. Self-mutilation is a way of expressing and dealing with deep distress, anger, dissociation, and emotional pain to have self-purification [54]. However, self-purification by self-mutilation does not last very long [54].

Large et al. [55] suggest that one of the primary causes for major self-mutilation is the individual's first psychotic break. In cases with schizophrenia, the degree of injury extent can be rather bizarre and potentially very harmful. Patients with schizophrenia are known to attempt self-mutilation due to command hallucination, catatonic excitement, or associated depression [24].

Genital injury by self-mutilation involves injury to the penis, the scrotum, and the testicles. The type of injury varies from simple skin laceration to total amputation of the penis and testis.

4. Treatment

The first case with macroscopic penile replantation was reported in 1929 by Ehrlich [47]. Cohen et al. reported the first microvascular replantation of penis in 1977. Approximately more than 70% of cases were treated with macroscopic replantation since 1970.

The distal penile stump has no circulation because the arterial supply consists of the branches of pudenda artery, dorsal artery, deep artery, bulbourethral artery, and accessory pudenda artery. Variation is present in the origin, distribution, and symmetry of these arteries.

Replantation of a penile stump without reestablishing the arterial blood site could be regarded as a graft. Hence it should survive by imbibition, obtaining nutrients from the adjacent graft by diffusion [56]. Graft is successful method because the dorsal and urethral arteries represent an excellent source of vascularity to the glans and corpus spongiosum [57].

Without vascular reestablishing the arterial blood supply, the circulation ater macroscopic repair could be reestablished through the spongy tissue of the penis as a graft [58].

This microsurgical replantation of the penis depends on corporal sinusoidal blood flow, which could act as diffusion for the composite graft. However, by this process complications of skin necrosis, fistula formation, loss of sensations, and erectile dysfunction have been reported [47].

The current concept of treatment choice is microvascular replantation for penile amputation because it yields better cosmetic restoration, physiological micturition, preservation of sensation, and erectile function.

The development of microsurgical techniques has improved the rate of successful clinical outcome regarding the penile replantation [59]. This method also has some weak point that it is not always possible to identify deep dorsal arteries, veins, or nerves in pediatric patients [56]. Furthermore, this procedure requires special equipment, instruments, and training, which are not always available in generalized hospital.

Belinky et al. invented a method to use the distal urethra to cover the distal unroofed corpus cavernosum, but this process requires a relatively healthy urethra and long penile stump to obtain satisfactory sexual and cosmetic result [60]. Mazza et al. developed a two-stage technique using a scrotal fasciocutaneous flap, which is tubularized and sutured to the

distal end of the penis. This process provides good cosmetic results but has some shortcomings like higher expense due to two-stage operation and a high rate of metal stenosis [61]. Buckle mucosa could be used to reconstruct the distal parts of the cavernosum but this method has a tendency to have contractures [62].

Pediatric phalloplasty has some controversies including the indication about the age, size, and, especially, neophallic growth during puberty [1]. Performing penis reconstruction in childhood is crucial to minimize the emotional impact by this surgery because normal like appearance is important for children especially during puberty to prevent emotional stress and to achieve favorable genital identity [63].

5. Complications

Superficial or partial penile injury can be treated with suturing and wound dressing after exploration. More extensive injuries including urethral and corpus cavernous can be treated by free transfer flaps and different grafts. Penile amputation, whether it is partial or total, requires complex and skilled reconstructive techniques including phalloplasty [12, 64, 65].

Expeditious and prudent postoperative care is needed to avoid delayed complications such as infection, curvature, erectile dysfunction, unrecognized urethral injury, and chronic pain. Severe penile injury might be associated with adjacent comorbidity involving the scrotum, pelvis, buttocks, and thighs. In these scenarios, delicate surgical skill with staged treatment is needed [5].

The aim of the reconstruction in penile injury is to embody an esthetically acceptable shape, to obtain normal or near normal functional outcomes including erection and sensation, and to minimize the postoperative sequel including fistulae or urethral strictures.

6. Comment

Owing to the specific location and mobility of penis, severe injury on penis is rare. The severity of penile injury could be judged by the depth of the penis: glans or penile skin, corpus cavernosum, and urethra. However, in cases of inatrogenic injury, severe injuries could be often observed. Furthermore, although the penis has mobility and protected by direct trauma due to its particular area, it is more prone to injury in erection state [66, 67].

During erection state, tunica albuginea becomes thinner, and it is highly susceptible to penile injury. The mean arterial pressure of corpus cavernosum during erection is 100 mmHg. To overcome the tensile strength to be ruptured, mean arterial pressure is needed to be over 1500 mmHg [68].

To reduce the possibility of the sequel such as devastating deformities such as deviation or shortened penis and functional impairment, these patients have to be treated by expert surgeons as soon as possible severe penile is injury can be defined when patients have two or more injury of the following components: penile skin, glans, corpora cavernous, and urethra.

The location of the amputated site is very critical landmark for treatment strategy in managing penile amputation. When the amputation occurs at the shaft of the penis, microvascular replantation is recommended. Most amputations are less documented because those injuries are repaired immediately. The glans amputation could be successfully reattached if it is managed within eight hours [69]. However, if the injury happens to be detected even after eight hours, the stump could be connected successfully resulting in favorable cosmetic and functional results [69, 70]. There have been many techniques for glans reconstruction after complete or partial amputation.

Recently, Faydaci et al. reported the successful outcome of treatment in penis amputation by circumcision [71]. They performed hyperbaric oxygen therapy after primary anastomosis. Considering that oxygen plays an important role for wound healing, hyperbaric oxygen therapy can increase the angiogenesis and stimulate the proliferation of fibroblast [72].

7. Conclusion

To date, there are no specific guidelines for the treatment of severe penile injury because the injury mechanism is a complex and multifaceted subject. In this review, authors have described the various penile injuries, which have relatively higher incidence. Physicians have to keep in mind that the goal of treatment of penile injury is to achieve normal-like appearance, reduce functional damage such as erectile dysfunction and sensory loss, and minimize the postoperative sequel. Furthermore, pediatric penile injury has to be approached with delicate and prudent care plan.

Conflict of Interests

The authors declare that there is no conflict of interests regarding the publication of this paper.

Acknowledgments

This work was supported by the National Research Foundation of Korea (NRF) Grant funded by the Korea government (MSIP) (no. 2011-0020128) and by Soonchunhyang University Research Fund.

References

[1] N. P. E. Djakovic, L. Martinez-Pineiro, T. Lynch, Y. Mor, and R. Santucci, *Guidelines on Urological Trauma*, EAU Guidelines, 2009.

[2] S. V. Perovic, R. P. Djinovic, M. Z. Bumbasirevic, R. A. Santucci, M. L. Djordjevic, and D. Kourbatov, "Severe penile injuries: a problem of severity and reconstruction," *BJU International*, vol. 104, no. 5, pp. 676–687, 2009.

[3] S. J. Moon, D. H. Kim, J. H. Chung et al., "Unusual foreign bodies in the urinary bladder and urethra due to autoerotism," *International Neurourology Journal*, vol. 14, no. 3, pp. 186–189, 2010.

[4] M. Rashid and S. Sarwar, "Avulsion injuries of the male external genitalia: classification and reconstruction with the customised

radial forearm free flap," *British Journal of Plastic Surgery*, vol. 58, no. 5, pp. 585–592, 2005.

[5] M. S. El-Bahnasawy and M. T. El-Sherbiny, "Paediatric penile trauma," *BJU International*, vol. 90, no. 1, pp. 92–96, 2002.

[6] J. P. Gearhart and J. A. Rock, "Total ablation of the penis after circumcision with electrocautery: a method of management and long-term followup," *Journal of Urology*, vol. 142, no. 3, pp. 799–801, 1989.

[7] G. R. Gluckman, M. L. Stoller, M. M. Jacobs, and B. A. Kogan, "Newborn penile glans amputation during circumcision and successful reattachment," *Journal of Urology*, vol. 153, part 1, no. 3, pp. 778–779, 1995.

[8] D. J. Katz, W. Chin, S. Appu et al., "Novel extraction technique to remove a penile constriction device," *The Journal of Sexual Medicine*, vol. 9, no. 3, pp. 937–940, 2012.

[9] L. B. Mellick, "Wire cutters and penis skin entrapped by zipper sliders," *Pediatric Emergency Care*, vol. 27, no. 5, pp. 451–452, 2011.

[10] B. Ochoa, "Trauma of the external genitalia in children: amputation of the penis and emasculation," *The Journal of Urology*, vol. 160, no. 3, part 2, pp. 1116–1119, 1998.

[11] E. E. Widni, M. E. Höllwarth, and A. K. Saxena, "Analysis of nonsexual injuries of the male genitals in children and adolescents," *Acta Paediatrica*, vol. 100, no. 4, pp. 590–593, 2011.

[12] A. Cook, A. E. Khoury, D. J. Bagli, W. A. Farhat, and J. L. Pippi Salle, "Use of buccal mucosa to simulate the coronal sulcus after traumatic penile amputation," *Urology*, vol. 66, no. 5, pp. 1109.e7–1109.e8, 2005.

[13] S. D. Niku, J. A. Stock, and G. W. Kaplan, "Neonatal circumcision," *Urologic Clinics of North America*, vol. 22, no. 1, pp. 57–65, 1995.

[14] W. F. Gee and J. S. Ansell, "Neonatal circumcision: a ten year overview: with comparison of the Gomco clamp and the Plastibell," *Pediatrics*, vol. 58, no. 6, pp. 824–827, 1976.

[15] T. E. Wiswell, H. L. Tencer, C. A. Welch, and J. L. Chamberlain, "Circumcision in children beyond the neonatal period," *Pediatrics*, vol. 92, no. 6, pp. 791–793, 1993.

[16] C. M. Gomes, L. Ribeiro-Filho, A. M. Giron, A. I. Mitre, E. R. R. Figueira, and S. Arap, "Genital trauma due to animal bites," *Journal of Urology*, vol. 165, no. 1, pp. 80–83, 2001.

[17] G. Selvaggi, C. Dhejne, M. Landen, and A. Elander, "The 2011 WPATH standards of care and penile reconstruction in female-to-male transsexual individuals," *Advances in Urology*, vol. 2012, Article ID 581712, 13 pages, 2012.

[18] A. F. Morey and T. A. Rozanski, "Genital and lower urinary tract trauma," in *Campbell-Walsh Urology*, A. R. Wein, L. R. Kavoussi, A. C. Novick et al., Eds., pp. 2649–2655, WB Saunders, Philadelphia, Pa, USA, 9th edition, 2007.

[19] J. M. Cummings and J. A. Boullier, "Scrotal dog bites," *The Journal of Urology*, vol. 164, no. 1, pp. 57–58, 2000.

[20] R. T. Strait, "A novel method for removal of penile zipper entrapment," *Pediatric Emergency Care*, vol. 15, no. 6, pp. 412–413, 1999.

[21] J. T. Kanegaye and N. Schonfeld, "Penile zipper entrapment: a simple and less threatening approach using mineral oil," *Pediatric Emergency Care*, vol. 9, no. 2, pp. 90–91, 1993.

[22] R. Flowerdew, I. J. Fishman, and B. M. Churchill, "Management of penile zipper injury," *The Journal of Urology*, vol. 117, no. 5, p. 671, 1977.

[23] P. A. McCann, "Case report: a novel solution to penile zipper injury: the needle holder," *TheScientificWorldJournal*, vol. 5, pp. 298–299, 2005.

[24] S. Aboseif, R. Gomez, and J. W. McAninch, "Genital self-mutilation," *Journal of Urology*, vol. 150, no. 4, pp. 1143–1146, 1993.

[25] V. Raveenthiran, "Releasing of zipper-entrapped foreskin: a novel nonsurgical technique," *Pediatric Emergency Care*, vol. 23, no. 7, pp. 463–464, 2007.

[26] W. W. Ezell, E. I. Smith, R. P. McCarthy, I. M. Thompson, and H. N. Habib, "Mechanical traumatic injury to the genitalia in children," *Journal of Urology*, vol. 102, no. 6, pp. 788–792, 1969.

[27] J. H. Mydlo, "Treatment of a delayed zipper injury," *Urologia Internationalis*, vol. 64, no. 1, pp. 45–46, 2000.

[28] N. Eke, "Fracture of the penis," *The British Journal of Surgery*, vol. 89, no. 5, pp. 555–565, 2002.

[29] M. A. Asgari, S. Y. Hosseini, M. R. Safarinejad, B. Samadzadeh, and A. R. Bardideh, "Penile fractures: evaluation, therapeutic approaches and long-term results," *Journal d'Urologie*, vol. 155, no. 1, pp. 148–149, 1996.

[30] J. Zargooshi, "Penile fracture in Kermanshah, Iran: report of 172 cases," *Journal of Urology*, vol. 164, no. 2, pp. 364–366, 2000.

[31] A. M. El-Taher, H. A. Aboul-Ella, M. A. Sayed, and A. A. Gaafar, "Management of penile fracture," *The Journal of Trauma*, vol. 56, no. 5, pp. 1138–1140, 2004.

[32] M. C. Uygur, B. Gülerkaya, U. Altuğ, C. Germiyanoğlu, and D. Erol, "13 years' experience of penile fracture," *Scandinavian Journal of Urology and Nephrology*, vol. 31, no. 3, pp. 265–266, 1997.

[33] J. Zargooshi, "Penile fracture in Kermanshah, Iran: the long-term results of surgical treatment," *BJU International*, vol. 89, no. 9, pp. 890–894, 2002.

[34] E. M. Mazaris, K. Livadas, D. Chalikopoulos, A. Bisas, C. Deliveliotis, and A. Skolarikos, "Penile fractures: immediate surgical approach with a midline ventral incision," *BJU International*, vol. 104, no. 4, pp. 520–523, 2009.

[35] M. Muentener, S. Suter, D. Hauri, and T. Sulser, "Long-term experience with surgical and conservative treatment of penile fracture," *Journal of Urology*, vol. 172, no. 2, pp. 576–579, 2004.

[36] L. Koifman, A. G. Cavalcanti, C. H. Manes, D. R. Filho, and L. A. Favorito, "Penile fracture—experience in 56 cases," *International Braz J Urol*, vol. 29, no. 1, pp. 35–39, 2003.

[37] G. Faydaci, A. Ozgul, U. Kuyumcuoglu, T. Aktoz, and M. Oder, "Dorsal vein rupture after practice of taqaandan, necrotising cavernositis, penile reconstruction, urethroplasty and penile prosthesis implantation," *Andrologia*, vol. 44, no. 1, pp. 851–855, 2012.

[38] J. Noh, T. W. Kang, T. Heo, D. D. Kwon, K. Park, and S. B. Ryu, "Penile strangulation treated with the modified string method," *Urology*, vol. 64, no. 3, p. 591, 2004.

[39] F. G. E. Perabo, G. Steiner, P. Albers, and S. C. Müller, "Treatment of penile strangulation caused by constricting devices," *Urology*, vol. 59, no. 1, article 137, 2002.

[40] C. Patel, R. Kim, M. Delterzo, and R. Wang, "Prolonged penile strangulation with metal clamps," *Asian Journal of Andrology*, vol. 8, no. 1, pp. 105–106, 2006.

[41] T. Xu, M. Gu, and H. Wang, "Emergency management of penile strangulation: a case report and review of the Chinese literature," *Emergency Medicine Journal*, vol. 26, no. 1, pp. 73–74, 2009.

[42] S. J. Baruah, P. K. Bagchi, S. K. Barua, and P. M. Deka, "An innovative surgical technique for treating penile incarceration injury caused by heavy metallic ring," *Indian Journal of Urology*, vol. 25, no. 2, pp. 267–268, 2009.

[43] H. Aliabadi, A. S. Cass, P. Gleich, and C. F. Johnson, "Self-inflicted foreign bodies involving lower urinary tract and male genitals," *Urology*, vol. 26, no. 1, pp. 12–16, 1985.

[44] H. P. Navarro, M. J. D. Moreno, P. C. López et al., "Penile foreign bodies," *Archivos Espanoles de Urologia*, vol. 62, no. 6, pp. 501–507, 2009.

[45] N. U. Rahman, S. P. Elliott, and J. W. McAninch, "Self-inflicted male urethral foreign body insertion: endoscopic management and complications," *BJU International*, vol. 94, no. 7, pp. 1051–1053, 2004.

[46] D. S. Cho, S. J. Kim, and J. B. Choi, "Foreign bodies in urethra and bladder by implements used during sex behavior," *Korean Journal of Urology*, no. 44, pp. 1131–1134, 2003.

[47] A. R. Babaei and M. R. Safarinejad, "Penile replantation, science or myth? A systematic review," *Urology Journal*, vol. 4, no. 2, pp. 62–65, 2007.

[48] G. H. Jordan and D. A. Gilbert, "Management of amputation injuries of the male genitalia," *The Urologic Clinics of North America*, vol. 16, no. 2, pp. 359–367, 1989.

[49] B. Volkmer and S. Maier, "Successful penile replantation following autoamputation: twice!," *International Journal of Impotence Research*, vol. 14, no. 3, pp. 197–198, 2002.

[50] S. S. Shirodkar, F. T. Hammad, and N. A. Quereshi, "Male genital self-amputation in the Middle East. A simple repair by anterior urethrostomy," *Saudi Medical Journal*, vol. 28, no. 5, pp. 791–793, 2007.

[51] H. Stunell, R. E. Power, M. Floyd, and D. M. Quinlan, "Genital self-mutilation," *International Journal of Urology*, vol. 13, no. 10, pp. 1358–1360, 2006.

[52] C. S. Romilly and M. T. Isaac, "Male genital selt-mutilation," *British Journal of Hospital Medicine*, vol. 55, no. 7, pp. 427–431, 1996.

[53] W. C. Myers and M. Nguyen, "Autocastration as a presenting sign of incipient schizophrenia," *Psychiatric Services*, vol. 52, no. 5, pp. 685–686, 2001.

[54] E. D. Klonsky, "The functions of deliberate self-injury: a review of the evidence," *Clinical Psychology Review*, vol. 27, no. 2, pp. 226–239, 2007.

[55] M. Large, N. Babidge, D. Andrews, P. Storey, and O. Nielssen, "Major self-mutilation in the first episode of psychosis," *Schizophrenia Bulletin*, vol. 35, no. 5, pp. 1012–1021, 2009.

[56] J. R. Jezior, J. D. Brady, and S. M. Schlossberg, "Management of penile amputation injuries," *World Journal of Surgery*, vol. 25, no. 12, pp. 1602–1609, 2001.

[57] M. Šolinc, D. Kosutic, A. Stritar, F. Planinsek, M. Mihelič, and R. Lukanovič, "Preexpanded radial forearm free flap for one-stage total penile reconstruction in female-to-male transsexuals," *Journal of Reconstructive Microsurgery*, vol. 25, no. 6, pp. 395–398, 2009.

[58] A. M. Raney, H. Maneis, and P. D. Zimskind, "Reanastomosis of completely transected penis in canine. Review of current concepts," *Urology*, vol. 6, no. 6, pp. 735–737, 1975.

[59] F. K. Hashem, S. Ahmed, A. A. Al-Malaq, and J. M. Abudaia, "Successful replantation of penile amputation (post-circumcision) complicated by prolonged ischaemia," *British Journal of Plastic Surgery*, vol. 52, no. 4, pp. 308–310, 1999.

[60] J. J. Belinky, G. M. Cheliz, C. A. Graziano, and H. M. Rey, "Glanuloplasty with urethral flap after partial penectomy," *The Journal of Urology*, vol. 185, no. 1, pp. 204–206, 2011.

[61] O. N. Mazza and G. M. J. Cheliz, "Glanuloplasty with scrotal flap for partial penectomy," *Journal of Urology*, vol. 166, no. 3, pp. 887–889, 2001.

[62] E. Palminteri, E. Berdondini, M. Lazzeri, F. Mirri, and G. Barbagli, "Resurfacing and reconstruction of the glans penis," *European Urology*, vol. 52, no. 3, pp. 893–900, 2007.

[63] M. L. Djordjevic, M. Z. Bumbasirevic, P. M. Vukovic, S. Sansalone, and S. V. Perovic, "Musculocutaneous latissimus dorsi free transfer flap for total phalloplasty in children," *Journal of Pediatric Urology*, vol. 2, no. 4, pp. 333–339, 2006.

[64] P. Charlesworth, A. Campbell, S. Kamaledeen, and A. Joshi, "Surgical repair of traumatic amputation of the glans," *Urology*, vol. 77, no. 6, pp. 1472–1473, 2011.

[65] R. Meyer, U. K. Kesselring, and M. T. Edgerton, "One-stage reconstruction of the vagina with penile skin as an island flap in male transsexuals," *Plastic and Reconstructive Surgery*, vol. 66, no. 3, pp. 401–406, 1980.

[66] S. A. Amukele, G. W. Lee, J. A. Stock, and M. K. Hanna, "20-Year experience with iatrogenic penile injury," *The Journal of Urology*, vol. 170, no. 4, part 2, pp. 1691–1694, 2003.

[67] A. F. Morey, M. J. Metro, K. J. Carney, K. S. Miller, and J. W. McAninch, "Consensus on genitourinary trauma: external genitalia," *BJU International*, vol. 94, no. 4, pp. 507–515, 2004.

[68] M. Cecchi, G. L. Pagni, C. Ippolito, D. Summonti, C. A. Sepich, and L. Fiorentini, "Fracture of the penis: description of a case," *Archivio Italiano di Urologia, Andrologia*, vol. 69, no. 3, pp. 137–139, 1997.

[69] J. Sherman, J. G. Borer, M. Horowitz, and K. I. Glassberg, "Circumcision: successful glanular reconstruction and survival following traumatic amputation," *Journal of Urology*, vol. 156, no. 2, pp. 842–844, 1996.

[70] H. I. Patel, K. P. Moriarty, P. A. Brisson, and N. R. Feins, "Genitourinary injuries in the newborn," *Journal of Pediatric Surgery*, vol. 36, no. 1, pp. 235–239, 2001.

[71] G. Faydaci, K. Uğur, C. Osman, Ş. Şermin, and E. Bilal, "Amputation of glans penis: a rare circumcision complication and successful management with primary anastomosis and hyperbaric oxygen therapy," *Korean Journal of Urology*, vol. 52, no. 2, pp. 147–149, 2011.

[72] M. L. Djordjevic, E. Palminteri, and F. Martins, "Male genital reconstruction for the penile cancer survivor," *Current Opinion in Urology*, vol. 24, no. 4, pp. 427–433, 2014.

Hindawi Publishing Corporation
BioMed Research International
Volume 2014, Article ID 616149, 10 pages
http://dx.doi.org/10.1155/2014/616149

Research Article

The Role of Intrinsic Pathway in Apoptosis Activation and Progression in Peyronie's Disease

Carla Loreto,[1] Giampiero La Rocca,[2] Rita Anzalone,[2] Rosario Caltabiano,[3] Giuseppe Vespasiani,[4] Sergio Castorina,[1] David J. Ralph,[5] Selim Cellek,[6] Giuseppe Musumeci,[1] Salvatore Giunta,[1] Rados Djinovic,[7] Dragoslav Basic,[8] and Salvatore Sansalone[4]

[1] *Department of Bio-Medical Sciences, Anatomy and Histology Section, University of Catania, Via S. Sofia 87, 95123 Catania, Italy*
[2] *Department of Experimental Biomedicine and Clinical Neuroscience, University of Palermo, 90100 Palermo, Italy*
[3] *Department G.F. Ingrassia Section of Anatomic Pathology University of Catania, 95123 Catania, Italy*
[4] *Department of Urology, School of Medicine Tor Vergata University of Rome, 00133 Rome, Italy*
[5] *University College London Hospital, London WC1E 6BT, UK*
[6] *Cranfield Health Cranfield University, MK43 0AL, UK*
[7] *Sava Perovic Foundation, Center for Genito-Urinary Reconstructive Surgery, 11000 Belgrade, Serbia*
[8] *Clinic of Urology, Clinical Center Nis, 18000 Nis, Serbia*

Correspondence should be addressed to Carla Loreto; carla.loreto@unict.it

Received 26 February 2014; Accepted 31 May 2014; Published 13 August 2014

Academic Editor: Ralf Herwig

Copyright © 2014 Carla Loreto et al. This is an open access article distributed under the Creative Commons Attribution License, which permits unrestricted use, distribution, and reproduction in any medium, provided the original work is properly cited.

Peyronie's disease (PD) is characterized with formation of fibrous plaques which result in penile deformity, pain, and erectile dysfunction. The aim of this study was to investigate the activation of the intrinsic apoptotic pathway in plaques from PD patients. Tunica albuginea from either PD or control patients was assessed for the expression of bax, bcl-2 and caspases 9 and 3 using immunohistochemistry and by measurement of apoptotic cells using TUNEL assay. Bax overexpression was observed in metaplastic bone tissue, in fibroblasts, and in myofibroblast of plaques from PD patients. Little or no bcl-2 immunostaining was detected in samples from either patients or controls. Caspase 3 immunostaining was very strong in fibrous tissue, in metaplasic bone osteocytes, and in primary ossification center osteoblasts. Moderate caspase 9 immunostaining was seen in fibrous cells plaques and in osteocytes and osteoblasts of primary ossification centers from PD patients. Control samples were negative for caspase 9 immunostaining. In PD patients the TUNEL immunoassay showed intense immunostaining of fibroblasts and myofibroblasts, the absence of apoptotic cells in metaplasic bone tissue and on the border between fibrous and metaplastic bone tissue. Apoptosis occurs in stabilized PD plaques and is partly induced by the intrinsic pathway.

1. Introduction

Peyronie's disease (PD) is a connective tissue disorder where formation of fibrous plaques in tunica albuginea (TA) and erectile tissue can result in penile deformity, pain, and erectile dysfunction [1–4]. Although PD is considered a localized disorder, a recent biomolecular study seems to suggest the involvement of the entire TA [5]. Fibrosis, its major pathological manifestation, arises from fibroblast proliferation and accumulation of extracellular matrix; PD progresses with formation of plaques or even ectopic calcification having the appearance of scar tissue, which prevents TA expansion during erections [6, 7]. An external stress, sustained most likely in the erect state (typically during sexual activity), has been suggested to initiate plaque development [8]; the resulting TA injury or tearing then is suggested to heal abnormally [9].

The mechanisms underpinning PD are unclear [9–11], and relatively little is known about the disease itself. As a result effective medical treatments that can alter its course

or progression are not yet available [7, 12]. To date corrective surgery is the sole effective treatment. A greater understanding of PD pathophysiology at the molecular level has the potential to help develop novel medical therapeutic approaches.

Apoptosis, or programmed cell death, is a fundamental mechanism with a key role throughout development [13]. In the fully formed organism it mediates the maintenance of tissue homeostasis involved in normal tissue turnover, whereas its dysregulation plays a role in multiple disease processes [14]. Apoptosis can take place either through the extrinsic (death receptor-mediated) or the intrinsic (mitochondrial) pathway (Figure 1). The former pathway involves activation of death signaling ligands like tumor necrosis factor-related apoptosis-inducing ligand (TRAIL) through its death receptors DR4 and DR5 and has a role in immune and homeostasis processes [13, 15]; these events in turn activate the initiator caspase 8, which cleaves and activates the executioner caspase 3. Executioner caspases induce biochemical and morphological changes such as chromatin condensation, nuclear fragmentation, and cytoskeletal degradation; once they have been activated the apoptosis process becomes irreversible.

The intrinsic mitochondrial pathway is activated by a range of exogenous and endogenous stimuli including DNA damage, ischemia, and oxidative stress (Figure 1). Moreover it plays an important function in development and in elimination of damaged cells [13]. The intrinsic pathway is influenced by members of the bcl family bound to the mitochondrial membrane, including bax and bcl-2, which act as pro- or antiapoptotic regulatory proteins, respectively [16]. In the intrinsic pathway the functional consequence of proapoptotic signaling is mitochondrial membrane perturbation and release of cytochrome C in the cytoplasm, where it forms a complex or apoptosome with apoptotic protease activating factor 1 (APAF1) and the inactive form of caspase 9. This complex hydrolyzes adenosine triphosphate to cleave and activate caspase 9. The initiator caspase 9 then cleaves and activates the executioner caspases 3, 6, and 7, resulting in cell apoptosis [14, 17]. The antiapoptotic proteins bcl-2 and bcl-XL inhibit cytochrome C release [18].

We have previously described apoptotic cell death in TA plaques from patients with PD and demonstrated its activation via the extrinsic pathway by assessing an overexpression of tumour necrosis factor-related apoptosis-inducing ligand (TRAIL) and its death receptor, DR5, in fibroblast and myofibroblast cells [19]. Following up on this previous work, we have decided to investigate the possible activation of the intrinsic pathway through the study of bax, bcl-2, caspase 9, the activation of caspase 3 (the point of no return leading irreversibly to cell death), and the TUNEL assay, which documents DNA fragmentation and hence the achievement of the apoptosis process.

2. Materials and Methods

2.1. Patients and Tissues. Wedge-shaped biopsy specimens (approximately 3 × 5 mm) were collected from 15 patients (mean age 53 ± 10 years; range 31–67) at the level of the corporotomy during corrective surgery for PD. All patients, who had had stable PD for at least 6 months, underwent albugineal grafting using the geometrical principle as originally described by Egydio and Sansalone [20]. The TA was incised and grafted at the level of the maximum penile curvature, where plaque formation was most prominent [21].

The study protocol was approved by the ethics committee of the Clinic of Urology, Clinical Center Nis, Nis, Serbia. The informed consent of each patient was obtained before tissue collection.

During preoperative examination all patients reported having spontaneous erections but being prevented from regular sexual intercourse by a penile curvature of above 45°. Degree of penile curvature and rigidity were evaluated with Doppler ultrasonography after intracavernous injection of 10–20 μg alprostadil.

Control samples were specimens from 4 patients (mean age 23 ± 3 years; range 21–27) with congenital penile curvature who underwent Nesbit's corrective procedure [22]. Their clinical history was negative for generalized penile disease; none had macroscopic signs of degenerative or inflammatory disorders. Histological examination using Mayer's hematoxylin (Histolab Products AB, Sweden) and eosin (Histolab Products AB, Sweden) showed no detectable pathological abnormalities (not shown).

2.2. Immunohistochemistry. For the immunohistochemical studies, PD plaques were fixed overnight in 10% neutral buffered formalin (Bio-Optica, Italy). After fixation and overnight washing in water they were dehydrated in graded ethanol and paraffin-embedded. They were then cut into 5 μm thick sections, using a microtome (Hn40, Reichert-Jung, USA) and placed on silanized glass slides. After rehydration endogenous peroxidase activity was quenched by treatment with 3% H_2O_2 for 10 min as previously described [23]. Nonspecific antibody binding was blocked by treatment with normal horse/goat serum diluted 1 : 20 in phosphate buffered saline (PBS), 0.1% bovine serum albumin (BSA, Roche Applied Science, Germany). Sections were treated (5 min × 3 times) in capped polypropylene slide-holders with citrate buffer (pH 6) using a microwave oven (750 W) to unmask antigen sites.

The following primary antibodies were used: rabbit polyclonal antihuman bax (1 : 100, Dako, Denmark), mouse monoclonal antibody antihuman bcl-2 (Dako, Denmark), mouse monoclonal antihuman caspase 9 (1 : 100, Santa Cruz Biotechnology, USA), and rabbit monoclonal antihuman caspase 3 (1 : 50, Abcam, UK). The primary antibodies were applied directly onto sections and slides were incubated overnight (4°C) in a humid chamber. The sections were then washed in PBS and treated with a biotinylated antibody and detected using peroxidase-labeled streptavidin, both incubated for 10 min at room temperature (LSAB+System-HRP, Dako Italy).

The immunoreaction was assessed using a Zeiss Axioplan light microscope (Oberkochen, Germany) after incubating sections in 0.1% 3,3′-diaminobenzidine and 0.02% hydrogen

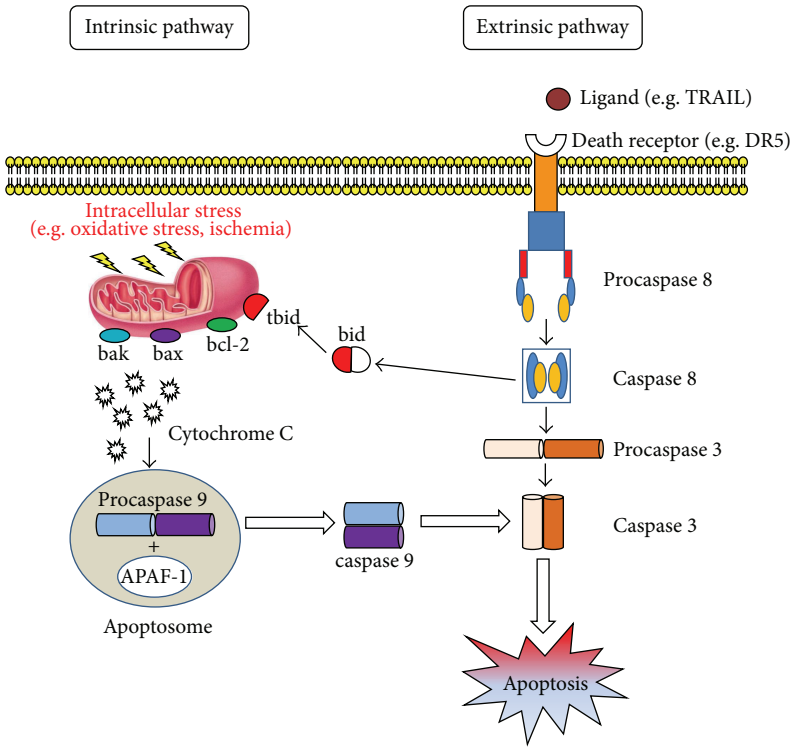

Figure 1: Apoptosis works through two main, alternative pathways: death receptor-mediated (or extrinsic) and mitochondria-dependent (or intrinsic). The former pathway is initiated by ligation of specific death receptors by their ligands. The main death receptors—Fas and tumour necrosis factor- (TNF-) related apoptosis inducing ligand (TRAIL) receptors DR4 and DR5—induce cell death following ligation with Fas ligand (FasL) or TRAIL, respectively, followed by recruitment of procaspase 8. This process gives rise to caspase 8 activation. The latter induces apoptosis by directly activating caspase 3 or by cleaving bid (BH3 interacting domain death agonist), resulting in mitochondrial dysfunction and subsequent release of cytochrome C and activation of caspases 9 and 3. Caspase 3 promotes the typical apoptosis features, including DNA fragmentation and cell death in several tissues. The mitochondrial pathway is partly influenced by bcl family members bound to the mitochondrial membrane, including bax and bcl-2, which are, respectively, pro- or antiapoptotic regulatory proteins. The antiapoptotic proteins bcl-2 and bcl-XL inhibit cytochrome c release, whereas bcl-2—associated X protein(bax), bcl-2 homologous antagonist/killer (bak), and bid, all proapoptotic proteins, promote its release from mitochondria. Cytochrome C and deoxyadenosine triphosphate (dATP) bind to apoptotic protease activating factor (APAF-1) to form a multimeric complex that recruits and activates procaspase 9, an apoptosis-mediating executioner protease that in turn activates caspase 3, resulting in cell apoptosis.

peroxide solution (DAB substrate kit, Vector Laboratories, Burlingame, CA, USA) for 4 min. Sections were lightly counterstained with Mayer's hematoxylin and then mounted on GVA mount (Zymed Laboratories, San Francisco, CA, USA).

2.3. Evaluation of Immunohistochemical Staining. Staining for bax, bcl-2, caspase 9, and caspase 3 was classified as negative/positive. Immunohistochemical staining was brown chromogen detected on the edge of the hematoxylin-stained cell nucleus or distributed in the cytoplasm or the membrane. Intensity of staining (IS) was graded in a semiquantitative manner using a 5-point scale: 0 = no detectable staining, 1 = weak staining, 2 = moderate staining, 3 = strong staining, and 4 = very strong staining. The proportion of immunopositive cells (extent score = ES) was evaluated at 20x magnification blindly by two anatomists and a histologist. ES was scored as a proportion of the final number of 100 cells into five classes: <5% (0), 5–30% (+), 31–50% (++), 51–75% (+++), and >75% (++++). Counting was performed at 20x magnification.

Positive and negative controls were run to test the specific reaction of the primary antibodies used. Positive controls were basal cell carcinoma specimens. For the negative controls, randomly selected sections from PD patients were treated with normal rabbit serum instead of the specific antibodies.

2.4. In Situ Detection and Measurement of Apoptotic Cells (TUNEL). In situ detection of apoptosis at the single cell level was performed by terminal deoxynucleotidyl transferase-(TdT-) mediated dUTP-biotin nick end labeling, TUNEL (In Situ Cell Death Detection Kit, POD, Roche) as previously described [24]. The method involves adding deoxyuridine triphosphate (dUTP) labeled with fluorescein to the ends of the DNA fragments by the catalytic action of TdT. End-labeling experiments were performed in triplicate to enable standardization of the results for the different tissue samples. Paraffin-embedded sections of 5 μm thicknesses were dewaxed. Slides were rinsed twice in 0.01 M PBS (pH 7.4), transferred to 0.07 M citrate buffer (pH 6.0; Bio-Optica),

and treated in a microwave oven at 750 W for 1 min for permeabilization. Sections were then immersed in Tris-HCl 0.1 M (Roche), pH 7.5, containing 3% BSA and 20% normal bovine serum (Sigma-Aldrich, St. Louis, MO, USA) for 30 min at 20°C, rinsed twice in PBS, and immersed in TdT buffer (Roche). Sections were then covered with TdT and fluorescein-labeled dUTP in TdT buffer and incubated in a dark humid chamber at 37°C for 60 min. They were incubated with an antibody specific for fluorescein conjugated to peroxidase with 30 min incubation at 37°C. Staining was visualized with DAB, which stains nuclei with DNA fragmentation brown. Sections were counterstained with Mayer's hematoxylin. In negative controls TdT was omitted from the reaction. Ten fields from randomly selected slides were observed under a light microscope. Each field was photographed with a digital camera (Canon, Japan) at 20x and 40x magnification. On each photomicrograph the same three observers, blinded to sample identity, counted the cells exhibiting a positive TUNEL reaction. The proportion of positive cells was calculated for each photomicrograph and a mean value was obtained for each sample.

2.5. Computerized Image Analysis. To quantify immunohistochemical staining, 10 sections/sample were analyzed in stepwise fashion as a series of consecutive fields with a 40x magnification; the stained area was expressed as pixels/field. Randomly selected fields from each section were analyzed and the percent area staining for bax, bcl-2, caspase 9, and caspase 3 was calculated using AxioVision rel. 4.8.2 image analysis software and an AxioVision 4 Module AutoMeasure (Zeiss, Göttingen, Germany) to quantify the level of immunolabeling in each field. Values from all consecutive images of each biopsy were averaged. Digital pictures were taken using an Axiocam camera (Zeiss, Göttingen).

2.6. Statistical Analysis. Statistical analysis was performed using SPSS software (rel. 16.0, Chicago, IL, USA). Comparisons between mean values were tested with Student's unpaired t-test. P values less than 0.05 were considered significant. Cohen's kappa coefficient was used to measure interobserver agreement and averaged over the three observers. Overall agreement was graded as follows: 0–0.2 (slight), 0.21–0.40 (fair), 0.41–0.60 (moderate), 0.61–0.80 (substantial), and 0.81–1.0 (almost perfect).

3. Results

3.1. General Observations. On hematoxylin and eosin-stained specimens the collagen fiber arrangement was mostly disrupted. Fibers were affected to different degrees in all PD patients, the damage involving fragmentation, tears, and splitting. Elastic fibers were often fragmented; clumps of collagen bundles and surrounding elastic fibers were also noted. In contrast, control TA samples exhibited preserved collagen bundles displaying longitudinal fiber orientation in the outer layer and circular fibers in the inner layer (not shown).

3.2. Bax Expression. PD plaques showed areas of osseous metaplasia with heterotopic ossification (Figure 2(a), asterisk) and several osteocytes were detected in bone lacunae (Figure 2(a), double arrowhead).

Immunohistochemical examination of sections from PD plaques showed bax overexpression (IS: 4; ES: ++++) in some osteocytes in metaplastic bone (Figure 2(b), arrow) and in osteoblasts found in the primary ossification centers (Figure 2(a), arrow). In particular bax overexpression was detected in osteoblasts and fibroblasts on the border of the metaplastic bone tissue (Figure 2(b), double arrowhead) and in vessels (Figure 2(b), asterisk). Very strong bax positivity was also demonstrated in PD plaques in the fibroblast cytoplasm and in the myofibroblast membrane and cytoplasm (Figure 2(c)) (IS: 4; ES: ++++), whereas very few immunostained cells were detected in control samples (Figure 2(d)) (IS: 3; ES: +). The percentage of bax immunopositive cells in PD plaque and control tissue is shown in Figure 7(a). Interobserver agreement was 0.94.

3.3. Bcl-2 Expression. Little or no bcl-2 immunostaining was detected in samples from PD patients (IS: 1; ES: 0) or from controls (IS: 2; ES: +) (Figures 3(a) and 3(b), resp.). The percentage of bcl-2 immunopositive cells in PD plaque and control tissue is shown in Figure 7(b). Interobserver agreement was 0.95.

3.4. Caspase 3 Expression. Caspase 3 immunostaining was very strong (IS: 4; ES: ++++) in fibroblasts lying on the border between fibrous and metaplastic bone tissue; it was also very strong in fibrous tissue (Figure 4(a), arrowheads) and in metaplastic bone osteocytes (Figure 4(a), arrow). Haversian canals (Figure 4(b), arrows) exhibiting primary ossification centers (Figure 4(b), arrowhead) were observed in metaplastic bone wherein a strong caspase 3 immunostaining was found in osteoblasts. Little or no caspase 3 immunostaining was seen in control samples (IS: 3; ES: 0) (Figure 3(c)). The percentage of caspase 3 immunopositive cells in PD plaque and control tissue is shown in Figure 7(c). Interobserver agreement was 0.90.

3.5. Caspase 9 Expression. Moderate immunostaining for caspase 9 was seen in fibrous cells from PD plaques (Figure 5(a), arrows) and in osteocytes (arrow) and osteoblasts of primary ossification centers (arrowhead) (Figure 5(b)) (IS: 2; ES: +++). Control samples were negative for caspase 9 immunostaining (Figure 5(c)) (IS: 0; ES: 0). The percentage of bax immunopositive cells in PD plaque and control tissue is shown in Figure 7(d). Interobserver agreement was 0.89.

3.6. TUNEL Staining. The TUNEL immunoassay showed intense staining of fibroblasts and myofibroblasts from PD plaques (Figure 6(a)) and no stained cells in the metaplastic bone tissue or on the border between fibrous and metaplastic bone tissue (Figure 6(b)). Very few apoptotic cells were detected in control specimens (Figure 6(c)). Quantitative analysis of TUNEL-positive cell staining in PD samples is reported in Figure 8.

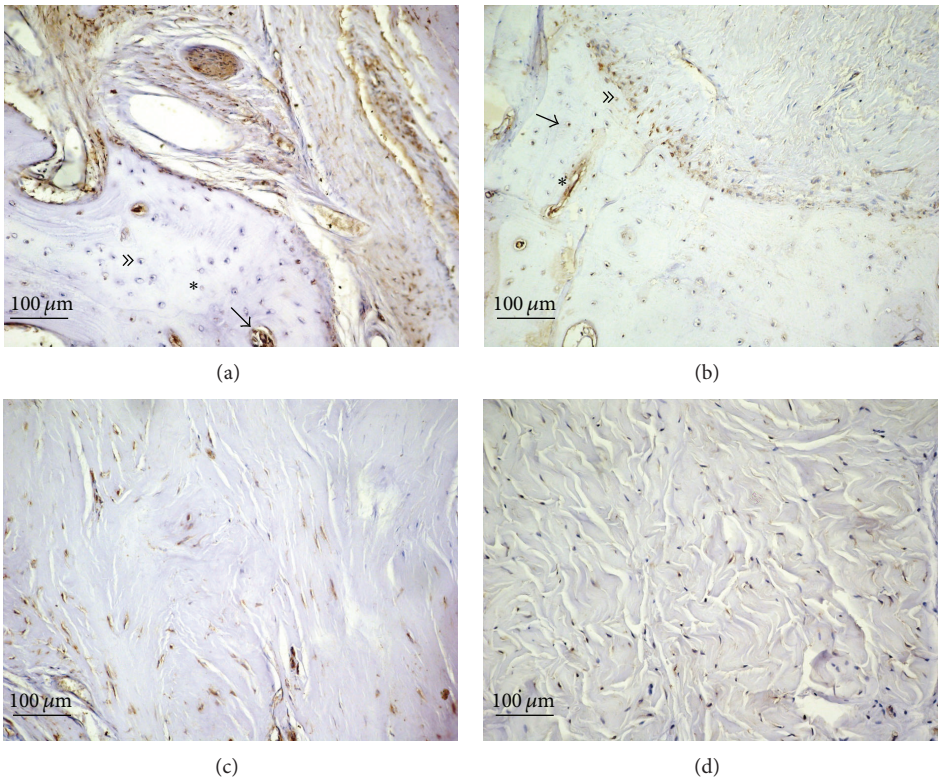

Figure 2: Bax immunostaining in plaque from a patient with Peyronie's disease (a, b, c) and in control tissue (d); magnification is 20x for all. Scale bar = 100 μm. Asterisk at (a): areas of osseous metaplasia with heterotopic ossification; double arrowhead: an osteocyte in bone lacunae; arrow: bax overexpression in an osteoblast of a primary ossification center. Arrow at (b): bax overexpression in an osteocyte in metaplastic bone; double arrowhead: bax overexpression in osteoblasts and fibroblasts on the border of the metaplastic bone tissue; asterisk: bax overexpression in a blood vessel.

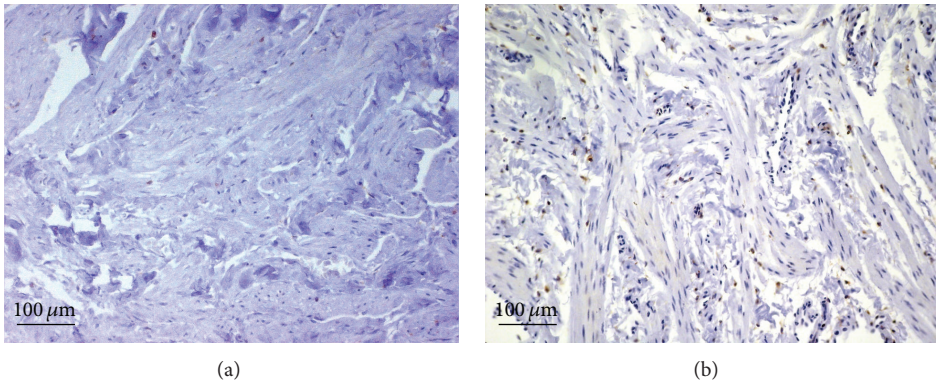

Figure 3: Bcl-2 immunostaining in plaque from a patient with Peyronie's disease (a) and in control tissue (b); magnification is 20x for all. Scale bar = 100 μm.

4. Discussion

Even though PD has been described in the 18th century, its pathogenic mechanism and molecular basis are poorly understood and its therapeutic approach is still empirical [25].

A previous study by our group documented the involvement of the extrinsic pathway in the activation of programmed cell death in PD. The present study examines the possible activation of the intrinsic apoptotic pathway through the immunohistochemical demonstration of staining for a number of key molecules: bcl-2, bax, anti- and proapoptotic oncoproteins, respectively, involved in apoptosis regulation, modulating cell survival or death [26–30], caspase 9, which is associated with the intrinsic pathway, and the executioner caspase 3 (Figure 1). The study also

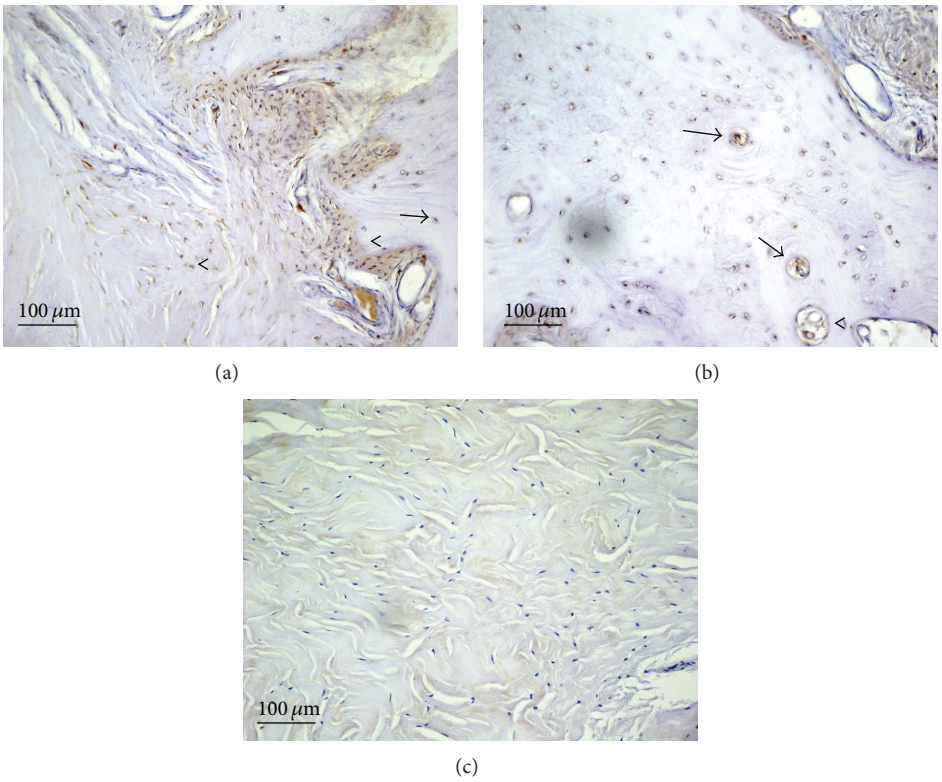

Figure 4: Caspase 3 immunostaining in plaque from a patient with Peyronie's disease ((a) and (b)) and in control tissue (c); magnification is 20x for all. Scale bar = 100 μm. (a) Arrowheads: caspase 3 immunostaining in fibrous tissue; arrow: caspase 3 immunostaining in a metaplastic bone osteocyte. (b) Arrows: haversian canals; arrowhead: a primary ossification center.

seeks to demonstrate the completion of the apoptotic process using the TUNEL assay. Bax upregulation and negative bcl-2 immunostaining, associated with moderate caspase 9 activation, suggest that the apoptotic process documented in PD patients is at least partly regulated by the intrinsic pathway.

TA tissue from PD patients also exhibited upregulation of caspase 3, the executioner caspase of the apoptotic cascade. The apoptotic cascade has been subdivided into three sets of stages. *Initiation stages* include induction of the cascade, for instance, by ligand-receptor interactions or a cellular stress leading to the first proteolytic event. *Execution stages* begin with the activation of executioner caspases such as caspase 3: this is called the "point of no return" since, once activated, these proteases degrade a variety of proteins (including those involved in DNA maintenance and repair such as PARP), resulting in irreversible cell damage. These complex events lead to *apoptotic death*, with collapse of the nucleus and of the cell itself and DNA fragmentation [31].

The caspase 3 immunopositivity found in the plaques from the PD patients, both in fibrous and in metaplastic bone tissue, seems to be in contrast with the TUNEL test results, which suggest that apoptotic cells are found in fibrous tissue but are absent at the level of the osseous metaplasia. However, the discrepancy can be accounted for by the fact that the anticaspase 3 antibody used in these experiments recognizes both the cleaved and the noncleaved form of the protein. This suggests that whereas the apoptotic process takes place in fibrous tissue as a defense mechanism, at the level of the osseous metaplasia, where a degenerative process is already under way, the apoptosis mechanism is already activated but stops and does not continue with caspase 3 activation (cleavage). Apoptosis can therefore be regarded as an injury-limiting mode of cell disposal [32]. Indeed osseous metaplasia can be considered as a tissue adaptation event responding to a microenvironmental change, leading to replacement of sensitive cells with less sensitive ones. Areas of fibrous tissue subject to chronic trauma and a hypoxic microenvironment may therefore give rise to formation of bone tissue presumably from stem cells that undergo osteogenic differentiation [33]. TA disruption in PD usually involves a variety of steps that include a local increase in microvascular permeability, persistent accumulation of fibrin and collagen, perivascular inflammation, elastic fiber disruption and loss, disruption of collagen bundle organization, increased synthesis of transforming growth factor β1 (TGF-β1), and ultimately calcification followed by ossification [34–39]. Increased expression of TGF-β1, plasminogen activator inhibitor 1, reactive oxygen species (ROS), and other profibrotic factors as well as of inducible nitric oxide synthase (iNOS) leads to fibroblast/myofibroblast proliferation and collagen buildup [40, 41] as a defense mechanism against oxidative stress. ROS, iNOS, and TGF-β1 are capable of inducing fibroblast and myofibroblast apoptosis [33, 42–46]. In normal repair and healing a protective mechanism clears myofibroblasts through apoptosis; however, failure of

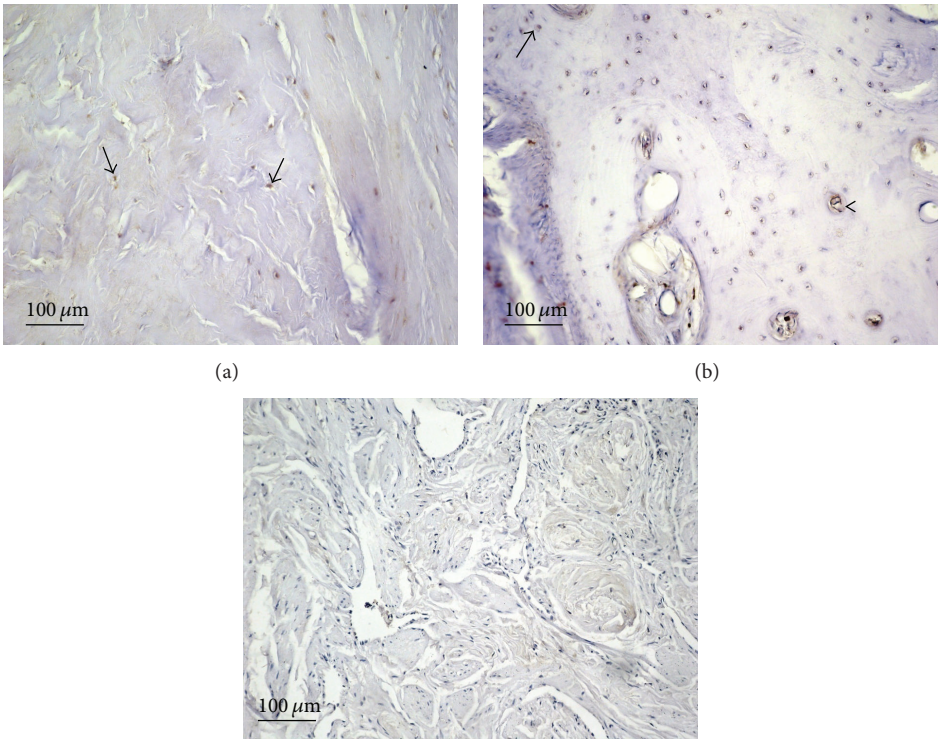

Figure 5: Caspase 9 immunostaining in plaque from a patient with Peyronie's disease (a and b) and in control tissue (c); magnification is 20x for all. Scale bar = 100 μm. (a) Arrows: caspase 9 immunostaining in fibrous cells from PD plaques (Figure 5(a), arrows) and in osteocytes (arrow). (b) Arrowheads: caspase 9 immunostaining in osteoblasts of a primary ossification centers.

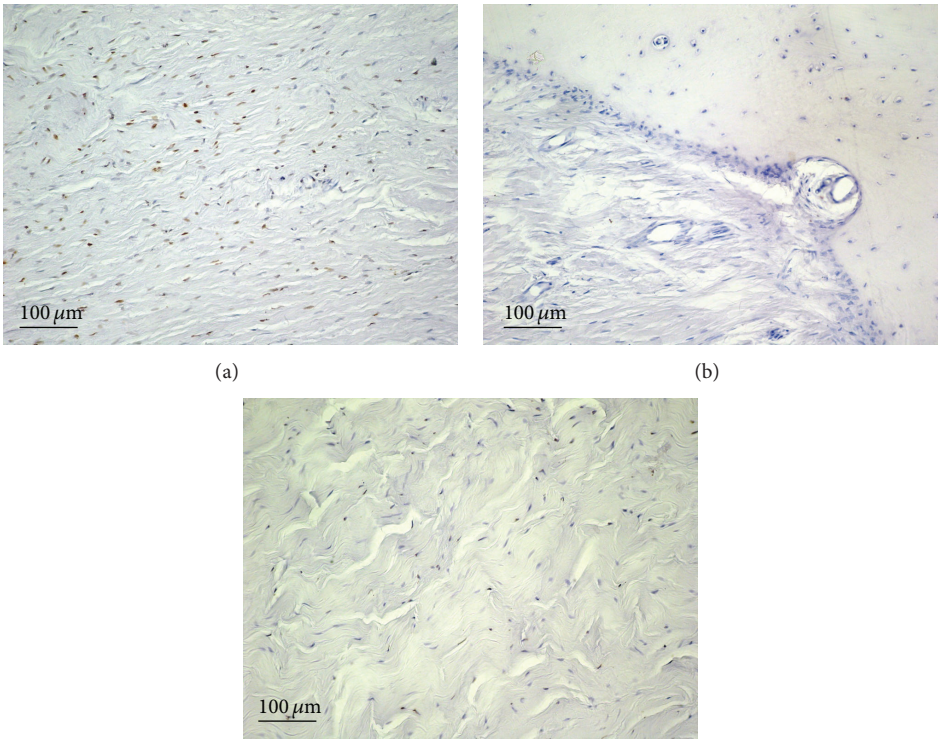

Figure 6: TUNEL staining in plaque from a patient with Peyronie's disease ((a) and (b)) and in control tissue (c); magnification is 20x for all. Scale bar = 100 μm.

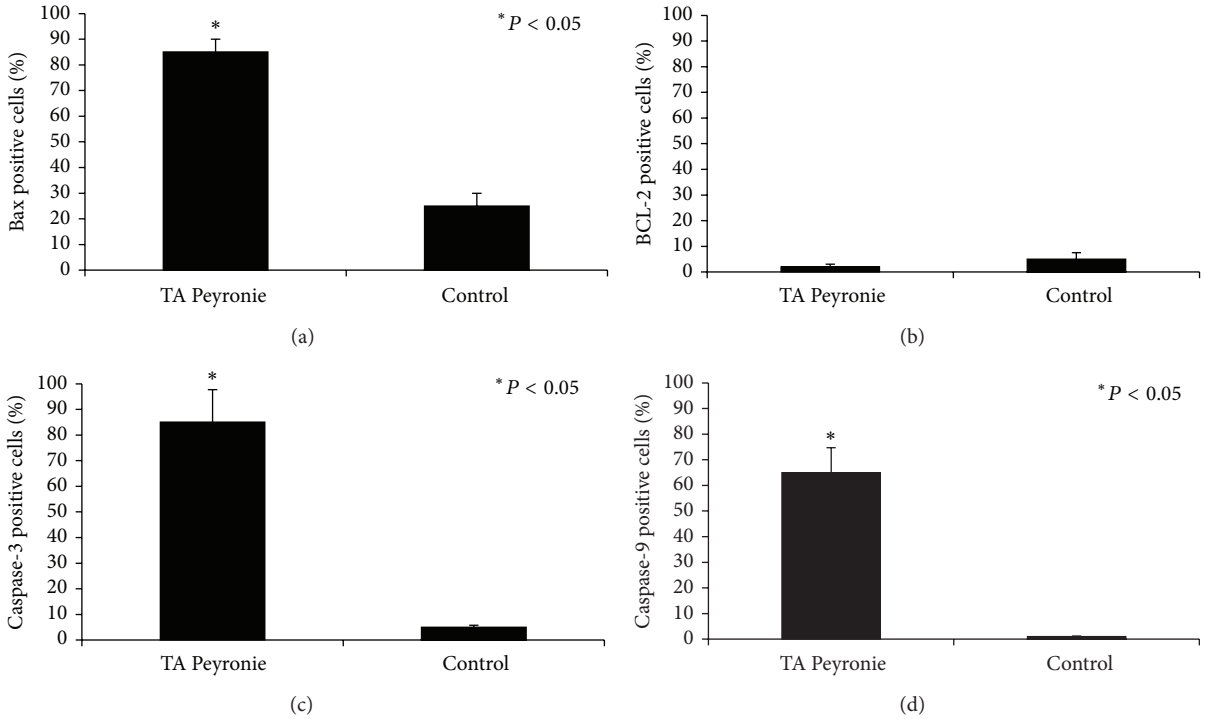

Figure 7: Quantitative analysis of bax (a), bcl-2 (b), caspase 3 (c), and caspase 9 (d) immunostaining in PD samples. In both panels, asterisks indicate significant differences versus the control group ($P < 0.05$).

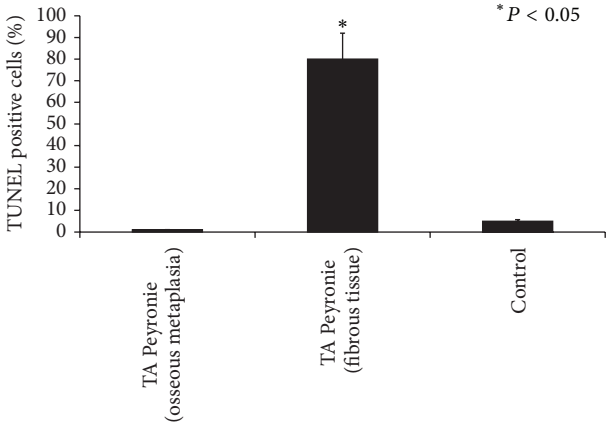

Figure 8: Quantitative analysis of TUNEL-positive cell staining in PD samples. Different cell positivity can be seen in areas with osseous metaplasia and in fibrous tissue areas. Asterisks indicate significant differences versus the control group ($P < 0.01$).

the mechanism entails their persistence inducing fibrosis, collagen buildup, and tissue contraction [7]. Activation of the apoptosis mechanism through the extrinsic pathway, demonstrated in our previous paper, and via the mitochondrial pathway in the present one may be regarded as the reason for plaque stabilization and the halting of fibrosis progression. However, after activation the apoptosis process could be blocked by endogenous apoptosis inhibitors, as likely occurs in the osseous metaplasia area. Further in vivo and in vitro research are therefore needed to gain insights into this delicate process.

A study by Lucattelli et al. [47] demonstrated in a new mouse model of PD that mice aged 12 months develop osseous metaplasia, probably as a consequence of upregulation of hypoxia-inducible factor-1 (HIF-1): this seems to determine an increased expression of HIF-1 target genes such as TGF-β and iNOS which, as noted above, are partly responsible for apoptosis induction. This is probably why there were no apoptotic cells in the osseous metaplasia region.

A further consideration emerging from the analysis of our data is that the moderate expression of caspase 9 and overexpression of caspase 3 indicate a weak role for the intrinsic pathway in programmed cell death, a role that is played principally by the extrinsic pathway as demonstrated by our previous findings. This is reasonable, since this pathway is basically activated by death receptor binding with ligands such as TRAIL, whereas the intrinsic pathway is activated by exogenous stimuli such as inflammation-induced oxidative stress (ROS) [40].

Recent studies have shown that phosphoinositide 3-kinase (PI3K)/Akt signaling regulates fibrotic responses including collagen synthesis and cell proliferation [48]. Jung and colleagues synthesized HS-173, a novel PI3K inhibitor, and found that it inhibited fibroblast growth in a dose-dependent manner and induced apoptosis [48]. Although these findings appear to contrast with ours, the discrepancy may be ascribed to the fact that they were obtained in vivo or that our samples contained stabilized plaque, likely through apoptosis activation and achievement. Indeed it is well known

that when cells lack proliferation factors due, for instance, to tissue overgrowth, they stop proliferating and often die by apoptosis [14].

Previous studies have advanced the hypothesis of an abnormal wound healing process in PD, possibly through a failure of fibroblast apoptosis [49]. Alternatively the significant increase in the number of apoptotic cells detected in PD plaques could be ascribed to an efficient mechanism of programmed cell death leading to plaque stabilization; it may therefore be hypothesized that although the apoptosis process could be impaired during disease evolution, it might however result in plaque stabilization. It would therefore be interesting to study nonstabilized plaque to gain further insights into the activation and progression of the apoptosis process.

In this study we tested the involvement of the intrinsic apoptosis pathway and of executioner caspases in PD and completed the experimental work with the TUNEL assay. Novel therapeutic strategies, for instance, based on TRAIL agonists, could help PD patients through enhancement of myofibroblast death in the attempt to induce plaque stabilization and prevent disease progression.

5. Conclusion

Apoptotic cell death occurs in stabilized PD plaques and is partly induced by the intrinsic mitochondrial pathway. The present findings can have clinical implications and may help devise improved treatment strategies. A therapeutic approach aimed at enhancing apoptosis-inducing molecules would at least help delay the progression of PD. Identification of target molecules for gene construct or biological or chemical reagent delivery to target sites could contribute to inducing PD plaque stabilization.

Conflict of Interests

The authors declare that there is no conflict of interests regarding the publication of this paper.

References

[1] G. H. Jordan, S. M. Schlossberg, and C. J. Devine, "Surgery of the penis and urethra," in *Campbell's Urology*, P. C. Walsh, A. B. Retik, E. D. Vaughan, and A. J. Wein, Eds., pp. 3376–3394, WB Saunders, Philadelphia, Pa, USA, 7th edition, 1998.

[2] M. B. Noss, N. S. Day, G. J. Christ, and A. Melman, "The genetics and immunology of Peyronie's disease," *International Journal of Impotence Research*, vol. 12, supplement 4, pp. S127–S132, 2000.

[3] W. J. G. Hellstrom and T. J. Bivalacqua, "Peyronie's disease: etiology, medical, and surgical therapy," *Journal of Andrology*, vol. 21, no. 3, pp. 347–354, 2000.

[4] S. S. Gholami, S. S. Gholami, T. F. Lue, and T. F. Lue, "Peyronie's disease," *Urologic Clinics of North America*, vol. 28, no. 2, pp. 377–390, 2001.

[5] O. U. Zorba, S. Sirma, G. Ozgon, E. Salabas, U. Ozbek, and A. Kadioglu, "Comparison of apoptotic gene expression profiles between Peyronie's disease plaque and tunica albuginea," *Advances in Clinical and Experimental Medicine*, vol. 21, no. 5, pp. 607–614, 2012.

[6] R. C. Dean and T. F. Lue, "Physiology of penile erection and pathophysiology of erectile dysfunction," *Urologic Clinics of North America*, vol. 32, no. 4, pp. 379–395, 2005.

[7] N. F. Gonzalez-Cadavid, T. R. Magee, M. Ferrini, A. Qian, D. Vernet, and J. Rajfer, "Gene expression in Peyronie's disease," *International Journal of Impotence Research*, vol. 14, no. 5, pp. 361–374, 2002.

[8] N. F. Gonzalez-Cavid and J. Rajfer, "Mechanisms of disease: new insight into the cellular and molecular pathology of Peyronie's disease," *Nature Clinical Practice Urology*, vol. 2, pp. 291–297, 2005.

[9] H. P. Ehrlich, "Scar contracture: cellular and connective tissue aspects in Peyronie's disease," *Journal of Urology*, vol. 157, no. 1, pp. 316–319, 1997.

[10] K. T. McVary, "Peyronies disease," in *Proceedings of the American Urological Association Annual Meeting*, Plenary Session 3, 2001.

[11] C. A. Anaheim and C. J. Davis, "The microscopic pathology of Peyronie's disease," *The Journal of Urology*, vol. 157, pp. 282–284, 1997.

[12] W. J. G. Hellstrom and Y. R. Cockerham, "Intralesional injection therapy for Peyronie's disease," *Journal of Sexual Medicine*, vol. 6, no. 7, pp. 1811–1814, 2009.

[13] C. Munöz-Pinedo, "Sinaling pathway that regulate life and cell death: evolution of apoptosis in the contex of self-defence," in *Self and Nonself*, C. López-Larrea, Ed., chapter 8, pp. 124–143, Springer, 2012.

[14] E. K. Rowinsky, "Targeted induction of apoptosis in cancer management: the emerging role of tumor necrosis factor-related apoptosis-inducing ligand receptor activating agents," *Journal of Clinical Oncology*, vol. 23, no. 36, pp. 9394–9407, 2005.

[15] C. Loreto, L. E. Almeida, M. R. Migliore, M. Caltabiano, and R. Leonardi, "TRAIL, DR5 and caspase 3-dependent apoptosis in vessels of diseased human temporomandibular joint disc. An immunohistochemical study," *European Journal of Histochemistry*, vol. 54, no. 3, pp. 175–179, 2010.

[16] R. Caltabiano, R. Leonardi, G. Musumeci et al., "Apoptosis in temporomandibular joint disc with internal derangement involves mitochondrial-dependent pathways: an in vivo study," *Acta Odontologica Scandinavica*, vol. 71, no. 3-4, pp. 577–583, 2013.

[17] C. Loreto, L. E. Almeida, P. Trevilatto, and R. Leonardi, "Apoptosis in displaced temporomandibular joint disc with and without reduction: An immunohistochemical study," *Journal of Oral Pathology and Medicine*, vol. 40, no. 1, pp. 103–110, 2011.

[18] S. W. Fesik, "Insights into programmed cell through structural biology," *Cell*, vol. 103, no. 2, pp. 273–282, 2000.

[19] C. Loreto, G. Barbagli, R. Djinovic et al., "Tumor necrosis factor-related apoptosis-inducing ligand (TRAIL) and its death receptor (DR5) in Peyronie's disease. A biomolecular study of apoptosis activation," *Journal of Sexual Medicine*, vol. 8, no. 1, pp. 109–115, 2011.

[20] P. H. Egydio and S. Sansalone, "Peyronie's reconstruction for maximum length and girth gain: geometrical principles," *Advances in Urology*, vol. 2008, Article ID 205739, 9 pages, 2008.

[21] G. Garaffa, S. Sansalone, and D. J. Ralph, "Penile reconstruction," *Asian Journal of Andrology*, vol. 15, no. 1, pp. 16–19, 2013.

[22] R. M. NESBIT, "Congenital curvature of the phallus: report of three cases with description of corrective operation," *The Journal of Urology*, vol. 93, pp. 230–232, 1965.

[23] G. Musumeci, P. Castrogiovanni, C. Loreto, S. Castorina, K. Pichler, and A. M. Weinberg, "Post-traumatic caspase-3 expression in the adjacent areas of growth plate injury site: a morphological study," *International Journal of Molecular Sciences*, vol. 14, no. 8, pp. 15767–15784, 2013.

[24] C. Loreto, A. Orlandi, A. Ferlosio et al., "Cryopreserved penile tunica albuginea for allotransplantation: a morphological and ultrastructural investigation," *Journal of Sexual Medicine*, vol. 9, no. 9, pp. 2378–2388, 2012.

[25] D. J. Ralph and S. Minhas, "The management of Peyronie's disease," *BJU International*, vol. 93, no. 2, pp. 208–215, 2004.

[26] D. L. Vaux, S. Cory, and J. M. Adams, "Bcl-2 gene promotes haemopoietic cell survival and cooperates with c-myc to immortalize pre-B cells," *Nature*, vol. 335, no. 6189, pp. 440–442, 1988.

[27] S. J. Korsmeyer, "Bcl-2 initiates a new category of oncogenes: regulators of cell death," *Blood*, vol. 80, no. 4, pp. 879–886, 1992.

[28] X. M. Yin, Z. N. Oltvai, and S. J. Korsmeyer, "BH1 and BH2 domains of Bcl-2 are required for inhibition of apoptosis and heterodimerization with Bax," *Nature*, vol. 369, no. 6478, pp. 321–323, 1994.

[29] Z. N. Oltvai, C. L. Milliman, and S. J. Korsmeyer, "Bcl-2 heterodimerizes in vivo with a conserved homolog, Bax, that accelerates programed cell death," *Cell*, vol. 74, no. 4, pp. 609–619, 1993.

[30] W. W. Wong and H. Puthalakath, "Bcl-2 family proteins: the sentinels of the mitochondrial apoptosis pathway," *IUBMB Life*, vol. 60, no. 6, pp. 390–397, 2008.

[31] B. Huppertz, H. Frank, and P. Kaufmann, "The apoptosis cascade—morphological and immunohistochemical methods for its visualization," *Anatomy and Embryology*, vol. 200, no. 1, pp. 1–18, 1999.

[32] C. Loreto, C. Galanti, R. Leonardi et al., "Possible role of apoptosis in the pathogenesis and clinical evolution of radicular cyst: an immunohistochemical study," *International Endodontic Journal*, vol. 46, no. 7, pp. 642–648, 2013.

[33] D. Vernet, M. G. Ferrini, E. G. Valente et al., "Effect of nitric oxide on the differentiation of fibroblasts into myofibroblasts in the Peyronie's fibrotic plaque and in its rat model," *Nitric Oxide*, vol. 7, no. 4, pp. 262–276, 2002.

[34] C. J. Davis, "The microscopic pathology of Peyronie's disease," *The Journal of Urology*, vol. 157, no. 1, pp. 282–284, 1997.

[35] C. J. Devine Jr., K. D. Somers, G. H. Jordan, and S. M. Schlossberg, "Proposal: trauma as the cause of the Peyronie's lesion," *Journal of Urology*, vol. 157, no. 1, pp. 285–290, 1997.

[36] J. P. Jarow and F. C. Lowe, "Penile trauma: an etiologic factor in Peyronie's disease and erectile dysfunction," *The Journal of Urology*, vol. 158, no. 4, pp. 1388–1390, 1997.

[37] K. D. Somers and D. M. Dawson, "Fibrin deposition in Peyronie's disease plaque," *Journal of Urology*, vol. 157, no. 1, pp. 311–315, 1997.

[38] A. W. Shindel, G. Lin, H. Ning et al., "Pentoxifylline attenuates transforming growth factor-β1-stimulated collagen deposition and elastogenesis in human tunica albuginea-derived fibroblasts part 1: impact on extracellular matrix," *The Journal of Sexual Medicine*, vol. 7, no. 6, pp. 2077–2085, 2010.

[39] L. X. Young, A. J. Bella, D. B. O'Gorman, B. S. Gan, K. B. Lim, and G. B. Brock, "Protein biomarker analysis of primary Peyronie's disease cells," *The Journal of Sexual Medicine*, vol. 7, pp. 99–106, 2010.

[40] N. F. Gonzalez-Cadavid and J. Rajfer, "Treatment of Peyronie's disease with PDE5 inhibitors: an antifibrotic strategy," *Nature Reviews Urology*, vol. 7, no. 4, pp. 215–221, 2010.

[41] A. Pardo, R. Barrios, V. Maldonado et al., "Gelatinases A and B are up-regulated in rat lungs by subacute hyperoxia: pathogenetic implications," *The American Journal of Pathology*, vol. 153, no. 3, pp. 833–844, 1998.

[42] M. G. Ferrini, T. R. Magee, D. Vernet, J. Rajfer, and N. F. González-Cadavid, "Aging-related expression of inducible nitric oxide synthase and markers of tissue damage in the rat penis," *Biology of Reproduction*, vol. 64, no. 3, pp. 974–982, 2001.

[43] M. G. Ferrini, D. Vernet, T. R. Magee et al., "Antifibrotic role of inducible nitric oxide synthase," *Nitric Oxide*, vol. 6, no. 3, pp. 283–294, 2002.

[44] T. J. Bivalacqua, E. K. Diner, T. E. Novak et al., "A rat model of Peyronie's disease associated with a decrease in erectile activity and an increase in inducible nitric oxide synthase protein expression," *Journal of Urology*, vol. 163, no. 6, pp. 1992–1998, 2000.

[45] H. H. Davila, M. G. Ferrini, J. Rajfer, and N. F. Gonzalez-Cadavid, "Fibrin as an inducer of fibrosis in the tunica albuginea of the rat: a new animal model of Peyronie's disease," *BJU International*, vol. 91, no. 9, pp. 830–838, 2003.

[46] T. Teramoto, A. Kiss, and S. S. Thorgeirsson, "Induction of p53 and Bax during TGF-β1 initiated apoptosis in rat liver epithelial cells," *Biochemical and Biophysical Research Communications*, vol. 251, no. 1, pp. 56–60, 1998.

[47] M. Lucattelli, B. Lunghi, S. Fineschi et al., "A new mouse model of Peyronie's disease: an increased expression of hypoxia-inducible factor-1 target genes during the development of penile changes," *The International Journal of Biochemistry & Cell Biology*, vol. 40, no. 11, pp. 2638–2648, 2008.

[48] K. H. Jung, Y. Ryu, H. Lee et al., "A novel PI3K inhibitor alleviates fibrotic responses in fibroblasts derived from Peyronie's plaques," *International Journal of Oncology*, vol. 42, no. 6, pp. 2001–2008, 2013.

[49] M. Gelbard, "Myofibroblasts and mechanotransduction: do forces in the tunica albuginea contribute to peyronie's disease?" *Journal of Sexual Medicine*, vol. 5, no. 12, pp. 2973–2976, 2008.

Hindawi Publishing Corporation
BioMed Research International
Volume 2014, Article ID 923171, 7 pages
http://dx.doi.org/10.1155/2014/923171

Research Article

Venous Ligation: A Novel Strategy for Glans Enhancement in Penile Prosthesis Implantation

Geng-Long Hsu,[1,2] James W. Hill,[3] Cheng-Hsing Hsieh,[4] Shih-Ping Liu,[2] and Chih-Yuan Hsu[1]

[1] *Microsurgical Potency Reconstruction and Research Center, Hsu's Andrology and National Taiwan University, 3F 88, Wen-Hu Street, Neihu District, Taipei City 11445, Taiwan*
[2] *Department of Urology, National Taiwan University Hospital, College of Medicine, Taipei City 10048, Taiwan*
[3] *Department of Radiology, University of Southern California, Los Angeles, CA 90033, USA*
[4] *Division of Urology, Buddhist Tzu-Chi General Hospital, Taipei Branch, School of Medicine, Buddhist Tzu-Chi University, Hualien City 970, Taiwan*

Correspondence should be addressed to Geng-Long Hsu; genglonghsu@gmail.com

Received 28 March 2014; Accepted 10 June 2014; Published 7 August 2014

Academic Editor: Ralf Herwig

Copyright © 2014 Geng-Long Hsu et al. This is an open access article distributed under the Creative Commons Attribution License, which permits unrestricted use, distribution, and reproduction in any medium, provided the original work is properly cited.

Although penile implantation remains a final solution for patients with refractory impotence, undesirable postoperative effects, including penile size reduction and cold sensation of the glans penis, remain problematic. We report results of a surgical method designed to avoid these problems. From 2003 to 2013, 35 consecutive patients received a malleable penile implant. Of these, 15 men (the enhancing group) were also treated with venous ligation of the retrocoronal venous plexus, deep dorsal vein, and cavernosal veins. The remaining 20 men formed the control group, treated with only a penile implant. Follow-up ranged from 1.1 to 10.0 years, with an average of 6.7 ± 1.5 years. Although preoperative glanular dimension did not differ significantly between the two groups, significant respective difference at one day and one year postoperatively was found in the glanular circumference (128.8 ± 6.8 mm versus 115.3 ± 7.2 mm and 130.6 ± 7.2 mm versus 100.5 ± 7.3 mm; both $P < 0.05$), radius (38.8 ± 2.7 mm versus 37.1 ± 2.8 mm and 41.5 ± 2.6 mm versus 33.8 ± 2.9 mm; latter $P < 0.01$), and satisfaction rate (91.7% versus 53.3%, $P < 0.01$) as well. Based on our results, selective venous ligation appears to enhance the glans penis dimension in implant patients.

1. Introduction

The human penis has been in its current anatomical form for a couple of thousand centuries [1]. In our comparative study of penile anatomy in quadruped and biped animals [2], the former consistently possess an os penis that is virtually free from rigidity problems, whereas humans are peculiar among bipedal animals in possessing disproportionately large and extraordinarily hydraulic corpora cavernosa (CC), an os analog, which prevents the glans from being too feeble for intromission. Interestingly, the glans makes no contribution to the necessary rigidity of the penile shaft [3]. The erectile capability of the human penis largely depends on sinusoids in the glans penis, the corpus spongiosum, and the CC, the latter of which are also exclusively responsible for overall erection rigidity [4, 5]. The human penis frequently encounters erectile dysfunction (ED), defined as inability either to attain or to maintain rigid erection for satisfactory intercourse [6].

Although we have lived in the era of medical treatment of ED since sildenafil was introduced in 1998 [7], penile implantation remains the final viable solution for many patients with refractory ED. The overall number of penile implantations per year rebounded after a temporary dip following introduction of sildenafil [8]. Penile prosthesis has been the best option to provide reliable penile rigidity in many ED patients [9, 10], and it may be performed under local anesthesia [11–14]. Nevertheless, many candidates are reluctant to accept this treatment, because it is not natural

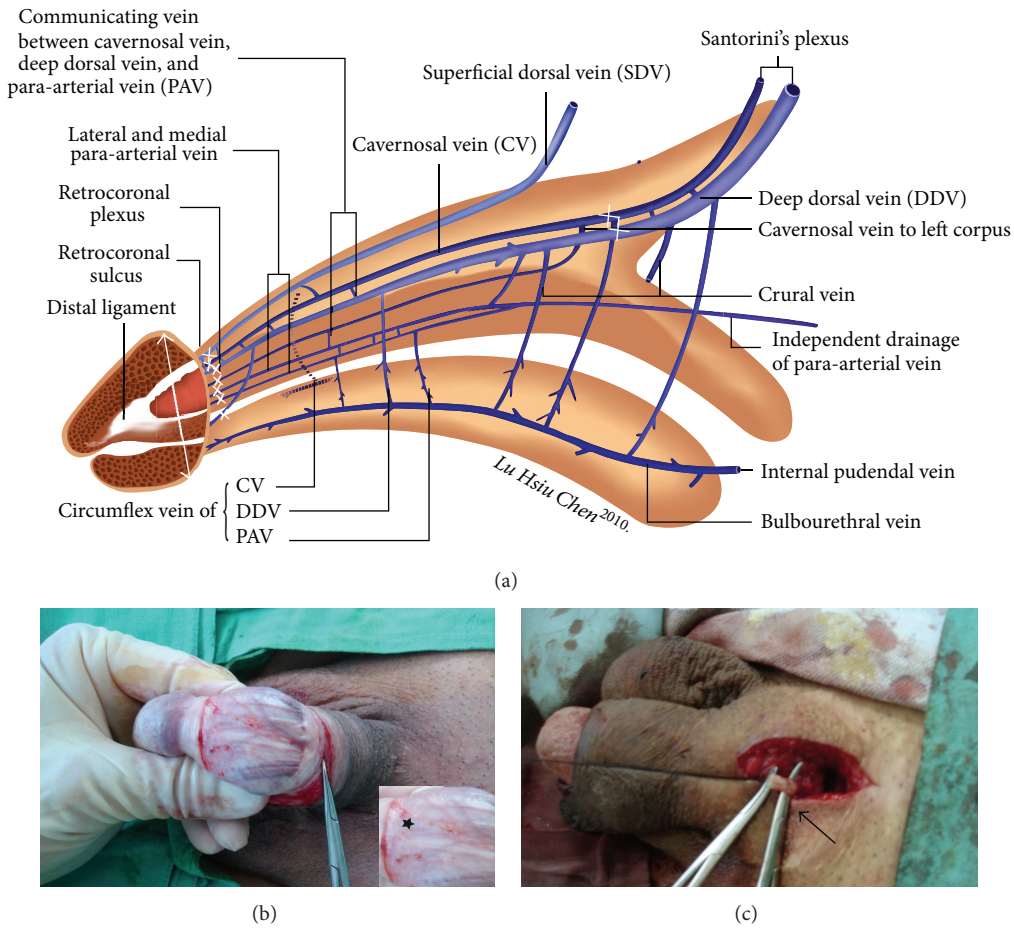

Figure 1: Schematic illustration and photos of this penile enhancing surgery. (a) Illustration showing new insight into penile venous anatomy from lateral view in the human penis. The glans penis composed of sinusoids through which blood drains independently to the deep dorsal vein (DDV), cavernosal veins (CVs), and para-arterial veins. The venous plexus were ligated at retrocoronal sulcus (multiple smaller cross). DDV and CVs were subsequently ligated close to penile hilum (large cross). The radius of glans was assessed (double arrow). (b) Ongoing surgery demonstrating the visibility of the retrocoronal plexus (asterisk) can be enhanced via squeezing the glanular sinusoids after a circumferential approach was performed. Segment of 1-2 cm was stripped while the ligation number may be as many as 29. (c) The proximal segment of DDV (clamped by mosquito hemostat, arrow) and CVs was freed and ligated close to penile hilum.

and some adverse outcomes can occur, such as prosthesis loss, sinusoidal damage, a need for revision surgery, and seemingly intolerable postoperative consequences such as a cold, smaller, and wrinkled glans penis, shortening of the penile shaft, and even loss of penile perception. Among these, glanular problems stand out. Herein we found that venous ligations at a retrocoronal level constitute a viable option for reducing the incidence of glanular size reduction. The techniques outlined herein were refined over the course of extensive clinical practice and cadaveric studies of penile tunical and venous anatomy [15–17].

2. Materials and Methods

From 2003 to 2013, a total of 35 ED patients, aged from 37 to 75 years, received a single-piece penile implant with either malleable or mechanical prosthesis under an acupuncture-aided local anesthesia on an outpatient basis. Penile dimension was obtained in terms of glanular circumference and radius measured along the corona of the glans penis (Figure 1(a)), while the penile stretch length was recorded and then glandular radius was reassessed on 30-degree oblique pelvic X-ray film. Of these, 15 men, each of whom expressed concern about a loss of postoperative penile dimension, were allocated into an enhancing group and were treated with venous ligation of the retrocoronal venous plexus (Figure 1(b)) and proximal ligation of the deep dorsal vein and cavernosal veins (Figure 1(c)) in addition to regular penile implantation. The remaining 20 males were treated with just standard penile implantation and were regarded as a control group. In the enhancing and control group the types of prosthesis used were 4, 2, 4, 2, and 3 versus 4, 3, 6, 4, and 3 to AMS Spectra, Mentor Acuform, AMS600, AMS650, and Dacromed Duraphase II, respectively.

2.1. Venous Ligation and Penile Implant. These procedures were initiated with acupuncture-aided local anesthesia [18]. The operative time was recorded from the time of injecting

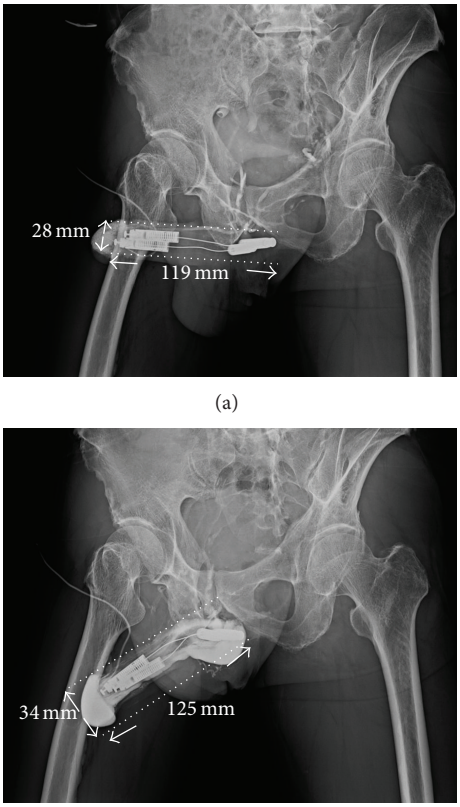

(a)

(b)

Figure 2: Pelvic X-ray film of 30° oblique view of a 65-year-old male. He underwent the first surgery somewhere in 2005. A cold glans syndrome prompted to receive the venous ligation surgery. (a) The glanular radius was enhanced from 28 mm to 34 mm after the penile venous surgery. The corporeal length was 119 mm from X-ray, and it was 180.0 mm from implant surgery; however 90.0 mm × tan 60°(1.73205080757) = 206.1 mm. (b) The DDV was ligated at the level of retrocoronal and hilum region. Enhancement was demonstrated in both the glans penis and entire penile shaft after a contract medium was injected to the glans penis via a #23 scalp needle.

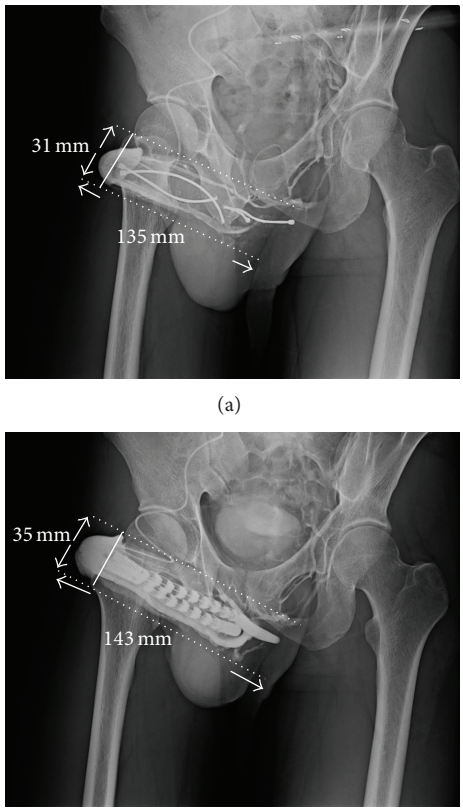

(a)

(b)

Figure 3: Pelvic X-ray film of 30° oblique view of a 35-year-old male of traumatic impotence. He underwent the first surgery somewhere in 2006. A mechanical failure of penile prosthesis prompted him to receive an implant revision and the venous ligation surgery for cold glans syndrome. (a) The glanular radius was enhanced from 31 mm to 35 mm after the penile venous surgery. (b) The DDV was ligated at the level of retrocoronal and hilum region. Enhancement was shown in both the glans penis and entire penile shaft after a contract medium was injected to the glans penis via a #23 scalp needle.

the local anesthetic to the completion of skin suturing. A circumferential subcoronal incision was standard for regular penile implantation in all patients [19]. Thus the implantation was made following a 4 cm corporotomy which was performed on the distal-lateral corpus bilaterally. The tunical wound was sutured with 6-0 nylon continuously with exact approximation of the tunica albuginea and subsequently with interrupted sutures at each 1.5 cm interval for enhancement. The overlying fascia layers and skin were approximated with 5-0 chromic suture, layer by layer. In the enhancing group before penile implantation was performed, a meticulous venous dissection was made along the dorsal retrocoronal region, based on new insights of penile venous anatomy (Figure 1(a)). The visibility of drainage veins of the glans penis could be enhanced via manual squeezing on the glans (Figure 1(b)). They were meticulously stripped for at least a 1.0 cm segment and then ligated with 6-0 nylon sutures, resulting in 29 ligatures in total. Proximally venous ligations were made on the deep dorsal vein and cavernosal vein (Figure 1(c)) deep to the penile hilum as much as possible. The glans radius was reassessed on postoperative X-ray (Figures 2, 3, and 4). Corporeal length and glandular dimension were also analyzed manually. These were followed annually. Overall satisfaction rate was also recorded in both groups. Statistical Mann-Whitney U and Fisher's exact test were applied where appropriate.

3. Results

The follow-up time was from 1.1 to 10.0 years with an average of 6.7 ± 1.5 years. Loss of follow-up occurred in 3 and 5 men in the enhancing and control group, respectively. Among them, 2 and 4 males died. To provide a comprehensive overview, Table 1 summarizes demographic data of the 35 patients. The operative time was 45.0–67.0 min (average 52.3 ± 5.5 min) and 101.5–117.8 min (average 121.7 ± 6.8 min) for the control and enhancing group, respectively. There was no difference in the preoperative glanular circumference between groups (112.7 ± 15.8 mm versus 113.6 ± 13.2 mm; $P = 0.55$). Although the

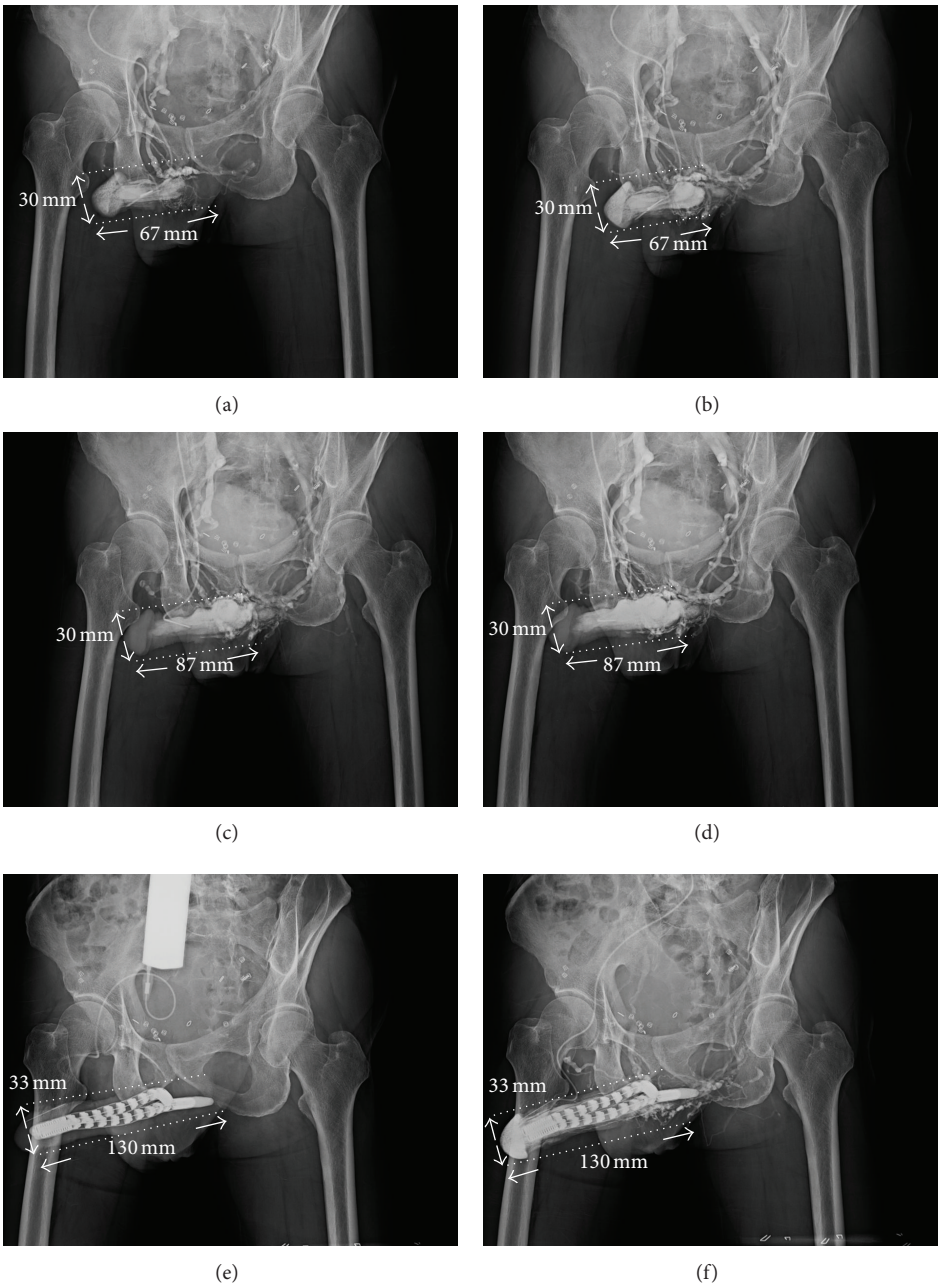

Figure 4: Pelvic X-ray film of 30° oblique view of a 77-year-old male of traumatic impotence. He underwent cryosurgery for prostate adenocarcinoma in 2010. (a) Cavernosogram was made after 20 mL of contract medium was injected. (b) Cavernosogram was undertaken after another 30 mL of contract medium was injected. (c) The penile tissue could not extend 30 min after 20 μg prostaglandin E1 (PGE1) was intracavernously injected. The venous leakage was shown because the drainage veins are conspicuous despite an intracavernosal pressure which exceeded 110 mmHg. (d) The situation was reassured. (e) The venous surgery was performed for penile enhancement in addition to regular penile implant. The penile length was increased although the glandular radius changed from 30 mm to 33 mm. This situation is confirmed (f).

operation time was significantly protracted (121.7 ± 6.8 min versus 52.3 ± 5.5 min; $P < 0.001$), there was a significant difference between the enhancing and control groups at one day and one year postoperatively in glanular circumference (128.8 ± 6.8 mm versus 115.3 ± 7.2 mm and 130.6 ± 7.2 mm versus 100.5 ± 7.3 mm, resp.; both $P < 0.05$) and glanular radius (38.8 ± 2.7 mm versus 37.1 ± 2.8 mm and 41.5 ± 2.6 mm versus 33.8 ± 2.9 mm, resp.; latter $P < 0.01$).

Postoperative satisfaction rate was greater in the enhancing group (91.7% versus 53.3%, $P < 0.01$). In the control group, 45% (9/20) of patients complained of a cold glans. No patients in the enhancing group reported

Table 1: Summary of 35 implant patients who underwent venous ligation for penile enhancement in implant patients.

Grouping	Patients		Circumference of glans corona Manual measurement (mm)			Radius of glans penis Manual measurement (mm)			Corporal length Surgery (mm)	Corporeal length X-ray (mm)	Satisfaction rate Number/available (%)
	Number	Age	Preop	Postop (1 day)	Postop (1 year)	Preop	Postop (1 day)	Postop (1 year)			
Enhancing	15	37–75	112.7 ± 15.8	128.8 ± 6.8	130.6 ± 7.2	37.3 ± 2.9	38.8 ± 2.7	41.5 ± 2.6	182.3 ± 8.2	135.3 ± 7.9	11/12 (91.7)
Control	20	41–75	113.6 ± 13.2	115.3 ± 7.2	100.5 ± 7.3	36.9 ± 2.4	37.1 ± 2.8	33.8 ± 2.9	181.5 ± 8.4	136.3 ± 8.5	8/15 (53.3)
Total	**35**										
P value[†]		NS[*]	0.55	<0.05	<0.01	NS[*]	NS[*]	<0.01	NS[*]	NS[*]	<0.01

[*] NS stands for not significant with *P* value of greater than 0.05.

[†] Univariate comparisons were performed using the Mann-Whitney *U* test as necessary for parameters with continuous values and Fisher's exact test with discontinuous parameters.

this problem. Corporeal length was 18.2 cm and 18.1 cm in manual measurement in the enhancing and control group, respectively, and its corresponding measurement was 13.5 and 13.6 cm, respectively, on 30-degree oblique film.

4. Discussion

Where rigidity is concerned, humans have not benefitted from penile evolution, advancing from the os penis (a rigid body) in quadrupeds to the CC (a hydraulic system) in upright animals [20]. Not surprisingly, pursuits for penile rigidity appear endlessly in human history. The development of the penile implant is being a good example [21]. An implanted penis may mitigate rigidity problems but unfortunately may place the penis at risk not only of compromising tissue integrity [22], but also of penile dimension reduction once the CC are implanted. Several studies support these concerns [12, 23]. We acknowledge the variability of manual measurements of penile dimension, which lack a universal standard. In this series, we use objective criteria based on a 30° oblique X-ray film. Those data were corrected by tangent 60° ($\tan 60^\circ = 1.73205080757$), and smaller values were still demonstrated in each corresponding parameter. Thus, parameters from X-ray film may be difficult to compare with those from manual measurement (Table 1 182.3 ± 8.2 and 181.5 ± 8.4 to enhancing and control group, resp.) and that by X-ray (135.3 ± 7.9 and 136.3 ± 8.5 correspondingly) because discrepancy exists consistently. However, evaluating penile dimension is reliable if comparison is made based on chronological X-ray films.

Although extensive studies of human penis have been performed, an understanding of its anatomy may leave room for improvement [24]. The sinusoids of the corpora cavernosa (CC) differ from those in the corpus spongiosum (CS), which is capped with the glans penis, containing the same sort of sinusoids. Are there, therefore, only two types of sinusoids in the human penis? In our study, the CC, CS, and glans penis each possess specific types of sinusoids histologically [25]. It was accordingly hypothesized that blockage of the draining veins of glanular sinusoids might encourage gradual growth of glanular volume [26]. The venous ligation technique presented here confirms this in our experience [27, 28].

The loss of penile length and the appearance of glans coldness after implantation appear unavoidable in some cases, and several studies have aimed to solve these problems [29–33]. Fortunately, many patients might not care much once their rigidity is improved. However, these problems are bothersome for some men. In this series, three males underwent a first penile implantation somewhere else and requested a viable solution for cold glans syndrome. This problem was mitigated by penile implant revision and the glanular enhancement procedure described herein, resulting in satisfactory outcomes (Figures 2 and 3). Applying this novel method of penile enhancement could benefit cold glans syndrome in patients with penile implant. Further, an acupuncture-aided pure local anesthesia has permitted patients to return to casual activity promptly with negligible morbidity [34].

5. Conclusion

In conclusion, a combination of venous stripping of the retrocoronal plexus and ligation of the DDV and CVs at the penile hilum appears to enhance glanular dimension in implant patients and may treat cold glans syndrome. Studies of larger numbers of patients are required.

Conflict of Interests

The authors declare that there is no conflict of interests regarding the publication of this paper.

Acknowledgments

The authors would like to thank Daniel Freeman for his English editing, along with Ms. Hsiu-Chen Lu, Anita Ho, and Zooey Ping for their preparations of the illustration and photos presented in this paper.

References

[1] *Fossil Reanalysis Pushes Back Origin of Homo Sapiens*, Scientific American, 2005.

[2] G. L. Hsu, C. W. Lin, C. H. Hsieh et al., "Distal ligament in human glans: a comparative study of penile architecture," *Journal of Andrology*, vol. 26, no. 5, pp. 624–628, 2005.

[3] G. L. Hsu, C. H. Hsieh, H. S. Wen et al., "Anatomy of the human penis: the relationship of the architecture between skeletal and smooth muscles," *Journal of Andrology*, vol. 25, no. 3, pp. 426–431, 2004.

[4] G. Hsu, "Hypothesis of human penile anatomy, erection hemodynamics and their clinical applications," *Asian Journal of Andrology*, vol. 8, no. 2, pp. 225–234, 2006.

[5] R. C. Dean and T. F. Lue, "Physiology of penile erection and pathophysiology of erectile dysfunction," *Urologic Clinics of North America*, vol. 32, no. 4, pp. 379–395, 2005.

[6] E. Molodysky, S. P. Liu, S. J. Huang, and G. L. Hsu, "Penile vascular surgery for treating erectile dysfunction: current role and future direction," *Arab Journal of Urology*, vol. 11, pp. 254–266, 2013.

[7] Anonymous, "FDA approves oral therapy for erectile dysfunction," *American Journal of Health-System Pharmacy*, vol. 55, pp. 981–984, 1998.

[8] D. K. Montague, "Penile prosthesis implantation in the era of medical treatment for erectile dysfunction," *Urologic Clinics of North America*, vol. 38, no. 2, pp. 217–225, 2011.

[9] D. K. Montague, "Experience with semirigid rod and inflatable penile prostheses," *Journal of Urology*, vol. 129, no. 5, pp. 967–968, 1983.

[10] J. J. Kaufman, A. Lindner, and S. Raz, "Complications of penile prosthesis surgery for impotence," *The Journal of Urology*, vol. 128, no. 6, pp. 1192–1194, 1982.

[11] R. C. Benson Jr., D. M. Barrett, and D. E. Patterson, "The Jonas prosthesis—technical considerations and results," *Journal of Urology*, vol. 130, no. 5, pp. 920–922, 1983.

[12] F. B. Scott, "Outpatient implantation of penile prostheses under local anesthesia," *Urologic Clinics of North America*, vol. 14, no. 1, pp. 177–185, 1987.

[13] A. Das, M. Soroush, P. Maurer, and I. Hirsch, "Multicomponent penile prosthesis implantation under regional anesthesia," *Techniques in Urology*, vol. 5, no. 2, pp. 92–94, 1999.

[14] J. M. S. M. dos Reis, S. Glina, M. F. da Silva, and V. Furlan, "Penile prosthesis surgery with the patient under local regional anesthesia," *Journal of Urology*, vol. 150, no. 4, pp. 1179–1181, 1993.

[15] G. L. Hsu, C. H. Hsieh, H. S. Wen, Y. C. Chen, S. C. Chen, and M. S. Mok, "Penile venous anatomy: an additional description and its clinical implication," *Journal of Andrology*, vol. 24, no. 6, pp. 921–927, 2003.

[16] C. H. Hsieh, C. J. Wang, G. L. Hsu et al., "Penile veins play a pivotal role in erection: the haemodynamic evidence," *International Journal of Andrology*, vol. 28, no. 2, pp. 88–92, 2005.

[17] G. L. Hsu, Y. P. Hung, M. H. Tsai et al., "Penile veins are the principal component in erectile rigidity: a study of penile venous stripping on defrosted human cadavers," *Journal of Andrology*, vol. 33, no. 6, pp. 1176–1185, 2012.

[18] G. L. Hsu, U. X. Zaid, C. H. Hsieh, and S. J. Huang, "Acpuncture assisted regional anesthesia for penile surgeries," *The Translational Andrology and Urology*, vol. 2, no. 4, pp. 291–300, 2013.

[19] G. L. Hsu, C. H. Hsieh, H. S. Wen et al., "Outpatient penile implantation with the patient under a novel method of crural block," *International Journal of Andrology*, vol. 27, no. 3, pp. 147–151, 2004.

[20] C. H. Hsieh, S. P. Liu, G. L. Hsu et al., "Advances in understanding of mammalian penile evolution, human penile anatomy and human erection physiology: clinical implications for physicians and surgeons," *Medical Science Monitor*, vol. 18, no. 7, pp. RA118–RA125, 2012.

[21] W. E. Goodman and W. W. Scott, "Phalloplasty.," *The Journal of urology*, vol. 68, no. 6, pp. 903–908, 1952.

[22] S. K. Wilson, J. R. Delk, E. A. Salem, and M. A. Cleves, "Long-term survival of inflatable penile prostheses: single surgical group experience with 2,384 first-time implants spanning two decades," *Journal of Sexual Medicine*, vol. 4, no. 4, pp. 1074–1079, 2007.

[23] S. Deveci, D. Martin, M. Parker, and J. P. Mulhall, "Penile length alterations following penile prosthesis surgery," *European Urology*, vol. 51, no. 4, pp. 1128–1131, 2007.

[24] C. Gratzke, J. Angulo, K. Chitaley et al., "Anatomy, physiology, and pathophysiology of erectile dysfunction," *Journal of Sexual Medicine*, vol. 7, no. 1, pp. 445–475, 2010.

[25] G. L. Hsu, G. Brock, B. Von Heyden, L. Nunes, T. F. Lue, and E. A. Tanagho, "The distribution of elastic fibrous elements within the human penis," *British Journal of Urology*, vol. 73, no. 5, pp. 566–571, 1994.

[26] G. L. Hsu, C. H. Hsieh, H. S. Wen et al., "Penile enhancement: an outpatient technique," *European Journal of Medical Sexology*, vol. 11, pp. 6–10, 2002.

[27] H. S. Wen, C. H. Hsieh, G. L. Hsu et al., "The synergism of penile venous surgery and oral sildenafil in treating patients with erectile dysfunction," *International Journal of Andrology*, vol. 28, no. 5, pp. 297–303, 2005.

[28] S. C. Chen, C. H. Hsieh, G. L. Hsu et al., "The progression of the penile vein: could it be recurrent?" *Journal of Andrology*, vol. 26, pp. 56–63, 2005.

[29] K. K. Chew and B. G. A. Stuckey, "Use of transurethral alprostadil (MUSE) (prostaglandin E1) for glans tumescence in a patient with penile prosthesis," *International Journal of Impotence Research*, vol. 12, no. 3, pp. 195–196, 2000.

[30] A. Miranda-Sousa, M. Keating, S. Moreira, M. Baker, and R. Carrion, "Concomitant ventral phalloplasty during penile implant surgery: A novel procedure that optimizes patient satisfaction and their perception of phallic length after penile implant surgery," *Journal of Sexual Medicine*, vol. 4, no. 5, pp. 1494–1499, 2007.

[31] T. S. Hakky, J. Suber, G. Henry et al., "Penile enhancement procedures with simultaneous penile prosthesis placement," *Advances in Urology*, vol. 2012, Article ID 314612, 5 pages, 2012.

[32] F. Borges, L. Hakim, and C. Kline, "Surgical technique to maintain penile length after insertion of an inflatable penile prosthesis via infrapubic approach," *The Journal of Sexual Medicine*, vol. 3, no. 3, pp. 550–553, 2006.

[33] K. C. J. Lee and G. B. Brock, "Strategies for maintaining penile size following penile implant," *Translational Andrology and Urology*, vol. 2, no. 1, pp. 67–73, 2013.

[34] G. L. Hsu, H. S. Chen, C. H. Hsieh, W. Y. Lee, K. L. Chen, and C. H. Chang, "Clinical experience of a refined penile venous stripping surgery procedure for patients with erectile dysfunction: is it a viable option?" *Journal of Andrology*, vol. 31, no. 3, pp. 271–280, 2010.

Hindawi Publishing Corporation
BioMed Research International
Volume 2014, Article ID 403603, 4 pages
http://dx.doi.org/10.1155/2014/403603

Clinical Study

Treatment of Bilateral Varicocele and Other Scrotal Comorbidities Using a Single Scrotal Access: Our Experience on 34 Patients

F. Iacono,[1] A. Ruffo,[1] D. Prezioso,[1] G. Romeo,[1] E. Illiano,[1] G. Di Lauro,[2] L. Romis,[2] and S. Sansalone[3]

[1] *Department of Urology, Federico II University, Via S. Pansini 5, 80100 Naples, Italy*
[2] *Department of Urology, Hospital Santa Maria delle grazie, Via Domiziana, Località la Schiana, Pozzuoli, 80078 Naples, Italy*
[3] *Department of Urology, Tor Vergata University, Viale Oxford 81, 00133 Rome, Italy*

Correspondence should be addressed to A. Ruffo; antonio.ruffo7@gmail.com

Received 30 April 2014; Accepted 6 June 2014; Published 23 July 2014

Academic Editor: Ralf Herwig

Copyright © 2014 F. Iacono et al. This is an open access article distributed under the Creative Commons Attribution License, which permits unrestricted use, distribution, and reproduction in any medium, provided the original work is properly cited.

Introduction. Varicocele is the main cause of infertility in male and the most correctable cause of it too. In this study, we present our experience on 34 patients affected by bilateral varicocele and other scrotal comorbidities treated underwent surgery with a scrotal access. *Materials and Methods*. 34 patients were enrolled with clinical palpable and infraclinical (ultrasonic doppler scanning) bilateral varicocele and other comorbidities like right hydrocele, left hydrocele, bilateral hydrocele, and epididymal cyst. They all underwent scrotal bilateral varicocelectomy under local anesthesia. *Results and Discussion*. At 6 months, no other complications were reported. No case of testicular atrophy was observed. None had recurrence of varicocele. All scrotal comorbidities were treated as well. *Conclusion*. Scrotal access with local anesthesia is a safe and useful technique to treat patients with bilateral varicocele and other scrotal comorbidities.

1. Introduction

Varicocele is a common abnormality with the following andrological implications: failure of ipsilateral testicular growth and development, symptoms of pain and discomfort, male infertility. It is commonly believed that this condition may begin with the onset of puberty, at around the age of 15 [1].

Most varicoceles are left-sided, and the left-sided predominance is explained by turbulent venous flow related to the right angle insertion of the left testicular vein into the left renal vein [2]. Varicocele is a physical abnormality present in 11.7% of men with normal semen analysis and in 25.4% of men with abnormal semen [3].

Varicoceles are recognized as the most common surgically correctable cause of male infertility, but the exact mechanism of varicocele-induced impairment of spermatogenesis remains a matter of debate. The exact association between reduced male fertility and varicocele is unknown, but a meta-analysis showed that semen improvement is usually observed after surgical correction [4].

Varicocele is associated with increased sperm DNA damage, and this sperm pathology may be secondary to varicocele-mediated oxidative stress. Varicocelectomy can reverse this sperm DNA damage, as shown in several studies [5].

Physical examinations and scrotal ultrasounds remain the most commonly used methods. Varicocele is graded at the time of the initial physical examination according to the Dublin grading system (I–III) [6]. Surgical correction of varicocele improves their fertility potential [7]. Several surgical approaches to varicocelectomy exist, each with its own advantages and drawbacks: varicocele embolization, the traditional inguinal (Ivanissevich), or high retroperitoneal (Palomo) approaches, laparoscopic repair and microsurgical repair *via* an inguinal, or subinguinal incision.

Figure 1: A median scrotal incision was done on rafe.

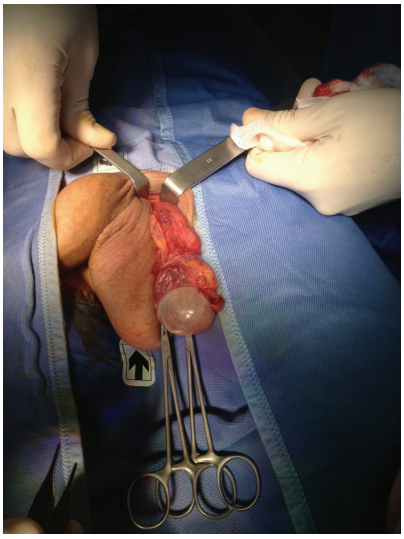

Figure 2: Exposure of left testis. A resection and eversion of the tunica vaginalis was performed in order to remove hydrocele.

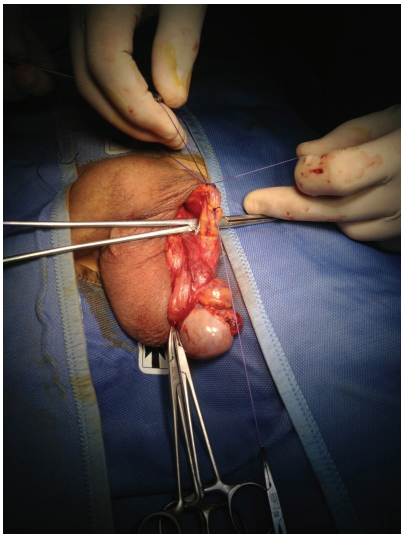

Figure 3: Ligation of the anterior spermatic venous plexus.

Complications of varicocele repair include hydrocele formation, persistence or recurrence of the varicocele, and rarely testicular atrophy [8].

Although no specific recommendations exist as to the optimal surgical technique for varicocelectomy, the use of magnification to preserve lymphatics and testicular arteries is recommended.

We strongly believe that microsurgical varicocelectomy is the gold-standard technique for varicocelectomy in both adults and adolescents, due to lower postoperative recurrence and complication rates compared to other techniques [9].

However, surgery via a scrotal approach was not widespread due to the difficulty of preserving the arterial supply of the testis because the pampiniform plexus of veins encoils the testicular artery at the level of the scrotum. By the way we think that scrotal access is useful in the management of bilateral varicocelectomy in order to avoid two surgical incisions [10] and it can be a valid technique when there are other scrotal comorbidities to be treated.

2. Materials and Methods

We enrolled in our study, from February 2012 to March 2014, 34 adult patients with clinical palpable and infraclinical (ultrasonic doppler scanning) bilateral varicocele and other comorbidities like right hydrocele (6 pts), left hydrocele (8 pt), bilateral hydrocele (8 pts), and epididymal cyst (12 pts).

They underwent scrotal microsurgical bilateral varicocelectomy.

Varicocele has been classified into 4 stages. Before surgery all the patients underwent a complete physical examination, including supine and standing scrotal examination and a color doppler ultrasound examination.

Under local anesthesia, a single incision was made on the median raphe, rather than two incisions at the root of the two hemiscrotums (Figure 1).

Dartos fascia was open, and left testis was exposed by opening the tunica vaginalis in order to remove serous fluid given by a hydrocele. A resection and eversion of the tunica vaginalis was performed (Figure 2).

Using two Farabeuf retractors the left spermatic cord was exposed more proximally until the external inguinal ring and at this level the cremasteric and internal spermatic fascia were opened longitudinally with the exposure of the testicular vein. In this case we performed an en block ligation of the anterior spermatic venous plexus using an absorbable suture (2.0 vicryl) (Figure 3). In our opinion preserving the cremasteric and deferential arteries is enough to supply vascularization to the testis in cases where the testicular artery is damaged.

Cremasteric fascia was closed using an absorbable suture (5.0 vicryl).

The same procedure was performed on the right testis (Figures 4, 5, and 6).

Figure 4: Exposure of the right testis.

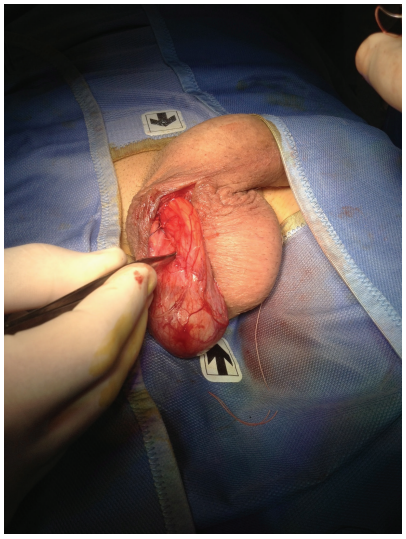

Figure 5: Exposure of the spermatic cord.

Dartos fascia was sutured using a continuous running suture using a 3.0 vicryl.

Skin was closed using 3 stiches in nonabsorbable suture 3.0 Prolene (Figure 7).

Surgery for both testis lasted 30 minutes.

3. Results and Discussion

All patients were evaluated at 1 week, at 3 and 6 months after the operation by means of physical examination, scrotal Doppler ultrasound, and sperm analysis.

None of the patients reported pain at 3-month follow-up.

Edema of the spermatic cord occurred in 12 pts with spontaneous regression at 3-month follow up, and in 2 pts contralateral hydrocele was observed.

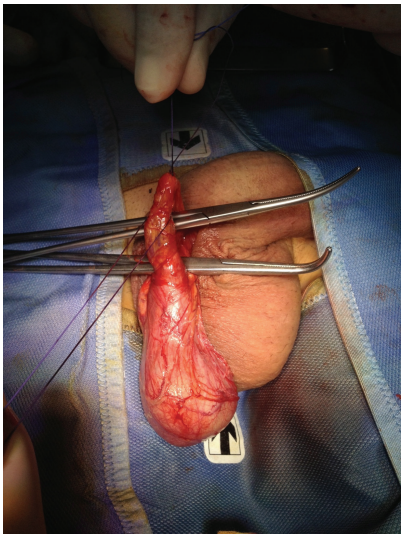

Figure 6: Ligation of the anterior spermatic venous plexus.

Figure 7: Closure of the scrotal incision with 3 nonabsorbable stiches.

At 6 months no other complications were reported.

No case of testicular atrophy was observed.

None had recurrence of varicocele.

In our opinion subinguinal varicocelectomy is the best approach for unilateral varicocele because it has the advantage of allowing the spermatic cord structures to be pulled up and out of the wound so that the testicular artery, lymphatics, and small periarterial veins may be more easily identified and preserved. In addition, subinguinal approach allows access to external spermatic and even gubernacular veins, which may bypass the spermatic cord and result in recurrence if not ligated.

In the early 1900s, an open scrotal approach was employed, involving the mass ligation and excision of the

varicose plexus of veins. At the level of the scrotum, however, the pampiniform plexus of veins is intimately entwined with the coiled testicular artery. For many authors scrotal operations are to be avoided because damage to the arterial supply of the testis frequently results in testicular atrophy. For this reason, in the scrotal approach we expose the spermatic cord more proximally, at level of the external ring, in order to avoid any damage to the testis vascularization (Figure 2).

However, anatomic studies have proved that the diameter of the testicular artery is the main blood supply to the testis being greater than the diameter of the deferential artery and cremasteric artery combined [11].

By the way we believe that the deferential (vasal) artery and, if preserved, the cremasteric artery, will provide adequate blood supply to the testes to prevent atrophy.

4. Conclusions

In our opinion varicocele repair must be proposed in young adult men with impairment of seminal parameters. Patients with bilateral varicocele prefer a single incision. When the incision is made on the median raphe, no scars remain. In bilateral varicocele with other scrotal comorbidities the single approach reduces invasiveness and increases patient satisfaction.

Conflict of Interests

The authors declare that there is no conflict of interests regarding the publication of this paper.

References

[1] O. Steeno, J. Knops, L. Declerck, A. Adimoelja, and H. van de Voorde, "Prevention of fertility disorders by detection and treatment of varicocele at school and college age," *Andrologia*, vol. 8, no. 1, pp. 47–53, 1976.

[2] E. Sabanegh and A. Agarwal, "Male infertility," in *Campbell-Walsh Urology*, A. J. Wein, L. R. Kavoussi, A. C. Novick, and A. W. Partin, Eds., pp. 636–637, Saunders, Philadelphia, Pa, USA, 10th edition, 2012.

[3] S. A. Said, A. Aribarg, P. Virutamsen et al., "The influence of varicocele on parameters of fertility in a large group of men presenting to infertility clinics," *Fertility and Sterility*, vol. 57, no. 6, pp. 1289–1293, 1992.

[4] A. Agarwal, F. Deepinder, M. Cocuzza et al., "Efficacy of varicocelectomy in improving semen parqameters: new meta-analytical approach," *Urology*, vol. 70, no. 3, pp. 532–538, 2007.

[5] A. Zini and G. Dohle, "Are varicoceles associated with increased deoxyribonucleic acid fragmentation?" *Fertility and Sterility*, vol. 96, no. 6, pp. 1283–1287, 2011.

[6] A. V. Hirsh, K. M. Cameron, J. P. Tyler, J. Simpson, and J. P. Pryor, "The Doppler assessment of varicoceles and internal spermatic vein reflux in infertile men," *British Journal of Urology*, vol. 52, no. 1, pp. 50–56, 1980.

[7] M. H. Nasr-Esfahani, H. Abasi, S. Razavi, S. Ashrafi, and M. Tavalaee, "Varicocelectomy: semen parameters and protamine deficiency," *International Journal of Andrology*, vol. 32, no. 2, pp. 115–122, 2009.

[8] M. Goldstein, "Surgical management of male infertility," in *Campbell-Walsh Urology*, A. Wein, L. R. Kavoussi, A. C. Novick, A. W. Partin, and C. A. Peters, Eds., pp. 648–987, Elsevier Saunders, Philadelphia, Pa, USA, 2012.

[9] P. Mirilas and A. Mentessidou, "Microsurgical subinguinal varicocelectomy in children, adolescents, and adults: surgical anatomy and anatomically justified technique," *Journal of Andrology*, vol. 33, no. 3, pp. 338–349, 2012.

[10] F. Iacono, G. Capparelli, and M. D'Armiento, "Bilateral varicocele repair by transscrotal extratunica vaginalis procedure in outpatients: a novel technique," *Techniques in Urology*, vol. 6, no. 3, pp. 196–200, 2000.

[11] J. D. Raman and M. Goldstein, "Intraoperative characterization of arterial vasculature in spermatic cord," *Urology*, vol. 64, no. 3, pp. 561–564, 2004.

Hindawi Publishing Corporation
BioMed Research International
Volume 2014, Article ID 121396, 7 pages
http://dx.doi.org/10.1155/2014/121396

Clinical Study

Alga *Ecklonia bicyclis*, *Tribulus terrestris*, and Glucosamine Oligosaccharide Improve Erectile Function, Sexual Quality of Life, and Ejaculation Function in Patients with Moderate Mild-Moderate Erectile Dysfunction: A Prospective, Randomized, Placebo-Controlled, Single-Blinded Study

Salvatore Sansalone,[1] Rosario Leonardi,[2] Gabriele Antonini,[3] Antonio Vitarelli,[4] Giuseppe Vespasiani,[1] Dragoslav Basic,[5] Giuseppe Morgia,[6] Sebastiano Cimino,[6] and Giorgio Ivan Russo[6]

[1] *Department of Experimental Medicine and Surgery, Tor Vergata University of Rome, Rome, Italy*
[2] *Centro Uro Andrologico, Acireale, Italy*
[3] *Department of Urology "U. Bracci", La Sapienza University of Rome, Rome, Italy*
[4] *Urologia Universitaria II, Azienda Ospedaliera Policlinico Bari, Bari, Italy*
[5] *Clinic of Urology, Clinical Center Nis, Nis, Serbia*
[6] *School of Medicine Policlinico Hospital, Department of Urology, University of Catania, Catania, Italy*

Correspondence should be addressed to Giorgio Ivan Russo; giorgioivan@virgilio.it

Received 18 March 2014; Accepted 1 June 2014; Published 20 July 2014

Academic Editor: Ralf Herwig

Copyright © 2014 Salvatore Sansalone et al. This is an open access article distributed under the Creative Commons Attribution License, which permits unrestricted use, distribution, and reproduction in any medium, provided the original work is properly cited.

We aimed to evaluate the efficacy of oral therapy with alga *Ecklonia bicyclis*, *Tribulus terrestris*, and glucosamine oligosaccharide (Tradamix TX1000) in patients with erectile dysfunction (ED) at 3 months of follow-up. From January 2013 to September 2013, 177 patients diagnosed with mild-moderate ED (IIEF-EF< 26) were enrolled in this multicenter, single-blinded, placebo-controlled study and randomized in Group A (Tradamix, $n = 87$) and Group B (placebo, $n = 90$). Penile color Doppler ultrasound measures, IIEF-15 questionnaire, male sexual health questionnaire-ejaculation disorder (MSHQ-EjD), and sexual quality of life (SQoL-M) were collected. We observed significant changes of the IIEF-15 in Group A (mean difference: 11.54; $P < 0.05$) at 3 months versus Group B ($P < 0.05$). PSV ($P < 0.05$), IIEF-intercourse satisfaction ($P < 0.05$), IIEF-orgasmic function (mean $P < 0.05$), IIEF-sexual desire ($P < 0.05$), IIEF-overall satisfaction ($P < 0.05$), MSHQ-EjD (mean difference: 1.21; $P < 0.05$), and SQoL-M (mean difference: 10.2; $P < 0.05$) were significantly changed in Group A versus baseline and Group B. Patients with moderate arterial dysfunction showed significant increase of PSV ($P < 0.05$), IIEF-EF ($P < 0.05$), MSHQ-EjD ($P < 0.05$), and SQoL-M ($P < 0.05$) in Group A. Therapy with Tradamix improves erectile and ejaculation function and sexual quality of life in patients with mild-moderate ED and in particular for those with moderate arterial dysfunction.

1. Introduction

All over the world, erectile dysfunction (ED) is considered one of the most diffuse sexual disorders. The prevalence rate of ED increases with age and with concomitant morbidities. To this regard, erectile dysfunction (ED) has progressively emerged as an important indicator of men's overall health, due to the very closed relationship to concomitant comorbidities [1–4].

Several observational studies recently demonstrated that ED is associated with different comorbid condition and overall poorer male health [5, 6], but also ED may significantly

increase the risk of cardiovascular disease (CVD), coronary heart disease, stroke [7], and all-cause mortality [8–11], and this increase is probably independent from conventional cardiovascular risk factors [9] and glycometabolic control [12].

Based on these considerations, phosphodiesterase-5 inhibitors (PDE5-i) have become the most popular treatment and are currently the first line monotherapy for ED [13].

However, it should be taken into account that some patients with complex ED may not be responders to PDE5-I monotherapy [14]. Furthermore, this category of drugs is not depicted from side effects that could impair pharmacological adherence.

The most common reported side effects are headache, muscular pains, hot flushes, tearing, and so on that can affect normal sexual intercourse [15]. It is also generally known that ED may be associated with serum total testosterone (TT) alterations. In fact, TT in men begins to decline in the late third or early fourth decade and diminish at a constant rate thereafter [16].

In this general context, studies on natural compounds have been conducted with the intention to limit side effects and to maintain efficacy [17, 18]. A new natural compound made of alga *Ecklonia bicyclis*, *Tribulus terrestris*, and glucosamine oligosaccharide has been diffused in order to improve male sexual function in elderly men, particularly libido and possible erectile dysfunction. *Ecklonia bicyclis* has radical scavenger activity 10–100 times more powerful than any other polifenol terrestris plants, which have only 3-4 phenolic and rings that are commonly considered among the most effective antioxidant molecules. The protodioscin is a steroidal saponin, which is about 90% of the extract obtained from aerial parts of *Tribulus terrestris*. Thanks to its particular steroidal structure it has an androgen mimetic action, binding and activating the receptor of testosterone. So this substance is able to increase the endogenous production of testosterone, dihydrotestosterone, hormone luteinizing hormone (LH), dehydroepiandrosterone (DHEA), and dehydroepiandrosterone sulfate (DHEAS).

glucosamine oligosaccharide acts both on nonadrenergic and noncholinergic system (NANC) and on endothelial cell system as a strong nitric oxide synthetase (NOS) simulator [16].

The aim of this prospective multicenter randomized, single-blinded, placebo-controlled study was to evaluate the efficacy and tolerability of the combination therapy with alga *Ecklonia bicyclis*, *Tribulus terrestris*, and glucosamine oligosaccharide in patients mild-moderate erectile dysfunction at 3 months of follow-up.

2. Patients and Methods

From January 2013 to September 2013, 214 patients diagnosed with mild-moderate ED (IIEF-EF < 26) were entered in this prospective multicenter randomized, single-blinded, placebo-controlled study. All subjects gave written informed consent before entering the study, which was conducted in accordance with the Declaration of Helsinki, and the Human Ethics Committee approved the study protocol (Serbian Ministry Of Education and Science, Grant No175092). All patients underwent preliminary assessment including a detailed medical and sexual history to evaluate the presence of risk factors such as diabetes mellitus, hypertension, dyslipidaemia, and smoking. All subjects were self-administered the IIEF-15 item questionnaire and the Male Sexual Health Ques-tionnaire-Ejaculation Disorder (MSHQ-EjD) and sexual quality of life instrument for men (SQoL-M).

The primary inclusion criteria were a minimum age of 18 years, a diagnosis of nonendocrinological ED according to the National Institutes of Health statement on ED, 1 naïve to treatment for ED, a stable heterosexual relationship for at least the previous 6 months, and a steady relationship with the same female partner.

Exclusion criteria were as follows: severe ED (IIEF-EF < 11), previous medical or surgical treatments for ED, any medical treatment for sexual dysfunction before or during the study, congenital or acquired penile curvature or chordee with hypospadias, age >75 years, hypogonadism (total testosterone level of <8 nmol or serum testosterone in the range of 8–11 nM and free testosterone <220 pmol, assessed at least on two occasions), and end diastolic velocity (EDV) >5 cm/s at penile color doppler ultrasound (CDU).

All patients were also subjected to a thorough physical examination. To be able to exclude organic sexual dysfunctions and other underlying illnesses, fasting blood glucose level, urinalysis, complete blood count, sex hormones, and prolactin levels were measured.

All measurements were conducted by a single physician unaware of the treatment status.

Patients were randomized according to a computer generated random sequence with a 1 : 1 ratio in two treatment groups, namely, Group A and Group B. The first group received one tablet orally twice a day for 3 months and one tablet consisted of 300 mg of alga *Ecklonia bicyclis*, 450 mg of *Tribulus terrestris* and 250 mg of glucosamine oligosaccharide (Tradamix TX1000, Tradapharma Sagl, Switzerland), while the second received one table twice a day for 3 months of placebo. We monitored adverse events on the light of common terminology criteria for adverse events (CTCAE) guidelines.

2.1. Main Outcome Measures. The primary efficacy outcome was the change from baseline to end point (3 months) for the IIEF-15. Secondary outcomes were the change from baseline to end point of IIEF-15 subscore, MSHQ-EJD, SQoL-M, and PSV. Safety assessments included treatment-emergent adverse events (TEAEs), serious AEs (SAEs), and orthostatic vital signs (blood pressure and heart rate).

2.2. Study Population. The study sample of 170 was powered for an approximately 10-point difference of the IIEF-15 using a two-sided type I error = 0.05 and type II error = 0.1 (90% power), requiring patients per group. The maximum sample size was set to 100 subjects per group, allowing for a 15% dropout rate.

Table 1: Baseline characteristics of patients enrolled.

	Group A (TRADAMIX TX 1000)	Group B (Placebo)
Number of patients	87	90
Age (yr), mean ± SD	63.92 ± 9.3	65.37 ± 8.81
BMI (Kg/m^2), mean ± SD	26.36 ± 3.0	25.2 ± 3.5
Hypertension, *n* (%)	40 (44.94)	42 (46.66)
Dyslipidemia, *n* (%)	24 (27.58)	2 (25.5)
Diabetes, *n* (%)	17 (19.54)	18 (20.0)
Total testosterone, mean	14.69 ± 1.25	13.26 ± 1.02
Smoking habit, *n* (%)	40 (39.21)	38 (38.0)
IIEF-EF, mean ± SD	21.16 ± 4.08	20.71 ± 3.77
IIEF-IS, mean ± SD	5.80 ± 2.07	6.06 ± 1.91
IIEF-OF, mean ± SD	5.11 ± 1.23	5.37 ± 1.37
IIEF-SD, mean ± SD	7.97 ± 1.69	7.80 ± 1.81
IIEF-OS, mean ± SD	4.89 ± 1.66	4.86 ± 1.44
MSHQ-EjD, mean ± SD	14.89 ± 3.09	14.50 ± 2.87
SQoL-M, mean ± SD	54.21 ± 2.11	55.87 ± 2.35
PSV, mean ± SD	31.52 ± 6.60	30.02 ± 5.56
EDV, mean ± SD	1.5 ± 1.0	1.2 ± 2.0
Normal arterial function (PSV ≥ 35 cm/s), *n* (%)	36 (35.3)	30 (33.3)
Moderate arterial dysfunction (PSV ≥ 25 and <35 cm/s), *n* (%)	31 (30.4)	29 (32.2)
Severe arterial dysfunction (PSV < 25 cm/s), *n* (%)	20 (19.6)	22 (24.4)

BMI = Body Mass Index; IIEF-EF = International Index of Erectile Function-Erectile Function; IIEF-IS = International Index of Erectile Function-Intercourse Satisfaction; IIEF-OF = International Index of Erectile Function-Orgasmic Function; IIEF-SD = International Index of Erectile Function-Sexual Desire; IIEF-OS = International Index of Erectile Function-Overall Satisfaction; MSHS-EJD = Male Sexual Health Questionnaire-Ejaculation Disorder; SQoL-M = sexual quality of life instrument for men; PSV = peak systolic velocity; EDV = end diastolic velocity.

2.3. Statistical Analysis. At baseline, the independent sample 2-tailed *t*-test was used to compare variables. For categorical parameters, chi-square test was applied. Changes from baseline to end of therapy were analysed using ranked one-way analysis of variance (ANOVA) with a term for treatment group. According to the penile Doppler ultrasound analysis, patients were divided into three categories: normal arterial function (NAF) (PSV ≥ 35 cm/s), moderate arterial dysfunction (MAD) (PSV ≥ 25 and <35 cm/s), and severe arterial dysfunction (SAD) (PSV < 25 cm/s). Treatment group differences for primary and secondary end points were determined using post hoc analysis. Data were reported as means ± standard deviation (SD) or median and nominal P values were presented. For all statistical comparisons, significance was considered as $P < 0.05$.

3. Results

Table 1 lists the baseline characteristics of patients enrolled. Of the 214 patients, 14 (6.54%) were excluded from the study because they did not meet the entry criteria. Of the 200 patients randomized, 87 and 90 subjects in Group A and in Group B completed the study protocol. The flow chart of this study is presented in Figure 1.

3.1. Main Outcome Measures. Table 2 lists the mean change differences from baseline to 3 months relative to main outcome measures. When concerning the primary endpoint of this study, we observed significant changes of the IIEF-15 in Group A (mean difference: 11.54; $P < 0.05$) at 3 months versus Group B at the intergroup analysis (mean difference: 10.22; $P < 0.05$). In Group A, significant differences from baseline to last follow-up were observed relative to PSV (mean difference: 1.36 cm/s; $P < 0.05$), IIEF-IS (mean difference: 1.72; $P < 0.05$), IIEF-OF (mean difference: 2.2; $P < 0.05$), IIEF-SD (mean difference: 1.03; $P < 0.05$), IIEF-OS (mean difference: 2.51; $P < 0.05$), MSHQ-EjD (mean difference: 1.21; $P < 0.05$), and SQoL-M (mean difference: 10.2; $P < 0.05$). In Group A, patients with moderate arterial dysfunction showed significant increase of IIEF-EF (mean difference: 1.82; $P < 0.05$), PSV (mean difference: 1.56; $P < 0.05$), MSHQ-EjD (mean difference: 1.23; $P < 0.05$), and SQoL-M (mean difference: 11.65; $P < 0.05$) from baseline to 3 months. Significant differences were found at the intergroup analysis when considering previous outcome measures (Table 2) and (Figure 2). Patients with normal arterial function and with severe arterial dysfunction of Group A did not report improvement of penile CDU measures after treatment. When considering serum TT and EDV, both groups did not show any difference after 3 months. All subjects included in the study protocol tolerated treatments, and none reported adverse events.

4. Discussion

Several studies have established that reactive oxygen ROS, especially superoxide anion and hydrogen peroxide, are important signaling molecules in cardiovascular cells [19, 20]. Enhanced superoxide production increases NO inactivation and leads to an accumulation of peroxynitrites and hydrogen peroxide [21]. ROS participate in growth, apoptosis, and the migration of vascular smooth muscle cells, in the modulation of endothelial function (including endothelium-dependent relaxation and expression of a proinflammatory phenotype), and in the modification of the extracellular matrix [22–24]. All of these events play important roles in endothelial dysfunction, suggesting that the sources of ROS and the signaling pathways that they modify may represent important therapeutic targets [25].

All these findings have determined the diffusion of several herbal extract with the intention of targeting previous pathways.

An interesting in vivo and in vitro animal investigations of a mixture of herbal extracts from *T. terrestris* and *C. officinalis* were conducted to investigate their relaxation effects and the mechanisms of action on penile erection. *T. terrestris* extract, *C. officinalis* extract, and the mixture of both extracts showed concentration-dependent relaxation effects

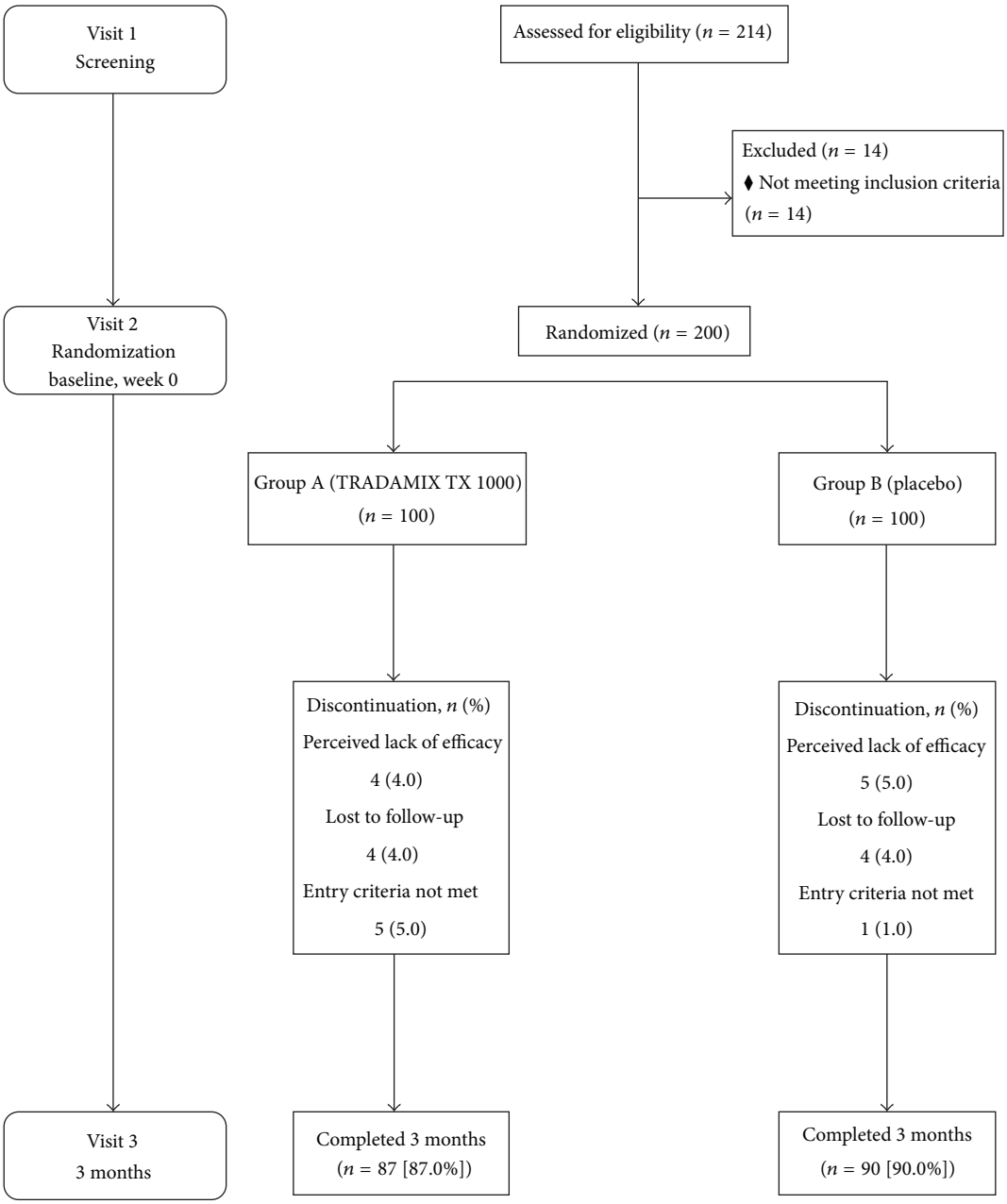

Figure 1: Disposition of subjects. Subject consolidated standards of reporting trials (CONSORT) diagram.

of the corpus cavernosum. Therefore, endothelium appears to be an important location of action of *T. terrestris* extract, functioning in relaxation mainly via NOS and exhibited relaxation effects mainly through cAMP and partly through cGMP [26].

It can be supposed that because herbal extracts do not contain a single ingredient but are a combination of multiple compounds, it would not be appropriate to expect a mechanism of action similar to that of a single compound such as a PDE-5 inhibitor. *C. officinalis* extract appears to exhibit relaxation effects by acting directly on the smooth muscle cells of the CC, not through the above pathway. With the administration of the mixture of extracts, cAMP concentration in the CC increased significantly. Based on the previous results, the extracts studied appear to exhibit relaxation effects on the CC mainly through cAMP and partly through cGMP.

This can be explained by the multiple mechanism of action of these compounds on several targets with the consequent therapeutical efficacy.

Based on our results and considering all subdomains of 15-question International Index of Erectile Function, therapy with multiple antioxidants was significantly superior in improving intercourse satisfaction, sexual desire, orgasmic

Table 2: Mean changes from baseline to 3 months for primary and secondary outcomes.

	Group A	Group B
IIEF-15, mean ± SD	11.54 ± 2.47[a,b]	1.32 ± 2.67
IIEF-EF, mean ± SD	0.35 ± 1.42	0.04 ± 1.00
IIEF-IS, mean ± SD	1.72 ± 1.63[a,b]	0.05 ± 2.15
IIEF-OF, mean ± SD	2.20 ± 1.51[a,b]	0.08 ± 1.77
IIEF-SD, mean ± SD	1.03 ± 1.35[a,b]	0.41 ± 0.34
IIEF-OS, mean ± SD	2.51 ± 1.45[a,b]	0.57 ± 0.39
MSHQ-EjD, mean ± SD	1.21 ± 2.03[a,b]	0.24 ± 1.07
SQoL-M, mean ± SD	10.20 ± 3.77[a,b]	1.24 ± 2.53
PSV (cm/s), mean ± SD	1.36 ± 0.75[a,b]	0.21 ± 0.44
EDV (cm/s), mean ± SD	0.24 ± 1.0	0.31 ± 0.9
Total testosterone (nmol/L), mean ± SD	14.26 ± 2.05	13.31 ± 1.32
Normal arterial function (PSV ≥35 cm/s) subgroup		
IIEF-EF, mean ± SD	0.94 ± 3.68	0.10 ± 4.10
PSV (cm/s), mean ± SD	0.16 ± 0.75	0.10 ± 0.87
MSHQ-EJD, mean ± SD	1.41 ± 1.85[a,b]	0.32 ± 1.54
SQoL-M, mean ± SD	8.76 ± 3.65	1.41 ± 3.21
Moderate arterial dysfunction (PSV ≥25 and <35 cm/s) subgroup		
IIEF-EF, mean ± SD	1.82 ± 3.08[a,b]	0.16 ± 2.69
PSV (cm/s), mean ± SD	1.56 ± 0.82[a,b]	0.23 ± 0.63
MSHQ-EJD, mean ± SD	1.23 ± 1.84[a,b]	0.11 ± 1.52
SQoL-M, mean ± SD	11.65 ± 3.12[a,b]	1.18 ± 2.87
Severe arterial dysfunction (PSV <25 cm/s) subgroup		
IIEF-EF, mean ± SD	0.54 ± 2.77	0.23 ± 2.41
PSV (cm/s), mean ± SD	0.05 ± 0.52	0.09 ± 0.74
MSHQ-EJD, mean ± SD	0.90 ± 2.56	0.25 ± 2.31
SQoL-M, mean ± SD	2.43 ± 2.89	1.21 ± 3.44

[a] $P < 0.05$ versus baseline; [b] $P < 0.05$ versus Group B.

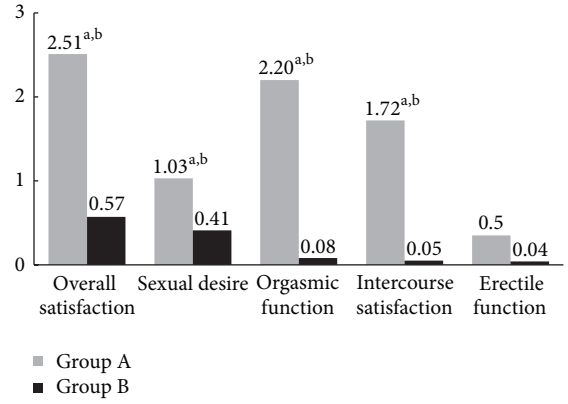

Figure 2: Mean changes from baseline to 3 months for International Index of Erectile Function domain ([a] $P < 0.05$, versus baseline; [b] $P < 0.05$, versus Group B).

function, and overall satisfaction. In fact, it should be noted that the severity of penile curvature or deformity may significantly contribute to man's inability to have intercourse.

Furthermore, patients referred the improvement of ejaculation and quality of life, as assessed by the MSHQ-EjD and the SQoL-M), although there was a short follow-up.

This new natural compound is thought to play an important double role (therapeutic and antiaging), on cavernous tissue, by acting on the etiopathogenetic aspects of ED, mainly the microstructural alteration of the corpus cavernosum tissues, following inflammation and/or oxidative damage [16].

We suppose that this combination of natural compounds may strength the efficacy of the single component, the *Ecklonia bicyclis* by a radical scavenger activity, the protodioscin by binding and activating the receptor of testosterone, and the glucosamine oligosaccharide, by acting on the nonadrenergic and noncholinergic system (NANC) and on the endothelial cell system as a strong nitric oxide synthetase (NOS) stimulator, thus improving the concentration of nitric oxide (NO) in the smooth cells inside the corpus cavernosum.

These considerations may explain the significant changes of IIEF-EF, MSHQ-EjD, PSV, and SQoL-M in Group A for men with moderate arterial penile dysfunction. We can affirm in fact that those with severe arterial dysfunction may not have benefits from therapy with natural compounds, since their ED was worse.

Penile CDU evaluation in ED has a significant role in determining the cause of ED. Arteriogenic ED or arterial insufficiency is diagnosed when PSV is <25 cm/s, with angiographic correlation showing that a PSV threshold of 25 cm/s has 92% accuracy in diagnosis of arterial integrity. Penile CDU represents an accurate tool to investigate cavernous artery inflow and venous leakage frequently used for assessing the efficacy of several genitourethral reconstruction surgical techniques, in patients who underwent urethroplasty, peyronie's disease related surgery, or penile revascularization [27, 28].

In this context, although the prevalence of ED before and after genitourethral reconstruction surgeries has not been correctly investigated, it may affect the expectancy of these techniques with failed results.

Although our population study was represented by subjects who did not underwent previous genitourethral reconstruction surgeries, we may suggest with caution to use oral therapy with alga *Ecklonia bicyclis*, *Tribulus terrestris*, and glucosamine oligosaccharide with the intention to ameliorate penile CDU in patients eligible for penile surgery.

However, this study is not depicted from limitations. First of all a longer follow-up would have added more information about the efficacy and its maintenance over the time. Second, ED was assessed by questionnaire and penile Doppler ultrasound and ejaculation function by the MSHQ-ED. Certainly, some more diagnostic procedures would have been beneficial. In conclusion, oral therapy with alga *Ecklonia bicyclis*, *Tribulus terrestris*, and glucosamine oligosaccharide has significant advantages in patients with mild-moderate

ED, by improving intercourse satisfaction, sexual desire, orgasmic function, overall satisfaction, ejaculation function, and quality of life. Further clinical study, involving a general population eligible for genitourethral reconstruction surgery may offer new insight about the efficacy of combination with alga *Ecklonia bicyclis*, *Tribulus terrestris*, and glucosamine oligosaccharide.

5. Conclusion

Patients affected by mild-moderate ED may significantly benefit from oral therapy with alga *Ecklonia bicyclis*, *Tribulus terrestris*, and glucosamine oligosaccharide by improving sexual and ejaculation function and sexual quality of life. In particular, those with moderate arterial dysfunction, considered as a peak systolic velocity (PSV) ≥25 and <35 cm/s, may significantly benefit from this therapy thanks to the improvement of IIEF-EF, MSHQ, SQoL-M, and PSV.

Conflict of Interests

The authors declare that there is no conflict of interests regarding the publication of this paper.

References

[1] P. Montorsi, P. M. Ravagnani, S. Galli et al., "Association between Erectile Dysfunction and Coronary Artery Disease: matching the Right Target with the right test in the right patient," *European Urology*, vol. 50, no. 4, pp. 721–731, 2006.

[2] J. I. Mäkinen, A. Perheentupa, O. T. Raitakari, M. Koskenvuo, P. Pöllänen, and I. Huhtaniemi, "Sexual symptoms in aging men indicate poor life satisfaction and increased health service consumption," *Urology*, vol. 70, no. 6, pp. 1194–1199, 2007.

[3] G. Jackson, R. C. Rosen, R. A. Kloner, and J. B. Kostis, "The second Princeton consensus on sexual dysfunction and cardiac risk: new guidelines for sexual medicine," *The Journal of Sexual Medicine*, vol. 3, no. 1, pp. 28–36, 2006.

[4] V. Favilla, S. Cimino, C. Salamone et al., "Risk factors of sexual dysfunction after transurethral resection of the prostate (TURP): a 12 months follow-up," *Journal of Endocrinological Investigation*, vol. 36, pp. 1094–1098, 2013.

[5] A. Salonia, G. Castagna, A. Saccà et al., "Is erectile dysfunction a reliable proxy of general male health status? The case for the international index of erectile function-erectile function domain," *The Journal of Sexual Medicine*, vol. 9, no. 10, pp. 2708–2715, 2012.

[6] R. O. Rosen, W. A. Fisher, I. Eardley, C. Niederberger, A. Nadel, and M. Sand, "The multinational Men's Attitudes to Life Events and Sexuality (MALES) study: I. Prevalence of erectile dysfunction and related health concerns in the general population," *Current Medical Research and Opinion*, vol. 20, no. 5, pp. 607–617, 2004.

[7] K.-K. Chew, J. Finn, B. Stuckey et al., "Erectile dysfunction as a predictor for subsequent atherosclerotic cardiovascular events: findings from a linked-data study," *The Journal of Sexual Medicine*, vol. 7, no. 1, pp. 192–202, 2010.

[8] C. Vlachopoulos, K. Rokkas, N. Ioakeimidis, and C. Stefanadis, "Inflammation, metabolic syndrome, erectile dysfunction, and coronary artery disease: common links," *European Urology*, vol. 52, no. 6, pp. 1590–1600, 2007.

[9] J.-Y. Dong, Y.-H. Zhang, and L.-Q. Qin, "Erectile dysfunction and risk of cardiovascular disease: meta-analysis of prospective cohort studies," *Journal of the American College of Cardiology*, vol. 58, no. 13, pp. 1378–1385, 2011.

[10] B. P. Gupta, M. H. Murad, M. M. Clifton, L. Prokop, A. Nehra, and S. L. Kopecky, "The effect of lifestyle modification and cardiovascular risk factor reduction on erectile dysfunction: a systematic review and meta-analysis," *Archives of Internal Medicine*, vol. 171, no. 20, pp. 1797–1803, 2011.

[11] G. I. Russo, S. Cimino, E. Fragala et al., "Insulin resistance is an independent predictor of severe lower urinary tract symptoms and of erectile dysfunction: results from a cross-sectional study," *The Journal of Sexual Medicine*, 2014.

[12] R. C. Ma, W. So, X. Yang et al., "Erectile dysfunction predicts coronary heart disease in type 2 diabetes," *Journal of the American College of Cardiology*, vol. 51, no. 21, pp. 2045–2050, 2008.

[13] K. Hatzimouratidis, E. Amar, I. Eardley et al., "Guidelines on male sexual dysfunction: erectile dysfunction and premature ejaculation," *European Urology*, vol. 57, no. 5, pp. 804–814, 2010.

[14] A. Tsertsvadze, F. Yazdi, H. A. Fink et al., "Oral sildenafil citrate (viagra) for erectile dysfunction: a systematic review and meta-analysis of harms," *Urology*, vol. 74, no. 4, pp. 831.e8–836.e8, 2009.

[15] P. Dorsey, C. Keel, M. Klavens, and W. J. G. Hellstrom, "Phosphodiesterase type 5 (PDE5) inhibitors for the treatment of erectile dysfunction," *Expert Opinion on Pharmacotherapy*, vol. 11, no. 7, pp. 1109–1122, 2010.

[16] F. Iacono, D. Prezioso, E. Illiano, G. Romeo, A. Ruffo, and B. Amato, "Sexual asthenia: Tradamixina versus Tadalafil 5 mg daily," *BMC Surgery*, vol. 12, supplement 1, article S23, 2012.

[17] V. Favilla, G. I. Russo, S. Privitera et al., "Combination of intralesional verapamil and oral antioxidants for Peyronie's disease: a prospective, randomised controlled study," *Andrologia*, 2013.

[18] G. Morgia, S. Cimino, V. Favilla et al., "Effects of Serenoa repens, selenium and lycopene (Profluss) on chronic inflammation associated with benign prostatic hyperplasia: results of "FLOG" (Flogosis and Profluss in Prostatic and Genital Disease), a multicentre Italian study," *International Brazilian Journal of Urology*, vol. 39, no. 2, pp. 214–221, 2013.

[19] M. K. Cathcart, "Regulation of superoxide anion production by NADPH oxidase in monocytes/macrophages: contributions to atherosclerosis," *Arteriosclerosis, Thrombosis, and Vascular Biology*, vol. 24, no. 1, pp. 23–28, 2004.

[20] K. K. Griendling, D. Sorescu, and M. Ushio-Fukai, "NAD(P)H oxidase: role in cardiovascular biology and disease," *Circulation Research*, vol. 86, no. 5, pp. 494–501, 2000.

[21] E. Vicari, S. la Vignera, R. Condorelli, and A. E. Calogero, "Endothelial antioxidant administration ameliorates the erectile response to PDE5 regardless of the extension of the atherosclerotic process," *Journal of Sexual Medicine*, vol. 7, no. 3, pp. 1247–1253, 2010.

[22] P. Li, R. Dietz, and R. Von Harsdorf, "Differential effect of hydrogen peroxide and superoxide anion on apoptosis and proliferation of vascular smooth muscle cells," *Circulation*, vol. 96, no. 10, pp. 3602–3609, 1997.

[23] L. Minutoli, A. Bitto, F. Squadrito et al., "Serenoa repens, lycopene and selenium: a triple therapeutic approach to manage benign prostatic hyperplasia," *Current Medicinal Chemistry*, vol. 20, no. 10, pp. 1306–1312, 2013.

[24] L. Vanella, G. I. Russo, S. Cimino, E. Fragala, V. Favilla, and G. li Volti, "Correlation between lipid profile and heme oxygenase system in patients with benign prostatic hyperplasia," *Urology*, vol. 83, no. 6, pp. 1444.e7–1444.e13, 2014.

[25] S. la Vignera, R. Condorelli, E. Vicari, R. D'agata, and A. E. Calogero, "Endothelial antioxidant compound prolonged the endothelial antiapoptotic effects registered after tadalafil treatment in patients with arterial erectile dysfunction," *Journal of Andrology*, vol. 33, no. 2, pp. 170–175, 2012.

[26] S. C. Kam, J. M. Do, J. H. Choi, B. T. Jeon, G. S. Roh, and J. S. Hyun, "In vivo and in vitro animal investigation of the effect of a mixture of herbal extracts from Tribulus terrestris and Cornus officinalis on penile erection," *Journal of Sexual Medicine*, vol. 9, no. 10, pp. 2544–2551, 2012.

[27] E. Chung, H. Yan, L. de Young, and G. B. Brock, "Penile Doppler sonographic and clinical characteristics in Peyronie's disease and/or erectile dysfunction: an analysis of 1500 men with male sexual dysfunction," *BJU International*, vol. 110, no. 8, pp. 1201–1205, 2012.

[28] O. Kayigil, E. Okulu, M. Aldemir, and E. Onen, "Penile revascularization in vasculogenic erectile dysfunction (ED): long-term follow-up," *BJU International*, vol. 109, no. 1, pp. 109–115, 2012.

Hindawi Publishing Corporation
BioMed Research International
Volume 2014, Article ID 240761, 5 pages
http://dx.doi.org/10.1155/2014/240761

Clinical Study

Neovaginal Prolapse in Male-to-Female Transsexuals: An 18-Year-Long Experience

Stefano Bucci, Giorgio Mazzon, Giovanni Liguori, Renata Napoli, Nicola Pavan, Susanna Bormioli, Giangiacomo Ollandini, Bernardino De Concilio, and Carlo Trombetta

Department of Urology, Cattinara Hospital, University of Trieste, Strada di Fiume 447, 34149 Trieste, Italy

Correspondence should be addressed to Giorgio Mazzon; giorgio_mazzon@libero.it

Received 19 February 2014; Accepted 29 March 2014; Published 7 May 2014

Academic Editor: Ralf Herwig

Copyright © 2014 Stefano Bucci et al. This is an open access article distributed under the Creative Commons Attribution License, which permits unrestricted use, distribution, and reproduction in any medium, provided the original work is properly cited.

Neovaginal prolapse is a rare and distressing complication after male-to-female sexual reassignment surgery. We retrospectively analysed the prevalence of partial and total neo-vaginal prolapses after sexual reassignment surgery in our institute. During the years, two different techniques have been adopted with the aim of fixing the neovaginal cylinder. In the first, two absorbable sutures are placed at the top of the penoscrotal cylinder and fixed to the Denonvilliers fascia. In the second, two additional sutures are added from the posterior/midpoint of the flap to the prerectal fascia. We enrolled 282 consecutive transsexual patients. 65 (23.04%) out of the 282 were treated with the first technique and the following 217 (76.96%) with the last technique. In the first technique, 1 case (1.53%) of total prolapse and 7 cases (10.76%) of partial prolapse were observed, while in the other 217 patients treated with the second technique only 9 cases of partial prolapse were observed (4.14%) and no cases of total prolapse. All prolapses occurred within 6 months from the procedure. In our experience, the use of 4 stitches and a more proximal positioning of the sutures to fix the penoscrotal apex with the Denonvilliers fascia guarantees a lower risk of prolapse.

1. Introduction

The final goal of androginoid sex reassignment surgery (SRS) is the creation of a feminine, functional and well-vascularised perinea-genital complex, free of poorly healed areas, scars, and neuromas. Ideally, the neovagina should be 10 cm in depth and about 30 mm in diameter. Moreover, it should be fashioned with moist, elastic, and hairless epithelium [1].

For decades, several techniques have been proposed, but, as suggested by Sutcliffe et al. in a systematic review, no operative standards of care are available in this particular surgical field [2].

These procedures expose patients to several possible early and late complications, leading to loss of aesthetic and functional satisfaction.

Specifically, neovaginal prolapse after sexual reassignment surgery in male-to-female transsexuals is a distressing complication for both patient and surgeon, leading to bad aesthetic and functional outcomes and can sometimes be difficult to correct. The frequency of this complication is difficult to ascertain, and literature only reports single cases (since the anatomic circumstances preceding the operation and the postoperative course are often not known).

Several authors have reported their outcomes after SRS but all of them enrolled a low number of patients, so the real incidence of neovaginal prolapse is not well known.

Perovic et al. in 89 consecutive transsexual male-to-female patients using penile skin and urethral flap had no reported cases of neovaginal prolapse [3].

Similarly, Krege et al. reported 2 cases of prolapse out of 66 patients who had undergone male-to-female SRS by penoscrotal flap vaginoplasty. However, authors did not specify if the prolapses were partial or total [4].

Finally, Djordjevic et al. [5] reported a series of 86 consecutive rectosigmoid vaginoplasties. In their experience 7 cases (8.1%) of partial vaginal prolapse were observed. However, this series comprehends both transsexual patients as well as females affected by vaginal agenesia or who had undergone vaginectomies for genital trauma. All vaginal prolapses were repaired by minor surgery.

Figure 1: Partial neovaginal prolapse.

Figure 2: Total neovaginal prolapse.

We herein report the incidence in our experience of total and partial neovaginal prolapse, how we prevent it, and what the optimal way to correct it is.

2. Materials and Methods

We retrospectively analysed the prevalence of partial (Figure 1) and total (Figure 2) neovaginal prolapses after androginoid sexual reassignment surgery between December 1994 and January 2012 in our institute. Our procedure includes bilateral orchiectomy, removal of corpora cavernosa, creation of the urethrostomy, neovaginoplasty, and creation of neoclitoris with preservation of neurovascular bundles and neovulvoplasty. Since the end of 2010 we have adopted an original technique, which consists of creating a neoclitoris embedded in urethral mucosa using a urethral flap [6]. In the refinement, the urethra is carefully dissected from the corpora cavernosa within buck's fascia and shortened approximately 7 cm distally from the bulbs. It is then spatulated on its ventral side down to the bulbs where a neomeatus is then created at the level of the female type urethra [4].

To create the neovagina, we adopted the penile and scrotal skin inversion technique (Figures 3(a) and 3(b)). We prefer not to close the apex of the neovaginal cylinder; in this way the penile and scrotal skin spontaneously covers the cavity where the cylinder is located, ensuring a deeper neovagina.

During the years, two different techniques have been adopted with the aim of fixing the neovaginal cylinders.

In the first, two absorbable stitches (Vicryl 3/0, which requires 35 days to be absorbed) are positioned at the top of the penoscrotal cylinder with the aim of fixing it to the Denonvilliers fascia (2 stitches technique, Figure 4). In the second technique we decided to fix the neovagina with four sutures: two absorbable stitches are fixed from the top of the penoscrotal cylinder to the Denonvilliers fascia and other two from the posterior/midpart of the scrotal flap (which will constitute the posterior neovaginal wall) to the prerectal fascia (4 stitches technique, Figure 5).

When the suture is passed through the Denonvilliers fascia, we often decide to incorporate in the suture some prostatic tissue or seminal vesicles, with the aim of strengthening the sutures.

At the end of the procedure, an inflatable silicon vaginal stent is introduced in the neovaginal cavity where it is maintained both day and night for 3 days, and afterwards only during night-time for a total of three months (Figure 6). We prefer to use a Coloplast (Minneapolis, USA) vaginal stent. This guarantees that the penoscrotal flap will adhere to the cavity, facilitating the recovery and at the same time reducing the risk of stenosis. After 4 days from the procedure, patients are educated by a specialized nurse as to how to self-dilate the neovagina with progressively larger dilators. Neovaginal self-dilation is a fundamental step for a good long term result, first of all for maintaining the depth of the neovagina but also for prevention of vaginal prolapse. Patients must learn how to perform the dilations well, without stretching the penoscrotal flap. In Figure 7, a scheme of the procedure is reported.

Patients are systematically reevaluated at 6 and at 12 months after the procedure.

Statistical analyses were performed with SPSS 17.0 software. We compared median values using t-test, if appropriate, or Wilcoxon sign-rank test. P values <0.05 were considered significant.

3. Results

282 consecutive male transsexuals who had undergone male-to-female sex reassignment surgery (SRS) at our institute were enrolled. 65 (23.04%) out of the 282, were treated with "two stitches" technique and the following 217 (76.96%) with the "four stitches" technique. Out of all of our patients, the first 9 were operated on using the inverted penile skin vaginoplasty approach, whereas in the other 273 a penile and scrotal skin inversion technique was used.

Out of the 65 patients operated with the "two stitches" technique, 8 patients presented a neovaginal prolapse (12.30%).

1 case (1.53%) of total prolapse and 7 cases (10.76%) of partial prolapse were observed, while in the other 217 patients

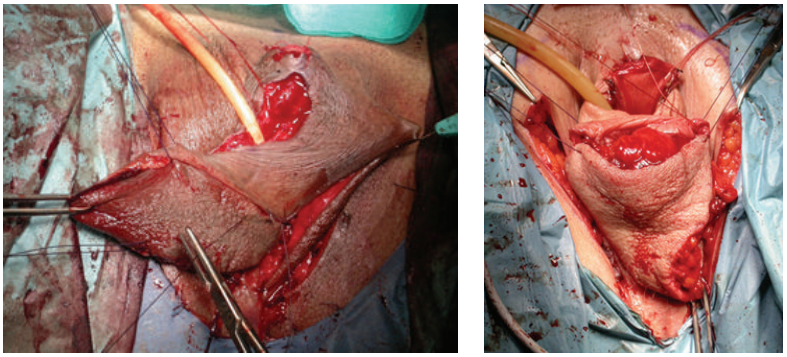

(a) (b)

Figure 3: (a) A penoscrotal cylinder is fashioned. (b) At the apex of penoscrotal cylinder two reabsorbable stitches (∗) are positioned, which subsequently will be fixed onto the Denonvilliers fascia.

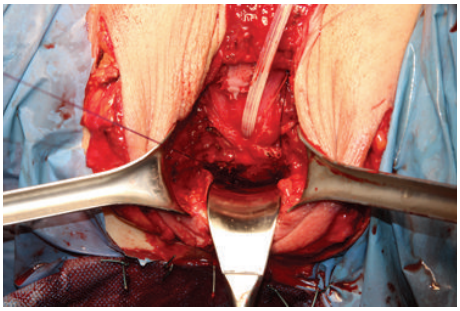

Figure 4: Penoscrotal cylinder is inverted and fixed to the Denonvilliers fascia.

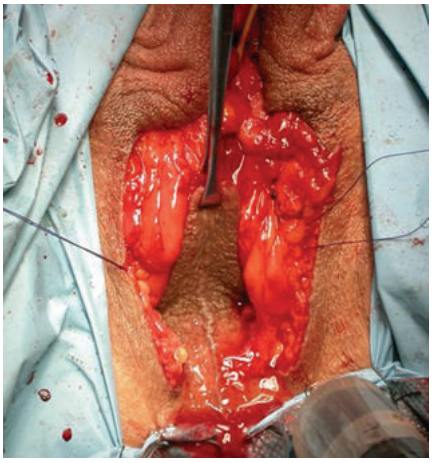

Figure 5: The cylinder is inverted and fixed on its midpart to the prerectal fascia.

treated with "four stitches" technique only 9 cases of partial prolapse were observed (4.14%) and no cases of total prolapse. Considering partial prolapses, 10 occurred at the posterior vault and 6 at the lateral vault. All prolapses occurred within 6 months from the procedure. Results are reported in Table 1; differences between groups are statistically significant, except for total prolapse ($P = 0.225$).

Figure 6: At the end of the procedure a Coloplast vaginal stent is placed inside the neovagina.

Table 1: Comparison of prolapse prevalence in "two stitches" versus "four stitches" groups.

	Old technique	New technique	P
Patients	65 (23.04%)	217 (76.96%)	
No prolapse	57	208	0.026
Prolapse	8 (12.30%)	9 (4.14%)	0.031
Partial	7 (10.76%)	9 (4.14%)	0.019
Total	**1 (1.53%)**	**0 (0%)**	**0.225**

4. Discussion

In our data, only one patient developed a total neovaginal prolapse. In this case, the "two stitches" technique was used. Moreover, the "two stitches" technique seemed to more frequently determine a partial prolapse in comparison to the "four stitches" technique (10.76% and 4.14%, resp.).

Penoscrotal flap vaginoplasty is one of the most common surgical procedures adopted nowadays to create a neovagina in male-to-female transsexuals.

Different methods for suspension of the neovagina have been described.

Stanojevic et al. proposed sacrospinous ligament fixation of the neovaginal wall to prevent prolapse. Authors have not preferred prolapse after 62 consecutive patients were treated with this technique [7]. We prefer not to use this procedure

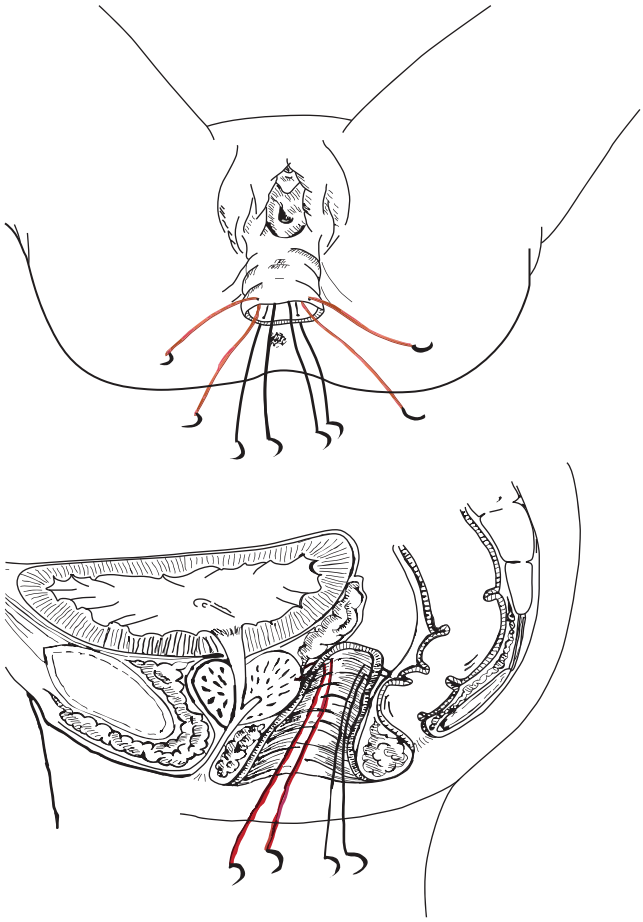

Figure 7: Diagram of where stitches have to be placed, anterior stitches in red and posterior in black.

because it requires extreme caution in consideration of the anatomic relationship to the pudendal vessels and nerves, sciatic nerve, ureter and rectum.

Other authors propose a nonsuture fixation of the neovagina with pliable lubricated [8] intravaginal packing that is left in place postoperatively for 5 days. However, we consider this technique at high risk of prolapse. In our technique, since using four stitches, the prolapse of the neovaginal vault is exceptionally rare: two are in order to suture the vault to the prostate and two to suture the rectum to the lateral part of the neocavity.

We believe that fixing the apex of the penoscrotal flap to the Denonvilliers fascia avoids the risk of total prolapse, while suturing the midpoint of the cylinder considerably reduces the risk of partial prolapse.

Sacropexy with synthetic mesh should be the most valid approach to the neovaginal prolapse as the correct neovaginal axis is restored and neovaginal function is preserved. This technique guarantees an adequate neovaginal depth and an excellent functional result. The main cause for suspension failure and the detachment of stitches from the neovaginal wall is also reduced not only because of the large vagina-mesh contact area but also thanks to the no-traction suspension. This is possible because the length of the mesh is regulated by the distance between the neovagina and sacral promontory.

Long-term outcomes of prolapse treatment in transsexual patients are not available in literature. A review of the literature including 40 studies published in 2011 provides an update of surgical management of pelvic organ prolapse in women [9]. The first problem is to define what the best surgical choice for prolapse treatment is. Authors compared outcomes of abdominal sacropexy versus vaginal sacrospinous colpopexy. Abdominal sacral colpopexy was better than vaginal sacrospinous colpopexy with a lower rate of recurrent vault prolapse (RR 0.23, 95% CI 0.07 to 0.77) [10, 11], even if associated with longer operating time and even if it is more expensive.

A second problem is if the colpopexy must be performed with absorbable or nonabsorbable grafts. One trial compared abdominal sacral colpopexy using either an absorbable cadaveric fascia lata graft (Tutoplast) or a nonabsorbable monofilament polypropylene mesh (Trelex). In both groups there were no recurrences of vaginal prolapse [12].

To the best of our knowledge, large databases of transsexual patients who underwent colpopexy for neovaginal prolapse do not exist in literature; only single cases are at best reported [13, 14], and in all of these an open approach was used. In reality, in our experience the sacropexy results are difficult in patients who have undergone ileal vaginoplasty because the ileal walls are not easily stretched with respect to the penal scrotal graft that on the other hand results in having a much more malleable and extendable and resistant wall and therefore is more adequate for this type of surgery.

The same surgery has already been described laparoscopically. This procedure was reported for the first time in 2006 [15] with the aim of restoring the neovagina without compromising its function.

The optimal choice for treating partial prolapse is not very clear; however even in these cases colposacropexy is most likely the best choice. In 6 out of the 17 patients affected by partial prolapse we decided to reposition the two sutures in the midpoint of the cylinder, but the risk of recurrence was very high; in fact 4 of them referred a partial prolapse again. In these cases no other surgical procedures have been performed. In the remaining 11 patients no surgical procedure was performed.

We had a single case of total neovaginal prolapse. In this case, considering that she had undergone an abdominal exploration for acute local peritonitis 7 years before, we decided to correct it with an open colposacropexy. Prolapse occurring after several months was caused by the disuse of lubrication during sexual intercourse. In all 3 cases, patients reported the presence of prolapse after prolonged sexual intercourse in "uncomfortable places" without the use of any type of lubricant.

In order to avoid stenosis and prolapse of the neovagina it is very important to use the vaginal stent regularly after surgery. In our opinion, it has several advantages. First of all, the stent maintains an adequate depth and diameter of the neovagina and guarantees that the skin cylinder will adhere to the cavity, facilitating the recovery and, at the same time, reducing the risk of stenosis. Moreover, it assures a good

drainage of fluids collected inside the neovagina, reducing the risk of infection.

Our study has some limitations: we have not considered if our technique influences the length of the neovagina, and, moreover, data regarding sexual satisfaction during penetration was not available. Furthermore, being a retrospective analysis, it was not possible to verify when the prolapse occurred after SRS.

However, in our experience, all of the prolapses occurred within 6 months from SRS, and we believe that a crucial role in prolapse prevention is performed postoperatively by patients.

In fact, patients must be adequately informed about the management of their neovagina after surgery. Daily dilations are mandatory in order to maintain depth and avoid stenosis. The use of abundant lubrication, with the aim of reducing friction during dilatations and intercourse, which can cause detachment of the skin cylinder and prolapse, is crucial.

To the best of our knowledge, this is the largest study investigating vaginal prolapse in male-to-female transsexuals after SRS.

5. Conclusion

In our experience, a more proximal position of the sutures to fix the penoscrotal apex to the Denonvilliers fascia guarantees a lower risk of prolapse. Specifically, total neovaginal prolapse has no longer been observed and partial prolapse now has a lower incidence.

Positioning 4 suture stitches is a short procedure and guarantees excellent functional outcome.

Moreover we believe that the postoperative management, in particular the early use of the vaginal dilator for self-dilatation and adequate lubrication, is mandatory and as important as timing and compliance of the patients in order to achieve a good aesthetic and functional result.

Conflict of Interests

The authors declare that there is no conflict of interests regarding the publication of this paper.

References

[1] R. B. Karim, J. J. Hage, and J. W. Mulder, "Neovaginoplasty in male transsexuals: review of surgical techniques and recommendations regarding eligibility," *Annals of Plastic Surgery*, vol. 37, no. 6, pp. 669–675, 1996.

[2] P. A. Sutcliffe, S. Dixon, R. L. Akehurst et al., "Evaluation of surgical procedures for sex reassignment: a systematic review," *Journal of Plastic, Reconstructive and Aesthetic Surgery*, vol. 62, no. 3, pp. 294–306, 2009.

[3] S. V. Perovic, D. S. Stanojevic, and M. L. J. Djordjevic, "Vaginoplasty in male transsexuals using penile skin and a urethral flap," *BJU International*, vol. 86, no. 7, pp. 843–850, 2000.

[4] S. Krege, A. Bex, G. Lümmen, and H. Rübben, "Male-to-female transsexualism: a technique, results and long-term follow-up in 66 patients," *BJU International*, vol. 88, no. 4, pp. 396–402, 2001.

[5] M. L. Djordjevic, D. S. Stanojevic, and M. R. Bizic, "Rectosigmoid vaginoplasty: clinical experience and outcomes in 86 cases," *Journal of Sexual Medicine*, vol. 8, no. 12, pp. 3487–3494, 2011.

[6] C. Trombetta, G. Liguori, S. Benvenuto et al., "Neo-urethroclitoroplasty according to petrovic," *Urologia*, vol. 78, no. 4, pp. 267–273, 2011.

[7] D. S. Stanojevic, M. L. Djordjevic, A. Milosevic et al., "Belgrade Gender Dysphoria Team. Sacrospinous ligament fixation for neovaginal prolapse prevention in male-to-female surgery," *Urology*, vol. 70, no. 4, pp. 767–771, 2007.

[8] R. B. Karim, J. J. Hage, and J. W. Mulder, "Neovaginoplasty in male transsexuals: review of surgical techniques and recommendations regarding eligibility," *Annals of Plastic Surgery*, vol. 37, no. 6, pp. 669–675, 1996.

[9] C. M. Maher, B. Feiner, K. Baessler, and C. M. A. Glazener, "Surgical management of pelvic organ prolapse in women: the updated summary version Cochrane review," *International Urogynecology Journal*, vol. 22, no. 11, pp. 1445–1457, 2011.

[10] J. T. Benson, V. Lucente, E. McClellan, and J. Cornella, "Vaginal versus abdominal reconstructive surgery for the treatment of pelvic support defects: a prospective randomized study with long-term outcome evaluation," *American Journal of Obstetrics and Gynecology*, vol. 175, no. 6, pp. 1418–1422, 1996.

[11] C. F. Maher, A. M. Qatawneh, P. L. Dwyer, M. P. Carey, A. Cornish, and P. J. Schluter, "Abdominal sacral colpopexy or vaginal sacrospinous colpopexy for vaginal vault prolapse: a prospective randomized study," *American Journal of Obstetrics and Gynecology*, vol. 190, no. 1, pp. 20–26, 2004.

[12] P. J. Culligan, L. Blackwell, L. J. Goldsmith, C. A. Graham, A. Rogers, and M. H. Heit, "A randomized controlled trial comparing fascia lata and synthetic mesh for sacral colpopexy," *Obstetrics and Gynecology*, vol. 106, no. 1, pp. 29–37, 2005.

[13] G. Loverro, C. Bettocchi, M. Battaglia et al., "Repair of vaginal prolapse following penoscrotal flap vaginoplasty in a male-to-female transsexual," *Gynecologic and Obstetric Investigation*, vol. 53, no. 4, pp. 234–236, 2002.

[14] R. W. Frederick and G. E. Leach, "Abdominal sacral colpopexy for repair of neovaginal prolapse in male-to-female transsexuals," *Urology*, vol. 64, no. 3, pp. 580–581, 2004.

[15] G. Condous, R. Jones, and A. M. Lam, "Male-to-female transsexualism: laparoscopic pelvic floor repair of prolapsed neovagina," *Australian and New Zealand Journal of Obstetrics and Gynaecology*, vol. 46, no. 3, pp. 254–256, 2006.