

Case Report

Moxidectin Efficacy in a Goat Herd with Chronic and Generalized Sarcoptic Mange

Nektarios D. Giadinis,¹ Rania Farmaki,² Nikolaos Papaioannou,³ Elias Papadopoulos,⁴ Harilaos Karatzias,¹ and Alexander F. Koutinas⁵

¹ *Clinic of Farm Animals, School of Veterinary Medicine, Aristotle University of Thessaloniki, 546 27 Thessaloniki, Greece*

² *Clinic of Medicine, Veterinary Faculty, University of Thessaly, 43 100 Karditsa, Greece*

³ *Laboratory of Pathology, School of Veterinary Medicine, Aristotle University of Thessaloniki, 546 27 Thessaloniki, Greece*

⁴ *Laboratory of Parasitology and Parasitic Diseases, School of Veterinary Medicine, Aristotle University of Thessaloniki, 546 27 Thessaloniki, Greece*

⁵ *Companion Animal Clinic, School of Veterinary Medicine, Aristotle University of Thessaloniki, 546 27 Thessaloniki, Greece*

Correspondence should be addressed to Nektarios D. Giadinis, ngiadini@vet.auth.gr

Received 14 December 2010; Accepted 24 March 2011

Academic Editor: Pedro J. Ginel

Copyright © 2011 Nektarios D. Giadinis et al. This is an open access article distributed under the Creative Commons Attribution License, which permits unrestricted use, distribution, and reproduction in any medium, provided the original work is properly cited.

A case of sarcoptic mange affecting almost all the animals of a dairy goat herd is described. This pruritic skin disease led progressively to high mortality and dramatic drop of milk yield. The lesions of the affected goats were typical of a chronic and generalized-diffuse sarcoptic mange. Diagnosis was confirmed by skin scrapings and histopathology in which many mites were demonstrated. All surviving goats were treated with injectable moxidectin solution 1% (CYDECTIN-Fort Dodge) at the dose of 0.2 mg/kg, applied every 15 days for four times, subcutaneously. Although pruritus had decreased soon after the first treatment, a satisfactory healing of cutaneous lesions was witnessed 6 weeks after the beginning of moxidectin trial. Parasitological cure was achieved in all affected animals by the end of the trial. In the four monthly followups, no evidence of sarcoptic mange could be found.

1. Introduction

Sarcoptic mange is a highly contagious and pruritic acariasis of the skin affecting more than 100 domestic and wild mammalian species, including humans [1–3]. The causative mite, *Sarcoptes scabiei*, inflicts damage to the skin mainly by forming tunnels within the upper epidermal layers [4]. The mite is transmitted by direct contact or with fomites [5]. The disease has been reported to affect mainly the traditional goat herds, with the newly purchased animals known to serve as the main source of the contamination [2, 6, 7].

Dairy goat enterprises are an important part of livestock production in Greece [8]. Although sarcoptic mange is a common ectoparasitic disease in this country, affecting almost all domestic animal species and especially pigs, goats, sheep, and dogs [9–11], there have been no adequate

epidemiological studies to address the problem among small ruminant flocks or herds.

Intense pruritus, manifested over the face, pinnae, neck, limbs, or over the body and associated with the presence of papules, crusts, excoriations, and hypotrichosis-alopecia, on an erythematous or hyperpigmented, lichenified, thick, and folded skin make up the typical clinical picture of sarcoptic mange as it appears in the goat. The affected animals usually die at the final stage of the disease, preceded by anorexia, emaciation or cachexia, lethargy, and lagging behind [2, 12–14].

The application of systemic acaricidal treatment in dairy goat herds is questionable because of the residue problem of the milk [15] and the inconsistency of therapeutical results so far obtained [6, 13, 16]. The macrocyclic lactone moxidectin has been proven to be a safe and effective endoparasiticide

in goats [17–19] and a valuable acaricide for the sarcoptic mange of the other domestic animal species [20], though has never been tested for this purpose in the caprine counterpart, at least to our knowledge. The aim of this paper was to evaluate its efficacy in chronic, generalized, and debilitating sarcoptic mange affecting a traditional goat herd and resulting in high morbidity and mortality rates as well as a dramatic milk yield along with substantial losses, carcasses, and hides.

2. Case Report

2.1. Historical Data. The goat herd, located on a hilly area of northern Greece, was comprised of 700 goats belonging to a native breed (*Capra prisca*) and organized in a semiextensive system. In a 3-month period beginning from the end of the winter, the farmer noticed a quickly spreading and intensely pruritic dermatopathy that eventually affected almost every goat in the herd and eventually resulted in the death of 400 out of 700 animals (57%). According to the farmer, the problem had emerged two months after the introduction of a few goats purchased from another enterprise. The farmer had been advised to treat the affected animals with a single subcutaneous injection of ivermectin (0.3 mg/kg) but of no avail, as only a temporary and mild improvement was observed soon, followed by a relapse of clinical signs.

2.2. Clinical and Laboratory Findings. Three adult female goats, where admitted to the Farm Animal Clinic (Veterinary Faculty, Aristotle University of Thessaloniki, Greece), with a generalized and diffuse skin disease that was highly pruritic characterized by alopecia-hypotrichosis, erythema, hyperpigmentation, excoriations, thick crusts, skin folding, and lichenification (Figure 1(a)). These animals were also emaciated (Figure 1(b)) and anorectic with no actual milk yield. They all died after a couple of days without treatment or any other type of clinical intervention and were soon necropsied thereafter. The only macroscopic findings were emaciation and bacterial bronchopneumonia with *Pasteurella multocida* as its cause. All the goats were tested negative for *Mycoplasma* spp., paratuberculosis, and lentiviral infection. Similar clinical signs, the severity of which varied, were also observed in all the other affected goats during a visit to the goat farm.

Microscopic examination of multiple skin scrapings, obtained from new skin lesions (papules) of all, a total of 8, goats revealed the presence of several *Sarcoptes* mites as well as their eggs and fecal pellets. Eight mm punch skin biopsies, obtained from the skin lesions of the neck and thoracic wall of each of the first three scabietic goats, were processed routinely and stained with hematoxylineosin. The ensuing histopathological examination disclosed a severe orthokeratotic and laminated hyperkeratosis, epidermal acanthosis, and spongiosis as well as superficial perivascular to interstitial dermatitis with a strong eosinophilic component within the cellular infiltrate; several mites were also found embedded within the stratum corneum (Figure 2).

2.3. Treatment. All surviving goats (300 totally) were treated with moxidectin after having secured a written consent from

the farmer. Study protocol and technical details were also approved by the Institutional Animal Care in the prefecture of Thessaloniki, Greece. An injectable moxidectin solution of 1% (CYDECTIN-Fort Dodge) was applied subcutaneously at the dose of 0.2 mg/kg every 15 days and for a total of four treatments. The milk yield was much reduced and discarded as toxic because of the moxidectin residues. At the same time, the goat premises were thoroughly cleaned and sprayed with an acaricidal aqueous solution containing 2000 ppm amitraz (TAK-TIC-Intervet) in an effort to eliminate the recontamination potential.

Moxidectin treatment, applied successfully to all goats of this herd, resulted in a dramatic decrease of mortality rate (1%), as only 3 emaciated to cachectic animals died shortly thereafter. Although pruritus level decreased profoundly within 15 days after the first moxidectin injection, it took almost 6 weeks for the cutaneous lesions to disappear and to witness partial haircoat regrowth. Parasitological cure was achieved at the same time for the majority of the goats, apart from those with severe and generalized/diffuse skin disease in which two more weeks were allowed, coinciding with the end of 8-week trial with moxidectin. In all four clinical and parasitological reexaminations, performed during the following 3 months, no evidence of sarcoptic mange could be demonstrated, with the appetite and body weight of the affected animals restored back to normal. Haircoat regrew completely 5 months after the beginning of moxidectin trial, whereas milk yield never reached the precariosis level, at least during the ongoing lactation period. However, it was restored back to normal level during the next one.

3. Discussion

Sarcoptic mange is a common ectoparasitic disease in the majority of the countries with many goat enterprises [3, 16, 21]. In this herd, the morbidity rate was much higher compared to what has been reported in some South Asian countries [12]. The increased morbidity rate, noticed in this study, could be attributed to a combination of factors such as poor nutrition and hygiene level and overcrowding conditions. Mortality rate was quite high (57%) and most likely was the result of the severity, generalization, and chronicity of the disease itself although higher rates have been reported in various wild ruminant species [22, 23]. Prolonged anorexia due to intense pruritus led to the debility and emaciation, or predisposed to secondary bacterial infections (e.g., bacterial bronchopneumonia), all finally leading to the death of the affected goats. Bacterial complications have also been incriminated as the cause of death in scabietic cattle [24].

Apart from the animal losses, the farmer was worried about the dramatic drop of milk yield also reported in similarly affected sheep [25] and cattle and attributed to the significant reduction of food intake secondary to intense pruritus [24].

Sarcoptic mange in goats can be treated with parenteral ivermectin [16] and/or lime sulfur [13], herbal [26], or organophosphate dips [16]. However, the topical treatments,

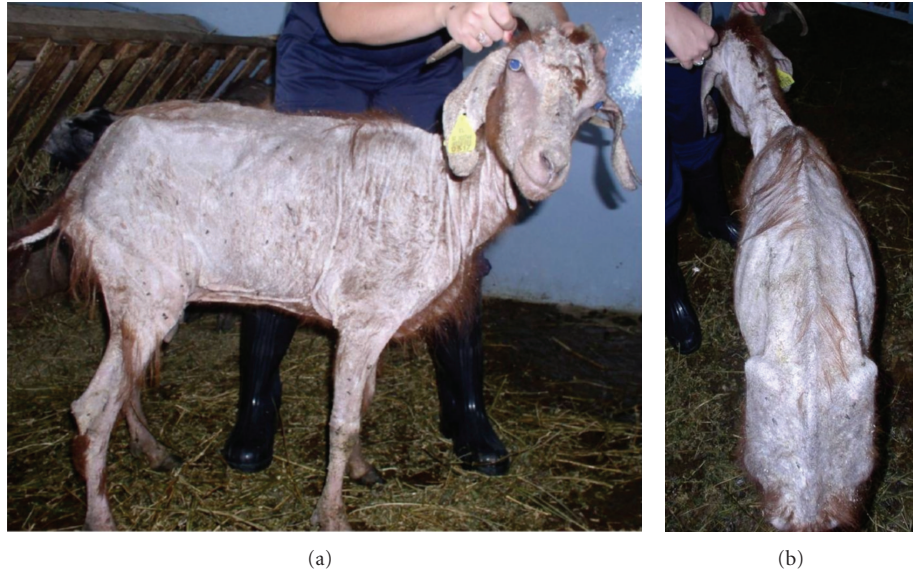


FIGURE 1: Lateral and dorsal view of a one-year-old female goat with sarcoptic mange, showing the typical skin lesions of the disease and the emaciation of the animal.

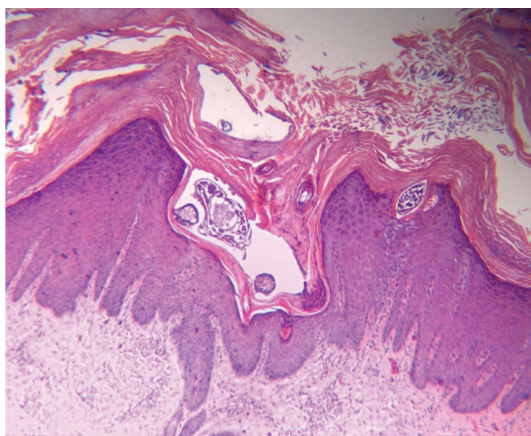


FIGURE 2: Skin biopsy obtained from lesional skin, in which a hyperplastic superficial dermatitis, along with several *Sarcoptes scabiei* mites embedded within the hyperkeratotic stratum corneum, is shown (H&E 50x).

apart from resulting in toxic side effects, had low efficacy rates and frequent relapses [6, 16]. In this goat herd, the treatment with parenteral moxidectin coupled with the application of frequent cleaning and disinfection measures within the goat premises was found to be both efficacious and uneventful. Moxidectin alone or in combination with other medication has been successfully used in the treatment of sheep [10, 25], cattle [27], horses [28], dogs, and rabbits [20, 29] affected with sarcoptic mange. In dairy farms, this treatment is not advisable during the milking period, because moxidectin is a lipophilic molecule and much of it is excreted into the milk [30]. However, in the severely affected goat herd of this paper this was not a problem, as the milk production

had reached a minimal level, and the collected milk had been discarded during the 8-week trial with moxidectin.

4. Conclusion

Sarcoptic mange is a common problem in our traditional goat herds, leading to heavy animal losses if left untreated. This preliminary open trial has shown that treatment with moxidectin is effective, safe, and practical also for goats, especially when it is coupled with thorough cleaning and disinfection of the premises with acaricidal solutions.



Acknowledgment

The authors of the paper do not have any direct financial relation with the commercial identity mentioned in the paper that might lead to a conflict of interests.

References

- [1] K. E. Ibrahim and M. T. Abu-Samra, "Experimental transmission of a goat strain of *Sarcoptes scabiei* to desert sheep and its treatment with ivermectin," *Veterinary Parasitology*, vol. 26, no. 1-2, pp. 157-164, 1987.
- [2] D. W. Scott, *Large Animal Dermatology*, WB Saunders, Philadelphia, Pa, USA, 1988.
- [3] S. T. Bornstein, T. Morner, and W. M. Samuel, "*Sarcoptes scabiei* and sarcoptic mange," in *Parasitic Diseases of Wild Mammals*, W. M. Samuel, M. J. Pybus, and A. A. Kocan, Eds., pp. 107-119, Iowa State University Press, Ames, Iowa, USA, 2nd edition, 2001.
- [4] D. O. Morris and R. W. Dunstan, "A histomorphological study of sarcoptic acariasis in the dog: 19 cases," *Journal of the American Animal Hospital Association*, vol. 32, no. 2, pp. 119-124, 1996.

- [5] C. F. Curtis, "Current trends in the treatment of *Sarcoptes*, *Cheyletiella* and *Otodectes* mite infestations in dogs and cats," *Veterinary Dermatology*, vol. 15, no. 2, pp. 108–114, 2004.
- [6] P. G. G. Jackson, H. W. Richards, and S. Lloyd, "Sarcoptic mange in goats," *Veterinary Record*, vol. 112, no. 14, p. 330, 1983.
- [7] D. E. Anderson, D. M. Rings, and D. G. Pugh, "Diseases of the integumentary system," in *Sheep and Goat Medicine*, D. G. Pugh, Ed., pp. 197–222, WB Saunders, Philadelphia, Pa, USA, 2002.
- [8] M. de Rancourt, N. Fois, M. P. Lavín, E. Tchakerian, and F. Vallerand, "Mediterranean sheep and goats production: an uncertain future," *Small Ruminant Research*, vol. 62, no. 3, pp. 167–179, 2006.
- [9] H. Himonas, K. Antoniadou-Sotiriadou, and E. Papadopoulos, "Frequency of infection in swines with *Sarcoptes scabiei* in areas of Macedonia and Thessaly," *Bulletin of The Hellenic Veterinary Medical Society*, vol. 42, pp. 122–126, 1992.
- [10] E. Papadopoulos and G. Fthenakis, "Administration of moxidectin for treatment of sarcoptic mange in a flock of sheep," *Small Ruminant Research*, vol. 31, no. 2, pp. 165–168, 1999.
- [11] A. F. Koutinas, M. N. Saridomichelakis, N. Soubasis, S. Bornstein, and C. K. Koutinas, "Treatment of canine sarcoptic mange with fipronil spray: a field trial," *Australian Veterinary Practitioner*, vol. 31, no. 3, pp. 115–119, 2001.
- [12] P. Dorny, T. Van Wyngaarden, J. Vercruyse, C. Symoens, and A. Jalila, "Survey on the importance of mange in the aetiology of skin lesions in goats in Peninsular Malaysia," *Tropical Animal Health and Production*, vol. 26, no. 2, pp. 81–86, 1994.
- [13] M. C. Smith and D. M. Sherman, *Goat Medicine*, Lea and Febiger, Philadelphia, Pa, USA, 1994.
- [14] L. León-Vizcaíno, M. J. Cubero, E. González-Capitel et al., "Experimental ivermectin treatment of sarcoptic mange and establishment of a mange-free population of Spanish ibex," *Journal of Wildlife Diseases*, vol. 37, no. 4, pp. 775–785, 2001.
- [15] J. Lusat, E. R. Morgan, and R. Wall, "Mange in alpacas, llamas and goats in the UK: incidence and risk," *Veterinary Parasitology*, vol. 163, no. 1-2, pp. 179–184, 2009.
- [16] J. Manurung, P. Stevenson, Beriajaya, and M. R. Knox, "Use of ivermectin to control sarcoptic mange in goats in Indonesia," *Tropical Animal Health and Production*, vol. 22, no. 3, pp. 206–212, 1990.
- [17] V. S. Mavrogianni, G. C. Fthenakis, E. Papadopoulos, J. Skoufos, G. Christodouloupoulos, and A. Tzora, "Safety and reproductive safety of moxidectin in goats," *Small Ruminant Research*, vol. 54, no. 1-2, pp. 33–41, 2004.
- [18] E. Papadopoulos, V. S. Mavrogianni, S. Ptochos, S. Tsakalidis, and G. Fthenakis, "Evaluation of the efficacy of moxidectin in a herd of goats after long-standing consistent use," *Small Ruminant Research*, vol. 57, no. 2-3, pp. 271–275, 2005.
- [19] S. B. Howell, J. M. Burke, J. E. Miller et al., "Prevalence of anthelmintic resistance on sheep and goat farms in the southeastern United States," *Journal of the American Veterinary Medical Association*, vol. 233, no. 12, pp. 1913–1919, 2008.
- [20] R. Wagner and U. Wendlberger, "Field efficacy of moxidectin in dogs and rabbits naturally infested with *Sarcoptes* spp., *Demodex* spp. and *Psoroptes* spp. mites," *Veterinary Parasitology*, vol. 93, no. 2, pp. 149–158, 2000.
- [21] A. R. Sheikh-Omar, M. Zamri, and C. C. Lee, "A survey of mange mite infestation in goats from Serdang, Malaysia," *Pertanika*, vol. 7, no. 1, pp. 83–85, 1984.
- [22] L. León-Vizcaíno, M. R. Ruiz De Ybáñez, M. J. Cubero et al., "Sarcoptic mange in Spanish ibex from Spain," *Journal of Wildlife Diseases*, vol. 35, no. 4, pp. 647–659, 1999.
- [23] I. Yeruham, S. Rosen, A. Hadani, and A. Nyska, "Sarcoptic mange in wild ruminants in zoological gardens in Israel," *Journal of Wildlife Diseases*, vol. 32, no. 1, pp. 57–61, 1996.
- [24] W. C. Rebhun, *Diseases of Dairy Cattle*, Lippincott Williams & Wilkins, Philadelphia, Pa, USA, 1995.
- [25] G. C. Fthenakis, E. Papadopoulos, C. Himonas, L. Leontides, S. Kritas, and J. Papatsas, "Efficacy of moxidectin against sarcoptic mange and effects on milk yield of ewes and growth of lambs," *Veterinary Parasitology*, vol. 87, no. 2-3, pp. 207–216, 2000.
- [26] S. S. Das, P. S. Banerjee, B. A. Pandit, and B. B. Bhatia, "Efficacy of a herbal compound against sarcoptic mange in goats," *Tropical Animal Health and Production*, vol. 26, no. 2, pp. 117–118, 1994.
- [27] B. Losson and J. F. Lonneux, "Field efficacy of injectable moxidectin in cattle naturally infested with *Chorioptes bovis* and *Sarcoptes scabiei*," *Veterinary Parasitology*, vol. 51, no. 1-2, pp. 113–121, 1993.
- [28] S. A. Osman, A. Hanafy, and S. E. Amer, "Clinical and therapeutic studies on mange in horses," *Veterinary Parasitology*, vol. 141, no. 1-2, pp. 191–195, 2006.
- [29] L. J. Fourie, J. Heine, and I. G. Horak, "The efficacy of an imidacloprid/moxidectin combination against naturally acquired *Sarcoptes scabiei* infestations on dogs," *Australian Veterinary Journal*, vol. 84, no. 1-2, pp. 17–21, 2006.
- [30] C. M. Carceles, M. S. Diaz, M. S. Vicente, J. F. Sutra, M. Alvinerie, and E. Escudero, "Milk kinetics of moxidectin and doramectin in goats," *Research in Veterinary Science*, vol. 70, no. 3, pp. 227–231, 2001.



Hindawi

Submit your manuscripts at
<http://www.hindawi.com>

