International Scholarly Research Network
ISRN Pathology
Volume 2011, Article ID 219790, 9 pages
doi:10.5402/2011/219790

Research Article

Evaluation of the *In Situ* Hybridization Signal Patterns of Liquid-Based Cytological Human Papillomavirus Specimens for Diagnosing Squamous Intraepithelial Lesion

Katsunari Ishida,[1] Makoto Nagasaki,[1] Masayuki Kobayashi,[2] Tatsushi Nakagawa,[3] Toru Nabika,[4] and Kiyomi Taniyama[5]

[1] *Department of Clinical Laboratory, National Hospital Organization Hamada Medical Center, Hamada 697-8511, Japan*
[2] *Department of Obstetrics and Gynecology, National Hospital Organization Hamada Medical Center, Hamada 697-8511, Japan*
[3] *Department of Obstetrics and Gynecology, Tokuyama Central Hospital, Shunan 745-8522, Japan*
[4] *Department of Functional Pathology, Shimane University School of Medicine, Izumo 693-8511, Japan*
[5] *Institute for Clinical Research, National Hospital Organization, Kure Medical Center and Chugoku Cancer Center, Kure 737-0023, Japan*

Correspondence should be addressed to Makoto Nagasaki, mnagasaki@hamada2.hosp.go.jp

Received 15 April 2011; Accepted 8 June 2011

Academic Editors: A.-J. Kruse, C. K. Panda, and R. S. Saad

Copyright © 2011 Katsunari Ishida et al. This is an open access article distributed under the Creative Commons Attribution License, which permits unrestricted use, distribution, and reproduction in any medium, provided the original work is properly cited.

To examine the diagnostic utility for squamous intraepithelial lesion (SIL) by cytological *in situ* hybridization (c-ISH) for the human papillomavirus using liquid-based cytology specimens, we investigated c-ISH signal patterns in the cases of low-grade SIL (LSIL), atypical squamous cells of undetermined significance (ASC-US), and high-grade SIL (HSIL). Episomal (E) and/or integrated (I) signals were observed. Two signal patterns ($E \geqq I$ or $I > E$) were obtained by counting the number of $E+$ or $I+$ cells. $E \geqq I$ was specific to LSIL and ASC-US (10/12); $I > E$, to HSIL (9/11) ($P < 0.01$, χ^2 test), suggesting significant utility of c-ISH in diagnosing SIL. In the cell fraction, $E \geqq I$ in large cells was dominant in LSIL. Two cases of $I > E$ in large cells of LSIL showed HPV persistence and/or progression during follow-up. Thus, c-ISH is useful in routine testing for diagnosing cervical dysplastic lesions, especially for detecting LSIL suspected for progression.

1. Introduction

Human papillomavirus (HPV) is responsible for uterine cervical cancer [1]. Screening programs for cervical cancer detection have greatly reduced the incidence of cervical cancer and cancer-related mortality. However, the cytological Papanicolaou test has relatively low sensitivity as well as a high false-negative rate and high interobserver variability. Recent studies have reported that exfoliated cells sorted for liquid-based cytology (LBC) are useful for immunohistochemical (p16) and molecular analysis methods such as in situ hybridization (ISH) or polymerase chain reaction (PCR) for detecting viral DNA in these samples [2, 3]. Evaluating exfoliated cells is more convenient than evaluating biopsy specimens for screening patients at high risk of cervical cancer.

Although cervical intraepithelial neoplasia (CIN) 1 lesions are regress spontaneously [4], it is known that high risk HPV integration occurs in a subset of LSILs [5], which could be an early event in carcinogenesis. Therefore, it is important to detect a marker protein or viral genomic state (including the episomal [E] and/or integrated [I] form) before the lesion progress. Under these considerations, we evaluated cytological ISH (c-ISH) with LBC specimens by using a Ventana's autostainer for detect the signal patterns and the results were evaluated along with the corresponding biopsy specimens.

2. Materials and Methods

The study included 33 cases who had negative for intraepithelial lesion (NILM), low-grade intraepithelial neoplasia

Table 1: A list of the case studied.

Case No.	Age	PCR (HPV genotype)	cytology Papacicolaou	c-ISH	HE	histology h-ISH superficial	intermediate	basal
1	40	–	NILM	–	metaplasia	–	–	–
2	31	53	NILM	–	metaplasia	–	–	–
3	22	31	NILM	–	sq. epithelium	–	–	–
4	35	58	LSIL	+	CIN1	*I*/*E*(+)	*I*(÷)	*I*(÷)
5	27	18/58	LSIL	+	CIN1	*E*/*I*(+)	*E*/*I*(+)	*I*(÷)
6	45	6/18	LSIL	+	CIN1	–	–	–
7	25	56	LSIL	+	CIN1	*E*/*I*(+)	*E*/*I*(+)	*I*(÷)
8	26	51	LSIL	+	CIN1	–	–	–
9	28	16	LSIL	+	*CIN3 (CIS)	*I*(+)	*I*(+)	*I*(+)
10	30	52	LSIL	–	CIN3	*I*(÷)	*I*(÷)	*I*(÷)
11	29	18	LSIL	+	CIN1	*E*/*I*(+)	*E*/*I*(+)	*I*(+)
12	24	66	LSIL	+	CIN1	*E*/*I*(+)	*E*/*I*(+)	–
13	30	16	LSIL	+	CIN1	–	–	*I*(÷)
14	52	53	LSIL	+	CIN1	–	–	–
15	39	52	LSIL	+	CIN2	–	–	–
16	26	–	LSIL	–	cervicitis	–	–	–
17	38	16	ASC-US	+	CIN1	*E*(+)	*E*(+)	*I*(÷)
18	38	52	ASC-US	–	CIN1	*E*(+)	*E*(+)	–
19	57	–	ASC-US	–	metaplasia	–	–	–
20	48	–	ASC-US	–	cervicitis	–	–	–
21	38	–	ASC-US	–	cervicitis	–	–	–
22	47	59	HSIL (moderate)	+	CIN1	–	–	–
23	29	16	HSIL (moderate)	–	CIN1	–	–	–
24	42	–	HSIL (moderate)	+	CIN3	*I*(+)	*I*(+)	*I*(+)
25	60	16/18/68	HSIL (moderate)	+	CIN3	*I*(÷)	*I*(÷)	*I*(÷)
26	24	66	HSIL (moderate)	+	*CIN3	*I*(÷)	*I*(÷)	*I*(÷)
27	30	16/33	HSIL (moderate)	+	CIN3	*I*/*E*(+)	*I*(+)	*I*(+)
28	26	16	HSIL (severe)	+	CIN3	*I*(+)	*I*(+)	*I*(+)
29	64	52	HSIL (severe)	+	CIN3	*I*(÷)	*I*(÷)	*I*(÷)
30	29	16	HSIL (severe)	+	CIN3	*E*(+)	*E*/*I*(+)	*I*(+)
31	41	52	HSIL (CIS)	+	CIN3 (CIS)	*I*/*E*(+)	*I*(+)	*I*(+)
32	25	16	HSIL (CIS)	+	CIN3 (CIS)	*I*/*E*(+)	*I*(+)	*I*(+)
33	30	16	HSIL (CIS)	+	CIN3 (CIS)	*E*/*I*(+)	*I*/*E*(+)	*I*(+)

Abbreviations: NILM, negative for intraepithelial lesion; sq., squamous; LSIL, low grade intraepithelial neoplasia; ASC-US, atypical squamous cells of undetermined significance;
HSIL, high grade intraepithelial neoplasia; CIN, cervical intraepithelial neoplasia; CIS, carcinoma in situ; PCR, polymerase chain reaction; c-ISH, cytological in situ hybridization; h-ISH, histological ISH; superficial, superficial layer; intermediate, intermediate layer; basal, basal laer in cervical epithelial layer; *E*, episomal pattern; *I*, integrated pattern.
The intensity of expression of above items was evaluated on an arbitrary scale from – (no detectable staining), ÷ (weak staining intensity), to + (significant staining intensity).
In hISH, *E*/*I* indicates the E-signal is more than *I*-signal, *I*/*E* indicates the *I*-signal more than *E*-signal.
*In the case 9 and 26 (CIN3 cases), CIN1 lesions are also observed in the same histological specimen.

(LSIL), atypical squamous cells of undetermined significance (ASC-US), or high-grade intraepithelial neoplasia (HSIL) (moderate dysplasia, severe dysplasia, or carcinoma in situ) and had presented at Department of Obstetrics and Gynecology of Hamada Medical Center between 2008 and 2010. The patients with LSIL were followed for 3 months to 2 years and did not undergo treatment such as laser vaporation. They underwent the biopsy procedure on the same day as or the day after the cytology specimens were obtained, and histological examination was performed as gold standard. The results of the first cytological and histological tests were shown in Table 1.

Cytological examination was performed using split samples. Briefly, the exfoliated cervical samples were directly smeared using a bloomed brush; this was followed by Papanicolaou staining. Next, the brush was immediately suspended

in ThinPrep PreservCyt Solution (Hologic Corporation, Mass, USA) for LBC specimens.

We performed ISH using c-ISH and histological ISH (h-ISH) specimens. 1G-sedimented smears on slide glass using Setting Chambers (MBL, Nagoya, Japan) were prepared from ThinPrep PreservCyt Solution for c-ISH. For h-ISH, 4-μm-thick sections were prepared from paraffin blocks. ISH was performed on an autostainer (BenchMarK LT; Ventana Medical systems, Tucson, Ariz, USA) according to the manufacturer's instructions, with an ISH iVIEW Blue Plus Research Kit and INFORM HPV III Family 16 Probes (B) (Ventana) for h-ISH, and with Probe (C) for c-ISH. The probe cocktail had an affinity with high-risk HPV genotypes such as 16, 18, 31, 33, 35, 39, 45, 51, 52, 56, 58, and 66. The nuclear signals were punctate or diffuse, corresponding to I and E signals, respectively. To determine whether the samples identified as HPV positive by INFORM ISH were true positives, we stained a positive control section in the same run. In addition, we carefully eliminated the artifact staining according to instruction manual [6].

Exfoliated cells were recovered from the residue of the Thin Prep PreservCyt Solution. Approximately 1 mL of PreservCyt Solution was washed in phosphate-buffered saline, followed by genomic DNA isolation with MagCoreR HF16 System (RBC Bioscience Corp., Taipei, Taiwan). The presence of HPV DNA was determined by PCR and reverse-hybridization on a dot array by using HPV GenoArray Test Kit (HybriBio Limited, Hong Kong). HPV DNA was amplified with the L1 consensus HPV PGMY09/PGMY11 primer set as described previously [7]. Detectable HPV genotypes by type-specific oligonucleotides immobilized on a nylon membrane are as follows: high risk (16, 18, 31, 33, 35, 39, 45, 51, 52, 56, 58, 59, 66, and 68), low risk (6, 11, 42, 43, and 44), and unknown risk (HPV53- and CP8304). Dot signals visible on the membrane were considered positive; however, quantitative estimation was not possible.

The comparison between the two groups was analyzed using Chi-square test. P value of <0.05 were considered statistically significant.

3. Results

3.1. Results of Cytology, Histology, In Situ Hybridization (ISH) and Polymerase Chain Reaction (PCR). For 33 patients, we performed cytological and histological examinations in combination with ISH and PCR as listed in Table 1.

HPV DNA was detected in 27 patients by PCR in NILM (2/3, 66.7%), LSIL (12/13, 92.3%), ASC-US (2/5, 40.0%), and HSIL (11/12, 91.7%). Of 27 cases, 19 were found to have genotypes 16, 52, 18, 58 [8].

In h-ISH, an E-signal (diffuse signal) and an I-signal (punctuated signal) were detected in each cell layer as previously reported [9]. Dysplastic cells showing the I-signal were detected in the intermediate and superficial layers as well as in the basal layer in CIN1 cases (Figure 1). In c-ISH, the positive cells were easily detectable (Figures 2(a) to 2(f)). Among the PCR positive cases of NILM, LSIL, ASC-US, and HSIL, a positive signal of c-ISH was detected in 0% (0/2), 84.6% (11/13), 50.0% (1/2), and 90.9% (10/11) cases, respectively. However, the morphology of the positive cells (E-signal, Figures 2(a) to 2(c); I-signal, Figures 2(d) to 2(f)), was not exactly the same as the morphology observed in the Papanicolaou smear. We classified the cells on the basis of the nuclear signal and cell size into categories such as large-sized cells (L-cell; Figures 2(a) and 2(d)), medium-sized cells (M-cells; Figures 2(b) and 2(e)), and small-sized cells (S-cells; Figures 2(c) and 2(f)). It is likely that these sizes correspond to the superficial, intermediate, and basal cells observed in the epithelial layer in biopsy specimens.

3.2. Evaluation of c-ISH Signals. To evaluate the signal in c-ISH, we counted the E- and I-positive cells in each cell population (Table 2). The positive cells on each glass slide were counted. The pattern with E signals greater than I signals is expressed as $E > I$, the pattern with an equal number of E signals and I signals is expressed as $E = I$, and the pattern with more I signals than E signals as $I > E$. In the total cell (L-cell + M-cell + S-cell) fraction, the positive cell pattern of $E \geqq I$ was observed in 10 out of 12 cases in LSIL and ASC-US. On the other hand, the pattern $I > E$ was observed in 9 out of 11 cases in HSIL. There was a significant difference between the frequency of the $E \geqq I$ pattern in LSIL and that of the $I > E$ pattern in HSIL ($P < 0.01$ in the Chi test). This indicates the usefulness of c-ISH in diagnosing the SIL according to the pattern of signals.

We estimated the sensitivity, specificity, PPV, and NPV of cytology exams (Papanicolaou) in combination with c-ISH signals to detect CIN1 or CIN2/3 using histological examination as the gold standard (Table 3). As shown in Tables 3(2) and 3(3), the combination of Papanicolaou test HSIL with the c-ISH signal pattern $E \geqq I$ increased the specificity (90.0% to 100%), PPV (83.3% to 100%), and NPV (85.7% to 90.9%), and the $I > E$ pattern increased the sensitivity (76.9% to 90.0%) and PPV (83.3% to 90.0%) for the detection of CIN2/3. In LSIL, the combination with $E \geqq I$ increased the sensitivity and PPV (69.2% (9/13) to 88.9% (8/9)) and $I > E$ increased the specificity and NPV (80% (16/20) to 88.9% (8/9)) for CIN1.

The numbers of E or I cells in each cell population (Table 2) are shown in scatter plots (Figures 3 and 4). As shown in Figure 3(a), cases of the $I > E$ pattern of LSIL ($*1$ and $*2$) and $E > I$ pattern of HSIL ($*3$ and $*4$) were found to be minor cases of each lesion. Comments on these cases are provided in the Discussion section. Positive large-sized cells were present in all 11 (100%) patients with LSIL and 7 of 11 (63%) patients with HSIL. On the other hand, M + S cells were observed in 6 of 11 patients (54%) with LSIL and all 11 (100%) patients with HSIL (Figure 4). The major cellular component of LSIL was revealed to be large-sized cells in c-ISH. The results obtained for the large-sized cells (Figure 3(b)) with the $I > E$ pattern cases ($*1$ and $*2$) were appear to be unusual in comparison with those for the 5 $E \geqq I$ cases ($*6$, $*7$, $*8$, $*11$, and $*12$), where regression was observed in all cases (NILM, PCR negative, and ISH negative). In $*1$ (case 4), the $I > E$ pattern of HPV

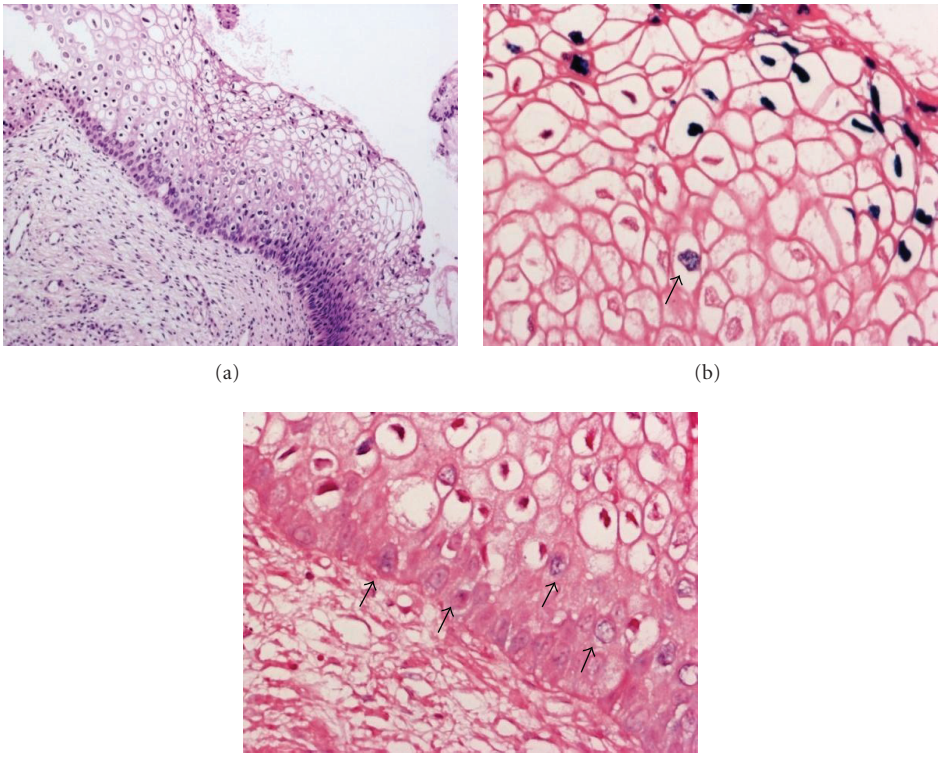

Figure 1: The CIN1 and h-ISH. (Case 5 patient). CIN1 with koilocytosis ((a), HE) (×100) and h-ISH ((b), (c)) (×400). E-signal positive superficial layer cells, *I*-signal positive intermediate layer cell (arrow in (b)), and *I*-signal weak positive basal layer cells (arrows in (c)) are observed.

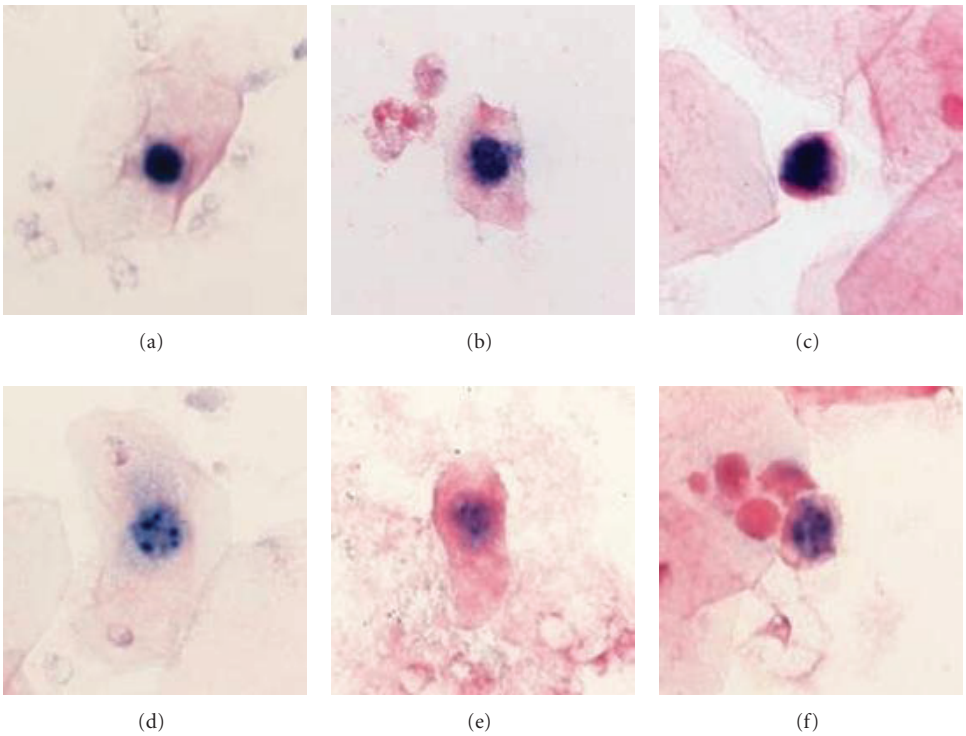

Figure 2: The signal patterns and cell types in c-ISH (×400). Positive signals of *E* ((a), (b), and (c)) or *I* ((d), (e), and (f)) are visible in large-sized cells ((a) and (d)), medium-sized cells ((b) and (e)), and small-sized cells ((c), (f)). (a) (d) LSIL case; (b) (e) HSIL (moderate dysplasia) case; (c) (f) HSIL (severe dysplasia) case.

Table 2: Positive cell number of each signal (E, I) of c-ISH.

Case No.	cytology (pap)	c-ISH									
		L+M+S-cell			L-cell			M-cell		S-cell	
		E	I	pattern	E	I	pattern	E	I	E	I
1	NILM	0	0		0	0		0	0	0	0
2	NILM	0	0		0	0		0	0	0	0
3	NILM	0	0		0	0		0	0	0	0
4	LSIL	6	9	$I > E^{\#}$	6	9	$I > E$	0	0	0	0
5	LSIL	7	6	$E > I^{\#}$	7	6	$E > I$	0	0	0	0
6	LSIL	3	3	$E = I^{\#}$	3	3	$E = I$	0	0	0	0
7	LSIL	21	0	$E > I^{\#}$	14	0	$E > I$	6	0	1	0
8	LSIL	8	0	$E > I^{\#}$	6	0	$E > I$	0	0	2	0
9	LSIL	13	1	$E > I^{\#}$	9	1	$E > I$	0	0	4	0
10	LSIL	0	0		0	0		0	0	0	0
11	LSIL	1	1	$E = I^{\#}$	1	1	$E = I$	0	0	0	0
12	LSIL	9	4	$E > I^{\#}$	7	4	$E > I$	2	0	0	0
13	LSIL	5	5	$E = I^{\#}$	4	5	$I > E$	1	0	0	0
14	LSIL	2	1	$E > I^{\#}$	1	0	$E > I$	1	1	0	0
15	LSIL	0	2	$I > E^{\#}$	0	2	$I > E$	0	0	0	0
16	LSIL	0	0		0	0		0	0	0	0
17	ASC-US	1	1	$E = I^{\#}$	1	1		0	0	0	0
18	ASC-US	0	0		0	0		0	0	0	0
19	ASC-US	0	0		0	0		0	0	0	0
20	ASC-US	0	0		0	0		0	0	0	0
21	ASC-US	0	0		0	0		0	0	0	0
22	HSIL (moderate)	1	4	$I > E^{\#}$	0	3		1	1	0	0
23	HSIL (moderate)	0	0		0	0		0	0	0	0
24	HSIL (moderate)	22	35	$I > E^{\#}$	6	19		8	15	8	1
25	HSIL (moderate)	10	9	$E > I^{\#}$	0	3		0	3	10	3
26	HSIL (moderate)	13	5	$E > I^{\#}$	3	0		7	2	3	3
27	HSIL (moderate)	7	35	$I > E^{\#}$	5	11		0	13	2	11
28	HSIL (severe)	1	6	$I > E^{\#}$	0	1		0	1	1	4
29	HSIL (severe)	0	1	$I > E^{\#}$	0	0		0	0	0	1
30	HSIL (severe)	1	47	$I > E^{\#}$	0	0		1	10	0	37
31	HSIL (CIS)	0	1	$I > E^{\#}$	0	0		0	0	0	1
32	HSIL (CIS)	0	9	$I > E^{\#}$	0	0		0	0	0	9
33	HSIL (CIS)	2	18	$I > E^{\#}$	0	5		0	12	2	1

c-ISH, cytological in situ hybridization; L-cell, large-sized cell; M-cell, medium-sized cell; S-cell, small-sized cell; LSIL, low-grade intraepithelial neoplasm; ASC-US, atypical squamous cells of undetermined signification; HSIL, high-grade intraepithelial neoplasm; CIS, carcinoma in situ; E, episomal pattern; I, integrated pattern

Statistically $^{\#}$significant ($P < 0.01$) between $E \geqq I$ pattern in LSIL/ASC-US group and I > E pattern in HSIL group.

was detected (Figure 5). Although regression to NILM was observed, HPV was consistently detected (PCR positive (type 58) and ISH positive) during a period of at least 6 months; ∗2 (case 15) was CIN2 with a negative ISH; ∗5 (case 13) progressed to HSIL (moderate dysplasia) after 22 months. Therefore, LSIL cases showing the $I > E$ pattern in a large-sized cell fraction appear to indicate that careful diagnosis and follow-up may be necessary.

4. Discussion

It is important to morphological, viral, oncological, and immunological markers for the early stage of uterine cervical dysplasia. The viral-infected condition, such as the episomal or integrated form, is believed to be important because the HPV integration is known to represent a key step towards the progression of the disease [10]. Therefore, we investigated HPV-infected cells to search for a diagnostic and/or prognostic marker by using the c-ISH in liquid-based specimens. PCR was also performed for the comparison.

Although HPV type 52 was not the most commonly detected genotype in this study, which does not agree with the results obtained in a previous report [8], this difference is probably due to the selected LSIL patients who were followed up without any treatment.

Table 3: Combination of Papanicolaou and c-ISH signal patterns to detect CIN1 or CIN2/3.

		histology					
		metaplasia/cervicitis	CIN1	CIN2/3		LSIL-CIN1	HSIL-CIN2/3
(1) cytology:	NILM	3	0	0	sensitivity	69.2% (9/13)	76.9% (10/13)
Pap	LSIL	1	9	3	specificity	80.0% (16/20)	90.0% (18/20)
	ASC-US	3	2	0	PPV	69.2% (9/13)	83.3% (10/12)
	HSIL	0	2	10	NPV	80.0% (16/20)	85.7% (18/21)
(2) cytology:	NILM	0	0	0	sensitivity	88.9% (8/9)	66.7% (2/3)
Pap with c-ISH	LSIL	0	8	1	specificity	66.7% (2/3)	100% (9/9)
($E \geqq I$)	ASC-US	0	1	0	PPV	88.9% (8/9)	100% (2/2)
	HSIL	0	0	2	NPV	66.7% (2/3)	90.0% (9/10)
(3) cytology:	NILM	0	0	0	sensitivity	50% (1/2)	88.9% (8/9)
Pap with c-ISH	LSIL	0	1	1	specificity	88.9% (8/9)	50.0% (1/2)
($I > E$)	ASC-US	0	0	0	PPV	50% (1/2)	88.9% (8/9)
	HSIL	0	1	8	NPV	88.9% (8/9)	50.0% (1/2)

Pap, Papacicolaou; NILM, negative for intraepithelial lesion; LSIL, low grade squamous intraepithelial lesion;
ASC-US, atypical squamous cells of undetermined significance; HSIL, high grade squamous intraepithelial lesion;
CIN, cervical intraepithelial neoplasia; PPV, positive predictive value; NPV, negative predictive value
The calculated sensitivity, d/b+d; specificity, a/a+c; PPV, d/c+d; NPV, a/a+b.
LISL-CIN1: [a]Cytology was NILM, ASC-US, HSIL and histology was metaplasia/cervicitis, CIN2/3 [b]Cytology was NILM, ASC-US, HSIL and histology was CIN1 [c]Cytology was LSIL and histology was metaplasia/cervicitis, CIN2/3 [d]Cytology was LSIL and histology was CIN1 . HSIL-CIN2/3; [a]Cytology was NILM, ASC-US, LSIL and histology was metaplasia/cervicitis, CIN1 [b]Cytology was NILM, ASC-US, LSIL and histology was CIN2/3 [c]Cytology was HSIL and histology was metaplasia/cervicitis, CIN1 [d]Cytology was HSIL and histology was CIN2/3.

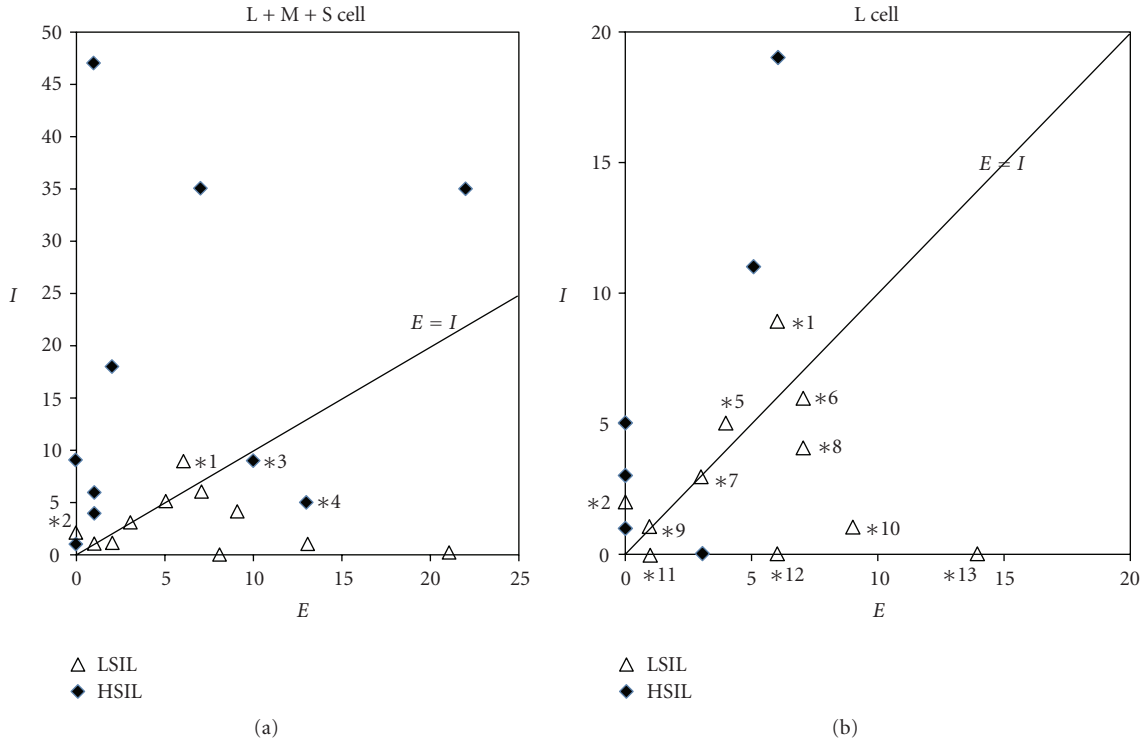

Figure 3: The scatter plot graph of c-ISH positive cells of LSIL or HSIL patients in Table 2. c-ISH positive cells of LSIL or HSIL patients were plotted by signal patterns (E or I) for (a) total cell population (L (large-sized cell) + M (medium-sized cell) + S (small-sized cell)) or (b) L cell (large-sized cell) population. Follow-up conditions of patients: ∗1 (case 4), NILM (PCR 58+, ISH+); ∗2 (case 15), CIN2, ISH-; ∗5 (case 13), HSIL (moderate dysplasia) (PCR 16+, ISH+); ∗6 (case 5), ∗7 (case 6), ∗8 (case 12), ∗11 (case 14), ∗12 (case 8): NILM (PCR-, ISH-); ∗9 (case 11), CIN1, conization; ∗10 (case 9), CIN3 (CIS), conization; ∗13 (case 7); NILM. h-ISH of ∗3 and ∗4 patient: ∗3 (case 25), The number of E (+) S-cells were more than that of I (+) L + M +S-cell.; ∗4 (case 26), Both CIN1 and CIN3 lesion were observed in the same histological specimen.

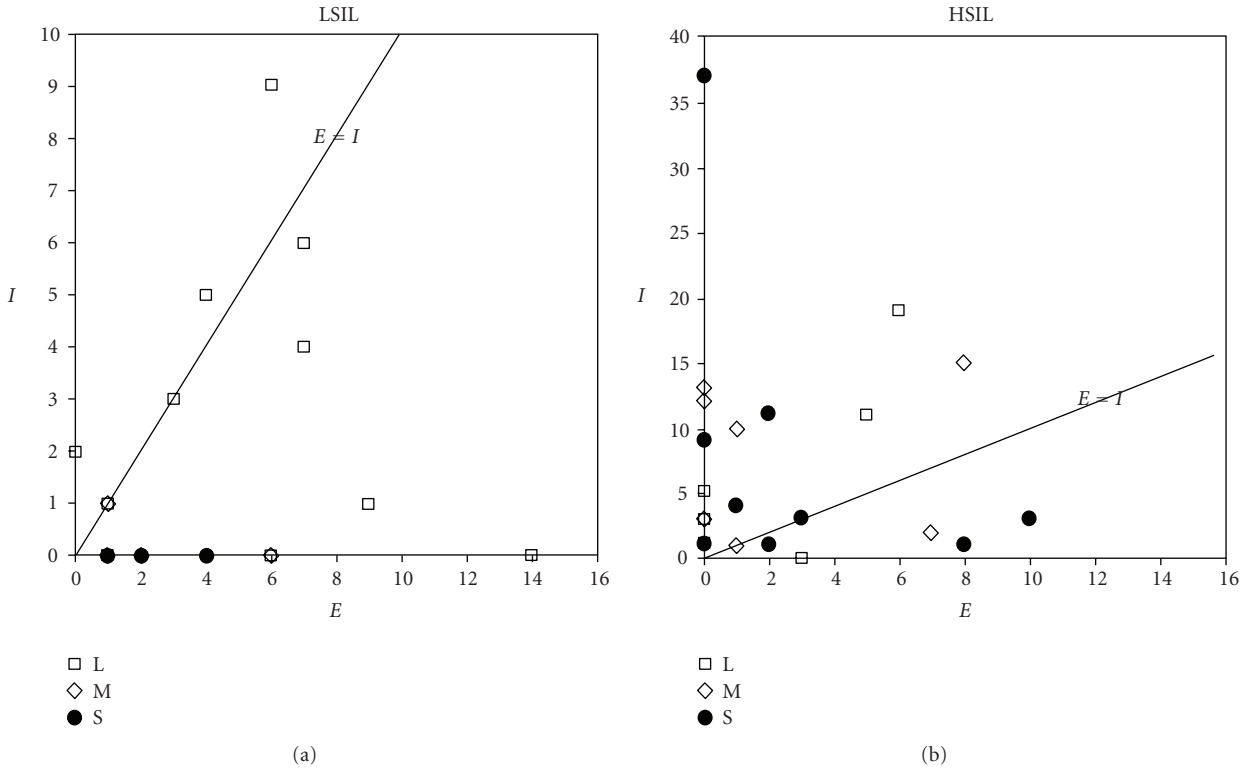

Figure 4: The scatter plot graph of each c-ISH positive cell population in Table 2. The signal patterns of each cell population (L (large-sized cell), M (medium-size cell), and S (small-sized cell)) were plotted for LSIL (a) or HSIL (b) patients.

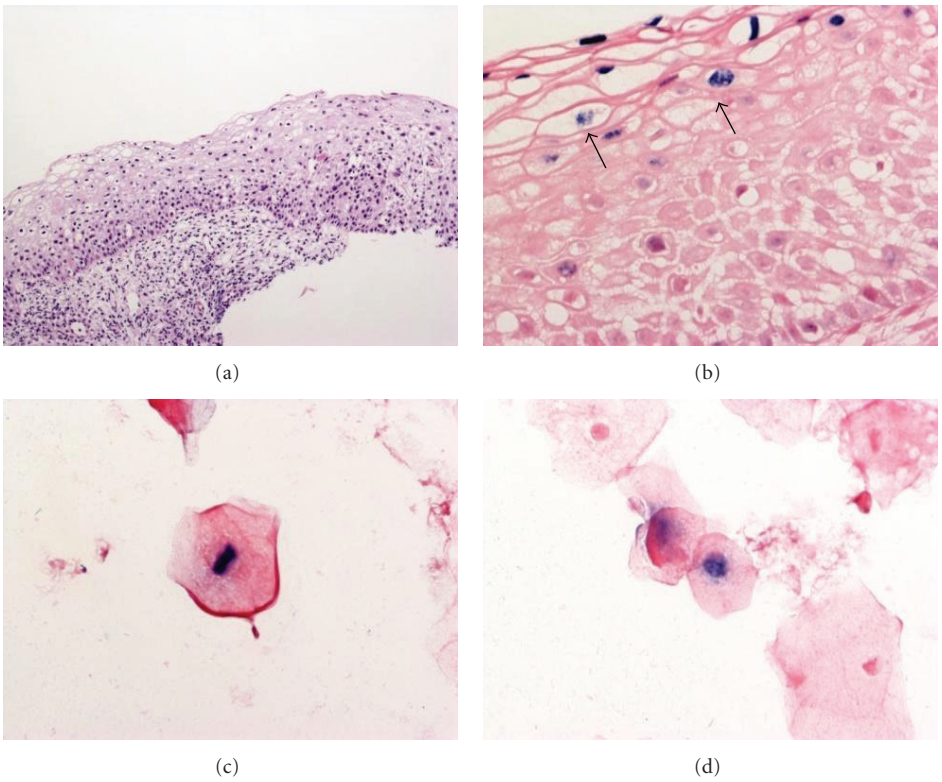

Figure 5: h-ISH and c-ISH of case 4 patient (CIN1). CIN1 (HE, ×100) (a). *E*- or *I*-signal (arrows) positive superficial cells are observed in h-ISH (×400) (b). c-ISH shows the *E*-signal (c) or *I*-signal (d) positive large-sized cells (×400).

We used Ventana autostainer for the ISH examination using the Inform HPV III probe. Guo et al. [11] reported an ISH method, which uses the Inform HPV III probe. This method has significantly improved sensitivity compared to HPV II, and this sensitivity is comparable to PCR for detecting HPV DNA in tissue sections. Although higher specificity was reported [12, 13], Alameda et al. [14] pointed out that the Ventana Inform has lower sensitivity. However, the version used is not described in the report. In this study, we detected c-ISH positive signals, which were similar to the results provided by PCR in both LSIL and HSIL. We also detected more positive signals of c-ISH than of h-ISH in PCR-positive LSIL cases (91.6% (11/12) versus 58.3%(7/12)) and PCR-positive HSIL cases (90% (10/11) versus 81.8% (9/11)). Thus, c-ISH is revealed to be more sensitive than h-ISH, especially in low-grade lesions. As discussed by Guo et al. [11], the heterogenous distribution of HPV in low-grade CIN might cause signal absence in tissue sections, resulting in false-negative results. On the other hand, in case 10 (CIN3), weak integrated signals were detected in h-ISH but not in c-ISH. Because the punctate signal pattern is known to be more frequent in CIN3 and because it becomes more difficult to recognize or interpret the ISH signals, it is possible that we did not recognize the weak signals in c-ISH.

In evaluating the ISH signals, diffuse, punctate + diffuse, and punctate patterns were described previously [2, 14]. As the coexistent pattern (punctate + diffuse) was found to be abundant in both h-ISH and c-ISH, we classified the c-ISH signal patterns into $E \geqq I$ and $I > E$ categories according to the number of E+ or I+ cells in each case. Therefore, we found that the $E \geqq I$ pattern corresponds to LSIL, and the $I > E$ pattern corresponds to HSIL. The differences were found to be statistically significant ($P < 0.01$). The signal patterns of c-ISH seem to be very useful for diagnosing the SIL. In the combination of the Papanicolaou test with the c-ISH signal patterns, HSIL with the $E \geqq I$ pattern increased the specificity, PPV and NPV, and the $I > E$ pattern increased the sensitivity and PPV for detection of CIN2 or more advanced lesions. And also LSIL with $E \geqq I$ pattern increased the sensitivity and PPV, $I > E$ pattern increased the specificity and NPV to detect the CIN1. So, the combination of Papanicolaou test with c-ISH signal patters appears to be useful in the diagnosis of CIN lesion. However, the specificity and NPV of HSIL with $I > E$ to detect CIN2/3 was decreased to 50% (1/2). LSIL with E $\geqq$ I pattern decreased the specificity and NPV (66.7%) to detect CIN1. Therefore, the results of signal patterns of c-ISH are useful if they are separately thought about the sensitivity and specificity in the cases of LSIL or HSIL compared with the diagnosis of CIN.

The $E > I$ pattern cases of HSIL ($*3$ and $*4$) shown in Figure 3 are discussed. In $*3$ (case 25), many E+ S-cells were detected. It is difficult to demonstrate a diffuse integrated pattern in ISH using Ventana system [12]. Therefore, there is a possibility that c-ISH-positive S-cells undergo diffuse integrated staining. In the case of $*4$ (case 26), both CIN1 and CIN3 (severe dysplasia) lesions were observed in the same histological specimen. Because the cytological specimens were composed of superficial and intermediate layered cells according to the histological analysis, the E+ cells of CIN1 appear to be easily detected in c-ISH.

We focused on the LSIL patients with an $I > E$ pattern indicating L-sized positive cells, because an atypical persistent detection of HPV in NILM or progression to HSIL were observed during the followup of these patient. Although persistent detection of HPV is reported to be common among CIN patients at followup even in cases where cytology and histology results are obtained [2], the integration of high-risk HPV is generally a key event in cervical carcinogenesis [10]. De Marchi Triglia et al. [9] reported that the presence of a punctate signal in the superficial layer in histological analysis is associated with cases without progression. Although we did not detect the I-positive S-sized cells in c-ISH in both the case 4 and 13, I-positive basal cells were detected in h-ISH. We do not know the correlation between I-positive basal and superficial cells as well as the destiny of I-positive superficial cells now. To reveal the significance of I-positive L-cell (c-ISH) and superficial cells (h-ISH), we will investigate such cases in the future studies involving a greater number of patients.

5. Conclusion

We investigated c-ISH (Ventana method) for liquid-based cytology specimens and detected c-ISH-positive cells that showed E- or I-signals. From these cases, the $E \geqq I$ pattern was found to be in LSIL, and the $I > E$ pattern in HSIL, and the differences were revealed to be statistically significant ($P < 0.01$). In follow-up examination for the LSIL cases, we found the 2 patients who had large-sized cells with the $I > E$ pattern. They showed HPV persistence and/or progression during follow-up. Therefore, presence of the $I > E$ pattern of c-ISH large-sized cells in LSIL may be a promising marker for follow-up studies.

Acknowledgment

This work was financially supported in parts by the National Hospital Organization of Japan.

References

[1] M. Narisawa-Saito and T. Kiyono, "Basic mechanisms of high-risk human papillomavirus-induced carcinogenesis: roles of E6 and E7 proteins," *Cancer Science*, vol. 98, no. 10, pp. 1505–1511, 2007.

[2] T. Fujii, M. Saito, T. Iwata et al., "Ancillary testing of liquid-based cytology specimens for identification of patients at high risk of cervical cancer," *Virchows Archiv*, vol. 453, no. 6, pp. 545–555, 2008.

[3] B. Samama, C. Schaeffer, and N. Boehm, "P16 expression in relation to human papillomavirus in liquid-based cervical smears," *Gynecologic Oncology*, vol. 109, no. 2, pp. 285–290, 2008.

[4] A. B. Moscicki, S. Shiboski, N. K. Hills et al., "Regression of low-grade squamous intra-epithelial lesions in young women," *Lancet*, vol. 364, no. 9446, pp. 1678–1683, 2004.

[5] G. Gallo, M. Bibbo, L. Bagella et al., "Study of viral integration of HPV-16 in young patients with LSIL," *Journal of Clinical Pathology*, vol. 56, no. 7, pp. 532–536, 2003.

[6] T. M. Grogan, H. Nitta, L. Pestic-Dragovich, L. Pang, and J. Ji, *Interpretation Guide for Ventana INFORM® HPV Probes In Situ Hybridization(ISH) Staining of Cervical Tissue*, Ventana Medical Syatems, 2006.

[7] M. Lin, L. Y. Yang, L. J. Li, J. R. Wu, Y. P. Peng, and Z. Y. Luo, "Genital human papillomavirus screening by gene chip in Chinese women of Guangdong province," *Australian and New Zealand Journal of Obstetrics and Gynaecology*, vol. 48, no. 2, pp. 189–194, 2008.

[8] T. Nakagawa, H. Hirano, M. Kobayashi, K. Ishida, S. Ishida, and M. Nagasaki, "Human papillomavirus (HPV) genotyping and detection of HPV genome integration in cervical lesions by liquid-based cytology," *Modern Trends in Obstetrics & Gynecology*, vol. 59, pp. 5–10, 2010 (Japanese).

[9] R. De Marchi Triglia, K. Metze, L. C. Zeferino, and L. A. Lucci De Angelo Andrade, "HPV in situ hybridization signal patterns as a marker for cervical intraepithelial neoplasia progression," *Gynecologic Oncology*, vol. 112, no. 1, pp. 114–118, 2009.

[10] M. Pett and N. Coleman, "Integration of high-risk human papillomavirus: a key event in cervical carcinogenesis?" *Journal of Pathology*, vol. 212, no. 4, pp. 356–367, 2007.

[11] M. Guo, Y. Gong, M. Deavers et al., "Evaluation of a commercialized in situ hybridization assay for detecting human papillomavirus DNA in tissue specimens from patients with cervical intraepithelial neoplasia and cervical carcinoma," *Journal of Clinical Microbiology*, vol. 46, pp. 274–280, 2008.

[12] L. J. Layfield and M. N. Qureshi, "HPV DNA testing in the triage of atypical squamous cells of undetermined significance (ASCUS): cost comparison of two methods," *Diagnostic Cytopathology*, vol. 33, no. 2, pp. 138–143, 2005.

[13] D. F. I. Kurtycz, M. Smith, R. He, K. Miyazaki, and J. Shalkham, "Comparison of methods trial for high-risk HPV," *Diagnostic Cytopathology*, vol. 38, no. 2, pp. 104–108, 2010.

[14] F. Alameda, M. L. Marinoso, B. Bellosillo et al., "Detection of HPV by in situ hybridization in thin-layer (ThinPrep) cervicovaginal samples," *Tumor Biology*, vol. 32, pp. 603–609, 2011.



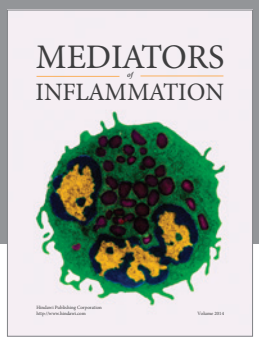



Hindawi

Submit your manuscripts at
http://www.hindawi.com