

## Clinical Study

# Lung Cancer Diagnosed More Than Five Years after the Development of Polymyositis/Dermatomyositis

**Ken Uchibori, Tomoyuki Ogata, Tuyoshi Shirai, Shuta Yamauchi, Masahiro Masuo, Sahoko Chiba, Haruhiko Furusawa, Kimitake Tsuchiya, Toshihide Fujie, Meiyo Tamaoka, Hiroyuki Sakashita, Yuki Sumi, Yasunari Miyazaki, and Naohiko Inase**

*Department of Pulmonary Medicine, Tokyo Medical and Dental University, 1-5-45 Yushima, Bunkyo-ku, Tokyo 113-8519, Japan*

Correspondence should be addressed to Yuki Sumi; [ysumi.pulm@tmd.ac.jp](mailto:ysumi.pulm@tmd.ac.jp)

Received 29 March 2013; Accepted 8 May 2013

Academic Editors: C. Flores and A. S. Melani

Copyright © 2013 Ken Uchibori et al. This is an open access article distributed under the Creative Commons Attribution License, which permits unrestricted use, distribution, and reproduction in any medium, provided the original work is properly cited.

**Background.** The patients with polymyositis (PM) and dermatomyositis (DM) often develop the malignancies in their clinical course. The incidence of cancer is estimated at about 15%. The risk of cancer is the highest within the first year of myositis diagnosis and drops substantially thereafter. The patients with lung cancer diagnosed more than 5 years after the onset of PM or DM are the minority. **Methods and Patients.** We surveyed the medical records of patients with lung cancer over the period from 1995 to 2011. **Results.** We found five patients who developed lung cancer more than 5 years after the diagnosis of PM/DM. Three patients were male, and two were female. The median age was 61.2 ( $\pm 11.7$ ). Histological types were diverse. The clinical stages ranged from IA to IV. Three patients had smoking histories. Four patients suffered from DM, and one suffered from PM. All patients received oral corticosteroid therapy. Two patients also received ciclosporin, and another two received azathioprine. Anti-Jo-1 antibody was positive in one patient. Four patients were complicated with interstitial pneumonia (IP). **Conclusion.** These lung cancers diagnosed more than 5 years after the onset of PM/DM were probably related to IP or smoking but might not be comorbid with PM/DM.

## 1. Background

Idiopathic inflammatory myopathies are a group of chronic systemic autoimmune diseases that mainly affect the skeletal muscle. The common subtypes include adult dermatomyositis (DM), polymyositis (PM), and inclusion body myositis. In 1975, Bohan and Peter proposed the diagnostic criteria for DM and PM using clinical, laboratory, and pathological features which remain to be the gold standard for use in clinical studies (Table 1). These data were conducted in western population [1, 2]. On the other hand, Ungprasert et al. reviewed the characteristics of PM/DM in Asia [3]. They described that DM is more common, with the ratio of DM to PM being 1.36:1. Sixty-nine percent of them were females with mean age of 45.5 years. Extramuscular manifestations, including arthritis/arthralgia, dysphagia, and interstitial lung disease (IP), are found in one-third of the

patients. They also clarified that the malignancy was found in 10% of patients. The link between PM and malignancy (gastric cancer) was first described in a case report by Sterz in 1916 [4]. While the most available evidence points to an association between DM and malignancy, the association with PM is much weaker [5, 6]. The incidence of cancer in patients with DM and PM is estimated at about 15% [7–10]. Of the cancers diagnosed before DM, most precede the myositis by 2 years or less [9]. The risk of cancer is the highest within the first year of myositis diagnosis and drops substantially thereafter [8, 9]. The cancer risk in patients with PM returns to the expected rates for the general population 5 years after diagnosis, whereas that in patients with DM remains higher than the expected population values for most cancers [9]. Gastric cancer and lung cancer are the two most frequent reported malignancies, accounting for 19.3% and 24.4% of cases, respectively [11]. The most frequent histopathologic

TABLE 1: Bohan and Peter diagnostic criteria for dermatomyositis/polymyositis.

- (1) Symmetrical weakness of limb-girdle muscles and anterior neck flexor
- (2) Muscle biopsy shows evidence of characteristic myositis
- (3) Elevated serum skeletal muscle specific enzyme, especially creatinine phosphokinase
- (4) Electromyographic (EMG) evidence of myositis
- (5) Typical dermatomyositis rash, including heliotrope and Gottron's papules

Definite polymyositis: all of items (1)–(4); probable: any three of items (1)–(4); possible: any two of items (1)–(4). Definite dermatomyositis: item (5) plus any three of items (1)–(4); probable: item (5) plus any two of items (1)–(4); possible: item 5 plus any one of items (1)–(4).

type of lung cancer reported in Japan is small cell carcinoma (SCLC) (48%), followed by squamous cell carcinoma (SCC) (20%) and adenocarcinoma (16%) [11].

PM/DM is probably a paraneoplastic event in some patients. Ovarian, lung, and colorectal cancers have been diagnosed frequently both before and after the PM/DM diagnosis, which suggests that these cancers may be associated with the disease [9]. Two findings, namely, improvement of PM/DM after cancer treatment and recurrence of muscle weakness at relapse of malignant disease, further suggest a paraneoplastic origin [12]. This paraneoplastic phenomenon may stem from an immune reaction to antigens expressed in both cancer cells and regenerating fibers in affected muscle. Various tumors express high levels of myositis autoantigens and an autoimmune response directed against cancer which cross-reacts with regenerating muscle cells [13, 14]. Casciola-Rosen et al. reported a possible mechanism behind the link between malignancy and inflammatory myopathy [13]. Regenerating cells in myositis muscle not in normal muscle express high levels of myositis-specific antigens: Mi-2, the catalytic subunit of DNA-dependent protein kinase. They proposed that an autoimmune response directed against cancer cross-reacts with regenerating muscle cells.

Our group sought to investigate the characteristics of patients who were diagnosed with lung cancer more than 5 years after the diagnosis of PM/DM.

## 2. Methods and Patients

We retrospectively surveyed the medical records of 800 inpatients with lung cancer treated at Tokyo Medical and Dental University Hospital between 1995 and 2011.

## 3. Results

Five of the lung cancer inpatients were diagnosed more than 5 years after the diagnosis of PM/DM (Table 2).

Case 1 (Figure 1) was a 69-year-old male exsmoker (Brinkman Index (daily number of cigarettes  $\times$  years) (B.I.) 1440) who had been diagnosed with DM at the age of 56 with primary manifestations of bilateral femoral myalgia, multiple

arthralgia, and difficulty in lifting his left arm. Laboratory data revealed elevated creatinine kinase ((CK) 5258 IU/L) and the presence of anti-Jo-1 antibody. IP was detected in the chest CT. Oral prednisolone (PSL) was started at 60 mg/day and tapered to 3 mg/day. Six years later, the patient was diagnosed with IP and started on ciclosporin (CyA) 150 mg/day. CyA-induced renal dysfunction developed after 5 years of CyA treatment, prompting a switch to tacrolimus treatment instead. Eleven years from the DM onset, the patient's response to PSL weakened, and his IP deteriorated. In response, his physicians increased the PSL dose and started him on cyclophosphamide (CPA) therapy. PSL was tapered again to 3 mg/day, and azathioprine (AZP) was selected as an alternative immunosuppressant. Thirteen years from the DM onset, a tumor of the left pulmonary hilum was detected on a chest X-ray. CT examination revealed liver metastasis at the time of cancer diagnosis. Large cell neuroendocrine carcinoma (LCNEC), cT1aN1M1b (HEP) stage IV, was diagnosed.

Case 2 (Figure 2) was a 47-year-old male current smoker (B.I. 750) who had been diagnosed with DM at the age of 40 with primary manifestations of skin rash and stiff shoulders. CK was elevated (2039 IU/L), and anti-Jo-1 antibody was absent in the laboratory data. No evidence of interstitial pneumonia was found in the chest CT. Oral PSL was started at 60 mg/day and tapered to 10 mg/day. After three years, CyA was commenced at an initial dose of 100 mg/day to control the DM activity, but the dose had to be increased to 400 mg/day. Ten years after the onset of DM, chest X-ray and CT examinations revealed several small tumors in the posterior segment of the right superior lobe, along with enlargement of mediastinal lymph nodes. Small cell lung carcinoma (SCLC), cT1aN2 M0 stage IIIA, was diagnosed.

Case 3 (Figure 3) was a 69-year-old female never-smoker who had been diagnosed with PM at the age of 63 with primary manifestations of general malaise and difficulty in lifting her arms. CK was elevated (9190 IU/L), and anti-Jo-1 antibody was absent in the laboratory data. Mild IP was evident in the chest CT. Oral PSL (50 mg/day) and AZP (100 mg/day) were commenced together, and the former was gradually tapered to 2.5 mg/day. Eighteen months later the patient moved abroad temporarily. While abroad, she discontinued the AZP completely and received PSL only intermittently. After returning to Japan, her myositis worsened, compelling us to resume treatment with both PSL (15 mg/day) and AZP (150 mg/day). Several months later she complained of pain in the right back. A tumor of 5 cm diameter was detected by chest X-ray in the right inferior lung field. Adenocarcinoma, cT3N3M1b (LYM, HEP) stage IV, was diagnosed.

Case 4 (Figure 4) was a 71-year-old female never-smoker who had been diagnosed with DM at the age of 41 with primary manifestations of skin rash, general malaise, and weakness. Laboratory data revealed elevated CK, but anti-Jo-1 antibody was not tested. Mild IP was detected in a chest CT examination 17 years after the DM was diagnosed. Oral PSL was started at 50 mg/day and tapered gradually to 5 mg/day with good control of the DM activity. Thirty years after the DM onset she complained of fever and cough, and chest X-ray revealed infiltrative shadows in the left lung field. Poorly

TABLE 2: Profiles of the 5 patients. Only 1 patient had PM, and only 1 patient was positive for anti-Jo1 antibody. Immunosuppressants were coadministered with PSL in 4 patients. Four patients had complication with IP. The histological patterns and stages were diverse. Three patients were heavy smokers.

Case Age	Myositis	Time from myositis to LK	Anti-Jo1	Treatment for PM/DM (at diagnosis of LK)	IP	Histological pattern	Clinical staging	B.I.
Case 1 69 y. M	DM	13 y. 9 m.	+	PSL + AZP (CyA, Tac., mPSL, and CPA)	+	LCNEC	Stage IV	1440 Ex.
Case 2 47 y. M	DM	7 y. 8 m.	–	PSL + CyA	–	SCLC	Stage IIIA LD	750 Curr.
Case 3 69 y. F	PM	5 y. 7 m.	–	PSL + AZP	+	Adeno	Stage IV	0
Case 4 71 y. F	DM	30 y.	Unknown	PSL	+	Adeno	Stage IV	0
Case 5 50 y. M	DM	12 y.	–	PSL + CyA	+	SCC	Stage IA	600 Ex.

DM: dermatomyositis; PM: polymyositis; PSL: prednisolone; CyA: ciclospoin; CPA: cyclophosphamide; AZP: azathioprine; Tac: tacrolimus; LCNEC: large cell neuroendocrine carcinoma; SCLC: small cell carcinoma; Adeno: adenocarcinoma; SCC: squamous cell carcinoma; B.I.: Brinkman Index; Ex.: exsmoker; Curr.: current smoker.

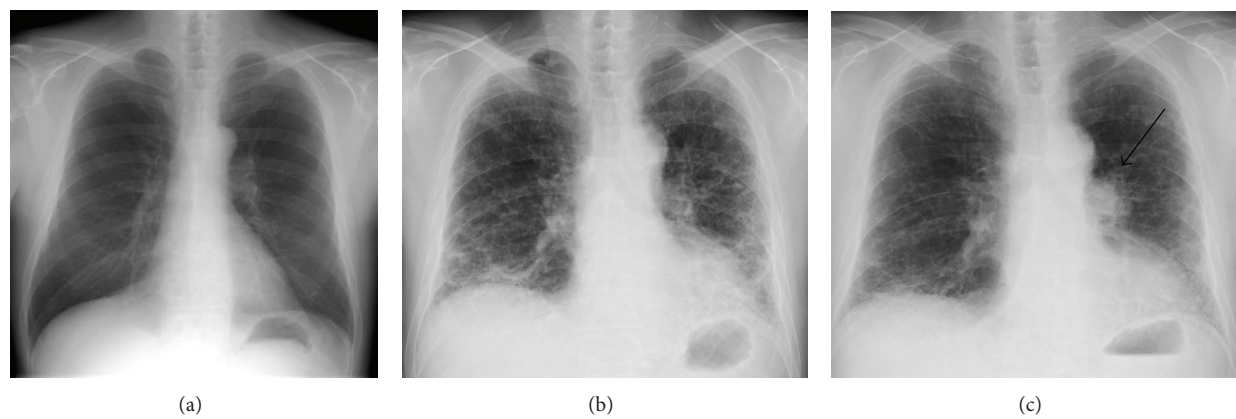


FIGURE 1: Chest X-ray at the onset of DM (a). Chest X-ray at the deterioration of IP 11 years after the onset of DM (b). X-ray at the lung cancer diagnosis 13 years after the onset of DM (c).

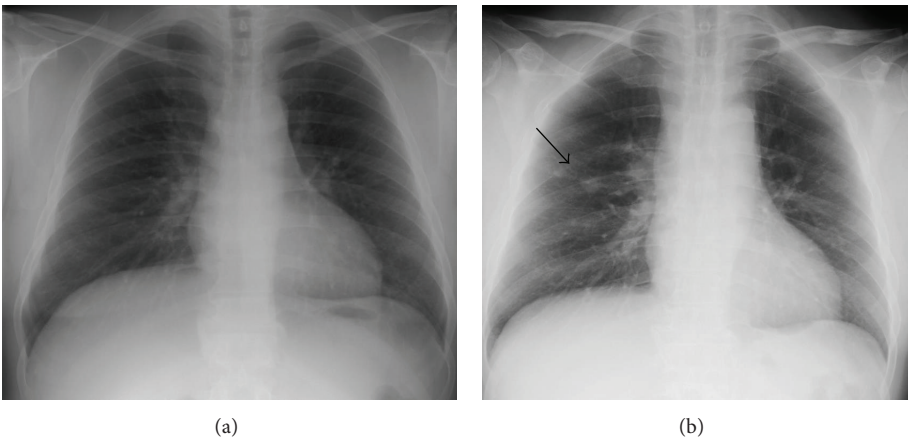


FIGURE 2: Chest X-ray at the onset of DM (a). Chest X-ray at the lung cancer diagnoses revealing a small tumor in the right middle lung field 7 years after the onset of DM (b).

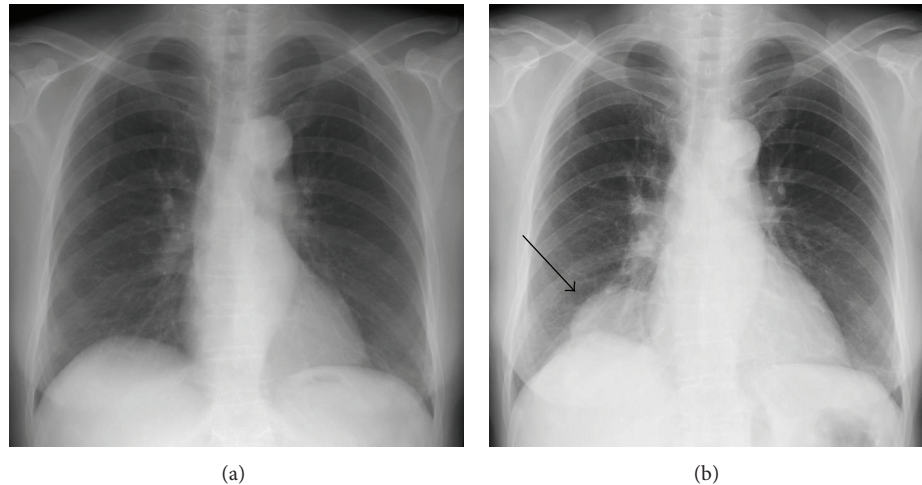


FIGURE 3: Chest X-ray at the onset of DM (a). Chest X-ray at the lung cancer diagnoses showing a tumor in the right lower lung field 5 years after the onset of DM (b).

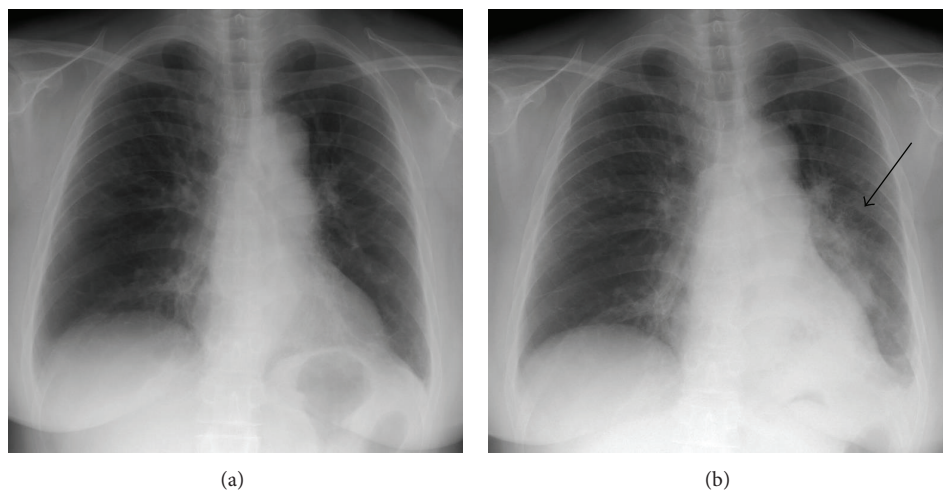


FIGURE 4: Chest X-ray at the onset of DM (a). Chest X-ray at the lung cancer diagnosis revealing infiltrative shadows in the left lung field 30 years after the onset of DM (b).

differentiated adenocarcinoma, cT4N2M1 (BRA, SKI, ADR, and OTH), was diagnosed.

Case 5 (Figure 5) was a 50-year-old male ex-smoker (B.I. 600) who had been diagnosed with DM at the age of 38 with primary manifestations of arthralgia, dyspnea, and slight fever. CK was elevated (2747 IU/L), and anti-Jo-1 antibody was absent in the laboratory data. IP was detected on the chest CT. Oral PSL was started at 60 mg/day and tapered to 10 mg/day. CyA (200 mg/day) was administered concurrently, and both drugs were continued at the same doses for 12 years. Twelve years after the DM diagnosis, a chest CT scan revealed a nodule in the lateral-basal segment of the right inferior lobe. SCC, cT1N0M0, was diagnosed.

#### 4. Conclusion

In summary, 4 patients were diagnosed with DM, and 1 was diagnosed with PM. Three patients were male, and 2 were female. The average age of the patients at lung cancer

diagnosis was 61.2 years old ( $\pm 11.2$ ). Anti-Jo-1 antibody was positive in only 1 patient. Three patients were smokers: 2 were exsmokers (B.I. 1440, 600), and 1 was a current smoker (B.I. 750). All 5 patients received glucocorticoids for treatment of PM/DM, 2 received CyA, and 2 received AZP as an immunosuppressant. Four patients (80%) suffered from complication with IP when the PM/DM was diagnosed, but none had deteriorated to the point of respiratory failure. The pathological findings and stages were diverse: 1 patient had SCLC stage IIIA, 1 patient had LCNEC stage IV, 1 patient had SCC stage IA, and 2 patients had adenocarcinoma clinical stage IV. The patient with SCC underwent surgery, the patient with SCLC underwent chemoradiation, and the others received chemotherapy only.

#### 5. Discussion

PM and DM are both reported to be strongly associated with an elevated risk of malignant disease [15]. The onset



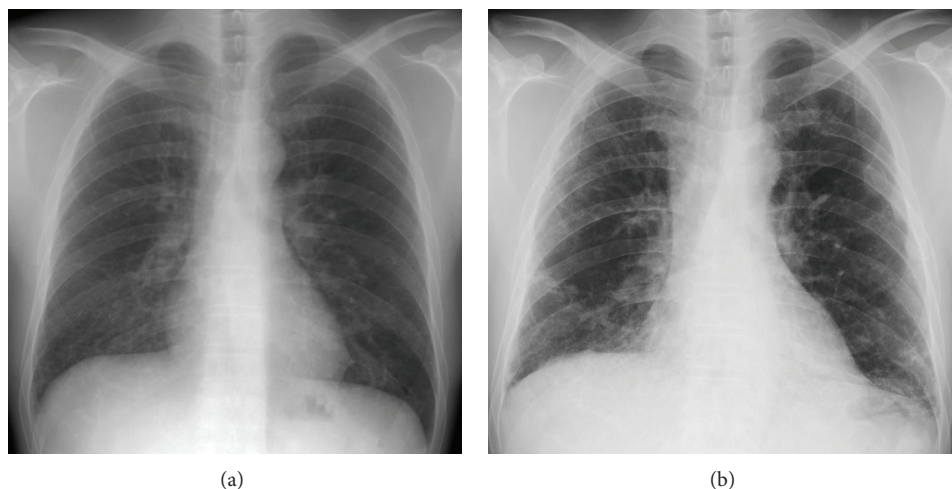


FIGURE 5: Chest X-ray at the onset of DM (a). Chest X-ray at the lung cancer diagnosis 12 years after the onset of DM (b).

of PM/DM has been frequently observed shortly before or after the detection of malignant disease. This suggests that some cases of PM/DM stem from an immune reaction to antigens expressed in both cancer cells and muscles. In the current review we identified five patients with PM/DM who developed lung cancer more than 5 years after the onset of PM/DM. We suggest that the incidence of late cancers could be independent from PM/DM which develops due to coexpressing antigen between cancer cells and muscles. Though the lung cancers cells certainly could have arisen more than 5 years before they became clinically apparent, the tumor cells would have been too scanty in number to trigger the vast immune responses observed in PM/DM. Rather, we suspect that the patient backgrounds or drugs used to treat the PM/DM contributed to the carcinogenesis.

The evidence linking cigarette smoking to human lung cancer has included a large volume of both prospective and retrospective epidemiologic research. The Surgeon General of the United States definitively concluded that “cigarette smoking is the major cause of lung cancer” [16]. Estimates of the relative risk of lung cancer in the long-term smoker compared with the lifetime nonsmoker vary from 10- to 30-fold. The cumulative lung cancer risk among heavy smokers may be as high as 30 percent, compared with a lifetime risk of lung cancer of 1 percent or less in nonsmokers. The risk being the highest for SCC, followed by SCLC and adenocarcinoma [17]. Therefore the lung cancers of cases 1, 2, and 5 are possibly related to smoking.

IP is also sometimes complicated with PM/DM and associated with lung cancers in the clinical course. Individuals with diffuse pulmonary fibrosis are estimated to have a 14-fold increased risk for lung cancer, even when controlling for age, gender, and smoking history [18, 19]. In our review, 4 out of 5 patients (cases 1, 3, 4 and 5) suffered a comorbidity with IP.

The important role of asbestos exposures in lung cancer etiology is well established [17]. Patients with prior asbestos exposure complicated by interstitial fibrosis (i.e., asbestosis) are much more likely to develop lung cancer than patients

with asbestos exposure alone. In our review, case 2 had a past exposure to asbestos.

Patients with PM/DM are usually treated with glucocorticoids and immunosuppressants. While glucocorticoids are established to be noncarcinogenic, some drugs, for example, alkylating agents, do have proven carcinogenic effects. This suggests that the long-term administration of immunosuppressants may increase the risk of malignancy [8]. The patients in our review received the immunosuppressants CPA, AZP, and CyA, in addition to steroids. The IARC, an agency operating within the World Health Organization, has evaluated the carcinogenic risk for all three of these agents [20]. All three are sufficiently proven to be carcinogenic in humans. CPA exerts its carcinogenic effect via a genotoxic mechanism after the agent is bioactivated to alkylating metabolites. CPA is as an independent cause of acute myeloid leukemia and bladder cancer, but there is no evidence that it elevates the risk of lung cancer. AZP exerts its carcinogenic effect via two mechanisms. As an immunosuppressant, AZP is associated with posttransplant lymphoproliferative disorders with a generally viral etiology. In parallel, it contributes to cancer by damaging DNA, more specifically, by causing 6-thioguanine to accumulate within the DNA. AZP causes cancer of the skin (SCC) and non-Hodgkin lymphoma. There is no evidence, however, that AZP increases the risk of lung cancers. CyA is an immunosuppressant, and long-term immunosuppression is linked to an increased risk of cancer. CyA causes cancer of the skin (squamous cell carcinoma) and multiple other organs (oral cavity, vagina, cervix, colon, and rectum), as well as non-Hodgkin lymphoma. Yet as with CPA and AZP, no studies demonstrate an association between CyA and an increased incidence of lung cancer. On these grounds, the patients’ lung tumors in our review might not be caused by the immunosuppressants the patients received.

In conclusion, we believe that the lung cancers diagnosed more than 5 years after the diagnosis of PM/DM in our cases were more likely to have been related to smoking or IP than to myositis or the immunosuppressive drugs used for PM/DM treatment.

## References

- [1] A. Bohan and J. B. Peter, "Polymyositis and dermatomyositis—I," *New England Journal of Medicine*, vol. 292, no. 7, pp. 344–347, 1975.
- [2] A. Bohan and J. B. Peter, "Polymyositis and dermatomyositis (Second of two parts)," *New England Journal of Medicine*, vol. 292, no. 8, pp. 403–407, 1975.
- [3] P. Ungprasert, N. Leeaphorn, N. Hosiriluck et al., "Clinical features of inflammatory myopathies and their association with malignancy: a systematic review in Asian population," *ISRN Rheumatology*, vol. 2013, Article ID 509354, 7 pages, 2013.
- [4] G. Sterz, "Polymyositis," *Berlin Klinische Wochenschrift*, vol. 53, article 489, 1916.
- [5] B. B. Antiochos, L. A. Brown, Z. Li, T. D. Tosteson, R. L. Wortmann, and W. F. C. Rigby, "Malignancy is associated with dermatomyositis but not polymyositis in Northern New England, USA," *Journal of Rheumatology*, vol. 36, no. 12, pp. 2704–2710, 2009.
- [6] Y. Yazici and L. J. Kagen, "The association of malignancy with myositis," *Current Opinion in Rheumatology*, vol. 12, no. 6, pp. 498–500, 2000.
- [7] D. Stockton, V. R. Doherty, and D. H. Brewster, "Risk of cancer in patients with dermatomyositis or polymyositis, and follow-up implications: a Scottish population-based cohort study," *British Journal of Cancer*, vol. 85, no. 1, pp. 41–45, 2001.
- [8] R. Buchbinder, A. Forbes, S. Hall, X. Dennett, and G. Giles, "Incidence of malignant disease in biopsy-proven inflammatory myopathy: a population-based cohort study," *Annals of Internal Medicine*, vol. 134, no. 12, pp. 1087–1095, 2001.
- [9] C. L. Hill, Y. Zhang, B. Sigurgeirsson et al., "Frequency of specific cancer types in dermatomyositis and polymyositis: a population-based study," *The Lancet*, vol. 357, no. 9250, pp. 96–100, 2001.
- [10] B. Sigurgeirsson, B. Lindelof, O. Edhag, and E. Allander, "Risk of cancer in patients with dermatomyositis or polymyositis—a population-based study," *New England Journal of Medicine*, vol. 326, no. 6, pp. 363–367, 1992.
- [11] Y. Saito, M. Odaka, S. Sato et al., "Clinicopathological study of resected and autopsied cases of lung cancer associated with dermatomyositis," *Japanese Journal of Lung Cancer*, vol. 44, no. 7, pp. 763–766, 2004.
- [12] M. A. Verducci, G. D. Malkasian Jr., S. J. Friedman, and R. K. Winkelmann, "Gynecologic carcinoma associated with dermatomyositis-polymyositis," *Obstetrics and Gynecology*, vol. 64, no. 5, pp. 695–698, 1984.
- [13] L. Casciola-Rosen, K. Nagaraju, P. Plotz et al., "Enhanced autoantigen expression in regenerating muscle cells in idiopathic inflammatory myopathy," *Journal of Experimental Medicine*, vol. 201, no. 4, pp. 591–601, 2005.
- [14] D. Fiorentino and L. Casciola-Rosen, "Autoantibodies to transcription intermediary factor 1 in dermatomyositis shed insight into the cancer-myositis connection," *Arthritis and Rheumatism*, vol. 64, no. 2, pp. 346–349, 2012.
- [15] B. E. Barnes and B. Mawr, "Dermatomyositis and malignancy: a review of the literature," *Annals of Internal Medicine*, vol. 84, no. 1, pp. 68–76, 1976.
- [16] U.S. Department of Health and Human Services, "The Health Consequences of Smoking: A Report of the Surgeon General," Atlanta: U.S. Department of Health and Human Services, Centers for Disease Control and Prevention, National Center for Chronic Disease Prevention and Health Promotion, Office on Smoking and Health, 2004, [http://www.cdc.gov/tobacco/data\\_statistics/sgr/2004/index.htm](http://www.cdc.gov/tobacco/data_statistics/sgr/2004/index.htm).
- [17] M. Parkin, J. E. Tyczynski, P. Boffetta, J. Samet, P. Shields, and N. Caporaso, "Lung cancer epidemiology and etiology," in *Pathology and Genetics of Tumours of the Lung, Pleura, Thymus and Heart*, W. D. Travis, E. Brambilla, H. K. Müller-Hermelink, and C. C. Harris, Eds., pp. 12–15, WHO Press, Geneva, Switzerland, 3rd edition, 2004, <http://www.tchelp.com>.
- [18] R. Hubbard, A. Venn, S. Lewis, and J. Britton, "Lung cancer and cryptogenic fibrosing alveolitis: a population-based cohort study," *American Journal of Respiratory and Critical Care Medicine*, vol. 161, no. 1, pp. 5–8, 2000.
- [19] K. Archotogeorgis, P. Steiropoulos, A. Tzouveleakis, E. Nena, and D. Bouros, "Lung cancer and interstitial lung diseases: a systematic review," *Pulmonary Medicine*, vol. 2012, Article ID 315918, 11 pages, 2012.
- [20] IARC Working Group on the Evaluation of Carcinogenic Risks to Humans, IARC Monographs on the Evaluation of Carcinogenic Risks to Humans IARC Monographs, Volume 100, A Review of Human Carcinogens, Part A: Pharmaceuticals. International Agency for Research on Cancer, Lyon, France, 2008, <http://monographs.iarc.fr/ENG/Monographs/vol100A/index.php>.

