Hindawi Publishing Corporation
Ulcers
Volume 2013, Article ID 734859, 5 pages
http://dx.doi.org/10.1155/2013/734859

Clinical Study

Crossectomy and Foam Sclerotherapy of the Great Saphenous Vein versus Stripping of Great Saphenous Vein and Varicectomy in the Treatment of the Legs Ulcers

Alvaro Delgado-Beltran

Vascular Surgery Center of Girardot, Girardot, Colombia

Correspondence should be addressed to Alvaro Delgado-Beltran; alvarodelgado17@yahoo.com

Received 26 August 2013; Accepted 13 October 2013

Academic Editor: Arkadiusz Jawien

Objective. To show our results in the surgical treatment of legs varicose ulcers, with crossectomy and foam sclerotherapy (CAFE) of the great saphenous vein (GSV) in group I and stripping of GSV and varicectomy in group II. *Methods*. 35 patients with active venous leg ulcers were recruited and treated. They were collected in two groups. Group I were treated by crossectomy and foam sclerotherapy of the GSV and group II were treated by stripping of GSV and varicectomy. The healing time of the ulcer and the complications were recorded after the procedure in the follow-up visits. *Results*. 29 out of the 35 patients completed the follow-up. There were eight cases of incomplete healing of the leg ulcer, 4 in group I (19.04%) and 4 in group II (40%), $P < 0.05$. The average rate of healing in group I was 0.38 cm/day and 0.13 in group II, $P < 0.05$. *Conclusion*. CAFE technique of the great saphenous vein in the treatment of 6 CEAP patients is a procedure that improves the rate of ulcer healing as compared to these two groups. It is a safe and reliable minimally invasive method, with less morbidity.

1. Introduction

Venous ulcers are the last state of the chronic venous insufficiency which treatment is long, expensive, and disappointing. The affected patients are usually treated by compressive therapy of the legs and wound dressings of different kinds [1].

The association of venous ulcers and saphenous vein reflux is well established, and therefore we encourage a rapid surgical decision on these patients focused on the hemodynamic control rather than the treatment of the ulcer alone [2, 3]. Ablative procedures of the superficial venous system with complete resection of the saphenous veins and varix imply the risk of complications such as contamination and infection of the surgical wounds. Reliability of this technique and the recent reintroduction of sclerosing agents with higher foam stability allow the possibility to occlude saphenous trunks with minimal invasiveness and in a very practical way [4].

We report our early experience with crossectomy and foam sclerotherapy (CAFE) of the great saphenous vein in patients with saphenous vein reflux and venous ulceration.

2. Materials and Methods

2.1. Patients and Groups. Between September 2008 and January 2010, 35 patients with active venous leg ulcer were recruited for the study. Twenty-nine accomplished the follow-up period.

Group I consisted of 21 patients (23 limbs), 6 males, and 15 females, with an average age of 58.9 years (range: 36–86). Of the 21 patients, 17 had primary CVI and 4 had postthrombotic limbs.

Group II had 8 patients (10 limbs), 2 males and 8 females, with an average age of 58.5 years (range: 43–71). Three patients had post-thrombotic limbs and 5 had primary CVI (Table 1).

A complete vascular examination was performed in order to rule out significant arterial disease and ABI > 0.9 was found in all the patients; venous ultrasound was done in order to confirm greater or lesser saphenous vein reflux and exclude any occlusive thrombus in the deep or perforator systems. The Doppler duplex scan color evaluations were done with Sonosite MicroMaxx Ultrasound System

(a) (b)

Figure 1: (a) Foam preparation. (b) Foam injection in the great saphenous vein.

Table 1: Patients.

	Group I	Group II
Patients	21	8
Limbs	23	10
Primary CVI (Patients)	17	5
Secondary CVI (Patients)	4	3
Mean age	59	58.5

(Sonosite, Inc. Bothell, WA, USA), 5–10 MHz electronic linear array probe, in standing position in order to find reflux, which was considered positive if it was 1 second or longer, and the saphenous vein diameter was 4 mm or more at the saphenofemoral junction. Then the patient was examined in prone position to exclude the aforementioned thrombus. Size of the ulcer was measured by the use of a metrical strip. These observations were registered in the record of each patient and they were conducted to elective surgery.

In group I the surgical procedure consisted in crossectomy of the affected saphenous vein and the distal saphenous vein was canalized with a 6 F silicon Nelaton urethral tube until the knee level and slowly filled with foam; meanwhile the tube was withdrawn; the foam was built with 6 cc of polidocanol 1% (Polydosclerol, Sigvaris, Sig Med, 16 Parkway North Deerfield, IL, USA) foamed with 18 cc of air (3 : 1) using Tessari's technique [5] (Figures 1(a) and 1(b)) with a three-way stopcock (Elcam Medical A.C.A.L., Bar-Am 13860 Israel) and two plastic syringes, BD Plastipak, Becton Dickinson, Mexico. A severe spasm of the saphenous vein and its main tributaries was observed immediately (Figure 2). The surgical incision was closed and medium stretch elastic bandage compression of the limb was sustained through the first ambulatory control, 3 or 4 days after the surgery. Then it was changed daily.

In Group II all the 8 patients have a crossectomy and removal of the saphenous vein between the groin and the ankle. The medium stretch elastic bandage compression was changed daily. Both, the patients and their relatives were instructed about the way to change and to put the elastic bandages from the forefoot to the above knee area of the leg. The first change was done by us.

Figure 2: Spasm of the great saphenous vein and tributaries.

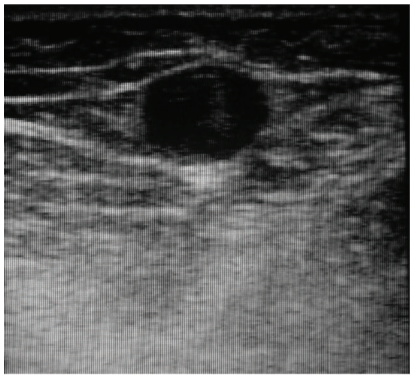

Figure 3: Obliteration of the great saphenous vein.

Clinical and ultrasound follow-up was performed 7 and 14 days after the surgery (Figure 3) and elastic bandage compression was maintained until the ulcer healed. Complete ulcer healing was defined as a full epithelization of the wound and absence of secretions (Figure 4). Ultrasound parameters during follow-up included: detection of possible deep vein thrombosis in both groups and absence of color in

Table 2: Characteristics and evolution of group I patients.

Patient	Age	Gender	Leg	Comorbidities	Ulcer area	Evolution time (months)	Date of surgery	Date of healing	Days	Rate cm/day
1	58	F	Left	SAH	12	16	29/11/2009	06/01/2010	45	0.266
2	61	F	Left	N	20	360	24/10/2009	Not healed		
3	71	F	Left	N	4	12	25/09/2009	12/11/2009	48	0.083
4	62	F	Right	N	16	6	24/09/2009	28/10/2009	38	0.421
5	64	F	Left	SAH	12	15	13/09/2009	07/10/2009	34	0.352
6	63	F	Left	SAH, DVT	180	60	03/09/2009	Not healed		
7	53	M	Left	DVT	2	72	30/08/2009	27/09/2010	28	0.071
8	42	F	Right	N	1.5	6	20/08/2009	27/01/2010	160	0.009
9	86	F	Right	SAH	7	9	12/06/2009	02/07/2009	20	0.35
10	58	F	Left	Ovarian cancer	56	29	01/06/2009	18/08/2009	78	0.717
11	72	F	Right	SAH	34	420	31/05/2009	29/07/2009	59	0.576
12	47	F	Bilat.	N	33	18	29/05/2009	22/07/2009	74	0.445
13	40	M	Right	DVT	7	48	20/04/2009	20/05/2009	30	0.233
14	62	M	Bilat.	N	15	120	29/03/2009	15/04/2009	17	0.882
15	38	M	Right	SAH, DVT	0.5	30	19/03/2009	21/05/2009	33	0.015
16	61	F	Right	Pott	180	60	16/03/2009	Not healed		
17	72	F	Right	SAH	12	12	02/03/2009	06/09/2009	137	0.087
18	69	M	Right	Barrett	204	17	02/03/2009	Not healed		
19	68	F	Right	N	4	34	22/02/2009	11/03/2009	17	0.235
20	54	M	Right	Diabetes	70	60	19/02/2009	17/06/2009	126	0.555
21	36	F	Left	N	16	45	16/09/2008	15/10/2008	29	0.551
Mean	58.9				42.19	69			56.6	0.38

N: none. SAH: systemic arterial hypertension. DVT: deep vein thrombosis. Pott: Pott disease. Barrett: Barrett esophagus. Bilat: bilateral.

the saphenous vein during the Valsalva or the compression-release maneuver in the thigh and in the calf, in Group I.

All data were expressed in terms of means and standard deviation from the mean. Fischer's test was used to compare the two groups at the end points: ulcer healing and healing rate. $P < 0.05$ was considered statistically significant.

3. Results

The follow-up ranged from 2 to 17 months. At the time of procedure the area of ulceration ranged from 0.5 to 204 cm^2 (mean: 41.9 cm^2) in group I. In group II the follow-up ranged from 2 to 15 months and the size of ulceration ranged from 2 to 30 cm^2 (mean: 12.71 cm^2).

During follow-up there were eight cases of incomplete healing of the ulcer, four in Group I (19.04%)—in one of them an incompetent Cockett perforating vein was showed and later treated by ultrasound guided sclerotherapy—and four in Group II (40%) $P < 0.05$.

In the Group I ulcer healing occurred in average time of 56.6 days, ranged from 17 to 160 during the follow after the procedure, and the rate of healing was of 19 of 23 limbs (82.6%). None of these patients have had recurrence in the follow up period. In group II ulcer healing occurred in average time of 39 days, ranged from 15 to 89, and the rate of healing was of 6 of 10 limbs. None had recurrence. Mean ulcer healing speed was 0.38 cm/day in group I and 0.13 cm/day in group II $P < 0.05$. There was one patient with clinical evidence of infection on the leg after surgery in the group II (Figure 5).

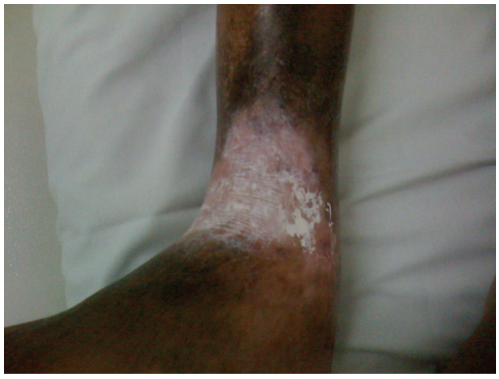

Figure 4: Ulcer healed.

Table 2 summarizes the characteristics and evolution of Group I patients.

Table 3 summarizes the characteristics and evolution of Group II patients.

Table 3: Characteristics and evolution of group II patients.

Patient	Age	Gender	Leg	Comorbidities	Ulcer area	Evolution time (months)	Date of surgery	Date of healing	Days	Rate cm/day
1	61	F	Right	SAH	10	60	26/07/2009	24/11/2009	89	0.112
2	71	M	Right	SAH, CHF	8	60	31/07/2009	30/09/2009	60	0.133
3	52	F	Bilat.		4,5	8	29/11/2009	12/01/2010	14	0.071
4	56	M	Bilat.	DVT	30	36	25/10/2008	Not healed		
5	69	F	Left	SAH	15	24	11/02/2009	Not healed		
6	52	F	Left	DVT	4	36	31/01/2010	17/02/2010	17	0.235
7	43	F	Left		2	12	12/06/2009	27/06/2009	15	0.133
8	64	F	Left	DVT	20	6	20/08/2009	Not healed		
Mean	58.5				12.714	30.25			39	0.136

N: none. SAH: systemic arterial hypertension. DVT: deep vein thrombosis. Pott: Pott disease. Barrett: Barrett esophagus. Bilat: Bilateral.

Figure 5: Skin infection after surgery.

4. Discussion

Venous ulcer is the latest state of venous disease with high social and healthcare cost and with deterioration of quality of life [6, 7]. Several approaches to heal them have been made with high recurrence rate due to the hemodynamic problem that is beneath it, deriving the focus of therapy to the surgical options [8, 9], and now with minimally invasive concepts [10, 11]. Foam sclerotherapy was reintroduced in 1990 for the treatment of venous disorders and it has shown to be an important alternative in the management of patients with venous ulcers, as reported, Garrido et al. [12].

Our goal is the development of a definitive treatment, with minimal chances of complications and recurrences and a low cost. This technique must eradicate the reflux from the main incompetent vein just in its origin and along the incompetent saphenous trunk and its main incompetent tributaries, it must be minimally invasive, with proven effectiveness not affected by the vein size or tortuosity, and finally it must have wide availability and low cost.

Sclerotherapy is widely used as a cosmetic practice to treat spider veins to treat venous malformations [13]. More recently, with the development of the foam it gained more indications as to treat the great superficial trunks. Tessari's technic made more affordable the use of foam in venous practice, so we are now able to convert a tensoactive agent into foam, giving it longer time of contact with the venous endothelium and therefore producing a more effective vein fibrosis with relative independence of the vein size or shape and their flow speed [14].

Foam has the extra advantages of being visible under ultrasound, painless, easy to handle, and is not expensive. The rate of occlusion of veins with this technique is very high [15] and is accepted as a reliable option to occlude main trunks in chronic venous insufficiency settings [16]. Furthermore, with the filling of the main tributaries of the saphenous vein with foam and a good compression, varicose veins resection was not needed. That was why we infused 24 cc of foam in the saphenous vein and its main tributaries in each leg.

Stability of the foam is an issue and it depends on the tensoactive properties of the product and Polidocanol is a detergent with good foam stability.

Under a CEAP 6 patient, as we have shown in this study, CAFE of the great saphenous vein in this group of patients made it possible to reach the healing of more than 80% of the ulcers without complications and faster than in the stripping of the saphenous vein group.

References

[1] O. Nelzén, "Leg ulcers: economic aspects," *Phlebology*, vol. 15, no. 3-4, pp. 110–114, 2000.

[2] W. Marston, "Evaluation and treatment of leg ulcers associated with chronic venous insufficiency," *Clinics in Plastic Surgery*, vol. 34, no. 4, pp. 717–730, 2007.

[3] J. Bergan, L. Pascarella, and L. Mekenas, "Venous disorders: treatment with sclerosant foam," *Journal of Cardiovascular Surgery*, vol. 47, no. 1, pp. 9–18, 2006.

[4] J. H. Ulloa jr, "Oclussion rate with foam schlerotherapy for the treatment of the great saphenous vein incompetence: a multicentric study of 3170 cases," *Journal of Vascular Surgery*, vol. 55, no. 1, 297 pages, 2012.

[5] L. Tessari, "Nouvelle technique d'obtention de la scléro-mousse," *Phlebologie*, vol. 53, pp. 129–133, 2000.

[6] M. A. Fonder, G. S. Lazarus, D. A. Cowan, B. Aronson-Cook, A. R. Kohli, and A. J. Mamelak, "Treating the chronic wound: a practical approach to the care of nonhealing wounds and

wound care dressings," *Journal of the American Academy of Dermatology*, vol. 58, no. 2, pp. 185–206, 2008.

[7] I. C. Valencia, A. Falabella, R. S. Kirsner, and W. H. Eaglstein, "Chronic venous insufficiency and venous leg ulceration," *Journal of the American Academy of Dermatology*, vol. 44, no. 3, pp. 401–424, 2001.

[8] M. Kalra and P. Gloviczki, "Surgical treatment of venous ulcers: role of subfascial endoscopic perforator vein ligation," *Surgical Clinics of North America*, vol. 83, no. 3, pp. 671–705, 2003.

[9] R. L. Kistner, "Etiology and treatment of varicose ulcer of the leg," *Journal of the American College of Surgeons*, vol. 200, no. 5, pp. 646–647, 2005.

[10] S. M. Elias and K. L. Frasier, "Minimally invasive vein surgery: its role in the treatment of venous stasis ulceration," *American Journal of Surgery*, vol. 188, no. 1, supplement 126, pp. 30–124, 2004.

[11] S. Raju and L. L. Villavicencio, *Surgical Management of Venous Diseases*, Williams and Wilkins, Philadelphia, Pa, USA, 1997.

[12] J. R. C. Garrido, J. R. C. Garcia-Olmedo, and M. A. G.-O. Dominguez, "Elargissement des limites de la scléro thérapie: nouveaux produits sclérosants," *Phlébologie*, vol. 50, no. 2, pp. 181–188, 1997.

[13] M. H. Meissner, P. Gloviczki, J. Bergan et al., "Primary chronic venous disorders," *Journal of Vascular Surgery*, vol. 46, no. 6, supplement S, pp. S54–S67, 2007.

[14] L. Tessari, A. Cavezzi, and A. Frullini, "Preliminary experience with a new sclerosing foam in the treatment of varicose veins," *Dermatologic Surgery*, vol. 27, no. 1, pp. 58–60, 2001.

[15] K. D. Gibson, B. L. Ferris, and D. Pepper, "Foam sclerotherapy for the treatment of superficial venous insufficiency," *Surgical Clinics of North America*, vol. 87, no. 5, pp. 1285–1295, 2007.

[16] J. Bergan and V. Cheng, "Foam sclerotherapy for the treatment of varicose veins," *Vascular*, vol. 15, no. 5, pp. 269–272, 2007.