Hindawi Publishing Corporation
ISRN Plastic Surgery
Volume 2013, Article ID 756439, 5 pages
http://dx.doi.org/10.5402/2013/756439

Clinical Study

An Audit of Surgical Management of Pressure Sores in a Resource Constrained Hospital in Kenya

W. F. Nangole,[1] S. O. Khainga,[1] Soren Otieno,[2] and Audi Tanga[2]

[1] *Division of Plastic Surgery, Department of Surgery, University of Nairobi, P.O. Box 19676-00202, Nairobi, Kenya*
[2] *National Spinal Injury Hospital, P.O. Box 20906-00202, Nairobi, Kenya*

Correspondence should be addressed to W. F. Nangole; nangole2212@yahoo.com

Received 28 April 2013; Accepted 30 May 2013

Academic Editors: H. Mizuno, İ. Özyazgan, and E. Raposio

Objective. To determine the surgical management of pressure sores at the National Spinal Injury Hospital and the outcome. *Design*. This was a four-year prospective study from June 2008 to June 2012. *Setting*. The study was carried out at the National Spinal Injury Hospital, Nairobi, Kenya. *Subjects*. Patients with pressure sores operated on during the defined period of study. *Results*. A total of 46 patients with 58 pressure sores were operated on during the defined period of study. The male : female ratio was 10.5 : 1. The mean age was 36.5 years. Trochanteric sores accounted for 60 percent of the pressure sores operated on with the V-Y tensor fascia lata, the commonest surgical procedure, accounting for 37 percent of the procedures performed. At one year of followup 90 percent of the surgeries done were successful with no ulcer recurrence noted. *Conclusion*. Surgical management of pressure sores even in resource constrained environment would result in faster rehabilitation and early patient discharge. The recurrence of the pressure sores could be greatly reduced by involving patients relatives in the rehabilitation and home-based care.

1. Introduction

Pressure sores area is a common problem that spreads across the entire medical field. Prevention is the best way to manage pressure sores. Various pressure dispersion methods are now in use to try and mitigate pressure sores from forming.

However, once pressure sores are formed, then one must institute proper wound care management. Many products are now available in the market to assist in pressure ulcer management with each being claimed to provide better results. This is, however, rarely available in many facilities in developing countries like ours.

Surgery still remains the cornerstone in the management of the Grades 3 and 4 pressure sores [1].

Majority of the sores seem to concentrate on the pelvic girdle pressure points.

Patients with spinal injury are prone to pressure sores formation. One of the biggest challenges in such patients is the recurrence of the pressure sores. To prevent recurrence the use of ripple mattress and home-based nursing care is encouraged. However, in many resource constrained countries the cost of ripple mattresses is way beyond the means of many families. No outreach programs exist to provide home-based care.

Many surgical procedures have been described to assist in the closure of the pressure sores. The flaps commonly used are either local or regional flaps that could broadly be classified as either myocutaneous or fasciocutaneous. Most of these flaps are pedicle or axial flaps and rarely random flaps.

Among the factors that would influence which flap one could use would include the site and size of the ulcer, any previous surgeries, and the surgeons' experience.

Different authors have reported different success rates as far as closure of the ulcers is concerned [2, 3].

Not many studies have been done in Sub-Saharan Africa to determine the success rates of the surgical management of pressure sores, in an environment with very poor community support programs and no pressure dispersion methods.

In this study we followed up the patients who were managed surgically for a mean duration of one year at the National Spinal Injury Hospital, a hospital based in Nairobi, Kenya.

2. Materials and Methods

This was prospective study carried out at the National Spinal Injury Hospital.

Subjects were patients with pressure sores that were managed surgically during the defined study period between June 2008 and June 2012.

Data on patients' demography was taken. Thorough physical examination was then undertaken on the patients with special emphasis on the type and size of the ulcer. All the ulcers were then managed by various types of wound-dressing methods until they were assessed clinically and found to be ready for closure. Prior to this, pus swabs and bone radiographs were taken to ensure that there was no infection.

Before surgery all patients had haemogram, serum albumin, urea and electrolytes done. Only patients with normal levels were subjected to surgery.

Prophylactic antibiotic was given prior to surgery. Either general anesthesia or sedation was used depending on the level of spinal cord injury.

The surgical procedure performed was influenced by factors such as the type of the defect, the size of the wounds, any previous surgeries done, and the operating surgeons experience or preference.

Methylene blue was routinely used to mark the ulcer cavity. Lidocaine with adrenaline solution 1 : 200000 was infiltrated around the wound and the incision markings so as to reduce the bleeding.

All wounds had drains inserted during surgery and were only removed once they were inactive. Postoperatively the flaps were inspected on the first postoperative day and subsequently daily to rule out any haematoma formation or sepsis. Change of dressing was done on the third postoperative day. Sutures where indicated were removed on the tenth to fourteenth postoperative day.

Upon recovery the patients were discharged home and followed up in the outpatient department. First visit was after one month and thereafter after every three months till one year of followup. Patients relatives were taught how to turn the patient every two hours and to assist in basic hygiene such as removal of soiled diapers. Sheepskin and gloves with water were improvised for pressure dispersion. In a few cases the patients' progress was monitored through telephone interviews with the patients or the relatives.

3. Results

A total of 46 patients with 58 pressure sores were followed up during the study period of four years. The male : female ratio was 10.5 : 1. The age range for the patients was 19 years to 63 years of age. The mean age was 36.5 years. Paraplegia accounted for 73 percent of the patients operated on with quadriplegia 27 percent.

Tronchanteric sores accounted for 60 percent of the ulcers operated on with sacral 34 percent and ischial 6 percent (Tables 1, 2, and 3).

Thirty-seven patients with 47 flaps repaired were reviewed one year after surgery. (One patient died before one year of followup, and 8 patients were lost on followup.) Of the 47 flaps reviewed at one year postsurgery, 89 percent had completely healed with no signs of ulcer recurrence noted. Two ulcers had recurred within the one year of followup, while two of the other ulcers had shown partial wound dehiscence.

Table 1: The types of operations done for the various ulcers.

Diagnosis	Operation done	Frequency	Percentage
Sacral pressure sore	V-Y gluteal fasciocutaneous flap	8	13.5
	V-Y gluteal myocutaneous flap	4	7
	Transverse lumbar fasciocutaneous flap	8	13.5
Trochanteric pressure sores	V-Y tensor fascia lata flap	29	50
	Inferior gluteal rotational myocutaneous flap	4	7
	direct closure	2	3
Ischial pressure sore	V-Y hamstring flap	1	2
	Gracilis myocutaneous flap	2	4
Total		58	100

Table 2: Outcome of surgery at 1 month of follow up.

Procedure done	Full take	Partial take	Failed	Total
V-Y gluteal myocutaneous flap	4	0	0	4
V-Y tensor fascia lata flap	27	2	0	29
V-Y gluteal fasciocutaneous flap	8	0	0	8
Transverse lumbar flap	8	0	0	8
Inferior gluteal myocutaneous flap	4	0	0	4
V-Y hamstring flap	1	0	0	1
Gracilis myocutaneous flap	2			2
Delayed primary closure	0	0	2	2
Total	54	2	2	58
Percentage	93	3.5	3.5	100

4. Discussion

Surgical management of pressure is probably the best option for management of advanced pressure sores in resource constrained environment. While conservative management of advanced pressure sore has been shown to be effective with the use of modern wound dressing materials such as VAC dressings, these materials are way beyond the reach of many patients in such environment. Most dressings employed are usually the traditional dressing materials which in many

Table 3: Outcome of surgery at one year of followup.

Procedure done	Full take	Partial dehiscence	Recurrence	Total
V-Y gluteal myocutaneous flap	4	0	0	4
V-Y tensor fascia lata flap	21	2	0	23
V-Y gluteal fasciocutaneous flap	6	0	0	6
Transverse lumbar flap	6	0	0	6
Inferior gluteal rotational myocutaneous flap	3	1	0	4
Delayed primary closure	0	0	1	1
V-Y hamstring flap	0	0	1	1
Gracilis myocutaneous flap	2	0	0	2
Total	42	3	2	47
Percentage	89.4	6.4	4.2	100

instances would result in prolonged hospital stays with long durations before the wounds heal [3].

On the other hand surgery ensures quick closure of the wounds enabling faster rehabilitation and hence prompts discharge of the patients. The biggest disadvantage of surgery in our environment, however, is the lack of adequate skilled resources in terms of trained plastic surgeons.

The mean age for the patients in this study was 36.5 years. This is a relatively young age group as compared to many other studies [4, 5]. However, ulcers in patients with spinal injury tend to occur in a younger age group as compared to other medical conditions.

The male : female ratio was 10.5 : 1 Many studies have consistently found pressure sores to be a predominant of the male patients [4–6].

Tronchanteric sores in this study were the commonest sores encountered and also operated on. While the pelvic girdle pressure points in many studies account for the majority of the ulcers, the distribution between the various sites is not constant [4–6].

Operatively, the principles of pressure ulcers surgery entails complete excision of the ulcer with all necrotic tissues. Painting the wound with methylene blue as done in this study assists one to visualize the ulcer base. All the bony pressure points should also be excised [1–3]. The wound should then be covered by a flap. The choice of the flap depends on many factors including the size, location of the ulcer, any previous surgeries, and the surgeons preference. The flap must be adequately mobilized and should be closed without tension. It should also obliterate the dead space as much as possible.

Drains should be inserted to prevent haematoma formation.

Primary closure of the wound usually results in tension and eventually fails [1]. In this series we had two patients whose wounds we closed primarily. Both wounds dehisced, and a repeat procedure had to be done.

The tensor fascia lata flap was the commonest surgical procedure done in this series. This was the flap of choice for the tronchanteric pressure sores. While many options are still available for the closure of the tronchanteric pressure sores, many authors favour the V-Y tensor fascia lata as the procedure of choice [2, 7–10]. It is a relatively easy flap to raise and can be advanced a lot once its pedicle has been localized. It is also a reliable flap with good outcome [2, 7, 8]. In our series we had partial necrosis of one of the tensor fascia lata flap. In this particular case the main problem was haematoma formation secondary to blocked drains. Sepsis resulted in partial loss of the other tensor fascia lata flap.

The sacral pressure sores in this study contributed to 34 percent of the ulcers operated on. Many series have shown sacral sores to be the commonest pressure sore [3–5]. Majority of these sores were closed with either the V-Y gluteal fasciocutaneous or myocutaneous flaps. The other operation employed was the transverse lumbar fasciocutaneous flap. All the three types of procedures done had a good outcome with all the flaps successfully. The gluteal fasciocutaneous flaps were employed in cases where the sores were relatively small and hence could be closed without much advancement of the tissues (see the Appendix (Figures 1–4)). In the cases where the ulcers were deep and very wide and hence a lot of advancement required, our tendency was to use the pedicle V-Y gluteal myofasciocutaneous flaps. Fischer et al. also advocated the use of this flap in wide sacral defects [11]. The flap was either based on the superior or inferior gluteus vessels. The transverse lumbar rotational flap was our flap of choice in cases where the gluteus flaps could not be used. The transverse lumbar flaps have also been widely used in the literature [12, 13]. The main drawback with the transverse lumbar flap is the donor defect that in our series had to be closed with a skin graft. In a few cases the graft take was poor resulting in wounds that had to be dressed for a while before healing occurred. The advantage of the transverse lumbar flap, however, includes ease raising of the flap.

Only three patients presented with the ischial pressure sore. In one patient we did a V-Y hamstring advancement flap. The flap was initially successful but had recurrence at about six months of followup. Among the advantages of the V-Y hamstrings flap is the possibility of repetitive use of the flap as a readvancement in the event the ulcer recurs [14, 15]. The gracilis myocutaneous flap was utilized in the other cases.

Our overall success rate at one year of followup was about 90 percent. Many authors have reported different success rates [1–3, 16]. The overall long term success is obviously influenced by many other nonsurgical factors such as physiotherapy, nutritional support, pressure dispersion methods, and patient support mechanisms both at home

Figure 1: Sacral pressure sore.

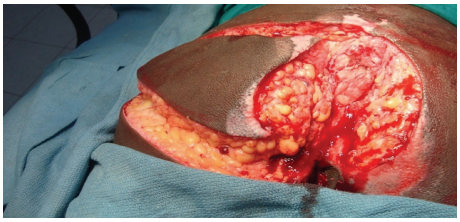

Figure 2: V-Y gluteal fasciocutaneous flap raised.

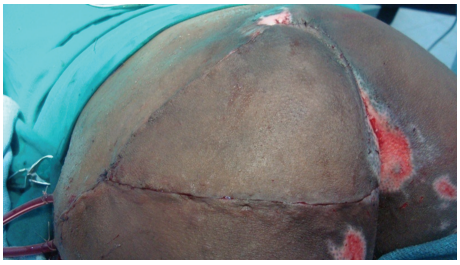

Figure 3: V-Y gluteal fasciocutaneous flap sutured into the defect.

Figure 4: V-Y gluteal flap, at 4 months of followup.

Figure 5: Patient with large left trochanteric pressure sore.

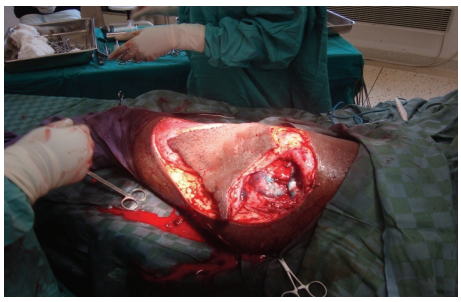

Figure 6: V-Y tensor fascia lata flap raised.

Figure 7: V-Y tensor fascia lata flap advanced into the wound.

and in hospital. We do not have any community outreach program in our centre for the spinal injured patient. Majority of our patients also cannot afford ripple mattresses or any other pressure dispersion mechanisms. The patient support while back at home is thus solely performed by the relatives of the patient. We do, however, support them at the hospital by teaching them on how to do regular turning of the patients and ensuring proper patient hygiene. Other unconventional pressure dispersion methods such as sheepskin and gloves with water are taught to the relatives.

In conclusion, surgical management of pressure sores in the spinal injured patients even in resource constrained environment would result in excellent surgical outcomes. Good preoperative management compounded with good surgical practice will ensure good surgical outcome. In an environment with very minimal community outreach and patient support services, the relatives must be fully involved in the postoperative care of the patients including frequent turning of the patient and ensuring good personal hygiene. Readily available materials such as sheepskin could be used for pressure dispersions since ripple mattresses are not affordable in the majority of the cases.

Appendix

See Figures 1, 2, 3, 4, 5, 6, and 7.

References

[1] H. . Conway and B. H. Griffith, "Plastic surgery for closure of decubitus ulcers in patients with paraplegia; based on experience with 1,000 cases," *American Journal of Surgery*, vol. 91, no. 6, pp. 946–975, 1956.

[2] B. C. Jiburum, J. U. Achebe, and F. C. Akpuaka, "Early results of operative closure of pressure sores in traumatic paraplegics," *International Surgery*, vol. 80, no. 2, pp. 178–180, 1995.

[3] W. Nangole and S. O. Khainga, "Pressure ulcers presentations and management at Kenyatta National Hospital and Spinal Injury Hospital," *The East African Medical Journal*, vol. 86, no. 12, 2009.

[4] M. Lepistö, E. Eriksson, H. Hietanen, and S. Asko-Seljavaara, "Patients with pressure ulcers in Finnish hospitals," *International journal of nursing practice*, vol. 7, no. 4, pp. 280–287, 2001.

[5] E. Jaul, "Pressure sores unit—a one year study," *Harefuah*, vol. 140, no. 10, pp. 903–991, 2001.

[6] A. Thoroddseu, "Pressure sore prevalence: a national survey," *Journal of Clinical Nursing*, vol. 8, no. 2, pp. 170–179, 1999.

[7] A. . Siddiqui, T. Wiedrich, and V. L. Lewis Jr., "Tensor fascia lata V-Y retroposition myocutaneous flap: clinical experience," *Annals of Plastic Surgery*, vol. 31, no. 4, pp. 313–317, 1993.

[8] C. E. Paletta, B. Freedman, and S. J. Shehadi, "The V-Y tensor fascia latae musculocutaneous flap," *Plastic and Reconstructive Surgery*, vol. 83, pp. 852–857, 1989.

[9] F. Nahai, H. L. Hill, and T. R. Hester, "Experiences with the tensor fascia lata flap," *Plastic and Reconstructive Surgery*, vol. 63, no. 6, pp. 788–799, 1979.

[10] J. C. McGregor and A. C. Buchan, "Our clinical experience with the tensor fasciae latae myocutaneous flap," *British Journal of Plastic Surgery*, vol. 33, no. 2, pp. 270–276, 1980.

[11] J. Fisher, P. G. Arnold, J. Waldorf, and J. E. Woods, "The gluteus maximus musculocutaneous V-Y advancement flap for large sacral defects," *Annals of Plastic Surgery*, vol. 11, no. 6, pp. 517–522, 1983.

[12] H. L. Hill, R. G. Brown, and M. J. Jurkiewicz, "The transverse lumbosacral back flap," *Plastic and Reconstructive Surgery*, vol. 62, no. 2, pp. 177–184, 1978.

[13] S. S. Kroll and L. Rosenfield, "Perforator-based flaps for low posterior midline defects," *Plastic and Reconstructive Surgery*, vol. 81, no. 4, pp. 561–566, 1988.

[14] J. E. Hurteau, J. Bostwick, F. Nahai, R. Hester, and M. J. Jurkiewicz, "V-Y advancement of hamstring musculocutaneous flap for coverage of ischial pressure sores," *Plastic and Reconstructive Surgery*, vol. 68, no. 4, pp. 539–542, 1981.

[15] S. S. Kroll and S. Hamilton, "Multiple and repetitive uses of the extended hamstring V-Y myocutaneous flap," *Plastic and Reconstructive Surgery*, vol. 84, no. 2, pp. 296–302, 1989.

[16] R. D. Foster, J. P. Anthony, S. J. Mathes, W. Y. Hoffman, D. Young, and I. Eshima, "Flap selection as a determinant of success in pressure sore coverage," *Archives of Surgery*, vol. 132, no. 8, pp. 868–873, 1997.