Hindawi Publishing Corporation
Advances in Vascular Medicine
Volume 2014, Article ID 432820, 6 pages
http://dx.doi.org/10.1155/2014/432820

Review Article

IVC Filters: Challenges and Future Directions

Misaki M. Kiguchi and Ellen D. Dillavou

University of Pittsburgh Medical Center, Pittsburgh, PA 15213, USA

Correspondence should be addressed to Ellen D. Dillavou; dilled@upmc.edu

Received 8 May 2014; Accepted 14 September 2014; Published 23 November 2014

Academic Editor: Arnon Blum

Since their introduction in 1973, inferior vena cava filters have evolved concurrent with advancing technology, and, therefore, their use has expanded due to broader indications for insertion. This paper focuses on the challenges and future directions of this trend, including a closer look at complications, retrieval rates, and cost-effectiveness.

1. Introduction

Venous thromboembolism events (VTE), which include deep vein thrombosis (DVT) and pulmonary embolism (PE), are a common problem, affecting an estimated 422/100,000 people in the United States [1]. Anticoagulation is the current standard of treatment in the management of DVT and PE [2, 3]. In patients with DVT who have a contraindication to or proven failure of anticoagulation, IVC filter placement as a mode of PE prevention is well supported by Level 1 evidence and recent consensus guidelines [4–6]. There are widely accepted indications for IVC filter placement as shown in the following.

Indications for Inferior Vena Cava Filters

(i) Absolute indications:

(a) inability to anticoagulate with documented PE, IVC, iliac, femoral, or popliteal DVT;
(b) recurrent PE on therapeutic anticoagulation;
(c) bleeding complications on anticoagulation for PE/DVT.

(ii) Relative indications:

(a) free floating IVC/Iliac thrombus;
(b) septic pulmonary embolism;
(c) extension of DVT on adequate anticoagulation;
(d) high risk for complications from anticoagulation for DVT/PE;
(e) massive PE or large DVT with limited reserve for further insult;
(f) recurrent PE with IVC filter;
(g) recent DVT undergoing major surgery or thrombolysis;
(h) pregnancy with proximal DVT.

See [4–6].

However, over the last decade, the ease of use and retrievability of modern IVC filters have had the effect of lowering the threshold for device insertion in many clinical settings, rapidly expanding relative and prophylactic indications. Because of this trend, a closer look at complications, retrieval rates, and cost-effectiveness of IVC filter placement has been the focus of the University of Pittsburgh Medical Center Vascular Division. As one of the largest divisions in the country, it is positioned to address the challenges created by the increased IVC filter placement and to provide guidelines to address them. The following chapter will address some of the pressing clinical issues in IVC filter use and will highlight the work done at the University of Pittsburgh Medical Center.

2. Complications of IVC Filter Placement

Perioperative complications rates are low with IVC filter placement, consisting mainly of insertion site DVT and rarely

Table 1: IVC filter complications.

Perioperative complications	
Improper placement	1.3%
Pneumothorax	0.02%
Hematoma	0.6%
Air embolism	0.2%
Arterial puncture	0.04%
Arteriovenous fistula	0.02%
Insertion site thrombosis	0.4–1.8%
Late complications	
IVC thrombosis	2–9.5%
IVC penetration	4.4%
Migration	1–18%
Filter embolization	2–5%
Filter fracture	2–10%
Recurrent PE	1.3%
Recurrent DVT	6–36%
Mortality	0.12%

References: [16–20].

bleeding or vascular injury. However, increasing attention is being paid to long-term complications as filter placement has only now recently become commonplace since its first introduction in 1967 (Table 1). Insertion site thrombosis/DVT occurs most frequently of complications and is more common with higher profile delivery systems [7]. Caval thrombosis occurs in 1–10% of patients, and if symptomatic, catheter-directed thrombolysis and adjunctive mechanical thrombectomy can be used [8]. Case reports detail many IVC filter complications, including successful pharmacomechanical thrombolysis in a patient requiring hemodialysis secondary to filter migration with iliocaval and renal vein thrombosis [9]. Although this is a rare complication, this case report highlights successful prompt thrombus debulking to preserve renal function in a perioperative patient at high risk for bleeding.

Filter fracture, embolization from IVC filter thrombi, and migrations have also been reported. Fracture may decrease IVC filter efficacy with its structural change [10]. Embolization from IVC filter thrombi has been managed with anticoagulation, but more often, a second IVC filter is placed about the original IVC filter [11]. Migrations can occur if a standard 28 mm filter is placed in an IVC of more than 28 mm or during line exchanges. All filters that migrate above the renal veins should be retrieved. Although endovascular methods have successfully recovered migrated filters, immediate surgical extraction is necessary if percutaneous retrieval is difficult or dangerous [12]. Reports of migration into the heart are not uncommon and surgical and endovascular attempts at retrieval are well reported [13–15].

With increasing use of IVC filters and diagnostic abdominal CT scans, imaging often reports asymptomatic extraluminal IVC filter penetration with alarming frequency (Figures 1(a) and 1(b)) [16, 21–23]. Although symptomatic filter penetration occurs at a much lower rate, penetration into the aorta, duodenum, or the ureters has been reported. Our institution retrospectively reviewed patients with GI complications associated with IVC filters from 2008 to 2012. Eight patients had symptomatic IVC filter related GI complications, ranging from abdominal pain, to nausea/vomiting, to fever, and to bacteremia [24]. True penetration is difficult to assess on CT scans, and, thus, asymptomatic penetration can generally be left alone. Symptoms, however, necessitate removal and repair of adjacent injured structures. Out of the eight patients reviewed at our institution for GI complications, one patient had superior mesenteric venous penetration and thrombosis treated with hydration and anticoagulation; of the seven duodenal perforations, two patients underwent successful laparotomy. Five patients had attempted endovascular retrieval. Four were successful. One patient with successful endovascular retrieval had transient sepsis treated with antibiotics. Although a relatively rare complication of IVC filter placement, removal of filter after symptomatic penetration can be safely performed either surgically or by endovascular maneuvers. Even with strut penetration through the caval wall into the surrounding viscera, endovascular retrieval is thought to be feasible and safe. Consideration of such attempts should include concurrent arterial access for control of any bleeding from aortic penetration and the use of perioperative antibiotics to prevent bacteremia from translocation of GI flora [25–28].

3. Retrieval Rates

In patients with a documented DVT/PE, a retrievable IVC filter should be removed when a therapeutic dose of anticoagulation has been reached and the patient has been found to tolerate this. This can be done without cessation of anticoagulation. Alternatively, prophylactic IVC filters in patients should be removed whenever the significant risk factors for DVT/PE resolve or patients can safely receive prophylactic anticoagulation. Difficult and challenging retrievals have been predicted by longer dwell times [29].

Theoretically, the long-term complications from IVC filters should be mitigated by the introduction of retrievable filters but have not been seen. Retrieval rates for IVC filters have been generally low. A single-center study reviewed plans for IVC filter retrievals after placement between 2001 and 2006. Only 30.4% of patients had documented plans for retrievals. Of those without plans, 21.6% did not have contraindications to removal. History of malignancy and intolerance to anticoagulation predicted lower retrieval rates [30].

A landmark paper from UPMC Pittsburgh demonstrated that a specific institutional protocol monitoring insertion and removal of IVC filters significantly increased filter retrieval rates, especially in the trauma population, a patient population that traditionally lacks routine follow-up [31]. Review of the institutional trauma registry identified consecutive patients receiving retrievable IVC filters between January 2004 and February 2007 prior to initiation of the specific retrieval protocol. A group of consecutive trauma patients receiving retrievable IVC filters from August 2007 to July 2008 after initiation of the specific retrieval protocol were then prospectively followed. Of those eligible for retrieval, retrieval attempts were made in only 42% of those patients with IVC filters placed prior to the protocol versus 95%

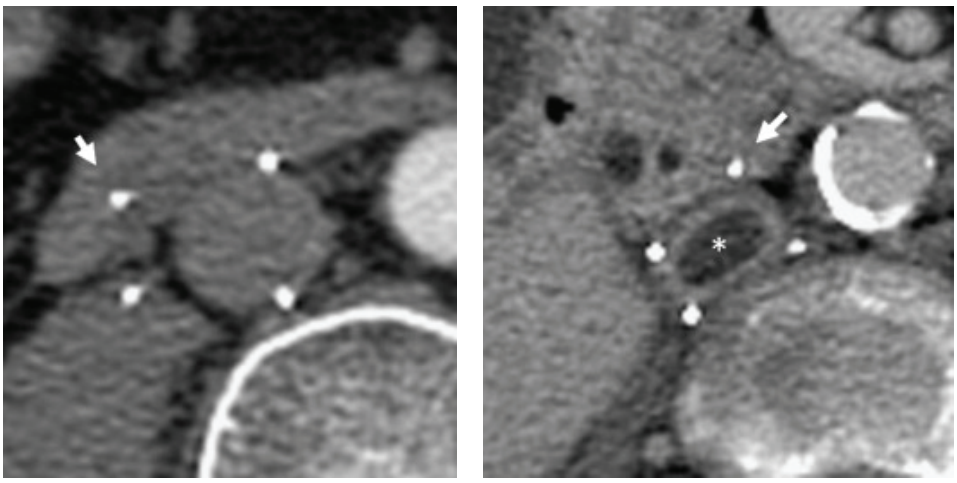

(a) (b)

Figure 1: (a) and (b) CT scan images of extraluminal penetration of IVC filter struts into duodenum. Reproduced with permission from Elsevier reference number 500862427.

of those patients with IVC filters placed after the protocol ($P < .001$). Multiple reasons account for a low retrieval rate but the primary factor included clinical oversight. This is not surprising owing to the diverse range of specialties requesting IVC filter placement and placing them [31]. After the recommendation came out of the University of Pittsburgh study and its successful results guided the implementation of institute specific retrieval protocols, retrieval rates have significantly increased with the establishment of dedicated filter clinics. Our own institution recently reviewed retrievals of IVC filters placed by vascular surgery between 2004 and 2009. The majority (67%) of the 401 patients received a prophylactic IVC filter with an overall retrieval rate of 59.1% [29], higher than the reported literature range of 20–50% [32–36]. One hundred forty-two out of the 401 consecutive retrievable IVC filters placed in the study period had no attempted retrieval. The most common reason for nonretrieval was physician oversight [29]. We have found that for most success in filter retrieval the proceduralist service, whether vascular surgery or interventional radiology, should be responsible for patient management and arranging retrieval [31, 37].

Although most nonretrievals are due to inattention to patient management or patient noncompliance, difficult retrievals may further decrease enthusiasm for improving retrieval rates. Troubleshooting difficult retrievals have become the topic of many case reports. We have examined patient-related and device-specific predictors of challenging and failed retrievals. During this study period, four hundred and one patients underwent IVC filter placement. Approximately two-thirds were for prophylactic indications. Overall retrieval rate was 59.1% with 237 successful retrievals out of 259 attempts. Failed retrievals were significantly predicted by prolonged dwell time, therapeutic indication, and filter wall apposition. Challenging retrievals were defined when adjunctive endovascular maneuvers were necessary to attempt retrieval. Thirty-eight (15.3%) out of 248 nonaborted retrievals were defined as challenging and predicted by increased dwell time, filter tilt, and filter wall apposition.

The tilt of the filter often prevents successful snaring of the hook, as it embeds into the caval wall or leans into the renal vein [38, 39]. Large caliber balloons can be utilized from the femoral approach, inflated above the filter, and pulled against the IVC filter to correct its tilt. The balloon can also be wedged between the filter and IVC caval wall to push the hook towards the caval center for better exposure [40].

A second snare from the femoral vein can be used to delicately grasp a filter leg, tilting the hook away from the wall. Endobronchial forceps have been used to grasp and maneuver the IVC filter directly under direct fluoroscopic guidance [41]. A Glidewire (Terumo, Somerset, NJ) or pigtail catheter has been often used as a retraction loop snare through the filter apex to straighten a tilt [42]. "Flossing" of the filter with a wire from the femoral vein captured by the jugular snare can assist in restraightening but involves dual access from both the femoral and jugular veins [43–45]. Increased dwell time predicts more tissue ingrowth into the cava and the use of endovascular laser sheath as a thermal dissection device has been described [46]. Although filter tilt renders retrieval difficult, with the introduction of other innovative endovascular maneuvers, it does not predict retrieval failure [29].

Troubleshooting filter retrievals should be approached with caution. Administration of heparin is recommended with difficult retrievals as clot typically builds up around wires. Fracture or entanglement of snares/wires within the IVC filter struts is not uncommon and attempts should not be at the expense of necessitating open IVC foreign body retrieval or patient injury.

4. Cost-Effectiveness of Retrievable IVC Filters

No current Level 1 evidence exists suggesting prophylactic IVC filters in the trauma population are superior to prophylactic doses of anticoagulation. In addition, no evidence exists to recommend a specific duration of time during

which IVC filters should be placed in patients who cannot be anticoagulated and provide maximal therapeutic benefit. The Eastern Association of Trauma (EAST) and American College of Chest Physicians (ACCP) have contributed to wide variations in practice patterns due to conflicting guidelines [3, 47]. Although current data only supports IVC filter use in patients with known thromboembolism with a contraindication to therapeutic anticoagulation or those who cannot be prophylactically anticoagulated more than 72 hours after injury, clinical decisions vary and remain individualized in the absence of Level 1 evidence.

In the context of conflicting societal recommendations and the low but not negligible morbidity associated with IVC filter placement, the cost of the procedure and device contribute to the controversy surrounding prophylactic filter use. Our institution contributed the first of its kind cost analysis and Markov modeling of IVC filter use in high-risk trauma patients. The study demonstrated that the minimal effectiveness of prophylactic IVC filtration to prevent PE in this population was estimated to cost over $380,000 per gained quality of life year. Both the clinical and economic implications of this study should not be underestimated. In both the initial hospitalization and long-term healthcare costs, prophylactic IVC filtration was not a cost-effective intervention [48]. These results are theoretic and limited by the assumptions used in the Markov model but were the first to highlight cost-effectiveness as a potential contributing factor in resolving the conflict between different societal practice guidelines. The model is constrained by the thresholds of variables that contribute to the model but plays a significant role in reminding all clinicians that not only the probabilities of complications and effectiveness from placing or not placing the IVC filter should affect decision-making but also societal cost should play a role in clinical practice.

5. Future Directions

Once the clinical decision has been made to insert an IVC filter, clinicians must decide on a particular filter model and type. Although the clinical scenario will likely determine the filter type (i.e., permanent versus retrievable) and lessons can be learned from the only randomized controlled trial involving permanent filters [49], no randomized clinic trial between different retrievable filter models has been performed. Despite the evolution of filter designs and updates, no comparative studies to show one retrievable filter superiority over another exist. In addition, although the PREPIC trial showed caval filtration with permanent IVC filters to be effective in preventing pulmonary embolisms, the advent of retrievable filters negates the long-term risks described with permanent filters. To fully evaluate the risks, benefits, and alternations of retrievable IVC filters in specific patient populations, prospective randomized controlled trials are necessary to determine the most appropriate thromboembolic prevention that improve patient survival while minimizing complications. However, due to the small incidence of IVC filter complications and the costs and ethical dilemmas of imaging asymptomatic patients after IVC filter placement, a large randomized trial is impractical. The PRESERVE (predicting the safety and effectiveness of inferior vena cava filters) study will be a multicenter prospective registry, advocated by the Society of Vascular Surgery (SVS) as well as the Society for Interventional Radiology (SIR) as well as seven IVC filter manufacturers. In the absence of a randomized trial, hopefully the PRESERVE study will be able to give clinicians practical guidance on filter choice and real risk for patients.

Retrieval rates, despite the integration of institutional specific protocols, are alarmingly low. The clinical benefits of removal have not been fully elucidated, and thus, strict adherence to following these patients, whether by the proceduralist or a dedicated retrieval team, must be carried out to maximize retrieval rates. In addition, referring clinicians should be educated on the risks, benefits, alternatives, and the need for retrieval, as many are aware of the benefits of caval interruptions but not of the responsibility during and after placement.

As Avgerinos et al. demonstrated challenging retrievals are predicted by factors that imply difficult retrieval due to endothelial proliferation or neointimal incorporation into the caval wall (i.e., increased dwell time, filter tilt, etc.) [29]. The mechanism behind this response is poorly understood but creates an opportunity to modify current temporary IVC filters to more favorable retrieval attempts. Methods to reduce or document the rate of endothelial proliferation will dramatically impact more successful retrieval attempts.

6. Conclusions

The field of caval filtration has rapidly developed by changes to technology and design modification over the past 40 years to include various commercially available permanent and retrievable IVC filters placed percutaneously. The University of Pittsburgh Medical Center, as a large center serving a wide geographic area, has tried to address many of the questions and challenges that arise from their use. Clinical trials will further compare IVC filter advantages/disadvantages, further define indications, explore maximum patient benefit, and outline cost-effectiveness.

Conflict of Interests

The authors declare that there is no conflict of interests regarding the publication of this paper.

References

[1] S. B. Deitelzweig, B. H. Johnson, J. Lin, and K. L. Schulman, "Prevalence of clinical venous thromboembolism in the USA: current trends and future projections," *The American Journal of Hematology*, vol. 86, no. 2, pp. 217–220, 2011.

[2] G. H. Guyatt, E. A. Akl, M. Crowther, H. J. Schünemann, D. D. Gutterman, and S. Z. Lewis, "Introduction to the ninth edition: antithrombotic therapy and prevention of thrombosis, 9th ed: American College of Chest Physicians evidence-based clinical practice guidelines," *Chest*, vol. 141, no. 2, pp. 48S–52S, 2012.

[3] C. Kearon, E. A. Akl, A. J. Comerota et al., "Antithrombotic therapy for VTE disease: antithrombotic therapy and prevention of

thrombosis, 9th ed: American College of Chest Physicians Evidence-Based Clinical Practice Guidelines," *Chest*, vol. 141, supplement 2, pp. e419S–e494S, 2012.

[4] A. S. Baadh, J. F. Zikria, S. Rivoli, R. E. Graham, D. Javit, and J. E. Ansell, "Indications for inferior vena cava filter placement: do physicians comply with guidelines?" *Journal of Vascular and Interventional Radiology*, vol. 23, no. 8, pp. 989–995, 2012.

[5] J. Hirsh, G. Guyatt, G. W. Albers, R. Harrington, and H. J. Schünemann, "Executive summary: American College of Chest Physicians evidence-based clinical practice guidelines (8th edition)," *Chest*, vol. 133, no. 6, supplement 1, pp. 71S–109S, 2008.

[6] J. A. Kaufman, T. B. Kinney, M. B. Streiff et al., "Guidelines for the use of retrievable and convertible vena cava filters: report from the Society of Interventional Radiology multidisciplinary consensus conference," *Journal of Vascular and Interventional Radiology*, vol. 17, no. 3, pp. 449–459, 2006.

[7] J. Blebea, R. Wilson, P. Waybill et al., "Deep venous thrombosis after percutaneous insertion of vena caval filters," *Journal of Vascular Surgery*, vol. 30, no. 5, pp. 821–829, 1999.

[8] B. P. Yan, T. J. Kiernan, V. Gupta, A. E. Ajani, and R. M. Schainfeld, "Combined pharmacomechanical thrombectomy for acute inferior vena cava filter thrombosis," *Cardiovascular Revascularization Medicine*, vol. 9, no. 1, pp. 36–40, 2008.

[9] M. Kiguchi, K.-A. McDonald, S. Govindarajan, M. S. Makaroun, and R. A. Chaer, "Pharmacomechanical thrombolysis for renal salvage after filter migration and renal vein thrombosis," *Journal of Vascular Surgery*, vol. 53, no. 5, pp. 1391–1393, 2011.

[10] M. S. Johnson, "Vena cava filter fracture: unplanned obsolescence," *Journal of Vascular and Interventional Radiology*, vol. 23, no. 2, pp. 196–198, 2012.

[11] W. Nicholson, W. J. Nicholson, P. Tolerico et al., "Prevalence of fracture and fragment embolization of Bard retrievable vena cava filters and clinical implications including cardiac perforation and tamponade," *Archives of Internal Medicine*, vol. 170, no. 20, pp. 1827–1831, 2010.

[12] B. Haddadian, F. Shaikh, M. Djelmami-Hani, and Y. Shalev, "Sudden cardiac death caused by migration of a TrapEase inferior vena cava filter: case report and review of the literature," *Clinical Cardiology*, vol. 31, no. 2, pp. 84–87, 2008.

[13] J. O. F. Roehm Jr., "Bird's nest filter migration to the right atrium," *The American Journal of Roentgenology*, vol. 185, no. 2, pp. 555–556, 2005.

[14] R. Urena and L. Greenwood, "Bird's nest filter migration to the right atrium," *American Journal of Roentgenology*, vol. 183, no. 4, pp. 1037–1039, 2004.

[15] P. Rasuli, R. Mehran, G. French, M. Turek, K. A. Lalonde, and P. Cardinal, "Percutaneous retrieval of a vena cava filter from the right atrium: case report," *Canadian Association of Radiologists Journal*, vol. 51, no. 1, pp. 30–35, 2000.

[16] C. O. Bogue, P. R. John, B. L. Connolly, D. J. Rea, and J. G. Amaral, "Symptomatic caval penetration by a Celect inferior vena cava filter," *Pediatric Radiology*, vol. 39, no. 10, pp. 1110–1113, 2009.

[17] L. F. Angel, V. Tapson, R. E. Galgon, M. I. Restrepo, and J. Kaufman, "Systematic review of the use of retrievable inferior vena cava filters," *Journal of Vascular and Interventional Radiology*, vol. 22, no. 11, pp. 1522.e3–1530.e3, 2011.

[18] C. A. Athanasoulis, J. A. Kaufman, E. F. Halpern, A. C. Waltman, S. C. Geller, and C.-M. Fan, "Inferior vena caval filters: review of a 26-year single-center clinical experience," *Radiology*, vol. 216, no. 1, pp. 54–66, 2000.

[19] C. S. Joels, R. F. Sing, and B. T. Heniford, "Complications of inferior vena cava filters," *The American Surgeon*, vol. 69, no. 8, pp. 654–659, 2003.

[20] C. E. Ray Jr. and J. A. Kaufman, "Complications of inferior vena cava filters," *Abdominal Imaging*, vol. 21, no. 4, pp. 368–374, 1996.

[21] R. J. Feezor, T. S. Huber, M. B. Welborn III, and S. R. Schell, "Duodenal perforation with an inferior vena cava filter: an unusual cause of abdominal pain," *Journal of Vascular Surgery*, vol. 35, no. 5, pp. 1010–1012, 2002.

[22] M. C. Proctor, L. J. Greenfield, K. J. Cho, M. M. Moursi, and E. A. James, "Assessment of apparent vena caval penetration by the Greenfield filter," *Journal of Endovascular Surgery*, vol. 5, no. 3, pp. 251–258, 1998.

[23] M. B. Streiff, "Vena caval filters: a comprehensive review," *Blood*, vol. 95, no. 12, pp. 3669–3677, 2000.

[24] E. A. Genovese, G. Jeyabalan, L. K. Marone, E. D. Avgerinos, M. S. Makaroun, and R. A. Chaer, "Management of symptomatic gastrointestinal complications associated with retrievable inferior vena cava filters," in *Proceedings of the 42nd the Annual Meeting of the Society for Clinical Vascular Surgery (SCVS '13)*, Miami, Fla, USA, March 2013.

[25] E. K. Shang, D. P. Nathan, J. P. Carpenter, R. M. Fairman, and B. M. Jackson, "Delayed complications of inferior vena cava filters: case report and literature review," *Vascular and Endovascular Surgery*, vol. 45, no. 3, pp. 290–294, 2011.

[26] M. Siepe, S. Koeppe, W. Euringer, and C. Schlensak, "Aortocaval fistula from acute rupture of an abdominal aortic aneurysm treated with a hybrid approach," *Journal of Vascular Surgery*, vol. 49, no. 6, pp. 1574–1576, 2009.

[27] P. Sparrow, "Double whammy: inferior vena cava filter-related perforation and thrombosis of the inferior vena cava and aorta," *Circulation*, vol. 123, no. 7, pp. e245–e246, 2011.

[28] M. Veroux, T. Tallarita, M. Pennisi, and P. Veroux, "Late complication from a retrievable inferior vena cava filter with associated caval, aortic, and duodenal perforation: a case report," *Journal of Vascular Surgery*, vol. 48, no. 1, pp. 223–225, 2008.

[29] E. D. Avgerinos, J. Bath, J. Stevens et al., "Technical and patient-related characteristics associated with challenging retrieval of inferior vena cava filters," *European Journal of Vascular and Endovascular Surgery*, vol. 46, no. 3, pp. 353–359, 2013.

[30] J. F. Mission, R. K. Kerlan Jr., J. H. Tan, and M. C. Fang, "Rates and predictors of plans for inferior vena cava filter retrieval in hospitalized patients," *Journal of General Internal Medicine*, vol. 25, no. 4, pp. 321–325, 2010.

[31] S. H. Ko, B. R. Reynolds, D. H. Nicholas et al., "Institutional protocol improves retrievable inferior vena cava filter recovery rate," *Surgery*, vol. 146, no. 4, pp. 809–816, 2009.

[32] D. Imberti, M. Bianchi, A. Farina, S. Siragusa, M. Silingardi, and W. Ageno, "Clinical experience with retrievable vena cava filters: results of a prospective observational multicenter study," *Journal of Thrombosis and Haemostasis*, vol. 3, no. 7, pp. 1370–1375, 2005.

[33] H. S. Kim, M. J. Young, A. K. Narayan, K. Hong, R. P. Liddell, and M. B. Streiff, "A comparison of clinical outcomes with retrievable and permanent inferior vena cava filters," *Journal of Vascular and Interventional Radiology*, vol. 19, no. 3, pp. 393–399, 2008.

[34] C. E. Ray Jr., E. Mitchell, S. Zipser, E. Y. Kao, C. F. Brown, and G. L. Moneta, "Outcomes with retrievable inferior vena cava filters: a multicenter study," *Journal of Vascular and Interventional Radiology*, vol. 17, no. 10, pp. 1595–1604, 2006.

[35] R. Karmy-Jones, G. J. Jurkovich, G. C. Velmahos et al., "Practice patterns and outcomes of retrievable vena cava filters in trauma patients: an AAST multicenter study," *The Journal of Trauma*, vol. 62, no. 1, pp. 17–24, 2007.

[36] O. Dabbagh, N. Nagam, R. Chitima-Matsiga, S. Bearelly, and D. Bearelly, "Retrievable inferior vena cava filters are not getting retrieved: where is the gap?" *Thrombosis Research*, vol. 126, no. 6, pp. 493–497, 2010.

[37] J. Minocha, I. Idakoji, A. Riaz et al., "Improving inferior vena cava filter retrieval rates: impact of a dedicated inferior vena cava filter clinic," *Journal of Vascular and Interventional Radiology*, vol. 21, no. 12, pp. 1847–1851, 2010.

[38] J. S. Marquess, C. T. Burke, A. H. Beecham et al., "Factors associated with failed retrieval of the Gunther Tulip inferior vena cava filter," *Journal of Vascular and Interventional Radiology*, vol. 19, no. 9, pp. 1321–1327, 2008.

[39] J. L. Hermsen, A. R. Ibele, L. D. Faucher, J. K. Nale, M. J. Schurr, and K. A. Kudsk, "Retrievable inferior vena cava filters in high-risk trauma and surgical patients: factors influencing successful removal," *World Journal of Surgery*, vol. 32, no. 7, pp. 1444–1449, 2008.

[40] F. C. Lynch, "Balloon-assisted removal of tilted inferior vena cava filters with embedded tips," *Journal of Vascular and Interventional Radiology*, vol. 20, no. 9, pp. 1210–1214, 2009.

[41] S. W. Stavropoulos, R. G. Dixon, C. T. Burke et al., "Embedded inferior vena cava filter removal: use of endobronchial forceps," *Journal of Vascular and Interventional Radiology*, vol. 19, no. 9, pp. 1297–1301, 2008.

[42] L. Rubenstein, A. K. Chun, M. Chew, and C. A. Binkert, "Loop-snare technique for difficult inferior vena cava filter retrievals," *Journal of Vascular and Interventional Radiology*, vol. 18, no. 10, pp. 1315–1318, 2007.

[43] B. Iliescu and Z. J. Haskal, "Advanced techniques for removal of retrievable inferior venacava filters," *CardioVascular and Interventional Radiology*, vol. 35, no. 4, pp. 741–750, 2012.

[44] T. W. F. Vink, J. A. Reekers, L. C. van Dijk, J. J. Wever, and H. van Overhagen, "Balloon-assisted retrieval of tilted optease IVC filter," *CardioVascular and Interventional Radiology*, vol. 35, no. 4, pp. 975–977, 2012.

[45] W. T. Kuo, R. T. Tong, G. L. Hwang et al., "High-risk retrieval of adherent and chronically implanted IVC filters: techniques for removal and management of thrombotic complications," *Journal of Vascular and Interventional Radiology*, vol. 20, no. 12, pp. 1548–1556, 2009.

[46] W. T. Kuo and J. S. Cupp, "The excimer laser sheath technique for embedded inferior vena cava filter removal," *Journal of Vascular and Interventional Radiology*, vol. 21, no. 12, pp. 1896–1899, 2010.

[47] F. B. Rogers, M. D. Cipolle, G. Velmahos, G. Rozycki, and F. A. Luchette, "Practice management guidelines for the prevention of venous thromboembolism in trauma patients: the EAST practice management guidelines work group," *Journal of Trauma—Injury, Infection and Critical Care*, vol. 53, no. 1, pp. 142–164, 2002.

[48] E. L. Spangler, E. D. Dillavou, and K. J. Smith, "Cost-effectiveness of guidelines for insertion of inferior vena cava filters in high-risk trauma patients," *Journal of Vascular Surgery*, vol. 52, no. 6, pp. 1537.e2–1545.e2, 2010.

[49] H. Decousus, "Eight-year follow-up of patients with permanent vena cava filters in the prevention of pulmonary embolism: the PREPIC (Prévention du Risque d'Embolie Pulmonaire par Interruption Cave) randomized study," *Circulation*, vol. 112, no. 3, pp. 416–422, 2005.