Hindawi Publishing Corporation
Advances in Orthopedic Surgery
Volume 2014, Article ID 518310, 7 pages
http://dx.doi.org/10.1155/2014/518310

Clinical Study

Analysis of Contoured Anatomic Plate Fixation versus Intramedullary Rod Fixation for Acute Midshaft Clavicle Fractures

Juliann Kwak-Lee,[1] Elke R. Ahlmann,[1] Lingjun Wang,[2] and John M. Itamura[3]

[1] *Los Angeles County + University of Southern California Medical Center, 1200 N. State Street, GNH 3900, Los Angeles, CA 90033, USA*
[2] *Department of Orthopedics, Los Angeles County + University of Southern California Medical Center, 1200 N. State Street, GNH 3900, Los Angeles, CA 90033, USA*
[3] *Keck School of Medicine, Kerlan-Jobe at White Memorial Medical Center, 1700 Cesar E. Chavez Avenue, Suite 1400, Los Angeles, CA 90033, USA*

Correspondence should be addressed to Elke R. Ahlmann; ahlmann2002@yahoo.com

Received 9 September 2013; Accepted 27 January 2014; Published 2 March 2014

Academic Editor: Ely Steinberg

The recent trend has been toward surgical fixation of displaced clavicle fractures. Several fixation techniques have been reported yet it is unclear which is preferable. We retrospectively reviewed one hundred one consecutive patients with acute midshaft clavicle fractures treated operatively at a level-1 trauma center. Thirty-four patients underwent intramedullary pin fixation and 67 had anatomic plate fixation. The outcomes we assessed were operative time, complications, infection, implant failure, fracture union, range of motion, and reoperation rate. There were 92 males and 9 females with an average age of 30 years (range: 14–68 years). All patients were followed to healing with an average followup of 20 months (range: 15–32 months). While fracture union by six months ($P = 0.8729$) and range of motion at three months ($P = 0.6139$) were similar, the overall healing time for pin fixation was shorter ($P = 0.0380$). The pin group had more infections ($P = 0.0335$) and implant failures ($P = 0.0245$) than the plate group. Intramedullary pin fixation may have improved early results, but there was no long term difference in overall rate of union and achievement of full shoulder motion. The higher rate of implant failure with pin fixation may indicate that not all fracture patterns are amenable to fixation using this device.

1. Introduction

Clavicle fractures are common injuries accounting for 5–10% of all fractures [1–3]. The majority of fractures (70–80%) are located within the middle third of the shaft [1, 2, 4]. Traditionally, acute midclavicular fractures have been treated nonoperatively with either sling or figure-of-eight bandage, with a reported less than 1% rate of fracture nonunion [5–8]. Until recently, operative indications typically included open fractures, tenting of the skin, neurovascular injuries, and concomitant shoulder girdle injuries [9, 10]. However, more recent studies have reported nonunion rates of 4–29% [11–16] and malunion rates of 14–36% [9, 14, 17–19] with displaced clavicle fractures. One study demonstrated that shoulder biomechanics were significantly altered by malunion of the clavicle [19]. Patients complained of weakness, rapid fatiguability, loss of endurance, numbness, and paraesthesias with overhead activities and deficits in functional cosmesis. Studies that have used patient-based outcome measures have described unsatisfactory outcome rates of 25–30%, with complications including neurologic symptoms and functional deficits [2, 9, 12, 15, 19]. Improved patient outcomes, earlier return to function, decreased nonunion and malunion rates, and better cosmesis have all been reported with operative fixation of acute clavicle fractures [13, 16, 17, 20]. Based on these recent studies, the trend has moved towards surgical stabilization of selected clavicle fractures, with operative indications including significant shortening or distraction

(>1.5 centimeters), displacement greater than 100%, and the presence of a zed fragment [10, 17, 21].

Several fixation methods have been reported including plate fixation [9, 17, 21], intramedullary pin fixation [22–25], and placement of intramedullary threaded k-wires [20, 26] and elastic intramedullary nails [6, 27]. Plate fixation has emerged as a popular technique. Placement of the plate has been a subject of debate with common locations including superior, anterior, or inferior surfaces of the clavicle. Several biomechanical studies evaluating plate placement concluded that anteroinferior plates may fail at a lower load than superiorly placed plates [28, 29]. Typically low contact dynamic compression (LCDC) plates or reconstruction plates have been used [14, 21]; however, precontoured plates designed to parallel the S-shaped curve of the clavicle have recently become popular alternatives [9, 17, 30]. Disadvantages of plate fixation include extensive soft tissue dissection which may result in damage to the superior clavicular nerves resulting in paresthesias, as well as implant prominence due to the superficial location of the plate [31, 32].

A less invasive alternative gaining popularity is intramedullary pin fixation. This technique utilizes a limited incision for fracture reduction and a separate small incision for pin placement through the lateral clavicle. Only a limited number of studies with small numbers of patients have evaluated the clinical outcome of this method of fixation [22–25, 33].

The purpose of this study is to evaluate whether one method of fixation (either pin or plate fixation) is preferable over the other in terms of complication rates, intraoperative variables, return to full shoulder motion, and time to fracture union for the treatment of acute midshaft clavicle fractures.

2. Patients and Methods

A retrospective review of the upper extremity trauma database was conducted to identify all operatively treated clavicle fractures at our institution from 2006 to 2010. All patients who presented with clavicle fractures with either displacement ≥100%, shortening of ≥1.5 centimeters, and/or the presence of a vertical zed fragment are counseled and offered surgical fixation. A total of 125 patients with clavicle fractures who underwent open reduction internal fixation of the clavicle were identified. All patients with concomitant shoulder girdle injuries, that is, floating shoulders (7 patients), clavicle fractures of the distal third or proximal third (7 patients), and less than one year of followup were excluded (10 patients). This left a total of 101 patients with isolated operatively treated midshaft clavicle fractures available for review.

Retrospective chart review was performed for operative time, estimated blood loss, intraoperative and postoperative complications, shoulder range of motion, and length of time to fracture healing.

Digital plain radiographs of the clavicle taken at initial injury and at each followup visit were reviewed by a single investigator (ERA) for initial injury fracture pattern, Orthopaedic Trauma Association (OTA) Classification [34], implant-related complications, and evidence of fracture healing. The initial injury radiographs were reviewed for the presence or absence of a zed fragment. The amount of initial fracture shortening and displacement were measured using a digital ruler. The clavicle fracture was deemed radiographically healed when there was evidence of bridging callous and obliteration of the initial fracture lines.

Table 1: Injury mechanism distribution.

Mechanism of injury	Number of patients
Sports	30
Fall from bicycle	27
Ground level fall	17
Motorcycle	15
No data	5
Fall from height	2
Hit by car	2
Motor vehicle accident	2
Assault	1
Total	**101**

There were 92 males and 9 females with an average age of 29.7 years (range: 14 to 68 years). The majority of injuries were due to low energy trauma (Table 1). There were 47 right (47%) and 54 left (53%) sided injuries, of which 50 (50%) affected the dominant side extremity. The average time from injury to surgery was 12.8 days (range: 1 to 43 days). Sixty-seven patients (66%) underwent plate fixation and 34 (34%) underwent intramedullary pin placement. The average length of followup was 20 months (range: 15 to 32 months). Patient demographics are summarized in Table 2.

All surgical procedures were performed by or under the supervision of two upper extremity trauma surgeons. One surgeon exclusively performed plate fixation while the second surgeon performed both plate and pin fixation surgeries. The surgical indications for fracture fixation included open fracture, presence of a zed fragment, >100% vertical displacement, shortening of >1.5 cm, and skin tenting.

All 67 clavicle plate fixation procedures were performed in a similar fashion through an incision centered over the superior aspect of the clavicle, taking care to dissect and preserve the cutaneous supraclavicular nerves whenever possible. Acumed anatomic contoured clavicle plates (Acumed USA, Hillsboro, OR) were used on all 67 patients and all were positioned over the superior surface of the clavicle (Figures 1(a)-1(b)). All fractures were fixed with three 3.5 mm screws (6 cortices of fixation) on either side of the fracture site. Occasionally, in order to aid in reduction of small fracture fragments or zed fragments, 2.0 mm Modular Hand System screws (Synthes, Inc., West Chester, PA) were additionally used.

Thirty-four patients underwent intramedullary pin fixation by a single surgeon using a standardized technique of a limited incision for fracture reduction and a separate small incision for pin placement through the lateral clavicle. Twenty-nine patients had fixation using the Rockwood Clavicle Pin (Depuy Orthopaedics, Warsaw, IN) and five patients had placement of the Acumed Clavicle Rod (Acumed USA, Hillsboro, OR). Both pin fixation methods were performed

Table 2: Patient demographics and fracture patterns.

Demographics	Pin (range)	Plate (range)	P value
No. of patients	34	67	0.1135
Age (years)	27.6 (14–59)	31.7 (16–68)	0.1453
Gender: male	29	63	0.1843
Gender: female	5	4	0.2194
Dominant extremity fracture	17	33	0.7287
Time from injury to surgery (days)	11.8 (3–26)	13.4 (1–42)	0.6349
Length of followup (months)	19 (15–26)	22 (18–32)	0.2578
Fracture pattern			
OTA 15-B1	12	15	
OTA 15-B2	16	34	0.3492
OTA 15-B3	6	18	
Average displacement (mm)	18.4 (9–30)	20.6 (7–47)	0.1649
Average shortening (mm)	21.6 (7–37)	20.2 (7–37)	0.3631

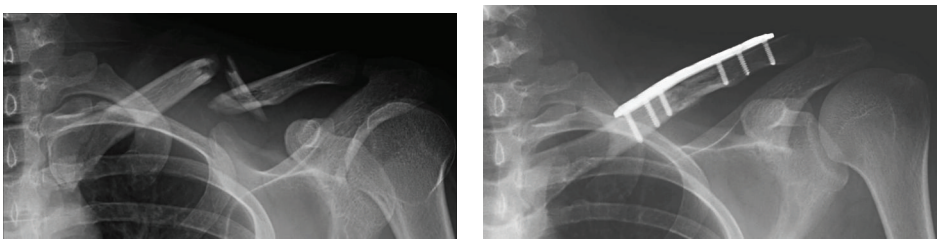

(a) (b)

Figure 1: (a) AP radiograph of the shoulder demonstrates the intercalary fragment in the midshaft clavicle fracture representing the zed fragment and >100% fracture displacement. (b) Postoperative radiograph of the same patient after fracture fixation using the Acumed contoured clavicle plate.

according to the manufacturers' recommended technique and both pins function in a similar manner (Figures 2(a)–2(c)).

Postoperatively patients were placed in a shoulder sling for 10 days and subsequently allowed to perform passive and active range of motion exercises from 0 to 90 degrees of shoulder elevation under the direction of a physical therapist. Six weeks postoperatively, all patients were then allowed to perform active and passive range of motion, including overhead activities. Patients were told to refrain from participating in sports for a total of 6 months from the time of operative fixation. Those patients who underwent intramedullary pin fixation were told that they would have to undergo a second procedure from removal of the pin at a minimum of three months postoperatively or when there was evidence of healing of the fracture. Clavicle plates were not routinely removed after fracture union.

Statistical analysis was performed using GraphPad Prism software (GraphPad Software, Inc., San Diego, CA). Chi-square test and Student's t-test were used to determine differences in demographic data, intraoperative measures, rate of fracture healing, and range of motion. Fisher's exact test was used to determine differences in the distribution of fracture patterns and the rate of complications between the two groups. A P value of less than 0.05 was considered significant.

3. Results

Operative times were measured from incision to skin closure. In the pin group, the average operative time was 99.5 min (range 43–169 min) while in the plate group, the average operative time was significantly longer with an average of 131.8 min (range 30–246 min) ($P = 0.0007$). Estimated blood loss between the two procedures showed no difference ($P = 0.4709$).

The complications for pin and plate fixation are described in detail in Table 3. In the intramedullary pin group, there was a significantly increased rate of implant failure ($P = 0.0245$). All 3 failures consisted of the rod backing out through the skin and required either removal or reinsertion of the pin if the fracture was not fully healed. The fracture pattern of these three patients showed comminution and the presence of zed fragments. The one failure after plate fixation was breakage of the plate 3 weeks postoperatively as a result of a fall during a seizure episode. This patient underwent a second procedure for removal of the plate and repeat fixation using a new Acumed clavicle plate. The pin group also demonstrated a significantly higher rate of implant-associated infection than those treated with plate fixation ($P = 0.0335$). As plate fixation techniques included a larger incision and more dissection, 11 of 67 patients (16.4%) developed numbness

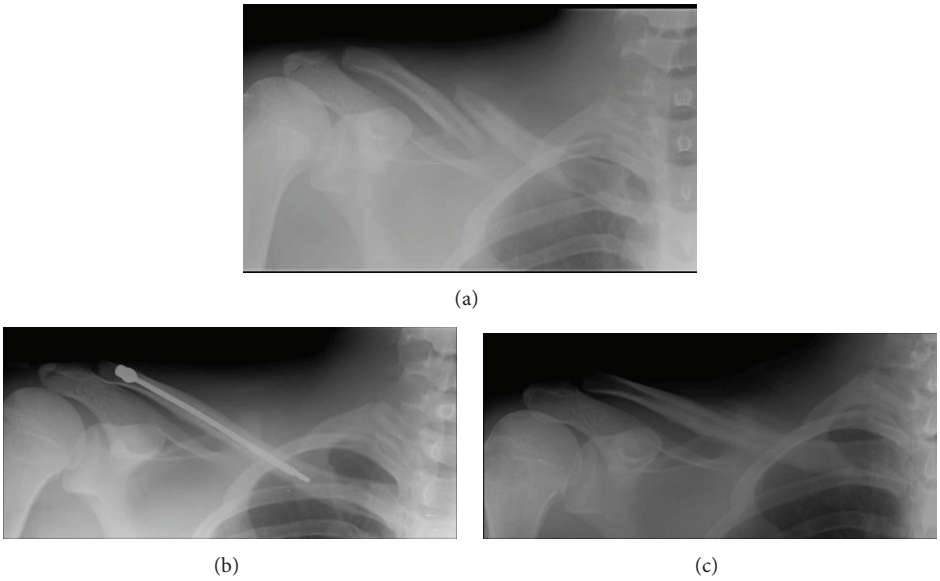

Figure 2: (a) AP radiograph of the clavicle showing a midshaft clavicle fracture with displacement and 2.3 cm shortening. (b) Postoperative radiograph of the same patient after fracture fixation using the Rockwood clavicle. (c) Followup radiograph taken 3 months postoperatively after fracture union and removal of the Rockwood clavicle pin.

Table 3: Clinical results and complications of pin versus plate fixation.

Complications	Pin (no. of patients)	%	Plate (no. of patients)	%	*P* value
Infection	4	11.8	1	1.5	0.0335
Implant failure	3	8.8	1	1.5	0.0245
Nonunion after 6 months	3	8.8	4	6	0.8729
Failed implant removal	3	8.8	0	0	0.5472
Adhesive capsulitis	1	2.9	0	0	0.8720
Symptomatic implant	0	0	2	2.9	0.6949
DVT	0	0	1	1.5	0.8483
Incisional symptoms	0	0	11	16.4	0.0275

DVT: deep venous thrombosis.

or hypersensitivity over their incision sites which was not seen after pin fixation ($P = 0.0275$). Two patients (2.9%) developed implant prominence or symptomatic implants, yet neither desired to have subsequent surgery for plate removal.

Unique to the pin group, 76% of patients (26 of 34 patients) underwent a second surgery for pin removal as recommended. Three of these patients (8.8%) had failed implant removal with breakage of the pin and subsequent implant retention. All three patients had a 2.5-millimeter rod.

Full range of motion at 3-month followup was similarly achieved in both groups with 18 of 34 patients (52.9%) in the pin group and 39 of 67 patients (58.2%) in the plate group ($P = 0.6139$). One patient in the pin group (2.9%) developed postoperative adhesive capsulitis, which resulted in a delay in regaining full shoulder motion. This patient did eventually attain full motion by six months postoperatively. All patients in this series regained full shoulder motion by 6 months.

There was a significantly longer time to fracture union in those patients who underwent plate fixation with an average of 14.6 weeks (range 6–33.5 weeks) compared to pin fixation at 9.5 weeks (range 6–24 weeks) ($P = 0.0380$). Fracture nonunion at 6 months (26 weeks) was 6.0% (4 of 67) in the plate group and 8.8% (3 of 34) in the pin group ($P = 0.8729$). In both groups, all fractures that did not heal within six months were in patients who were heavy smokers; these patients did eventually heal their fractures by their latest followup.

4. Discussion

Management of patients with displaced midshaft clavicle fractures has evolved over the last 10 years with a move away from nonoperative treatment to the use of various fixation devices including the intramedullary pin and plate fixation. Yet the ideal method of treatment still remains unclear. We therefore compared intraoperative variables, complications, function, and fracture healing in patients treated with intramedullary pin devices and anatomic contoured plates determine if one method is preferable to the other.

We acknowledge several limitations of this study. First, owing to the nonrandomized retrospective design we did not control for potentially confounding variables such as patient demographics and fracture pattern. We did, however, determine that there were no significant differences (P values >0.05) between patients who underwent pin fixation and those who had plate fixation with regards to age, gender distribution, hand dominance, sidedness of the fracture, time to surgery, fracture pattern, and length of followup. This indicates that the two groups of patients were similar and for this reason we believe that they can be effectively compared. Second, there is inherent selection bias in the choice of surgical implant when performing a retrospective analysis. In this series, one surgeon only performed plate fixation; the other initially performed mainly pin fixation and then moved toward primarily performing plate fixation. One would be led to believe that this bias would skew the plate group toward more comminuted fractures and the pin group toward more simple fracture patterns. Nonetheless we observed no difference in the distribution of fracture patterns between the two groups ($P > 0.05$) such that selection bias based on fracture pattern is less likely.

The standard technique of plate fixation has advanced with the design of the precontoured plate which better fits the curve of the clavicle and was developed to reduce some of the common complications associated with this fixation technique including implant prominence. Despite the use of contoured plates, two patients in our series (3%) did report symptoms of discomfort associated with implant prominence, yet neither wished to undergo a further surgical procedure for plate removal. This is lower than the rate of plate prominence previously reported which has ranged from 7 to 32% with precontoured plates [17, 35]. A study evaluating the clinical applicability of the Acumed locking clavicle plate reported that this plate is adequately shaped for the fixation of fractures in the medial three-fifths of the clavicular shaft [30]. However, not all patients with a fracture located in the lateral two-fifths of the clavicular shaft had anatomic fit of the plate. This may explain why a certain proportion of patients may still have implant prominence despite the use of an "anatomic" plate.

Another complication in our series primarily seen with plate fixation was a symptomatic incision, including both hypersensitivity and numbness. Although during our surgical approach we routinely dissect, neurolyse, and protect the supra- and infraclavicular nerves, 16.4% of patients in the plate group still reported skin numbness or hypersensitivity around their surgical incision. It is possible that intraoperative traction and/or stretching of the nerves over the plate may still occur in a certain proportion of patients and lead to this complication.

The S-shaped clavicle poses a problem for intramedullary pin insertion with sufficient engagement length into the curved medullary canal and may potentially explain why a higher rate of implant failure was seen in our series after pin fixation. A biomechanical study evaluating pin fixation in simple midshaft clavicle fractures reported that stability of fracture fixation is closely related to the length of intramedullary pin engagement [36]. The intramedullary pin functions as an internal splint that maintains alignment of the fracture without rigid fixation [20, 22, 37] and thus is not designed for axially and rotationally unstable fracture patterns. Since the pin functions as a load sharing device having no rigid fixation, a longer leverage of bending moment is needed to improve stability of the fracture fixation [20]. However, using a large and rigid intramedullary pin has the problem of a short engaged length in both the curved medullary canal of the clavicle and the medial fracture fragment, resulting in higher stress at the bone-pin interface, which is an important cause of pin loosening and failure of fixation [22]. Thus in the presence of significant comminution or a zed fragment at the fracture site, there is even less engaged length of the pin in the medullary canal further limiting the amount of fixation. Several biomechanical analyses of the Rockwood clavicle pin confirmed this as the pin was reported to be inadequate for fixation when rotational stiffness was required [38, 39]. All three patients in our series who developed loosening of the Rockwood clavicle pin had segmental comminution making them rotationally and axially unstable and thus less appropriate for pin fixation. It is for this reason that we now only perform intramedullary pin fixation for simple fractures with adequate cortical apposition.

Our patients who had loss of fixation additionally developed infection as the pin backed out of the lateral end of the clavicle to a point that the device became superficial resulting in skin breakdown and erosion of the lateral fixation nut through the skin. This then led to bacterial seeding of the implant with the development of purulent drainage and an abscess at the pin entry site. One additional patient who did not have implant failure also developed an abscess over the superficial lateral fixation nut. Mudd et al. [24] reported similar problems with lateral prominence of the implant resulting in skin necrosis and infection in four of 18 patients (22%) while Strauss et al. [25] reported 3 of 16 (19%) patients developed posterior skin breakdown due to implant prominence. We did note less prominence and a decrease in related complications once we started using a high-speed burr to smooth the sharp lateral end of the rod and make it flush with the nut. We recommend taking into consideration the patient's habitus and soft tissue coverage over the posterolateral acromion when considering intramedullary pin fixation as this device may be prominent and problematic for thin patients.

Pin fixation for clavicle fractures is less invasive. Extensive soft tissue dissection is spared and the periosteum remains intact. This may allow abundant callus formation and better healing of the fracture, which is perhaps reflected in our faster healing rate with plate fixation, although ultimately there was no difference in the overall rate of union when compared to plate fixation. There were three patients in the pin group (8.8%) and four patients (6%) in the plate group with delayed union who had not healed their fractures by 6 months. All patients were smokers and ultimately healed their fractures by 18 months after surgery. These rates are comparable to those reported in the literature with delayed union and nonunion rates of 0–6% [23–25] and 0–17% [13, 23–25], respectively, for

intramedullary pin fixation and 0–4% [17, 21, 37] and 2–4% [17, 35, 40], respectively, for plate fixation.

Both intramedullary pins and contoured clavicle plates are reasonable choices for fixation of midshaft clavicle fractures. The less invasive technique of intramedullary pin fixation may have improved early results with shorter operative times and faster overall fracture healing, but in the long term there was no significant difference in overall rate of union and achievement of full shoulder motion between the two groups. The higher rate of implant failure associated with pin fixation may indicate that this device is not suitable for all fracture patterns. We recommend plate fixation for fractures with significant comminution or a zed fragment. Pin fixation should be reserved for simple fractures with good cortical apposition as this technique is both more technically challenging and requires adequate bone purchase thus making it less suitable for rotationally and axially unstable fracture patterns.

Disclosure

Each author certifies that his or her institution has approved the human protocol for this investigation and that all investigations were conducted in conformity with ethical principles of research and that informed consent for participation in the study was obtained. See Guidelines for Authors for a complete description of levels of evidence (Level of Evidence: Therapeutic Level III).

Conflict of Interests

Dr. Kwak-Lee, Dr. Ahlmann, and Lingjun Wang certify that they have no commercial associations (e.g., consultancies, stock ownership, equity interest, patent/licensing arrangements, etc.) that might pose a conflict of interest in connection with the submitted article. Dr. Itamura is a speaker for Acumed.

References

[1] M. D. McKee, "Clavicle fractures," in *Rockwood and Green's Fractures in Adults*, pp. 1106–1143, Lippincott Williams & Wilkins, Hagerstown, Md, USA, 7th edition, 2010.

[2] A. Nordqvist, C. J. Petersson, and I. Redlund-Johnell, "Midclavicle fractures in adults: end result after conservative treatment," *Journal of Orthopaedic Trauma*, vol. 12, no. 8, pp. 572–576, 1998.

[3] F. Postacchini, S. Gumina, P. de Santis, and F. Albo, "Epidemiology of clavicle fractures," *Journal of Shoulder and Elbow Surgery*, vol. 11, no. 5, pp. 452–456, 2002.

[4] A. Nordqvist and C. Petersson, "The incidence of fractures of the clavicle," *Clinical Orthopaedics and Related Research*, vol. 300, pp. 127–132, 1994.

[5] K. Andersen, P. O. Jensen, and J. Lauritzen, "Treatment of clavicular fractures: figure-of-eight bandage versus a simple sling," *Acta Orthopaedica Scandinavica*, vol. 58, no. 1, pp. 71–74, 1987.

[6] C. S. Neer, "Nonunion of the clavicle," *Journal of the American Medical Association*, vol. 172, pp. 1006–1011, 1960.

[7] C. M. Robinson and D. A. Cairns, "Primary nonoperative treatment of displaced lateral fractures of the clavicle," *Journal of Bone and Joint Surgery A*, vol. 86, pp. 1359–1365, 2004.

[8] C. R. Rowe, "An atlas of anatomy and treatment of midclavicular fractures," *Clinical Orthopaedics and Related Research*, vol. 58, pp. 29–42, 1968.

[9] M. D. McKee, L. M. Wild, and E. H. Schemitsch, "Midshaft malunions of the clavicle," *Journal of Bone and Joint Surgery A*, vol. 85, no. 5, pp. 790–797, 2003.

[10] M. Zlowodzki, B. A. Zelle, P. A. Cole, K. Jeray, and M. D. McKee, "Treatment of acute midshaft clavicle fractures: systematic review of 2144 fractures. On behalf of the Evidence-Based Orthopaedic Trauma Working Group," *Journal of Orthopaedic Trauma*, vol. 19, no. 7, pp. 504–508, 2005.

[11] M. R. Brinker, T. B. Edwards, D. P. O'Connor, and C. M. Robinson, "Estimating the risk of nonunion following nonoperative treatment of a clavicular fracture," *Journal of Bone and Joint Surgery A*, vol. 87, no. 3, pp. 676–677, 2005.

[12] J. M. Hill, M. H. McGuire, and L. A. Crosby, "Closed treatment of displaced middle-third fractures of the clavicle gives poor results," *Journal of Bone and Joint Surgery B*, vol. 79, no. 4, pp. 537–541, 1997.

[13] D. B. Judd, M. P. Pallis, E. Smith, and C. R. Bottoni, "Acute operative stabilization versus nonoperative management of clavicle fractures," *American Journal of Orthopedics*, vol. 38, no. 7, pp. 341–345, 2009.

[14] V. Kulshrestha, T. Roy, and L. Audige, "Operative versus nonoperative management of displaced midshaft clavicle fractures: a prospective cohort study," *Journal of Orthopaedic Trauma*, vol. 25, no. 1, pp. 31–38, 2011.

[15] J. Nowak, M. Holgersson, and S. Larsson, "Sequelae from clavicular fractures are common: a prospective study of 222 patients," *Acta Orthopaedica*, vol. 76, no. 4, pp. 496–502, 2005.

[16] V. Smekal, A. Irenberger, P. Struve, M. Wambacher, D. Krappinger, and F. S. Kralinger, "Elastic stable intramedullary nailing versus nonoperative treatment of displaced midshaft clavicular fractures: a randomized, controlled, clinical trial," *Journal of Orthopaedic Trauma*, vol. 23, no. 2, pp. 106–112, 2009.

[17] Canadian Orthopaedic Trauma Society, "Nonoperative treatment compared with plate fixation of displaced midshaft clavicular fractures," *Journal of Bone and Joint Surgery*, vol. 89, pp. 1–10, 2007.

[18] K. Y. Chan, J. B. Jupiter, R. D. Leffert, and R. Marti, "Clavicle malunion," *Journal of Shoulder and Elbow Surgery*, vol. 8, no. 4, pp. 287–290, 1999.

[19] M. D. McKee, E. M. Pedersen, C. Jones et al., "Deficits following nonoperative treatment of displaced midshaft clavicular fractures," *Journal of Bone and Joint Surgery A*, vol. 88, no. 1, pp. 35–40, 2006.

[20] E. J. Zenni, J. K. Krieg, and M. J. Rosen, "Open reduction and internal fixation of clavicular fractures," *Journal of Bone and Joint Surgery A*, vol. 63, no. 1, pp. 147–151, 1981.

[21] M. D. McKee, J. G. Seiler, and J. B. Jupiter, "The application of the limited contact dynamic compression plate in the upper extremity: an analysis of 114 consecutive cases," *Injury*, vol. 26, no. 10, pp. 661–666, 1995.

[22] D. Boehme, R. J. Curtis Jr., J. T. DeHaan, S. P. Kay, D. C. Young, and C. A. Rockwood Jr., "Non-union of fractures of the mid-shaft of the clavicle. Treatment with a modified Hagie intramedullary pin and autogenous bone-grafting," *Journal of Bone and Joint Surgery A*, vol. 73, no. 8, pp. 1219–1225, 1991.

[23] C. Chu, S. Wang, and L. Lin, "Fixation of mid-third clavicular fractures with knowles pins: 78 patients followed for 2–7 years," *Acta Orthopaedica Scandinavica*, vol. 73, no. 2, pp. 134–139, 2002.

[24] C. D. Mudd, K. J. Quigley, and L. B. Gross, "Excessive complications of open intramedullary nailing of midshaft clavicle fractures with the Rockwood Clavicle Pin," *Clinical Orthopaedics and Related Research*, vol. 469, no. 12, pp. 3364–3370, 2011.

[25] E. J. Strauss, K. A. Egol, M. A. France, K. J. Koval, and J. D. Zuckerman, "Complications of intramedullary Hagie pin fixation for acute midshaft clavicle fractures," *Journal of Shoulder and Elbow Surgery*, vol. 16, no. 3, pp. 280–284, 2007.

[26] F. A. Grassi, M. S. Tajana, and F. D'Angelo, "Management of midclavicular fractures: comparison between nonoperative treatment and open intramedullary fixation in 80 patients," *Journal of Trauma*, vol. 50, no. 6, pp. 1096–1100, 2001.

[27] M. Mueller, C. Rangger, N. Striepens, and C. Burger, "Minimally invasive intramedullary nailing of midshaft clavicular fractures using titanium elastic nails," *The Journal of Trauma*, vol. 64, no. 6, pp. 1528–1534, 2008.

[28] M. R. Iannotti, L. A. Crosby, P. Stafford, G. Grayson, and R. Goulet, "Effects of plate location and selection on the stability of midshaft clavicle osteotomies: a biomechanical study," *Journal of Shoulder and Elbow Surgery*, vol. 11, no. 5, pp. 457–462, 2002.

[29] C. Robertson, P. Celestre, A. Mahar, and A. Schwartz, "Reconstruction plates for stabilization of mid-shaft clavicle fractures: Ddifferences between nonlocked and locked plates in two different positions," *Journal of Shoulder and Elbow Surgery*, vol. 18, no. 2, pp. 204–209, 2009.

[30] J. I. Huang, P. Toogood, M. R. Chen, J. H. Wilber, and D. R. Cooperman, "Clavicular anatomy and the applicability of precontoured plates," *Journal of Bone and Joint Surgery A*, vol. 89, no. 10, pp. 2260–2265, 2007.

[31] C. Collinge, S. Devinney, D. Herscovici, T. DePasquale, and R. Sanders, "Anterior-inferior plate fixation of middle-third fractures and nonunions of the clavicle," *Journal of Orthopaedic Trauma*, vol. 20, no. 10, pp. 680–686, 2006.

[32] J. Poigenfurst, G. Rappold, and W. Fischer, "Plating of fresh clavicular fractures: results of 122 operations," *Injury*, vol. 23, no. 4, pp. 237–241, 1992.

[33] C. P. Kleweno, A. Jawa, J. H. Wells et al., "Midshaft clavicular fractures: comparison of intramedullary pin and plate fixation," *Journal of Shoulder and Elbow Surgery*, vol. 20, no. 7, pp. 1114–1117, 2011.

[34] J. L. Marsh, T. F. Slongo, J. Agel et al., "Fracture and dislocation classification compendium—2007: Orthopaedic Trauma Association Classification, Database and Outcomes Committee," *Journal of Orthopaedic Trauma*, vol. 21, supplement 10, pp. S1–S133, 2007.

[35] C. VanBeek, K. J. Boselli, E. R. Cadet, C. S. Ahmad, and W. N. Levine, "Precontoured plating of clavicle fractures: decreased hardware-related complications?" *Clinical Orthopaedics and Related Research*, vol. 469, no. 12, pp. 3337–3343, 2011.

[36] T. Harnroongroj and Y. Jeerathanyasakun, "Intramedullary pin fixation in clavicular fractures: a study comparing the use of small and large pins," *Journal of Orthopaedic Surgery*, vol. 8, no. 2, pp. 7–11, 2000.

[37] M. Demirhan, K. Bilsel, A. C. Atalar, E. Bozdag, E. Sunbuloglu, and A. Kale, "Biomechanical comparison of fixation techniques in midshaft clavicular fractures," *Journal of Orthopaedic Trauma*, vol. 25, no. 5, pp. 272–278, 2011.

[38] D. S. Drosdowech, S. E. E. Manwell, L. M. Ferreira, D. P. Goel, K. J. Faber, and J. A. Johnson, "Biomechanical analysis of fixation of middle third fractures of the clavicle," *Journal of Orthopaedic Trauma*, vol. 25, no. 1, pp. 39–43, 2011.

[39] T. Renfree, B. Conrad, and T. Wright, "Biomechanical comparison of contemporary clavicle fixation devices," *Journal of Hand Surgery*, vol. 35, no. 4, pp. 639–644, 2010.

[40] O. Böstman, M. Manninen, and H. Pihlajamäki, "Complications of plate fixation in fresh displaced midclavicular fractures," *The Journal of Trauma*, vol. 43, no. 5, pp. 778–783, 1997.