

Research Article

Medium-Term Results of Treatment for Complicated Acute Type B Dissection: A Spanish Experience in a Single Centre

Jesus Alvarez-Garcia, Stefan Stefanov Kiuri, Alvaro Fernandez Heredero, Andres Salazar Alvarez, Nieves Aleicel Concepcion Rodriguez, and Luis Riera de Cubas

Department of Vascular Surgery, Hospital la Paz, 28026 Madrid, Spain

Correspondence should be addressed to Jesus Alvarez-Garcia; jesalvgar1985@gmail.com

Received 12 September 2013; Revised 1 December 2013; Accepted 9 December 2013; Published 15 January 2014

Academic Editor: Miltiadis I. Matsagkas

Copyright © 2014 Jesus Alvarez-Garcia et al. This is an open access article distributed under the Creative Commons Attribution License, which permits unrestricted use, distribution, and reproduction in any medium, provided the original work is properly cited.

Objective. To analyze and evaluate medium-term results obtained in endovascular treatment of complicated type B dissection. **Methods.** Prospective registry and retrospective analysis of the dissections treated with endoprosthesis in 1998 and 2010. Comorbidity, clinical presentation, anatomical characteristics, and evolution were recorded. Actuarial analysis was conducted for survival, follow-up and survival free of endoleaks, and free of reintervention due to relapse and/or progression. **Results.** Eighteen (18) patients were treated (14 male : 4 female), with a median age of 53 years (range 29–80). Their main symptoms were acute pain in 16 cases and hypertensive crisis in 15. The indications were 10 dissections not controlled by medication, 4 aneurysm dissecans, 2 acute lower limb ischemias, and 2 Type A progressions. Median 1.7 devices were used (range 1–4). Coverage of left subclavian artery was required in 3 cases, and of subclavian and left carotid artery in other 2 cases. There was a 100% technical success. Median follow-up was 43.1 months (1.5–127 range). There were two deaths caused by multiorgan failure, early mortality of 0%, and hospital mortality of 11%. There was a case of Type I Endoleak and 5 cases which required a new intervention due to relapse and/or progression. Cumulative survival at 30 months was 88%; follow-up free of endoleaks at 36 months was 91%. Follow-up free of progression/relapse at 12 months was 88%. **Conclusion.** Endovascular treatment of complicated type B acute dissection is an effective therapy for this condition, with a low associated mortality and with acceptable survival.

1. Introduction

Acute type B aortic dissection (B-AD) is still a life threatening situation [1–3], particularly complicated ones, which comprise up to 22% [3–5]. Dissection is considered complicated when present at least one of the following features: refractoriness to medical treatment, in terms of blood pressure and/or pain management, ascending progression, malperfusion syndromes, and/or aneurysmal degeneration with a diameter of 5.5 centimeters or more [1, 6, 7].

Besides these characteristics described about dissection, the fragility of these patients explains their high mortality. They are typically elderly with high comorbidity and/or connective tissue diseases [1, 7].

Regarding treatments to be used, medical treatment is the best choice in noncomplicated dissections [1, 6, 7], while in complicated dissection presents mortality rates of 20%

on the second day and between 25 and 50% in month [4, 7], which inevitably leads to consider the use of more aggressive therapies [7, 8] such as conventional surgery and endovascular techniques.

In conventional surgery (which thoracotomy, aortic clamping, and occasionally prolonged mechanical ventilation [9]) postoperative mortality ranges between 15 and 30%, which can rise up to 50% in emergency cases [8, 10]. On the other hand, when endoluminal devices are used, the mortality rates are about 17% [10], although it is true that we are not aware of their long-term evolution and complications [6].

The advantage offered by treatment with endoprosthesis is sealing the entry tear, redirecting the flow towards the real lumen, causing the obliteration, depressurization, and thrombosis of the false lumen, with sustained permeability of which is associated with aneurysmal degeneration [7, 10].

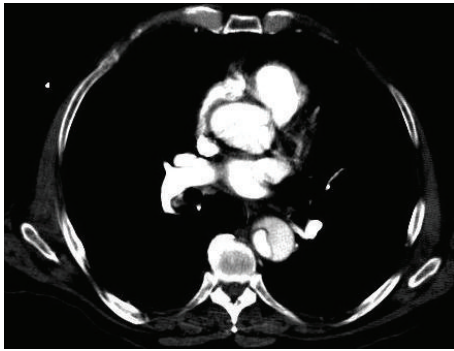


FIGURE 1

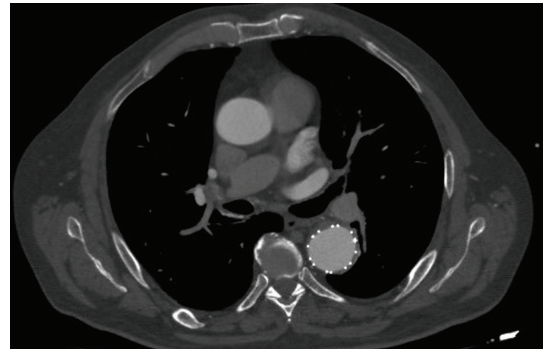


FIGURE 2

The objective of this study is to analyze our results obtained in endovascular treatments of complicated acute type B dissection during a period of 12 years and their mid-long-term follow-up.

2. Materials and Method

Based on our center prospective registry of patients treated with endoprosthesis between 1998 and 2010, a retrospective analysis was conducted of data for complicated B-ADs with less than 14 days of evolution.

Data were collected about comorbidity, clinical presentation, anatomical characteristics, surgical procedure, devices used, associated treatments, and technical success, according to the criteria by “reporting standards for thoracic endovascular aortic repair (TEVAR)” [11]. Regarding treatment indications, we limit to 72 hours of noncontrolled pain or blood pressure above 120 mmHg, which coincides with the publication by Ehrlich and Cols, to define refractoriness to medical treatment [10].

During in-hospital follow-up, renal failure after surgery and major postoperative neurological complications were recorded and at long term, follow-up free of Type I and III endoleaks [11] and follow-up free of reintervention due to progression and/or relapse [12].

According to protocol, after diagnosis by computerized axial tomography (Figure 1), patients were treated under general anesthesia and arteriographic control. Whenever available, transesophageal and electroencephalographic control was conducted. As the sole criterion, in an urgent situation, cerebrospinal fluid drainage was performed for cases where extensive endovascular repair was foreseen, including the occlusion of more than 10 pairs of intercostal arteries [13].

Bypass of supraaortic trunks were conducted according to the international recommendations by the “Society for Vascular Surgery,” in patients with any of the following conditions: (1) subclavian artery flow with insufficient compensation by ipsilateral vertebral retrograde flow, (2) presence of mammary-coronary bypass; (3) posterior inferior cerebellar artery depending on left vertebral, (4) hypogastric artery occlusion, (5) occlusion or absence of right vertebral artery, (6) previous lumbar or midsacrum ligature from other surgical procedures, (7) vascular access for hemodialysis in

upper left limb, and (8) extensive coverage of thoracic aorta (>20 cm) [14].

Technical success was defined as the absence of conversion to open surgery, no deaths within 24 hours, no intraoperative Type I or III endoleaks, or no endoprosthesis occlusion [11].

Malperfusion syndrome was considered to include those clinical cases of acute limb ischemia, acute renal and abdominal failure associated with the dissection, and radiological signs of limb, renal and/or visceral hypoperfusion [3, 15].

We considered major neurological episodes, according to the publication standards by TEVAR [11], those episodes of medullary ischemia or strokes with objective clinical diagnosis. Postoperative renal failure, in agreement with “The Second International Consensus Conference of the Acute Dialysis Quality Initiative (ADQI) Group,” was understood as the first occurrence of a creatinine value that was twice the baseline value for patients’ age and ethnicity, oligoanuria (<0.5 mL/kg/12 h), and/or the need for dialysis [16].

Follow-up was conducted by Angio CT scan (Figure 2), within the week after the procedure, at 3, 6, and 12 months and then annually. Actuarial analysis was conducted for survival and follow-up free of endoleaks and follow-up free of reintervention due to relapse and/or progression. The accepted values were those where standard error was below 10%.

3. Results

Eighteen (18) patients were treated, 14 men and 4 women, with a median age of 53 years (range 29–80). 66% of these patients presented hypertension, and 60% were habitual smokers; these were the most frequent clinical backgrounds (Table 1). Three subjects, 17%, presented dissection on previous aortic dilation, with an average diameter of 56 mm (range 45–70). One patient suffered Marfan Syndrome.

Associated symptomatology included acute pain in 17 cases, hypertensive crisis in 16, and acute lower limb ischemia in two patients. Two other patients presented vagal reaction, one suffered a sudden onset of dyspnea, and another patient presented high creatinine values due to renal artery involvement. In seven cases, the aorta was the only vessel affected (Table 2).

TABLE 1: Epidemiological characteristics.

Gender (female : men)	04 : 14
Age: median (range)	53 (29–80)
DM	3 (16%)
DL	4 (22%)
Smoking	9 (50%)
COPD	3 (16%)
CKF	3 (16%)
IC	3 (16%)
HTN	12 (66%)
ACVA	0
Median comorbidities per patient	2.1

DM: diabetes mellitus; DL: dyslipidemia; COPD: chronic obstructive pulmonary disease; CKF: chronic kidney failure; IC: ischemic cardiopathy; HTN: hypertension; ACVA: acute cerebrovascular accident (stroke).

The primary indication for invasive treatment was poor control of symptoms through medication, which occurred in 11 patients. Two of them presented insufficient pain management with controlled blood pressure, and in nine of them, pain and blood pressure were refractory to drugs, one of them being the patient with Marfan Syndrome.

The remaining indications were 3 patients treated for aneurysm dissections, one of them, with an aneurysm of 43 mm, associated insufficient clinical control; 2 other subjects required treatment for acute lower limb ischemia, one of them with refractory pain; and the last 2 cases were due to Type A progression (Figure 3), both with low response to analgesic treatment. One of the dissections with ascending progression was treated with ascending aorta replacement, while covering the entrance and conservative management was chosen for the other one (Table 3).

Regarding devices used, 4 patients were treated with relay thoracic endoprostheses (Bolton Medical, Sunrise, Florida), 5 patients with valiant thoracic stent grafts (Medtronic Vascular, Santa Rosa, California), and 8 patients with talent thoracic stent graft system (Medtronic Vascular, Santa Rosa, California). There was median 1.7 endoprostheses used per patient, ranging from one to four. Subclavian artery coverage was required in 3 cases, and other 2 cases required left carotid and subclavian artery coverage.

Within operating room, 100% of patients required pharmacological blood pressure control during the procedure; in 2 cases, there was electroencephalographic monitoring, and 15 patients underwent cerebrospinal fluid drainage.

There was 100% technical success, with immediate improvement in pain symptoms, which even disappeared after the procedure. The following associated procedures were required, listed by vascular areas.

Within the supraaortic territory, one carotid stenting and two bypass procedures were conducted. One patient required stent implantation in his left carotid artery, due to proximal migration of endoprosthesis. Another patient underwent sequential carotid-carotid-subclavian bypass, due to requiring subclavian-carotid coverage in order to obtain an anchorage area large enough for the endoluminal device. And

TABLE 2: Vessels involved.

Aorta exclusively	7
Supraaortic trunks	1
Celiac trunk	7
Upper mesenteric artery	1
Lower mesenteric artery	1
Right renal artery	3
Left renal artery	1
Right iliac artery	2
Left iliac artery	5

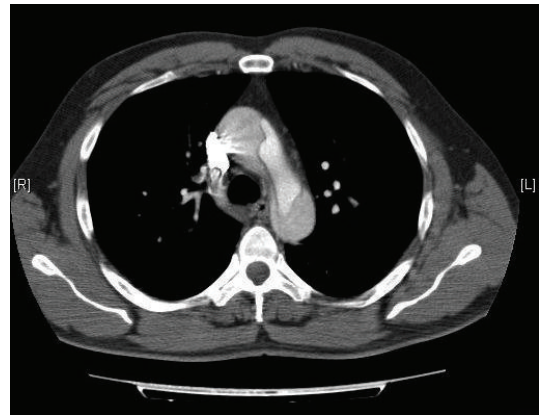

FIGURE 3

another subject required aneurismal ascending aorta repair, with right carotid ligature, and therefore a left-right carotid-carotid bypass was performed. No sequelae were objectived during the follow-up.

Within the visceral area, 3 patients had renal stents implanted.

Within the aortoiliac area, 3 iliac stents were implanted and 3 aortouniliac endoprostheses. Each endoprosthesis had an iliac occluder and a femoral-femoral bypass associated and in one case, a covered stent was implanted from the external iliac to the hypogastric artery (Table 3).

Five cases required reintervention, three of them due to progression (two distal and one proximal), one due to aortic rupture, and the last one due to device rotation, with hemodynamic consequences.

In one of the distal progression cases, a talent aortouniliac device was implanted, and a femoral-femoral bypass was performed while in the other case, an intimal flap was attached in the left femoral artery.

The patient with proximal progression required the implantation of a valiant endoprosthesis with subclavian and carotid occlusion and a carotid-carotid bypass.

Aortic rupture occurred at 23 days of the B-AD treatment. This was associated with a Type Ib Endoleak, on a Talent device. Despite the emergency implantation of two Bolton devices, with an interval of 22 days between them, death occurred four days after the last implantation, due to hemorrhagic shock.

TABLE 3: Associated indications, devices, and treatments.

Patient	Primary indication	Devices	Associated procedures
1	Insufficient medical treatment for pain and BP	Bolton	Covered stent (Wallgraft) in left carotid artery and embolization of transplanted kidney.
2	Insufficient medical treatment for pain and BP	Relay	
3	Dilation 43MM	Valiant thoracic	Covered stent (Wallgraft) in right renal artery
4	Dilation 53MM	Valiant	Sequential right carotid-left carotid-left subclavian bypass
5	Insufficient medical treatment for pain and BP	Bolton Relay	Covered stent (symbiot) in left renal artery
6	Insufficient medical treatment for pain and BP	Valiant × 2	
7	Insufficient medical treatment for pain and BP	Bolton Relay	
8	Insufficient medical treatment for pain	Valiant	
9	Acute Lower limb ischemia	Valiant × 2	Ascending aorta replacement. right common carotid ligature and carotid-carotid left-right bypass
10	DILATION 70MM	Talent × 2	Talent abdominal aortouniliac endoprosthesis, talent occluder in left common iliac artery and cross-over femoro-femoral bypass
11	Insufficient medical treatment for pain AND BP	Talent × 2	
12	Insufficient medical treatment for pain	Talent × 4	Covered stent (Wallgraft) in left iliac artery
13	Ascending progression	Talent × 2	Talent abdominal aortouniliac endoprosthesis, talent occluder in right common iliac artery, right iliac-hypogastric Wallgraft and femoro-femoral bypass
14	Insufficient medical treatment for pain and BP	Talent × 2	Covered stent (Wallgraft) in right iliac artery
15	Ascending progression	Talent × 2	
16	Acute lower limb ischemia	Talent	Covered stent (Wallgraft) in left Iliac artery and right femoral thrombectomy
17	Insufficient medical treatment for pain and BP	Talent × 2	Covered stent (Wallgraft) in right renal artery and talent abdominal aortouniliac endoprosthesis with cross-over femoro-femoral bypass
18	Insufficient medical treatment for pain and BP in Marfan patient	Talent × 2	

The valiant endoprosthesis torsion was successfully treated, both technically and clinically, with a Bolton device.

Three postoperative acute renal failures were described, and no major neurological episode was observed. Mortality at 30 days was 0%, with two deaths at 46 and 55 days, which represents 11% rate of hospital mortality. The death of the patient which required an ascending aorta replacement was due to multiorgan failure during the postoperative period, while the patient who required a new intervention due to aortic rupture died due to the above mentioned hemorrhagic shock.

There was average follow-up of 43.1 months (standard deviation 41 and range 1.5–127). Cumulative survival at 30 months was 88%, and survival free of endoleaks at 24 months was 88%, while follow-up free of endoleaks at 36 months was 91%. Survival free of progression/relapse at 12 months was 83%, and follow-up free of progression/relapse at 12 months was 88% (Figure 4).

4. Conclusions

Current use of endoprostheses for complicated Type B aortic dissections seems to be quite established and supported by

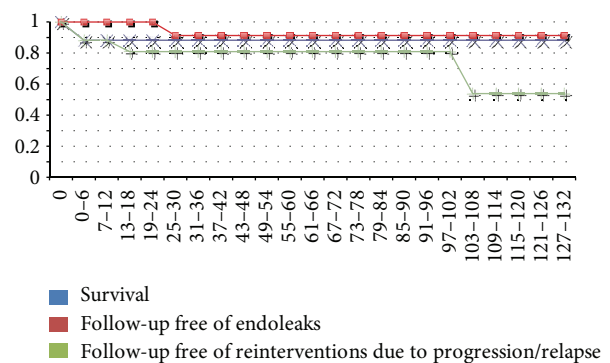


FIGURE 4: Survival and follow-up curves.

scientific evidence, with lower short-term mortality rates than the rest of alternative options [1, 6, 7, 10] and with medium-term studies showing good results under controlled conditions [10].

Our study, based on clinical experience, presents a realistic situation in one single center. We realise that we only

perform around six hundred arterial procedures, with sixty endovascular aortic repair annually. Despite its chronological bias and its limited sample size, it is in line with standardized publications, with hospital mortalities between 3 and 20% in international series and 11% in our data and with survival at one year and 5 years of 79% and 61% respectively, versus 88% in our series at 30 months [10, 17, 18].

The use of different models, from various manufacturers and even of different generations, is directly associated with the normal evolution during the last 10 years. However, all devices have the same limitation: their design. This design, targeted at aortic aneurysms, does not meet all needs for the correct treatment of dissections; therefore, they are used off-label [1, 3]. Until relatively recent times (2010), there were no devices designed and approved for dissections in Spain; therefore, results obtained can be improved, a priori, once these new specific devices are used [3, 19].

Indication is another relevant item. A high rate of insufficient medical treatment (61%) is observed as primary indication. Aggressive treatment for pain management and blood pressure control is not always enough. Pain represents a special problem. Its subjective and extremely personal nature may lead to a potential excess in therapeutic indication; if this was so, it would amount to 10% of the series in our case. However, we think that the implantation of endoprosthesis in these cases seems to be justified by the absence of clinical symptoms after the intervention, and the potential complications if not treated.

Regarding associated techniques, supraaortic trunks revascularization continues being a subject for debate. In the clinical practice guidelines by the "Society for Vascular Surgery," there are no clear premises about its indication. Revascularization is suggested if there is a left subclavian occlusion during implantation of the endoprosthesis, and previous routine revascularization is recommended if collateral circulation involvement is foreseen; in this case, assessment of the left vertebral artery is very important [20]. All this is part of a cautious attitude, considering the devastating nature of potential neurological complications, and the low rates of complications with the preservation of subclavian antegrade flow [15], rationale we support and apply in our center.

Regarding endoleaks and reinterventions, we have observed in our series an aggressive behavior difficult to control. There are multiple reasons for this: on one hand, the characteristics of the disease and the patients and on the other hand, the use of non-specific endoprostheses on difficult anatomies. Therefore, we consider close follow-up of these patients is necessary, as well as a conservative attitude, unless there are life-threatening events for the patient [7, 21, 22].

For all the above mentioned, we consider that endovascular repair with endoprosthesis is a valid treatment, with acceptable mortality rate and follow-up without complications, even though the evolution of its complications is usually unpredictable and catastrophic and therefore represents a challenge for surgeons.

Conflict of Interests

The authors declare that there is no conflict of interests regarding the publication of this paper.

References

- [1] L. F. Hiratzka, G. L. Bakris, J. A. Beckman et al., "2010 ACCF/AHA/AATS/ACR/ASA/SCA/SCAI/SIR/STS/SVM guidelines for the diagnosis and management of patients with thoracic aortic disease: a report of the American college of cardiology foundation/American heart association task force on practice guidelines," *Circulation*, vol. 121, no. 13, pp. e266–e369, 2010.
- [2] S. Svensjö, H. Bengtsson, and D. Bergqvist, "Thoracic and thoracoabdominal aortic aneurysm and dissection: an investigation based on autopsy," *British Journal of Surgery*, vol. 83, no. 1, pp. 68–71, 1996.
- [3] V. Rimbau-Alonso, C. García-Madrid, I. Murillo-Barrios, and J. Muntañá-Figols, "Cirugía endovascular de la disección aguda tipo B," *Angiología*, vol. 58, supplement 1, pp. S69–S81, 2006.
- [4] P. G. Hagan, C. A. Nienaber, E. M. Isselbacher et al., "The International Registry of Acute Aortic Dissection (IRAD): new insights into an old disease," *Journal of the American Medical Association*, vol. 283, no. 7, pp. 897–903, 2000.
- [5] S. R. Lauterbach, R. P. Cambria, D. C. Brewster et al., "Contemporary management of aortic branch compromise resulting from acute aortic dissection," *Journal of Vascular Surgery*, vol. 33, no. 6, pp. 1185–1192, 2001.
- [6] Z. Hao, W. Zhi-Wei, Z. Zhen, H. Xiao-Ping, W. Hong-Bing, and G. Yi, "Endovascular stent-graft placement or open surgery for the treatment of acute type B aortic dissection: a meta-analysis," *Annals of Vascular Surgery*, vol. 26, no. 4, pp. 454–461, 2012.
- [7] C. A. Nienaber and J. T. Powell, "Management of acute aortic syndromes," *European Heart Journal*, vol. 33, no. 1, pp. 26–35, 2012.
- [8] L. G. Svensson, N. T. Kouchoukos, D. C. Miller et al., "Expert consensus document on the treatment of descending thoracic aortic disease using endovascular stent-grafts," *The Annals of Thoracic Surgery*, vol. 85, no. 1, pp. S1–S41, 2008.
- [9] S. D'Souza, A. Duncan, F. Aguila et al., "TEVAR for non-aneurysmal thoracic aortic pathology," *Catheterization and Cardiovascular Interventions*, vol. 74, no. 5, pp. 783–786, 2009.
- [10] M. P. Ehrlich, H. Rousseau, R. Heijmen et al., "Midterm results after endovascular treatment of acute, complicated type B aortic dissection: the talent thoracic registry," *The Journal of Thoracic and Cardiovascular Surgery*, vol. 145, no. 1, pp. 159–165, 2013.
- [11] M. F. Fillingier, R. K. Greenberg, J. F. McKinsey, and E. L. Chaikof, "Reporting standards for thoracic endovascular aortic repair (TEVAR)," *Journal of Vascular Surgery*, vol. 52, no. 4, pp. 1022–1033, 2010.
- [12] M. Brandt, K. Hüssel, K. P. Walluscheck, A. Böning, A. Rahimi, and J. Cremer, "Early and long-term results of replacement of the descending aorta," *European Journal of Vascular and Endovascular Surgery*, vol. 30, no. 4, pp. 365–369, 2005.
- [13] I. Y. P. Wan, G. D. Angelini, A. J. Bryan, I. Ryder, and M. J. Underwood, "Prevention of spinal cord ischaemia during descending thoracic and thoracoabdominal aortic surgery," *European Journal of Cardio-Thoracic Surgery*, vol. 19, no. 2, pp. 203–213, 2001.

- [14] J. S. Matsumura and A. Z. Rizvi, "Left subclavian artery revascularization: society for vascular surgery practice guidelines," *Journal of Vascular Surgery*, vol. 52, no. 4, pp. 65S–70S, 2010.
- [15] M. F. Conrad and R. P. Cambria, "Aortic dissection," in *Rutherford's Vascular Surgery*, J. L. Cronenwett and W. Johnston, Eds., pp. 2090–2109, Elsevier, Philadelphia, Pa, USA, 7th edition, 2010.
- [16] R. Bellomo, C. Ronco, J. A. Kellum, R. L. Mehta, and P. Palevsky, "Acute renal failure—definition, outcome measures, animal models, fluid therapy and information technology needs: the Second International Consensus Conference of the Acute Dialysis Quality Initiative (ADQI) Group," *Critical Care*, vol. 8, no. 4, pp. R204–R212, 2004.
- [17] M. Schoder, M. Czerny, M. Cejna et al., "Endovascular repair of acute type B aortic dissection: long-term follow-up of true and false lumen diameter changes," *Annals of Thoracic Surgery*, vol. 83, no. 3, pp. 1059–1066, 2007.
- [18] H. Eggebrecht, C. A. Nienaber, M. Neuhäuser et al., "Endovascular stent-graft placement in aortic dissection: a meta-analysis," *European Heart Journal*, vol. 27, no. 4, pp. 489–498, 2006.
- [19] C. A. Nienaber, S. Kische, and H. Ince, "Thoracic aortic stent-graft devices: problems, failure modes, and applicability," *Seminars in Vascular Surgery*, vol. 20, no. 2, pp. 81–89, 2007.
- [20] S. Chen, F. Yei, L. Zhou et al., "Endovascular stent-grafts treatment in acute aortic dissection (type B): clinical outcomes during early, late, or chronic phases," *Catheterization and Cardiovascular Interventions*, vol. 68, no. 2, pp. 319–325, 2006.
- [21] J. Y. Won, S.-H. Suh, H.-K. Ko et al., "Problems encountered during and after stent-graft treatment of aortic dissection," *Journal of Vascular and Interventional Radiology*, vol. 17, no. 2, part 1, pp. 271–281, 2006.
- [22] M. G. M. Steinbauer, A. Stehr, K. Pfister et al., "Endovascular repair of proximal endograft collapse after treatment for thoracic aortic disease," *Journal of Vascular Surgery*, vol. 43, no. 3, pp. 609–612, 2006.

