Hindawi Publishing Corporation
Advances in Orthopedic Surgery
Volume 2014, Article ID 891875, 6 pages
http://dx.doi.org/10.1155/2014/891875

Clinical Study

A Novel Technique for Proximal Hamstring Tendon Repair: High Reoperation Rate in a Series of 56 Patients

William Blakeney,[1,2] Simon Zilko,[1] Wael Chiri,[1] and Peter Annear[2,3]

[1] *Department of Orthopaedics, Royal Perth Hospital, Perth, WA 6000, Australia*
[2] *Department of Orthopaedics, Mount Hospital, Perth, WA 6000, Australia*
[3] *Perth Orthopaedics and Sports Medicine Centre, Perth, WA 6005, Australia*

Correspondence should be addressed to William Blakeney; blakeney@gmail.com

Received 11 September 2013; Revised 17 November 2013; Accepted 1 December 2013; Published 17 February 2014

Academic Editor: Federico Canavese

This investigation looked at functional outcomes, following a novel technique of surgical repair using table staples. Patients underwent surgery for proximal hamstring rupture with table staples used to hold the tendon reapproximated to the ischial tuberosity. Functional outcomes following surgery were assessed. We also used a combined outcome assessment measure: the Perth Hamstring Assessment Tool (PHAT). A total of 56 patients with a mean age of 51 (range 15–71) underwent surgery. The mean follow-up duration was 26 months (range 8–59 months). A large proportion of patients (21/56, 37.5%) required reoperation for removal of the staple. Patients that did not require removal of the table staple did well postoperatively, with low pain scores (0.8–2 out of 10) and good levels of return to sport or running (75.8%). Those that required removal of the staple had a significantly lower PHAT score prior to removal, 47.8, but this improved markedly once the staple was removed, with a mean of 77.2 ($P < 0.001$). Although our patients achieved similar outcomes in terms of pain and function, we thought the reoperation rate was unacceptably high. We would not recommend proximal hamstring tendon repair using this technique.

1. Introduction

Proximal hamstring rupture from the ischial tuberosity occurs acutely following an injury involving sudden hip flexion with an extended knee. It is often seen in athletes with a peak incidence in middle-aged individuals [1]. Surgical repair results in significantly better outcomes, including greater rate of return to sport, greater strength/endurance, and better subjective outcomes than nonsurgical treatment [2]. There have been a number of proposed surgical methods for the treatment of proximal hamstring injuries. A well-described technique is using bioabsorbable or metal suture anchors [3]. Some surgeons use suture-only fixation with or without bone tunnels. Others have used headless metal interference screw fixation with Achilles allograft reconstruction [4]. A systematic review which included 298 patients found a rerupture rate of 2.7% [2].

Table staples have been extensively used in the past for ligament repairs and reconstructions. They have been used to augment Anterior Cruciate Ligament (ACL), Medial Collateral Ligament, and posterolateral corner repairs [5–7]. Repair of proximal hamstring tendon ruptures with table staples has not, that we are aware of, been reported in the literature.

The trial surgeon (PA) performed a number of repairs of proximal hamstring tendons with table staples over a two-year period. It was hoped that this technique would increase the strength of surgical repair and decrease rerupture rates. We noticed a high number of patients following surgery with ongoing localised pain related to the table staple. Many of these required surgery to remove the staple. We did a retrospective review of a series of proximal hamstring injuries that had repairs with table staples.

2. Methodology

2.1. Eligibility Criteria. Symptomatic patients, between the ages of 15 and 75, with MRI confirmed injuries of the proximal hamstring origin who were fit and willing to undergo

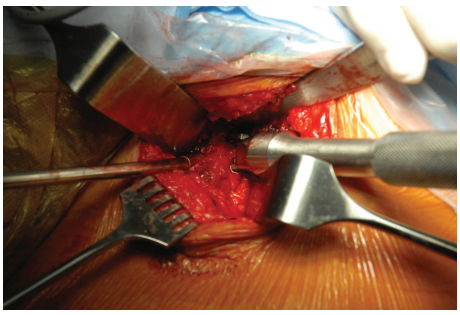

Figure 1

surgical repair were included. This included acute incomplete ruptures with retraction >2 cm or chronic incomplete ruptures which remained symptomatic. Chronic ruptures were defined as those presenting later than 3 months from injury (see Figure 6: treatment algorithm).

2.2. Setting and Location. The trial was undertaken at one metropolitan tertiary care hospital.

2.3. Surgical Procedure. The patient under general anaesthetic is positioned prone on the operating table. The affected limb is prepped and draped, allowing access to the surgical site and the ability to flex the knee. In the setting of an acute tear, a transverse incision of 6–8 cm in the line of the gluteal fold was used. With chronic tears or late presentations with retraction of the tendon, a longitudinal incision extending distally from the ischial tuberosity for 6–8 cm was used.

After dissection through superficial layers, the gluteus maximus muscle was elevated superiorly with a broad retractor, and the deep fascia was incised vertically. The sciatic nerve was identified and dissected free of any surrounding scar tissue. Often, especially in the chronic presentations, the sciatic nerve is densely adherent to the retracted tendon. Once the sciatic nerve was protected, the hamstring tendons were identified, debrided, and mobilised.

The ischial tuberosity is debrided to provide a fresh bed for the tendons. If the tendon ends were easily reapproximated to the ischial tuberosity, they were then held in place with stainless steel table staples. A medium-sized 4-prong staple was used for the semitendinosus and biceps femoris attachment and a small 2-prong staple for the semimembranosus attachment (see Figure 1). In patients with smaller anatomy such that the ischial tuberosity could not accommodate 2 staples, a single 4-prong staple was used to attach all tendons (see Figure 2). Where only one tendon was torn a single 2-prong staple was used. Patients with retracted tendons that were difficult to approximate to the ischial tuberosity had number 5 braided nonabsorbable sutures passed through the hamstring tendons and then through drilled bone tunnels in the ischial tuberosity. The tendons were then reapproximated and held with the table staples. The sutures were tied over the table staples.

Wound closure was performed in layers with a subcuticular skin suture. All patients followed a standard postoperative rehabilitation regime.

Table 1: PHAT scoring guide.

Category	Method	Score
(1) Pain (×3)	Patient marks on line	10-Ans
(2) Maximum times (×3)	0 mins	0
	1–10 mins	5
	11–30 mins	8
	31–60 mins	12
	>60 mins	15
(3) Activity grade	Full sport	15
	Can run, Cannot play full sport	10
	Cannot run pain free	5
	Pain with walking	0
(4) Local tenderness	None	10
	Mild	5
	More than mild	0
Maximum points		100

Figure 2

2.4. Outcomes. The main outcomes assessed were functional outcomes: rates of return to sport, return to other activities (sitting, driving a car, and running), and pain scores using a visual analog scale.

We created a combined outcome assessment measure: the Perth Hamstring Assessment Tool (see the appendix). The Perth Hamstring Assessment Tool (PHAT) is a score that looks at a range of functional outcomes. It includes pain scores at rest, sitting, and stretching out. It looks at return to activities from sitting, to driving a car, to running, and full preinjury level of sport. It provides a score out of 100, with a higher score corresponding to a higher function (see Table 1). We looked at total score as well as the individual components. Patients that required a second procedure were scored both before the surgery and then after surgery.

We also assessed our complications: in particular, the number of patients requiring a second surgical procedure for removal of table staple. In patients that had repeat surgery we

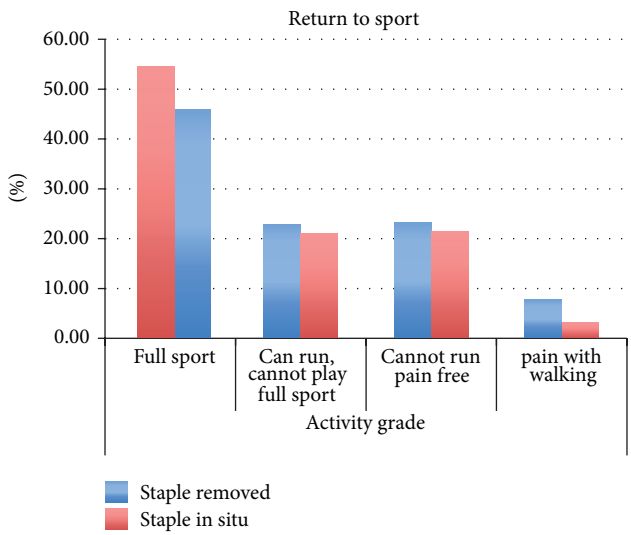

Figure 3

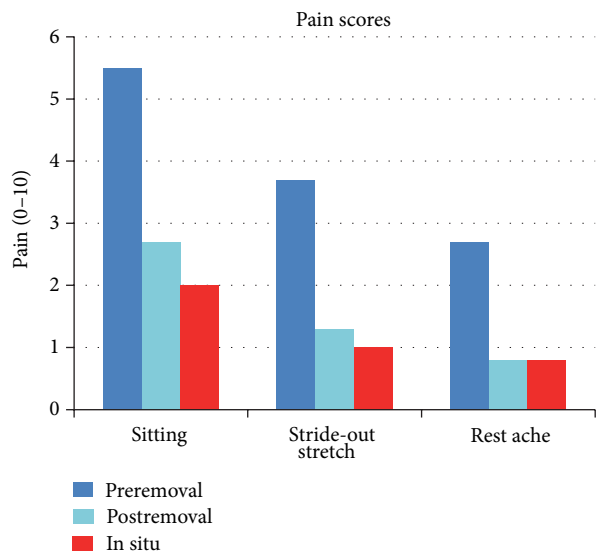

Figure 4

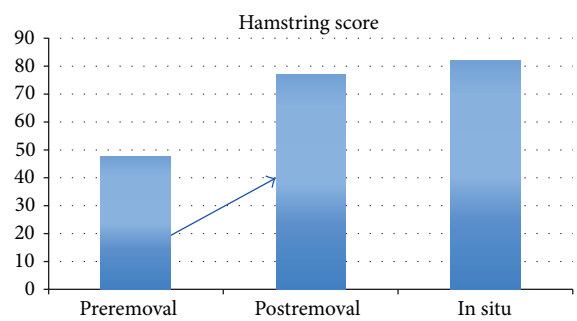

Figure 5

also looked at the state of repair of the proximal hamstring repair at the time of surgery and whether the staple was solid or had loosened. These outcomes were assessed by review of patient's clinical notes. Other complications were also noted.

2.5. Statistical Methods. The statistical analysis used independent Mann-Whitney U test to compare differences between mean values between patients requiring reoperation and those who did not. Wilcoxon T test was used to compare difference in means between patients' scores before and after reoperation. Fisher exact test was used to determine any significant difference in reoperation rate between the different staple sizes. A P value <0.05 was used to determine significance.

3. Results

A total of 56 patients underwent proximal hamstring tendon repair. The mean age was 51 (range 15–71) and there were 29 females and 27 males. The mean follow-up was 26 months (range 8–59 months). Thirty patients had an acute rupture and 26 patients had chronic ruptures. Only 46 of 56 patients (82.1%) completed the PHAT Questionnaire. All patients' clinical notes were available for review. Of the 10 patients that did not complete the questionnaire 5 had the staple in-situ and 5 had the staple removed.

Seventy-four point four per cent of patients (34/46) return to full sport or running. There was a higher number of patients that returned to sport in the group that did not require reoperation (see Figure 3). Only 2 of 46 patients (4.35%) had ongoing pain with walking.

A similar trend was seen with pain scores (at rest, with stride-out stretch, and sitting) significantly higher in those that required staple removal compared to those with the staple in situ ($P < 0.001$). These reduced to similar levels after staple removal, with no significant difference seen in mean pain scores in those with staple removed and those not requiring removal ($P = 0.517$) (see Figure 4).

The mean PHAT Score in all patients was 80.6. Patients with the staple left in situ had a mean score of 82.3. Those that required removal of the staple had a significantly lower score prior to removal, 47.8, but this improved markedly once the staple was removed, with a mean of 77.2 ($P < 0.001$) (see Figure 5). There was no significant difference in the PHAT Score between those that still had the staple in situ and those that had had it removed ($P = 0.38$).

Of the 56 patients, 21 (37.5%) underwent reoperation for removal of the staple. Of the 35 that have not had a reoperation, a further 4 are awaiting surgery to have the staple removed. Seven patients had a single 2-prong staples inserted (of which one required reoperation for removal), 29 had a single 4-prong staple inserted (of which 12 were removed), and 19 had both a 4-prong and a 2-prong staple, inserted (of which 8 were removed). There was no significant difference in the incidence of reoperation between any of the staple combinations ($P = 0.43$). At the time of surgery, the staple was noted to be loose in 5 cases, but in only one case had the repair failed when the staple loosened requiring rerepair. In

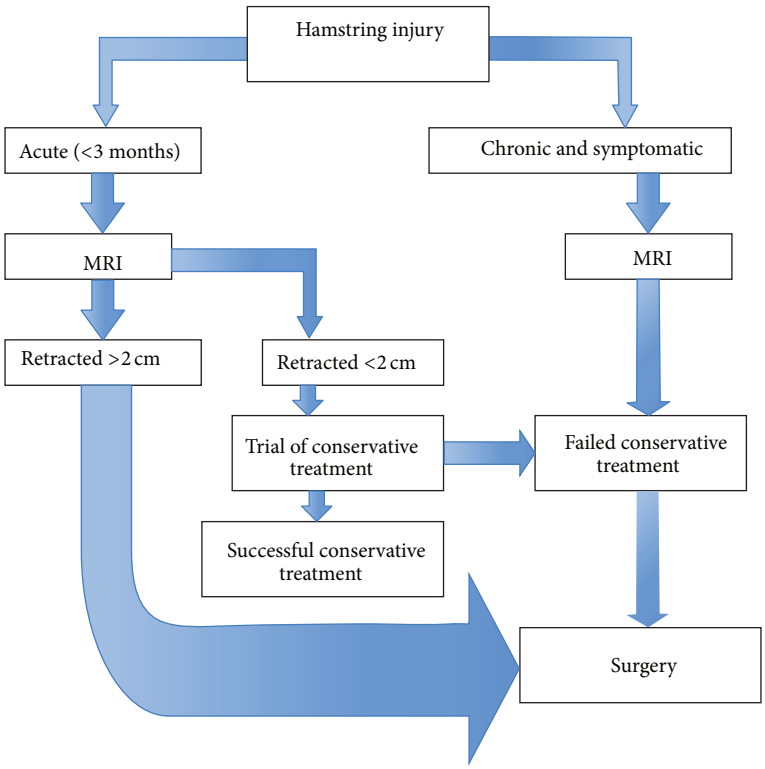

Figure 6: Treatment algorithm.

4 cases the surgeon noted that the staple was proud or had backed out. In the remaining cases, the staple was still in a good position.

Five other complications were seen overall. There were three deep infections, which required return to theatre for washout and debridement. One of these deep infections followed the second operation for removal of staple. There was one wound dehiscence.

4. Discussion

This study assessed patient functional outcomes following surgery for proximal hamstring tendon rupture. Patients that did not require removal of the table staple did well postoperatively, with low pain scores (0.8–2 out of 10) and good levels of return to sport or running (75.8%). Patients that required removal of table staple went on to achieve similar levels of return to sport and running (69.2%), as well as similarly low pain scores (0.8–2.7 out of 10).

A large proportion of patients (21/56, 37.5%) that underwent proximal hamstring repair with a table staple required reoperation for removal of the staple. This is an unacceptably high reoperation rate, with the inherent risks of a second operation. Most of the patients that required reoperation had localized pain over the ischial tuberosity and increased pain with all activities. Some of these problems were due to loosening of the staple or backing out. Some of these problems were due to loosening of the staple or backing out. In some patients the staple was still in the original position, suggesting the anatomy of the ischial tuberosity must not be amenable to table staples.

We find the Perth Hamstring Assessment Tool useful for assessing patients' pain and function after hamstring repair. High scores were achieved in both patients that had the staple left in situ (mean 82.3) and those that had the staple removed (mean 77.2). It is a useful tool for assessing those that require removal of the staple, with preremoval scores very low (mean 47.8).

A systematic review by Harris et al. in 2011 on the treatment of proximal hamstring ruptures, showed significantly better subjective outcomes ($P < 0.05$), return to sport ($P < 0.001$), and reduced risk of rerupture ($P < 0.05$) in patients treated surgically compared with patients treated nonsurgically [2]. Surgical techniques included bioabsorbable or metal suture anchors, suture only fixation; reconstruction plate internal fixation for bony avulsions, and Achilles tendon allograft augmentation. All surgical techniques were grouped together and not compared.

A 2008 study by Wood et al. looked at 72 consecutive reconstructions using three suture anchors. At the time of the six-month postoperative check, fifty-seven patients (80%) had returned to their preinjury level of sports [8].

Another 2008 study by Sallay et al. reported on 25 patients that underwent primary repair of proximal hamstring tendon to the ischium with two to four titanium suture anchors [9]. At a mean of 53 months follow-up, 23 of 25 patients (92%) reported minimal to no pain. Four patients reported increased stiffness following sports and 2 patients reported

constant stiffness. There were no obvious reruptures or failed repairs.

Folsom and Larson reported on repair of 26 acute or chronic proximal hamstring tears. The acute tears were repaired using suture anchors [4]. The chronic tears were repaired using Achilles allograft sutured to the proximal hamstring tendons and then fixed to the ischium with a metal interference screw. At a mean follow-up of 20 months, 20% reported ongoing pain and 76% had returned to sporting activities. There was no statistically significant difference between the chronic and acute groups. However, numbers in the chronic group were low (5 patients) with low power to detect a difference. There were 3 major complications in the acute group: one rerupture at 4 months, one patient developed complex regional pain syndrome and one deep infection.

Orava and Kujala reported on 8 proximal hamstring ruptures repaired with heavy nonabsorbable sutures through drilled bone tunnels [10]. Two of these repairs were augmented with grafts from plantaris tendon and facia lata. At a mean of 5.7 years follow-up only 62% reported good overall outcome. Those operated on within 2 months of the injury did better than those operated on later.

Brucker and Imhoff reported on the functional outcomes of 8 patients that underwent surgical repair for proximal hamstring rupture [11]. They used a suture anchor repair with a mean of 3.5 anchors. At a mean of 20 months follow-up, half of the patients (4 of 8) reported localised pain and discomfort and 75% (6 of 8) had returned to sport. One patient required a second operation following pull-out of a metal suture anchor.

A recent trial by Birmingham et al. looked at 9 acute and 14 chronic repairs using suture anchors, with the average period of follow-up 43.3 months [12]. Twenty-one of twenty-three patients reported returning to activity at an average of 95% of their preinjury activity level at an average of 9.8 months. Eighteen patients reported excellent results, four, good results, and one, fair results.

The functional results of patients in the above studies are similar to the patients in this study, when looking at those who did not require staple removal and those who did once the staple was removed. One limitation of this study is that the Perth Hamstring Assessment Tool is not a validated outcome measure. There is no validated outcome measure, to our knowledge, that is used for this patient population. We have found it a useful tool for identifying patient progress following surgery. Taking the components of the score individually gives us many of the important clinical outcomes that we look for following proximal hamstring repair.

This study is one of the largest series of proximal hamstring tendon repairs in the literature. Although our patients achieved similar outcomes in terms of pain and function, we thought the reoperation rate was unacceptably high. The study surgeon has now changed operative fixation technique, using suture anchors as described by Carmichael et al. [3]. Our future direction is to compare the patients operated with this new technique with the patient population in this study. We are in the process of validating the Perth Hamstring Assessment Tool.

Appendix

Perth Hamstring Assessment Tool

(1) Choose a number between 0 and 10 which best describes your pain.

(i) When Sitting:

0	1	2	3	4	5	6	7	8	9	10
(No Pain)	–	–	–	–	–	–	–	–	–	(Unbearable Pain)

(ii) With Stride-out Stretch:

0	1	2	3	4	5	6	7	8	9	10
(No Pain)	–	–	–	–	–	–	–	–	–	(Unbearable Pain)

(iii) At Rest:

0	1	2	3	4	5	6	7	8	9	10
(No Pain)	–	–	–	–	–	–	–	–	–	(Unbearable Pain)

(2) What is the maximum amount of time for which you can perform these activities without resting?

(i) Sitting in a chair:

0 mins ☐
1–10 mins ☐
11–30 mins ☐
31–60 mins ☐
>60 mins ☐

(ii) Driving a car:

0 mins ☐
1–10 mins ☐
11–30 mins ☐
31–60 mins ☐
>60 mins ☐

(iii) Running:

0 mins ☐
1–10 mins ☐
11–30 mins ☐
31–60 mins ☐
>60 mins ☐

(3) What best describes your current level of activity?

Full Sport ☐
Can run, Can't play full sport ☐
Can't run pain free ☐
Pain with waking ☐

(4) Do you have any local tenderness over your hamstring?

None ☐
Mild ☐
More than Mild ☐

Conflict of Interests

The authors declare that there is no conflict of interests regarding the publication of this paper.

Acknowledgment

No financial support has been received in the production of this paper.

References

[1] S. Cohen and J. Bradley, "Acute proximal hamstring rupture," *Journal of the American Academy of Orthopaedic Surgeons*, vol. 15, no. 6, pp. 350–355, 2007, (Review).

[2] J. D. Harris, M. J. Griesser, T. M. Best, and T. J. Ellis, "Treatment of proximal hamstring ruptures a systematic review," *International Journal of Sports Medicine*, vol. 32, no. 7, pp. 490–495, 2011.

[3] J. Carmichael, I. Packham, S. P. Trikha, and D. G. Wood, "Avulsion of the proximal hamstring origin. Surgical technique," *The Journal of Bone and Joint Surgery. American Volume*, vol. 91, supplement 2, pp. 249–256, 2009.

[4] G. J. Folsom and C. M. Larson, "Surgical treatment of acute versus chronic complete proximal hamstring ruptures: results of a new allograft technique for chronic reconstructions," *American Journal of Sports Medicine*, vol. 36, no. 1, pp. 104–109, 2008.

[5] J. J. Lee, K. Otarodifard, B. J. Jun, M. H. McGarry, G. F. Hatch III, and T. Q. Lee, "Is supplementary fixation necessary in anterior cruciate ligament reconstructions?" *American Journal of Sports Medicine*, vol. 39, no. 2, pp. 360–365, 2011.

[6] N. Adachi, M. Ochi, M. Deie, Y. Izuta, and H. Kazusa, "New hamstring fixation technique for medial collateral ligament or posterolateral corner reconstruction using the mosaicplasty system," *Arthroscopy*, vol. 22, no. 5, pp. 571. e1–571. e3, 2006.

[7] P. F. Hill, V. J. Russell, L. J. Salmon, and L. A. Pinczewski, "The influence of supplementary tibial fixation on laxity measurements after anterior cruciate ligament reconstruction with hamstring tendons in female patients," *American Journal of Sports Medicine*, vol. 33, no. 1, pp. 94–101, 2005.

[8] D. G. Wood, I. Packham, S. P. Trikha, and J. Linklater, "Avulsion of the proximal hamstring origin," *Journal of Bone and Joint Surgery. American Volume*, vol. 90, no. 11, pp. 2365–2374, 2008.

[9] P. I. Sallay, G. Ballard, S. Hamersly, and M. Schrader, "Subjective and functional outcomes following surgical repair of complete ruptures of the proximal hamstring complex," *Orthopedics*, vol. 31, no. 11, p. 1092, 2008.

[10] S. Orava and U. M. Kujala, "Rupture of the ischial origin of the hamstring muscles," *American Journal of Sports Medicine*, vol. 23, no. 6, pp. 702–705, 1995.

[11] P. U. Brucker and A. B. Imhoff, "Functional assessment after acute and chronic complete ruptures of the proximal hamstring tendons," *Knee Surgery, Sports Traumatology, Arthroscopy*, vol. 13, no. 5, pp. 411–418, 2005.

[12] P. Birmingham, M. Muller, T. Wickiewicz, J. Cavanaugh, S. Rodeo, and R. Warren, "Functional outcome after repair of proximal hamstring avulsions," *Journal of Bone and Joint Surgery. American Volume*, vol. 93, no. 19, pp. 1819–1826, 2011.