Hindawi Publishing Corporation
ISRN Plastic Surgery
Volume 2014, Article ID 969420, 10 pages
http://dx.doi.org/10.1155/2014/969420

Clinical Study

Comparison between Peroneus Brevis Flap and Reverse Sural Artery Flap for Coverage of Lower One-Third Leg Defects

Ramesha Kunchekoppal Thammannagowda,[1] Ghuge Ashish,[1] Shankarappa Mudukappa,[1] Dehpande Pushkar,[1] and Abhishek Vijayakumar[2,3]

[1] *Department of Plastic Surgery, Victoria Hospital, BMCRI, Bangalore 560062, India*
[2] *Bangalore Medical College and Research Institute (BMCRI) and Rajiv Gandhi University of Health Sciences (RGUHS), Bangalore, Karnataka 560062, India*
[3] *128 Vijay Doctors Colony, Konanakunte, Bangalore, Karnataka 560062, India*

Correspondence should be addressed to Abhishek Vijayakumar; abhishekbmc@yahoo.co.in

Received 6 December 2013; Accepted 30 December 2013; Published 3 March 2014

Academic Editors: H. Mizuno and C. Shipkov

Posttraumatic wounds and soft tissue defects in the distal third of the leg and ankle remain a challenge. Defects at this site will often require flap cover. Free flap is ideal for these defects and gives good results but with its own limitations. The reverse sural artery flap (RSAF) and distal peroneus brevis flap (DPBF) have gained popularity for lower third leg defects among surgeons. We did a retrospective study on 64 patients admitted between 2011 and 2013 with posttraumatic moderate size defects of lower one-third leg who underwent RSAFs and DPBFs. These patients were followed up in the immediate and late postoperative period for complications and outcome assessment. The average surface area covered by DPBF was 27 cm^2 and by RSAF was 38 cm^2. Both flaps gave a good functional outcome. DPBF has better aesthetic appearance at donor site and recipient site, with the advantages of ease of surgery, speedy recovery, less hospital stay, and no donor site morbidity; DPBFs appear to be a preferred choice for moderate size lower third leg defects. RSAFs should be chosen over DPBFs for defects in medial malleolus and larger size defects.

1. Introduction

Complex wounds and soft tissue defects in the distal third of the leg and ankle remain a difficult problem to solve. Several reconstructive procedures have been proposed to repair soft tissue defects in these regions, including local cutaneous flaps, pedicled fasciocutaneous flaps, pedicled muscle flaps, and free flaps. An ideal flap should be technically easy to harvest and reliable and have a high success rate with minimal donor site morbidity. Free-tissue transfer could be the treatment of choice, but it requires a team approach and accompanies long operative time, donor morbidity, and a risk of complete failure. Also nonavailability of microsurgical expertise and facility at peripheral centers, high volume trauma centers, the cost involved, and, sometimes, the patient-related factors may preclude the option of free flap. Although free-tissue transfer plays an important role in limb salvage, a thorough understanding and applications of regional flap designs can sometimes provide easier and more cost-effective alternatives for soft tissue coverage of the injured lower extremity [1]. Two flaps have emerged popular among surgeons due to their versatility, ease of mobilization, and reliability, the reverse sural artery flap and peroneus brevis flap.

Randomized control trials in reconstructive surgery are a challenge due to varied presentation, limited number of cases, and also surgeon preference and experience. The present retrospective study compares reverse sural artery flap and distally based peroneus brevis flap in reconstruction of distal lower limb defects of moderate size.

2. Materials and Methods

A nonrandomized prospective and retrospective study of 64 patients admitted between 2011 and 2013 was done. Patients

with posttraumatic moderate size defects of lower one-third leg requiring flap cover for exposed bone, tendon, and implant were included in the study. 32 patients underwent RSAFs and 32 patients underwent PBFs. Lower third leg defects were classified as follows.

Anatomical distribution:

(1) lower one-third tibia,
(2) medial malleolus,
(3) lateral malleolus,
(4) anterior ankle joint,
(5) tendo achilles.

Area:

(1) less than 20 cm^2: small size,
(2) 20 to 63 cm^2:moderate size,
(3) more than 63 cm^2: large defects.

We included patients with moderate size defects in our study, wherein the patients in two groups were made comparable by same site selection, matching range of area, and similar age group. Flap selection was random and left to surgeon preference. Data was collected on a proforma including information regarding the patient's gender, age, occupation, vascularity, and wound characteristics, including etiology, site, size, and depth.

Routine investigations included full laboratory investigations, fasting and postprandial glucose level, and plain X-rays. All patients underwent hand held Doppler evaluation of perforator to rule out atherosclerosis. Patients were operated under regional anaesthesia. Postoperatively patients received antibiotics for five days and adequate analgesia. Flap was assessed daily and first dressing was done on day five of surgery. Patients were discharged once flap and split skin grafting were healthy on assessment after first dressing and subsequent dressings. Patients were followed up twice weekly for the first month and then once a month for six months.

Distally based peroneus brevis flap was first described by Mathes and Nahai [2] and further characterized in detail by Eren et al. [3] and Yang et al. [4].

2.1. Surgical Anatomy

2.1.1. Flap Anatomy. The peroneus brevis is a thin, fusiform muscle, which lies in the lateral compartment of the leg. It takes origin from the fibula, anterior intermuscular septum, and posterior intermuscular septum. It arises from the distal two-thirds of the leg and lies deep to the peroneus longus muscle belly. It runs next to the fibula, deep to the tendon of the peroneus longus. The peroneus brevis tendon inserts distally on the styloid process at the base of the fifth metatarsal. The peroneus brevis muscle is innervated by the musculocutaneous branches of the common peroneal nerve, which arise from L4 and 5 and S1. The Blood supply to the peroneal muscles arises from contributions from the peroneal artery, anterior tibial artery, and perforators from the posterior tibial artery.

2.1.2. Operative Technique. After spinal anaesthesia, patient is placed in supine position with 60 degree knee flexion and ankle in plantar flexion and tourniquet is raised. Wound is debrided. Incision is taken 1-2 cm posterior to the fibular axis. Deep fascia is cut to expose peroneal compartment. Peroneus longus is visible. Peroneus longus is dissected off the underlying peroneus brevis muscle. The peroneus brevis muscle flap is raised from proximal to distal off its fibular attachment up to the constant distal perforator is identified or up to 6 cm from lateral malleolus. For defects over lower one third tibia (LOTT) and anterior ankle, peroneus brevis muscle was tunneled by creating a subcutaneous plane (Figure 1). For defects over lateral malleolus, the skin bridge was incised and lap inset was given. Flap was covered with split skin grating (Figure 8).

2.2. RSAFs

2.2.1. Flap Anatomy. The sural artery arises from the popliteal artery. It joins the sural nerve coursing between the two heads of the gastrocnemius and follows the lateral edge of the Achilles tendon. The sural artery is intimately connected with the sural nerve and plays an important role in supplying the skin of the lower and middle posterior leg. A pair of concomitant veins travels with the sural artery. The sural nerve descends in close association with the lesser saphenous vein, coursing posterior to the lateral malleolus, to innervate the lateral side of the foot and the fifth toe. Approximately four to eight perforators arise from the fibular artery, pierce the crural fascia, and give rise to several branches that join adjacent perforators, forming an interconnecting vascular suprafascial plexus that extends from the proximal part of the leg to the posterior margin of the lateral malleolus. A larger perforator is located approximately 5 cm proximal to the lateral malleolus.

Flap Markings. Leg is divided into upper, middle, and lower one-third. Skin paddle is marked over the middle one-third. Axis of flap is from midpoint of popliteal fossa to midpoint of lateral malleolus and tendo achilles (Figure 2).

2.2.2. Surgical Technique. The surgical procedure is performed while the patient is under spinal anesthesia. The patient is placed in a prone position and the flap is raised under tourniquet control. The flap is outlined approximately at the junction of the two heads of the gastrocnemius. The precise location of the skin paddle depends on the length of pedicle required. The pivot point of the pedicle is about 5 cm proximal to the tip of the lateral malleolus. The line of incision is traced over the course of the sural nerve and lesser saphenous vein. The incision is started on the proximal edge of the flap and is continued until reaching the gastrocnemius. The fascia is fixed to the flap by a few separate sutures. At midcalf, the sural nerve, superficial sural artery, and lesser saphenous vein are easily identified, ligated, and included within the flap. The dissection is continued distally, and the fibroadipose tissue around the pedicle is preserved. The pedicle is 2 to 3 cm wide including the sural nerve with its superficial artery and lesser saphenous vein. The dissection of

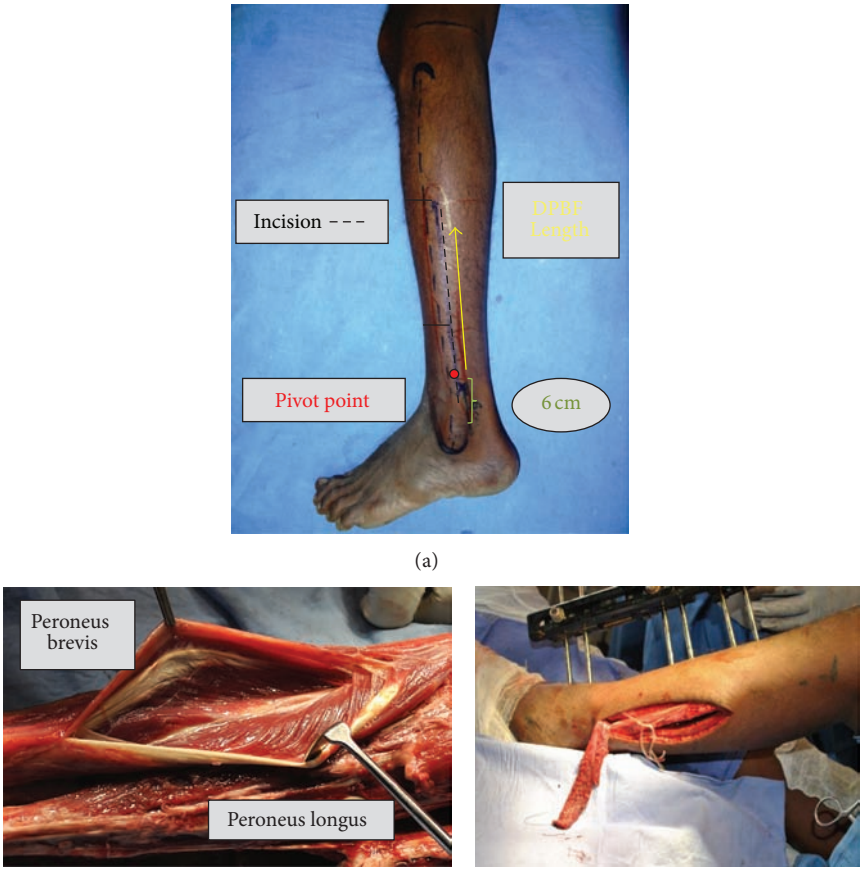

Figure 1: (a) Skin markings for distally based peroneus brevis flap. Incision is 1 cm posterior to fibular line. Pivot point is 6 cm proximal to lateral malleolus. (b) Peroneus brevis muscle identification. (c) Flap elevation from being proximal to distal.

the pedicle stops at the pivot point. The flap is transposed to the recipient site over the skin bridge. In few cases flap pedicle was islanded to donor site. The donor site is covered with a split thickness skin graft. The viability of the flap is assessed by its color and bleeding borders. The donor site is covered with a split thickness skin graft (Figures 3, 4, 5, 6, and 7).

3. Results

Thirty-two patients underwent PBFs and thirty two RSAFs. Mean age of patients of DPBFs was 35 years, (range 16–63), five were female patients and twenty-seven were male patients. Mean age of patients of RSAFs was 34 years, (range 14–56), four were female patients and twenty-eight were male patients.

Mean area of defect of all patients was 32 cm^2 with a range of 20 cm^2 to 60 cm^2. Patients of DPBF covered a defect with mean area of 27 cm^2 with a range of 20 cm^2 to 36 cm^2 while RSAFs group covered a mean defect area of 37 cm^2 (Table 1).

Duration of surgery included the time from elevation of flap to the end of procedure. Mean duration of surgery in DPBFs was sixty-five minutes with a range of fifty-two minutes to ninety-six minutes. Mean duration of surgery in RSAFs was one hundred thirty-five minutes with a range of one hundred fifteen minutes to one hundred ninety-five minutes.

Table 1: Patient characteristics.

Characteristics	Peroneus brevis flap	Reverse sural artery flap
Age (mean, range)	34.7 (16–63) yrs	33.6 (14–56) yrs
Sex		
Male	27	28
Female	5	4
Location of defect		
Lower one-third tibia	9	8
Medial malleolus	4	5
Lateral malleolus	10	9
Anterior ankle joint	5	5
Tendo achilles	4	5
Defect area cm^2	26.9 ± 4.4	37.5 ± 10

Venous congestion was more common ($P = 0.027$) with RSAFs (seven of thirty-two) as compared to DPBFs (two of thirty-two). Three out of the seven RSAFs with venous congestion had flap loss, while the other four RSAFs settled

Table 2: Outcome and complications.

Characteristics	Peroneus brevis flap	Reverse sural artery flap	Significance P value
Duration of surgery	65.4 ± 13 min	135.4 ± 20 min	0.000
Venous congestion	2	7	0.027
Significant flap loss (>10%)	2	6	0.128
Flap tip necrosis (<10%)	5	6	0.375
Total flap Loss	0	0	—
Split thickness skin graft loss over flap	4	0	0.000
Donor site complication	1	6	0.000
Duration of hospital stay	6.9 ± 1.3 days	9.8 ± 2.8 days	0.000
Return to daily activities	15.7 ± 2.1 days	25.1 ± 4.2 days	0.000

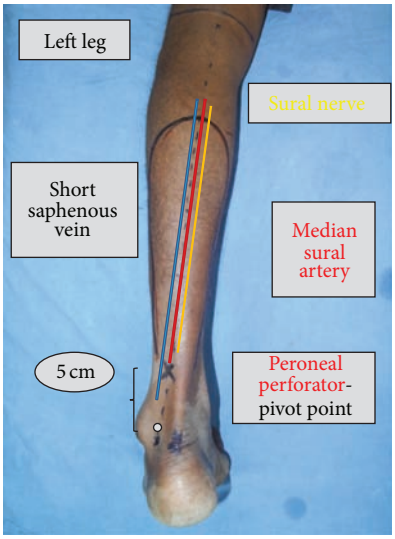

Figure 2: Skin markings for reverse sural artery flap. Axis of flap lies over short saphenous vein. Standard flap skin paddle is planned in middle third of leg as per defect size. Flap may be pedicled or islanded. Pivot point is 5 cm proximal to lateral malleolus.

by day 4 of surgery with conservative management. Out of thirty-two patients who underwent DPBFs, five patients had Flap tip necrosis (<10% flap area) (Figure 10). None of these had bone or tendon exposure. Three patients were managed with regular dressings, while two patients were managed with regrafting. Out of thirty-two patients who underwent RSAFs, six patients had flap tip necrosis (<10% flap area) (Figures 11-12). Two of these patients were subjected to flap readvancement and reinset and four patients were managed with regular dressings. Significant flap loss (>10%) with exposure of tendon or bone was seen in two patients of DPBFs as compared to six patients of RSAFs, but it was not statistically significant ($P = 0.128$). One patient of DPBFs group with significant flap loss underwent transposition flap cover and one patient was on VAC dressing followed by split skin grafting. Two patients of RSAFs group with flap loss underwent flap cover (perforator flap and transposition flap). Two patients were on VAC dressing followed by split skin grafting. Two patients with small defect were managed with regular dressing and skin grafting. No patient in RSAFs or DPBFs suffered from total flap loss. Patchy skin graft loss at donor site requiring prolonged dressing was seen in six patients of RSAFs. One case had donor site wound dehiscence in DPBFs group which healed by secondary intention. Partial skin graft loss requiring regrafting over the DPBF was seen in four patients (Figure 9).

Mean duration of stay in hospital in DPBF group was seven days as compared to RSAFs of ten days. Time to return to routine activity was sixteen days in DPBFs as compared to twenty-five days for RSAFs (Table 2). On early and late followup in 13 cases of RSAFs the donor site scar appearance was aesthetically unpleasing, while in DPBF donor site scar was linear and acceptable. All patients of RSAFs had bulky flaps, and they demanded subsequent thinning procedures on followup, whereas in DPBFs the flap site there was autothinning by 3–6 months in most patients. RSAFs were divided under local anesthesia with flap thinning at six weeks. Skin graft color over flap was not a concern to most patients.

4. Discussion

Soft tissue defects of the lower third of the leg are difficult to reconstruct. Free flap is currently the treatment of choice for large soft tissue defects of the lower extremity and it solves the problem of donor site morbidity in the immediate vicinity of the flap. It is however a technically demanding procedure for surgeons with less microsurgical experience.

Our study compared distally based peroneus brevis muscle flap and reverse sural artery flap in reconstruction of lower third leg defects of moderate size. Mean age of patients in our study was 34 years which is less in comparison to other studies. As our centre caters more to trauma cases there were no cases of defects following tumor excision. Due to less number of cases of diabetes and peripheral vascular disease as comorbidity among patients these were excluded from study to make it more comparable among the flaps.

Fasciocutaneous or neurofasciocutaneous flaps from the leg are useful and versatile reconstructive options for patients with moderate sized soft tissue defects of the leg, ankle, and foot. In 1987 Ferreira et al. presented the concept of fasciocutaneous flap of the distal pedicle based on the inframalleolar perforators. Masquelet et al. [5] were the first to describe the vascularisation of the skin in the lower limb and the arteries which follow the trajectory of the peripheral nerves. The sural

(a) (b)

Figure 3: RSAF cover for defect over medial malleolus. RSAF is pedicled over the skin bridge. Donor site covered with split thickness skin graft.

(a) (b)

Figure 4: RSAF cover for defect over tendo achilles. RSAF is islanded by raising skin flaps. Donor site covered with split thickness skin graft.

nerve comes down the leg in close relationship with the short saphenous vein.

This nerve is supplied by the superficial sural artery in the proximal third of the calf and by fasciocutaneous branches arising from the peroneal artery in the distal half of the leg along the suprafascial course of the sural nerve. This sural artery anastomoses with the peroneal artery by means of 3–5 fasciocutaneous perforators which ensure adequate inverse irrigation of the flap. The peroneal artery supplies the sural nerve and venous anastomoses circulate along this artery to ensure venous return.

In 1994, Hasegawa et al. affirmed that the pivot point of the flap must be at least 5 cm above the tip of the lateral malleolus [6], but, as demonstrated by Zhang et al. [7] in 2005, the vascular pivot point of the distally based sural flap can be safely designed even 1.5 cm proximal to the lateral malleolus. We believe that individual skin marking is fundamental in the preoperative phase because preestablished landmarks, based on previous anatomical studies, are out of date. Jeng and Wei, considering the previously reported high failure rate in performing this flap because of variable vascular anatomy, advised the use of preoperative Doppler examination to identify perforators and their distance from the lateral malleolus in each clinical case [8]. Bocchi et al. [9] stated that the constant use of a Doppler probe during the preliminary evaluation provides more safety to the surgical

(a) (b) (c)

Figure 5: (a) 32-year-old male with posttraumatic defect over tendo achilles region. (b) RSAF was elevated and pedicled to cover the defect. Split thickness graft covered the donor site. At 6 weeks after surgery flap division was performed. (c) Followup at three months.

(a) (b) (c) (d)

Figure 6: (a) 40-year-old male patient with posttraumatic defect over tendo achilles region. (b) DPBF was raised with incision extending into the lateral aspect of wound. PB flap inset given and covered with split thickness skin graft. Donor site was closed primarly. (c) On early followup flap looked bulky. (d) On further followup (6 months) there was autothinning.

procedure and increases the success rate of the sural artery flap. We routinely use preoperative Doppler study to rule out significant arterial disease and also to mark perforators which help in flap design.

Other surgeons do not include the sural nerve in the flap based on the existence of a perforated branch of the peroneal artery which by itself is capable of irrigating the graft without the need to transfer the accompanying nerve [10]. With respect to the size of the flap, the largest dimension documented in the literature is 17 cm × 16 cm, but the complication rate increases accordingly with the graft size [11]. With enlarged flaps, the larger pedicle may be compressed more easily once it is tunneled and postoperative swelling increases which may augment venous congestion of the flap with the risk that this involves a greater possibility of suffering from partial necrosis of the skin bridge under which the graft is tunneled [12]. Other authors do not tunnel the flap under the skin due to fear of compression of the fatty pedicle against the skin especially in the postoperative phase when more swelling develops [13]. Other modifications to increase size include delaying [14–16] a wider than usual pedicle [17], supercharging [18], and harvesting a midline cuff of the

(a) (b)

Figure 7: (a) 38-year-old male with posttraumatic defect over left leg lower one-third tibia. RSAF was elevated and pedicled to cover the defect. Split thickness graft covered the donor site. (b) Followup at three months.

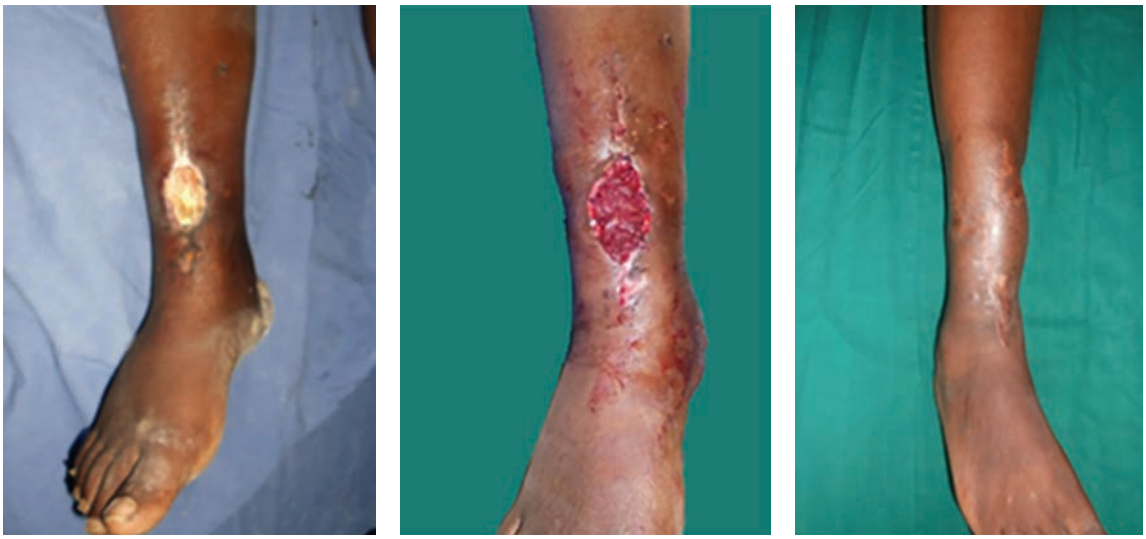

(a) (b) (c)

Figure 8: (a) 24-year-old male patient with posttraumatic defect over lower one-third tibia region. (b) DPBF was raised and tunneled to defect site. PB flap inset given and covered with split thickness skin graft. Donor site was closed primarly. (c) On early followup flap looked bulky.

gastrocnemius muscle with the flap [19]. Techniques without proximal extension of the flap such modifications included exteriorizing the pedicle [20], mobilizing the peroneal perforator in the intermuscular septum [6], and cross-leg sural flap [21]. From our experience with extended or proximal reverse sural flap in 18 cases (unpublished data) partial flap necrosis occurred in one case with main complication being venous congestion in 5 cases, all managed conservatively. We found that in upper third of the leg, the sural nerve lies deep between the heads of gastrocnemius muscle, which must be carefully dissected, safely maintaining the mesentery-like connection with the deep fascia. This mesentery-like structure contains small perforator vessels that run into the deep fascia and possibly ramify with the fascial vascular plexus, which accounts for the reliability of this distally based flap despite its huge dimensions. Longer pedicle is achieved by stopping the dissection 6 to 8 cm from the lateral malleolus, so that more than one peroneal perforators are incorporated in the flap.

In our study flap tip necrosis (<10%) occurred in 5 cases of DPBF (16%) and 6 cases of RSAF (18%). In DPBFs, majority of these were for defects of medial malleolus. Though the number of flap tip necrosis was higher in RSAF group, the mean area of defect of RSAF group was significantly

Figure 9: DPBF done for defect over tendoa chilles region. Flap is healthy. Partial loss of split thickness skin graft over the flap.

Figure 10: DPBF done for defect over distal third of tibia showing flap tip necrosis.

Figure 11: RSAF done for defect over distal third of tibia showing flap tip necrosis.

Figure 12: RSAF done for defect over anterior ankle showing partial flap necrosis.

more than DPBF (37.5 cm^2 versus 26.9 cm^2). From our initial experience, we routinely began to discard the proximal 2-3 cm of peroneus brevis muscle. It reduced the incidence of flap tip necrosis. Significant flaps loss (>10%) was present in two cases of DPBF (6%) and six cases of RSAF (18%). Both cases of DPBF loss were to medial malleolus defect and RSAF loss was of higher surface area. Most cases of flap loss were managed with vacuum assisted closure devices and secondarily with skin graft. Other patients were managed with flap cover and readvancement of RSAF. No patient in RSAFs or DPBFs suffered from total flap loss.

In a series of 70 sural flaps used for soft tissue coverage of the distal leg, the overall success rate was 86% for the flap alone or combined with a skin graft. However, the partial or complete flap necrosis rate was 36%, which was unfavourable. Risk factors included patient age of more than 40 years, peripheral artery disease, venous insufficiency, and diabetes mellitus. Tobacco use, chronic alcoholism, and minimal family support are secondary risk factors for flap failure [22]. In a large study of 179 reverse sural artery flaps by Wei et al. in 2012 it was observed that partial flap necrosis occurred in 11.2% of cases. They concluded that partial necrosis rate was significantly higher in the flaps with top edge locating in the upper 1/9 of the calf, in the flaps with length-width ratio (LWR) $\geq 5:1$ and in the flaps with width of skin island (width) ≥ 8 cm [23]. The major disadvantage of this flap is the scarification of the sural nerve leading to anaesthesia of the lateral foot. However, the long-term disability is minimal in most patients. An insensate flap and

the final scar, especially when skin grafting of the donor site is needed, are other drawbacks. However, poor cosmesis would be a lesser concern in traumatology [24].

Muscle flaps for distal lower limb reconstruction are limited due to lack of mobile muscle belly in this region. The soleus muscle flap has been useful in treating small to moderate sized defects but is limited by its small distal rotation arc [25].

The use of proximally based peroneus brevis as a pedicled muscle flap was first described by Pers and Medgyesi [26]. In 2001, Eren et al. described the use of the distally based peroneus brevis flap for reconstruction around the ankle [3]. A larger series on this flap by Schmidt and Giessler [27] has been the 109 cases reported in 2010. Detailed surgical anatomy was provided by Hughes et al. in a cadaveric study of twenty limbs. The area covered with this muscle ranged between 12 and 21 cm^2 and averaged 15.5 cm^2. Also on average, the most distal extent of the muscle was 0.92 cm distal to the tip of the fibular malleolus (range −2.0 to 3.0 cm). The superficial peroneal nerve pierced the deep fascia on an average location of 14 cm proximal to the tip of the fibular malleolus (range 10–18 cm). The average maximum width of the PB muscle was 5.10 cm (range 4–8 cm) at an average of 13.16 cm (range 10.5–15 cm) from the tip of the fibular malleolus. There was an average of 1.7 pedicles to the PB muscle (range 3–12), which entered the muscle in a segmental fashion. However, the proximal pedicle was larger than the more distal ones. In all limbs, the most proximal pedicle came off the peroneal artery. The pedicles, which pierced the anterior intermuscular septum, were supplied from the anterior tibial artery and generally entered the middle portion of the muscle. The most distal pedicles often pierced the posterior intermuscular septum and were supplied by either branches of the posterior tibial artery or perforating peroneal arteries. The average location of the most distal pedicle was 5.15 cm proximal to the tip of the malleolus (range 2.0–8.0 cm). The average location of the second most distal pedicle was 10.08 cm from the tip of the malleolus (range 4.0–16.0 cm). The average location of the third most distal pedicle was 17.79 cm (range 5.0–28.0 cm). The average location of the most proximal pedicle was 22.73 cm (range 16–28 cm). The total freeable length was determined by how much of the muscle could be released without completely detaching it from the origin. The average freeable length was 20.29 cm (range 76–21 cm) [25].

As a proximally based flap, the peroneus brevis is useful for covering small to moderate defects of the distal third of the tibia and ankle. The perforators supplying the distally based peroneus brevis flap on the lateral aspect of the leg adjacent to the ankle are constant and probably because they are deeper they seem to escape damage in most injuries of the ankle. The distally based flap can be raised with a segment of the vascularised fibula if needed. It is particularly a good choice for defects of the lateral malleolus and tendo achilles.

Whether used for defects of the leg or ankle, the muscle, initially bulky, has the benefit of "autothinning" over time. As the muscle atrophies, it provides a better aesthetic result than local fasciocutaneous flaps, but irregular contour and color of skin graft over muscle can be a problem. The thinner flap has advantage particularly around the ankle as the reconstruction is less likely to interfere with footwear.

Major complications faced with DPBF were flap tip necrosis and skin graft failure. Five of 32 cases had flap tip necrosis (<10%) as proximal part of muscle has compromised blood flow. Our experience has seen that discarding proximal 2-3 cm of muscle decreases incidence of flap tip necrosis. Significant flap loss (>10%) was seen in two cases. It was observed that in both cases defect was over medial malleolus; thus, greater arc of rotation of flap resulted in compromised blood flow. Another frequent complication was skin graft failure which occurred in 4 cases of which 2 patients had venous congestion in immediate postoperative period. We observed that bulky dressing and VAC dressing reduced incidence of graft failure.

Main advantage that we found with DPBF was shorter operative time and shorter hospital stay which is of importance in a high volume trauma centre with limited beds. We discharge most patients once flap is healthy with no signs of infection and follow up these cases on outpatient basis.

Several studies have shown that the loss of the peroneus brevis with functional peroneus longus does not cause instability of the ankle [28]. In our study only 1 patient out of 32 DPBFs had gait disturbance on followup; whether it was due to loss of function of peroneus brevis or due to concomitant ankle injury could not be assessed. All patients have the cosmetic problem of a linear scar on the lateral aspect of the leg which was inconspicuous in most patients. No guttering or unevenness was noted in donor site muscle.

5. Conclusions

To conclude, RSAF and DPBF are reliable for lower third leg defects of moderate size. Both flaps gave a good functional outcome. DPBFs had better aesthetic appearance at donor site and recipient site. DPBFs have the advantage of ease of surgery, speedy recovery, less hospital stay, and no donor site morbidity. DPBFs appear to be preferred choice for Lower third leg defects. RSAFs should be chosen over DPBFs for defects on medial malleolus and larger size defects.

Disclosure

This work contains parts of Pushkar Deshpande and Prakash Kumar M N doctoral thesis.

Conflict of Interests

The authors declare that there is no conflict of interests.

References

[1] T.-C. Lu, C.-H. Lin, C.-H. Lin, Y.-T. Lin, R.-F. Chen, and F.-C. Wei, "Versatility of the pedicled peroneal artery perforator flaps for soft-tissue coverage of the lower leg and foot defects," *Journal of Plastic, Reconstructive and Aesthetic Surgery*, vol. 64, no. 3, pp. 386–393, 2011.

[2] S. J. Mathes and F. Nahai, *Reconstructive Surgery: Principles, Anatomy and Technique*, Churchill-Livingstone, New York, NY,

USA, 1997.

[3] S. Eren, A. Ghofrani, and M. Reifenrath, "The distally pedicled peroneus brevis muscle flap: a new flap for the lower leg," *Plastic and Reconstructive Surgery*, vol. 107, no. 6, pp. 1443–1448, 2001.

[4] Y.-L. Yang, T.-M. Lin, S.-S. Lee, K.-P. Chang, and C.-S. Lai, "The distally pedicled peroneus brevis muscle flap anatomic studies and clinical applications," *Journal of Foot and Ankle Surgery*, vol. 44, no. 4, pp. 259–264, 2005.

[5] A. C. Masquelet, M. C. Romaña, and G. Wolf, "Skin island flaps supplied by the vascular axis of the sensitive superficial nerves: anatomic study and clinical experience in the leg," *Plastic and Reconstructive Surgery*, vol. 89, no. 6, pp. 1115–1121, 1992.

[6] M. Hasegawa, S. Torii, H. Katoh, and S. Esaki, "The distally based superficial sural artery flap," *Plastic and Reconstructive Surgery*, vol. 93, no. 5, pp. 1012–1020, 1994.

[7] F.-H. Zhang, S.-M. Chang, S.-Q. Lin et al., "Modified distally based sural neuro-veno-fasciocutaneous flap: anatomical study and clinical applications," *Microsurgery*, vol. 25, no. 7, pp. 543–550, 2005.

[8] S.-F. Jeng and F.-C. Wei, "Distally based sural island flap for foot and ankle reconstruction," *Plastic and Reconstructive Surgery*, vol. 99, no. 3, pp. 744–750, 1997.

[9] A. Bocchi, S. Merelli, A. Morellini, S. Baldassarre, E. Caleffi, and F. Papadia, "Reverse fasciosubcutaneous flap versus distally pedicled sural island flap: two elective methods for distal-third leg reconstruction," *Annals of Plastic Surgery*, vol. 45, no. 3, pp. 284–291, 2000.

[10] Y. S. Hasan, "Doppler assisted reversed neuro-fascio-cutaneous flaps in foot reconstruction," *Egyptian Journal of Plastic and Reconstructive Surgery*, vol. 30, no. 2, pp. 101–105, 2006.

[11] B. le Fourn, N. Caye, and M. Pannier, "Distally based sural fasciomuscular flap: anatomic study and application for filling leg or foot defects," *Plastic and Reconstructive Surgery*, vol. 107, no. 1, pp. 67–72, 2001.

[12] Y. K. Tu, S. Veng, W. L. Yeh, and K. C. Wang, "Reconstruction of the ankle and heel defects by a modified wide-base reverse sural flap," *The Journal of Trauma*, vol. 47, pp. 82–88, 1999.

[13] S.-L. Chen, T.-M. Chen, T.-D. Chou, S.-C. Chang, and H.-J. Wang, "Distally based sural fasciomusculocutaneous flap for chronic calcaneal osteomyelitis in diabetic patients," *Annals of Plastic Surgery*, vol. 54, no. 1, pp. 44–48, 2005.

[14] D. Erdmann, N. Gottlieb, J. S. Humphrey, T. C. Le, W. Bruno, and L. S. Levin, "Sural flap delay procedure: a preliminary report," *Annals of Plastic Surgery*, vol. 54, no. 5, pp. 562–565, 2005.

[15] Z. Tosun, A. Özkan, Z. Karaçor, and N. Savaci, "Delaying the reverse sural flap provides predictable results for complicated wounds in diabetic foot," *Annals of Plastic Surgery*, vol. 55, no. 2, pp. 169–173, 2005.

[16] U. Kneser, A. D. Bach, E. Polykandriotis, J. Kopp, and R. E. Horch, "Delayed reverse sural flap for staged reconstruction of the foot and lower leg," *Plastic and Reconstructive Surgery*, vol. 116, no. 7, pp. 1910–1917, 2005.

[17] J. C. Lo, H. C. Chen, H. H. Chen, and E. Santamaria, "Modified reverse sural artery flap," *Chang Gung Medical Journal*, vol. 20, no. 4, pp. 293–298, 1997.

[18] O. Tan, B. Atik, and M. Bekerecioglu, "Supercharged reverse-flow sural flap: a new modification increasing the reliability of the flap," *Microsurgery*, vol. 25, no. 1, pp. 36–43, 2005.

[19] M. M. Al-Qattan, "Lower-limb reconstruction utilizing the reverse sural artery flap-gastrocnemius muscle cuff technique," *Annals of Plastic Surgery*, vol. 55, no. 2, pp. 174–178, 2005.

[20] T. R. Maffi, J. Knoetgen III, N. S. Turner, and S. L. Moran, "Enhanced survival using the distally based sural artery interpolation flap," *Annals of Plastic Surgery*, vol. 54, no. 3, pp. 302–305, 2005.

[21] C. J. Quarmby and P. J. Skoll, "The distally based, cross-leg, sural artery island flap," *Plastic and Reconstructive Surgery*, vol. 108, no. 3, pp. 798–799, 2001.

[22] S. P. Baumeister, R. Spierer, D. Erdmann, R. Sweis, L. S. Levin, and G. K. Germann, "A realistic complication analysis of 70 sural artery flaps in a multimorbid patient group," *Plastic and Reconstructive Surgery*, vol. 112, no. 1, pp. 129–140, 2003.

[23] J. W. Wei, Z. G. Dong, J. D. Ni et al., "Influence of flap factors on partial necrosis of reverse sural artery flap: a study of 179 consecutive flaps," *The Journal of Trauma and Acute Care Surgery*, vol. 72, no. 3, pp. 744–750, 2012.

[24] A. Costa-Ferreira, J. Reis, C. Pinho, A. Martins, and J. Amarante, "The distally based island superficial sural artery flap: clinical experience with 36 flaps," *Annals of Plastic Surgery*, vol. 46, no. 3, pp. 308–313, 2001.

[25] B. le Fourn, N. Caye, and M. Pannier, "Distally based sural fasciomuscular flap: anatomic study and application for filling leg or foot defects," *Plastic and Reconstructive Surgery*, vol. 107, no. 1, pp. 67–72, 2001.

[26] L. A. Hughes and J. L. Mahoney, "Anatomic basis of local muscle flaps in the distal third of the leg," *Plastic and Reconstructive Surgery*, vol. 92, no. 6, pp. 1144–1154, 1993.

[27] M. Pers and S. Medgyesi, "Pedicle muscle flaps and their applications in the surgery of repair," *British Journal of Plastic Surgery*, vol. 26, no. 4, pp. 313–321, 1973.

[28] A. B. Schmidt and G. A. Giessler, "The muscular and the new osteomuscular composite peroneus brevis flap: experiences from 109 cases," *Plastic and Reconstructive Surgery*, vol. 126, no. 3, pp. 924–932, 2010.