Hindawi Publishing Corporation
Advances in Orthopedic Surgery
Volume 2015, Article ID 631254, 4 pages
http://dx.doi.org/10.1155/2015/631254

Clinical Study

Treatment of Aseptic Hypertrophic Nonunion of the Lower Extremity with Less Invasive Stabilization System (New Approach to Hypertrophic Nonunion Treatment)

Metin Uzun,[1] Murat Çakar,[2] Ahmet Murat Bülbül,[3] and Adnan Kara[3]

[1]*Maslak Hospital, Orthopaedic Department, Acibadem University, Darüşşafaka Street, Büyükdere Street No. 40, Maslak, Sarıyer, İstanbul, Turkey*
[2]*Okmeydani Education and Training Hospital, Okmeydani, İstanbul, Turkey*
[3]*Orthopaedic Department, Medipol University, İstanbul, Turkey*

Correspondence should be addressed to Metin Uzun; drmetinuzun@gmail.com

Received 15 August 2015; Revised 26 November 2015; Accepted 30 November 2015

Academic Editor: Werner Kolb

Aim. To evaluate whether aseptic hypertrophic nonunion in the long bones of the lower extremity can be treated successfully with LISS applied with closed methods without grafting. *Materials and Methods.* The study included 7 tibias and 9 femurs of 16 patients. All cases had hypertrophic nonunion. Initial surgical treatment was with intramedullary nailing in 14 cases, 6 of which had required an exchange of intramedullary nail. All the patients were treated with LISS plate with closed methods. *Results.* Union was obtained at mean 7 months in all patients. No implant loosening or breakage of the implant was observed and there was no requirement for secondary surgery. *Conclusion.* Cases of hypertrophic nonunion have excellent blood supply and biological potential. Therefore, there is no need for bone grafting and the addition of fracture stability is enough to achieve full union. Using a limited approach and percutaneous screw insertion, LISS provides fracture stabilization with soft tissue protection.

1. Introduction

Although good outcomes have been reported from the surgical treatment of tibia and femur diaphysis fractures, nonunion can always be a troubling complication. Nonunion may be seen as oligotrophic, hypertrophic, or atrophic. Hypertrophic nonunion differs from other forms of nonunion, as there is still the biological capacity for union. This nonunion type occurs as a result of mechanical instability. Many methods have been reported to enhance stability in the treatment of nonunion, such as plate, intramedullary (IM) nail, or external fixator. The standard treatment is to exchange the IM nail for a larger size, with or without applying graft.

The aim of this study was to evaluate the treatment of hypertrophic nonunion with closed reduction and fracture stability with LISS and to assess if this method was sufficient to achieve union without the necessity of grafting.

2. Materials and Methods

A retrospective evaluation was made of 16 patients with aseptic hypertrophic nonunion of the lower extremity treated with LISS between 2006 and 2009.

The diagnosis of nonunion was made clinically and radiologically. Clinical nonunion was defined as patients with pain and motion at the fracture site and radiological nonunion as no bone bridging observed 6 months after the initial treatment. The cases of hypertrophic nonunion included in the study met the criteria of the Weber and Cech classification. Patients were excluded if they had draining fistulas or infection determined by erythrocyte sedimentation rate, serum C-reactive protein, and white blood cell levels or if the nonunion was septic.

The patients comprised 9 males and 7 females with a mean age of 24 years (range, 15–48 years). The bones involved were

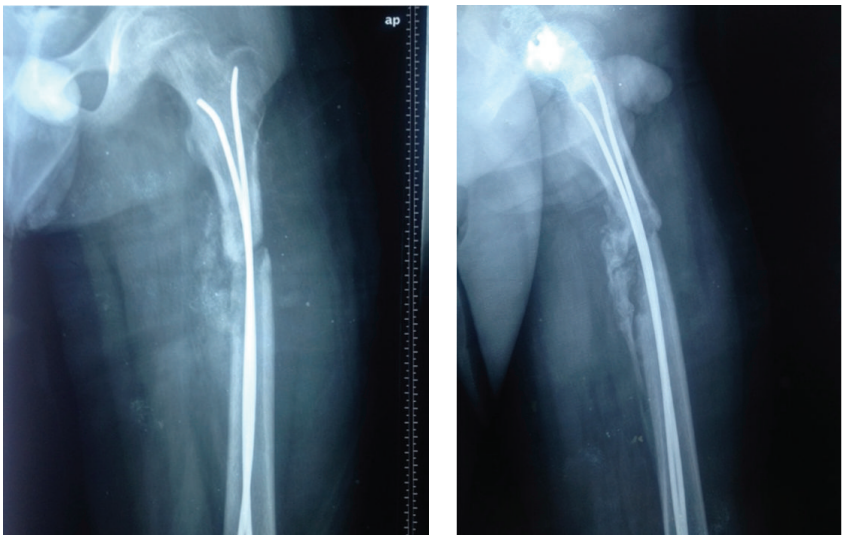

Figure 1: A 14-year-old boy 8 months after a traffic accident. Titanium intramedullary nail was initially applied and hypertrophic nonunion can be seen in the left femur.

Figure 2: The same patient 3 months after the removal of nails and the application of LISS without grafting.

Figure 3: Postoperative 6 months.

7 tibias and 9 femurs with time of nonunion ranging from 7 to 18 months. Two patients were previously managed by cast immobilization only, and the remaining 14 patients were initially treated surgically with intramedullary nailing, 6 of whom had undergone intramedullary nail exchange.

Antibiotic prophylaxis was administered 30 minutes before surgery. The patients were positioned supine on a radiolucent operating table. After the necessary draping and preparation, the previous implants in 14 patients were removed from the previous skin incision (Figure 1). Reduction, alignment, and rotation were corrected under fluoroscopy; then tibial and femoral LISS implants were inserted without opening the fracture site (Figure 2). Postoperative active and passive range of motion exercises were started as soon as could be tolerated. All patients were mobilized on 2 crutches with partial weight-bearing. Antibiotic prophylaxis was continued for 2 days postoperatively. The mean duration of hospitalization was 5.6 days (range, 3–10 days). The patients were followed up clinically and radiologically on postoperative day 1 and then at 3, 6, and 12 weeks and 6, 9, 12, and 18 months. Radiological evaluation was made from standing anteroposterior and lateral radiographs. Clinical evaluation was based on pain, motion in the fracture site, infection, and function. A visual scale was used to evaluate the pain. Union was defined radiologically when there was bridging callus in at least three cortices (Figure 3).

3. Results

In this study, union was achieved in all patients at mean 7 months (range, 4–12 months). Superficial infection was determined in 3 cases (2 femurs and 1 tibia) which was successfully treated with oral antibiotics. Shortening of the limb of <2 cm was seen in 3 (13%) of the patients (1 femur and 2 tibias). No implant loosening or breakage of implants was determined. All patients achieved functional extremities without instability or pain.

4. Discussion

Bone fracture initiates a cascade of events to heal the bone [1, 2]. Any disruption to this cascade from biological or mechanical factors such as poor bone quality, comminution, bone loss, soft tissue damage, infection, insufficient mechanical stabilization, multiple surgery history, or smoking may result in delayed union or nonunion [1, 2].

Nonunion can be classified on the basis of anatomy, the presence and absence of infection, healing potential, or stiffness. The Weber and Cech classification is used for hypertrophic or atrophic nonunion based on the capability of biological reaction [3]. The hypertrophic form is characterized by abundant callus formation and a persistent radiolucent line at the fracture site. This form especially occurs due to lack of mechanical stability, but there is a sufficient blood supply and new bone formation. This nonunion type has biological potential and often only requires the addition of fracture stability to be able to achieve union.

Treatment of hypertrophic nonunion can be achieved through enhancement of stability. Therefore, many surgical techniques have been applied, including screw and plate fixation, external fixation, intramedullary nailing, bone transport, and free fibula grafting with or without bone grafting [2, 4–8]. However, if there is a history of surgery, the most popular treatment is to exchange the nail for a larger size with or without debridement at the nonunion site. If there is no surgical history or deformity, then open reduction and stabilization by plating with bone graft has been a standard treatment for diaphyseal nonunion of long bones [6, 9–11]. Some authors such as Bellabarbo and Weresh have reported difficulties and failure of exchange reamed intramedullary nails in nonunited femoral shaft fractures [6, 10, 11]. In the light of this, new techniques have been developed using LISS to enhance mechanical stability in lower extremity long bone hypertrophic nonunion, as was used in the current study [12–14].

When literature is examined, LCP was introduced for four reasons: (1) osteoporotic bone fracture, (2) comminution at the fracture site, (3) intra-articular fracture, and (4) short segment periarticular fracture [15–17]. The advantage of LCP is that stability does not depend on compression between the plate and bone and the periosteal blood supply to the fracture fragments is better preserved compared to DCP [16, 17]. Although many authors have tried to use this advantage for nonunion treatment, because of the prolonged immobilization periods and repeated operations required in severely osteopenic bones, good screw hold can not be achieved. Therefore, as a new treatment modality, LCP augmentation has been used with retaining hardware in cases previously treated with IM nail [5, 9, 10, 13, 14]. The advantages of the retaining nail are as follows: (1) alignment of the fracture is maintained and could help to maintain stability, (2) sometimes removal of the broken screw or nail may not be possible, and (3) there is no additional operating time entailing more blood loss and more soft tissue damage [15–17]. Chen et al. treated 55 patients with aseptic nonunion of femoral shaft fractures by retaining previous implants, open reduction, and internal fixation with DCP and supplementation with cancellous bone graft [12]. All nonunions united at 24 weeks and superficial wound infection developed in 1 case. Nadkarni et al. evaluated 11 patients who had previously undergone locked intramedullary nailing for fractures of long bones [13]. In all cases, the fracture site was exposed and LCP was applied over the intramedullary nail with autologous bone graft. Radiological union was achieved in all cases at 6.2 months and no complications developed. Kumar evaluated the role of locking plate with graft in difficult nonunion fractures. Roetman et al. analyzed augmentive plate fixation in 32 femoral nonunions after intramedullary nailing and it was concluded that augmentive plate fixation while leaving the nail in situ is simple and safe [14]. Different studies have found a union rate from 94% to 100% with plating [13, 14].

Although some authors have reported excellent results from the open method using LCP, there may be problems in the application of the plate due to bone surface deformation associated with hypertrophy at the fracture site. However, Wagner reported excellent results and showed that plate can be applied easily with no need to mould the plate [17].

In light of this information in literature, we considered that, with enhanced stability, union could be achieved without debridement and grafting. Therefore, all the patients in this study were treated with LISS applied with closed reduction and without any bone graft. Using the closed method resulted in a shorter operating time, less blood loss, no donor site problems for a bone graft area, and, consequently, less pain and less analgesia requirement. In this study, 16 patients with nonunion of the long bones were treated with LISS applied with the closed method without any bone graft. Union was achieved in all patients in mean 7 months (range, 4–12 months).

In conclusion, hypertrophic bone nonunion has an excellent blood supply and biological potential, so there is no need for bone grafting and just the addition of fracture stability will be enough to provide full osseous union. LISS provides fracture stabilization with soft tissue protection through the use of a limited approach and percutaneous screw insertion.

Disclosure

This is an original paper and its level of evidence is level 4 case series.

Conflict of Interests

The authors declare that there is no conflict of interests regarding the publication of this paper.

Acknowledgments

This paper was developed at the two centers of Acibadem University, Maslak Hospital, and Medipol University.

References

[1] K. J. Pugh and S. R. Rozbruch, "Nonunions and malunions," in *Orthopaedic Knowledge Update, Trauma*, M. R. Baumgaertner and P. Tornetta, Eds., pp. 117–118, American Acadamy of Orthopaedic Surgeons, Rosemont, Ill, USA, 2005.

[2] E. C. Rodriguez-Merchan and F. Forriol, "Nonunion: general principles and experimental data," *Clinical Orthopaedics and Related Research*, no. 419, pp. 4–12, 2004.

[3] B. G. Weber and O. Cech, *Pseudoarthrosis: Pathology, Biomechanics, Therapy, Results*, Hans Huber Medical Publisher, Berne, Switzerland, 1976.

[4] K.-D. Gao, J.-H. Huang, F. Li et al., "Treatment of aseptic diaphyseal nonunion of the lower extremities with exchange intramedullary nailing and blocking screws without open bone graft," *Orthopaedic Surgery*, vol. 1, no. 4, pp. 264–268, 2009.

[5] K.-D. Gao, J.-H. Huang, J. Tao et al., "Management of femoral diaphyseal nonunion after nailing with augmentative locked plating and bone graft," *Orthopaedic Surgery*, vol. 3, no. 2, pp. 83–87, 2011.

[6] D. J. Hak, "Management of aseptic tibial nonunion," *The Journal of the American Academy of Orthopaedic Surgeons*, vol. 19, no. 9, pp. 563–573, 2011.

[7] M. Kocaoğlu, L. Eralp, C. Sen, M. Cakmak, H. Dincyürek, and S. B. Göksan, "Management of stiff hypertrophic nonunions by distraction osteogenesis: a report of 16 cases," *Journal of Orthopaedic Trauma*, vol. 17, no. 8, pp. 543–548, 2003.

[8] L. X. Webb, "Bone defect nonunion of the lower extremity," *Techniques in Orthopaedics*, vol. 16, no. 4, pp. 387–397, 2001.

[9] C. Bellabarba, W. M. Ricci, and B. R. Bolhofner, "Results of indirect reduction and plating of femoral shaft nonunions after intramedullary nailing," *Journal of Orthopaedic Trauma*, vol. 15, no. 4, pp. 254–263, 2001.

[10] M. J. Weresh, R. Hakanson, M. D. Stover, S. H. Sims, J. F. Kellam, and M. J. Bosse, "Failure of exchange reamed intramedullary nails for ununited femoral shaft fractures," *Journal of Orthopaedic Trauma*, vol. 14, no. 5, pp. 335–338, 2000.

[11] A. J. Furlong, P. V. Giannoudis, P. DeBoer, S. J. Matthews, D. A. MacDonald, and R. M. Smith, "Exchange nailing for femoral shaft aseptic non-union," *Injury*, vol. 30, no. 4, pp. 245–249, 1999.

[12] C.-M. Chen, Y.-P. Su, S.-H. Hung, C.-L. Lin, and F.-Y. Chiu, "Dynamic compression plate and cancellous bone graft for aseptic nonunion after intramedullary nailing of femoral fracture," *Orthopedics*, vol. 33, article 393, 2010.

[13] B. Nadkarni, S. Srivastav, V. Mittal, and S. Agarwal, "Use of locking compression plates for long bone nonunions without removing existing intramedullary nail: review of literature and our experience," *The Journal of Trauma*, vol. 65, no. 2, pp. 482–486, 2008.

[14] B. Roetman, N. Scholz, G. Muhr, and G. Möllenhoff, "Augmentive plate fixation in femoral non-unions after intramedullary nailing. Strategy after unsuccessful intramedullary nailing of the femur," *Zeitschrift fur Orthopadie und Unfallchirurgie*, vol. 146, no. 5, pp. 586–590, 2008.

[15] K. A. Egol, E. N. Kubiak, E. Fulkerson, F. J. Kummer, and K. J. Koval, "Biomechanics of locked plates and screws," *Journal of Orthopaedic Trauma*, vol. 18, no. 8, pp. 488–493, 2004.

[16] W. R. Smith, B. H. Ziran, J. O. Anglen, and P. F. Stahel, "Locking plates: tips and tricks," *The Journal of Bone & Joint Surgery—American Volume*, vol. 89, no. 10, pp. 2298–2307, 2007.

[17] M. Wagner, "General principles for the clinical use of the LCP," *Injury*, vol. 34, supplement 2, pp. 31–42, 2003.