

## *Retraction*

# **Retracted: Study on the Application Value of CT Thin-Layer Scan Data Assisted 3D Printing Technology in Hip and Knee Replacement**

### **Journal of Healthcare Engineering**

Received 11 July 2023; Accepted 11 July 2023; Published 12 July 2023

Copyright © 2023 Journal of Healthcare Engineering. This is an open access article distributed under the Creative Commons Attribution License, which permits unrestricted use, distribution, and reproduction in any medium, provided the original work is properly cited.

This article has been retracted by Hindawi following an investigation undertaken by the publisher [1]. This investigation has uncovered evidence of one or more of the following indicators of systematic manipulation of the publication process:

- (1) Discrepancies in scope
- (2) Discrepancies in the description of the research reported
- (3) Discrepancies between the availability of data and the research described
- (4) Inappropriate citations
- (5) Incoherent, meaningless and/or irrelevant content included in the article
- (6) Peer-review manipulation

The presence of these indicators undermines our confidence in the integrity of the article's content and we cannot, therefore, vouch for its reliability. Please note that this notice is intended solely to alert readers that the content of this article is unreliable. We have not investigated whether authors were aware of or involved in the systematic manipulation of the publication process.

In addition, our investigation has also shown that one or more of the following human-subject reporting requirements has not been met in this article: ethical approval by an Institutional Review Board (IRB) committee or equivalent, patient/participant consent to participate, and/or agreement to publish patient/participant details (where relevant).

Wiley and Hindawi regrets that the usual quality checks did not identify these issues before publication and have since put additional measures in place to safeguard research integrity.

We wish to credit our own Research Integrity and Research Publishing teams and anonymous and named external researchers and research integrity experts for contributing to this investigation.

The corresponding author, as the representative of all authors, has been given the opportunity to register their agreement or disagreement to this retraction. We have kept a record of any response received.

### **References**

- [1] S. Sun, Y. Xi, X. Shi, L. Zhao, F. Ma, and J. Qian, "Study on the Application Value of CT Thin-Layer Scan Data Assisted 3D Printing Technology in Hip and Knee Replacement," *Journal of Healthcare Engineering*, vol. 2021, Article ID 3491509, 7 pages, 2021.

## Research Article

# Study on the Application Value of CT Thin-Layer Scan Data Assisted 3D Printing Technology in Hip and Knee Replacement

Shihua Sun <sup>1</sup>, Yongbin Xi <sup>1</sup>, Xingchen Shi <sup>1</sup>, Li Zhao <sup>2</sup>, Fuming Ma <sup>3</sup>,  
and Jifang Qian <sup>2</sup>

<sup>1</sup>The No. 2 People's Hospital of Lanzhou Orthopaedics Department, Lanzhou Gansu 730030, China

<sup>2</sup>Gansu Provincial Maternity and Child-Care Hospital Medical Imaging Center, Lanzhou Gansu 730040, China

<sup>3</sup>The No. 2 People's Hospital of Lanzhou Orthopaedics ED, Lanzhou Gansu 730030, China

Correspondence should be addressed to Jifang Qian; 1541112110881@post.eurasia.edu

Received 26 July 2021; Accepted 2 September 2021; Published 27 September 2021

Academic Editor: Balakrishnan Nagaraj

Copyright © 2021 Shihua Sun et al. This is an open access article distributed under the Creative Commons Attribution License, which permits unrestricted use, distribution, and reproduction in any medium, provided the original work is properly cited.

To better study hip and knee replacement, 50 eligible hip and knee patients from March 2020 to April 2021 were selected. A 1 : 1 scale solid model was printed with CT thin-layer scanning data assisted by 3D printing technology to evaluate the ankle function of patients six months after surgery. The results showed that the 3D rapid prototyping time of the 1 : 1 fracture model in 50 patients was 3-4 hours. The operation time was 70-90 min, and the average operation time was 80 min. The actual application in operation was consistent with that in the simulation of the 3D printing model, after surgery, and there was no infection of incision soft tissue or loss of reduction in all 50 patients. CT thin-layer scan data aided 3D printing technology can help clinical hip and knee replacement simulation and planning, improving surgery's accuracy and safety.

## 1. Introduction

Hip and knee replacement is a procedure to solve moderate-to-severe knee osteoarthritis and has a high success rate. It mainly relaxes the soft tissue and bone tissue of the knee joint through the balance of the joint space, corrects the mechanical axis of the lower limbs, rebuilds the joint stability, relieves the symptoms of the patient, reduces the time in bed, achieves normal early activities, and restores the knee limbs [1]. Bio-mechanical analysis shows that correct alignment of prosthetic components is one of the most critical features of successful hip and knee replacement, and the key is accurate intraoperative amputation. The surgical methods for middle and late KOA include hip and knee replacement [2] assisted with 3D printing. With the increasing popularity of hip and knee replacement for debilitating knee osteoarthritis and joint function loss, studying methods to improve the efficacy, accuracy, and repeatability of hip and knee replacement has become an important goal of contemporary orthopaedic research.

3D printing technology is a rapid manufacturing technology that can form the three-dimensional structure of the

product through “layered manufacturing and layer-by-layer stacking” [3]. 3D printing technology has begun to be applied in the medical field and has played an essential role in formulating routine surgical evaluation programs, such as the type of disease in patients with bone defects, the placement of prostheses, and the degree of deformity correction. In recent years, the hospitals used 3D printing technology to assist the total hip replacement, implemented the nursing intervention based on this technology, and summarized the experience as follows.

3D printing technology is an emerging high technology in recent years. Its wide application can be seen in people's clothing, food, shelter, and transportation, especially in the medical field, which has made some achievements. It has obvious advantages in treating joint surgery diseases and brings hope to the later treatment of OA patients. This technology can simulate complex orthopaedic surgery by computer software before the operation and make the operation from complex to simple [4]. 3D printed individual osteotomy guide is a modern hip and knee replacement technology to facilitate implant and lower limb alignment

correction. Using computed tomography (CT) or magnetic resonance imaging (MRI), the preoperative image data were imported into the rapid prototyping machine through the computer simulation software system. Making 3D models and personal osteotomy templates helps to understand the shape and skeletal anatomy of the affected knee joint and allows for more accurate preoperative planning. It enables the operator to simulate osteotomy on the three-dimensional model [5–7]. It helps the surgeon provide a clearer answer to the patient and his family so that the patient can easily understand the surgical process and actively cooperate with the individualized treatment plan formulated by the doctor. Neubert et al. [8] performed traditional total knee replacement for patients diagnosed with advanced knee OA. Postoperative dislocation of the knee's anatomical structure can lead to patellofemoral pain, knee instability, stiffness, low function, low range of motion, and wear and loosening of components. Despite the theoretical advantages of PSI in hip and knee replacement, the clinical advantages of PSI in hip and knee replacement surgery over conventional knee replacement are controversial. In cadaver studies, Collins [9] used patient-specific computer-assisted osteotomy guides or traditional intramedullary line osteotomy guides. Measurements of posterior femoral roll, tibiofemoral adduction, and passive varus-valgus relaxation in caducous knee joints were demonstrated. Liu et al. concluded from this study that compared with traditional hip and knee arthroplasty, the knee kinematics of personalized osteotomy guide assisted total knee arthroplasty is significantly closer to normal than traditional hip and knee arthroplasty. It indicated that applying 3D printed personalized osteotomy guides after knee replacement has better anatomical lines and knee joint function, faster rehabilitation and recovery, less pain, longer life, and better hip and knee joint quality of life with replacement prosthesis [10]. In conclusion, the accurate alignment of the arthroplasty prosthesis in the neutral position during hip and knee replacement can relieve the pain of postoperative patients and obtain satisfactory knee function, by ERAS, improving patient survival. Hip and knee replacement has a high success rate in resolving pain and improving function. However, patients may experience a range of adverse postoperative outcomes in cases where mispositioning of traditional hip and knee replacement is observed, and examples include thickness loss of polyethylene tibial bearings, eccentric load, prosthesis loosening, and eventually early revision. Lu et al. [11] showed that computer-assisted hip and knee replacement was superior to traditional hip and knee replacement with instruments to avoid these complications. In this project, in the individualized assisted hip and knee replacement osteotomy group, 9.3% of the patients' knee mechanical axis deviated from the neutral position by more than 3 degrees and 21.2% of the conventional osteotomy plate deviated from the neutral lower limb line. Personalized osteotomy using guide plate to assist in the correction of lower limbs can improve the accuracy and has a small error. It is suggested that the alignment should be in the 0–3 degree range of the mechanical shaft and that the manual intramedullary/extramedullary guide cannot consistently achieve the shaft in this

range. Alazri et al. [12] performed hip and knee replacement in 15 patients with preoperative planning assisted by an individualized osteotomy guide and conventional hip and knee replacement in 15 patients in the control group. The results showed that using the personalized osteotomy guide plate reduced the operation time and blood loss during and after the operation, which proved that the perioperative effect of three-dimensional assisted hip and knee arthroplasty is better than traditional methods. Yang et al. compared blood loss, operation time, and alignment of the mechanical axis with single femoral and tibial component between the navigation template group and the conventional method group [13]. The results showed that the mean operative time and mean blood loss in the navigation template group were statistically significantly lower than those in the conventional group. With this novel individualized navigation template, the operation is simplified and accurate, with good lower extremity lines, femoral anterior inclination, posterior tibial inclination, and knee space. The operation time is greatly reduced. Typically, each hip and knee replacement is completed in about 45 minutes.

Zhang and Lv found that postoperative functional recovery of the affected limb in hip replacement patients was closely related to perioperative intervention and functional exercise [14]. Therefore, scientific and practical nursing measures to improve the effectiveness of surgery and improve patients' prognoses have a positive role. Total hip replacement is very traumatic for patients. In addition, most patients and their families have significant concerns about the expected results of the operation due to disease and limited knowledge of the operation. As a result, severe anxiety, uncertainty, fear, and other destructive emotions appear in patients before surgery. In the past, traditional nursing intervention only relied on the oral expression of nursing staff to carry out preoperative education and psychological comfort for patients. It is difficult for patients to understand the cognition of the disease and the procedures related to surgery [15, 16]. The 3D printing model based on 3D printing technology can be customized according to the patient's disease characteristics and condition. At the same time, the patient's disease characteristics, surgical methods, surgical procedures, expected clinical effects, etc., can be vividly presented to patients and their families. Studies have shown that nursing staff can simulate the whole process of prosthetic installation by 3D printing models before surgery and the effects of hip replacement by showing the results after surgery. In this way, patients' doubts and perplexity are eliminated to the maximum extent, and the foundation is laid for patients to establish confidence in overcoming the disease [17]. At the same time, the postoperative nursing staff will show 3D printed models, including postures, walking styles, etc., to guide patients to maintain the correct daily lifestyle, vividly guide patients to adopt a scientific and reasonable lifestyle, and increase patients' attention to relevant precautions [18].

In hip and knee replacement, 3D printed fracture models based on CT thin-layer scan data can help fully understand the fracture, simulate the operation, and customize the surgical plan. Implementing individualized precision

surgery can improve the operation efficiency and reduce bleeding and complications, and the curative effect is satisfactory.

## 2. Research Methods

**2.1. Standard Criteria.** Inclusion criteria: (1) age >18, male or female; (2) hip and knee fractures confirmed by imaging, which belongs to AO/ASIF type B or C; (3) no obvious abnormality of wrist function before the injury; and (4) those who agree to surgical treatment. Exclusion criteria: (1) old fracture of distal hip and knee joint; (2) pathological fracture; (3) patients with other anonymous limb fractures and vascular and nerve injuries; and (4) poor compliance.

**2.2. General Information.** A total of 50 eligible hip and knee patients were selected from March 2020 to April 2021. Among them, 20 were male and 30 were female; the average age was 53 years. Twenty-five patients were  $\geq 60$  years old. The causes of injury are as follows: 35 cases fell while walking, 8 fell from a height, and seven were injured by car accident and other reasons. Fracture site: 34 cases of the left radius and 16 cases of the right radius. All hip and knee fractures were confirmed by X-ray and/or CT. AO/ASIF classification: there were 4 cases of type B1, 5 cases of type B3, 16 cases of type C1, 18 cases of type C2, and 7 cases of type C3. The operation time was 1–5 days after injury.

### 2.3. Methods

- (1) CT thin-slice scan: Siemens 64-slice spiral CT was used as the CT equipment. The subject was placed prone, and the CT scan scope included the entire foot [19]. Scanning parameters: tube voltage, 120 kV; tube current, 200 mA; layer thickness, 1 mm; collimator,  $2.0 \times 1.0$ ; adjust the window width and window level according to the individual image of the patient. The scanned data were burned to DVD for processing, and the data were processed in the installation of graphics workstation and medical 3D reconstruction software Mimics14.0. MakerBot 3D was applied to prepare subsequent 3D model printing [20].
- (2) 3D printing of the fracture model: the patient underwent a preoperative spiral CT scan with the layer spacing controlled at 0.5 mm to obtain  $512 \times 512$  pixel DICOM format data. These data were fed into Mimics, 3D medical reconstruction software, to reconstruct a digital model of the hip and knee, and 3D editing is used to remove the carpus. The distal articular surface of the hip and knee was directly displayed. Then, the data were transmitted to a 3D printer to quickly establish a 1:1 3D solid fracture model (Figure 1). The model was used to reconfirm the fracture type. The fracture blocks were carefully analyzed under direct vision, especially for articular

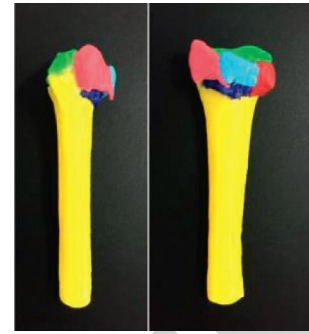

FIGURE 1: 3D printed solid model visually showing fracture morphology.

dislocations that were not directly visible on ordinary X-rays and CT (Figure 2).

- (3) Using professional Mimics software to reconstruct the 3D model and *in vitro* stimulation operation, grey segmentation extracts the area of the bone boundary contour. The area segmentation extracts the information area of each fracture again. Each bone block was transformed into an individual and assigned a colour. The 3D model is then reconstructed (Figure 3). One by one, the displaced bone pieces were simulated reduction to restore the distal hip and knee anatomy (Figure 4). The parameters of the anatomic distal volar locking hip and knee plate (DVRTM system) and screws were all imported into the software database. The implant model with millimetre accuracy was removed and placed on the distal volar side of the hip and knee for simulated internal fixation. To confirm that the fracture was satisfactorily reduced, that the implant was in an ideal position, and that no screws were inserted into the joint cavity, all screw lengths and plate specifications were measured and recorded. According to the simulated operation situation, the individualized operation plan is made for each patient for reference in the actual operation.

### 2.4. Surgical Methods

**2.4.1. Actual Operation.** Brachial plexus or general anaesthesia was used. The patient was placed supine, the affected limb was abducted on the side table, the upper arm was strapped with a balloon tourniquet, and the routine disinfection towel was spread. A skin incision approximately 8 cm long was made along with the flexor carpi radialis muscle on the volar side of the distal forearm. At the radial anatomy of the flexor carpi radialis tendon, pay attention to protect the radial artery and median nerve and pull the flexor carpi radialis tendon to the ulnar side; the flexor pollicis longus is separated at the beginning of the radius and retracted to the ulnar side to expose the front rotator. A lateral incision of about 2.0 cm was made on the distal anterior pronator muscle to expose the broken end of the fracture and



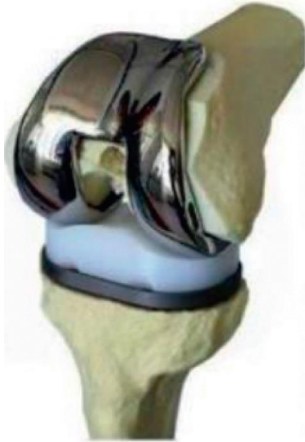

FIGURE 2: 3D printed solid model showing the joint surface directly.

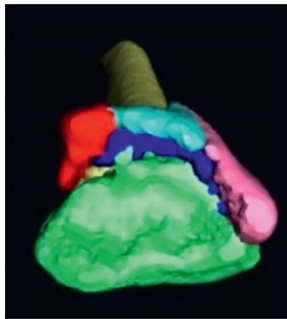


FIGURE 3: *In vitro* stimulation of the morphology before surgery.

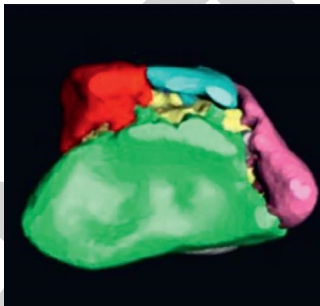


FIGURE 4: *In vitro* stimulation of the morphology after surgical reduction.

determine the “watershed” of the distal radius to verify the displacement of the fractured mass. In strict accordance with the surgical plan, each fracture block was reduced successively to restore the original radius length, palmetto angle, and ulnar deflection angle. The distal end of the plates did not exceed the “watershed” of the distal radius. The plate was fixed with a built-in screw in the sliding hole, followed by a distal locking screw and a proximal cortical screw. The simulated surgical records and fluoroscopy verified the length of the screw. If the defect is severe, artificial bone or autologous bone graft is taken. In order to stop bleeding fully, the guide tube can be left and the incision can be closed.

**2.4.2. Postoperative Treatment.** Routine prophylactic antibiotics were used for one day after surgery, and detumescence and analgesia were administered simultaneously. DVRTM plates were selected according to the specifications determined in the simulated operation. They were retrogradely implanted through the incision at the distal end of the anterior flexor muscle through the deep surface of the muscle. Negative pressure drainage is usually removed 24 hours after surgery. Patients are encouraged to do early functional exercise. From the second day after the operation, they start to actively move the fist, shoulder, elbow, and other joints of the affected side, and they start to move the wrist joints and strength training about six weeks after the operation. X-ray films were taken to guide functional exercise at 4, 8, and 12 weeks after the operation. At half year after surgery, the patient was evaluated by functional and radiological methods: the function of the affected wrist, fracture reduction, and healing. After that, they were followed up every three months.

**2.5. Observation Indicators.** The actual plate size, screw length, operative time, intraoperative blood loss, and postoperative fracture healing time were recorded, and the postoperative reduction effect and wrist function were evaluated.

**2.5.1. Wrist Function.** At the last follow-up, wrist function was assessed using Dienst criteria. No pain, no passive motion limitation, normal grip strength, active extension, and flexion range of motion reduction less than  $15^\circ$  is optimal. For patients with occasional pain, passive movement is slightly restricted, the function is basically normal, the grip strength is normal, and the dynamic range of the extensor and flexors is reduced by  $15^\circ \sim 30^\circ$ ; for patients who often feel pain, passive activity is slightly restricted, grip strength is significantly reduced, active activity is reduced by  $30^\circ \sim 50^\circ$ , and function is significantly weakened. Good rate = (good + good) cases/total cases  $\times 100\%$ .

**2.5.2. Reduction Effect and Judgment Standard.** The improved Sarmiento score was used to evaluate the resetting effect. The score is according to the degree of dorsal inclination of distal hip and knee joint, the degree of loss of radius height, and the degree of loss of ulnar declination angle: 0, 1, 2, and 4 points, the worse the reset, the higher the score; the three items are accumulated to get the total score of the improved Sarmiento system: 0 is excellent, 1~3 is good, 4~6 is ok, and 7~12 is bad. Good rate = (good + good) cases/total cases  $\times 100\%$ .

### 3. Research Results

The operation time of 50 patients was 50 min, and the intraoperative blood loss was 40 mL. The specifications of bone plates used in the actual operation were utterly consistent with the preoperative plan, and the accuracy of screw length was 98.5% (40 cases). The follow-up period was six

TABLE 1: 3D rapid prototyping time and operation time of 50 patients.

Category	The number of cases	The scope	The average
3D rapid prototyping time (h)	50	3–4	3.5
The operation time (min)	50	70–90	80

TABLE 2: Operation time and blood loss ( $x \pm s$ ).

	$n$	Operation time (min)	Operative blood loss (mL)
3D replacement	50	$114.5 \pm 12.5$	$381.2 \pm 90.5$
$t$		3.724	2.687
$P$		$\leq 0.001$	0.019

TABLE 3: Range of motion of the knee after surgery ( $x \pm s$ ).

	$n$	Before the operation	After the operation	$t$	$P$
3D replacement	50	$85.4 \pm 18.9$	$110.3 \pm 14.7$	-6.427	$\leq 0.001$
		0.267	0.191		
		0.798	0.824		

months. All fractures healed successfully with a healing time of  $8.7 \pm 1.1$  weeks. In terms of imaging, X-ray films were taken during follow-up six months after surgery to measure the reduction of distal hip and knee joint: the height of the radial styloid process was  $10.6 \pm 2.6$  mm. The palmar angle was  $11.3 \pm 3.4^\circ$ . The ulnar deflection was  $21.2 \pm 5.4^\circ$ . Among the 41 patients, the reduction effect was excellent in 27 cases, good in 11 cases, and fair in 3 cases, with an excellent and good rate of 92.7%. No loss of fracture reduction or loosening of the implant was observed by comparing with the X-ray immediately after operation. The overall excellent and reasonable rate of wrist function was 95.1%, in which 28 cases were excellent, 11 cases were good, and 2 cases were fair. No complications such as wound infection, median nerve injury, internal fixation failure, and tendon rupture were observed.

3D rapid prototyping time and operation time of 50 patients: the 1:1 3D rapid prototyping time of 50 patients was 3–4 hours and the mean 3D rapid prototyping time of the fracture model was 3.8 hours; the operation time was 70–90 min, with an average of 80 min, as shown in Table 1.

Surgical blood loss: the 3D operation time was short and the surgical blood loss was significantly less, as shown in Table 2.

The knee range of motion was significantly improved before and after surgery and two weeks after surgery, as shown in Table 3.

The preoperative CT scan results can be used for preoperative osteotomy planning, which is conducive to choosing prosthesis size and position. The hip and knee prosthesis is limited beyond the edge of the osteotomy surface in certain areas and does not increase short-term postoperative discomfort. When using anatomic hip and knee prosthesis, the rotation of the platform prosthesis can be determined according to the principle of optimal coverage.

The HSS score before and after surgery is shown in Figure 5.

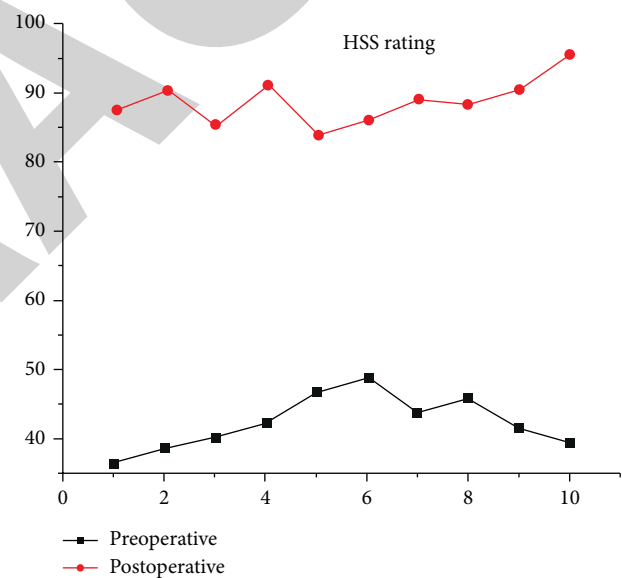


FIGURE 5: HSS score before and after replacement.

The hip and knee HSS scores of patients in the 3D printed osteotomy guide plate group and the positioning surgery group two weeks after surgery were statistically significant. 3D printing technology enables orthopaedic surgeons to intuitively understand the situation of the hip and knee before surgery, accurately guide the formulation of surgical plans, simulate the operation, and improve the accuracy of surgery.

#### 4. Conclusions

To study the application of 3D printing technology assisted CT thin-slice scan data in treating hip and knee joint replacement, 50 patients were studied before surgery. CT thin-layer scan was performed to obtain the reconstruction

technology. The 1:1 scale solid model was printed with the assistance of 3D printing technology. According to the 1:1 scale solid model of fracture, the clinician can choose the location of initial steel plate implantation and, at the same time, perform morphological pretreatment on the implanted plate. In the actual operation, the length and number of screws applied were the same as those in the simulated operation of the 3D printing model, and no incision soft tissue infection or reduction loss occurred in the 50 patients. The results show that CT thin-layer scan data aided 3D printing technology has high reliability in clinical planning. Based on the preliminary selection, modification, and editing, CT can separate the adjacent bone pieces one by one and divide the entire calcaneus of the patient into independent mask modules. In other words, the obtained 3D reconstruction data can be converted into STL form in the computer background. Then, the model can be printed. 3D model stage: the 1:1 fracture model 3D rapid prototyping time is 3-4 hours, the average fracture model 3D rapid prototyping time is 3.5 hours, the average operation time is 80 minutes, the overall ankle joint function of 50 patients recovered well, and the excellent rate was 96%. CT thin-layer scan assisted by 3D printing technology can further demonstrate the excellent matching rate between simulated surgery and actual intraoperative steel plate, reduce clinicians' impaired cognition of Google typing and spatial morphology, and shorten the operation time.

In summary, CT thin-layer scan data aided 3D printing technology can help in hip and knee replacement simulation and plan formulation and improve surgical accuracy and safety.

## Data Availability

The data used to support the findings of this study are available from the corresponding author upon request.

## Conflicts of Interest

The authors declare that they have no conflicts of interest.

## References

- [1] U. Lützen, C. M. Naumann, M. Marx et al., "A study on the value of computer-assisted assessment for SPECT/CT-scans in sentinel lymph node diagnostics of penile cancer as well as clinical reliability and morbidity of this procedure," *Cancer Imaging*, vol. 16, no. 1, p. 29, 2016.
- [2] N. Shohat, T. Bauer, M. Buttaro et al., "Hip and knee section, what is the definition of a p joint infection (PJI) of the knee and the hip? Can the same criteria be used for both joints?: pico infections," *The Journal of Arthroplasty*, vol. 34, no. 2, pp. S325–S327, 2019.
- [3] M. Jansen, A. Ooms, T. D. Turmezei, J. W. Mackay, and F. Lafeber, "Pos1092 subchondral bone normalization after knee joint distraction treatment as measured with ct," *Annals of the Rheumatic Diseases*, vol. 80, no. Suppl 1, pp. 825–826, 2021.
- [4] L Zhichen, J. Weijie, J Zhao, Y Chen, C Dongfeng, and C Zheng, "A retrospective study on the application of cemented polyethylene liner technique in hip revision," *Chinese Journal of Reparative and Reconstructive Surgery*, vol. 32, no. 9, p. 1, 2018.
- [5] S Yoshinori, S. Sakamoto, S Takemura, Y Wataru, M Shimura, and S Ishihara, "Study on the generation of the intermetallic compound and the whiskers observed in the double-layer plating system (sn/cu)," *Journal of the Japan Institute of Metals and Materials*, vol. 81, no. 5, pp. 226–233, 2017.
- [6] U. A. Usman, I. Yusoff, M. Raoov, Y. Alias, J. Hodgkinson, and N. Abdullah, "An integrated toolkit using multiple methods for determining the potential sources of iron and manganese in groundwater: a case study from the lower Kelantan river basin, Malaysia," *Environmental Earth Sciences*, vol. 80, no. 14, pp. 1–17, 2021.
- [7] M. Li, Z. Zhao, H. Li et al., "Study on engineering application and degradation efficiency of nanoscaled tio2 used as photocatalytic fog sealing," *Advances in Materials Science and Engineering*, vol. 2021, no. 4, 10 pages, Article ID 1379886, 2021.
- [8] A. Neubert, K. J. Wilson, C. Engstrom et al., "Comparison of 3d bone models of the knee joint derived from ct and 3t Mr imaging," *European Journal of Radiology*, vol. 93, no. 3, pp. 178–184, 2017.
- [9] K. A. Collins, "Periprosthetic joint infections of the hip and knee," *Physician Assistant Clinics*, vol. 6, no. 2, pp. 229–238, 2021.
- [10] H. Liu, F. Meng, and S. Hua, "4d mapping of the fracture evolution in a printed gypsum-like core by using x-ray ct scanning," *Advances in Civil Engineering*, vol. 2021, no. 3, 12 pages, Article ID 8820828, 2021.
- [11] H. Lu, H. Peng, Z. Peng, D. Liu, Q. Wu, and R. Liu, "The application of digital design combined with 3d printing technology in skin flap transplantation for fingertip defects during the covid-19 epidemic," *BioMed Research International*, vol. 2021, no. 2, 7 pages, Article ID 5554500, 2021.
- [12] M. Alazri, I. Al-Jubari, and A. R. Albattat, "The impact of strategic planning factors on service quality: an empirical study of private universities in Oman," *Journal of Asian Finance Economics and Business*, vol. 8, no. 7, pp. 557–569, 2021.
- [13] K. Yang, K. Wu, J. Feng, L. Yutian, X. Zhu, and D. Xu, "Study on the antitumor effect and glycolysis of andrographolide in anaplastic thyroid carcinoma," *Evidence-based Complementary and Alternative Medicine*, vol. 2021, no. 1, 11 pages, Article ID 5526581, 2021.
- [14] S. Zhang and Z. Lv, "Diagnosis and exercise rehabilitation of knee joint anterior cruciate ligament injury based on 3d-ct reconstruction," *Complexity*, vol. 2020, no. 7, 13 pages, Article ID 3690124, 2020.
- [15] I. B. Zavialov, A. A. Osadchiv, P. O. Zavialov, V. V. Kremenskiy, and I. V. Goncharenko, "Study of water exchange in the Kerch strait based on historical data and contact measurements in 2019," *Oceanology*, vol. 61, no. 3, pp. 329–337, 2021.
- [16] Y. L. Li and X. P. Lai, "Comparative study on supplementary data of pharmaceutical patent between China and Europe," *Chinese Journal of New Drugs*, vol. 29, no. 17, pp. 1921–1926, 2020.
- [17] Z. Xue and S. Wei, "Study on the compositions and the value of knowledge-based GDP in China," *Open Journal of Social Sciences*, vol. 6, no. 1, pp. 246–256, 2018.
- [18] S. W. Qiu, M. Tu, F. Fan et al., "Age estimation in han adults by thin-layer ct scan of cranial sutures," *Fa Yi Xue Za Zhi*, vol. 36, no. 4, pp. 507–513, 2020.
- [19] Y. Wang, H. L. Teng, M. Y. Zhu, K. L. Huang, and C. W. Lin, "Clinical outcomes of endoscopic spinal surgery for tiny lumbar disc herniation with severe radiating pain of lower

limb,” *Zhongguo gu Shang = China journal of orthopaedics and traumatology*, vol. 33, no. 6, pp. 508–513, 2020.

- [20] F. Azadian, O. Asif, and A. C. Rastogi, “Flexible, thin-layer solid-state s based on V2O5-g composite electrode and ionic liquid gel polymer electrolyte for portable electronic systems,” *ECS Transactions*, vol. 97, no. 7, pp. 35–43, 2020.

RETRACTED