

## *Retraction*

# **Retracted: Effectiveness and Prognosis: Drainage Skin-Bridge Sparing Surgery Combined with Fistulotomy versus Fistulotomy Only in the Treatment of Anal Fistula**

### **Journal of Healthcare Engineering**

Received 14 November 2022; Accepted 14 November 2022; Published 25 January 2023

Copyright © 2023 Journal of Healthcare Engineering. This is an open access article distributed under the Creative Commons Attribution License, which permits unrestricted use, distribution, and reproduction in any medium, provided the original work is properly cited.

*Journal of Healthcare Engineering* has retracted the article titled “Effectiveness and Prognosis: Drainage Skin-Bridge Sparing Surgery Combined with Fistulotomy vs. Fistulotomy Only in the Treatment of Anal Fistula” [1] due to concerns that the peer review process has been compromised.

Following an investigation conducted by the Hindawi Research Integrity team [2], significant concerns were identified with the peer reviewers assigned to this article; the investigation has concluded that the peer review process was compromised. We therefore can no longer trust the peer review process, and the article is being retracted with the agreement of the Chief Editor.

The authors do not agree with the retraction.

### **References**

- [1] X. Wang, C. Wang, and R. Qi, “Effectiveness and Prognosis: Drainage Skin-Bridge Sparing Surgery Combined with Fistulotomy versus Fistulotomy Only in the Treatment of Anal Fistula,” *Journal of Healthcare Engineering*, vol. 2021, Article ID 6940072, 7 pages, 2021.
- [2] L. Ferguson, “Advancing Research Integrity Collaboratively and with Vigour,” 2022, <https://www.hindawi.com/post/advancing-research-integrity-collaboratively-and-vigour/>.

## Research Article

# Effectiveness and Prognosis: Drainage Skin-Bridge Sparing Surgery Combined with Fistulotomy versus Fistulotomy Only in the Treatment of Anal Fistula

Xiao Wang , Chunliang Wang, and Ruihua Qi

Department of Anorectal Surgery, The First People's Hospital of Fuyang Hangzhou, Hangzhou, Zhejiang 311400, China

Correspondence should be addressed to Xiao Wang; wangxiao@st.btbu.edu.cn

Received 3 August 2021; Revised 28 August 2021; Accepted 4 September 2021; Published 28 November 2021

Academic Editor: Osamah Ibrahim Khalaf

Copyright © 2021 Xiao Wang et al. This is an open access article distributed under the Creative Commons Attribution License, which permits unrestricted use, distribution, and reproduction in any medium, provided the original work is properly cited.

**Objective.** This study intends to analyze the difference in the efficacy of drainage skin-bridge sparing surgery combined fistulotomy (DSCF) and fistulotomy alone. **Methods.** 125 patients with anal fistula were enrolled as study subjects and randomly divided into control group (CG) and observation group (OG) by double-blind lottery. The CG received drainage skin-bridge sparing surgery with fistulotomy and the OG received fistulotomy only. **Results.** The VAS scores of the trauma in the OG were lower than those in the CG on 1st day of surgery and 7 days after surgery ( $P < 0.05$ ). The length of hospital stay and time to wound healing were shorter in the OG than in the CG ( $P < 0.05$ ). The incidence of postoperative bleeding in the OG was 9.52%, which was lower than 22.58% in the CG ( $P < 0.05$ ). The rectal examination scores were lower in the OG than in the CG at 3 and 5 days postoperatively ( $P < 0.05$ ). The Wexner scores of solid incontinence (0 to 4), liquid incontinence (0 to 4), gas incontinence (0 to 4), pad wearing (0 to 4), and lifestyle alteration (0 to 4) in the OG were lower than those of the CG at 5 days postoperatively ( $P < 0.05$ ). Voiding function scores were lower in the OG than in the CG at 2 and 3 days postoperatively ( $P < 0.05$ ). **Conclusions.** The efficacy of drainage skin-bridge sparing surgery combined fistulotomy is better than that of fistulotomy alone, which can accelerate postoperative healing, enhance urinary function, reduce postoperative bleeding, and improve anal function.

## 1. Introduction

Anal fistula (AF) is a chronic abnormal communication between the epithelialized surface of the anal canal and usually the perianal skin. It can be described as a narrow tunnel with its internal opening in the anal canal and its external opening in the skin near the anus [1, 2]. AF is more common in young and middle-aged men than in women, with data indicating that the frequency of AF is at least five times greater in men than in women [3]. If not treated aggressively, AF could lead to recurrent episode of infection, so that a simple fistula can progress to a complex fistula [4]. Studies have found that treatment option for AFs should focus on minimizing damage to the sphincter, eliminating the internal opening, and promoting epithelialization transformation [5] in addition to aggressive control of the condition. Previously, AF was mostly treated by fistula

removal, which was effective in removing the fistula, but due to the long incision, a significant scar was left after surgery and the patient will experience a long recovery period [6]. The drainage skin-bridge sparing surgery explores the exact trajectory of the fistula tract by probing, finger palpation, anoscopy, and methylene blue reduction test to determine the correlation between the sphincter and the operative site, and this procedure can completely remove the deep necrotic cavity, reduce scar tissue, and accelerate wound healing [7, 8].

However, drainage skin-bridge sparing surgery has been the most often used therapy for AF [9, 10], and there are few researches on whether DSCF coupled with fistulotomy may enhance the effectiveness of AF treatment. The purpose of this research was to evaluate the results of fistulotomy alone vs DSCF in conjunction with fistulotomy in 125 individuals with AF.

## 2. Materials and Methods

**2.1. Data.** One hundred and twenty-five patients with AF were enrolled for the study. Inclusion criteria: age >18 years, clinical examination showing fistula formation, simple AF, fistula length <2 cm, knowledge of the present study, signed informed consent, and obtained ethical approval from their hospital. Exclusion criteria: comorbid severe primary disease, long-term use of platelet aggregation inhibitors, coagulation dysfunction, comorbid infectious diseases, complicated AF, previous surgical treatment of the anal area, comorbid perianal skin disease, and comorbid other intestinal diseases.

### 2.2. Methods

**2.2.1. Observation Group (OG).** Preoperative anoscope was used to identify the precise position, course, and connection of the fistula to the sphincter, as well as the location of the internal opening in the observation group (OG). Spinal-epidural anesthesia was induced under the lithotomy position. A circular incision with a diameter of about 1.0 cm was made around the outer opening of the fistula. The tube wall and adjacent tissues were separated using sharp and blunt peeling following the trajectory of the fistula. Be cautious to retaining the skin above the fistula and the normal subcutaneous tissue. Moreover, a circular incision of approximately 1 cm was made above the AF, and the skin and subcutaneous tissue were incised up to the fistula wall, through which the stripped fistula tissue was retracted, and the fistula tissue was continuously peeled to the anus without damaging the anal sphincter. The fistula is excised after identifying the location of the internal opening, and the internal opening is raised near to the mucosa and ligated. With rubber strips drainage, the breadth of the skin bridge between incisions varied from 0.5 cm to 2.0 cm. If the patient's fistula was long, multiple incisions could be made to preserve multiple skin bridges, and the incisions were trimmed appropriately to keep the wound surface flat and ensure unobstructed drainage, and rubber strips were placed on all incisions for drainage. 24 h postoperatively, the anal filling was removed and the medication was changed, once in the morning and once in the evening. When changing the medication at the preserved skin bridges, the rubber strips were removed when fresh granulation developed beneath the skin bridges and was leveled with the skin bridges, and special care was given to disinfecting the surrounding skin bridges.

**2.2.2. Control Group (CG).** Only AF removal surgery was performed with the same method in the OG to explore the AF and internal opening. During the operation, all fistulas and internal openings are incised, and the internal opening and adjacent tissues are thoroughly removed. The cavity is scraped to completely remove the necrotic tissue, and the wound is trimmed into an inverted "U" shape to maintain unobstructed drainage. The postoperative dressing change was the same as that of the OG.

**2.3. Outcome Measurement.** The pain level of the trauma was evaluated on the day of surgery and 3 days, 5 days, and 7 days after surgery using Visual Analogue Scale (VAS) [11], respectively, ranging 0–10. The higher the score, the more severe the pain.

The time period from the day of surgery and discharge by fulfilling the discharge criteria, which include a trauma pain score of less than 3, well-grown new granulation at the trauma's base, no abnormal discharge, and regular urine and faeces. Wound healing time is the interval from the day of surgery to complete epithelialization of the wound.

Postoperative infection and trauma bleeding criteria [12]: purulent secretion oozing from the base of the trauma, local swelling, redness, warmth, pain, marked tenderness, and even elevated white blood cell count and fever manifestations. Traumatic hemorrhage criteria: bloody discharge oozing from the trauma surface or direct blood flow. All patients were compared during an observation period of 2 weeks postoperatively.

Rectal examination scores [13]: score 0: all anal functions returned to normal and the finger could be wrapped tightly; score 1: the anus could contract normally, but the finger could not be fully wrapped; score 2: the anus could contract normally, but the finger could feel a little pressure; score 3: the anus could not contract normally. The evaluations were performed 1 day before surgery, upon surgery, and 3 days, 5 days, and 7 days after surgery, respectively.

Functional evaluation of anal incontinence was evaluated with Wexner scale [14], which covers solid incontinence (0 to 4), liquid incontinence (0 to 4), gas incontinence (0 to 4), pad wearing (0 to 4), and lifestyle alteration (0 to 4). Each item was scored on a 0–4 scale, indicating never, rarely, sometimes, often, and always. The evaluations were performed immediately after surgery and five days afterwards.

Voiding function [15] was assessed on a scale of 0–3. Score 0: could urine on its own after surgery without any assistance, score 1: could urine only when listening to the sound of running water or applying heat to the bladder, score 2: only could urine smoothly with medication (neostigmine intramuscular), score 3: catheterization is required. The assessment was done 1 day before surgery, during surgery, 2 days after surgery, and 3 days following surgery, in that order.

**2.4. Statistical Methods.** Statistical analysis was performed with SPSS 23.0. Count data were expressed as ( $n$  (%)) and examined by  $X^2$  test. Measures were expressed as ( $\bar{x} \pm s$ ) and examined by  $t$ -test. Multipoint comparisons were analyzed with ANOVA with post hoc  $F$  test. Figures were produced with GraphPad Prism 8.  $P < 0.05$  was considered statistically significant.

## 3. Results

**3.1. General Information.** There was no statistical difference in the gender, AF type, mean age, mean body mass index (BMI), and mean duration between the two groups ( $P > 0.05$ ) (Table 1).

TABLE 1: Comparison of baseline data ( $\bar{x} \pm s$ )/(n (%)).

Data	Observation group (n = 63)	Control group (n = 62)	t/X <sup>2</sup>	P value	
Gender	Male	51 (80.95)	52 (83.87)	0.184	0.668
	Female	12 (19.05)	10 (16.13)		
Age (years)	45.62 ± 15.28	47.31 ± 14.94	0.625	0.533	
BMI (kg/m <sup>2</sup> )	22.43 ± 1.69	22.39 ± 1.57	0.137	0.891	
Duration of illness (years)	2.18 ± 1.43	2.32 ± 1.51	0.532	0.596	
Types of anal fistula	High grade	37 (58.73)	34 (54.84)	0.193	0.661
	Low grade	26 (41.27)	28 (45.16)		

3.2. *Pain Level.* VAS scores for trauma pain were significantly lower in the OG than in the CG upon surgery ( $P < 0.05$ ), and VAS scores decreased significantly in both groups on postoperative days 3, 5, and 7 compared with the postoperative day ( $P < 0.05$ ), but the difference between groups on postoperative days 3 and 5 was not statistically significant ( $P > 0.05$ ), and VAS scores were significantly lower in the OG than in the CG at 7 days postoperatively ( $P < 0.05$ ) (Figure 1).

3.3. *Length of Hospital Stay and Wound Healing Time.* The hospital stay was ( $13.25 \pm 2.69$ ) days in the OG and ( $19.94 \pm 3.46$ ) days in the CG, and the wound healing time was ( $16.86 \pm 2.61$ ) days in the OG and ( $24.94 \pm 4.19$ ) days in the CG ( $P < 0.05$ ). The hospitalization time and wound healing time of the OG were shorter than those of the CG (Figure 2).

3.4. *Postoperative Infection and Bleeding Rates.* Three patients in the OG had postoperative infection, with an infection rate of 4.76%, and four patients in the CG had postoperative infection, with an infection rate of 6.45%. The difference in infection rate between the two groups was not statistically significant ( $P > 0.05$ ). Six patients in the OG had postoperative bleeding, with a 9.52 percent bleeding rate, whereas 14 patients in the CG had postoperative bleeding, with a 22.58 percent bleeding rate. The postoperative bleeding rate in the OG was lower than that in the CG ( $P < 0.05$ ) (Table 2).

3.5. *Evaluation of the Anal Function.* There was no statistically significant difference in the anal function scores between the two groups on the preoperative day 1 ( $P > 0.05$ ), and the anal function scores gradually decreased in both groups on the postoperative day, day 3, day 5, and day 7, and the difference between the scores upon the surgery and the preoperative day 1 was not significant between the two groups ( $P > 0.05$ ). The OG scores on postoperative days 3, 5, and 7 were lower than the preoperative day 1 values ( $P < 0.05$ ). The CG scores on postoperative days 5 and 7 were lower than on preoperative day 1 ( $P < 0.05$ ); The postoperative day 3 and 5 scores in the OG were lower than those of the CG ( $P < 0.05$ ), and the scores between the two groups at 7 days postoperatively were not statistically significant ( $P > 0.05$ ) (Figure 3).

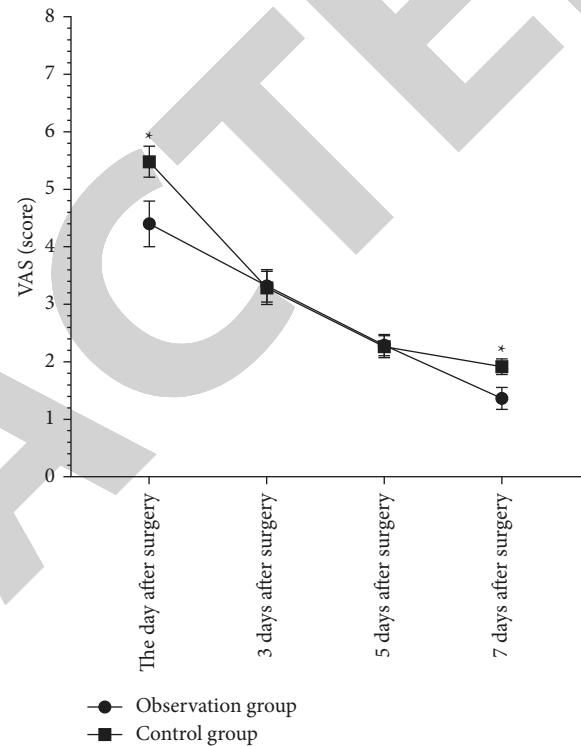


FIGURE 1: Traumatic pain. Compared with the control group, VAS scores on the day of surgery and 7 days after surgery were lower in the observation group ( $P < 0.05$ ) VAS scores at 3 and 5 days after surgery were not significantly different from those in the observation group ( $P > 0.05$ ). \* $P < 0.05$ .

3.6. *Functional Evaluation of Anal Incontinence.* Wexner scores were not statistically different upon the day of surgery between the two groups ( $P > 0.05$ ) and were reduced in both groups ( $P < 0.05$ ) while Wexner scores were lower in the OG than in the CG ( $P < 0.05$ ) (Figure 4).

3.7. *Urinary Function Evaluation.* There was no significant difference in the voiding function scores between the two groups 1 day before surgery ( $P > 0.05$ ). The voiding function scores in both groups gradually decreased at 2 and 3 days after surgery and were lower in the OG than in the CG ( $P < 0.05$ ) (Figure 5).

## 4. Discussion

Fistulotomy is performed by removing the entire fistula, ligating the internal opening, and ligating the inflamed tissue around the internal opening to reconstruct normal perianal

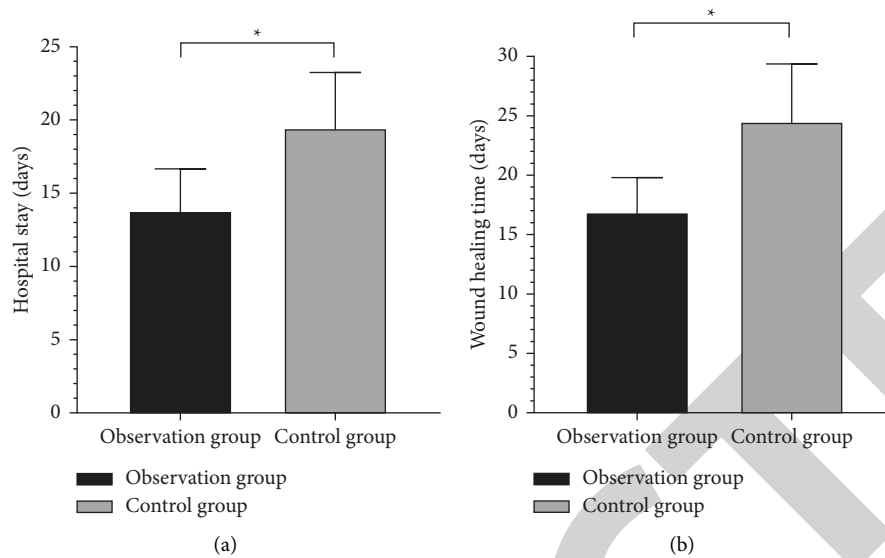


FIGURE 2: Length of stay and wound healing time. Compared with the control group, the length of stay (a) and wound healing time (b) were shorter in the observation group ( $P < 0.05$ ).  $*P < 0.05$ .

TABLE 2: Comparison of postoperative infection and bleeding rates ( $n$  (%)).

Grouping	Number of cases	Infection	Hemorrhage
Observation group	63	3 (4.76)	6 (9.52)
Control group	62	4 (6.45)	14 (22.58)
$X^2$		0.001	3.964
$P$ value		0.983	0.046

skin [16]. This treatment concentrated on the internal opening and fistula, not only to guarantee that the internal opening was ligated and the fistula was completely removed but also to retain normal perianal tissue and maintain anal defecation function [17]. However, studies have also found that fistulotomy is associated with a higher risk of postoperative complications such as fluid discharge, air discharge, and anal deformities due to the large incision [18, 19]. It was found that scarring following fistula removal is more pronounced and patients tend to have a low acceptance towards the quality of cosmetic recovery [20].

By maintaining the skin bridge over the fistula and draining the fistula using rubber strips, the drainage skin-bridge sparing operation coupled with fistula removal differs from simple fistula excision, thus eliminating the need for full incision of the fistula causing tissue damage, resulting in low level of pain and more rapid reduction of postoperative pain [8, 21]. In this study, the trauma VAS scores were lower in the OG than in the CG upon the day of surgery and at 7 days postoperatively, but there was no significant difference within the CG at 3 and 5 days postoperatively, suggesting that the combined procedure can exert pain control earlier than a single fistula removal and that pain can be eliminated more rapidly. Similar data indicate that for AFs, fistula excision coupled with drainage skin-bridge surgery significantly decreases postoperative discomfort [21]. In this study, the length of hospital stay and trauma healing time were shorter in the OG than in the CG, which shows that

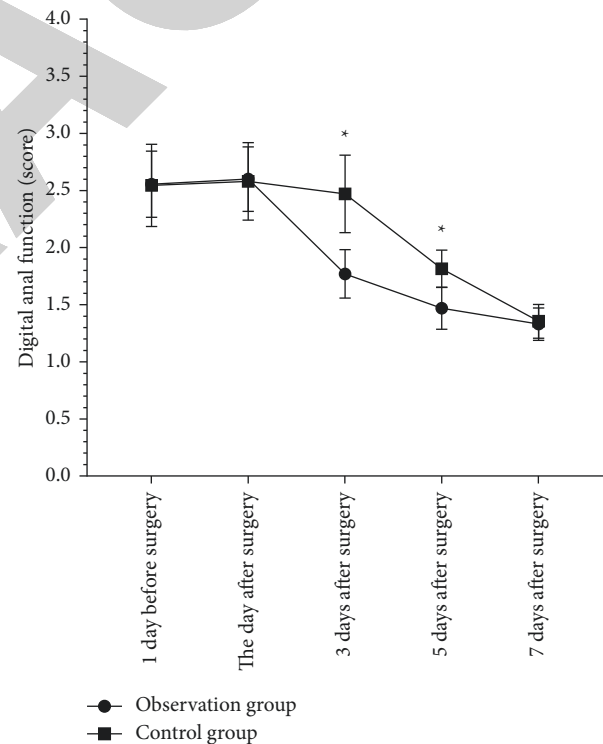


FIGURE 3: Rectal examination. Anal function ratings did not vary from the control group 1 day before surgery, 1 day after surgery, or 7 days after surgery ( $P > 0.05$ ). Compared with the control group, anal function scores at 3 and 5 days after surgery were lower in the observation group ( $P < 0.05$ ).  $*P < 0.05$ .

combined drainage skin-bridge preservation in addition to fistula excision can accelerate the postoperative recovery of patients and promote healing. The reason may be that the large incision was replaced by multiple small incisions with subcutaneous communication, significantly reduced trauma,

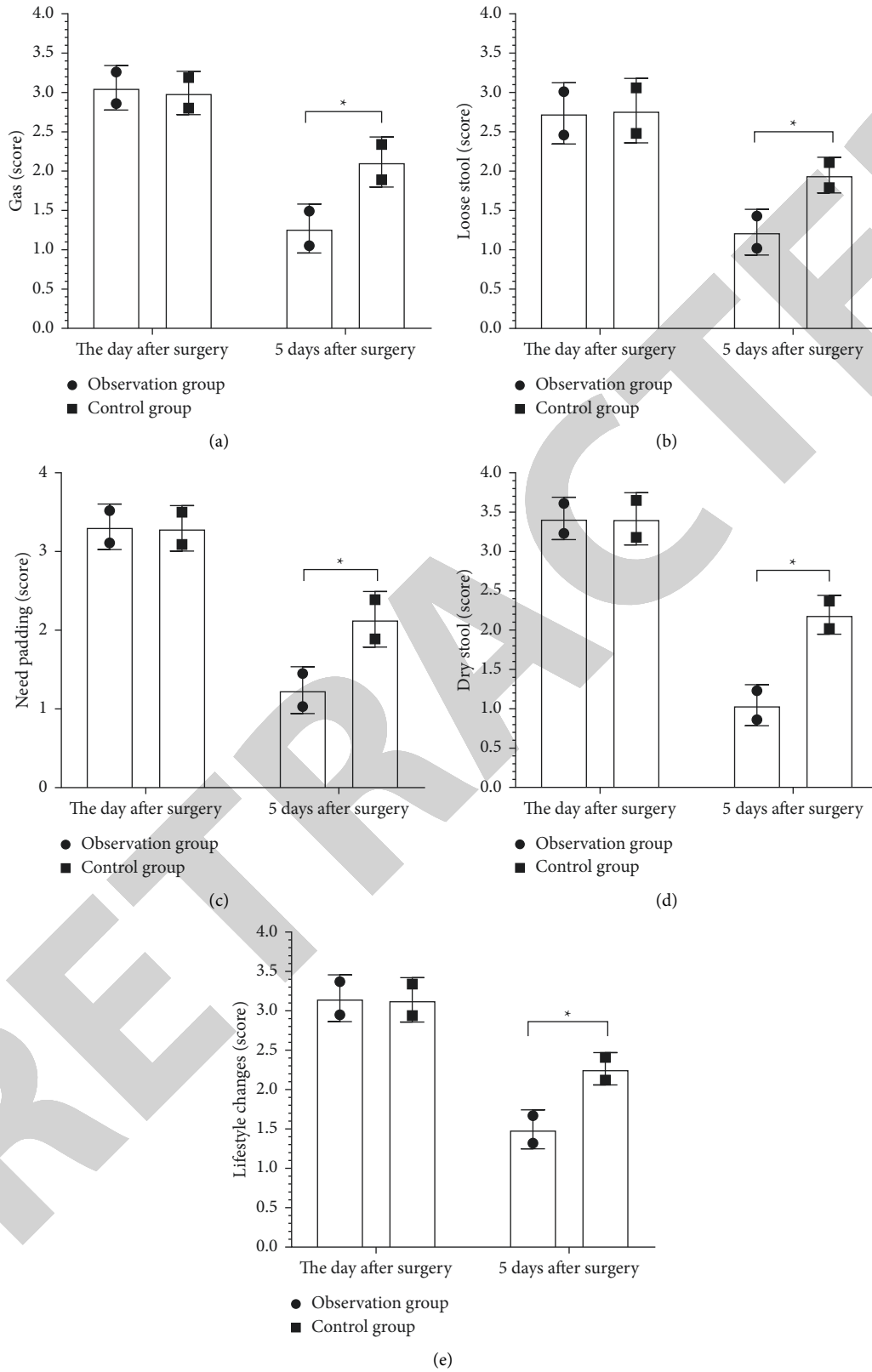


FIGURE 4: Wexner score. Compared with the control group on the day after surgery gas incontinence (a), liquid incontinence (b), pad wearing (c), solid incontinence (d), and lifestyle change (e) scores, all differences were small ( $P > 0.05$ ), and all scores were lower ( $P < 0.05$ ) in the observation group compared with the control group 5 days after surgery. \* $P < 0.05$ .



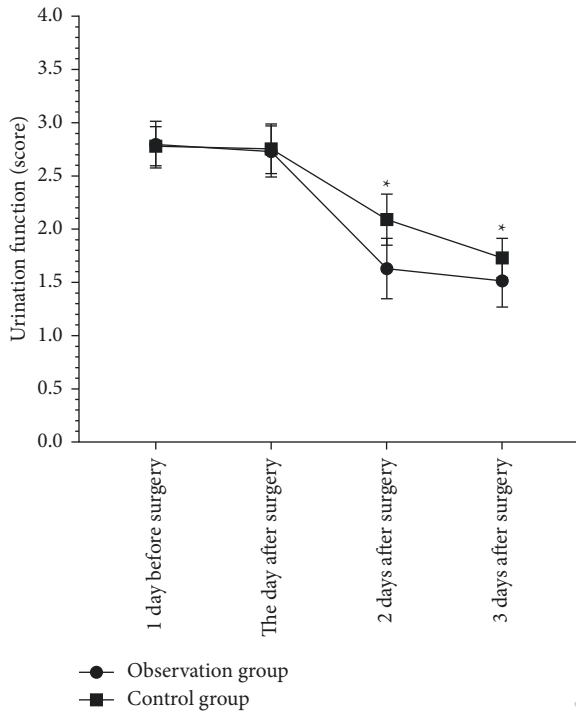


FIGURE 5: Voiding function. Compared with the control group, voiding function scores did not differ between 1 day before surgery and the day after surgery ( $P > 0.05$ ). Compared with the control group, voiding function scores at 2 and 3 days after surgery were lower in the observation group ( $P < 0.05$ ). \* $P < 0.05$ .

reduced bleeding, and growth of the skin margin to both sides, thus the trauma could heal more rapidly and the time required for healing was significantly shortened [22]. In this study, the postoperative infection rate in the OG was not significantly different from that in the CG. However, the postoperative bleeding rate in both groups was substantially lower than in the CG, indicating that the operation has a high safety profile in both groups and that treatment safety may be further enhanced by combining procedures, and the patients have less postoperative bleeding, which could facilitate recovery. This outcome was also associated with smaller trauma, which could be recovered more rapidly. Fistula removal combined with drainage skin-bridge preservation treatment can reduce postoperative infection and bleeding more significantly than single removal [23], which differs results of the present study, which may be caused by fine and accurate operation when performing fistula removal in the present study, thus ensuring higher quality of improvement.

In this study, there was no significant difference in anal function score and urinary function score between the day of surgery and 1 day before surgery in the OG. The reason may be that the pain on the day of surgery affected the anal function and urinary function to some extent, resulting in no significant difference in the scores before and after surgery. In contrast, the score of the OG decreased significantly at 3 days after surgery compared with that before surgery, while that of the CG decreased significantly from 5 days after surgery, suggesting that combined procedures could

accelerate the recovery of anal function, and the anal function scores of the two groups were not significantly different at 7 days after surgery since their anal function was close to normal then in both groups. The urinary function scores were lower in the OG than in the CG at 2 and 3 days postoperatively, suggesting that combined procedures produce faster recovery of the patient's urinary function in the same time period. In this study, the differences in Wexner scores between the two groups were not significant, which was also related to the fact that severe pain significantly affected anal function on the day after surgery, whereas all scores were lower in the OG than in the CG at 5 days after surgery, indicating that combined procedures provided more rapid relief of anal incontinence and anal function, which is consistent with the results of studies described above. It was also found that the combined procedures maintain good postoperative anal function and urination and patients will not experience significant anal incontinence [24]. The reason may be that the fact that the combined surgical surgery provides better pain control, and the reduction of pain allows the patient to urinate smoothly. Since the surgical trauma is small and does not create serious damage to the anal muscle tissue, the impact on anal function is significantly reduced and postoperative anal the function can be recovered more rapidly.

In conclusion, DSCF combined with fistula removal for the treatment of AF can accelerate postoperative healing, reduce postoperative bleeding, improve urinary function, and improve anal function compared with fistulotomy alone. However, this study included small sample size, resulting in the lack of sufficient representativeness of the study results, which needs to be further improved.

## Data Availability

The data used to support the findings of this study are included within the article.

## Conflicts of Interest

The authors declare that they have no conflicts of interest.

## References

- [1] J. Sugrue, J. Nordenstam, H. Abcarian et al., "Pathogenesis and persistence of cryptoglandular anal fistula: a systematic review," *Techniques in Coloproctology*, vol. 21, no. 6, pp. 425–432, 2017.
- [2] T. Yamamoto, P. G. Kotze, A. Spinelli, and R. Panaccione, "Fistula-associated anal carcinoma in Crohn's disease," *Expert Review of Gastroenterology and Hepatology*, vol. 12, no. 9, pp. 917–925, 2018.
- [3] A. Lauretta, N. Falco, E. Stocco, R. Bellomo, and A. Infantino, "Anal fistula laser closure: the length of fistula is the achilles' heel," *Techniques in Coloproctology*, vol. 22, no. 12, pp. 933–939, 2018.
- [4] P. Garg and P. Singh, "Video-assisted anal fistula treatment (VAAFT) in cryptoglandular fistula-in-ano: a systematic review and proportional meta-analysis," *International Journal of Surgery*, vol. 46, pp. 85–91, 2017.

- [5] Y. Nasser, L. Cassella, M. Berns, K. Zaghiyan, and J. Cohen, "The anal fistula plug in Crohn's disease patients with fistula-in-ano: a systematic review," *Colorectal Disease*, vol. 18, no. 4, pp. 351–356, 2016.
- [6] M. Barabino, A. Gatti, R. Santambrogio et al., "Biliary fistula after liver resection: central role of intraoperative perihepatic drain," *Minerva Chirurgica*, vol. 71, pp. 353–359, 2016.
- [7] F. Fang, Z. Zhang, K. Wang, F. Wang, H. P. Zheng, and Y. Zhuang, "The skin bridge is more important as an additional venous draining route in a perforator-plus flap," *Journal of Surgical Research*, vol. 234, pp. 40–48, 2019.
- [8] N. P. Brodin, K. J. Mehta, A. Basavatia et al., "A skin dose prediction model based on in vivo dosimetry and ultrasound skin bridge measurements during intraoperative breast radiation therapy," *Brachytherapy*, vol. 18, no. 5, pp. 720–726, 2019.
- [9] G. Melich, A. Pai, B. Balachandran, S. J. Marecik, L. M. Prasad, and J. J. Park, "Endoscopic control of enterocutaneous fistula by dual intussuscepting stent technique," *Surgical Endoscopy*, vol. 30, no. 9, pp. 4150–4151, 2016.
- [10] M. D. Ray, P. K. Garg, A. Jakhethiya, S. Kumar, and D. Pandey, "Modified skin bridge technique for ilio-inguinal lymph node dissection: a forgotten technique revisited," *World Journal of Methodology*, vol. 6, no. 3, pp. 187–189, 2016.
- [11] G. Z. Heller, M. Manuguerra, and R. Chow, "How to analyze the visual analogue scale: myths, truths and clinical relevance," *Scandinavian Journal of Pain*, vol. 13, no. 1, pp. 67–75, 2016.
- [12] M. Honkanen, E. Jämsen, M. Karppelin, R. Huttunen, O. Lyytikäinen, and J. Syrjänen, "Concordance between the old and new diagnostic criteria for periprosthetic joint infection," *Infection*, vol. 45, no. 5, pp. 637–643, 2017.
- [13] T. K. Rajab, L. G. Bordeianou, A. von Keudell, H. Rajab, and H. Zhou, "Digital rectal examination and anoscopy," *New England Journal of Medicine*, vol. 378, no. 22, p. e30, 2018.
- [14] V. Slavin, J. Gamble, D. K. Creedy, and J. Fenwick, "Perinatal incontinence: psychometric evaluation of the international consultation on incontinence questionnaire-urinary incontinence short form and Wexner scale," *Neurourology and Urodynamics*, vol. 38, no. 8, pp. 2209–2223, 2019.
- [15] L. Yang, A. S. Kibel, G. A. Colditz et al., "Caution with use of the EPIC-50 urinary bother scale: how voiding dysfunction modifies its performance," *The Journal of Urology*, vol. 198, no. 6, pp. 1397–1403, 2017.
- [16] L. Zheng, J. Lu, Y. Pu, C. Xing, and K. Zhao, "Comparative study of clinical efficacy between video-assisted anal fistula treatment and traditional fistula resection plus seton in treatment of complex anal fistula," *Zhonghua Wei Chang Wai Ke Za Zhi*, vol. 21, pp. 793–797, 2018.
- [17] M. C. Giglio, D. R. C. Spalding, A. Giakoustidis et al., "Meta-analysis of drain amylase content on postoperative day 1 as a predictor of pancreatic fistula following pancreatic resection," *British Journal of Surgery*, vol. 103, no. 4, pp. 328–336, 2016.
- [18] C. Chattot, P. Aristizabal, S. Bendifallah, and E. Darai, "Uteroabdominal wall fistula after cesarean section in a patient with prior colorectal resection for endometriosis: a case report and systematic review," *Journal of Minimally Invasive Gynecology*, vol. 24, no. 7, pp. 1234–1238, 2017.
- [19] Q. Zhong, Z. Yuan, T. Ma et al., "Restorative resection of radiation rectovaginal fistula can better relieve anorectal symptoms than colostomy only," *World Journal of Surgical Oncology*, vol. 15, no. 1, p. 37, 2017.
- [20] A. L. Chiang, A. C. Storm, H. Aihara, and C. C. Thompson, "Endoscopic full-thickness resection of fistula tract with suture closure," *Endoscopy*, vol. 50, pp. E15–E16, 2018.
- [21] F. Carannante, G. Mascianà, S. Lauricella, M. Caricato, and G. T. Capolupo, "Skin bridge loop stoma: outcome in 45 patients in comparison with stoma made on a plastic rod," *International Journal of Colorectal Disease*, vol. 34, no. 12, pp. 2195–2197, 2019.
- [22] C. Lin, T. Reece-Nguyen, and B. C. H. Tsui, "A retrograde tunnelling technique for regional anesthesia catheters: how to avoid the skin bridge," *Canadian Journal of Anesthesia*, vol. 67, no. 4, pp. 489–490, 2020.
- [23] M. D. Ray, A. Jakhethiya, S. Kumar, A. Mishra, S. Singh, and N. K. Shukla, "Minimizing post-operative complications of groin dissection using modified skin bridge technique: a single-centre descriptive study showing post-operative and early oncological outcomes," *World Journal of Surgery*, vol. 42, no. 10, pp. 3196–3201, 2018.
- [24] S. H. Emile, H. Elfeki, and M. Abdelnaby, "A systematic review of the management of anal fistula in infants," *Techniques in Coloproctology*, vol. 20, no. 11, pp. 735–744, 2016.